

We are IntechOpen, the world's leading publisher of Open Access books Built by scientists, for scientists

6,900

Open access books available

186,000

International authors and editors

200M

Downloads

Our authors are among the

154

Countries delivered to

TOP 1%

most cited scientists

12.2%

Contributors from top 500 universities



WEB OF SCIENCE™

Selection of our books indexed in the Book Citation Index
in Web of Science™ Core Collection (BKCI)

Interested in publishing with us?
Contact book.department@intechopen.com

Numbers displayed above are based on latest data collected.
For more information visit www.intechopen.com



Introductory Chapter: Etiology, Diagnostic, and Treatment Procedure at Traumatic Cases in Dentistry

Serdar Gözler

1. Introduction

Dental trauma presents one of the most important situations where clinicians are called upon to make unscheduled diagnostic and treatment approaches in an area that is outside their routine experience. Guidelines have been outlined for management of numerous dental and medical conditions. Traumatic cases in dentistry are classified by many sources; however, the World Health Organization's (WHO) classification system is the most comprehensive system which allows for minimal subjective interpretations. The WHO traumatic classification system is built up according to the following situations [1]:

1. Fracture of enamel of tooth,
2. Fracture of crown without pulpal involvement,
3. Fracture of crown with pulpal involvement,
4. Fracture of root of tooth,
5. Fracture of crown together with the root,
6. Unspecified tooth fracture,
7. Tooth luxation,
8. Intrusion and/or extrusion of teeth
9. Avulsion of teeth,
10. Other type of injuries including burns and laceration.

Most of the reported traumatic cases come from falls while children play [2]. At the present time, the dental trauma term must also be included for dental treatment sourced from traumatic cases. There are various invasive restorative dental treatment models in modern dentistry at the present time. For example, dental implant treatments, tissue repair purpose treatments, augmentations of maxillary sinuses,

and full mouth ceramic restoration treatments are restorative treatments which have extreme trauma risks.

Traumatic cases need urgent diagnosis and quick treatment. However, according to a review article by Andrease et al., there are few studies showing a positive relationship between treatment delay and pulpal and periodontal ligament healing complications [3]. Practical and most economic reasons are fulfilled such as demand for acute treatment (i.e. within a few hours) or delayed (i.e. after the first 24 hours) in traumatic cases. But it is commonly accepted that all injuries should be treated within few hours, for the comfort of the patient and also to reduce wound healing complications.

Another type of dental trauma is post-op developed traumatic cases which are based on bad occlusion usually. In many cases, sinus augmentation may be necessary; in this case, augmented sinus tissue must be supported by a biomaterial. Implants are placed when the biomaterial is set like a wall. The implants will bear occlusal forces after finishing implant-supported crowns. In some cases, biomaterial wall cannot bear the occlusal forces of implant-supported crowns and then collapses. That kind of problems is related to premature contact originated occlusal trauma. Traumatic occlusion is the most important reason for the breaking of the restorations or collapse of the operating area under the pressure of high occlusal load. Early occlusal contacts force the area with all cumulative occlusal pressure of the jaws. There may not be a problem if there is an adequate thickness set at the sinus augmentation. But in some cases, under the high occlusal forces, the biomaterial wall cannot bear the load and collapses consequently. Sometimes, sinus wall tears and the implant is mobilized to the far side of the sinus. The first action must take out the dislocated implant from the exposed sinus and repair the sinus wall. Generally, the accepted protocol is to wait after repair of the sinus area and then continue the implant treatment again [4, 5]. There are various approaches for the planning of dental implants: the number of implants, their locations, inclinations, quality of supporting bone, etc. In its wider sense, this includes considerations of multiple inter-related factors of ensuring adequate bone support, implant location number, length, distribution, and inclination, splinting, vertical dimension esthetics, occlusal schemes, and more [6]. Every different alternative of the planning of implant treatment will have a different effect on implant-supported restoration. The difference is related to the occlusal scheme of the prosthetic restoration.

Dentists must take their decisions according to their past experiences because the patients in avulsion are rare except children patients and emergency patients [7]. Additionally, clinicians must trust the preparation guidelines for trauma standards and the protocols stated before.

The protocols are set before but they have not tested for prospectively longitudinal studies in human. However, all protocols are set before and have found a strong place for routine applications clinically.

Periodontal wound healing protocols must be taken specially and must be based on biological reasons.

Permanent teeth's avulsions are the most serious of all dental traumatic cases. The prognosis of the treatment depends on the time taken at the place of accident or the time immediately after the avulsion [7]. Appropriate emergency management and treatment plan are important for a good prognosis. Guidelines are usually useful for delivering the best treatment possible in an efficient manner. The International Association of Dental Traumatology (IADT) has developed a consensus statement after a review of the dental literature and group discussions.

Unlike deciduous teeth, permanent teeth rarely undergo root resorption. Even in the presence of periodontal and radicular inflammation, resorption will occur primarily on the support bone side of the attachment apparatus and the root will be resistant to it [8].

Facial trauma that results in fractured, displaced, or lost teeth (deciduous or permanent) can have significant negative functional, esthetic, and psychological effects on children. Clinicians should collaborate to educate the children and parents about the prevention and treatment of traumatic injuries to the oral and maxillofacial area.

2. Diagnosis and treatment procedures according to the types of the traumatic cases

2.1 Radiographic examination

Several radiographic images must be taken from every patient in different angles, but the final decision is up to the clinician [9].

The following are suggested:

- X-ray image with 90° parallel with central rays through the examined tooth.
- Occlusal radiological examination.
- A lateral angulated dental periapical image which includes the mesial or distal aspects of the teeth examined as much as possible.

Cone-beam computerized tomography is extremely useful at this stage. It can be used for radiographic examination in detail of root fractures, mobility of teeth, periodontal status, and peripheral destructions of teeth. The CBT Radiographic System may not be available in every clinic; it may not be used routinely, but advantages of the system cannot be compared with those of conventional systems. Information for dental application of CBT is documented very well in the scientific literature.

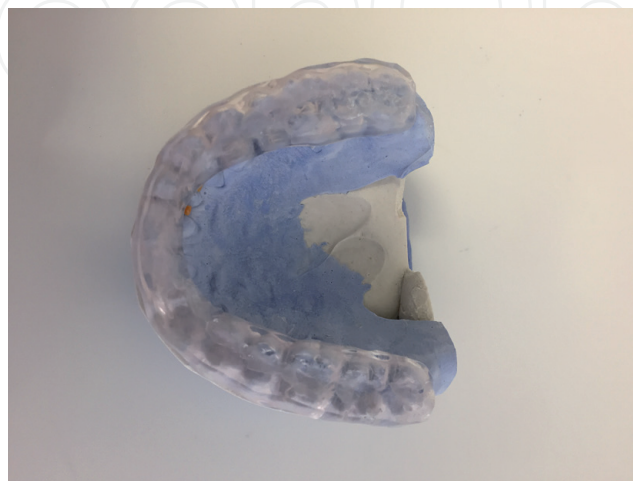

Figure 1.
Nonrigid splints can be used for stabilization of mobilized and fractured teeth.

2.2 Clinical examination, basic principles, and suggestions

There are many protocols and approaches to the clinical examination. They are very well classified and documented in current textbooks for assessment of TDIs [1].

2.3 Fixation with splints and their using period

According to the recent researches, using short-term nonrigid splints for treatment of luxated, fractured, and avulsed teeth is supported (**Figure 1**). Basically, splints are essentials for the patient's comfort and improvement of functions, and they are useful to maintain the location and correct position of teeth [9–11].

2.4 Medical treatment, antibiotics

There is no strong evidence for using systemic antibiotics for traumatic cases, luxation management, and coverage improvement of root fractures of teeth. This option is not mandatory and it is up to the dentist's own decision according to the past experience. Root fractures and related injuries of teeth and soft tissue may need surgical intervention. Use of antibiotic option is harmonized to the surgical operations and especially it may be useful for the soft tissue healing procedure [12, 7]. Soft tissue injuries, treatment methods, and healing procedure information are neither comprehensive nor detailed information is found in textbooks, the scientific literature, and, most recently, the Dental Trauma Guide (DTG) that can be accessed on <http://www.dentaltraumaguide.org>. Additionally, the DTG, also available on the IADT's web page <http://www.iadt-dentaltrauma.org>, provides a visual and animated documentation of treatment procedures as well as estimations of prognosis for the various TDIs [13].

2.5 Use of antibiotics

There is no strong evidence for using systemic antibiotics for traumatic cases, luxation management, and coverage improvement of root fractures of teeth. This option is not mandatory and it is up to the dentist's own decision according to the past experience. Root fractures and related injuries of teeth and soft tissue may need surgical intervention. Use of antibiotic option is harmonized to the surgical operations and especially it may be useful for soft the tissue healing procedure [14, 15, 2, 16].

2.6 Sensitivity tests

Sensitivity tests (cold test and electrical pulp test) are necessary for improving the pulp condition. Especially in an emergency atmosphere of a traumatic condition, revealing of pulp condition is one of the important attempts for treatment steps. Therefore, at least two signs and symptoms are necessary to make the diagnosis of necrotic pulp. Regular follow-up controls are required to make a pulpal diagnosis.

2.7 Vitality of permanent teeth

The basic principle is that maximum endeavor should be made for the protection of pulp vitality in a permanent tooth improving root development. Loss of a tooth in the period of childhood will produce occlusal source many complications. The immature permanent tooth can recover easily after exposing the pulp in traumatic

tooth/root fractures. In traumatic cases, root canal treatments are the most reasonable treatment for maintaining root development [8]. Additionally, emergency treatment of traumatized teeth can accelerate healing of the teeth.

2.8 Traumatic occlusion

As a dental practitioner, we may cause occlusal trauma. We change the occlusal surfaces of teeth when we make functional and esthetical restorations in clinical practice. Usually, natural teeth have adapted and shaped occlusion in the developmental period of humans, especially the development of the craniofacial area [17]. Muscles, bones, and teeth must be in full harmony. But sometimes, they may not be in accordance with accepted rules or standards, especially anatomically. The neural system also adapts to that inappropriate structure and there does not exist any high neuronal impulse in the neural system that may cause excessive contraction of masticatory muscles [18]. The dentist may change this complex, improper but harmonic structure. Dental treatment procedures may disrupt this harmonic relationship when we make composite restoration, orthodontic treatment, prosthetic, and/or implant restoration. In order to avoid traumatic occlusion, occlusal compliance in dental restorations should be at the highest possible level.

Occlusal trauma may be spotted in the following situations:

1. Prosthetic restorations
2. Implant supported prosthesis
3. Composite fillings
4. Orthodontic treatment
5. Oral surgery operations
6. Accidents

The main reason for the occlusal trauma is premature contact in the occlusion. Every dentist must be able to manage premature contacts in dental treatments.

Occlusal trauma is one of the most common problems of dental treatment. Every dentist must be extremely careful about avoiding dental premature contacts.

Trauma itself is not a disturbance, trauma is a result of an event. *Trauma is the damage of tissue and/or organs.* Trauma and its consequences may be acute or chronic. The acute situation is the result of the quick reflex response of the neuromuscular system to the premature contacts; however, the chronic situation may be developed within days, weeks, or years. The perception of the occlusal irregularity and a reaction to that problem is managed by the central nervous system (CNS). During human life, the main function of the masticatory muscles is to break food down into pieces small enough to be swallowed. CNS is like a protection mechanism of the stomatognathic system in that function. These are strong muscles that generate very large forces across in very short distances and apply them via rigid teeth. Such large forces can easily damage the teeth and their supporting tissues, tongue, cheeks, and the joints unless they are controlled precisely and effectively [3]. If the trauma is a system for protection of the stomatognathic structures, pain is the alarm ring bell of that system.

One of the biggest problems of prosthetic restorations is occlusal premature contacts. Early occlusal contacts cause the imbalance of dentures and it may

fracture the ceramic restorations. Unbalanced dentures are the reason for occlusal trauma and they may cause irritation on soft tissue and then tissue deteriorations consequently (Figure 2).

Occlusal premature contacts are effective on the way from the first contact to the maximum intercuspal position (MIP). It is not easy to detect premature contact at developing occlusion (Figure 3).

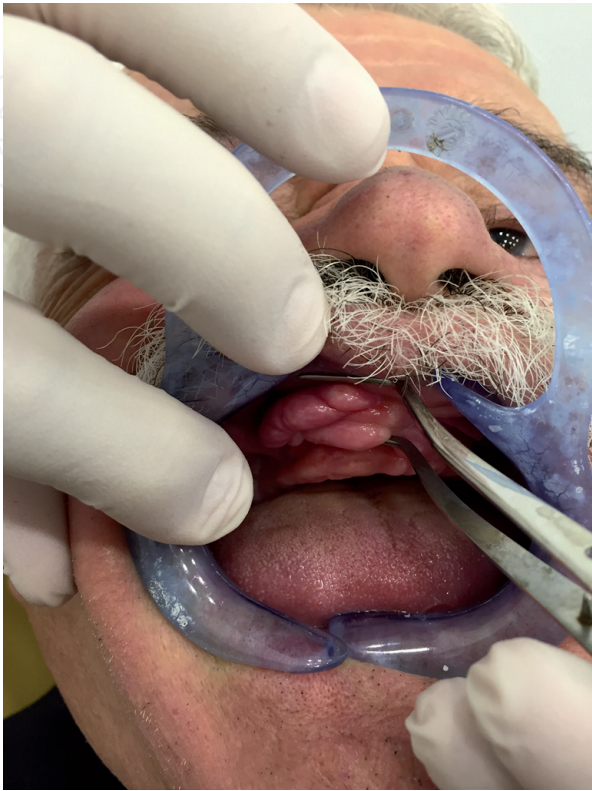

Figure 2.
Occlusal trauma caused by an upper denture.

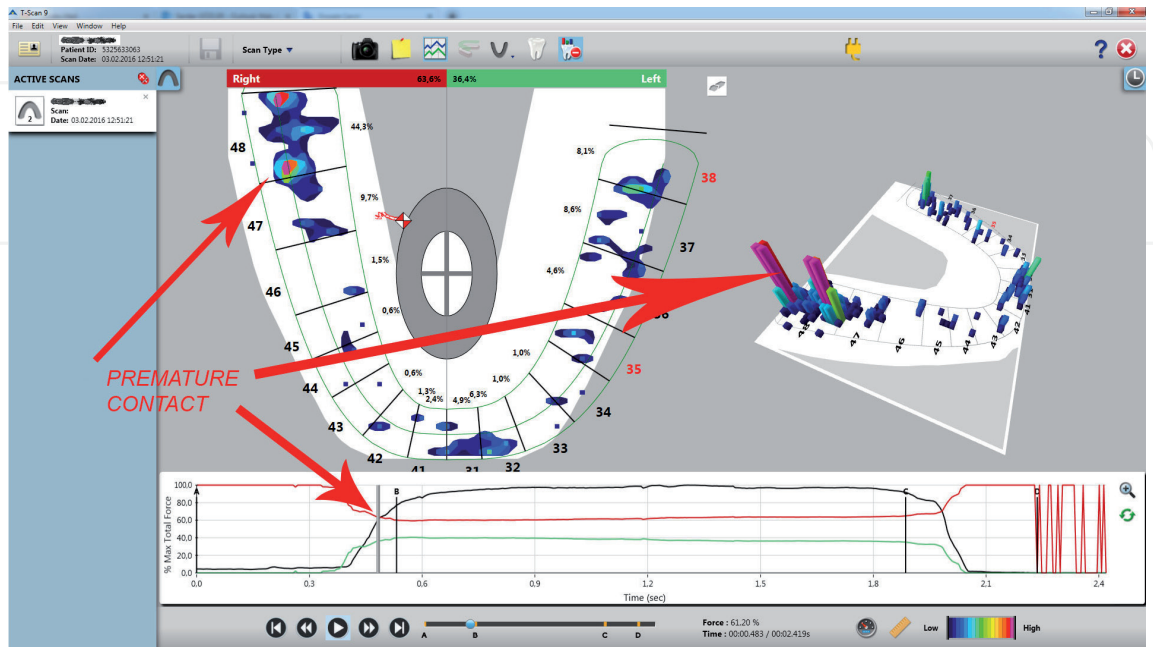


Figure 3.
Occlusal trauma: premature contact is affected on the way before of the way of MIP (maximum intercuspal position) peak point.

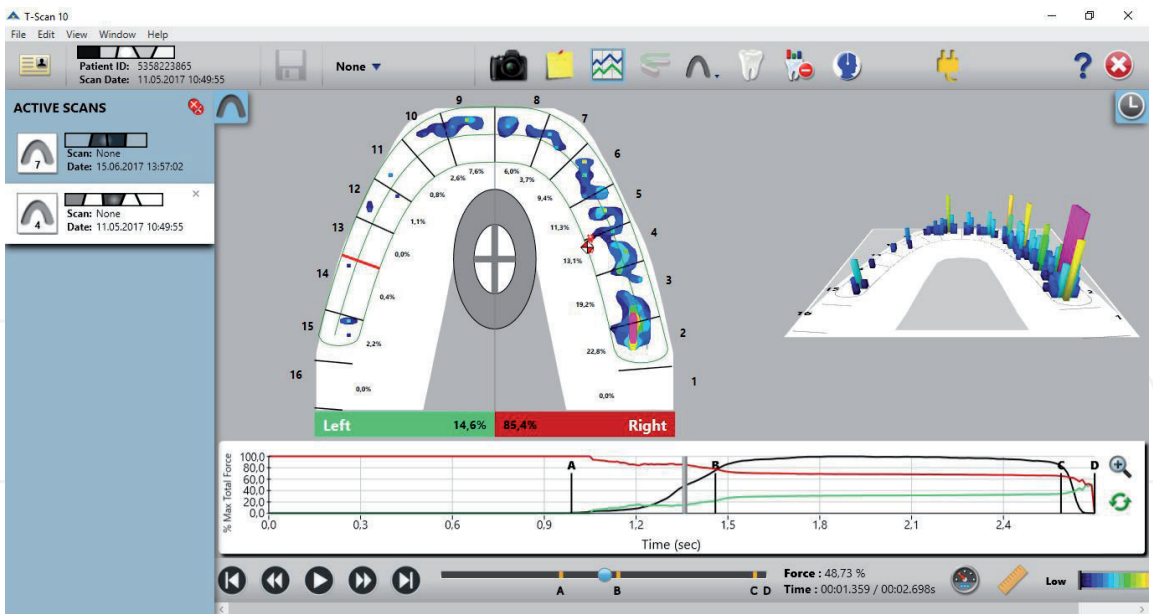


Figure 4.
Premature contacts can be described easily by computerized occlusal analyzing system. Occlusal papers or similar methods can not much help for finding premature contact.

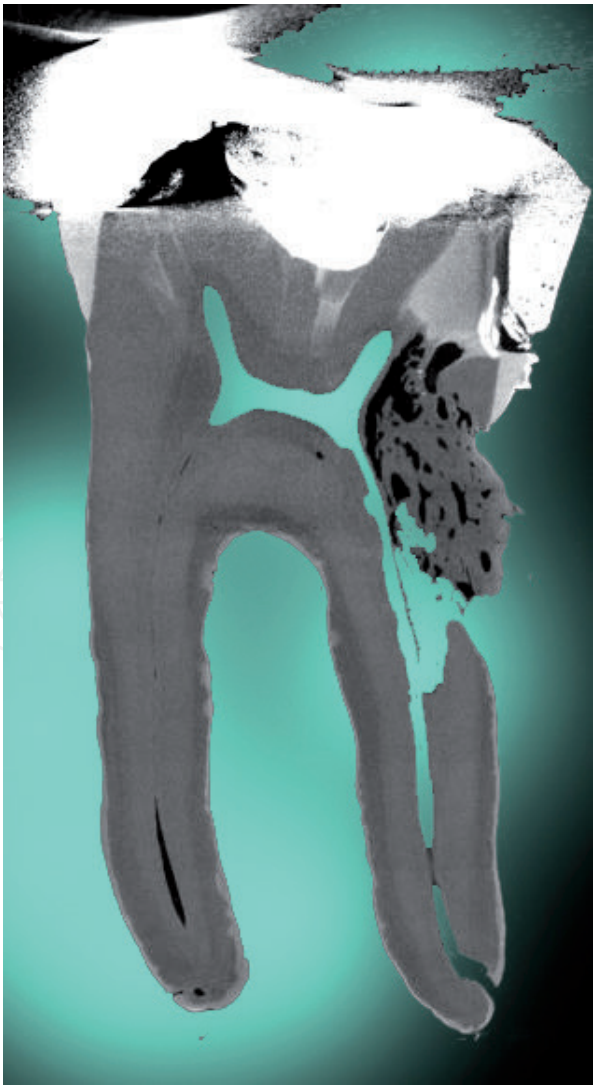

Figure 5.
Cervical area of a tooth has been destroyed under the traumatic occlusion.

The best method is computerized occlusal analyzing system for detecting the traumatic premature contact (**Figure 4**).

Abfractions are the reason for the wrong linear inclination of teeth and the tooth cervical area is damaged because of those kinds of problems of occlusal trauma (**Figure 5**).

Sometimes, the cervical area at the labial surface of the tooth is abraded in time because of the direction of occlusal force. If the teeth are covered by ceramic crown restoration, abrasion of teeth continues inside the ceramic restoration. Restorations are not protective against the abrasion (**Figure 6**). The only way to stop the abrasion is the occlusal adjustment of the restoration.

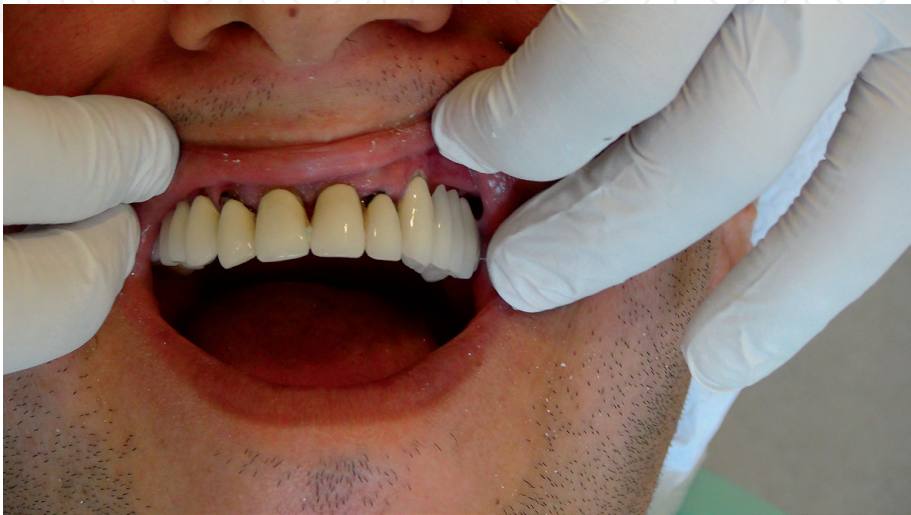

Figure 6.
Abfraction continues under the restorations. Crown restorations cannot protect the teeth from traumatic occlusal forces.

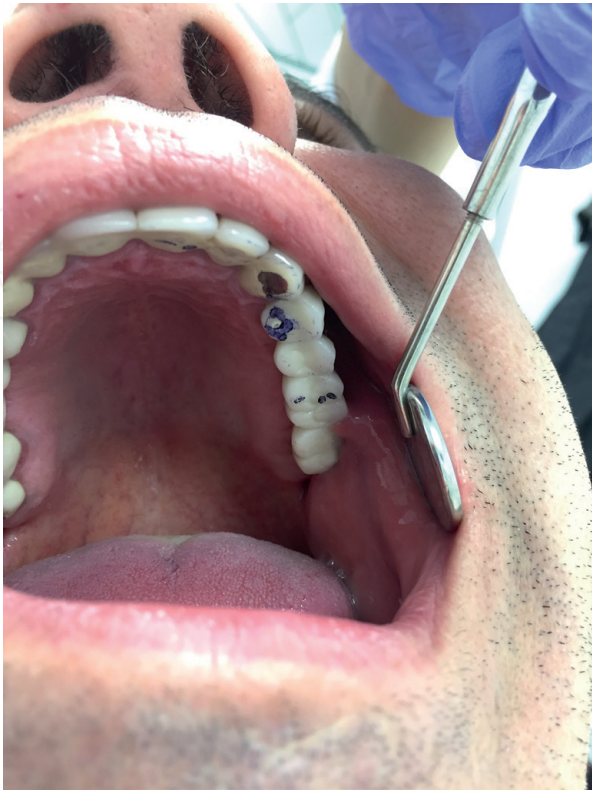

Figure 7.
Ceramic restorations have been broken under the traumatic occlusal strokes.

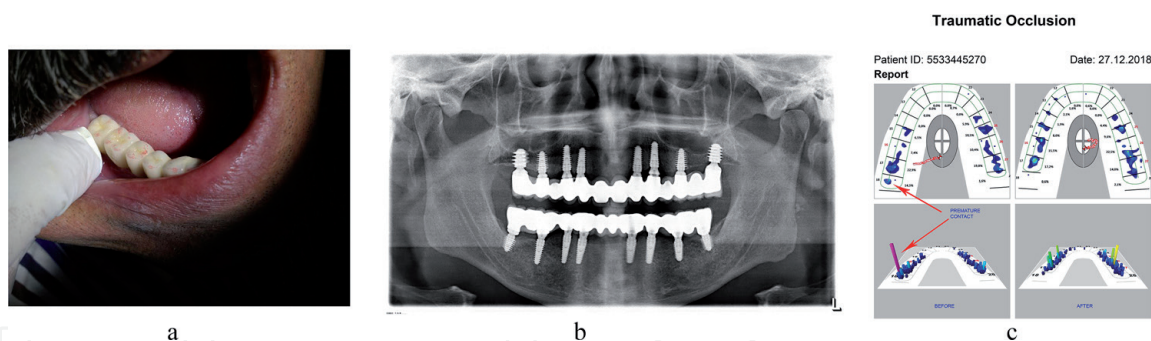


Figure 8.
 (a–c) Implant selection, their locations, and surgical steps are almost perfect; (a) everything seems normal when controlling with articulating paper, (b) but the patient is never relaxed with his new restorations. The problem can be detected when examining restoration with computerized occlusal analysis technic: there is severe premature contact detected on the right second molar area (c). The patient relaxed just after occlusal adjustment (c).

The ceramic materials are often used in restorative treatments. Premature contacts on the ceramic restorations must be eliminated; otherwise, periodontal receptors will never stop sending neuronal impulse and the muscles will never be relaxed. In this case, ceramic restoration has been broken because of the high occlusal pressure of premature contacts (**Figure 7**).

The abrasion effect of occlusal trauma is much more dramatically developed in the cases of implant prosthesis because implant restorations have no resilient features and the force transmits directly to the bone without resistance of any force breaker system like periodontal ligaments of natural teeth. In an implant-supported prosthesis, if occlusal equilibration is not made, the patient can never be relaxed. In **Figure 8a** and **b**, implant planning and surgery phase is perfect and the treatment with a full arch ceramic restoration is also finished, but the patient is never relaxed with his new restorations. The problem can be detected when examining restoration with computerized occlusal analysis technic: there is severe premature contact detected on the right second molar area. The patient relaxed just after an occlusal adjustment procedure (**Figure 8c**).

3. Conclusion

The most exposed group to dental trauma is young adults and children. Fractures of the upper part of the teeth and luxations are the most frequent cases. For a healthy result, the most important approach is the proper diagnosis and then proper treatment consequently.. This action plan is not only for tooth level, but is also a proper approach for other type traumatic injuries; the guidelines which have been developed and set by “The International Association of Dental Traumatology (IADT)” are important supportive materials for the clinicians. There are many specialists and researchers on “Dental Traumatology” who added important and useful suggestions.

In some cases, the collected data from traumatic injury may not be clear and precise. In those cases, clinicians can use the basic and agreed of opinions of IADT board specialists. Suggestions and opinions for unexpected situations are also developed by the IDTA members.

There are various guidelines for any kind of levels of urgent and long-term traumatic cases which are prepared and set by TDIs.

IntechOpen

IntechOpen

Author details

Serdar Gözler
Prosthodontic Department of Dentistry Faculty, Istanbul Aydın University,
Istanbul, Turkey

*Address all correspondence to: serdargozler@aydin.edu.tr

IntechOpen

© 2019 The Author(s). Licensee IntechOpen. This chapter is distributed under the terms of the Creative Commons Attribution License (<http://creativecommons.org/licenses/by/3.0>), which permits unrestricted use, distribution, and reproduction in any medium, provided the original work is properly cited. 

References

- [1] Bastone EB, Freer TJ, Mcnamara JR. Epidemiology of dental trauma: A review of the literature. *Australian Dental Journal*. 2000;**45**(1)
- [2] Perez R, Berkowitz R, McIlveen L, Forrester D. Dental trauma in children: A survey. *Dental Traumatology*. 1991;**7**(5):212-213. DOI: 10.1111/j.1600-9657.1991.tb00438.x
- [3] Andreasen JO, Gerds TA, Lauridsen E, Ahrensburg SS. Dental trauma guide a source of evidence-based treatment guidelines for dental trauma. *Dental Traumatology*. 2012;**28**:345-350
- [4] Cotruță AM, Mihăescu CS, Tănăsescu LA, Mărgărit R, Andrei OC. Analyzing the morphology and intensity of occlusal contacts in implant-prosthetic restorations using t-scan system. *Romanian Journal of Morphology and Embryology*. 2015;**56**(1):277-281
- [5] Wong RCW, Tideman H, Kin L, Merckx MAW. Biomechanics of mandibular reconstruction: A review. *International Journal of Oral and Maxillofacial Surgery*. 2010;**39**(4):313-319. DOI: 10.1016/j.ijom.2009.11.003
- [6] Gross MD. Occlusion in implant dentistry. A review of the literature of prosthetic determinants and current concepts. *Australian Dental Journal*. 2008;**53**(Suppl. 1)
- [7] Flores MT, Andersson L, Andreasen JO, Bakland LK, Malmgren B, Barnett F, et al. Guidelines for the management of traumatic dental injuries. II. Avulsion of permanent teeth. *Dental Traumatology*. 2007;**23**(3):130-136
- [8] Trope M. Root resorption due to dental trauma. *Endodontic Topics*. 2002
- [9] Diangelis AJ, Andreasen JO, Ebeleseder KA, Kenny DJ, Trope M, Sigurdsson A, et al. Guidelines for the management of traumatic dental injuries: 1. Fractures and luxations of permanent teeth. *Pediatric Dentistry*. 2016;**38**(6):358-368
- [10] Flores MT, Malmgren B, Andersson L, Andreasen JO, Bakland LK, Barnett F, et al. Guidelines for the management of traumatic dental injuries. III. Primary teeth. *Dental Traumatology*. 2007;**23**(4):196-202
- [11] Von Arx T, Filippi A, Lussi A. Comparison of a new dental trauma splint device (TTS) with three commonly used splinting techniques. *Dental Traumatology*. 2001;**17**(6):266-274
- [12] Lin S, Zuckerman O, Fuss Z, Ashkenazi M. New emphasis in the treatment of dental trauma: Avulsion and luxation. *Dental Traumatology*. 2007;**23**(5):297-303
- [13] Berger TD, Kenny DJ, Casas MJ, Barrett EJ, Lawrence HP. Effects of severe dentoalveolar trauma on the quality-of-life of children and parents. *Dental Traumatology*. 2009;**25**(5):462-469. DOI: 10.1111/j.1600-9657.2009.00809.x
- [14] Lee JY, Yanpiset K, Sigurdsson A, Vann WF. A case report of reattachment of fractured root fragment and resin-composite reinforcement in a compromised endodontically treated root. *Dental Traumatology*. 2001;**17**(5):227-230
- [15] Kargul B, Caglar E, Tanboga I. Dental trauma in Turkish children, Istanbul. *Dental Traumatology*. 2003;**19**(2):72-75. DOI: 10.1034/j.1600-9657.2003.00091.x
- [16] Case I, De Rossi SS, Stern I, Sollecito TP, Fushima K, Gallo LM, et al. Dislocation of the. *Journal of Prosthodontic Research*.

1985;**25**(3):246-251. DOI: 10.1016/j.jfoodeng.2016.06.008

[17] Hattori Y, Satoh C, Kunieda T, Endoh R, Hisamatsu H, Watanabe M. Bite forces and their resultants during forceful intercuspal clenching in humans. *Journal of Biomechanics*. 2009;**42**(10):1533-1538

[18] Iwase M, Ohashi M, Tachibana H, Toyoshima T, Nagumo M. Bite force, occlusal contact area and masticatory efficiency before and after orthognathic surgical correction of mandibular prognathism. *International Journal of Oral and Maxillofacial Surgery*. 2006;**35**(12):1102-1107