

We are IntechOpen, the world's leading publisher of Open Access books Built by scientists, for scientists

6,900

Open access books available

185,000

International authors and editors

200M

Downloads

Our authors are among the

154

Countries delivered to

TOP 1%

most cited scientists

12.2%

Contributors from top 500 universities



WEB OF SCIENCE™

Selection of our books indexed in the Book Citation Index
in Web of Science™ Core Collection (BKCI)

Interested in publishing with us?
Contact book.department@intechopen.com

Numbers displayed above are based on latest data collected.
For more information visit www.intechopen.com



Interruption of Pregnancy in Women with the Uterine Scar: Potential Risks

Galina Dikke and Vladimir Ostromenskiy

Abstract

Summary objective: To assess the risks and identify effective and safe methods of abortion in women with uterine scar. **Material:** Literary sources published in the databases of Medline, PubMed, and others, of which 57 are included in this review. **The main provisions:** Termination of pregnancy in women with a scar on the uterus involves the use of any available method. For women with a scar on the uterus, it is necessary to prepare the cervix before a surgical abortion in all terms. Abnormal implantation of the embryo within the fibrous tissue of the scar after caesarean section can cause life-threatening bleeding of the mother during or after the termination of the pregnancy. Surgical excision of the affected area by hysteroscopic access, as well as transvaginal or transabdominal local administration of Methotrexate with or without an additional intramuscular dose of the same drug, seems to be optimal from the point of view of minimizing the frequency of complications. **Conclusion:** A scar on the uterus after caesarean section presents a high risk of abnormal attachment of the ovum and fatal bleeding during abortion.

Keywords: medical abortion, surgical abortion, uterine scar, bleeding

1. Introduction

Interruption of pregnancy in patients with uterine scar, as well as in women without it, can be artificial (in early and late pregnancy period if medically required, and also in pregnancy period exceeding 22 weeks—at still birth) or spontaneous.

Although there is no doubt presently that now caesarean section is quite a safe procedure, it still presents a certain risk not only for the subsequent pregnancy and confinement, but also in case of its interruption.

Interruption of pregnancy in women with uterine scar assumes the use of any accessible method [1]. However, the abortion made by the method of uterine curettage in the interval period aggravates the forecast. The risk of scar inadequacy in this case increases 1.5 times.

Recently, substantial growth of registered cases of localisation of ovum in the uterine scar after previous caesarean section has been observed [2]. After one or several caesarean section operations, the specific localisation of the chorion, such as presentation and scar increta, can be a reason of serious complications during and after interruption of pregnancy.

2. Medicamentous interruption of pregnancy in women with an uterine scar

The technology of medicamentous interruption of pregnancy in the early period, the used preparations and their doses do not differ for groups of women having a uterine scar and those without it.

It is marked in medical periodicals that the use of Mifepristone and Misoprostol for interruption of pregnancy during the period not later than 49 days of amenorrhoea in women with a uterine scar is safe and effective [3, 4]. Not a single case of uterine rupture at the place of the scar or increased frequency of other complications is described for medicamentous interruption of pregnancy in early period in case of caesarean section in the anamnesis, in comparison with the women who did not undergo operative uterine treatment [5].

The preceding caesarean section operations are deemed to be a uterine rupture risk factor in case of interrupting gestation at 13 weeks and later. However, the study of abortion results in the second trimester, induced by Misoprostol, in 720 women with one or several prior caesarean section intervention shows that the use of the medicamentous method does not cause more frequent complications in comparison with the women with non-operated uterine (the absolute risk of uterine rupture is <0.4%) [1].

Thus, the presence of a uterine scar after the previous caesarean section is not a contraindication for medical abortion at early pregnancy and does not involve increased frequency of complications.

3. Recommendations for medical abortion in women after caesarean section in case of localisation of the chorion/placenta outside the uterine scar

- The most essential data for medicamentous interruption of pregnancy relate to the application of Misoprostol, but the level of evidence is low. The doses of Misoprostol in case of late pregnancy interruption should be twice lower for the women with uterine scar, in comparison with the women without it (**Table 1**) [6].
- The use of Mifepristone or hygroscopic dilators is not counter-indicative [7].
- In case of interruption of late pregnancy or foetus death in patients with the uterine scar, in most cases induction of confinement is more preferable than planned caesarean section irrespective of the number of past caesarean section operations (the recommendation of a professional consensus).
- In case of still birth, at the period of 27–28 and over 28 weeks of gestation, Misoprostol is not used for medicamentous abortion [6].
- The presently practiced options of medical treatment of women with incomplete or missed abortion include expectant management (for women with spontaneous miscarriage, with no excessive uterine bleeding, with stable haemodynamics and no signs of infection), medicamentous treatment (usually Misoprostol or Mifepristone/Misoprostol) or surgical treatment (vacuum aspiration or dilation and curettage). An important factor in choosing a method for management of spontaneous miscarriage is the woman's preference [8, 9].

- In case of non-developing pregnancy up to 63 days of amenorrhoea, only the use of Misoprostol at a dose of 800 mcg vaginally or 600 mcg sublingually is possible. Administration can be repeated in 3 hours, if necessary (2 doses maximum).
- The patients with a uterine scar willing to interrupt the pregnancy or those with unexpected miscarriage, need all-round detailed consultation, and the doctor must consider all variants of administration, their advantages and risks. Individual approach is necessary, with account of the obstetric anamnesis, comorbid diseases and potential complications, such as haemorrhage and uterine rupture constituting a life-threatening situation [1].

Advanced pregnancy, no previous confinement in the past medical history and previous confinement by caesarean section result in extended duration of abortion.

The mother's age, body mass index, race and the interval between administration of Mifepristone and Misoprostol do not affect the duration of the abortion.

Preparation of the cervix before surgical abortion is recommended to all women with the pregnancy exceeding 12–14 weeks. The preparation can be recommended as well to women with high risk of cervix trauma or uterine perforation at any pregnancy period. For this purpose, osmotic dilators (laminaria tents, Dilapan-S), pharmacological medications (Mifepristone, Misoprostol) or their combinations are used.

Preparation	Dose	Method of administration	Frequency of administration
Up to 49 days*	400 µg	Orally	One time
50–63 days*	800 µg	Vaginally***	One time
64–84 days*	800 µg 400 µg	Vaginally*** (first dose), subsequently vaginally*** or sublingually	Every 3 hours, up to 4 doses
If abortion fails to occur within 14 days, then vacuum aspiration is administered			
13–24 weeks*	200 µg	Vaginally*** (first dose), sublingually (subsequent doses)	Every 3 hours, up to interruption of pregnancy
If abortion fails to occur within 24 hours, then administration of Mifepristone is to be repeated in 3 hours after the last dose of Misoprostol, and after 12 hours-Misoprostol			
25–26 weeks*	100 µg	Vaginally,*** buccally or sublingually	Every 4 hours (in case of still birth-after 6 hours), up to interruption of pregnancy
An extra dose Misoprostol is applied if the placenta did not come off in 30 minutes after foetus expulsion			
27–28 weeks**	100 µg	Vaginally,*** buccally or sublingually	Every 4 hours, up to interruption of pregnancy
Over 28 weeks**	50 µg	Vaginally,*** buccally or sublingually	Every 6 hours, up to interruption of pregnancy
An extra dose Misoprostol is applied if the placenta did not come off in 30 minutes after foetus expulsion			
*Misoprostol is applied in 24–48 hours after administration of Mifepristone at a dose 200 mg one time ingestion.			
**Is not applied in case of still birth.			
***To exclude vaginal application in case of haemorrhage or signs of infection.			

Table 1.
Medical abortion schemes with application of misoprostol in women with a uterine scar [6].

The advantages of osmotic dilators over Mifepristone or Misoprostol have been identified in terms of efficiency [10–12], of Dilapan-S over laminaria tents in the accepted “one-day” procedures for cervical dilatation [13] and in respect of the use of Misoprostol in addition to osmotic dilators in case of cervix deformation or pregnancy period exceeding 16 weeks [14].

In some cases, osmotic dilators are used more extensively, for instance, in treatment of teenagers, non-parous women or women with cervical scars. It is also recommended to increase the number of dilators with the progress of pregnancy period. As compared with laminaria tents, by-half-less number of Dilapan-S rods is required because of wider cervical dilatation [14]. Two rods are recommended at the 13–15-week pregnancy period, three at 16–18-week period and four at 18 weeks-period and further (though only few proofs substantiate this recommendation). After 18 weeks, administration of Dilapan-S is recommended one time overnight [15]. However, one rod inserted 3–4 hours prior to the dilation and evacuation can be sufficient for the pregnancy period not exceeding 18 weeks.

The methods combining osmotic dilators and Misoprostol are efficient owing to the shortest known time to yield effect (from 2 to 4 hours). The possibility to complete the procedure within 1 day for the 18–22 weeks pregnancy period was demonstrated by Lyus R. et al., who used 3 Dilapan-S rods and 400 µg of Misoprostol. The average time for preparation of the cervix was 3 hours 40 minutes, and the average time of the manipulation—10 minutes [16].

The preparation of the cervix at the 17–22 weeks period of pregnancy requires greater time, sometimes 2–3 days (with replacement of dilators) [17]. The comparison of Dilapan-S with laminaria tents showed that the adequate cervical dilation on the 2nd day was achieved in 98 and 56% of women respectively [18].

4. Chorion ingrowth into the uterine scar in early pregnancy

Accreta, increta and percreta of the chorion is characterized by their accretion to the uterine myometrium without any intermediate decidual membrane, with different extent of their invasion into the myometrium. In the scientific literature, the term “placenta accreta” incorporates “placenta increta et percreta”.

4.1 Epidemiology

The chorion ingrowth into the uterine scar during the early pregnancy is diagnosed extremely seldom and varies between 1/110 and 1/2500 of pregnancy cases [19]. Some authors note a gradual increase in placentation anomalies, which coincides in proportion with the increased frequency of caesarean section operations: in 1970s years the figure was 1/70,000 [20], and in 2005—1/533 [21]. The meta-analysis made for the period from 1972 to 2011 describes 47 cases of diagnosed placentation anomalies in the first trimester and at the beginning of the second trimester [22].

4.2 Complications of artificial abortion in case of chorion increta into the uterine scar

According to Abbas et al. [23], placenta accreta is usually not identified in the first trimester of pregnancy, and the diagnosis concerning this pathology is made retrospectively for patients with excessive haemorrhage that arises during the uterine curettage which is secondary in relation to the invasion of chorionic villi in the myometrium [23]. Some observations of tardive uterine bleeding in some weeks and even several years after the abortion [24, 25] have been described.

According to Jang et al., the clinical manifestation may also include spontaneous uterine rupture with clinical development of “sharp belly” and haemoperitoneum [26]. Spontaneous uterine rupture was registered in 15 out of 47 cases (32%) described in the meta-analysis; most of them were asymptomatic and were accompanied by intra-abdominal haemorrhage and collapse [22].

The form of abnormal embryo implantation in the scar fibrous tissue after the caesarean section, dangerous for the mother's life, can lead to ectopic pregnancy (localisation of the ovum between the uterus and its serous membrane). The diagnostics of such condition with the help of ultrasonography does not represent any difficulties and is made for pregnancy period of 5–12 weeks, with the time interval between the last caesarean section and the ectopic pregnancy from 6 months to 12 years [27].

The complications associated with chorion intracta also include fistulisation, infection, perinatal and maternal death [28].

4.3 Diagnostics of chorion intracta into the uterine scar in early pregnancy

The review of literature devoted to the issue of early diagnostics of chorion ingrowth into the uterine scar, made by Timor-Tritsch et al. [22], showed that this diagnostics is quite complicated. The other authors also note that placental accreta, intracta or percreta in the first trimester of pregnancy is identified with difficulty [4, 24]. The literature refers only to several cases of diagnosed placenta accreta in the first trimester of pregnancy [23].

Most publications include information on placentation anomalies in the first trimester diagnosed during the morphological examination of the uterus ablated because of excessive bleeding that took place during the uterine curettage in early pregnancy or within a tardive period after the abortion.

No objective signs of chorion intracta into the uterine scar are present.

Chorion intracta risk factors (present in past medical history): uterine scar (caesarean section or myomectomy), manual ectomy of placenta, multiple gestation, dilation and curettage, endometriosis, multiple confinement, advanced age of the mother, IVF induced pregnancy.

The actual dependence of the chorion/placenta intracta frequency on the specified risk factors remains obscure. The combination of two-three and more factors is observed for most cases of placenta percreta [29]. In case of placenta presentation to the scar, the ingrowth risk makes 3% after the first caesarean section and reaches 40% and more after the third similar operation [30].

4.3.1 Ultrasonography

Diagnostics of ovum localisation in the uterine cavity, as viewed by ultrasonography, is an integral part of diagnosing uterine pregnancy and usually does not present any complexity.

Sonography is a very important instrument for exact location of the gestational sac and for diagnosing inadequacy of the postoperative uterine scar.

The ultrasonic signs of chorion ingrowth into the uterine scar in the first trimester are as follows (**Figures 1–4**):

- absence of decidual membrane in the area of localisation of the placenta
- low-lying gestational sac (in the scar area)
- invagination of the placenta towards the bladder

- hypoechoic inclusions (lacunae) in the placental area
- myometrium thickness in the retroplacental zone below 1 mm
- more intense uterine-placental blood flow.

Sensibility—41%, specificity—88% [19]. For comparison: these indices in the second trimester make 60 and 83.5% respectively.

Histopathologically, chorion increta (irrespective of having a uterine scar) is characterized by partial or complete **absence of decidual membrane**, following which the placental villi get accreted to the myometrium or invade it (**Figure 1**).

According to Richardson et al. [31], the “key” to identifying chorion increta lies in the retroplacental complex and is characterized by **absence of a hypoechogenic line (the norm being from 1 to 2 mm)**, that is, there is a loss of normal decidual interaction between the chorion and the myometrium (**Figure 2**).

The presence of placental lacunae (**Figures 3 and 4**), according to some authors, is the most valuable attribute of placenta increta, with the 89% sensibility, specificity of 81%, positive prognostic value of 73% and negative prognostic value of 93% [32], while the combination of lacunae and myometrium thickness below 1 mm in the retroplacental complex zone shows the metrics of 100, 72, 72 and 100% respectively [33].

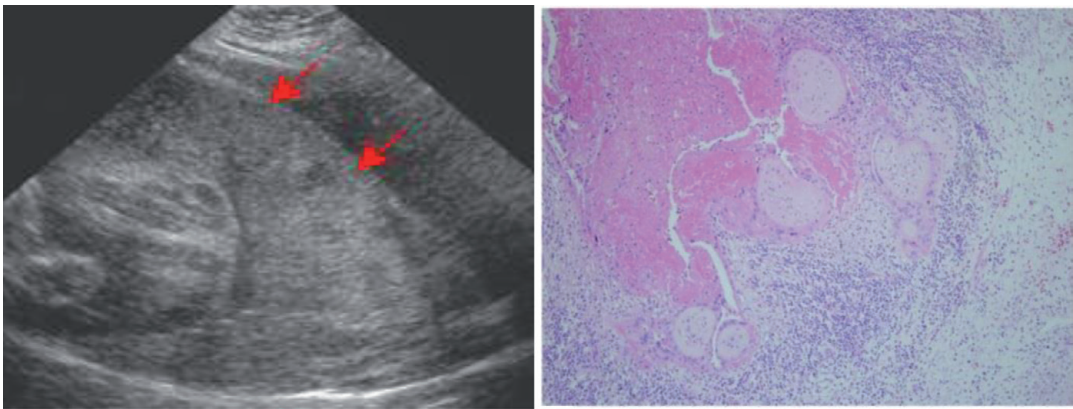


Figure 1.
On the left: ultrasonographic examination—absence of decidual membrane in the placental localisation area;
on the right: histopathological examination—chorionic villi in the myometrium with no decidual membrane (haematoxylin, eosin; 100×) [24].

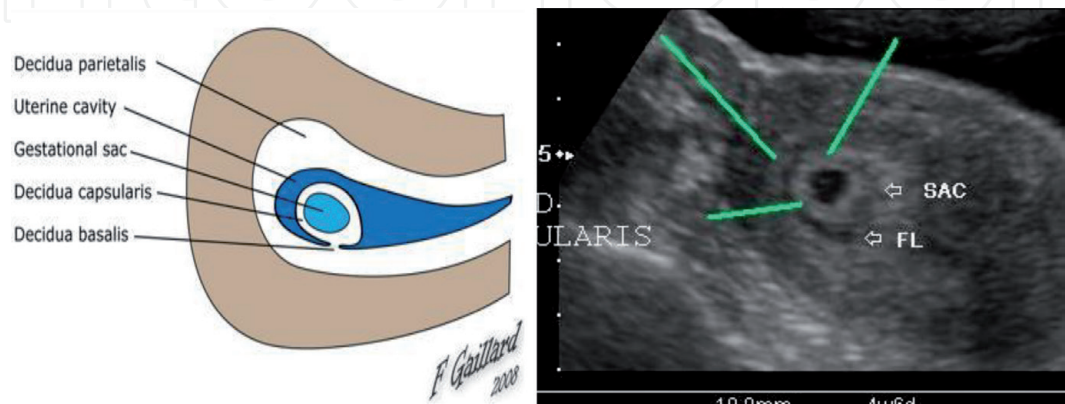


Figure 2.
Ultrasonographic examination: retroplacental complex (on the left: the scheme; on the right: designated with arrows from the left to the right—decidua capsularis, decidua parietalis, decidua basalis; other denotations: SAC—gestational sac, FL—fluid-containing space—hypoechogenic line between decidua parietalis and decidua basalis).

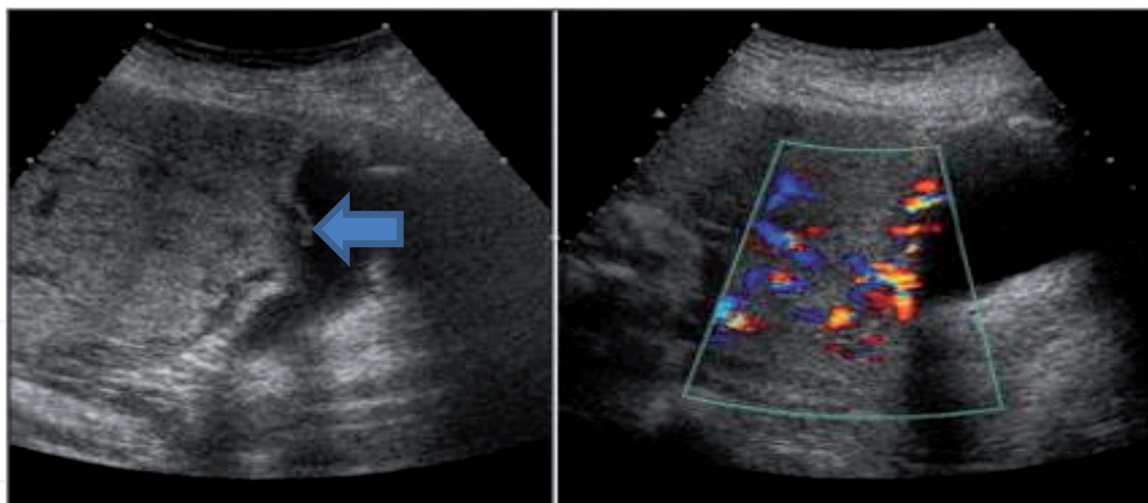


Figure 3.
Ultrasonographic examination: on the left—sonogram, grey scale: evagination of the placenta into the bladder; on the right—sonogram, colour doppler: visible hypervascularisation between the uterine serous membrane and the bladder wall; placental lacunae [34].

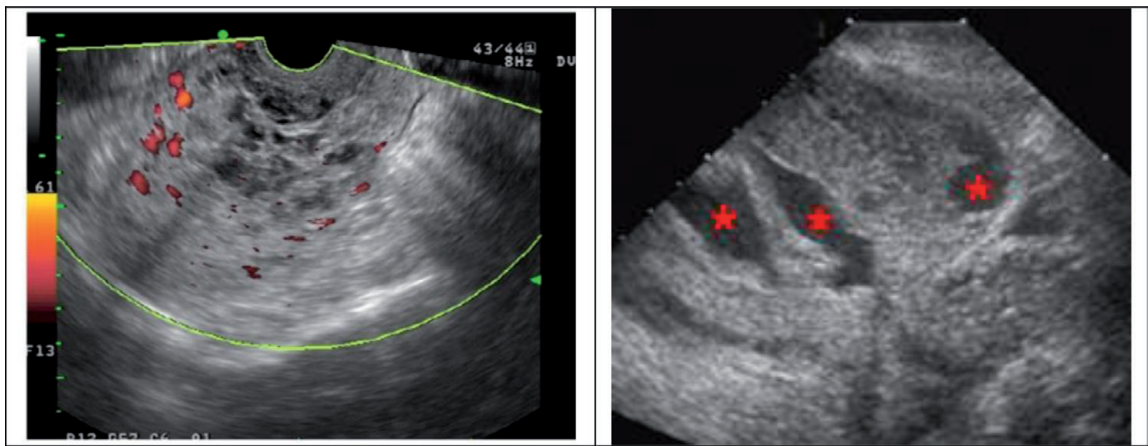


Figure 4.
Ultrasonographic examination: hypoechoic inclusions (lacunae) in the placental area (composite cystophorous “aggregate” in the uterine wall) [34].

The uterine scar inadequacy is diagnosed not only and not purely on the basis of thinning of the scar and the presence of considerable number of hyperechoic inclusions (connective tissue), but also by exposure of **other ultrasonic markers** which include: visualisation of total defect of the myometrium in the scar projection, in the form of a “niche” from the uterine cavity side, reaching the serous membrane; or partial defect in the myometrium in the scar projection, in the form of a “niche”, with thinning of the lower uterine segment down to 3 mm and below; myometrium deformation with retraction from the uterine serous membrane side and a “niche” from the uterine cavity side, with thinning of the unchanged myometrium down to 3 mm and below; total, subtotal necrosis of the myometrium. The enumerated criteria are deemed to be an indication for operative treatment of the inadequate uterine scar during the period of periconceptional preparation.

The value of uterine scar thickness indicator or other criteria of inadequacy as predictors of uterine rupture and excessive bleeding in the first trimester of pregnancy in case of its interruption, has not been studied and is not known. Most of the echographic criteria of placenta increta have a real diagnostic value only after 15 weeks of pregnancy (sensibility—78–93%, after 28 weeks—100%).

In the absence of a clear picture or in case of doubtful ultrasonographic results at suspicion on ectopic pregnancy, other methods of research are undertaken.

4.3.2 Magnetic resonance imaging

To diagnose placenta increta in the second and third trimesters of pregnancy, magnetic resonance imaging (MRI) is used in recent years in case of dubious results of ultrasonography [22]. However, diagnostics with the help of ultrasonography (including colour Doppler) and MRI has not shown a statistically significant difference [35]. No valid criteria of MRI diagnostics are so far developed.

An observation of a 41-year-old patient with a caesarean section in the past medical history has been described. The patient had an intra-abdominal haemorrhage on the 21st week of pregnancy, without any signs of placental anomalies according to the ultrasonography data, whereas the MRI showed a picture of deep placental invasion suggesting placenta increta or percreta (**Figure 5**). Placenta percreta was confirmed by the histological examination of the operatively extirpated uterus (ablated in connection with spontaneous uterine rupture during the confinement) [28].

An observation of a 42-year-old patient with vaginal haemorrhage and pain in the lower abdomen lasting for 2 weeks after the dilation and curettage, at the 5-week gestation period, has been described. The level of β -HCG in serum was 2009.3 mIU/ml. The diagnosis—chorionic increta—was made on the basis of magnetic resonance imaging (**Figure 6**).

The sensibility of magnetic resonance imaging is 77%, the specificity—50% in patients with average 30.8 weeks period of pregnancy. The accuracy of diagnosis makes 67% [36]. As to the earlier gestation periods, no data were found for the specified parameters.

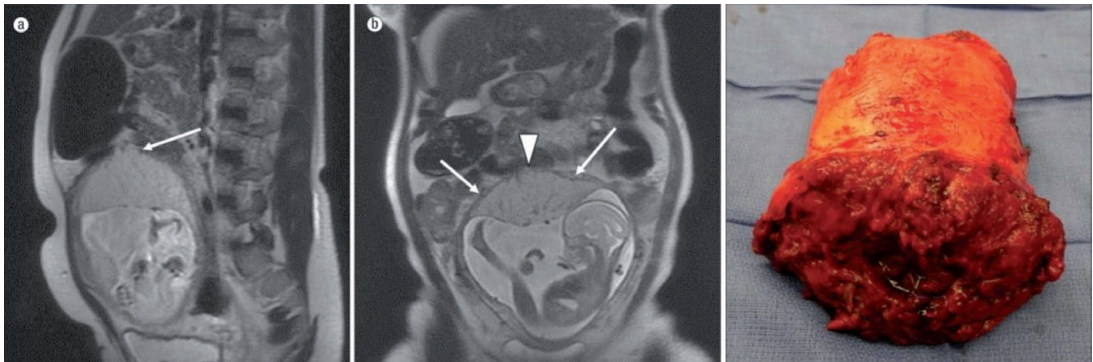


Figure 5. Patient N. aged 41. Magnetic resonance imaging (on the left): (a) sagittal MR image—deep placental invasion (the arrow); (b) coronal MR image of placenta (the arrowhead), invasion extending deep into the surrounding myometrium (the arrows). Gross specimen (on the right): extirpated uterus [28].

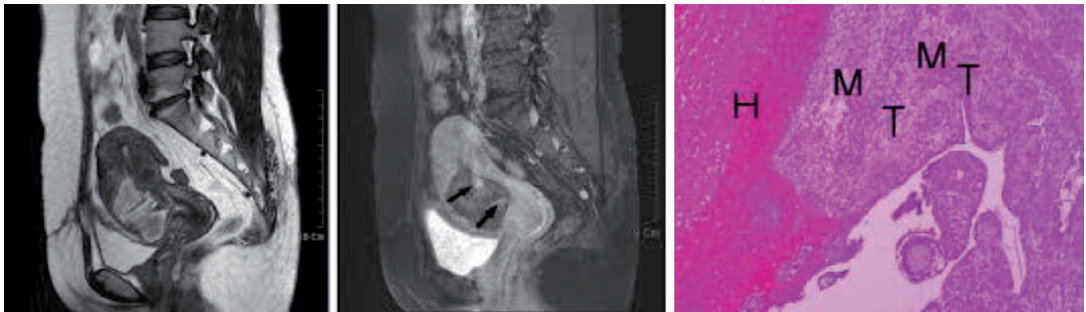


Figure 6. Patient R., 42 years old. Magnetic resonance imaging (on the left): A-sagittal T2-weighted MR image (TR/TE 4000/85 ms) of the pelvic area shows a clearly contoured intramyometric aggregate with high signal intensity. B-sagittal T1-weighted MR image (TR/TE 150/4.2 ms)—after intravenous administration of gadolinium-based contrast medium, shows a hypointense aggregate with focal areas of intensification (the arrows). Morphological examination (on the right): Invasion of trophoblast (T) in the myometrium (M), accompanied by a haematoma (H) [37].

5. Management of patients with ingrowth of chorion into the uterine scar in case of interrupting pregnancy in early periods

The scientific literature describes a clinical observation [38] of a woman with two caesarean section operations in the past history. The reviewed pregnancy was third, 11th week. The patient entered the hospital with excessive uterine haemorrhage. The nonsurgical arrangements (uterine curettage, etc.) proved to be inefficient, therefore she was subjected to hysterectomy. The total blood loss was estimated to be 3500–4000 ml. The haemoglobin figure was 8.1 g/dl. Transfusion of 9 units of erythrocytes and 4 units of fresh frozen plasma was effected. The patient recovered from the critical condition and was discharged on 7th day after the operation. The histopathological examination of the specimen (the extirpated uterus) confirmed the diagnosis “placenta accreta”.

Takeda et al. [25] describe a clinical observation of placenta increta in a 27-year-old woman (three pregnancies and one confinement by caesarean section in the past history). The pregnancy under review was non-developing, on 11th week, that ended surgically (curettage). Eight weeks after the curettage, haemorrhage occurred. The ultrasonography showed localized heterogeneous “aggregates” in the myometrium. The increased value of β -HCG in blood serum indicated at the presence of residual placental tissue. Diagnosis: placenta increta after abortion in the first trimester. Actions taken: transcatheter arterial chemoembolisation with dactinomycin for reaching immediate haemostasis and cellucidal effect on placenta tissues. Twenty days after the chemoembolisation, the value of β -HCG in blood serum fell to the normal level, and the “aggregate” characterising impairment of the uterus according to the ultrasonography data disappeared without complications.

The clinical observation described by Chou et al. [39] in respect of a 35-year-old woman with continual vaginal haemorrhage and preceding caesarean section in anamnesis, demonstrated a diagnosed 7th week pregnancy. The ovum with dimensions of 2.5×1.5 cm was located within the area of a uterine scar from the previous caesarean section. The original treatment was one-time injection of Methotrexate. Nevertheless, β -HCG levels remained high, and the transvaginal ultrasonography showed signs of continuing pregnancy. Consequently, hysteroscopic resectoscopy

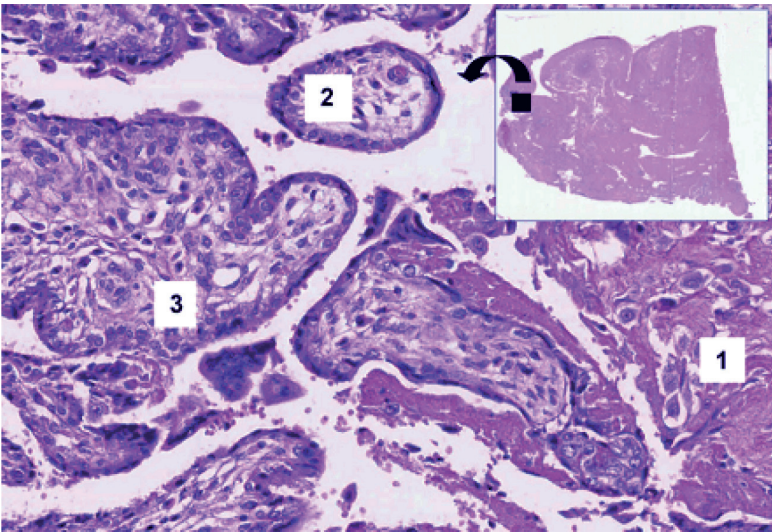


Figure 7.
Patient S., 40 years old. Diagnosis: pregnancy, 13 weeks. Caesarean section in the past medical history. Ingrowth of chorionic villi into the uterine scar. Laparotomy. It was found as well as a fundal uterine defect of 4 ± 3 cm with placental tissue penetrating through the uterine serosa. Hysterectomy. Histology of the placenta showing the myometrium (1) with invasions of chorionic villi (2) and trophoblast cells (3) (x20; haematoxylin – eosin staining) [38].

was made during which the gestational tissue was completely removed. This did not entail any intra- or postoperative complications. The level of β -HCG in blood serum returned to normal 4 weeks after the operation. According to the authors, the hysteroscopic ectomy of ingrown chorion residues can be regarded as primary treatment, and as a secondary option-after an unsuccessful attempt of treatment with Methotrexate [39]. Histopathology of the placenta is shown in **Figure 7**, performed on a 40-year-old patient with a uterine rupture at 13 weeks of gestation, described by the authors A. Esmans et al. [38].

Lim et al. [24] give a clinical observation of placenta accreta and tardive haemorrhage in a patient aged 41 with five pregnancy episodes in the past medical history (1—confinement, 1—caesarean section for presentation of placenta and 3 curettage manipulations). Placenta accreta caused vaginal haemorrhage 3 years after the abortion, in the first trimester, 5 weeks' period. Originally the patient had regular menstruation, further the menses became irregular and heavy within the last year, which was the reason to seek medical attention. The level of serum β -HCG was 0.27 mIU/mL. The ultrasonography failed to visualize the endometrium line. Originally, endometrium cancer or uterine myoma with necrosis of the node was suspected. Actions taken: curettage; subsequently, in connection with the continuing haemorrhage-hysterectomy. The histopathological examination evidenced the placenta tissue having no atypical trophoblast cells [24].

6. Recommendations for interruption of pregnancy in women with localisation of chorion/placenta in the uterine scar area after the caesarean section

The optimal treatment of patients in the first trimester of pregnancy with sonographic diagnosis of suspected chorion increta into the uterine scar remains uncertain. The suggested options include one principal type of treatment or its combination with other methods, like curettage, systemic or local administration of Methotrexate, hysteroscopy, laparotomy and uterine artery embolisation [22, 40].

A review by Timor-Tritsch and Monteagudo [22] analyses the structure of surgical interferences in 44 patients with the given diagnosis: 5 of them (10.6%) underwent uterine arteries embolisation; 38 (78.7%) were subjected to laparotomy; 35 of the latter (74.4%) to hysterectomy; 1 patient of this group was diagnosed with arteriovenous malformation after the dilation and curettage and was subjected to embolisation that subsequently ended in hysterectomy [22].

The sporadic, mainly individual, cases and their results are insufficient to draw a definite conclusion as to which of the performed interference methods is the most effective. It is almost impossible to identify what type of treatment entails maximum number of complications and should be avoided. Gynaecologists, as a rule, undertake curettage, laparoscopy and hysteroscopy, deeming them preferable as the “first-line” approach.

Nevertheless, the following recommendations were made on the basis of the meta-analysis [22]:

- If possible, dilation and curettage should be avoided because this might entail excessive bleeding, repeated curettage (for the haemostatic purpose) with no effect, blood transfusion, and in many cases—laparotomy and loss of uterus.
- Systemic administration of Methotrexate as the only method of treatment should be avoided. The argument: lengthy expectation of the effect or its absence results in further growth of the embryo and vascularisation of the

gestational sac; therefore the subsequent, “second line” of therapy may be accompanied by considerable complications.

- Uterine artery embolisation as a primary treatment should be used cautiously or not be used at all. Lengthy expectation of haemostasis or the haemorrhage fadeout can delay more effective primary treatment which could help in a faster manner or might allow avoiding of hysterectomy.
- Surgical exsection of the impairment area through hysteroscopic method, as well as transvaginal or transabdominal local administration of Methotrexate with or without additional intramuscular dose of this medication, appears to be the optimal means in terms of minimisation of frequency of complications.

7. Conclusion

Interruption of pregnancy in case of a uterine scar can be effected at any pregnancy period using any method; at the same time, no additional risks for the mother are described if the ovum is localized beyond the scar zone.

Ultrasonic examination is an important method for viewing possible ovum presentation to the scar and possible chorion increta into the scar.

At suspicion on chorion ingrowth into the uterine scar, dilation and curettage, systemic administration of Methotrexate, uterine artery embolisation should be avoided, while it is recommended to give preference to combined methods—surgical exsection of the impairment zone through hysteroscopic access and local administration of Methotrexate.


In all cases, patients with the uterine scar (irrespective of localisation of the ovum) are subject to hospitalisation for interruption of pregnancy at any period.

Author details

Galina Dikke and Vladimir Ostromenskiy*
Academy of Medical Education Named After F.I. Inozemcev, Saint-Petersburg,
Russia

*Address all correspondence to: ostromenskyvv@gmail.com

IntechOpen

© 2019 The Author(s). Licensee IntechOpen. This chapter is distributed under the terms of the Creative Commons Attribution License (<http://creativecommons.org/licenses/by/3.0>), which permits unrestricted use, distribution, and reproduction in any medium, provided the original work is properly cited. 

References

- [1] Taha MS et al. Management of failed early pregnancies after previous multiple caesarean sections; an evolving clinical dilemma. *EC Gynaecology*. 2018;**7**(5):163-169
- [2] Collins K, Alka K. Catastrophic consequences of a caesarean scar pregnancy missed on ultrasound. *Australasian Journal of Ultrasound in Medicine*. 2015;**18**(4):150-156
- [3] Chen BA, Reeves MF, Creinin MD, Gilles JM, et al. Misoprostol for treatment of early pregnancy failure in women with prior uterine surgery. *American Journal of Obstetrics and Gynecology*. 2008;**198**(6):626e1-626e5
- [4] Wang YL, Su TH, Huang WC, Weng SS. Laparoscopic management of placenta increta after late first-trimester dilation and evacuation manifesting as an unusual uterine mass. *Journal of Minimally Invasive Gynecology*. 2011;**18**(2):250-253
- [5] Willmott FJ, Scherf C, Ford SM, Lim K. Rupture of uterus in the first trimester during medical termination of pregnancy for exomphalos using mifepristone/misoprostol. *BJOG: An International Journal of Obstetrics and Gynaecology*. 2008;**115**(12):1575-1577
- [6] FIGO/Misoprostol. Recommended regimen. 2017. Available from: <https://www.figo.org/>
- [7] Loïc S et al. Delivery for women with a previous caesarean: Guidelines for clinical practice from the French College of Gynecologists and Obstetricians (CNGOF). *European Journal of Obstetrics, Gynecology, and Reproductive Biology*. 2013;**170**(1):25-32
- [8] NHS. Expectant Management of Miscarriage. 2012
- [9] Allison JL et al. Management of first trimester pregnancy loss can be safely moved into the office. *Reviews in Obstetrics and Gynecology*. 2011;**4**(1):5-14
- [10] Drezett J, Bessa MMM, Pedroso D, Silva ACF, et al. Misoprostol no aborto de segundo trimestre em gestações decorrentes de violência sexual: Análise de efetividade de um protocolo aplicado em serviço público de saúde brasileiro. *Reprodução Climatério*. 2014;**29**(3):105-111
- [11] American College of Obstetricians and Gynecologists. Practice bulletin #135: Second-trimester abortion. *Obstetrics and Gynecology*. 2013;**121**:1394-1406
- [12] Royal College of Obstetricians and Gynaecologists. The Care of Women Requesting Induced Abortion (Evidence-based Clinical Guideline No.7). London: RCOG Press; 2011. 130 p
- [13] Maurer K, Jacobson J, Turok D. Same day cervical preparation with misoprostol prior to second trimester D&E: A case series. *Contraception*. 2013;**88**(1):116-121
- [14] Hammond C, Chasen S. Dilation and evacuation. In: Paul M et al., editors. *Management of Unintended and Abnormal Pregnancies: Comprehensive Abortion Care*. Hoboken, USA: Wiley-Balckwell; 2009. pp. 157-177
- [15] Borgatta L, Roncarib D, Sonalkara S, Mark A, et al. Mifepristone vs. osmotic dilator insertion for cervical preparation prior to surgical abortion at 14-16 weeks: A randomized trial. *Contraception*. 2012;**86**:567-557
- [16] Lyus R, Lohr PA, Taylor J, Morroni C. Outcomes with same-day cervical preparation with Dilapan-S osmotic dilators and vaginal misoprostol before dilatation and evacuation at 18 to

21+6 weeks' gestation. *Contraception*. 2013;**87**(1):71-75

[17] Fox MC, Krajewski CM. Cervical preparation for second-trimester surgical abortion prior to 20 weeks' gestation: SFP clinical guidelines. *Contraception*. 2014;**89**:75-84

[18] Chambers DG, Willcourt RJ, Laver AR, Baird JK, Herbert WY. Comparison of Dilapan-S and laminaria for cervical priming before surgical pregnancy termination at 17-22 weeks' gestation. *International Journal of Women's Health*. 2011;**3**:347-352

[19] Rahimi-Sharbat F, Jamal A, Mesdaghinia E, Abedzadeh-Kalahroudi M, et al. Ultrasound detection of placenta accreta in the first trimester of pregnancy. *Iranian Journal of Reproductive Medicine*. 2014;**12**(6):421-426

[20] Hudon L, Belfort MA, Broome DR. Diagnosis and management of placenta percreta: A review. *Obstetrical & Gynecological Survey*. 1998;**53**(8):509-517

[21] Wu S, Kocherginsky M, Hibbard JU. Abnormal placentation: Twenty-year analysis. *American Journal of Obstetrics and Gynecology*. 2005;**192**(5):1458-1461

[22] Timor-Tritsch IE, Monteagudo A. Unforeseen consequences of the increasing rate of caesarean deliveries: Early placenta accreta and caesarean scar pregnancy. *American Journal of Obstetrics and Gynecology*. 2012;**210**:371-374

[23] Abbas AM, Shymaa AM, Osama SA, Abdalmageed S. Placenta percreta presenting with marked hemoperitoneum in the first trimester of pregnancy: A case report. *Middle East Fertility Society Journal*. 2018;**23**(3):251-253. Available from: <https://www.sciencedirect.com/>

[24] Lim S, Ha SY, Lee KB, Lee JS. Retained placenta accreta after a first-trimester abortion manifesting as an uterine mass. *Obstetrics & Gynecology Science*. 2013;**56**(3):205-207

[25] Takeda A, Koyama K, Imoto S. Conservative management of placenta increta after first trimester abortion by transcatheter arterial chemoembolization: A case report and review of the literature. *Archives of Gynecology and Obstetrics*. 2010;**281**(3):381-386

[26] Jang DG, Lee GSR, Yoon JH, Lee SJ. Placenta percreta-induced uterine rupture diagnosed by laparoscopy in the first trimester: Case report. *International Journal of Medical Sciences*. 2011;**8**(5):424-427

[27] Patel MA. Scar ectopic pregnancy. *Journal of Obstetrics and Gynaecology of India*. 2015;**65**(6):372-375

[28] Dew L, Harris S, Yost N, Magee K, de Prisco G. Second trimester placenta percreta presenting as acute abdomen. *Proceedings (Baylor University Medical Center)*. 2015;**28**(1):38-40

[29] Belfort MA. Placenta accreta. *American Journal of Obstetrics and Gynecology*. 2010;**203**(5):430-439

[30] Usta IM, Hobeika EM, Musa AA, Gabriel GE, Nassar AH. Placenta previa-accreta: Risk factors and complications. (Case-control level II-2). *American Journal of Obstetrics and Gynecology*. 2005;**193**:1045-1049

[31] Richardson A, Gallos I, Dobson S, Campbell BK, Coomarasamy A, Raine-Fenning N. Accuracy of first-trimester ultrasound in diagnosis of intrauterine pregnancy prior to visualization of the yolk sac: A systematic review and meta-analysis. *Ultrasound in Obstetrics & Gynecology*. 2015;**46**(2):142-149. DOI: 10.1002/uog

- [32] Shawky M, AbouBieh E, Masood A. Gray scale and doppler ultrasound in placenta accreta: Optimization of ultrasound signs. *Egyptian Journal of Radiology and Nuclear Medicine*. 2016;**47**(3):1111-1115
- [33] Twickler DM, Lucas MJ, Balis AB, Santos-Ramos R, Martin L, Malone S, et al. Color flow mapping for myometrial invasion in women with a prior caesarean delivery. *The Journal of Maternal-Fetal Medicine*. 2000;**9**(6):330-335
- [34] Warshak CR, Eskander R, Hull AD, Scioscia AL, Mattrey RF, Benirschke K, et al. Accuracy of ultrasonography and magnetic resonance imaging in the diagnosis of placenta accreta. *Obstetrics and Gynecology*. 2006;**108** (3 Pt 1):573-581
- [35] Varghese B, Singh N, George RAN, Gilvaz S. Magnetic resonance imaging of placenta accrete. *Indian Journal of Radiology and Imaging*. 2013;**23**(4):379-385
- [36] Riteau AS, Tassin M, Chambon G, Le Vaillant C, de Laveaucoupet J, Quéré MP, et al. Accuracy of ultrasonography and magnetic resonance imaging in the diagnosis of placenta accreta. *PLoS ONE*. 2014;**9**(4):e94866. DOI: 10.1371/journal.pone.0094866
- [37] Ju W, Kim SC. Placenta increta after first-trimester dilatation and curettage manifesting as an unusual uterine mass: Magnetic resonance findings. *Acta Radiologica*. 2007;**48**(8):938-940
- [38] Esmans A, Gerris J, Corthout E, Verdonk P, Declercq S. Placenta percreta causing rupture of an unscarred uterus at the end of the first trimester of pregnancy: Case report. *Human Reproduction*. 2004;**19**(10):2401-2403
- [39] Chou Y-M, Wu D, Wu K-Y, Lee C-L. Hysteroscopic removal of caesarean scar pregnancy after methotrexate treatment failure. *Gynecology and Minimally Invasive Therapy*. 2013;**2**(2):70-72. DOI: 10.1016/j.gmit.2013.02.008
- [40] Boza A, Boza B, Api M. Caesarean scar pregnancy managed with conservative treatment. *Iranian Journal of Medical Sciences*. 2016;**41**:450-455