

# We are IntechOpen, the world's leading publisher of Open Access books Built by scientists, for scientists

6,900

Open access books available

186,000

International authors and editors

200M

Downloads

Our authors are among the

154

Countries delivered to

TOP 1%

most cited scientists

12.2%

Contributors from top 500 universities



WEB OF SCIENCE™

Selection of our books indexed in the Book Citation Index  
in Web of Science™ Core Collection (BKCI)

Interested in publishing with us?  
Contact [book.department@intechopen.com](mailto:book.department@intechopen.com)

Numbers displayed above are based on latest data collected.  
For more information visit [www.intechopen.com](http://www.intechopen.com)



# Mycotic Aortic Aneurysms

*Lucas Ribé Bernal, Lucía Requejo, Aida Ribes and Manuel Miralles*

## Abstract

Various studies have evaluated the possibilities of surgical repair of mycotic aortic aneurysms (MAAs). Open surgical repair has usually been accepted as the gold standard treatment of MAAs. The main concern is that it carries a significant mortality risk, varying from 20 to 40% in different studies, and a 5-year survival rate of 30–50%. The largest study of open surgical treatment of mycotic aortic aneurysms (MAA) was published in 2018, and consisted of 187 patients of whom open repairs were performed in 107 patients (57%). Most of the endovascular series conclude that endovascular treatment of MAA is feasible and an acceptable alternative treatment to open repair. Although endovascular repair might be a durable option for some patients, late infection-associated complications frequently occur and are often lethal. An overall analysis of this rare pathology, its different diagnostic modalities, treatment options, and prognosis are presented and discussed in this chapter.

**Keywords:** aneurysm, endovascular, aortic repair, infected

## 1. Introduction

Infected aortic aneurysms, also known as “mycotic aortic aneurysms” (or microbial arteritis with aneurysms) are most commonly caused by bacterial infections. Around 1% of arterial aneurysms may be associated with an arterial infection. Although the prevalence of mycotic aortic aneurysms (MAAs) is low, its clinical impact may be severe and represents one of the most difficult arterial diseases to treat successfully.

In the early nineteenth century, Jean Nicolas Corvisart coined the term “vegetation” as it resembled a cauliflower, describing organic lesions of the heart. In his monograph, presented in 1806, Corvisart wrote that he had observed six cases of valve disease with vegetations [1].

Some years later, in 1815, Joseph Hodgson performed some illustrations of ulcerating/perforating aortic valve endocarditis. He described the valve vegetations as “wart-like excrescences” using the term “fungus” in a patient who presented with an aortic root abscess. This report was probably the first to document peripheral embolization [2].

In 1852, a British physician, William Kirkes, described that fibrinous fragments of valve vegetations were found in the kidneys, cerebral artery, and spleen in patients presenting with fever, heart murmur, purple skin spots, and skin nodules (later called “Osler nodules” by Emanuel Libman). He described how these fragments could be detached from the heart valves, passed into the blood, and may be arrested in the aorta or its branches [3, 4].

The suggestion of an infection point of entry and transportation by blood flow was reinforced by a pioneering microbiologist, Edwin Klebs. In 1878, he suggested that cases of endocarditis were always due to an infectious organism [5].

The first complete description of an infected aneurysm was presented in 1885 by Osler. He presented the first broad report of this entity with a complete description of clinical and anatomical features of infective endocarditis as the cause of these arterial infections. The report included clinical features, anatomical location in the aorta, and cases of “ulcer formation and perforation of the aorta with production of multiple aneurysms” [6].

There were some other early reports that explained how infected aortitis was nearly always secondary to endocarditis [3, 5, 7, 8]. In another report published in 1923, a series of 217 patients with mycotic aneurysms was presented, showing that 86% of mycotic aneurysms were associated with infective endocarditis [9]. Although most infected aneurysms are due to bacterial infections, the term “mycotic,” which is still misleading, is used to describe these aneurysms that arise after an inflammatory destruction of the arterial wall happens associated to arterial embolization. A wide variety of terminologies have been used to describe infected aortic aneurysms, although most of them have not received a great acceptance. Some of these include mycotic aortic aneurysms (MAAs), suppurative arteritis, septic aortic pseudoaneurysm (SAP), cryptogenic mycotic aneurysm, and microbial arteritis with aneurysms [10–13].

2. Etiology

**Table 1** includes a previous classification of infected aneurysms (**Table 1**) [14]. The main etiology of MAAs is considered to be similar to that of arterial aneurysms and includes the following:

- 1. *Contiguous infection*: an infection localized in a determined area might extend and affect the arterial wall. This can happen after bone infections (osteomyelitis and vertebral infections), intraabdominal infections, abscesses, pancreatitis, and pancreatic pseudocysts. Arterial aneurysms have been described after surgical procedures such as a cholecystectomy, appendectomy, knee replacement surgery, or intestinal surgery [15, 16].

	Mycotic aneurysm	Infected aneurysm	Microbial arteritis	Traumatic infected pseudoaneurysm	Contiguous septicemia
Etiology	Endocarditis	Bacteremia	Bacteremia	Traumatic	Bacteremia
Location	Any vessel	Distal aorta	Aortoiliac	Femoral, carotid	Aortoiliac
Age	30–50	>50	>50	<30	>50
Sex	F > M	M	M	M/F	M/F
Incidence	Rare	Unusual	Common	Common	Unusual
Number	Multiple	Single	Single	Multiple	Multiple
Bacteriology	Gram-positive cocci	Staphylococcus aureus, Escherichia coli	Salmonella	Polymicrobial	

M: Male. F: Female.

**Table 1.**  
Modified classification of infected aortic aneurysms according to Wilson et al. [14].

2. *Bacteremic seeding*: all arterial layers can be affected by bacteremic seeding, which may occur when there is a preexisting aneurysm, atherosclerotic plaque, or intimal injury. The intima is usually resistant to infection. Once it becomes diseased, bacteria may progress through it into other layers (media or adventitia). As the aorta is the most frequent site of atherosclerosis, it is also the most common location of primary arterial infection.
3. *Septic embolism*: embolization from heart chambers secondary to endocarditis (vegetations) can affect the intimal layer or vasa vasorum of vessels, leading to arterial wall infection and MAA formation. Embolization may occur in between 25 and 50% of patients with endocarditis, but only 1–5% develop symptomatic MAAs [17].
4. *Direct bacterial inoculation*: infected pseudoaneurysms after arterial injuries have become a common cause of mycotic aneurysms. The common femoral artery (CFA) is the most frequently affected vessel. Vascular trauma, gunshot or stab wounds to arteries, intra-arterial drug injection, and iatrogenic arterial injuries can produce a direct inoculation of bacteria into the vessel wall. Infected pseudoaneurysms resulting from drug injection using dirty needles may involve the CFA, external iliac, subclavian, and carotid arteries [18].
5. *Atherosclerosis*: MAAs may arise from preexisting aneurysms or atherosclerotic plaques.

### 3. Risk factors

Some important risk factors for development of MAAs include some of the following:

1. *Infection*: other sources of infection are the main cause of MAAs. Still today, the most common cause of MAAs is endocarditis, which explains more than 30% of cases [17]. The second most common infectious cause of MAAs is bacteraemia. Other infections have also been reported and associated to MAAs, including cholecystitis, pancreatitis, diverticulitis, urinary tract infections (UTI), soft tissue infections, and osteomyelitis.
2. *Arterial injuries*: previously described in etiology.
3. *Immunosuppression*: certain diseases and treatments may lead to impaired immunity states, including chronic corticoid use, alcohol abuse, diabetes mellitus, malignancy, chemotherapy, and severe neutropenia.

### 4. Epidemiology

Infected arterial aneurysms are relatively uncommon and can affect very different anatomical location and practically any artery. Depending on different studies presented in the literature, the most common sites for mycotic arterial aneurysms are the aorta and the intracranial cerebral arteries. Following Baddour publication in 2015, regarding an American Heart Association (AHA) statement report on infective endocarditis (IE) in adults, the most common site of mycotic aneurysms was the intracranial arteries, with an incidence of 1.5–5% of cases, and an overall mortality among those with IE of 60% [17]. Some other series have reported similar

findings, with intracranial arteries being the most common site for mycotic aneurysms (especially the middle cerebral artery), with an incidence of symptomatic peripheral mycotic aneurysms of 1–5% [19].

Some other reports have published that the higher incidence sites of infected aneurysms are the abdominal aorta, followed by peripheral arteries (typically occurring at bifurcation sites), cerebral arteries, and visceral arteries, in descending order of frequency [20]. On the other hand, previous historical series have reported that the abdominal aorta was the second most common site of aneurysm infection, with the common femoral artery being the most common site [21].

Mycotic aneurysms of coronary arteries are rare, but have also been described. González et al. performed a review including 922 cases of definite infective endocarditis (IE), and reported a 2% rate of symptomatic peripheral mycotic aneurysms. In their review, 66% of mycotic aneurysms were intracranial (in the region of the middle cerebral artery) and 34% were extracranial [19].

With regard to infected aneurysms of the aorta, most reported series have less than 50 patients. Most series concur that the most common aortic location for infected aneurysms of the aorta is the infrarenal aorta, with a similar distribution of cases between the aortic arch and descending aorta.

One of the largest series involving MAAs presented 36 cases of aortic infection, with the following epidemiology data: infrarenal aortic aneurysm in 15 patients (42%), a suprarenal aneurysm in 3 (8%), a thoracic aneurysm in 5 (14%), and a thoracoabdominal (TAAA) in 13 (36%) [22].

A large multicenter European study was published in 2014, where data from 123 patients with 130 identified MAAs were analyzed. Similar epidemiologic findings were found, with infrarenal location being the most common (51%), followed by descending MAAs (28%), paravisceral (12%), multiple MAAs (6%), and arch MAAs (3%) [23].

Primary MAAs are a challenging and very complex vascular pathology. Although they represent a small proportion of patients within all aortic aneurysms, when left untreated, they almost always develop into rupture or lethal complications. Without treatment, there is a very high level of lethal complications, including aortic rupture, abscess formation, and sepsis [17].

## 5. Microbiology

With regard to bacteriological patterns in infected aortic aneurysms, there have been some changes in bacterial patterns depending on the published series decade. Some initial studies on aortic infection have presented their results confirming *Staphylococcus aureus* as the most common infectious cause, followed by *Salmonella* organisms [24]. A series of 17 patients with MAAs reviewed in 1998 presented *Staphylococcus aureus* as the most common responsible organism (29% of patients), followed by *Salmonella* organisms (24% of patients) [25].

This change in bacteriologic patterns was already observed in the early 1980s, when comparing those series from before 1965 and those from after 1965. Collected series from English language reported before 1984 (178 patients with 243 MAAs) showed that *S. aureus* was the most common organism (28% of cultures), followed by *Salmonella* (15% of aneurysms) and *Streptococcus* (10% of patients). This series reported how there was some alteration in the involved bacterial flora before and after 1965. A decrease in the incidence of *Salmonella* infections was seen after 1965 (10% compared with 38% prior to that date), as well as an increase in the incidence of *Staphylococcus aureus* (from 19 to 30%) [21].

Some current series have presented a much higher incidence of Gram-negative organisms compared with older series, with Gram-negative microorganisms seen in up to 35%



of cases. Different groups have described a higher incidence of aneurysm rupture and mortality in those patients with Gram-negative infections compared with Gram-positive organisms. Aortic aneurysms with *Salmonella*-related infections have been associated with a faster progression and higher risk of early rupture [23]. Recent series have published an increase in Gram-negative bacteria in MAAs, including *Salmonella*, *E. coli*, *Campylobacter*, *Enterobacter*, *Serratia*, and *Proteus* [23, 26]. Some of these series have reported even higher rates in Gram-negative bacteria (*Salmonella*) compared to Gram-positive [26–29].

Although bacteriologic patterns continue to evolve, *Staphylococcus aureus* remains the most common pathogen, reported in up to 28–71% of cases [21, 23]. Reports from North America and Europe have described Gram-positive *Staphylococcus* as the most prevalent bacterial responsible for MAAs. On the other hand, there are reported differences regarding infective organisms depending on the geographic area. Many reports from Asia have presented Gram-negative *Salmonella* species as the most prevalent infecting organism in MAAs [23, 27, 28, 30].

Depending on the different series, anatomical location, and geographic area, blood cultures have been found to be positive in 50–85% of patients, with organisms being able to be isolated from the aneurysmal tissue in 62–76% of patients [23–26].

Some reviews have related mortality with the type of microorganism involved in aortic infections. In a series of 22 patients who presented with aortic aneurysmal infection, mortality was 36% in those with *Salmonella*-infected aortas, and 82% in those patients with aortic infections due to other microorganisms. Some other series have reported similar findings in terms of lower mortality associated with *Salmonella*-aortic infections [23, 27–29].

## 6. Clinical presentation

Symptoms of mycotic aortic aneurysms are very commonly nonspecific in the initial development of the disease. Patients with MAAs often present with fever of unknown cause. Many series have reported fever as the most common presenting sign of MAAs. These patients with febrile illness frequently present with insidious onset, apathy, weight loss, and general malaise [24].

A high index of suspicion is of great importance in order to avoid delay in diagnosis, as the natural history of most of these untreated mycotic aortic aneurysms is fatality. The most common causes of death in these patients are lethal sepsis or massive hemorrhage due to rupture [24, 31].

A vast majority of patients are symptomatic at the time of diagnosis. Most groups have outlined rates of MAAs as symptomatic on diagnosis involving 93–100% of cases [28, 31]. One of the most common symptoms at the time of initial evaluation is localized pain. When present, pain is most commonly localized in the abdomen, chest, or back. Some groups have reported pain as the most common initial clinical symptom of MAAs, in up to 88% of patients [28, 32]. It has been previously reported that the classic triad of mycotic aortic aneurysms includes fever, pulsatile mass, and back pain. This triad has been described in around 40% of patients [31].

Other manifestations have been described associated to MAAs, including the following:

### 1. Rupture

Massive hemorrhage may be a sign of MAAs. Some reports have described aortic rupture in MAAs in 50–85% of patients [24, 28, 31].

### 2. Expanding hematoma

Intraabdominal retroperitoneal hematomas usually produce hypovolemic shock. In cases of infected aortoiliac or associated mycotic femoral aneurysms, superficial expanding hematomas might be seen.

### 3. Acute ischemia of the lower limbs

Embolization is a common clinical sign that increases limb loss and mortality rates.

### 4. Mesenteric ischemia

Infected pararenal or thoracoabdominal aortic aneurysms (TAAA) involving the superior mesenteric artery (SMA) may cause acute thrombosis of the SMA or embolization into the distal mesenteric branches, leading to intestinal ischemia.

### 5. Osteomyelitis

Infection of the aorta may produce contiguous infection of the lumbar or thoracic vertebra. Interchangeably, a bone infection affecting the vertebra may provoke an infection of an aortic aneurysm.

### 6. Gastrointestinal bleeding

Although rare, primary aorto-duodenal fistula may occur due to an infected aortic aneurysm, when erosion of the vessel affects the third portion of the duodenum. Erosion and rupture of a MAA into a gastrointestinal structure, such as the esophagus or appendix, have also been described.

### 7. Intraabdominal abscess

### 8. Hemoptysis, dysphagia, and hoarseness

Rupture of a mycotic thoracic aortic aneurysm or pseudoaneurysm, or aorto-bronchial fistula formation may lead to hemoptysis [33].

### 9. Heart failure

### 10. Compression

Constriction or displacement of nearby structures may be present due to MAAs.

## 7. Infected versus inflammatory AAA

Although inflammation is frequently associated with aortic aneurysms, the classical appearance of an AAA needs to be differentiated from aortic aneurysms that are infected. Also mycotic aneurysms need to be addressed and distinguished from a clinical entity known as “inflammatory aneurysms.”

Approximately 3–10% of abdominal aortic aneurysms are characterized by increased inflammation surrounding the aneurysm. These inflammatory abdominal aortic aneurysms (IAAA) are typically differentiated from common AAAs by certain features. These include a classical description of periaortic inflammation as a white gleaming fibrotic surface with a thickened aneurysmal wall [34].

Other common features of IAAAs include major adhesions and fibrosis of close anatomical structures, such as the duodenum and ureters. This fibrosis commonly leads to indistinct retroperitoneal tissue planes on imaging studies.

The classic triad of IAAAs includes abdominal pain, weight loss, and elevation of inflammatory markers (CRP, ESR). Inflammatory aortic aneurysms are not associated with periaortic air or fluid and are not infected (tissue samples and blood cultures are negative).

## 8. Diagnosis

The diagnosis of mycotic aortic aneurysms might be very challenging. In the presence of fever, general malaise, and a pulsatile abdominal mass or aortic aneurysm in imaging testing, a MAA should be suspected and investigated. An early diagnosis of MAAs is essential as it is associated with a high rate of hemorrhage due to rupture and high rate of early sepsis and mortality. Once a MAA is suspected, the patient should be investigated with laboratory testing and imaging studies.

Various definitions have been proposed for the diagnosis of mycotic aneurysms, including clinical, laboratory and radiological features.

Most series agree that the definition of mycotic aortic aneurysm should include at least two of the following criteria:

- Fever, sepsis, or localized pain.
- Abnormal laboratory findings (elevated white cell count: WBC, C-reactive protein: CRP, or erythrocyte sedimentation rate: ESR).
- Positive blood or aortic tissue cultures.
- Specific radiologic findings, including: periaortic soft tissue air, fluid, or mass, saccular/multilobular aneurysm or pseudoaneurysm.

Some groups have used specific definitions to delineate mycotic aortic aneurysms, including all of the following: fever or sepsis, abnormal laboratory findings (elevated CRP or white cell count), positive blood cultures, and radiologic studies showing a false aneurysm (with or without stranding), periaortic fluid, or air around the aorta [35]. Common radiologic (CT and MRI) features of MAAs are an irregular aortic wall, a lobulated vascular periaortic mass, and peri-aneurysmal gas/soft-tissue mass/edema.

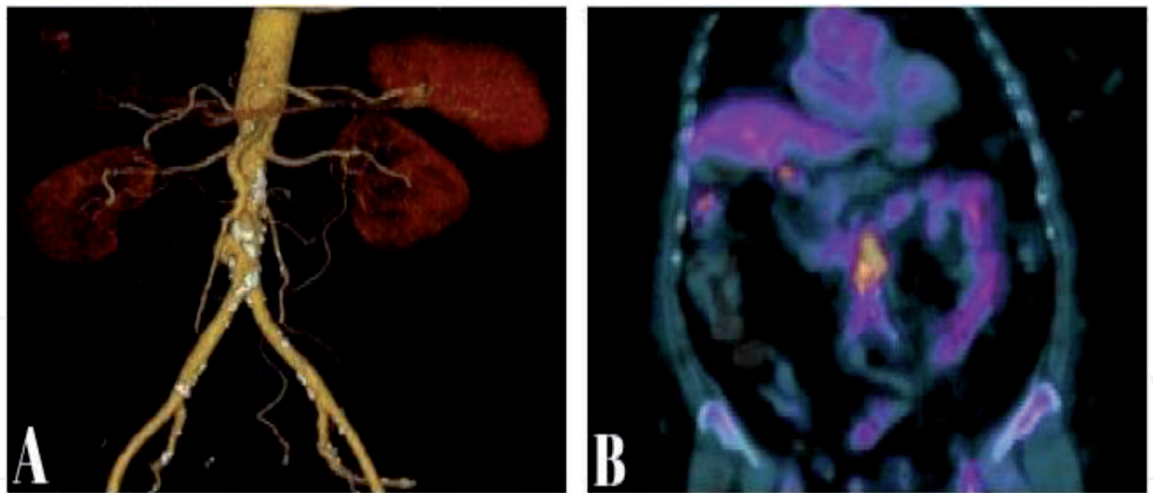
Although blood cultures may be negative in around 25–50% of patients, negative blood cultures alone are not enough to rule out infected aneurysms, and diagnostic testing should be completed.

Ultrasound scanning may be useful in diagnosing the presence of an aortic aneurysm, but it is not reliable for specific diagnosis of aortic infection. Digital subtraction angiography (DSA), besides being an invasive procedure, is not reliable for specific identification of features that suggest and diagnose an infected aneurysm.

Imaging studies for detection of MAAs include computed tomography scan (CT) and multislice CT angiography with 3D reconstruction, as well as magnetic resonance imaging (MRI). For many groups, MRI with gadolinium enhancement is becoming the noninvasive imaging modality of choice for the diagnosis of acute or chronic aortitis.

Nuclear medicine studies, including fluorodeoxyglucose-positron emission tomography (FDG-PET) and nuclear gallium scanning, are alternative modalities





**Figure 1.** CT scan showing a reconstruction of a distal infrarenal MAA (A). Fused frontal imaging of the contrast CT and FDG-PET scan showing highly elevated FDG uptake in the distal aorta (B).

	MAA grade I	MAA grade II	MAA grade III	MAA grade IV
Radiologic findings	1. A. ulcer or 2. A. mass or 3. A. pseudoaneurysm	Grade I and periaortic edema	Grade I and periaortic gas	Grade I and rupture (*)
Inflammatory markers (CRP and ESR)	+	+	+++	+++
Aortic tissue	—	+/-	+	+
Incidence	Rare	Very rare	Very rare	Very rare
Bacteriology	Absent	Present	Present	Present

MAA: mycotic aortic aneurysm; A.: aortic; CRP: C-reactive protein; ESR: elevated sedimentation rate; (\*): contained or not; +: positive; +++: highly positive.

**Table 2.** Ribé’s proposal of new modified classification of MAAs.

for evaluating mycotic aortic aneurysms that are becoming increasingly useful. PET-CT testing has a very high sensitivity and both high positive and negative predictive values for aortic graft infection, and also provides important information in the diagnosis of mycotic aneurysms [35].

Current imaging studies have reported variable sensitivities regarding FDG-PET. Most series have published specificities of 88–100% for 18F-FDG PET and PET-CT for diagnosing active inflammation in arteritis (**Figure 1**) [35–37].

There are very few classifications regarding infected aortic aneurysms. The author would like to add a new modified classification of MAAs (**Table 2**).

## 9. Management of MAAs

### 9.1 Antibiotherapy

#### 9.1.1 Recommendations

Various groups recommend vancomycin plus an anti-Gram-negative antibiotic (for coverage of *Salmonella* and Gram-negative microorganisms), including

intravenous fluoroquinolone, ceftriaxone, and piperacillin-tazobactam. Results of blood cultures and tissue samples are monitored for hours or days, until a pathogen is correctly identified. Empirical antimicrobial therapy is maintained during this time, and reviewed once a pathogen is defined. Antibiotherapy should then be tailored to cultures and antimicrobial susceptibility [23, 24, 31].

In general, at least 6 weeks of intravenous plus oral antibiotics should be implemented. However, there are no data to support specific duration of antibiotic therapy. Several authors have advocated long-term oral antibiotics after hospital discharge for all patients undergoing intervention, especially those who underwent endovascular repair. If positive cultures are obtained from tissue samples, life-long antibiotic therapy should be considered [31, 32, 38, 39].

## 9.2 Surgery

### 9.2.1 Excision and ligation without arterial reconstruction

The aneurysm should be dissected back to normal aortic tissue. Once the aneurysm has been resected, the proximal aorta should be oversewn with a nonabsorbable suture, ligated 1–2 cm proximally, and possible omental coverage, to prevent blowout of the arterial stump.

### 9.2.2 Excision with immediate revascularization

In those cases where it is likely that the patient may develop acute ischemia after arterial ligation, immediate revascularization should be considered. Extra-anatomical bypass (axillobifemoral bypass graft) after aneurysm resection and stump closure has been traditionally used. Autogenous vein, antibiotic, and silver impregnated grafts are also used. Other reported options are femoral-popliteal deep veins, cryopreserved arterial allografts, and Dacron prosthetic grafts [39–41].

### 9.2.3 Excision with interval reconstruction

#### 9.2.3.1 Hybrid repair

Some groups have described this technique of retrograde visceral revascularization (1, 2, 3, or 4 visceral vessels might be revascularized), followed by TEVAR/EVAR. The technique is performed through a midline laparotomy incision. When using the infrarenal aorta as the inflow vessel, a bifurcated 14 × 7 mm Dacron graft is prepared. Two side grafts (usually 6 mm Dacron grafts) are anastomosed to the lateral aspect of the bifurcated graft, to create the 4-graft retrograde bypass. Correct routing and fashioning of the grafts are crucial to avoid early graft thrombosis. The right branch (6–7 mm) is anastomosed to the right renal artery (RA). The right 7 mm graft would be anastomosed side-to-end to the coeliac axis (tunneled in a retropancreatic position). To avoid graft kinking, the left 7 mm graft is anastomosed in an end-to-side fashion to the SMA in a “lazy C” configuration [42].

## 9.3 Endovascular

Endovascular repair may be a suitable option for infected aortic aneurysms in high-risk patients, when open surgery mortality would be prohibitive. In cases of ruptured MAAs, endovascular repair may be an appropriate alternative, as a definitive treatment or until debridement and a final treatment may be performed. There is still ongoing controversy in the literature regarding the endovascular option as a main therapy or as an alternative [23, 30, 34, 39, 43].

Procedures are usually performed under epidural or general anesthesia, with open exposure of one or both common femoral arteries. In those undergoing TEVAR, cerebrospinal fluid (CSF) drainage should be considered in those patients with expected long thoracic segment coverage. Coverage of the left subclavian artery (LSA) is usually avoided unless completely necessary. Some authors have described aneurysm sac drainage after EVAR. The procedure is usually performed in a prone position. A 21-G needle is inserted into the aneurysm sac. Following dilation, a 14–16 Fr drainage catheter is used to aspirate and send the contents for microbiological analysis. Pryluck et al. consider that it might aid to decrease the infectious content of the aneurysm sac and effectively prevent late reinfection [44].

## **10. Prosthetic aortic infection**

Although this chapter tries to focus on primary MAAs, infected aneurysms or pseudoaneurysms can also occur following prosthetic replacement of the aorta.

The incidence of prosthetic aortic graft infection has been described in 0.5–2% of cases, including both early and delayed-onset complications [45]. All these prosthetic graft infections are associated with high morbidity and mortality rates. As previously described in the chapter, different surgical techniques have been described for repair of infected MAAs and aortic graft infection. Removal of all infected tissue and infected grafts are essential for a successful result.

Plastic surgery-reassembling procedures have also been described for coverage of arterial tissue after reconstruction, especially after infections involving the ascending aorta, aortic arch, and descending thoracic aorta. These procedures involve musculo-cutaneous pedicled flaps using various different muscles (including rectus abdominis, pectoralis major, latissimus dorsi, and vastus lateralis muscles) [46]. The application of these vascularized muscle and omental flaps by plastic surgeons, in conjunction with cardiothoracic and vascular surgeons, might be an important alternative for an adequate management of these prosthetic aortic infections. Omental flaps have been previously described as the most common applied type of autologous flap for coverage of ascending aorta, aortic arch, and descending thoracic aortic graft infections. Other options for wound closure in cases of infected prosthetic aortic grafts with associated wound infection include different types of vacuum-assisted closure (VAC) devices [46].

## **11. Clinical cases**

We present here a report of 3 cases of MAAs treated in our center, with a description of the procedural techniques and outcomes.

### **11.1 Clinical case description**

The first patient (JGR) was a 72-year-old male with a medical background of smoking, who was evaluated for fever and general malaise. Physical examination revealed an expansive abdominal pulsatile mass, with pain on palpation. Laboratory testing showed elevation of elevated WBC ( $22 \times 10^3/\mu\text{L}$ ), and inflammatory markers (CRP, ESR, and procalcitonin). CT angiogram revealed an infected infrarenal AAA, measuring 9.2 cm in diameter, with periaortic edema and gas (**Figure 2**). After cardiac, pulmonary, and renal evaluation, the patient was treated with an aorto-aortic silver-coated Dacron bypass graft. Blood cultures were positive for *Staphylococcus aureus*. After an uneventful recovery, he was discharged from hospital 10 days after surgery on long-term antibiotics.

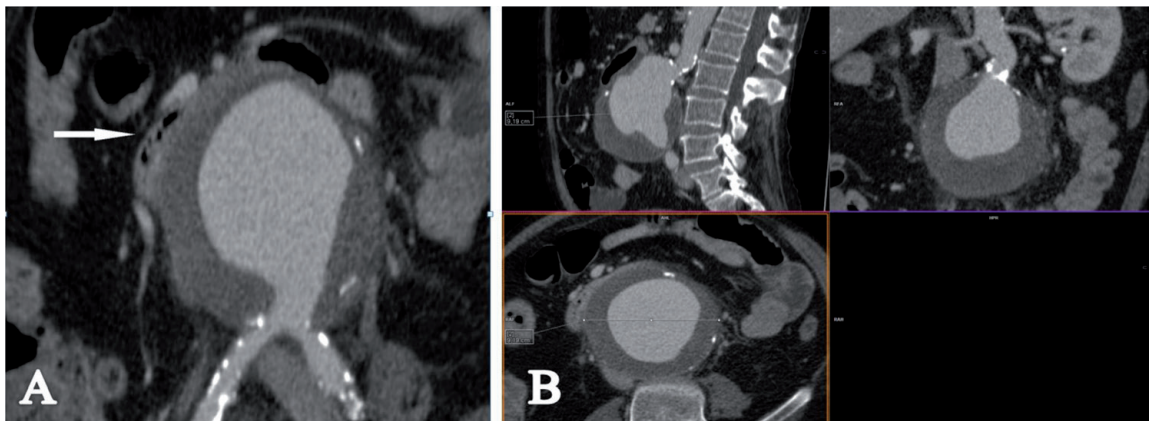


The second patient (ABM) was a 66-year-old male with a medical history of chronic obstructive pulmonary disease (COPD), hypertension, and smoking. He was initially evaluated in the emergency department for hematochezia, fever, and abdominal pain. Physical examination showed a distended abdomen with an abdominal pulsatile mass. Laboratory testing showed markedly elevated inflammatory markers, including CRP and ESR. The patient presented sudden rectal bleeding and hypotension. Emergent CT angiography scan demonstrated a MAA at the level of the infrarenal aorta, with an associated primary aorto-enteric fistula (AEF) **Figure 3**.

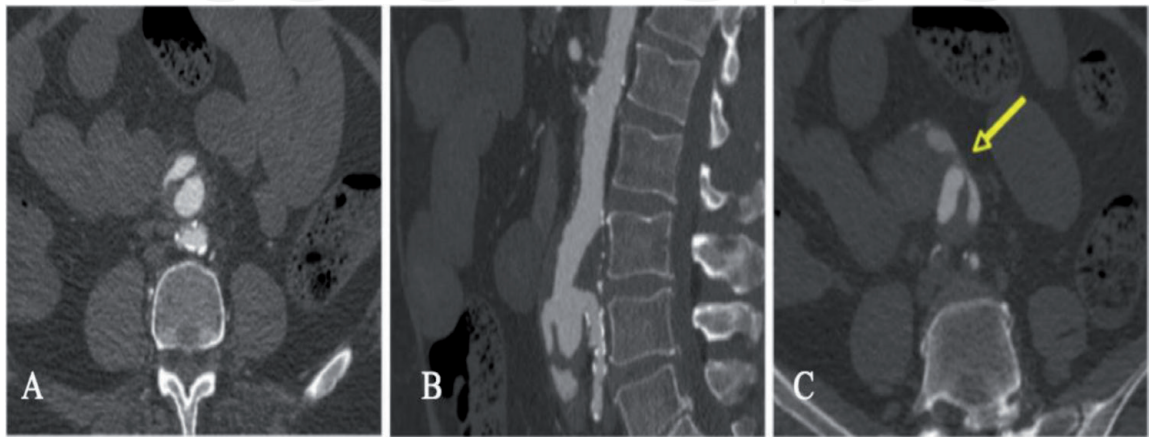
He was taken to the operating room and had an urgent open aortic and small bowel repair. An aorto-aortic straight bypass graft, using a silver-coated-Dacron graft, was performed. Repair of the fistula into the jejunum was carried out with resection of the perforated bowel, and end-to-end anastomosis of a non-affected segment of jejunum. A Jackson-Pratt drain was left for 6 postoperative days. Blood cultures and aortic tissue sample were both positive for *Salmonella* sp. The patient was kept in the intensive care unit (ICU) for 5 days. After evaluation by the infectious disease team, he was discharged home on long-term antibiotics 16 days after the surgery.

He had a follow-up at 1, 6, and 12 months. His last CT scan showed no signs of aortic infection, without elevation of inflammatory markers on laboratory testing. His latest physical examination revealed no vascular abnormalities.

The third patient (RMS) was a 74-year-old male who was admitted with persistent back pain and fever. CT scan revealed a juxtarenal infected aortic aneurysm



**Figure 2.**  
Patient 1. Chest computed tomography (CT) scan presenting a 9-cm MAA in the infrarenal aorta. MAA compressing (white arrow) the duodenum (A). Sagittal, frontal, and sagittal planes (B). MAA: mycotic aortic aneurysm.



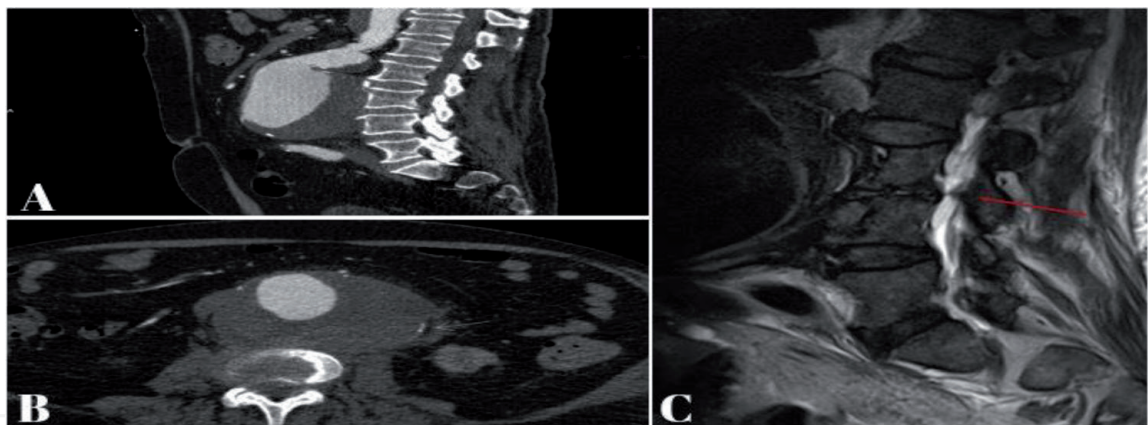
**Figure 3.**  
Patient 2. Abdomen angiography CT scan showing an infrarenal MAA. Multilobular mass seen in axial (A) and sagittal (B) planes. Presence of an aortoenteric fistula (AEF) at the site (yellow arrow) of this MAA (C).

with gas within the aneurysmal sac, measuring 9 cm in diameter (**Figure 4**). Further preoperative MRI-imaging revealed spondylodiscitis at the level of the lumbar vertebra L3-L4 (**Figure 4**).

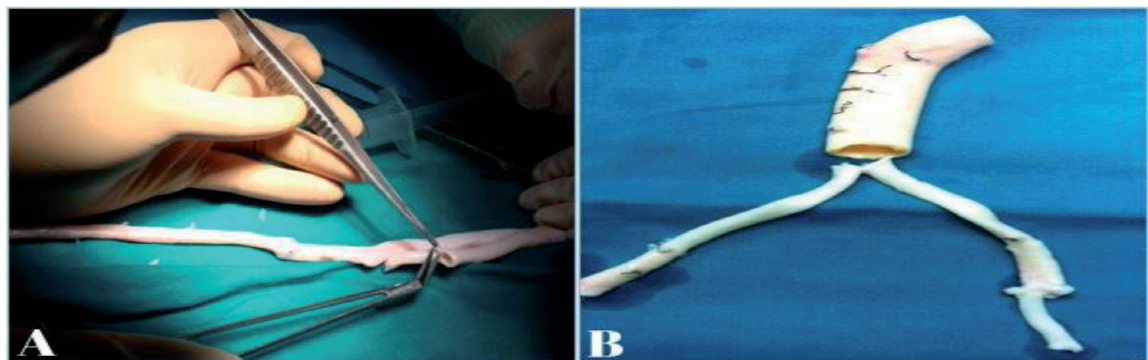
The patient was taken to the operating room and underwent an aorto-aortic straight rifampicin-bonded Dacron bypass-graft. Subsequent aortic wall tissue and blood cultures were found to be both positive for *Staphylococcus aureus*. Intravenous antibiotics were continued throughout the admission period and for 3 months after. After evaluation of the vertebral osteomyelitis by the orthopedic and microbiologist teams, he was discharged from the hospital 14 days after surgery on long-term intravenous (initially) and oral antibiotics.

Since 2011, we have performed in our center a novel hybrid repair in 2 cases of mycotic aortic aneurysms (MAAs), one of them a primary juxtarenal MAA, and the other one a suspected inflammatory infrarenal aortic aneurysm. This hybrid repair consisted in a two-stage procedure, performed within at least one-month difference, or once inflammatory markers and radiologic imaging studies had normalized.

The first stage of the procedure consisted in performing an open repair of the MAA, with interposition of a cryopreserved arterial allograft. This was done in 2 patients who presented with abdominal pain and a pulsatile mass on physical examination, with a CT angiogram that showed a contained ruptured aortic aneurysm in both cases. An aorto-aortic bypass graft using a cryopreserved arterial allograft was performed in both cases (**Figure 5**).



**Figure 4.** Patient 3. CT scan revealing a juxtarenal MAA with gas within the aneurysmal sac (B), measuring 9 cm in diameter (A). Magnetic resonance imaging (MRI) showing vertebral osteomyelitis (spondylodiscitis) in a sagittal plane, with bone erosion (red arrow) at the level of vertebral bodies L3-L4 (C).



**Figure 5.** Intraoperative images showing the surgical preparation of the arterial aortic cryopreserved allografts (A and B).



In the second stage, an endoprosthesis (Zenith<sup>®</sup> stent graft, Cook Medical Inc., Bloomington, Indiana, USA) was implanted just below the renal arteries, in the infrarenal aorta, 1 month after the procedure in the first patient. In the second case, an aortic endoprosthesis (Zenith Flex<sup>®</sup> stent graft, Cook Medical Inc., Bloomington, Indiana, USA) was deployed in the infrarenal aorta, sealing the inside of the cryopreserved allograft, 6 months after the initial procedure.

We believe that this alternative option might decrease the risk of rupture of the cryopreserved allograft anastomosis, which is a devastating complication of open repair of MAAs [23, 41].

## 12. Discussion

Treatment of aortic infection is still one of the most challenging situations for a vascular surgeon to confront.

Open extra-anatomic bypass revascularization combined with extensive debridement of all infected aortic and peri-aortic tissues, with excision of the infected aorta and oversewing of the non-infected aortic stump has been considered the standard treatment for aortic infection [22, 26, 31].

Open surgical options include the use of antibiotic-soaked Dacron grafts, cryopreserved aortic allografts, and biological bovine pericardial materials. The use of the superficial femoral vein (SFV) and femoral or popliteal vein segments have also been used as an alternative to in situ reconstructions in aortic infections [26, 32]. Revascularizations using vein grafts have the advantage of a potential lower risk of infection/reinfection. SFV as an autologous material has shown excellent performance in terms of long-term infectious complications. The main disadvantage is that vein harvesting is time-consuming. Another possible disadvantage of using the SFV is its diameter discrepancy with the aorta, and the possible limitation of vein length. These vein reconstructions are also functional and durable on follow-up over time [47–49].

Some groups have presented lower rates of recurrent infection and lower morbidity and mortality rates associated with rifampicin-soaked Dacron grafts compared to those with untreated grafts [35, 45].

Cryopreserved arterial allografts have the advantage of a higher resistance to infection, with low rates of reinfection. Techniques in cryopreservation have improved in the last decade, possibly contributing to better outcomes of revascularization using these allografts [35, 41, 50].

MAAs of the ascending aorta and aortic arch, without a past medical history of previous cardiac or cardiovascular surgery, are very rare. Macedo et al. reported an incidence of 2.6% of MAAs of the ascending aorta after a review of their more than 25-year experience with aortic mycotic aneurysms [51]. Descriptions of mycotic ascending aortic aneurysms or pseudoaneurysms in the literature are very scarce. MAAs of the thoracoabdominal aorta are also less common than those of the infrarenal aorta. Previous series have presented an incidence of primary infection of the thoracic and thoracoabdominal aorta affecting 0.7–4.5% of aortic aneurysms altogether [35]. Mycotic saccular, fusiform, and pseudoaneurysms of the ascending and descending thoracic aorta have been described in the literature. Repair of these aneurysms may be performed with different techniques, including cryopreserved arterial homografts, prosthetic antibiotic-soaked grafts, visceral debranching and endovascular stent-graft repairs, bovine pericardium patch grafts, and Dacron grafts with biological tissue coverage [35, 45, 52].

The largest series of mycotic aortic aneurysms was presented by Heinola et al. in 2018. This international multicenter study included 187 patients. In their series, 51

patients (27%) were treated with open prosthetic repair, 56 (30%) with a biological material, and 80 were treated with EVAR (43%). Overall, open repairs were performed in 107 patients (57%) in this group, making this the largest series up to date on open aortic repair of MAAs [32]. In their analysis, blood and/or tissue culture were positive in 43 (77%) cases, 33 (59%) were positive for non-*Salmonella* infection, and 10 (18%) were positive for *Salmonella* species. The most common registered bacterium on cultures was *Staphylococcus aureus* (27%). It presented a thirty-day survival of 95% (n = 53) and 90-day survival of 91% (n = 51). The overall treatment-related mortality was 9% (n = 5) [32].

The second largest study to date of open surgical treatment of mycotic aortic aneurysms (MAAs) was published in 2014 by Lin et al., including a group of 77 patients. In this study group, the in-hospital mortality rate was 10% (8/77) for patients who underwent open repair and 25% (2/8) for patients who underwent EVAR [27].

The first report of endovascular aneurysm repair of a MAA was reported in 1998 by Semba et al. They reported no postoperative complications from persistent bacteraemia after a 24-month follow up, without postoperative mortality [53]. Since then, there have been various case reports and series of cases describing EVAR and TEVAR for the treatment of ruptured aortic aneurysms and MAAs and their outcomes [23, 30, 34, 38, 39, 53]. These series report favorable results for EVAR/TEVAR for MAAs, providing a less invasive procedure with low early mortality rates [23, 30, 33, 34, 39, 53].

Kan et al. performed a systematic review of outcome after EVAR for the treatment of mycotic aortic aneurysms in 2007. They presented a life-time analysis, which reported a 30-day survival rate of 89%  $\pm$  4% and a 2-year survival rate of 82%  $\pm$  5.8%. They performed a multivariate logistic regression analysis, which showed that only ruptured aneurysms and fever were significant predictors of persistent infection in EVAR after MAAs [38].

The largest series to date on endovascular treatment of MAAs was reported in 2018 by Heinola et al. This multicenter-group reported 187 MAAs treated in 6 different European countries between 2006 and 2016 [32]. Another previous large series on endovascular treatment of MAAs was reported in 2012 by Sedivy et al. This series included 32 patients, treated during a 15-year period. In this series, 81% of patients survived the 30-day postoperative period. A total of 50% survived after 1-year follow-up and 40% survived after a 3-year follow-up [50]. **Table 3** includes the most important series regarding MAAs (**Table 3**) [22–32, 35, 38–41, 54].

Although some of these modern series present promising results, with lower 30-day mortality for endovascular treatments compared to open surgery, the risk of persistent infection and late complications might be higher. Some concerns are present in modern literature regarding endovascular repair, as there are still no long-term follow-up of these series and there is still an ongoing controversy and debate regarding placing a stent-graft in a tissue (aorta) that is still infected.

For some complex thoracoabdominal aortic aneurysms (TAAAs), therapeutic options may be scarce. In those cases of symptomatic mycotic TAAAs, there may not be enough time to create fenestrated/branched custom-made endovascular stent-grafts. In order to avoid the high morbidity and mortality rates associated with total open surgical repair of these mycotic TAAAs, some groups have advocated for the performance of a hybrid aortic repair.

This hybrid repair of type I, II, and III TAAAs consists in performing a visceral artery debranching with retrograde revascularization, followed by the implantations of a thoracoabdominal endovascular stent-graft [42, 55, 56].

Contrary to what happens in the infrarenal abdominal aorta, extra-anatomic bypasses are very exceptionally used to repair primary MAAs of the thoracic and

Series	Year	Number patients	Technique	Mortality (30-day)
Moneta	1998	17	Open	23%
Soravia-Dunand	1999	10	Open	57%
Oderich	2001	43	Open	21%
Müller	2001	33	Open	36%
Fillmore	2003	10	Open	40%
Kyriakides	2004	15	Open	26%
Dubois	2010	44	Open	18.2%
Kan	2010	41	Open (n = 21)	4.8%
			EVAR (n = 20)	5%
Yu	2011	53	Open	23%
Weis-Müller	2011	36	Open	33%
Uchida	2012	23	Open	5%
Sedivy	2012	32	EVAR-TEVAR	18.8%
Huang	2014	43	Open (n = 29)	20%
			EVAR (n = 11)	9%
Lin	2014	109	Open (n = 77)	10%
			EVAR (n = 8)	25%
Söreljus	2014	123	EVAR-TEVAR	9%
Touma	2014	16	Open-Allograft	28%
Söreljus	2016	132	Open (n = 62)	26%
			EVAR (n = 70)	14%
Luo	2017	40	EVAR-TEVAR	10%
Corvera	2018	17	Open-Allograft	6%
Heinola	2018	187	Open (n = 51)	5%
			EVAR (n = 80)	
			Allograft (n = 56)	

*Open, open surgical repair; EVAR, endovascular aneurysm repair; TEVAR, thoracic endovascular aneurysm repair.*

**Table 3.**  
*Largest modern series of mycotic aortic aneurysms (MAAs).*

thoracoabdominal aorta, or graft infections on those sites. Patients with mycotic aneurysms of the ascending aorta or arch may present with different signs and symptoms, including persistent fever, fatigue, chest or back pain, dyspnea, pleural effusion, and hypovolemic shock in cases of mycotic aortic rupture [57].

MAAs have also reported following heart transplantation and different cardiac surgical procedures. Bacterial, viral, fungal, and protozoal infections have been described after cardiac transplantation, understanding that these patients under immunosuppressive medication are at risk of mycotic aneurysm formation [58]. In cases of ascending, arch, or descending thoracic mycotic aneurysms associated with severe mediastinitis, surgical techniques for aortic repair include cryopreserved arterial homografts, repair with deep or superficial femoral veins, coverage with the use of the greater omentum, creation of pedicled muscular flaps for arterial cover-age, tissue debridement, and sternal re-closure [45, 57, 58].

We described in this chapter 2 cases of a novel hybrid repair of MAAs, includ-ing a staged hybrid procedure, with a first stage including resection of the infected

aneurysm and repair with an aortic cryopreserved arterial allograft, followed by a second procedure (once inflammatory markers have decreased and radiologic features have normalized) consisting of an aortic stent-graft. We believe that this option might minimize the risk of cryopreserved allograft rupture that has been previously described in the literature in cases of MAAs. Although there are no reports describing this technique, we consider that this might be a feasible alternative to prevent the risk of aortic rupture.

Long-term surveillance, including physical examination, laboratory assessment of inflammatory markers, and imaging studies (incorporating CT angiogram and FDG-PET or PET-CT) are critical for evaluation of possible complications and prompt decision in case of reinfections.

### **13. Conclusions**


Treatment of mycotic aortic aneurysms (MAAs) remains a real challenge in modern vascular surgery. There are currently different treatment options, with an immense improvement in endovascular techniques and devices. Despite the fact of technological and endovascular improvements, this complex pathology is still associated with high morbidity and mortality rates. An early diagnosis and interventional procedure (open, hybrid, or endovascular repair) and aggressive antibiotic therapy are essential to improve outcomes.

### **Author details**

Lucas Ribé Bernal\*, Lucía Requejo, Aida Ribes and Manuel Miralles  
University Hospital Le Fe, Valencia, Spain

\*Address all correspondence to: [lucasribemd@gmail.com](mailto:lucasribemd@gmail.com)

### **IntechOpen**

© 2019 The Author(s). Licensee IntechOpen. This chapter is distributed under the terms of the Creative Commons Attribution License (<http://creativecommons.org/licenses/by/3.0>), which permits unrestricted use, distribution, and reproduction in any medium, provided the original work is properly cited. 



## References

- [1] Corvisart JN. Essai sur les Maladies et les Lesions Organique du Coeur et des Gros Vaisseaux (An Essay on the Organic Diseases and Lesions of the Heart and Great Vessels. Translated by J. Gates. Boston: Bradford and the Read; 1812). Paris: Mequigon-Marvis; 1806
- [2] Hodgson J. A Treatise on the Diseases or Arteries and Veins. London: T. Underwood; 1815
- [3] Kirkes WS. On some of the principal effects resulting from the detachment of fibrinous deposits from the interior the heart, and their mixture with the circulating blood. *Medico-Chirurgical Transactions*. 1852;**35**:281-324
- [4] Libman E. A study of the endocardial lesions of subacute bacterial endocarditis. *The American Journal of the Medical Sciences*. 1912;**144**:313-327
- [5] Ellis H. Edwin Klebs: Discoverer of the bacillus of diphtheria. *British Journal of Hospital Medicine*. 2013;**74**(11):641
- [6] Osler W. The Gulstonian lectures on malignant endocarditis. *British Medical Journal*. 1885;**1**:467-470
- [7] Rodis E, Yakirevich V, Almog C, Michaeli D, Vidne BA. Complicated infective endocarditis: Surgical treatment. *The Journal of Cardio-vascular Surgery*. 1985;**26**(1):64-66
- [8] Osler W. On Some Points in the Etiology and Pathology of Ulcerative Endocarditis. Vol. 1. J.W. Kolckmann; 1881. pp. 341-346
- [9] Stengel A, Wolferth CC. Mycotic (bacterial) aneurysms of intravascular origin. *Archives of Internal Medicine*. 1923;**31**:537-554
- [10] Jarrett F, Darling RC, Mundth ED, Austen WG. Experience with infected aneurysms of the abdominal aorta. *Archives of Surgery*. 1975;**110**(11):1281-1286
- [11] Blum L, Keefer EB. Cryptogenic mycotic aneurysm. *Annals of Surgery*. 1962;**155**:398-405
- [12] Crane A. Primary multilocal mycotic aneurysm of the aorta. *Archives of Pathology*. 1937;**24**:634-641
- [13] Benett DE. Primary mycotic aneurysms of the aorta. Report of case and review of the literature. *Archives of Surgery*. 1967;**94**(6):758-765
- [14] Wilson SE, Van Wagenen P, Passaro E. Arterial infection. *Current Problems in Surgery*. 1978;**15**(9):1-89
- [15] Mazzalai F, Ragazzi R, Iurilli V, Toniato A, Da Giau G, Ballotta E. *Pseudomonas aeruginosa*-infected infrarenal abdominal aorta pseudoaneurysm secondary to laparoscopic colorectal surgery: Failure of endovascular stent graft treatment after primary open repair failed. *Canadian Journal of Surgery*. 2009;**52**(5):E193-E194
- [16] Woo SB, Cheng LC, Wong WC. Mycotic aortic aneurysm following treatment of pyogenic vertebral osteomyelitis. *Asian Cardiovascular & Thoracic Annals*. 2006;**14**(5):e102-e105
- [17] Baddour LM, Wilson W, Bayer A, Fowler V, Tleyjeh I, Rybak MJ, et al. Infective endocarditis in adults: Diagnosis, antimicrobial therapy, and management of complications: A scientific statement for healthcare professionals from the American Heart Association. *Circulation*. 2015;**132**(15):1435-1486
- [18] Stevenson RP, Semple C, Hussey K, McGovern J, Stuart WP, Kingsmore DB. Changes in the demographics of intravenous drug users with



mycotic common femoral artery pseudoaneurysm as a consequence of self-injection does not influence outcome following emergency ligation. *Vascular*. 2017;**25**(5):520-524

[19] González I, Sarriá C, López J, Vilacosta I, San Román A, Olmos C, et al. Symptomatic peripheral mycotic aneurysms due to infective endocarditis: A contemporary profile. *Medicine*. 2014;**93**(1):42-52

[20] Lee WK, Mossop PJ, Little AF, Fitt GJ, Vrazas JI, Hoang JK, et al. Infected (mycotic) aneurysms: Spectrum of imaging appearances and management. *Radiographics*. 2008;**28**(7):1853-1868

[21] Brown SL, Busuttil RW, Baker JD, Machleder HI, Moore WS, Barker WF. Bacteriologic and surgical determinants of survival in patients with mycotic aneurysms. *Journal of Vascular Surgery*. 1984;**1**(4):541-547

[22] Weis-Müller BT, Rascanu C, Sagban A, Grabitz K, Godehardt E, Sandmann W. Single-center experience with open surgical treatment of 36 infected aneurysms of the thoracic, thoracoabdominal, and abdominal aorta. *Annals of Vascular Surgery*. 2011;**25**(8):1020-1025

[23] Sörelíus K, Mani K, Björck M, Sedivy P, Wahlgren CM, Taylor P, et al. Endovascular treatment of mycotic aortic aneurysms: A European multicenter study. *Circulation*. 2014;**130**(24):2136-2142

[24] Müller BT, Wegener O, Grabitz K, Pillny M, Thomas L, Sandmann W. Mycotic aneurysms of the thoracic and abdominal aorta and iliac arteries: Experience with anatomic and extra-anatomic repair in 33 cases. *Journal of Vascular Surgery*. 2001;**33**:106-113

[25] Moneta GL, Taylor LM Jr, Yeager RA, Edwards JM, Nicoloff AD, McConnell DB, et al. Surgical treatment

of infected aortic aneurysm. *American Journal of Surgery*. 1998;**175**(5):396-399

[26] Dubois M, Daenens K, Houthoofd S, Peetermans WE, Fourneau I. Treatment of mycotic aneurysms with involvement of the abdominal aorta: Single-centre experience in 44 consecutive cases. *European Journal of Vascular and Endovascular Surgery*. 2010;**40**(4):450-456

[27] Lin CH, Hsu RB. Primary infected aortic aneurysm: Clinical presentation, pathogen, and outcome. *Acta Cardiologica Sinica*. 2014;**30**(6):514-521

[28] Yu SY, Hsieh HC, Ko PJ, Huang YK, Chu JJ, Lee CH. Surgical outcome for mycotic aortic and iliac aneurysm. *World Journal of Surgery*. 2011;**35**(7):1671-1678

[29] Hsu RB, Chang CI, Wu IH, Lin FY. Selective medical treatment of infected aneurysms of the aorta in high risk patients. *Journal of Vascular Surgery*. 2009;**49**(1):66-70

[30] Huang YK, Chen CL, Lu MS, Tsai FC, Lin PL, Wu CH, et al. Clinical, microbiologic, and outcome analysis of mycotic aortic aneurysm: The role of endovascular repair. *Surgical Infections*. 2014;**15**(3):290-298

[31] Oderich GS, Panneton JM, Bower TC, Cherry KJ Jr, Rowland CM, Noel AA, et al. Infected aortic aneurysms: Aggressive presentation, complicated early outcome, but durable results. *Journal of Vascular Surgery*. 2001;**34**(5):900-908

[32] Heinola I, Sörelíus K, Wyss TR, Eldrup N, Settembre N, Setacci C, et al. Open repair of mycotic abdominal aortic aneurysms with biological grafts: An international Multicenter study. *Journal of the American Heart Association*. 2018;**7**(12):1-9

- [33] Ribé L, Río J, Portero JL, Reparaz L. Late survival after endovascular repair of an *Aortobronchial fistula*. *EJVES Extra*. 2010;**19**(2):e22-e24
- [34] Stone WM, Fankhauser GT, Bower TC, Oderich GS, Oldenburg WA, Kalra M, et al. Comparison of open and endovascular repair of inflammatory aortic aneurysms. *Journal of Vascular Surgery*. 2012;**56**(4):951-955
- [35] Corvera JS, Blitzer D, Copeland H, Murphy D, Hess PJ Jr, Pillai ST, et al. Repair of thoracic and thoracoabdominal mycotic aneurysms and infected aortic grafts using allograft. *The Annals of Thoracic Surgery*. 2018;**106**(4):1129-1135
- [36] Soussan M, Nicolas P, Schramm C, Katsahian S, Pop G, Fain O, et al. Management of large-vessel vasculitis with FDG-PET: A systematic literature review and meta-analysis. *Medicine*. 2015;**94**(14):e622
- [37] Murakami M, Morikage N, Samura M, Yamashita O, Suehiro K, Hamano K. Fluorine-18-fluorodeoxyglucose positron emission tomography-computed tomography for diagnosis of infected aortic aneurysms. *Annals of Vascular Surgery*. 2014;**28**(3):575-578
- [38] Kan CD, Lee HL, Luo CY, Yang YJ. The efficacy of aortic stent grafts in the management of mycotic abdominal aortic aneurysm-institute case management with systemic literature comparison. *Annals of Vascular Surgery*. 2010;**24**(4):433-440
- [39] Sörelíus K, Wanhainen A, Furebring M, Björck M, Gillgren P, Mani K. Nationwide study of the treatment of mycotic abdominal aortic aneurysms comparing open and endovascular repair. *Circulation*. 2016;**134**(23):1822-1832
- [40] Kyriakides C, Kan Y, Kerle M, Cheshire NJ, Mansfield AO, Wolfe JH. 11-year experience with anatomical and extra-anatomical repair of mycotic aortic aneurysms. *European Journal of Vascular and Endovascular Surgery*. 2004;**27**(6):585-589
- [41] Touma J, Cochenne F, Parisot J, Fialaire Legendre A, Becquemin JP, Desgranges P. In situ reconstruction in native and prosthetic aortic infections using cryopreserved arterial allografts. *European Journal of Vascular and Endovascular Surgery*. 2014;**48**(3):292-299
- [42] Ribé L, Gibbs RG, Jenkins M, Wolfe JHN. Visceral and arch hybrid aortic repair for thoracoabdominal aneurysms. In: Greenhalgh RM, editor. *Vascular and Endovascular Challenges Update*. London, UK: Biba Medical; 2013. pp. 127-136. ISBN: 978-0-9570419-1-2
- [43] Bernal LR, Portero JL, Vila M, Ruiz DF, Reparaz LM. Hemoptysis caused by a left subclavian pseudoaneurysm: Endovascular solution for a challenging case. *Vascular*. 2013;**21**(3):159-162
- [44] Pryluck DS, Kovacs S, Maldonado TS, Jacobowitz GR, Adelman MA, Charles HC, et al. Percutaneous drainage of aortic aneurysm sac abscesses following endovascular aneurysm repair. *Vascular and Endovascular Surgery*. 2010;**44**(8):701-707
- [45] Gebhard C, Biaggi P, Sthli BE, Schwarz U, Felix C, Falk V. Complete graft dehiscence 8 months after repair of acute type A aortic dissection. *European Heart Journal Acute Cardiovascular Care*. 2013;**2**(1):72-76
- [46] Frautschi RS, Bassiri Gharb B, Duong MM, Gurunluoglu R, Papay F, Zins JE, et al. The cardioplastic approach to the treatment of infected aortic grafts. *Annals of Plastic Surgery*. 2017;**79**(2):221-225

- [47] Chervu A, Moore WS, Gelabert HA, Colburn MD, Chvapil M. Prevention of graft infection by use of prosthesis bonded with rifampin/collagen release system. *Journal of Vascular Surgery*. 1991;**14**:521-525
- [48] Daenens K, Fourneau I, Nevelsteen A. Ten-year experience in autogenous reconstruction with the femoral vein in the treatment of aortofemoral prosthetic infection. *European Journal of Vascular and Endovascular Surgery*. 2003;**25**:240-245
- [49] Czerny M, von Allmen R, Opfermann P, et al. Seft-made pericardial tube graft; a new surgical concept for treatment of graft infections after thoracic and abdominal aortic procedures. *The Annals of Thoracic Surgery*. 2011;**92**:1657-1662
- [50] Ben Ahmed S, Louvancourt A, Daniel G, Combe P, Duprey A, Albertini JN, et al. Cryopreserved arterial allografts for in situ reconstruction of abdominal aortic native or secondary graft infection. *Journal of Vascular Surgery*. 2018;**67**(2):468-477
- [51] Macedo TA, Stanson AW, Oderich GS, Johnson CM, Panneton JM, Tie ML. Infected aortic aneurysms: Imaging findings. *Radiology*. 2004;**231**:250-257
- [52] Mukherjee JT, Nautiyal A, Labib SB. Mycotic aneurysms of the ascending aorta in the absence of endocarditis. *Texas Heart Institute Journal*. 2012;**39**(5):692-695
- [53] Semba CP, Sakai T, Slonim SM, Razavi MK, Kee ST, Jorgensen MJ, et al. Mycotic aneurysms of the thoracic aorta: Repair with use of endovascular stent-grafts. *Journal of Vascular and Interventional Radiology*. 1998;**9** (1 Pt 1):33-40
- [54] Sedivy P, Spacek M, El Samman K, Belohlavek O, Mach T, Jindrak V, et al. Endovascular treatment of infected aortic aneurysms. *European Journal of Vascular and Endovascular Surgery*. 2012;**44**(4):385-394
- [55] Antoniou GA, El Sakka K, Hamady M, Wolfe JH. Hybrid treatment of complex aortic arch disease with supra-aortic debranching and endovascular stent graft repair. *European Journal of Vascular and Endovascular Surgery*. 2010;**39**(6):683-690
- [56] Jaffer U, Gibbs R. Mycotic thoracoabdominal aneurysms. *Annals of Cardiothoracic Surgery*. 2012;**1**(3):417-425
- [57] Masuda S, Takeuchi N, Takada M, Fujita K, Nishibori Y, Maruyama T. Ruptured thoracic aortic aneurysm infected with *listeria monocytogenes*: A case report and a review of literature. *Open Journal of Cardiovascular Surgery*. 2013;**6**:1-7
- [58] Anthuber M, Kemkes BM, Kreuzer E, Gokel M, Schuetz A, Kugler C, et al. Mediastinitis and mycotic aneurysm of the aorta after orthotopic heart transplantation. *Texas Heart Institute Journal*. 1991;**18**(3):186-193