

We are IntechOpen, the world's leading publisher of Open Access books Built by scientists, for scientists

6,900

Open access books available

186,000

International authors and editors

200M

Downloads

Our authors are among the

154

Countries delivered to

TOP 1%

most cited scientists

12.2%

Contributors from top 500 universities



WEB OF SCIENCE™

Selection of our books indexed in the Book Citation Index
in Web of Science™ Core Collection (BKCI)

Interested in publishing with us?
Contact book.department@intechopen.com

Numbers displayed above are based on latest data collected.
For more information visit www.intechopen.com



Clinical Presentation of Myasthenia Gravis

*Jianu Catalin, Jianu Silviana
and Barsan Claudia*

Abstract

Despite advances in applied sciences, myasthenia gravis (MG) remains a challenging disorder to diagnose and treat. The clinical presentation results in either transient or persistent painless weakness and abnormal fatigability of any (ocular, bulbar, limbs, trunk, respiratory) or all voluntary (skeletal) muscles; however, it is usually not to the same extent. Several scoring systems of MG signs or the global state of the patient have been proposed in an attempt to provide a standard scheme for use by all investigators. Some patients may have non-muscle-related complaints due to different disorders which may be associated with MG (thymoma, thyroid disorders, other autoimmune diseases, etc.).

Keywords: myasthenia gravis, transient or persistent weakness, skeletal muscles, thymoma

1. Myasthenia gravis: overview

Myasthenia gravis (MG) is a neuromuscular autoimmune disease characterized by the production of autoantibodies directed against molecules involved in neuromuscular transmission (NMT): the $\alpha 1$ subunit of the nicotinic postsynaptic acetylcholine receptors (AChR) and muscle-specific tyrosine kinase (MuSK) [1–3].

MG occurs more frequently in women than men; the age of onset in women is in their second and third decade of life, while in men, it is in the fourth [1, 4]. Moreover, there is a second peak of incidence in the sixth and seventh decades, with men being more affected. Epidemiologically, it was found that men tend to experience more severe symptoms [4, 5].

Clinically, MG is defined by a painless, fluctuant muscle weakness that progressively increases with repetitive muscle action but decreases with rest [1–3]. The degree of weakness is dependent on the exertion of the skeletal muscle group involved, but in some cases, it may change over longer periods without any evident cause [6].

Even though all types of voluntary muscle can be involved during the disease course, MG characteristically begins with a few isolated signs and spreads to other muscles within a variable period of time (weeks, months, or even years) [6].

In about 15–20% of the patients, myasthenic symptoms remain confined to the ocular muscles; however, with disease progression and usually within 2 years, the rest of them develop bulbar symptoms (i.e., dysphagia, dysarthria) and facial, axial, and limb weakness [1, 2, 6, 7].

The maximum severity of MG manifestations is usually reported during the first year in two-thirds of patients [1]. Additionally, it has become evident that, in general, the illness tends to stabilize, improve (57%), or even resolve (13%) after several years [3, 6].

It is important to emphasize that in MG, symptoms may worsen in certain conditions including stress, systemic illness (especially upper respiratory infections), hypo-/hyperthyroidism, pregnancy, menstrual cycle, exposure to heat, operative procedures, drugs affecting NMT, and fever [1, 5, 8]. However, in the majority of cases, no precipitating factor can be found [3, 5]. A severe exacerbation requiring endotracheal intubation with mechanical ventilation is defined as myasthenic crisis (Class V myasthenia by MG Foundation of America) [5].

The treatment used in MG includes symptomatic treatment (acetylcholinesterase inhibitors), rapid short-term immunomodulating therapies (plasmapheresis and intravenous immunoglobulin), chronic long-term immunomodulating treatment (glucocorticoids and/or other immunosuppressive agents), and, in selected patients, surgical treatment (thymectomy). In all cases, MG management should be individualized according to patient characteristics and the severity of the disease [3].

Currently, the mortality of MG is extremely low, considering that only among the 19% of the patients with severe generalized MG also need endotracheal intubation; the mortality can reach 8% despite ventilation [5, 6, 9].

2. Clinical features

The cardinal features of the initial course of MG are the transient or persistent weakness and abnormal fatigability of skeletal muscles that are typically least severe in the morning and after rest and worst as the day progresses and after repetitive activities [1, 3, 5] (**Table 1**).

The weakness, which is mostly asymmetrical, specifically affects the extraocular, bulbar, and proximal limb or truncal musculature and, in more rare cases, the respiratory muscles [3–5].

In about two-thirds of the patients with MG, the presenting symptoms are unilateral or asymmetrical ptosis and/or diplopia due to the involvement of extrinsic ocular muscles [2–4].

Over 15% of patients show (as an initial MG symptom) bulbar weakness, leading to slurred or nasal speech, voice alterations, or difficulty in chewing or swallowing; neck and extremity weaknesses are flagged as complaints in about 5% of patients [2, 5, 7, 10].

Importantly, careful questioning frequently reveals evidence of earlier subtle myasthenic manifestations, such as repeated purchases of eyeglasses to correct blurred vision or avoidance of foods that became difficult to chew or swallow. Also, family members may observe a changed, sleepy or sad, facial appearance caused by ptosis or facial weakness [1].

It has to be mentioned that, in MG, cognition, coordination, and tendon reflexes are normal. Also, local muscle atrophy is rarely seen in myasthenic patients, being reported especially in MuSK-antibody MG patients [1, 2, 5, 6].

2.1 Ocular symptoms

Ocular symptoms are the most frequent manifestations of MG, ultimately being present in 90% of patients [6]. The major ocular symptoms associated with MG are

Level	Symptoms	Early onset <40 years	Late onset >40 years	Thymoma
Ocular muscles	• Diplopia	++	++	+/-
	• Ptosis	++	+	+/-
Bulbar muscles	• Articulation	++	+/-	+/-
	• Face	+	+/-	+/-
	• Chewing	+/-	+/-	+/-
	• Swallowing	+/-	+/-	+/-
	• Neck			
Limbs muscles	• -Arms	+	+/-	+/-
	• -Hands and fingers	+	+/-	+/-
	• -Legs	++	+/-	+/-
Generalized	+/-	+/-	+/-	+
Respiration	+/-	+/-	+/-	+/-

Table 1.
Clinical manifestations of myasthenia gravis.

fluctuating ptosis (often with compensatory wrinkling of the forehead), diplopia, and, in milder cases, blurry vision [3, 5]. These manifestations may be intermittent in the early stages, typically becoming worse in the evening, while reading or driving, and especially in bright sunlight [1].

In MG a certain degree of photophobia is seen, commonly worsening the ptosis and/or diplopia; as a consequence, some patients often choose to wear dark sunglasses [1, 3].

Weakness involving one or more ocular muscles is, by definition, asymmetric, fluctuating, and fatigable [1]. The most frequently affected extraocular muscle is the medial rectus [3]. Furthermore, in MG, the pattern of weakness cannot be correlated with lesions of one or more nerves, and the pupillary responses are normal [1].

Asymmetric ptosis of the alternating sides over time is considered pathognomonic of MG. In some cases, ptosis can be severe enough to totally occlude vision if it is bilateral [1, 3].

Weakness of the orbicularis oculi muscles, frequently seen in MG patients, leads to incomplete closure of the eyelids, which produces discomfort by allowing soap or water in the eyes during bathing [1, 5]. It should also be mentioned that the weakness of lateral and medial recti can determine a pseudo-internuclear ophthalmoplegia with limited adduction of one eye and nystagmus of the abducting contralateral eye [5].

2.2 Bulbar symptoms

In about 15% of patients [11] with MG, bulbar symptoms, generally manifested as oropharyngeal muscle weakness, are evident from the beginning [12]; during the course of the disease, bulbar muscle involvement can be found in 60% of patients [3]. The characteristic bulbar symptoms seen in MG include fatigable chewing (particularly solid food) and swallowing (particularly liquids), dysarthria, and inadequate maintenance of the upper airway. Typically, the time needed for eating a meal increases, and conversation becomes difficult, especially while eating [1, 3, 6].

Dysarthria: Speech difficulties manifesting as dysarthria and nasality are commonly seen in MG. Initially, dysarthria is an isolated and fluctuating symptom that occurs mostly under the influence of emotions, worsens with prolonged talking, and disappears after a “silent period” [6]. Weakness of laryngeal muscles causes hoarseness; the voice may become weaker in volume, but MG does not determine aphonia [1, 6]. Orbicularis oris weakness is usually observed as the patient becomes unable to whistle, to kiss, and to blow up a balloon or by difficulty in pronouncing certain letters (p, f, s). Importantly, vocal cord paralysis, leading to stridor, or “crowing” during attempted deep inspirations, may be a sign of severe respiratory distress requiring endotracheal intubation [5, 6].

Dysphagia in MG is caused by weakness of the lips, the tongue, the masseter, and the pharyngeal muscles or sometimes a combination of these [6]. Dysphagia found in MG patients is typically associated with several characteristic signs as follows: difficulty chewing caused by incomplete jaw closure resulting from masseter and temporalis muscle weakness; difficulty swallowing exposing the patient to a high risk of aspiration, leading to coughing or choking especially while drinking; nasal regurgitation of liquids due to palatal muscle weakness; sensation that food is sticking in the throat as a consequence of upper pharyngeal muscle weakness; and weight loss—which can be correlated with the severity of eating difficulties. It is important to emphasize that dysphagia can precipitate a myasthenic crisis in patients with MG [1, 5, 6].

2.3 Facial appearance

Myasthenic patients usually have a facial appearance that gives the impression of a sleepy, expressionless, or sad person. This particular appearance is caused mostly by ptosis and facial weakness. Classical features found in MG are also the “myasthenic snarl” and the “rire vertical.” These signs occur as attempting to smile produce contraction of the medial part of the upper lip and a horizontal contraction of the corners of the mouth with loss of the natural upward curling and thus, gives the patient’s smile the appearance of a sneer. The weakness of the facial muscles usually occurs insidiously and can be asymmetric. Sometimes, a chronic contracted frontalis muscle may give a worried or surprised look to the patient. If weakness is severe, the jaw will tend to hang open and determine the patient to actively hold the mouth closed by sitting with a hand on the chin for support (studious or attentive appearance) [1, 6].

2.4 Limb, trunk, and respiratory weakness

Any trunk or limb muscle may be involved, but some are more often affected than are others; thus, neck flexors are weaker than neck extensors, and the deltoids, triceps, and extensors of the wrist and fingers and ankle dorsiflexors are usually more affected than other limb muscles. MG limb weakness is mostly proximal and often asymmetric [1, 5]. In MG the arms are typically more affected than the legs; also, in the upper extremities, the extensors are often involved before the flexors, while in the lower extremities, the reverse usually occurs [3, 5].

The main complains of the patients with MG which present weakness of the limbs or trunk muscles include fatigability, unexplained feelings of heaviness, inability to maintain arms at a higher position for a long period of time (i.e., when hanging laundry or washing hair), and difficulty in going up and down the stairs [6].

In some cases, severe weakness of neck extensor muscles leads to difficulty in balancing the head sometimes producing a “dropped head syndrome.” Pain in the

back and girdle muscles is frequently reported as a natural consequence of the insufficiency of the postural muscles; however, MG is typically not associated with chronic pain [1, 3, 5, 6].

Respiratory muscle weakness is revealed by limited chest wall movement and manifest use of accessory muscles of respiration. An important diaphragmatic weakness leads to orthopnea compromising the respiratory efficiency when the patient lies supine [4]. Respiratory muscle weakness may cause life-threatening myasthenic crisis with acute respiratory failure requiring immediate intubation, mechanical ventilation, and nasogastric tube feeding [3].

Note: MG is more frequently associated with other autoimmune disease than the general population. Among the autoimmune conditions found in MG patients are hyperthyroidism, rheumatoid arthritis, scleroderma, ulcerative colitis, pernicious anemia, Sjogren's syndrome, and sarcoidosis. Also, autonomic neuropathies, inflammatory myopathies, various autoimmune channelopathies, or acquired neuromyotonia (Isaac's syndrome) may be seen in patients with MG especially if associated with thymoma. Importantly, in MG patients with tachycardia or exophthalmos, a possible hyperthyroidism should always be addressed; it has to be mentioned that, in these cases, weakness may persist despite adequate management of MG [6, 13].

3. Physical examination

The physical examination should detect fatigable weakness in specific muscle groups by repetitive or sustained activity and also again after rest [1, 4].

Diplopia can be demonstrated by having the patient look laterally for about 30 seconds, leading to evident eye muscle fatigue [3]. The lid ptosis can improve by applying cold on the affected eye ("ice pack test"). Also, passively lifting a ptotic lid may cause the opposite lid to fall ("enhanced ptosis") [1]. Cogan's lid twitch—a pathognomic sign in MG—is described as the brief twitch seen in an eyelid that is elevated after rest [4, 5].

A useful functional test for dysarthria implies asking the patient to speak aloud without interruption producing nasality and/or hoarseness [6].

To test the limb muscle weakness, the patient should be asked to maintain for 3 minutes a horizontally stretched position of arms, hands, and fingers. In patients with MG, this test will lead to shaking or a gradual drooping of arms, hands, or fingers. Also, patients should be able to do knee bends or rise from a chair repeatedly without any support, 20 times.

Importantly, vital capacity and peak flow measurements should be assessed in all myasthenic patients [6].

4. Clinical classification

Several scoring systems of myasthenic signs or the global state of the patient have been proposed including the Osserman classification, myasthenia gravis composite (MGC) scale, and quantitative myasthenia gravis (QMG) score [6]. However, currently the most widely accepted is the MG Foundation of America (MGFA) Clinical Classification which divides MG into five main classes and several subclasses [3, 5] as follows:

- **Class I:** Any ocular muscle weakness; may have weakness of eye closure. All other muscle strength is normal.

- **Class II:** Mild weakness affecting muscles other than ocular muscles; may also have ocular muscle weakness of any severity.
 - **IIa.** Predominantly affecting the limb, axial muscles, or both. May also have lesser involvement of oropharyngeal muscles.
 - **IIb.** Predominantly affecting the oropharyngeal, respiratory muscles, or both. May also have lesser or equal involvement of the limb, axial muscles, or both.
- **Class III:** Moderate weakness affecting muscles other than ocular muscles; may also have ocular muscle weakness of any severity.
 - **IIIa.** Predominantly affecting the limb, axial muscles, or both. May also have lesser involvement of oropharyngeal muscles.
 - **IIIb.** Predominantly affecting the oropharyngeal and respiratory muscles or both. May also have lesser or equal involvement of the limb, axial muscles, or both.
- **Class IV:** Severe weakness affecting muscles other than ocular muscles; may also have ocular muscle weakness of any severity.
 - **IVa.** Predominantly affecting the limb, axial muscles, or both. May also have lesser involvement of oropharyngeal muscles.
 - **IVb.** Predominantly affecting oropharyngeal, respiratory muscles, or both. May also have lesser or equal involvement of limb, axial muscles, or both.
- **Class V:** Defined as a state requiring intubation, with or without mechanical ventilation, except when employed during routine postoperative management. The use of a feeding tube without intubation places the patient in Class IVb [14].

5. Myasthenia gravis subtypes and specific clinical situations

Ocular MG (OMG). Myasthenic weakness that remains restricted to the ocular muscles for more than 2 years is defined as OMG [15] (**Figure 1**). Although most patients with OMG also present concomitant weakness of the orbicularis oculi muscles, this is not considered as evidence of generalization [5]. Remission may be seen in about 20% of these patients; however, it has to be noted that recurrences are possible even after 20 years [4, 5].

Generalized MG (GMG) can be further subclassified in early-onset (EOMG) and late-onset (LOMG) disease, with the cutoff age usually set at age 40. EOMG patients are more often women, typically presenting anti-AChR antibodies and thymus hyperplasia, while LOMG patients are more frequently male and have MuSK antibodies in addition to anti-AChR antibodies [1].

MuSK-antibody myasthenia gravis (MuSK-MG). MuSK antibodies have been reported in up to 50% of seronegative autoimmune MG cases [16] as well as in OMG [17]. MuSK-MG occurs predominately in women from adolescence through middle age [1, 5]. The anti-MuSK phenotype has a distinct clinical syndrome with prominent weakness in the cranial, bulbar, and respiratory muscles, frequently with moderate to severe atrophy of these clinically affected muscles (especially facial and genioglossus muscles) [1, 4, 5, 18]. Thus, the major complaints of these patients




Figure 1.
Ocular myasthenia gravis.

include dyspnea, nasal speech, and dysphagia leading sometimes to an important weight loss [2]. Some patients also present weakness of the neck extensor. Typically, there is little to no ocular muscle weakness and only a mild involvement of the limb muscles. It is important to mention that, in these patients, the myasthenic symptoms are more severe than in non-MuSK-MG individuals, with more frequent respiratory crises [5]. In MuSK-MG thymic pathology is mostly absent or minimal [19].

Seronegative MG is defined by the absence of both anti-AChR and anti-MuSK antibodies (“double-seronegative MG”). These cases are clinically heterogeneous, but their frequency is particularly low. It has to be noted that some of these patients may have low-affinity anti-AChR antibodies that can only be detected using specialized assays [1].

Thymoma-associated MG. Thymic pathology (thymic lymphofollicular hyperplasia and thymoma) occurs in 80–90% of MG patients and is typically milder in seronegative MG [20]. It was reported that over 10% of patients with MG have a thymoma and, conversely, that 35% of thymoma patients have MG [5]. Thymoma-associated MG, also termed paraneoplastic MG, is a seropositive MG subtype which occurs primarily after the third life decade and is equally frequent in males and females. Patients with this MG subtype have a more severe disease with lower rates of remission and higher mortality (30%) than patients without thymoma [1, 5, 6].

Transient neonatal myasthenia gravis (TNMG) occurs in approximately 15% of infants born to mothers with autoimmune MG, as the anti-AChR antibodies get transferred across the placenta. The most common symptoms are feeble cry, ptosis, facial weakness, difficulty in feeding, respiratory weakness, and, in some cases, cyanosis. Rarely, affected infants present arthrogryposis (joint contracture) causing prolonged immobility in utero. It was found that the symptom severity in the newborn is not related to the severity of symptoms in the mother. These myasthenic manifestations resolve within the first month of life with acetylcholine esterase inhibitors [1, 5].

Juvenile myasthenia gravis (JMG) is defined as the onset of immune-mediated MG before age 18 [21] (**Figure 2**). These patients represent about 15% of the

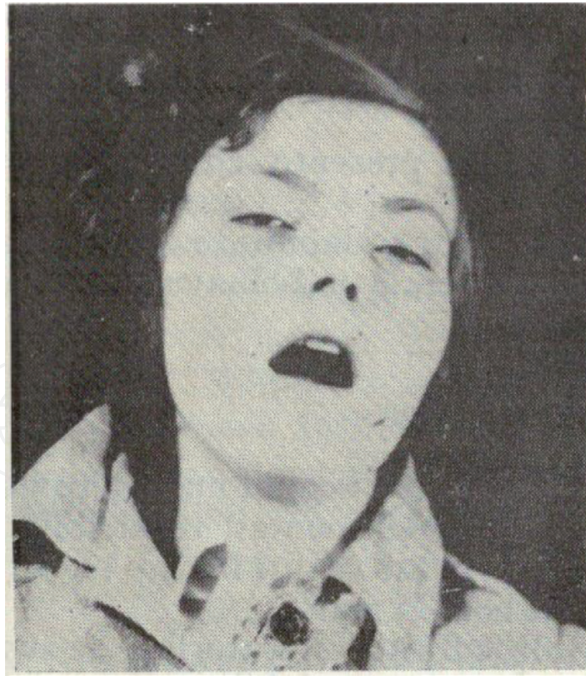

Figure 2.
Myasthenic crisis in juvenile myasthenia gravis.

autoimmune MG cases, being particularly uncommon in the first year of life. JMG is rarely associated with thymomas and has a high rate of spontaneous remission [1].

Congenital myasthenic syndromes (CMS) are caused by genetic (mostly autosomal recessive) abnormalities of the NMT, leading to fluctuating or persistent hypotonia of the ocular, bulbar, or limb muscles; in infancy it may cause arthrogryposis, delayed motor milestones, and unexplained apnea episodes. The weakness usually worsens during adolescence but then often stabilizes; however, prominent myopathy and scoliosis may be present [1, 4].

Lambert-Eaton myasthenic syndrome (LEMS). LEMS is a rare autoimmune disorder resulting from impaired release of ACh by the presynaptic terminal of the NM junction and in the autonomic ganglia. By definition, LEMS is associated with the presence of anti-presynaptic P/Q type voltage-gated calcium channels (VGCC) antibodies. Clinically, LEMS has an insidious onset - usually characterized by muscle tenderness - followed by progressive development of weakness and fatigue [1, 4, 5]. The most frequent symptoms found in LEMS include abnormal fatigue, weakness of the proximal muscles (particularly in the legs), hyporeflexia, and, dysautonomic manifestations (dry mouth, orthostatic hypotension constipation, and impotence). Some patients may present facilitation of strength after brief, isometric contraction and decline of strength after sustained activity. LEMS is classically associated with underlying malignancy or autoimmune disease. It was reported that in about 75% of men and 30% of women, this is a paraneoplastic condition accompanying in most of the cases (80%) a small cell lung cancer. The disease can also occur with other malignancies such as lymphoproliferative disorders, malignant thymoma, and rarely carcinoma of the breast, stomach, colon, prostate, and bladder [4, 5].

Pregnancy. MG may improve, worsen, or remain stable during pregnancy; however, a significant risk of deterioration in the puerperium was reported [1, 4]. Severe respiratory insufficiency can be triggered by the physical stress of labor and delivery; similarly, patients with eclampsia during pregnancy have a higher risk of complications of both conditions, considering, for example, that magnesium sulfate cannot be used in MG patients [5]. It should also be noted that a newborn

from a myasthenic pregnancy has a higher risk to develop TNMG (see above). Currently, women with MG are advised to delay pregnancy until after the disease is stable [1, 4] (Table 2).

Myasthenia gravis subtypes and specific clinical situations	Notes
Ocular MG	<ul style="list-style-type: none">• Weakness restricted to the ocular muscles
Generalized MG	<ul style="list-style-type: none">• Subclassified in early-onset and late-onset MG• Typically associated with anti-AChR antibodies
MuSK-antibody myasthenia gravis	<ul style="list-style-type: none">• Prominent weakness in the cranial, bulbar, and respiratory muscles• Myasthenic symptoms more severe than in non-MuSK-MG patients
Seronegative MG	<ul style="list-style-type: none">• Rare• Clinically heterogeneous
Thymoma-associated MG	<ul style="list-style-type: none">• 80–90% of MG patients also present thymic pathology• Lower rates of remission and higher mortality
Transient neonatal myasthenia gravis	<ul style="list-style-type: none">• May occur in infants born to mothers with autoimmune MG• The myasthenic symptoms resolve within the first month of life with treatment
Juvenile myasthenia gravis	<ul style="list-style-type: none">• The disease onset occurs before age 18• High rate of spontaneous remission
Congenital myasthenic syndromes	<ul style="list-style-type: none">• Caused by genetic (mostly autosomal recessive) abnormalities of the NMT
Lambert-Eaton myasthenic syndrome	<ul style="list-style-type: none">• Associated with anti-presynaptic P/Q type VGCC antibodies• Frequent symptoms: fatigue, weakness of the proximal muscles (particularly in the legs), hyporeflexia, and dysautonomic manifestations• Associated with underlying malignancy or other autoimmune disease
Pregnancy	<ul style="list-style-type: none">• MG may improve, worsen, or remain stable during pregnancy• Women with MG are advised to delay pregnancy until after the disease is stable

Table 2.
Myasthenia gravis subtypes and specific clinical situations—Summarized features.

IntechOpen

Author details

Jianu Catalin^{1,2*}, Jianu Silviana³ and Barsan Claudia²

1 Department of Neurology, “Victor Babes” University of Medicine and Pharmacy, Timisoara, Romania

2 Department of Neurology, Clinical Emergency County Hospital, Timisoara, Romania

3 Department of Ophthalmology, Military Emergency Hospital, Timisoara, Romania

*Address all correspondence to: dcjaniu@yahoo.com

IntechOpen

© 2019 The Author(s). Licensee IntechOpen. This chapter is distributed under the terms of the Creative Commons Attribution License (<http://creativecommons.org/licenses/by/3.0>), which permits unrestricted use, distribution, and reproduction in any medium, provided the original work is properly cited. 

References

- [1] Daroff RB, Jankovic J, Mazziotta JC, Scott L, editors. *Bradley's Neurology in Clinical Practice*. London, New York, Oxford, Philadelphia, St. Louis, Sydney, Toronto: Elsevier; 2016. ISBN: 978-0-323-28783-8. Pomeroy Seventh Edition
- [2] Angelini C, Martignago S, Biscigli M, Albertini E. Myasthenia gravis with anti-MuSK antibodies: Clinical features and histopathological changes. In: Pruitt JA, editor. *A Look into Myasthenia Gravis*. Rijeka: InTech; 2011. ISBN 978-953-307-821-2
- [3] Trouth AJ, Dabi A, Solieman N, Kurukumbi M, Kalyanam J. Myasthenia gravis: A review. *Autoimmune Disease*. 2012;**2012**:874680
- [4] Clarke C, Howard R, Rossor M, Shorvon S, editors. *Neurology: A Queen Square Textbook*. Oxford: Blackwell Publishing Ltd.; 2009. ISBN: 978-1-405-13443-9
- [5] Engel AG, editor. *Myasthenia Gravis and Myasthenic Disorders*. Oxford: Oxford University Press; 2012. ISBN-13: 9780199738670
- [6] Kaminski HJ. *Myasthenia Gravis and Related Disorders*. Totowa, New Jersey: Humana Press Inc; 2003. ISBN 1-58829-058-1
- [7] Scherer K, Bedlack RS, Simel DL. Does this patient have myasthenia gravis? *JAMA*. 2005;**293**(15):1906-1914
- [8] Grob D, Brunner N, Namba T, Pagala M. Lifetime course of myasthenia gravis. *Muscle & Nerve*. 2008;**37**(2):141-149
- [9] Beekman R, Kuks JBM, Oosterhuis HJGH. Myasthenia gravis: Diagnosis and follow-up of 100 consecutive patients. *Journal of the Neurological Sciences*. 1997;**244**:112-118
- [10] Myasthenia Gravis Foundation of America. *Myasthenia Gravis: A Manual for the Health Care Provider*. 2008. Available from: http://www.myasthenia.org/docs/MGFA_ProfessionalManual.pdf
- [11] Grob D. Course and management of myasthenia gravis. *JAMA*. 1953;**153**:529-532
- [12] Koopman WJ, Wiebe S, Colton-Hudson A, Moosa T, Smith D, Bach D, et al. Prediction of aspiration in myasthenia gravis. *Muscle & Nerve*. 2004;**29**(2):256-260
- [13] Romi F, Skeie GO, Gilhus NE. Striational antibodies in myasthenia gravis: Reactivity and possible clinical significance. *Archives of Neurology*. 2005;**62**(3):442-446
- [14] Jaretzki A 3rd, Barohn RJ, Ernstoff RM, Kaminski HJ, Keesey JC, Penn AS, et al. Myasthenia gravis: Recommendations for clinical research standards. Task Force of the Medical Scientific Advisory Board of the Myasthenia Gravis Foundation of America. *The Annals of Thoracic Surgery*. 2000;**70**(1):327-334
- [15] Kupersmith MJ, Latkany R, Homel P. Development of generalized disease at 2 years in patients with ocular myasthenia gravis. *Archives of Neurology*. 2003;**60**:243-248
- [16] Guptill JT, Sanders DB. Update on muscle-specific tyrosine kinase antibody positive myasthenia gravis. *Current Opinion in Neurology*. 2010;**23**(5):530-535
- [17] Bau V, Hanisch F, Hain B, Zierz S. Ocular involvement in MuSK antibody-positive myasthenia gravis. *Klinische Monatsblätter für Augenheilkunde*. 2006;**223**:81-83

[18] Evoli A, Tonali PA, Padua L, Monaco ML, Scuderi F, Batocchi AP, et al. Clinical correlates with anti-MuSK antibodies in generalized seronegative myasthenia gravis. *Brain*. 2003;**126** (Pt 10):2304-2311

[19] Lauriola L, Ranelletti F, Maggiano N, Guerriero M, Punzi C, Marsili F, et al. Thymus changes in anti-MuSK-positive and -negative myasthenia gravis. *Neurology*. 2005;**64**(3):536-538

[20] Willcox N, Schluep M, Ritter MA, Newsom-Davis J. The thymus in seronegative myasthenia gravis patients. *Journal of Neurology*. 1991;**238**:256-261

[21] Andrews PI, Sanders DB. Juvenile myasthenia gravis. In: Jones HR, DeVivo DC, Darras BT, editors. *Neuromuscular Disorders of Infancy, Childhood, and Adolescence*. Boston: Butterworth Heinemann; 2002. pp. 575-597. ISBN-13: 978-0750671903