

# We are IntechOpen, the world's leading publisher of Open Access books Built by scientists, for scientists

6,900

Open access books available

186,000

International authors and editors

200M

Downloads

Our authors are among the

154

Countries delivered to

TOP 1%

most cited scientists

12.2%

Contributors from top 500 universities



WEB OF SCIENCE™

Selection of our books indexed in the Book Citation Index  
in Web of Science™ Core Collection (BKCI)

Interested in publishing with us?  
Contact [book.department@intechopen.com](mailto:book.department@intechopen.com)

Numbers displayed above are based on latest data collected.  
For more information visit [www.intechopen.com](http://www.intechopen.com)



# Isn't Limb as Precious as Life?

*Prashant N. Mohite and André R. Simon*

## Abstract

As utilisation of peripheral extra-corporeal life support (ECLS) is becoming clinical routine, its associated complications become more frequent. Distal limb perfusion in femoral cannulation remains one of the Achilles's heels in patients with peripheral ECLS. Unless detected early, limb ischemia may result in loss of limb and sometimes life. A protocol-based approach, precautions during ECLS implantation and explantation procedures and continuous monitoring of the limb during ECLS support are key elements in preventing this complication. Utilisation of a distal limb perfusion cannula helps in prevention as well as management of limb ischemia; however, it may sometimes cause more damage than help. Management and consequence of limb ischemia essentially depends on its severity at the time of detection as well as time of intervention. This chapter offers a brief review of the burden of limb ischemia, means to prevent and approaches to manage it.

**Keywords:** extra-corporeal life support, limb ischemia, complications, distal limb perfusion

## 1. Introduction

Extra-corporeal life support (ECLS) for the last 2–3 decades has become an indispensable tool in the armamentarium of physicians and surgeons dealing with patients suffering severe cardio-pulmonary failure [1]. Over the period of time, its utilisation has seen a broadening in terms of indications, age limits and condition of patients [2–9]. Familiarisation with technique, continuous improvement of equipment and changes in strategy in favour of early intervention have helped to improve the survival of patients supported on the ECLS [10, 11]. However, unfortunately, a significant number of patients still suffer and succumb to complications instigated by the ECLS. In fact, not very uncommonly, ECLS related complications play a decisive role in the clinical outcome of the patient. For the purpose of this discussion, we use the term ECLS as a synonym for extra corporeal veno-arterial membrane oxygenation. Alternative technologies such Impella® or short term left ventricular assist (VAD) are not discussed. Initial ECLS in the acutely presenting patients is often implemented via femoral cannulation. Alternative approaches such as via the subclavian, axillary or carotid artery are used less commonly in adults and the incidence of limb ischemia in these scenarios is negligible compared to femoral artery. Therefore, for all practical purposes we will discuss lower extremity limb ischemia in this chapter. Late or chronic limb ischemia, sometimes occurring months after de-cannulation although symptomatic, seldom threatens limb survival and will not be discussed either.

Limb ischemia in patients supported on peripheral ECLS is one of the most dreaded complications and presents with a wide spectrum of clinical symptoms and outcomes.

Interestingly enough, this specific complication can be almost totally avoided with a protocol-based approach and precautions taken during the ECLS support; and if it occurs, it can be managed without significant consequences if detected and addressed immediately.

### **1.1 Indications**

ECLS, although offered by specialised units only, is becoming more and more adopted for treatment of patients presenting with a variety of problems. Recent developments in technology have resulted in easier implantation and maintenance, ability to implement directly at the bedside, complete cardiopulmonary support and cost-effectiveness when compared to other mechanical circulatory support devices.

In surgery, ECLS is utilised as a rescue in post-cardiotomy cardiogenic shock (PCCS) or as a temporary prolongation of cardiopulmonary bypass (CPB) to allow for an extensive weaning. Historically, the ECLS circuit was connected to the central CPB cannulation following unsuccessful weaning attempts of CPB. Recent years have seen a paradigm shift in preference to peripheral access. It is because peripheral cannulation allows for chest closure and avoids bleeding from high pressure aortic and thin-walled right atrial cannulation site and thus, multiple re-explorations for bleeding-temponade. Furthermore, the risk of formation of a positional thrombus on the intraluminal part of the aortic cannula, which may be dislodged at the time of decannulation and result in a catastrophic embolic event is avoided. And lastly, peripheral access obviates reopening of chest at the time of explantation of ECLS [2, 3]. Cannulation is either performed percutaneously or open, depending on the situation and the presenting patient.

A second group experiencing a significant increase in the utilisation of ECLS are patients during primary coronary intervention (PCI) [4, 5], although recent developments may lead to a shift in the technology used, such as Impella®. In this particular clinical setting, the expertise of interventional cardiologists and availability of fluoroscopy obviously lends itself to direct percutaneous implementation of ECLS. Bed-side, emergency direct ECLS implantation in intensive care units is a last and only resort to resuscitate patients after cardiopulmonary arrest undergoing prolonged efforts to re-establish life sustaining cardiac and pulmonary function (e-CPR) [6, 7]. In this situation, percutaneous peripheral access to the groin vessels is the preferable approach in view of the continuation of chest compressions and limited equipment available (e.g. fluoroscopy, surgical set).

In patients with advanced cardiac failure ECLS may be used as a bridge to decision, recovery or heart transplantation. In some of these patients, particularly those awaiting transplantation or long-term VAD implantation it is used in a 'semi-elective emergency situation' where patients are destabilising and showing signs of rapidly deteriorating end-organ function and impending cardiogenic shock. In this particular scenario ECLS is used to re-perfuse and stabilise end-organ function such as liver and kidney to allow for a non-emergency long-term VAD implantation at significantly less perioperative risk in a more stable patient. In this complex group of patients, peripheral access is favoured as it does not necessitate a sternotomy or thoracotomy leaving the chest 'virgin' or which may be complex due to previous, often multiple, surgical interventions. At the time of subsequent surgery ECLS can then easily be converted to CPB and continuation of ECLS post-surgery, if required [8, 9], can be achieved simply by switching back to an ECLS circuit.

In essence, peripheral access for the ECLS has become popular due to its flexibility of implantation outside operation theatre, reduced cannula site bleeding, the option of chest closure, avoidance of chest re-exploration and explantation without chest intervention. With the overall increase in the utilisation of ECLS in PCCS,

post-PCI, e-CPR and as a bridge to transplant or ventricular assist devices and even as a bridge-to-lower risk surgery as a preparational tool, ECLS related complications including limb ischemia are being seen more often than ever before.

## 1.2 Incidence of limb ischemia

ECLS, essentially being temporary mechanical circulatory support requires an exit strategy with a sustainable solution, namely short or long-term ventricular assist device or transplant. Until then, an uninterrupted and uncomplicated distal limb perfusion is essential for the continuation of peripheral ECLS for more than a few hours. Any complications during the period on ECLS support potentially hinder patients' progress to recovery or long-term solutions. Of these, limb ischemia is one of the notorious and unfortunately- most commonly encountered complications in patients supported. As with other complications, limb ischemia remains underreported in institutional audits and the literature and reported incidence of ECLS related limb ischemia vary significantly. The Extra-corporeal Life Support Organisation (ELSO) in its latest report shows 1% incidence of limb ischemia [12]. Whereas, a recent metanalysis reviewing 20 studies comprising 1886 patients revealed a pooled estimate of rate of limb ischemia as high as 16.9% (12.5–22.6%); compartment syndrome at 10.3% (7.3–14.5%) and amputation at 4.7% (2.3–9.3%) [13]. Other contemporary, smaller reviews report limb ischemia in range of 4.4–19% and 11–52% [14, 15]. The variation among published literature in incidence of limb ischemia and related complications may be due to difference in inclusion criteria of patients, difference in definition of limb ischemia and publication bias.

## 1.3 Causes and presentation spectrum of limb ischemia

Limb ischemia has a broad spectrum of presentation ranging from hypothermia to muscle necrosis. In patients on ECLS it may occur for a number of reasons. Of these, the first and foremost is, of course, the simple complete obstruction of the femoral artery by the systemic perfusion cannula, which is inserted in a retrograde fashion, either percutaneously or open. The second is the requirement of extensive vasoconstrictor and inotropic support, which may restrict the 'residual' flow to the limb to the point of induction of clinically relevant ischemia. The third is the result of a deterioration of remaining cardiac output and loss of pulse wave, as the limb may be perfused—adequately—during the systolic ejection and be completely ischemic should pulse-wave be lost. Finally, insertion of the venous cannula on the ipsilateral side may result in clinically relevant venous congestion by itself and thus exacerbate any arterial perfusion deficit. Thus, careful monitoring and adjustment of several variables is essential in the prevention of ischemia and the treatment must be aimed at not only correcting the underlying causation but also to mitigate the resulting effects as in necrosis or reperfusion induced injury.

The signs and symptoms of acute limb ischemia are classically described with the 6 Ps- **P**ain, **P**allor, **P**ulselessness, **P**araesthesia, **P**oikilothermia, and **P**aralysis [16]. In this context, Rutherford's grading of acute limb ischemia depending upon the clinical examination namely viable, threatened (salvageable if promptly treated) and irreversible (major tissue loss or permanent nerve damage inevitable) is helpful to determine the timing and type of intervention. The onset of fixed mottling of the skin usually implies irreversible changes but does not allow for an estimation as to the extent. Compartment syndrome results from increased pressure (greater than 30–45 mmHg) in the muscle compartments often due to ischemia or reperfusion related swelling which further decreases blood supply leading to a vicious cycle of swelling-ischemia-swelling, rapidly progressing to irreversible



necrosis of the affected muscles. Diagnosis is essentially clinical with findings of swelling, stiffness, pain, and loss of pulse. It is a limb and life-threatening emergency and is usually fatal unless immediate action is undertaken, almost always including four compartment fasciotomies [17].

Limb ischemia compromises survival not only of the involved limb but also the patient. The ischemic process, multiple procedures, and transfusions exacerbate the systemic inflammatory response related to ECLS, resulting in increased risk of death [18]. Tanaka *et al.* report a higher number of procedures per patient and an increased frequency of disseminated intravascular coagulation in patients with vascular complications [19]. They also found the rate of survival to discharge as 18 vs. 49% in patients with and without vascular complications, respectively, demonstrating vascular complications as an independent factor of survival in patients on VA ECLS [19]. While some authors did not find any correlation between limb ischemia and patient mortality [20–22], it is widely accepted that apart from severity of the underlying condition, neurological uncertainty, and eligibility for substantive therapy, the limb ischemia plays a seminal role in deciding fate of the patient supported on ECLS.

## 2. Prevention of limb ischemia

### 2.1 Prophylactic distal perfusion cannula

Several authors highlight the role of concurrent, prophylactic, selective distal limb perfusion from the time of femoral arterial cannulation for systemic perfusion in the prevention of limb ischemia. In one series, the authors claim no occurrence of limb ischemia in patients with prophylactic distal perfusion via selective cannulation (DPC) compared to a 21% incidence of ischemia in patients without DPC [21]. Tanaka *et al.* demonstrated that the absence of DPC was a significant predisposing factor for vascular complications, while other factors including medical history or risk factors like peripheral vascular disease and severity of baseline condition were not significantly associated with vascular complications [19]. However, from the review of published literature it is difficult to ascertain whether the elective avoidance of DPC or the presence of factors preventing its use (e.g. peripheral artery disease, vessel spasm, vessel injury due to attempted cannulation) are the underlying cause of the vascular complication.

In a comparative study, no limb ischemia was encountered in patients undergoing pro-active DPC in contrast to 9.3% incidence of limb ischemia in patients who underwent re-active DPC as a rescue strategy. They concluded that the delayed distal cannulation not only increased the extent of cannulation site bleeding, but also failed as a rescue therapy as it failed to improve the ischemia [23] whereas pro-active DPC prevented its occurrence. In addition, patients in the pro-active group demonstrated a significantly better weaning rate as well as survival.

However, despite extensive literature advocating DPC as being preventive to limb ischemia, there is no class I evidence about its efficacy. Understandably, it is difficult to design a randomised trial to identify actual protection offered by prophylactic DPC given the multiple factors responsible for mortality and morbidity and grave condition of patients supported on VA-ECMO.

Although DPC offers incessant perfusion to the distal limb, its insertion and maintenance are not always smooth, and it is not devoid of complications. The DPC due to their small calibre, slow and low flow, acute angles, multiple connections are prone to bending, thrombogenesis, and peripheral embolization. It is important to note that DPC blockage due to thrombosis may go unnoticed in absence of continuous

monitoring of its flow and result in complete thrombo-embolism and obstruction of the femoral artery. In order to avoid this scenario and assess whether limb perfusion remains adequate in the absence of DCP, Huang *et al.* measured the pressure in the superficial femoral artery distal to the systemic cannula and introduced the DPC only when this pressure was less than 50 mmHg [24]. In their cohort of 26 patients, only 9 patients fulfilling this criterion required the DPC and authors report no limb ischemia in any patients, with or without DPC. These findings are interesting and warrant further evaluation of their technique and confirmation by other study groups.

Compared to open cut-down DPC related complications are more common after percutaneous cannulation, often due to multiple cannulation attempts causing vessel injury, extravasation, hematoma and inadvertent cannulation of the *profunda femoris*. In contrast, while not ubiquitously feasible, technically more challenging and more time consuming, the open cut-down allows visualisation of the artery to ensure an adequate size of the cannula, proper placement, good haemostasis and the abandonment of the site without failed attempts in case of arterial calcifications [15]. Not surprisingly, a significantly higher incidence of limb ischemia was found in patients with a percutaneous DPC compared to patients with no DPC and open cut-down DPC in a series published by the Philadelphia group [25]. In this context, it is worth mentioning the 'chimney graft construction' approach on the femoral artery in which a small vascular graft is placed end-to-side onto the main femoral artery, thus allowing for bi-directional perfusion without obstruction of the vessel. This avoids the more complex V-A-DPC-ECLS circuit, the DPC itself and its complications [26]. However, while avoiding ischemia and advocated for small femoral arteries, in bigger vessels it may lead to distal limb hyper-perfusion [15] (**Table 1**).

A generalised and enthusiastic approach for prophylactic DPC should be carefully reviewed and implemented only in cases with high risk for limb ischemia. These include patients with a history and signs of peripheral vascular disease, atherosclerosis, previous utilisation of groin vessels for access and female gender due to smaller vessel size as they are more prone to develop limb ischemia. In addition, young age may be an independent risk factor due to the absence of collateral vascularisation [21]. Also, there are several variables influencing the risk of development of limb ischemia which can be addressed separately. These include low or no cardiac output resulting in loss of the pulse wave, although in patients with failure to oxygenate blood via the lung a low or absent biological output may be intended to prevent a watershed phenomenon and ensure cerebral oxygenation. High vasopressor support, peripheral shut-down and big calibre flow-occlusive systemic femoral cannulation are other factors influencing perfusion to distal limb and the development of limb ischemia.

As the principal role of the ECLS is temporary cardio-pulmonary support and preservation of organ perfusion, sufficient 'biomechanical' output can be provided often at a reasonable mechanical flow rate without complete replacement of the biological cardiac output. Cannulation with a small calibre systemic cannula may therefore provide enough flow and preserve a pulse wave allowing for sufficient perfusion of the distal limb. A 17F systemic cannula easily provides 4–5 L/min flow with a driving pressure of around 100 mmHg. Takayama *et al.* compared outcome in patients based on the size of the systemic cannula and showed that a 15F size cannula, while allowing for significantly less blood flow when compared to bigger (17–24F) cannulas, resulted in no difference in use of vasoactive medication, hemodynamic parameters or laboratory values measured [27]. On the other hand, significantly less cannulation-related adverse events were observed in the 15F group.

Patients on ECLS support may develop severe vasoplegia requiring high dose vasopressor support to sustain arterial blood pressure for satisfactory end-organ perfusion. Efforts to maintain a negative fluid balance to reabsorb peripheral and pulmonary oedema in a bid to wean ECLS may intensify vasopressor requirement

<b>Prevention of limb ischemia</b>
<b>Implantation</b>
Cut down and under vision cannulation whenever feasible
Percutaneous cannulation only with USG/Fluoroscopy
Use of small calibre systemic arterial cannula
Use of Prophylactic distal arterial perfusion cannula
Use of Prophylactic distal venous drainage cannula
Utilise contralateral limb for venous drainage cannula
<b>Maintenance</b>
Bear high suspicion for ischemia
Accept low ECLS flow when possible to reduce cannula size
Maintain left ventricular ejection
Maintain pulsatile flow
Wean vasopressors as soon as possible
Selective infusion of prostacyclin via distal perfusion cannula
Keep patient awake- can complain of limb pain (ischemia)
Suspect limb ischemia if serum Lactate levels high
Achieve and maintain good anticoagulation
<b>Monitoring</b>
Near infra-red spectroscopy in distal limb
Continuous measurement of DPC flow
Doppler Ultrasound of distal limb arteries
Temperature
<b>Explantation</b>
Prefer open cut-down and repair of vessels
Perform balloon thrombo-embolectomy
Avoid groin compression

**Table 1.**  
*Prevention of limb ischemia.*

further. While maintaining central blood pressure levels, capillary perfusion of end organs, specifically the intestine as well as the limbs may be significantly reduced in such a scenario. Therefore, it is important to strike a balance between vasopressor delivery dependent blood pressure management, maintenance of fluid balance, arterio-venous perfusion pressure delta and capillary delivery, prioritising vasopressor weaning over ‘drying up the lungs’. Maintenance of good intravascular volume also allows better ECLS flow and cardiac output along with pulsatility.

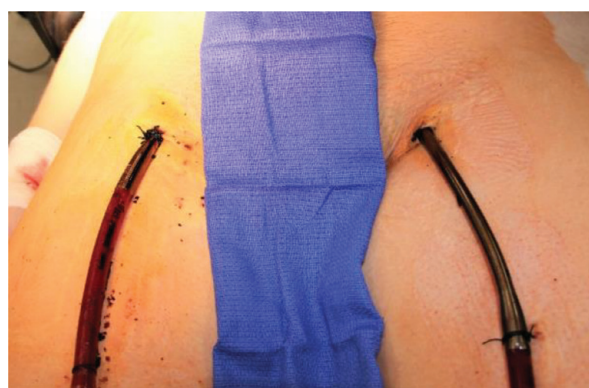In essence, utilisation of a small calibre systemic femoral cannula, when possible, acceptance a biomechanical output with low ECLS flow, continued pulsatile flow and avoidance of high dose vasopressors obviate the need for prophylactic DPC insertion in patients, potentially protecting them from DPC related complications. With this conservative management and a protocol of continuous, diligent monitoring, patients that develop limb ischemia can then be detected at an early stage and treated with subsequent DPC, if necessary.

## 2.2 ECLS and DPC implantation strategies

The individual approach of ECLS implantation heavily depends upon the place (out of the hospital, floor, bedside or operation theatre), urgency (elective or emergency), and aetiology (PCCS, post-PCI, primary graft failure or bridge to transplant) of the cardio-respiratory failure. In patients with cardiopulmonary arrest under resuscitation or peri-arrest patients, quick introduction of ECLS through is of utmost importance in order to sustain the patient's life. In this situation, the primary goal is the insertion of systemic arterial and venous cannulas and there may not be time for simultaneous DPC insertion. Such emergency bedside ECLS implantation in the intensive therapy unit is a scenario that usually does not offer facilities of an operation theatre making percutaneous insertion of peripheral cannulas necessary (**Figure 1**), often without availability of sonography to appropriately size for the smallest cannulae or fluoroscopy for intravascular positioning. In this context, it is important to note that percutaneous insertion of the DPC can be challenging in the presence of a systemic arterial cannula already in place, either due to the reduction or even absence of blood flow distal to the cannulation site or vasospasm and vessel injury during primary cannulation. Nevertheless, if it is attempted, ultrasound guidance during insertion is helpful and angiographic confirmation of DPC tip position in the superficial femoral artery should be obtained [25, 28].

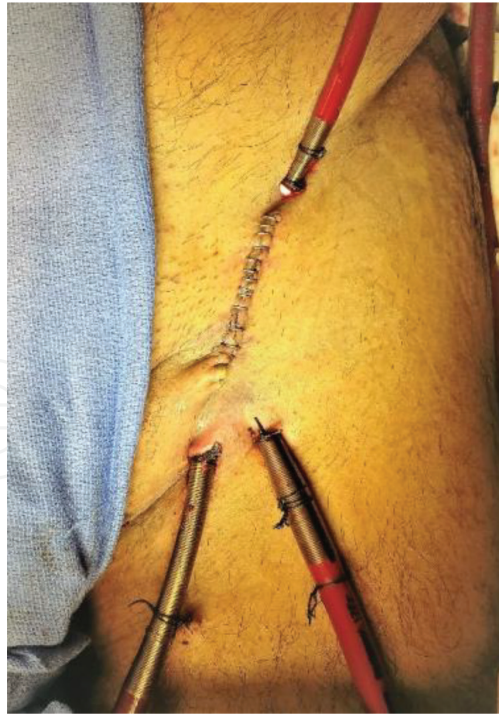PCCS is a scenario usually encountered after complex and long operations and has an extreme mortality. While ECLS is the only treatment option for these patients, it is important to make the decision to use it as early as possible and avoid repeated and prolonged attempts to wean the patient of CPB as these cause considerable collateral damage. ECLS should not be viewed as a last resort after all else has failed and the patient is in a catastrophic state but rather as a tool to be proactively used to ensure protection of organ function, continuous, uninterrupted sufficient perfusion and maintenance of a functioning coagulation system, thus preventing the well-known ICU exsanguination of these patients and offering both the heart as well as the patient a reasonable chance to recover.

For this, CPB can be converted directly to central ECLS, using the established cannulation or to peripheral ECLS. Peripheral ECLS allows the chest to be fully closed and no re-opening is needed for explantation of the ECLS system or for cannula-site bleeding especially in these patients on anti-coagulation therapy. With the patient stable on CPB it is safe and easy to perform a cut down to the groin vessels and placement of the cannulas under direct vision (**Figure 2**). If necessary, DPC can be introduced simultaneously. If the myocardial function is somewhat preserved, ECLS flows should be kept at a level allowing for blood flow through the heart to maintain left ventricular ejection in order to prevent its dilatation, stasis of



**Figure 1.**  
*Percutaneous cannulation.*





**Figure 2.**  
*Open cut-down cannulation.*

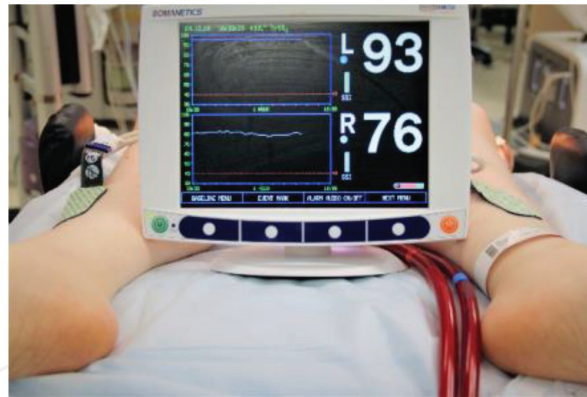blood and possible atrial and ventricular thrombus formation. In severe myocardial injury, the heart can be rested with full ECLS flow without ejection. In this case, the need for ventricular decompression should be discussed. With biological no-flow, a case of high vasopressor requirement or expected longer duration of support, the DPC can introduced at the same time.

Peri or post-PCI, with fluoroscopy readily available, all ECLS cannulas can be introduced percutaneously and their position be confirmed before the patient leaves the cath-lab. ECLS as a bridge to transplant in awake patients is a recent trend that offers early ambulation and avoids ventilator-associated complications [29]. However, bedside ECLS can be challenging as a cut down is not comfortable in such patients and difficult outside the environment of the operating theatre. In these patients, the systemic arterial and venous cannulae are introduced percutaneously under local anaesthesia or the patient undergoes a short analgo-sedation as full sedation may be too high risk. As a general principal, contralateral femoral arterial and venous cannulation should be encouraged, as the venous stasis and possible limb oedema caused by the venous cannula may intensify any ipsilateral arterial cannula related compromised distal limb perfusion [15].

## 2.3 Expectant monitoring of limb

### 2.3.1 Continuous monitoring

Continuous diligent monitoring of the limb for any signs of ischemia is a key to allow for timely and appropriate intervention. One elegant and inexpensive method of continuous monitoring is placing an additional pulse-oximetry probe on the toes of the cannulated limb. Its reading and waveform can be compared with the probe placed on the normal limb. However, hypothermia and non-pulsatile flow may not offer reliable pulse-oximetry reading. Near infra-red spectroscopy (NIRS), routinely used and established in transcranial cerebral oximetry can be helpful in such cases and is an alternative method for continuous monitoring. It involves application of sensor pads on the legs that detects regional oxygen saturation ( $rSO_2$ )



**Figure 3.**  
 NIRS continuous monitoring.

continuously, representing adequacy of tissue oxygenation. It should be applied as soon as ECLS is started. The  $rSO_2$  of the cannulated limb is compared with that of the opposite limb as well as with the baseline  $rSO_2$  providing live evidence of a drop in limb perfusion (**Figure 3**). A reduction in  $rSO_2$  values in the cannulated limb to less than 40 or more than 25% from baseline suggest inadequate limb perfusion and mandates urgent intervention [30, 31]. Technical glitches, however, like improper sensor pads attachments should be addressed before attempting to improve distal limb perfusion. Dong and colleagues utilised the NIRS successfully in a group of ECLS patients to detect and successfully treat limb ischemia with DPC in all patients having NIRS whereas 13.9% of the cohort not monitored required a fasciotomy [31]. Indeed, NIRS may reliably detect limb ischemia before it becomes clinically evident [31, 32]. Lamb *et al.* suggest continuous monitoring of limb utilising NIRS and evaluation of pedal doppler signals in case of a drop in baseline NIRS values to ensure adequate distal limb perfusion [33]. If available, we suggest that NIRS should be part of the protocol for peripheral ECLS.

In presence of DPC, continuous monitoring of its trans-cannular flow is the gold standard in monitoring distal limb perfusion (**Figure 4**). The DPC flow is dependent on a variety of factors, namely total ECLS flow, mean arterial pressure and systemic and peripheral vascular resistance, and possible thrombo-embolic occlusion in the DPC or distal artery. Therefore, any drop in the DPC flow must be correlated with these factors before any intervention. A drop in the DPC flow should also be cross-checked with the clinical signs of limb ischemia and drop in NIRS  $rSO_2$ . An hourly record of the DPC flow along with other ECLS parameters should be maintained and perfusionists should be alerted if there is a significant change. Cannula or connecting line bending, thrombosis and dislocation are common non patient related reasons for decreased DPC flow. Both antegrade and retrograde blood flow should be checked by clamps on either side of DPC side-port [10]. In the absence of a side-port, the DPC may have to be disconnected to assess for backflow through the cannula and appropriate flow in the proximal line. Thrombosis in the DPC is usually accompanied by embolization into the distal femoral artery and mandates embolectomy and DPC replacement. Only in the minority of cases it can be addressed by aspiration of the thrombotic material.

### 2.3.2 Hourly monitoring

Despite continuous monitoring of limb perfusion by means of NIRS and DPC flow, hourly inspection for skin colour change, palpation for temperature, capillary return at toe tips, calf palpation and calf girth measurement for compartment syndrome is of paramount importance. Pedal pulses should be checked in the *dorsalis pedis* and



**Figure 4.**  
*Continuous DPC flow monitoring.*

posterior tibial artery and when not palpable a hand-held ultrasound Doppler should be utilised to confirm the flow. The flow may be graded for documentation as palpable-strong pulsatile, palpable- weak pulsatile, doppler- pulsatile, doppler- continuous flow and absent flow. Hourly recording of continuously monitored variables namely DPC flow, NIRS  $rSO_2$  are necessary to establish trends and detect limb ischemia before it is clinically apparent. Numbers and signs that may be missed during continuous monitoring can be caught in a vigilant hourly survey. Ischemia in toes is seen not uncommon, even in the presence of well-maintained DPC flow due to peripheral micro thromboembolization and/or vasospasm due to peripheral shut down or high dose vasopressors.

## 2.4 Early detection of limb ischemia

Early detection of inadequate limb perfusion allows for immediate intervention to avoid its catastrophic consequences. In absence of the DPC, continuous NIRS monitoring supplemented by an hourly survey by means of clinical examination and Doppler ultrasound flow check in the distal arteries is usually adequate to detect limb ischemia at an early stage. NIRS  $rSO_2$ , clinical signs and ultrasound Doppler flow in the cannulated limb should be compared with opposite limb, not to confuse ischemia with peripheral shut down and peripheral vasospasm. In patients with a prophylactic or therapeutic introduction of DPC, it is important to remember that the DPC does not guarantee adequate perfusion. Thus, continuous measurement of DPC flow, maintenance of adequate anticoagulation and monitoring of actual limb perfusion remains essential. Awake non-intubated, non-sedated patients supported on ECLS may complain of pain, tingling- numbness or stiffness with the onset of limb ischemia. An increase in lactate levels without an attributable source and acute kidney failure may be signs of subclinical rhabdomyolysis and should immediately



raise suspicion of ischemia. Finally, signs of ischemia may be seen only in the toes, even with a good DPC flow due to peripheral embolization through DPC.

2.5 Explantation

ECLS is a lifesaver for patients with compromised cardiopulmonary function; however, it may instigate life-threatening complications and the incidence of complications increases with increase in duration of the ECLS. Yoe *et al.* found the duration of ECLS more than 7 days is a factor associated with the development of limb ischemia [23]. Therefore, weaning of ECLS should begin with recovery of vital organ function with the aim of its explantation as soon as possible. Extra caution is mandated during weaning of patients with the DPC, as the decrease in total ECLS flow decreases DPC flow that may lead to inadequate limb perfusion as well as thrombosis of the DPC. In this situation, the DPC flow should be maintained around at least 300 ml/min by applying a gate clamp on the retrograde arterial cannula. Explantation of ECLS at the end of successful weaning should be performed as an elective case in the operation theatre. The vessels are exposed and controlled with slings before removal of cannulas. Embolectomy is attempted multiple times with balloon tip catheters till satisfactory retro and antegrade blood flow is achieved. The artery is then repaired with or without a patch or an interposition graft to maintain its original calibre without flow limitation. The limb is monitored for at least 48 hours following ECLS explantation for any signs of residual or fresh ischemia.

3. Treatment of limb ischemia

Traditionally, 6 hours are recommended as a golden period for intervention in limb ischemia. In a series analysing limb ischemia in ECLS patients an additional retrograde reperfusion within 6 hours of onset of symptoms avoided amputations completely, whereas the same procedure after that period was burdened with a 20% amputation rate or permanent neurological deficit [34]. Therefore, every attempt should be made to re-establish adequate blood supply in the ischemic limb as soon as possible to avoid catastrophic consequences and residual damage (Table 2).

3.1 Therapeutic insertion of distal perfusion cannula

Limb ischemia due to inadequate flow in the distal artery detected at early stage ideally should be treated with the introduction of the DPC if not placed at ECLS implantation. Apart from conscious avoidance, reasons for not introducing

Management of established limb ischemia
Introduce distal perfusion cannula (DPC)- cut down
Percutaneous DPC- Check position with fluoroscopy
Continuous Epoprostenol in DPC
Thrombo-embolectomy
Change of cannulation site
Decompression compartment fasciotomy
Amputation

Table 2.  
Management of limb ischemia.



prophylactic DPC are among others: failed percutaneous insertion, atherosclerotic plaque palpated in open cut-down and need to return to the intensive care unit for patient stabilisation. In a metanalysis reviewing 22 retrospective studies comparing peripheral ECLS with or without DPC, the presence of a DPC was associated with at least a 15.7% absolute reduction in the incidence of limb ischemia; although without any impact on the patient survival [35].

Several cannulas from an introducer sheath up to a paediatric arterial cannula are recommended in the literature for this purpose. An ideal is the one that is resistant to bending and thrombosis and offering a least resistance to flow. We found the incidences of limb ischemia and limb ischemia requiring surgical intervention were significantly higher for the introducer sheath compared with the 10–12F Bio-Medicus® paediatric seldinger cannula utilised for distal limb perfusion (30.6 vs. 15.6% and 15.4 vs. 6.25%, respectively) [11].

To introduce the DPC percutaneously, the superficial femoral artery may be visualised distal to the systemic cannula via Ultrasound. If this is not possible, a cut-down insertion should be performed. If introduced bedside, especially percutaneously, the position of the DPC should be confirmed via x-ray.

### 3.2 Continuous infusion of anticoagulants and vasodilator drugs

Any ECLS circuit exposes blood to non-biological surfaces and is in itself thrombogenic. Therefore, adequate anticoagulation, usually achieved by continuous intravenous delivery of unfractionated heparin is essential to prevent complications such as thrombus formation and clotting of the circuit and stroke, limb and bowel ischemia. Conventionally heparin is delivered via a central venous catheter. As the small arteries of the distal limb are specifically at risk of micro-thrombotic clotting complications a targeted delivery of anticoagulants may offer a strategy to prevent distal ischemia. Continuous heparin delivery in the ECLS circuit before oxygenator at beginning of ECLS should be considered in any institutional protocol.

Due to the discrepancy in size of the aorta and distal superficial femoral artery as well as resistance between the systemic cannula and the DPC, there is a significant discrepancy in the flow rate between them, sometimes resulting in very little or almost no flow through the for DPC. In these cases, a gate clamp on the systemic arm can be helpful; however, it may cause flow turbulence, is potentially thrombogenic and increases driving pressure in the system.

Alternatively, and already mentioned above, Epoprostenol, a potent vasodilator, which is established in the treatment of peripheral vascular disease, can be delivered directly into the limb via DPC side-port in order to induce peripheral vasodilatation and increase perfusion. Some paediatric aortic cannulas have a side-port that can be readily used for this purpose [10]. Otherwise, a 3/8–3/8" connector with a side-port can be inserted into the arm feeding the DPC. In some patients this may result in an increased requirement of vasopressors to maintain central arterial pressure. As a word of caution, selective infusion of vasodilators may also result in hyper-perfusion and clinically relevant oedema, especially in presence of an *ipsilateral* venous cannula.

### 3.3 Change of cannulation site

Peripheral access for ECLS seek mainly due to urgency or bedside scenario is converted to central access once patient is stabilised or develops complication due to peripheral cannulation. One of the strategies in suspected or established limb involves shifting the arterial cannulation site followed by embolectomy and, if necessary, repair of the vessel. In many cases this may be the ascending aorta, as this offers

certain advantages such as oxygenated blood supply to coronaries and avoidance of any watershed phenomenon, even in patients with compromised lung function. Also, the opposite superficial femoral artery or axillary artery may be utilised if the treating physician wants to avoid sternotomy or cannulation of the aorta is difficult. In patients with acceptable lung function and compromised cardiac function, ECLS can be converted into a uni- or bi-ventricular short-term ventricular assist device at this time avoiding the further use of the oxygenator and thus allowing for a less stringent anticoagulation regime and easier mobilisation of the patient.

3.4 Management of advanced limb ischemia

Fasciotomy is a decompression manoeuvre performed on the limb with acute compartment syndrome, a surgical emergency. Release of pressure allows reperfusion of the ischemic muscles potentially avoiding amputation. A recent metanalysis consisting 1886 patients found 10% incidence of compartment syndrome requiring fasciotomy [13].

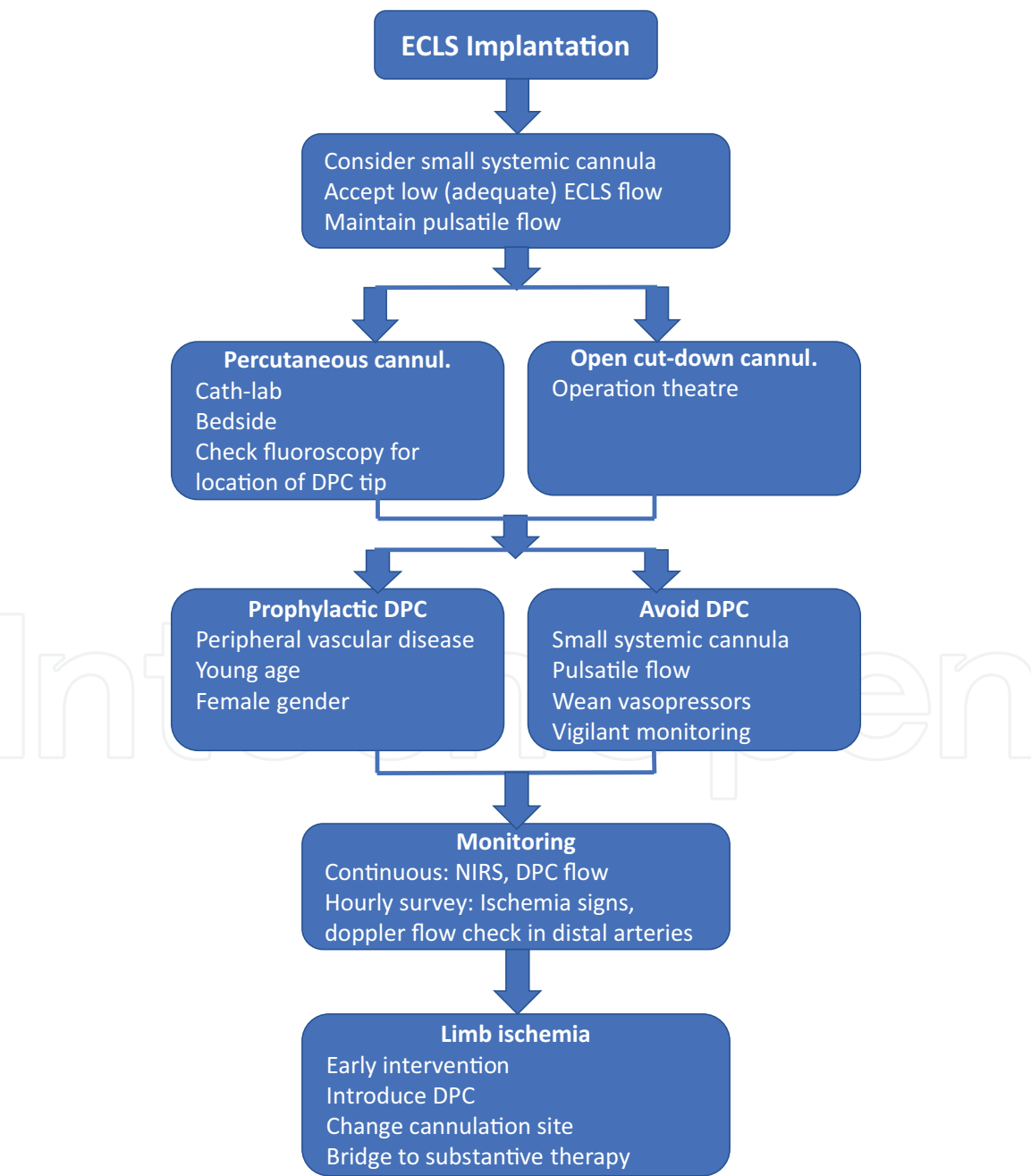


Figure 5.  
Protocol for management of limb ischemia.

Several authors confirm that the procedure is effective provided it is performed as soon as the diagnosis of compartment syndrome is established. It can be performed bedside under local anaesthesia [36, 37]. Four chamber fasciotomies essentially involve decompression of anterior and posterior compartment of the thigh and anterolateral and posteromedial compartments of lower leg. Primary closure of these wounds can be performed following explantation of ECLS and decrease of limb swelling.

A last and unfortunate resort in the management of advanced limb ischemia to save a life is to give up a limb. Irreversible ischemic damage to skin and muscles causes rhabdomyolysis, acute kidney injury, and metabolic acidosis. In such cases, amputation of the limb remains the only option to save the patient's life. Contemporary retrospective observational studies report incidence of lower limb amputation in patients supported with ECLS between 1 to 10% [11, 13, 15, 20, 21, 38]. However, some prospective studies with utilisation of newer technology and ideas such as NIRS for early detection of ischemia and distal arterial pressure based or pre-emptive introduction of DPC reported no amputations [23, 24, 31]. However, apart from the obvious benefit of these newer techniques, patients in studies focusing on limb ischemia may have received significant additional attention and care to prevent and treat limb ischemia at early stage. This in itself may have had a profound effect, further corroborating that early detection of limb ischemia with expectant monitoring and protocol-based prompt intervention may avoid its catastrophic consequences (**Figure 5**).

#### **4. Conclusions**

Care of the cannulated limb with maintenance of adequate perfusion to avoid ischemia is as important as the preservation of vital organ function. Limb ischemia plays a seminal role in the fate of a patient supported on ECLS. Vascular complications, particularly limb ischemia negatively affect survival in patients on ECLS. Expectant continuous monitoring utilising NIRS, if used, a flow monitored distal perfusion cannula and hourly surveys of flow in distal arteries and signs of ischemia are key in timely detection of limb ischemia. A prophylactic distal perfusion cannula should always be used in patients with risk factors for development of limb ischemia and can most likely be avoided in others if a small calibre systemic cannula is used. Acceptance of lower ECLS flow, maintenance of pulsatility and avoidance of vasopressors are additional important elements. Prompt intervention to re-establish adequate blood supply after suspicion of limb ischemia is essential to avoid its catastrophic consequences. The safest method of prophylactic or therapeutic introduction of a distal perfusion cannula remains the open cut-down and exposure. Percutaneously inserted distal perfusion cannulas should be checked for their position by fluoroscopy. Also, change of cannulation site and bridging ECLS to a substantive therapy should be part of any strategy for patients on ECLS. If properly integrated into an institutional protocol and adhered to, these strategies allow for successful treatment of patients in need of extracorporeal life support with low complication and high success rates.

#### **Acknowledgements**

Authors are not funded for preparation of this manuscript. Authors thank Olaf Maunz for helping with manuscript editing.

#### **Conflict of interest**

Authors do not have any conflicts of interest.

IntechOpen

IntechOpen

### **Author details**

Prashant N. Mohite\* and André R. Simon  
Royal Brompton and Harefield NHS Foundation Trust, Harefield Hospital,  
United Kingdom

\*Address all correspondence to: [p.mohite@rbht.nhs.uk](mailto:p.mohite@rbht.nhs.uk)

### **IntechOpen**

© 2019 The Author(s). Licensee IntechOpen. This chapter is distributed under the terms of the Creative Commons Attribution License (<http://creativecommons.org/licenses/by/3.0>), which permits unrestricted use, distribution, and reproduction in any medium, provided the original work is properly cited. 



## References

- [1] Thiagarajan RR, Barbaro RP, Rycus PT, McMullan DM, Conrad SA, Fortenberry JD, et al. Extracorporeal life support organization registry international report 2016. *ASAIO Journal*. 2017;**63**(1):60-67
- [2] Khorsandi M, Dougherty S, Bouamra O, Pai V, Curry P, Tsui S, et al. Extra-corporeal membrane oxygenation for refractory cardiogenic shock after adult cardiac surgery: A systematic review and meta-analysis. *Journal of Cardiothoracic Surgery*. 2017;**12**(1):55
- [3] Pappalardo F, Montisci A. Venous-arterial extracorporeal membrane oxygenation (VA ECMO) in postcardiotomy cardiogenic shock: How much pump flow is enough? *Journal of Thoracic Disease*. 2016;**8**(10):E1444-E1448
- [4] Sung PH, Wu CJ, Yip HK. Is extracorporeal membrane oxygenator a new weapon to improve prognosis in patients with profound cardiogenic shock undergoing primary percutaneous coronary intervention? *Circulation Journal*. 2016;**80**:572-578
- [5] Tsao NW, Shih CM, Yeh JS, et al. Extracorporeal membrane oxygenation-assisted primary percutaneous coronary intervention may improve survival of patients with acute myocardial infarction complicated by profound cardiogenic shock. *Journal of Critical Care*. 2012;**27**:530. e1-530.e11
- [6] Ortega-Deballon I, Hornby L, Shemie SD, Bhanji F, Guadagno E. Extracorporeal resuscitation for refractory out-of-hospital cardiac arrest in adults: A systematic review of international practices and outcomes. *Resuscitation*. 2016;**101**:12-20
- [7] Tonna JE, Johnson NJ, Greenwood J, Gaieski DF, Shinar Z, Bellezo JM, et al. Extracorporeal REsuscitation Consortium (ERECT) Research Group. Practice characteristics of Emergency Department extracorporeal cardiopulmonary resuscitation (eCPR) programs in the United States: The current state of the art of Emergency Department extracorporeal membrane oxygenation (ED ECMO). *Resuscitation*. 2016;**107**:38-46
- [8] Durinka JB, Bogar LJ, Hirose H, Brehm C, Koerner MM, Pae WE, et al. End-organ recovery is key to success for extracorporeal membrane oxygenation as a bridge to implantable left ventricular assist device. *ASAIO Journal*. 2014;**60**(2):189-192
- [9] Chung JC, Tsai PR, Chou NK, Chi NH, Wang SS, Ko WJ. Extracorporeal membrane oxygenation bridge to adult heart transplantation. *Clinical Transplantation*. 2010;**24**(3):375-380
- [10] Mohite PN, Maunz O, Simon AR. Pearls and pitfalls in short-term mechanical circulatory assist: How to avoid and manage complications. *Artificial Organs*. 2014;**38**(10):829-837
- [11] Mohite PN, Fatullayev J, Maunz O, Kaul S, Sabashnikov A, Weymann A, et al. Distal limb perfusion: Achilles' heel in peripheral venoarterial extracorporeal membrane oxygenation. *Artificial Organs*. 2014;**38**(11):940-944
- [12] Extracorporeal Life Support Organisation. ECLS Registry Report. Ann Arbor. 2017. Downloaded Nov 2017
- [13] Cheng R, Hachamovitch R, Kittleson M, Patel J, Arabia F, Moriguchi J, et al. Complications of extracorporeal membrane oxygenation for treatment of cardiogenic shock and cardiac arrest: A meta-analysis of 1,866 adult patients. *The Annals of Thoracic Surgery*. 2014;**97**(2):610-616

- [14] von Segesser L, Marinakis S, Berdajs D, Ferrari E, Wilhelm M, Maisano F. Prevention and therapy of leg ischaemia in extracorporeal life support and extracorporeal membrane oxygenation with peripheral cannulation. *Swiss Medical Weekly*. 2016;**146**:w14304
- [15] Roussel A, Al-Attar N, Khaliel F, Alkhoder S, Raffoul R, Alfayyadh F, et al. Arterial vascular complications in peripheral extracorporeal membrane oxygenation support: A review of techniques and outcomes. *Future Cardiology*. 2013;**9**(4):489-495
- [16] Brearley S. Acute leg ischaemia. *BMJ*. 2013;**346**:f2681
- [17] Tiwari A, Haq AI, Myint F, Hamilton G. Acute compartment syndromes. *The British Journal of Surgery*. 2002;**89**(4):397-412. Review
- [18] Levi M. Current understanding of disseminated intravascular coagulation. *British Journal of Haematology*. 2004;**124**:567-576
- [19] Tanaka D, Hirose H, Cavarocchi N, Entwistle JW. The impact of vascular complications on survival of patients on venoarterial extracorporeal membrane oxygenation. *The Annals of Thoracic Surgery*. 2016;**101**(5):1729-1734
- [20] Bisdas T, Beutel G, Warnecke G, et al. Vascular complications in patients undergoing femoral cannulation for extracorporeal membrane oxygenation support. *The Annals of Thoracic Surgery*. 2011;**92**:626-631
- [21] Foley PJ, Morris RJ, Woo EY, Acker MA, Wang GJ, Fairman RM, et al. Limb ischemia during femoral cannulation for cardiopulmonary support. *Journal of Vascular Surgery*. 2010 Oct;**52**(4):850-853
- [22] Avalli L, Sangalli F, Migliari M, Maggioni E, Gallieri S, Segramora V, et al. Early vascular complications after percutaneous cannulation for extracorporeal membrane oxygenation for cardiac assist. *Minerva Anestesiologica*. 2016;**82**(1):36-43
- [23] Yeo HJ, Yoon SH, Jeon D, Kim YS, Cho WH, Kim D, et al. The utility of preemptive distal perfusion cannulation during peripheral venoarterial extracorporeal membrane oxygenation support. *Journal of Interventional Cardiology*. 2016;**29**(4):431-436
- [24] Huang SC, Yu HY, Ko WJ, Chen YS. Pressure criterion for placement of distal perfusion catheter to prevent limb ischemia during adult extracorporeal life support. *The Journal of Thoracic and Cardiovascular Surgery*. 2004;**128**(5):776-777
- [25] Vallabhajosyula P, Kramer M, Lazar S, McCarthy F, Rame E, Wald J, et al. Lower-extremity complications with femoral extracorporeal life support. *The Journal of Thoracic and Cardiovascular Surgery*. 2016;**151**(6):1738-1744
- [26] Jackson KW, Timpa J, McIlwain RB, et al. Side-arm grafts for femoral extracorporeal membrane oxygenation cannulation. *The Annals of Thoracic Surgery*. 2012;**94**:111-112
- [27] Takayama H, Landes E, Truby L, Fujita K, Kirtane AJ, Mongero L, et al. Feasibility of smaller arterial cannulas in venoarterial extracorporeal membrane oxygenation. *The Journal of Thoracic and Cardiovascular Surgery*. 2015;**149**(5):1428-1433
- [28] Black MC, Slaughter MS. Proactive or reactive? Best approach to limb ischemia in peripheral venoarterial extracorporeal life support. *The Journal of Thoracic and Cardiovascular Surgery*. 2016;**151**(6):1745-1746
- [29] Mohite PN, Sabashnikov A, Reed A, Saez DG, Patil NP, Popov AF, et al.

Extracorporeal life support in “Awake” patients as a bridge to lung transplant. The Thoracic and Cardiovascular Surgeon. 2015;**63**(8):699-705

[30] Wong JK, Smith TN, Pitcher HT, Hirose H, Cavarocchi NC. Cerebral and lower limb near-infrared spectroscopy in adults on extracorporeal membrane oxygenation. Artificial Organs. 2012;**36**:659-667

[31] Kim DJ, Cho YJ, Park SH, Lim C, Park KH, Jheon S, et al. Near-infrared spectroscopy monitoring for early detection of limb ischemia in patients on veno-arterial extracorporeal membrane oxygenation. ASAIO Journal. 2017;**63**(5):613-617

[32] Prkic I, Stuth EA. Near-infrared spectroscopy provides continuous monitoring of compromised lower extremity perfusion during cardiac surgery. Journal of Clinical Anesthesia. 2016;**31**:38-41

[33] Lamb KM, DiMuzio PJ, Johnson A, Batista P, Moudgill N, McCullough M, et al. Arterial protocol including prophylactic distal perfusion catheter decreases limb ischemia complications in patients undergoing extracorporeal membrane oxygenation. Journal of Vascular Surgery. 2017;**65**(4):1074-1079

[34] Spurlock DJ, Toomasian JM, Romano MA, Cooley E, Bartlett RH, Haft JW. A simple technique to prevent limb ischemia during veno-arterial ECMO using the femoral artery: The posterior tibial approach. Perfusion. 2012;**27**:141-145

[35] Juo YY, Skancke M, Sanaiha Y, Mantha A, Jimenez JC, Benharash P. Efficacy of distal perfusion cannulae in preventing limb ischemia during extracorporeal membrane oxygenation: A systematic review and meta-analysis. Artificial Organs. 2017;**41**(11):E263-E273

[36] Go JY, Min YS, Jung TD. Delayed onset of acute limb compartment syndrome with neuropathy after venoarterial extracorporeal membrane oxygenation therapy. Annals of Rehabilitation Medicine. 2014;**38**(4):575-580

[37] Wall CJ, Santamaria J. Extracorporeal membrane oxygenation: An unusual cause of acute limb compartment syndrome. Anaesthesia and Intensive Care. 2010;**38**:5602

[38] Gander JW, Fisher JC, Reichstein AR, Gross ER, Aspelund G, Middlessworth W, et al. Limb ischemia after common femoral artery cannulation for venoarterial extracorporeal membrane oxygenation: An unresolved problem. Journal of Pediatric Surgery. 2010;**45**:2136-2140