

# We are IntechOpen, the world's leading publisher of Open Access books Built by scientists, for scientists

6,900

Open access books available

185,000

International authors and editors

200M

Downloads

Our authors are among the

154

Countries delivered to

TOP 1%

most cited scientists

12.2%

Contributors from top 500 universities



WEB OF SCIENCE™

Selection of our books indexed in the Book Citation Index  
in Web of Science™ Core Collection (BKCI)

Interested in publishing with us?  
Contact [book.department@intechopen.com](mailto:book.department@intechopen.com)

Numbers displayed above are based on latest data collected.  
For more information visit [www.intechopen.com](http://www.intechopen.com)



# Assessment and Treatment of Obstructed Defecation Syndrome

*Dimitrios Linardoutsos*

## Abstract

Fecal incontinence is not a rare clinical pathology in general population. Although it is more common in geriatric population, fecal incontinence should not be underestimated in younger genders. Obstructive defecation syndrome (ODS) has become a well-known syndrome with different clinical etiology and symptoms. The main symptom is inability of proper rectal emptying, but it can also overlap with symptoms of incontinence. In this chapter, we emphasize on the assessment of ODS, focusing on the coexistence and clinical relation to fecal incontinence. Anorectal studies are of great importance for the evaluation of the symptoms. Biofeedback is the key to the proper management of patients with ODS, showing significant improvement in incontinence as well. Surgical treatment of anatomic deformities that cause ODS is also important.

**Keywords:** obstructive defecation syndrome, incontinence, rectocele, dyssynergia, biofeedback

## 1. Introduction

Fecal incontinence is a common clinical problem in general population, mainly in older people. By definition, it is the inability to control bowel movements or, in other words, the uncontrolled and involuntary loss of solid or liquid stool or gas. The uncontrolled loss should last at least more than 1 month and with regard to patients who were previously continent. The terms anal or bowel incontinence are also used to represent the same clinical entity. Fecal incontinence, as a symptom, has various etiologies. Obstructed defecation syndrome is a very common pathology acting actually as one of the underlying causes of fecal incontinence.

Obstructed defecation syndrome (ODS) is the inability of the patient to empty the rectum normally. By definition, it is a clinical condition where the patient has the feeling of not emptying the rectum adequately. It can also be related, sometimes, to reduced bowel movements. Terminology of this condition in the literature also includes rectal outlet obstruction or evacuatory dysfunction. ODS may coexist with other bowel pathologies such as irritable bowel syndrome, anatomical deformities such as sigmoidocele, or even other colonic motility disorders, such as slow transit constipation. ODS is frequently associated with fecal incontinence. The established status quo is that fecal impaction, as a secondary effect from a rectocele or intussusception, causes overflow incontinence. Prolonged fecal impaction, prolapse or other ODS pathologies, all contribute to impairment of rectal compliance and thus sensitivity, as well as sphincter damage from chronic distention. ODS from

various causes can provoke episodes of incontinence; however, new data suggest an increased risk of anal incontinence in patients who have had different types of operation for ODS in the past.

## **2. Defecation physiology**

In order to understand the physiology of defecation, deep knowledge of the anatomy of the rectum and anal canal is very important. The rectum is the last part of the large intestine, located in the lower pelvis. Rectal function is crucial for retention of stool (continence) and for evacuation (defecation). The rectum measures about 15–17 cm in length, descending along the sacrococcygeal concavity and passing through the pelvic floor to the anal canal. The major part is called the rectal ampulla, which is a wide segment, with a perimeter that can extend to more than 15 cm. The lowest and narrowest part is the anal canal. The anorectal junction is formatted by the constant traction of the puborectal sling. The levator ani muscle, formed by the iliococcygeus, the pubococcygeal, and the puborectal muscles, serves as the pelvic floor. The relaxation of levator ani, and mainly the puborectalis muscle, the perineum and contraction of the lower abdomen, and the relaxation of the anal sphincter, all work in tandem in order to provide a normal defecation. Distention of rectal wall stimulates contractions of colon and rectal wall, mediated by the parasympathetic defecation reflex. Thus, phasic rectal contractions start and tone increases, formatting a conduit shape of rectum rather than a reservoir. For the above pattern of function, rectal sensitivity is of great importance. Once the rectum is filled with stool, the internal anal sphincter relaxes, as per the rectoanal inhibitory reflex. Simultaneous relaxation of the puborectalis muscle creates an obtuse anorectal angle, thus allowing defecation to occur normally. Defecation can be postponed with voluntary contraction of the external anal sphincter. Regarding pelvic floor innervations, the pudendal nerve innervates the external anal sphincter and some fibers of the puborectalis muscle, while the rest of puborectalis and levator ani muscles are getting innervations from sacral roots of S3 and S4 [1].

## **3. Clinical manifestation**

Symptoms of ODS include rectal or lower abdominal pain, a feeling of bloatedness or incomplete rectal evacuation, the use of vaginal splitting or perineal manipulation to help the defecation, prolonged straining, spending more time than usual in toilet, perineal descent, report of hard stools as well as dependency on laxatives and enemas. Obstructive defecation syndrome may be of various functional or anatomical origins. Functional etiology includes aganglionic rectum (short-term Hirschsprung), neuro-pathic disorders (multiple sclerosis, spinal cord lesions), and pelvic floor dyssynergia, such as in anismic patients. Mechanical ODS comes from anatomic deformities such as internal intussusception, rectocele, rectal prolapse or enterocele [2].

Soiling and real fecal incontinence are also usual symptoms of ODS mainly, but not solely, representing overflow diarrhea. In this chapter, we will focus on the coexistence and clinical relation between obstructive defecation syndrome and fecal incontinence.

## **4. Epidemiology**

Obstructive defecation and fecal incontinence have been recognized as related pathologies in geriatric population [3]. Fecal impaction and concomitant overflow

diarrhea, as a typical non-controlled loss of stool, is not unusual. However, the coexistence of other pathologies and the lack of accurate statistics still exist [4]. Fecal impaction and chronic straining can cause denervation and pelvic floor weakness, which is the most well-known cause of obstructed defecation syndrome [5].

Apart from chronic straining as a known cause, adaptation of endoanal ultrasound in assessment of incontinence showed anal sphincter disruption as a common cause of fecal incontinence [6]. However, it is well known that prevalence of anal incontinence remains equal between genders. This leads to the possible conclusion that the role of obstetric injury in fecal incontinence is important, but may be not crucial, bearing in mind the equal number of male patients suffering from this condition. In addition, most female patients who suffer from incontinence, report the onset of their symptoms many years after delivery, making clinicians consider other contributing pathologies on top of the sphincter damage [7]. Recently, more studies are dealing with the coexistence of underlying constipation and fecal pathology [8].

In general, population, overlapping of symptoms of slow transit constipation, obstructive defecation, and incontinence are considerable, indicating constipation as a principal risk factor for fecal incontinence. Damon et al. found that between 706 patients, 63% reported difficulty in defecation, and 51% found to have sense of incomplete evacuation [9]. Several other studies represent similar findings and demonstrate the role of ODS in coexistent fecal incontinence [10, 11].

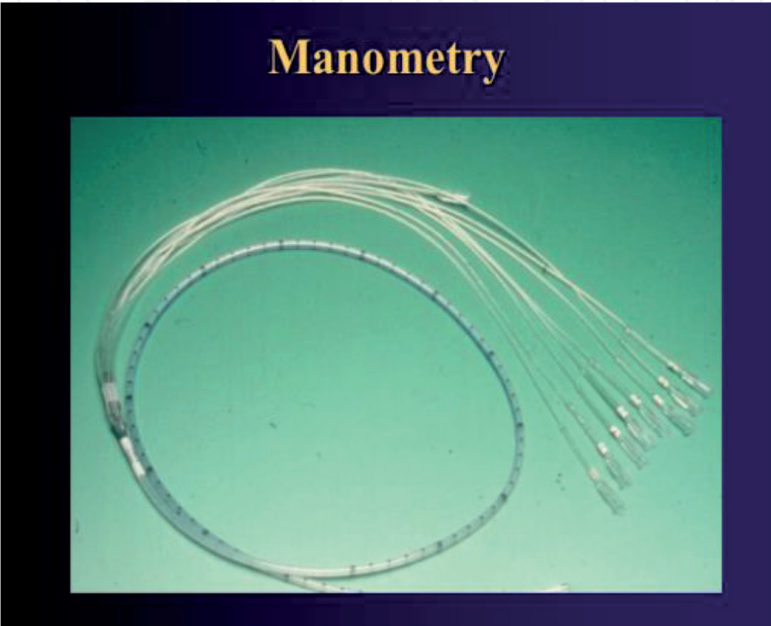
More specifically, in patients assessed in colorectal clinics, although the series are small, proctographic studies have shown similar findings. Rex et al. used anorectal manometry and defecography for the assessment of their patients. They demonstrated retention of contrast in rectoceles and incomplete evacuation in patients having clinical symptoms of ODS with concurrent incontinence [12]. In another study by Harewood et al., between 38 patients that evaluated with symptoms of incomplete evacuation and straining, 15% were found to also suffer from fecal incontinence [13]. In another study from Mohammed SD et al. on 200 patients complaining for symptoms of ODS, 91% reported incontinence [14]. Similar reports are coming from an evaluation of 161 male patients complaining for fecal incontinence, having found that almost half of them (48%) have concurrent functional constipation [15].

## 5. Assessment

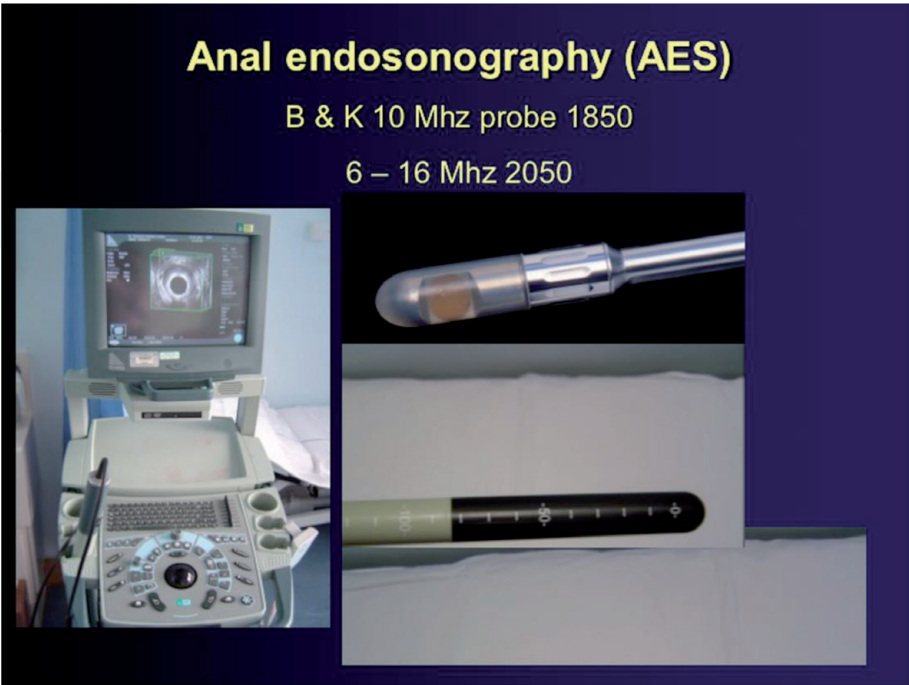
Rectal function and defecation should be assessed clinically and with several radiological or functional tests. Apart from colonoscopy, which is important to exclude any malignant causes of changes in bowel habits, clinical examination may reveal descent perineum, absence of rectoanal inhibitor reflex, sphincter tears or external openings of perianal sinus. Observation of perineum after requesting patient to squeeze usually allows us to understand if intussusception, or prolapse, is the clinical problem. Digital rectal exam is crucial to estimate the rest and squeeze anal tone, to assess for possible fecal impaction, rectocele or to palpate any abnormal mass.

Rectal sensitivity is usually assessed with air or water insufflation and distention of either a balloon or condom inserted to the rectum. Today multimodal balloon catheters allow the analysis of electrical and temperature receptors as well. Balloon expansion resembles the full rectum and triggers the need for evacuation. The time, the volume of the balloon, and the difficulty to expel provide much information about the rectal sensitivity and the possible dyssynergic defecation. Mean balloon volume is 50 ml of water. Expulsion should take less than 30 s in young men and less

than 1 min in older men, but in women expulsion should occur in about a minute, regardless of age. Balloon expulsion test along with anorectal manometry is considered the primary diagnostic tests for identifying ODS. New manometric catheters have an expulsion balloon on the tip, permitting the performance of anorectal manometry at the same time. Anorectal manometry with high resolution catheters provides excellent information. Catheters can have up to 36 channels, evaluating pressure along the entire anal canal as long as the changes of pressures at the time of rectal distention (**Figure 1**). Physicians can get information for rest and squeeze pressures, about the rectoanal inhibitor reflex, the push defecation test, and the pressures during cough.



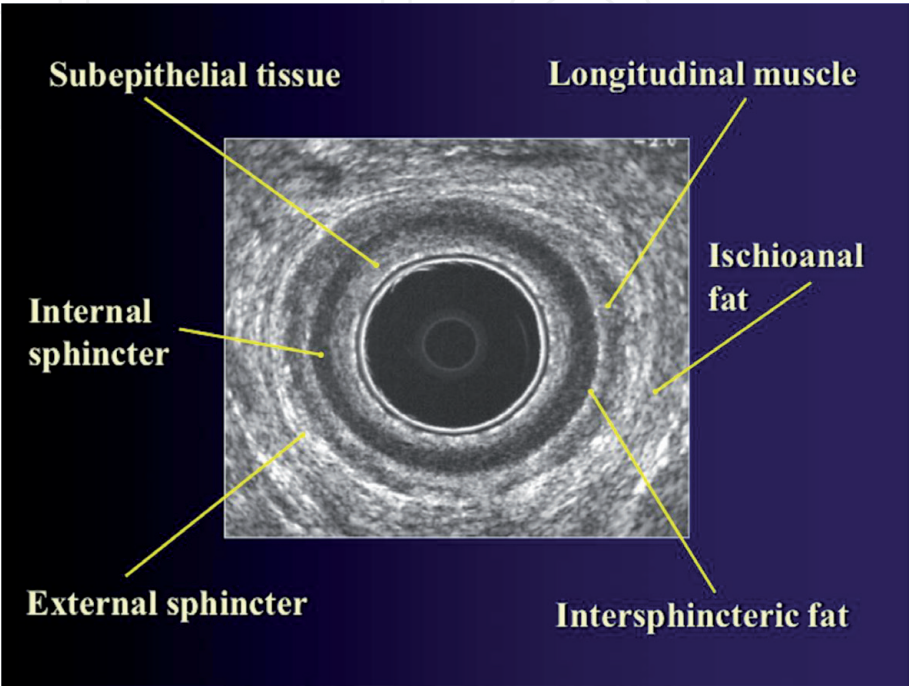
**Figure 1.**  
*Anorectal manometry catheter. The multiple respective channels can be seen.*



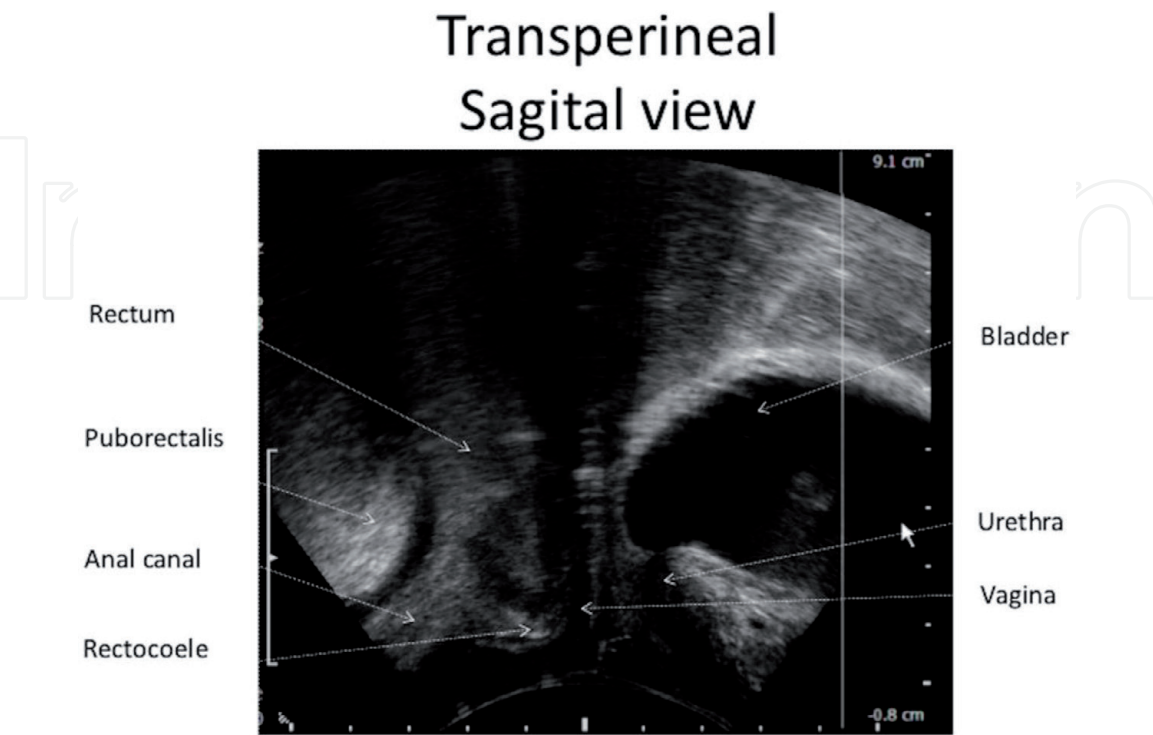
**Figure 2.**  
*Anal endosonography equipment. The ultrasound can be seen in operation at the left, while the ultrasound probe can be seen on the right.*



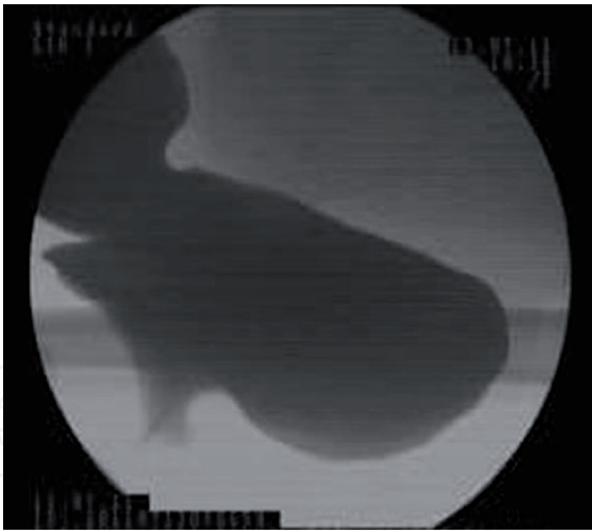
Anorectal ultrasonography is the most useful test not only to estimate the anatomy of the anal sphincters but also to estimate possible enterocele or rectocele, using the proper probe for perineal view (**Figures 2–4**). It is a cheap, painless, and very informative exam and provides the information needed by a colorectal surgeon. In expert hands, it can be the only exam necessary to evaluate obstructive defecation syndrome. Although most of the information taken from a proctogram can also be deciphered from a good total anorectal and pelvic ultrasound, experts in most centers prefer a combination of both for the best assessment of the patient [16] (**Figures 5 and 6**).



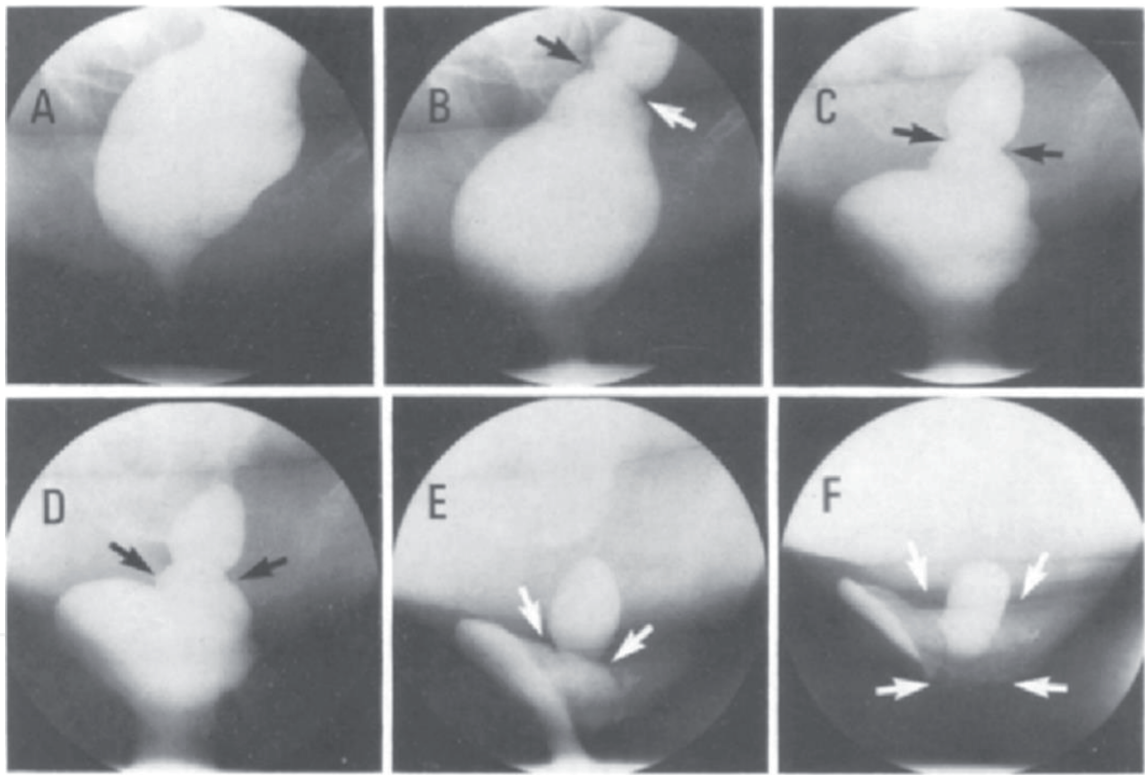
**Figure 3.**  
*Anal endoultrasonogram of a normal person. The distinct structures of the region can be seen and labeled.*



**Figure 4.**  
*Sagittal view of a transperineal ultrasonogram of a patient with rectocele, which can be discerned between the vagina and the anal canal.*



**Figure 5.**  
*Proctogram of a rectocele.*



**Figure 6.**  
*Proctographic imaging of a case of anorectal intussusception.*

## 6. Pathophysiology

As mentioned above, obstructive defecation syndrome has various clinical manifestations, but the predominant symptom is the sense of incomplete evacuation. Etiologic factors can be classified as either functional or anatomical. It is of high importance to clarify that, for patients with concomitant constipation from ODS and incontinence, soiling is coming as a result. Overlapping and mixed pathophysiology is very common. However, the most commonly accepted pathophysiological mechanisms are (a) overflow incontinence due to fecal impaction mainly in elderly people, (b) post defecation uncontrolled soiling or hard stool leakage after evacuation due to retained material, as in rectoceles, and (c) perineal denervation, pelvic

floor weakness or dyssynergy which cause fecal incontinence. All of the above mechanisms are the underlying cause of obstruction defecation syndrome and contribute to fecal incontinence.

### **6.1 Overflow incontinence: fecal impaction**

Incontinence in elder population is not uncommon. In geriatric population and particularly in institutionalized elders, prevalence of incontinence can reach 50%. Fecal impaction is defined as the prolonged retention of fecal material in the rectum. This can be a result of incomplete evacuation such as in ODS pattern, but also can happen from other causes such as immobility, hypothyroidism, neurologic disorders, dehydration, and dementia. Pharmaceutical agents such as opioids or antidepressants cause retard colonic contraction and may lead to fecal impaction. Rectum physiologically acts a fecal reservoir. Dilatation of rectal wall commences the autonomic nerve coordination for the pelvic relaxation and rectal wall contraction. In elder people, rectal sensitivity may be impaired due to chronic distention and denervation. These patients have reduced rectal sensation, pudendal neuropathy caused of chronic straining, or even concurrent reduced anal resting tone. However, when a large ball of fecal material remains for a while, secretion of mucus from rectal mucosa will cause significant soiling. Furthermore, uncontrolled contractions will end to true anal incontinence, and symptoms may be exacerbated after laxative use [17].

A similar clinical manifestation of overflow incontinence due to prolonged impaction can be seen not only in geriatric population but also in middle aged adults, although less commonly. Rectal hyposensitivity is of great importance to that type of incontinence. This is probably the underlying cause for the excessive distention of rectal wall and the development of megarectum. As a consequence, impaired rectal wall sensitivity contributes to excess rectal wall stretching and distention caused due to retained stool. As a result, paradoxical rectal contractions and overflow incontinence can happen to adult patients. In an interesting audit study from Gladman et al., rectal hyposensitivity was found in 27% of patients with coexisting constipation and incontinence [18]. On the basis of functional outlet obstruction, a few patients also have short segment Hirschsprung disease, leading to impaired rectoanal inhibitory reflex. A full rectal wall biopsy confirms the diagnosis. This disease is characterized by the absence of ganglion cells within the myenteric plexus. Rectal wall remains nonfunctional in terms of contractility, which ultimately leads to fecal retention. Surgery of the rectal wall is unusual because the same physiologic deformity usually occurs at the colonic wall. Therefore, subtotal or total colectomy is the most common surgical practice for these patients [19].

### **6.2 Incontinence due to rectal evacuatory disorders**

As mentioned above, the most common underlying pathology of obstructive defecation syndrome is mechanical outlet obstruction. Different anatomic abnormalities can cause disruption of the normal evacuatory root. Internal rectal intussusception is probably the most common underlying pathology. It represents invagination of distal sigmoid or upper rectum to mid rectum. Traditionally, internal intussusception is considered as a precursor of true full thickness rectal prolapse and a predominant cause of ODS. It is worth to mention that intussusception is quite the common finding in proctograms. Only a minor percentage of these patients requires surgical intervention and, interestingly, many of them do not complain for clinical symptoms of ODS. Rectal prolapse occurs in only 2% of the patients with internal intussusceptions [20]. Patients suffering from years from



intussusception or low take off rectal prolapse exhibit extreme straining during defecation. Eventually, this causes perineal dyssynergia from pudendal chronic neuropathy. Biofeedback remains the mainstay of treatment for this condition. The patient learns the correct technique for prompt defecation after coordination of pelvic floor muscles, under electrode monitoring [21].

Fecal incontinence in early stages of ODS is more seepage type and does not present as major episodes of leakage. It comes as an unintentional loss of small amount of liquid stool or mucus after the early hours post defecation. Patients describe a feeling of incomplete evacuation, the urge for repeated visits to toilet, incontinence or pruritus ani. Symptoms usually improve after courses of biofeedback [21]. For those who undergo surgical intervention for correction of rectoanal intussusceptions or rectocele, symptoms are also improved [22].

Apart from intussusceptions, patients with rectoceles and ODS may also have subsequent incontinence. Rectoceles can easily be detected in proctograms. These are always anterior and found only in female patients as a result of anterior herniation of rectum through the loose rectovaginal septum, causing bulging of posterior vaginal wall. Again, as in intussusception, rectocele may represent only a radiological finding in asymptomatic women. Biofeedback remains the cornerstone of the treatment algorithm. Small rectoceles usually do not require surgical intervention. Incontinence symptoms improve postoperatively in patients who are submitted to operation. Laparoscopic ventral mesh rectopexy has become the treatment of choice for fit female patients, mainly in Europe [23]. Perineal or transvaginal rectocele repair with or without levatorplasty is another option, with promising results in experienced centers [24]. Stapled transanal rectal resection procedure (STARR/TRANSTARR) has gained a wide acceptance among colorectal surgeons. The concept is the removal of the redundant anterior or circumferential rectal mucosa, allowing a straightened outlet [25, 26].

Although surgery for ODS has gained great acceptance between colorectal surgeons, it is crucial to understand that it is needed only for correction of major anatomic abnormalities. Furthermore, surgery for ODS may aggravate any symptoms of urgency, as well as cause subsequent incontinence, thus it is not without pitfalls or risks. Among the different techniques available for fixing rectoceles or intussusception, laparoscopic ventral mesh rectopexy seems to have the less risk of postoperative incontinence. However, it requires expert knowledge of the technique, its results are not widely reproducible, and mesh complications may lead surgeons to abandon the technique in the future [27, 28]. The Delorme and the Internal Delorme procedures have been widely used for rectal prolapse and for low take off prolapse or intussusception respectively, as causes of ODS symptoms. Internal mucosa excision and plication completely restores the rectal cavity, reducing, however, in the process, the rectal capacity and compliance. The resulting rectal hyposensitivity and abnormal distention contribute to urge incontinence. For patients with preoperative anal incontinence and rectal prolapse Delorme or Internal Delorme procedures should be avoided [29, 30]. Regarding the STARR technique, which is widely used to correct both rectocele and intussusception, criticism has been raised due to the lack of long-term results, as well as the worsening of urge incontinence in some patients. An Italian study on patients who underwent STARR reported increased predominantly incidence of urge type of incontinence. Maximum tolerated rectal volume capacity was impaired according to anorectal manometry [31]. The European Stapled Transanal Rectal Resection Registry reports urgency in about 20% of operated patients. Impaired rectal compliance and even minimal sphincter damage from the stapler can easily transform defecatory urgency to urge fecal incontinence [32].

### **6.3 Incontinence due to dyssynergia and pelvic floor weakness**

Dyssynergia, by all means, is a syndrome of different specific origins, with symptoms that can be produced by lack of coordination or malfunction of different pelvic muscles. Thus, pelvic dyssynergia generally results from paradoxical muscle spasm and failure of puborectalis sling to relax during defecation. As a consequence, functional outlet obstruction is not unusual. Rectal masses should be excluded with flexible sigmoidoscopy at the first instance and anatomic abnormalities as intussusception and rectoceles should be excluded—usually with a proctogram. Defecography is also crucial to recognize anismus patients and paradoxical spasm of the puborectalis muscle. Anal manometry usually shows increased anal rest pressures, failure of relaxation, and increased puborectalis activity during straining [16]. In proctograms, anorectal angle changes less than 15°, and the perineum fails to relax and to descend during defecation. There are different studies that show the connection between dyssynergia and fecal seepage or soiling. In the study of Rao SS et al., in 25 patients who reported seepage, residual anal pressure was raised and 29% were unable to expel a rectal balloon [33]. As mentioned above, rectal sensation is crucial, thus rectal hyposensitivity, which is common in functional obstruction syndrome, results in impaired rectoanal coordination and pelvic muscles relaxation.

Biofeedback is the first step in the treatment of patient with ODS and is mainly useful for patients with pelvic floor dyssynergy. It is a sophisticated approach using behavioral and physiologic methods. Biofeedback uses anorectal manometers and screen in front of the patient, where changes in attempts for defecation and correction of the technique can be visible for the patient, recognizing different patterns of muscular activity. The majority of patients report improved outcomes after repeated courses of biofeedback. For patients with rectal intussusception and small rectoceles, this is the treatment of choice [21]. Botulinum toxin injection is another option for anismus patients. Injection of 60–100 U on the puborectalis sling showed prominent results in patients with pelvic dyssynergy, although the lack of long-term data and the need for repeated injections [34].

The role of SNS in obstructive defecation has been debatable. Most of the studies for SNS have been done for patients with slow transit constipation or incontinence, and few data are available for ODS. Some of these patients report improvement of straining, but still more studies are required [35].

Pelvic floor weakness and pudendal denervation due to chronic straining or repeated perineum stretching had been traditionally considered as the principal mechanism for fecal incontinence. Prolonged straining, descent of perineum, and prolapse cause not only anal sphincter disruption but also chronic pudendal neuropathy. As a result, anal pressures are reduced and this predisposes to incontinence [36]. Pudendal neuropathy needs time to be established, but time is crucial because once it is established, the malfunction becomes permanent. In a longitudinal study of patients with perineal descending syndrome, more than 50% became incontinent in a second follow up 5 years after initial assessment [37]. In general, pelvic floor weakness, with all clinical presentations (rectocele, descending perineum, prolapsed) and organ prolapse predispose to evacuatory disorders and denervation, causing finally fecal incontinence.

## **7. Conclusions**

Fecal incontinence is a quite common and underestimated clinical syndrome, which is not exclusive to aged patients. Great clinical expertise is needed for the

assessment of the patients. Obstructive defecation syndrome has been nowadays accepted as one of the underlying pathologies that ultimately lead to fecal incontinence. Clinical assessment, defecatory proctogram, anorectal manometry evaluation, and endoanal ultrasound are the tools needed for a full discussion on a pelvic floor MDT. Conservative management with biofeedback is a key to the treatment, and of great benefit to the patients. Surgery for ODS should be offered only to patients who fail biofeedback or have major anatomic abnormalities. The decision of the type of surgery that will be suggested to the patient must be decided after a great deal of thought, because different procedures for ODS may lead to fecal incontinence as well.

### **Acknowledgements**

The author would like to acknowledge the work of Dr. Spyridon Smparounis in proofreading and correcting the drafts of this manuscript.

### **Author details**

Dimitrios Linardoutsos  
Advanced Laparoscopic Department of Surgery, Metropolitan General Hospital,  
Cholargos, Athens, Greece

\*Address all correspondence to: [dlinardoutsos@gmail.com](mailto:dlinardoutsos@gmail.com)

### **IntechOpen**

© 2019 The Author(s). Licensee IntechOpen. This chapter is distributed under the terms of the Creative Commons Attribution License (<http://creativecommons.org/licenses/by/3.0>), which permits unrestricted use, distribution, and reproduction in any medium, provided the original work is properly cited. 

## References

- [1] Fritsch H et al. Clinical anatomy of the pelvic floor. *Advances in Anatomy, Embryology, and Cell Biology*. 2004;**175**:1-64
- [2] Vrees MD, Weiss EG. The evaluation of constipation. *Clinics in Colon and Rectal Surgery*. 2005;**18**(2):65-75
- [3] Barrett J, Kiff E, et al. Anorectal function in the elderly. In: *Coloproctology and the Pelvic Floor*. 2nd ed. Oxford: Butterworth-Heinemann Ltd; 1992. pp. 470-476
- [4] Chatoor DR, Taylor SJ, et al. Fecal incontinence. *The British Journal of Surgery*. 2007;**94**(2):134-144
- [5] Snooks SJ, Barnes PR, et al. Damage to the innervation of the pelvic floor musculature in chronic constipation. *Gastroenterology*. 1985;**89**(5):977-981
- [6] Wald A. Clinical practise. Fecal incontinence in adults. *The New England Journal of Medicine*. 2007;**356**(16):1648-1655
- [7] Whitehead WE, Borrud L, et al. Fecal incontinence in US adults: Epidemiology and risk factors. *Gastroenterology*. 2009;**137**(2):512-517
- [8] Scott SM, Luniss PJ, Ratto C, Doglietto GB, editors. Risk factors in faecal incontinence. In: *Faecal Incontinence. Diagnosis and Treatment*. London UK: Springer-Verlag London Ltd; 2007. pp. 43-66
- [9] Damon H, Guye O, et al. Prevalence of anal incontinence in adults and impact and impact on quality of life. *Gastroentérologie Clinique et Biologique*. 2006;**30**(1):37-43
- [10] Bharucha AE, Zinsmeister AR, et al. Bowel disturbances are the most important risk factors for late onset fecal incontinence: A population-based case-control study in women. *Gastroenterology*; **139**(5):Q1559-Q1566
- [11] Bener A, Saleh N, et al. Prevalence and determinants of fecal incontinence in premenopausal women in Arabian community. *Climacteric*. 2008;**11**(5):429-435
- [12] Rex DK, Lappas JC. Combined anorectal manometry and defecography in 50 consecutive adults with fecal incontinence. *Diseases of the Colon and Rectum*. 1992;**35**(11):1040-1045
- [13] Harewood GC, Coulie B, Camilleri M, Rath-Harvey D, et al. Descending perineum syndrome: Audit of clinical and laboratory features and outcome of pelvic floor retraining. *The American Journal of Gastroenterology*. 1999;**94**(1):126-130
- [14] Mohamed SD. Co-existence of constipation and faecal incontinence: A greatly underappreciated clinical problem. *Neurogastroenterology and Motility*. 2010;**22**:37
- [15] Burgell RE. Fecal incontinence in men: Coexistent constipation and impact of real hyposensitivity. *Gastroenterology*. 2010;**138**:542
- [16] Videlock EJ, Lembo A, Cremonini F. Diagnostic testing for dyssynergic defecation in chronic constipation: Meta-analysis. *Neurogastroenterology and Motility*. 2013;**25**(6):509-520
- [17] Cooper ZR, Rose S. Fecal incontinence: A clinical approach. *Mount Sinai Journal of Medicine*. 2000;**67**(2):96-105
- [18] Gladman MA, Luniss PJ, et al. Rectal hyposensitivity. *The American Journal of Gastroenterology*. 2006;**101**(5):1140-1151
- [19] Parisi MA. Hirshprung disease overview. *Current Opinion in Pediatrics*. 2000;**12**(6):610-617



- [20] Siproudhis L, Pigot F, Godeberge P, Damon H, Soudan D, Bigard MA. Defecation disorders: A French population survey. *Diseases of the Colon and Rectum*. 2006;**49**(2):219-227
- [21] Rao SS, Valestin J, Brown CK, Zimmerman B, Schulze K. Long-term efficacy of biofeedback therapy for dyssynergic defecation: Randomized controlled trial. *The American Journal of Gastroenterology*. 2010;**105**(4):890-896
- [22] Mercer-Jones MA, D'Hoore A, Dixon AR, Lehur P, Lindsey I, Mellgren A, et al. Consensus on ventral rectopexy: Report of a panel of experts. *Colorectal Disease*. 2014;**16**(2):82-88
- [23] D'Hoore A, Penninckx F. Laparoscopic ventral recto(colpo)pexy for rectal prolapse: Surgical technique and outcome for 109 patients. *Surgical Endoscopy*. 2006;**20**(12):1919-1923
- [24] Lehur PA, Stuto A, Fantoli M, Villani RD, Queralto M, Lazorthes F, et al. ODS II Study Group. Outcomes of stapled transanal rectal resection vs. biofeedback for the treatment of outlet obstruction associated with rectal intussusception and rectocele: A multicenter, randomized, controlled trial. *Diseases of the Colon and Rectum*. 2008;**51**(11):1611-1618
- [25] Van Geluwe B, Stuto A, Da Pozzo F, Fieuws S, Meurette G, Lehur PA, et al. Relief of obstructed defecation syndrome after stapled transanal rectal resection (STARR): A meta-analysis. *Acta Chirurgica Belgica*. 2014;**114**(3):189-197
- [26] Ribaric G, D'Hoore A, Schiffhorst G, Hempel E. TRANSTAR Registry Study Group. STARR with CONTOUR® TRANSTAR™ device for obstructed defecation syndrome: One-year real-world outcomes of the European TRANSTAR registry. *International Journal of Colorectal Disease*. 2014;**29**(5):611-622
- [27] Ahmad NZ, Stefan S, et al. Laparoscopic ventral mesh rectopexy: Functional outcomes after surgery. *Journal of Surgery*. 2018;**4**(4):e205-e211
- [28] Borie F, Coste T, et al. Incidence and surgical treatment of synthetic mesh-related infectious complications after laparoscopic ventral rectopexy. *Techniques in Coloproctology*. 2016;**20**(11):759-765
- [29] Emile SH, Elbanna H, et al. Laparoscopic ventral mesh rectopexy vs Delorme's operation in management of complete rectal prolapse: A prospective randomised study. *Colorectal Disease*. 2017;**19**:50-57
- [30] Cavazzoni E, Rosati E, et al. Simultaneous Delorme's procedure and inter-sphincteric prosthetic implant for the treatment of rectal prolapse and faecal incontinence: Preliminary experience and literature review. *International Journal of Surgery*. 2015;**14**:45-48
- [31] Pucciani F. Post-surgical fecal incontinence. *Updates in Surgery*. 2018;**70**(4):477-484
- [32] Jayne DG, Schwander O, et al. Stapled transanal rectal resection for obstructed defecation syndrome: One-year results of the european STARR registry. *Diseases of the Colon and Rectum*. 2012;**55**(12):1205-1212
- [33] Rao SS, Ozturk R, et al. Investigation of the pathophysiology of fecal seepage. *The American Journal of Gastroenterology*. 2004;**99**(11):2204-2209
- [34] Hompes R, Harmston C, et al. Excellent response rate of anismus to botulinum toxin if rectal prolapsed misdiagnosed as anismus (pseudoanismus) is excluded. *Colorectal Disease*. 2012;**14**(2):224-230

[35] Ganio E, Masin A, et al. Short term sacral nerve stimulation for functional anorectal and urinary disturbances: Results in 40 patients: Evaluation of a new option for anorectal functional disorders. *Diseases of the Colon and Rectum*. 2001;**44**(9):1261-1267

[36] Kiff ES, Barnes PR, et al. Evidence of pudendal neuropathy in patients with perineal descent and chronic straining at stool. *Gut*. 1984;**25**(11):1279-1282

[37] Berkelmans I, Heresbach D, et al. Perineal descent at defecography in women with straining at stool: A lack of specificity or predictive value for future anal incontinence? *European Journal of Gastroenterology & Hepatology*. 1995;**7**(1):75-79