

# We are IntechOpen, the world's leading publisher of Open Access books Built by scientists, for scientists

6,900

Open access books available

186,000

International authors and editors

200M

Downloads

Our authors are among the

154

Countries delivered to

TOP 1%

most cited scientists

12.2%

Contributors from top 500 universities



WEB OF SCIENCE™

Selection of our books indexed in the Book Citation Index  
in Web of Science™ Core Collection (BKCI)

Interested in publishing with us?  
Contact [book.department@intechopen.com](mailto:book.department@intechopen.com)

Numbers displayed above are based on latest data collected.  
For more information visit [www.intechopen.com](http://www.intechopen.com)



# Extranodal T/NK Lymphomas

*Silvana Novelli*

## Abstract

Extranodal T/NK lymphomas comprise infrequent and highly aggressive entities such as extranodal NK/T-cell lymphoma nasal type, enteropathy-associated T-cell lymphoma, monomorphic epitheliotropic intestinal T-cell lymphoma, intestinal T-cell lymphoma NOS, and hepatosplenic T-cell lymphoma. Except for NK/T lymphoma nasal type, there is scarce evidence to support a specific therapeutic regimen in first line and relapse. As the only potentially curative therapy is allogeneic hematopoietic stem cell transplantation, it should be assessed in relapsing/refractory NK/T lymphoma nasal type and in the first line after remission in the other extranodal NK/T lymphomas.

**Keywords:** extranodal lymphoma, NK/T-cell lymphoma, NK lymphoma, hepatosplenic

## 1. Introduction

In this chapter, the majority of extranodal T/NK lymphomas will be discussed proportionally to the amount of available evidence and its clinical relevance. The 2016 WHO classification [1] includes the following entities: extranodal NK/T-cell lymphoma nasal type, enteropathy-associated T-cell lymphoma, monomorphic epitheliotropic intestinal T-cell lymphoma, intestinal T-cell lymphoma NOS, and hepatosplenic T-cell lymphoma. In general, these are very infrequent and aggressive lymphomas, being the most prevalent the extranodal NK/T-cell lymphoma, nasal type. The current classification separates enteropathy-associated T-cell lymphoma from monomorphic epitheliotropic intestinal T-cell lymphoma in two different entities; in this way, intestinal T-cell lymphoma NOS remains a category to place unclassifiable histologies. Recent advances in gene expression profiling have allowed identify genes and proteins with potential role in pathogenesis. Collaboration between different centers is showing promising results that will surely modify and improve current treatments and prognosis. It will also help to increase the evidence in the new classification categories.

## 2. Extranodal NK/T-cell lymphoma, nasal type (ENKL)

### 2.1 General features

Natural killer (NK) neoplasias are divided into extranodal NK/T, nasal type, and NK aggressive leukemia. The “nasal type” distinction is explained because there is a predominant affection of nasal zone, nasopharynx, and upper respiratory airways (60–90% of cases). The “extra-nasal” type also exists but is infrequent; it affects non-nasal areas such as the skin, testicles, intestines, and muscles [2].

Several works have tried to identify biologic differences between both clinical manifestations but it has not been possible. The “extra-nasal” variant has a worse outcome; patients frequently present with B symptoms, advanced stages, hemophagocytosis, and cytopenias.

Unlike Asia and Latin America, ENKL is infrequent in our media representing approximately 2% of non-Hodgkin lymphomas [3].

## 2.2 Etiology

Epstein-Barr virus (EBV) is an important feature of ENKL [4]. More than 90% of reported cases were positive for EBNA-1 and EBER-1. EBV is present in an episomal form not integrated into the host DNA, with type II latency [5, 6].

## 2.3 Diagnosis

At the morphological level, angiocentric and angio-invasive infiltrates composed of small-medium-sized atypical lymphocytes with irregular nuclei and immunoblasts are evident. There is a variable infiltration of plasma cells and, to a lesser extent, of eosinophils and histiocytes. The presence of extensive necrosis is frequent.

By immunohistochemistry, the tumor NK cells can have two lines of origin:

NK line (65–75% of cases): CD2 (+), CD3-ε (+) cytoplasmic, CD56 (+/-), CD94 (+), cytotoxic markers (TIA, GZM-B, perforin) (+), and TCR-β (BF1) (-).

True T-line (25–35% of cases): CD2 (+), CD3-ε (+), CD5 (+), CD8 (+/-), TCR-β (BF1) (+), CD56 (-/+), and cytotoxic markers (+).

EBV is detected in almost all cases by in situ hybridization (EBER) and by Southern blot. The latent EBV membrane protein has a variable expression, so it is not advisable to detect the virus [7].

Early chromosomal examinations recognized del(6)(q21q25) as a repetitive chromosomal anomaly in ENKL. In view of investigations of 6q, including gene expression profiling (GEP), PRDM1, FOXO3, and PTPRK were recognized as putative tumor suppressor genes. A high expression of genes of cytotoxic molecules such as granzyme H and deregulation of the NF-κB, AKT, and JAK-STAT3 pathways were also present in ENKL. Half of the patients have mutations in *FAS* and <50% in *TP53*. *DDX3X* and *BCL6* are also mutated; the former was more frequently mutated in men and was associated with poor survival [8].

## 2.4 Staging and prognosis

Because the prognosis is different between the “nasal” and the “extranasal” variants, techniques to detect occult disease become clinically important.

It is advisable to use PET/CT since it has shown greater sensitivity. In those cases where there is evidence of involvement of the central nervous system, it is necessary to consider complementing the study with magnetic resonance imaging (MRI) [9, 10].

Bone marrow biopsy is part of staging and cannot yet be replaced by the extensive use of PET/CT in this entity [11].

The staging should be performed according to Ann Arbor since most clinical trials have established it that way. However, TNM staging is also widely used since it offers the advantage of better assessing tumor size and infiltration of adjacent organs and tissues of the localized stage [12].

The ENKL prognostic index includes both stage and other variables. This index is fundamental for decision-making [13].

The ENKL index punctuates the presence of “B” symptoms, Ann Arbor stage ≥III, LDH ≥1 × upper normal limit, and regional lymph nodes (N1-N3, not M1) involvement

Risk group	Number of factors	% 5-year OS	RR of death
Group 1	0	81	1
Group 2	1	64	1.8
Group 3	2	34	4.1
Group 4	3–4	7	13.6

OS, overall survival; RR, relative risk.

**Table 1.**  
*Survival and relative risk of death.*

according to the TNM staging system. Every point increases the relative of death and impairs survival (see **Table 1**).

The viral quantification of EBV is useful to assess the tumor burden. Negative loads have a better prognosis than cases with low EBV load (<1000 copies/ml in plasma or <100 copies/mcg of mononuclear cell DNA) and that of high load. It is also useful to monitor the response to therapy. Therefore, it should be done whenever possible [14, 15].

2.5 Treatment

The treatment is planned according to the stage and the risk.

In patients with stages I–II and low risk, radiotherapy (≥54 Gy) is the best option. It has not been observed that adding chemotherapy improves the prognosis [2, 16, 17].

If we focus on cases with stages I–II, but intermediate risk and high risk, it has been shown that the best option is the combination of chemotherapy and radiotherapy.

In the JCOG0211 study, radiotherapy (50 Gy) and three cycles of dexamethasone, etoposide, ifosfamide, and carboplatin (DeVIC) were administered. The overall survival (OS) at 2 years was 78% (95% CI, 57–89%). It was compared with a historical control of patients treated only with radiotherapy (OS 45%). The overall response rate was 81% (77% complete response, CR) [18].

Another study showed similar results. Radiotherapy (40–52.8 Gy) and cisplatin 30 mg/m<sup>2</sup> weekly followed by three cycles of VIPD (etoposide 100 mg/m<sup>2</sup> days 1–3, ifosfamide 1200 mg/m<sup>2</sup> days 1–3, cisplatin 33 mg/m<sup>2</sup> days 1–3, and dexamethasone 40 mg days 1–4). The progression-free survival (PFS) and the OS estimated at 3 years were 85 and 86%, respectively [19].

ENKL is associated with a high expression of P glycoprotein that confers resistance to most anthracycline-based regimens. For this reason, non-dependent glycoprotein-P schemes have been designed.

The regimens that have demonstrated greater efficacy are based on L-asparaginase. However, they are associated with a high toxicity.

Also for stages IE–IIE (all risk groups), the DICE–L-asparaginase chemotherapy with radiotherapy (45 Gy) after four cycles vs. radiotherapy alone has been tested. The CR rate was higher for patients in the sequential radiotherapy group (90.9%) than in the radiotherapy group (77.8%; *p* = 0.124). PFS and OS at 5 years after diagnosis were significantly higher for patients in the chemo-radiotherapy group (PFS: 89%; OS: 82%) than in the radiotherapy group (PFS: 49%, *p* < 0.001; OS: 49%, *p* < 0.001) [20].

In advanced stages, the treatment must take into account the functional status of the patient.

If the patient’s general condition allows it (ECOG 0–2) and the patient is a candidate for an autologous hematopoietic stem cell transplant (ASCT), the first-line therapy will be the SMILE scheme followed by TASP (dexamethasone: 40 mg EV or oral, days

2–4; methotrexate: 2000 mg/m<sup>2</sup> EV, day 1; ifosfamide: 1500 mg/m<sup>2</sup> EV, days 2–4; *E. coli* L-asparaginase: 6000 U/m<sup>2</sup> EV, days 8, 10, 12, 14, 16, 18, and 20; etoposide: 100 mg/m<sup>2</sup> EV, days 2–4).

The overall response rate (ORR) and the complete responses after 2 cycles were 79% (90% CI, 65–89%) and 45%, respectively. Approximately half of the patients received an ASCT.

However, in those in the first line, the ORR was higher (86%), with CR of 69%. These responses were maintained in 90% of patients during follow-up. The OS at 1 year was 55% (95% CI, 38–69%). On the other hand, grade 4 neutropenia occurred in 92% of the cases [21, 22].

Another option for this high-risk group is the L-asparaginase, methotrexate, and dexamethasone (AspaMetDex) chemotherapy. In a phase 2 trial, it reported a CR rate of 61% after three cycles. Further results are needed to confirm the efficacy of this regimen [23].

In those patients with poor general condition and/or those who do not want to receive an ASCT, the management must be palliative or investigational since the prognosis is unfortunate.

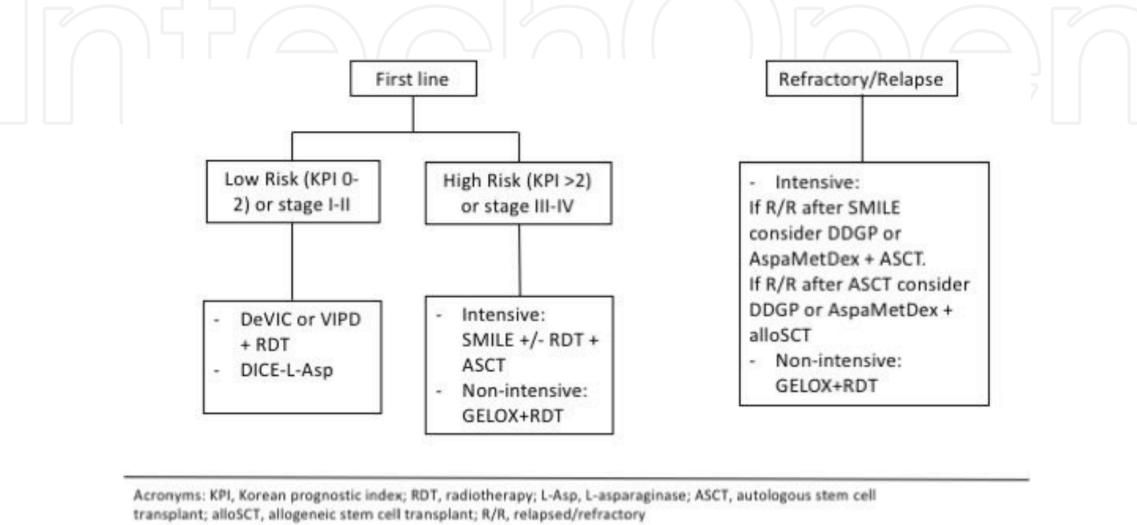
However, there is evidence that the “sandwich” scheme of GELOX (gem-citabine, oxaliplatin, and L-asparaginase) and radiotherapy after at least two cycles of GELOX offers good results and acceptable toxicities in IE–IIE stages. The ORR was 96.3%, with CR of 74.1%. The OS and PFS at 2 years were both 86% [24, 25].

In relapse, if patients are tributary to treatment and have not received the SMILE scheme, this will become the second line based on the results described above. However, if the patient has been refractory to the SMILE scheme, the alternatives are also investigational and with scarce evidence.

There is a retrospective study with the GELOX scheme. The ORR was 40% (20% CR). Those who achieved CR (two received ASCT and maintenance with L-asparaginase) were disease free for 7 months [26].

Regarding ASCT and allogeneic stem cell transplantation (alloSCT), there is less evidence of its role in high risk and/or advanced stage ENKL.

There is a prospective study in the pre-L-asparaginase era which included 16 ENKL cases. Nine cases received an ASCT in first or second CR and the remaining in progression. The OS at 2 years was 71.3% (first to second CR) and 25.8%, respectively [27].



**Figure 1.** Proposed treatments for extranodal NK/T-cell lymphoma, nasal type NK/T. KPI, Korean prognostic index; RDT, radiotherapy; L-Asp, L-asparaginase; ASCT, autologous stem cell transplant; alloSCT, allogeneic stem cell transplant; R/R, relapsed/refractory.



A registry study that includes 18 cases of patients who received an alloSCT demonstrated a PFS and OS at 5 years of 51 and 57%, respectively. Therefore, it becomes an alternative in very selected patients [28] (**Figure 1**).

New therapies, but not approved yet, are showing promising results. The most important results are those results obtained from the use of check point inhibitors (nivolumab and pembrolizumab). ORR oscillated between 57 and 100% but phase II trials are missing to confirm these results [29–31].

### 3. Enteropathy-associated T-cell lymphoma (EATL)

#### 3.1 General features

The EATL currently refers exclusively to previous type I EATL and is clearly associated with celiac disease (CD) and occurs more frequently in patients of Northern European origin. Dermatitis herpetiformis and hyposplenism may be associated. Patients who are diagnosed at a higher age of celiac disease have a higher risk of having an LTAE and proper management with a gluten-free diet effectively prevents its development [32, 33].

The most affected regions are the jejunum or ileum and are usually diagnosed after a resection for an acute abdomen. Patients have a rapid deterioration of their general condition despite strictly following the diet.

Refractory celiac disease (RCD) is the precursor lesion. It is defined by histological changes associated with enteropathy in cases with strict diet for >12 months or severe and persistent symptoms that require a clinical intervention regardless of the duration of the strict diet. There is a sub-classification, RCD type I, if the intraepithelial lymphocytes show a normal phenotype and constitute a polyclonal population, and RCD type II, if the intraepithelial lymphocytes immunophenotype is aberrant and clonal products are detected on TCR gene rearrangement analysis [34].

Loss of heterozygosity at 9p21, involving CDKN2A/B locus, was detected in more than 50% of cases with EATL. Loss of 17p12-p13.2 (TP53) was reported in 23%, but a high frequency of aberrant nuclear p53 expression (75%) suggested alternate means of deregulation of this tumor suppressor. Surprisingly, there are more new findings in terms of etiology in the monomorphic epitheliotropic intestinal T-cell lymphoma, and this will be further revised.

#### 3.2 Diagnosis

Endoscopic findings show one or multiple ulcerated intestinal masses or large exophytic masses. At the serological level, tissue anti-transglutaminase IgA and anti-endomysial IgA are the most sensitive and specific tests. The typing of HLA-DQ in search of the alleles that predispose to CD (DQ2/DQ8) is part of the diagnosis [35].

Histologically, EATL is characterized by a non-monomorphic infiltrate of cells with CD3 (+), CD7 (+), CD103 (+), cytotoxic proteins (+) CD8 (–/+), TCR-β (+/–), CD4 (–), CD5 (–), CD56 (–), and CD30 focally (+) in a subset of cases. Adjacent intraepithelial lymphocytes also have an aberrant immunophenotype CD3 (+), CD5 (–), CD8 (–), CD4 (–), and cytotoxic proteins (–).

At the cytogenetic level, gains of 1q and 5q are observed [36].

#### 3.3 Staging and prognosis

Staging will be carried out with the Lugano system [37] (see **Table 2**) Diagnostic tests include a CT scan, an endoscopic study, and a bone marrow biopsy. The index

Stage I	Tumor confined to GI tract. Single primary site or multiple, non-contiguous lesions.	
Stage II	Tumor extending into abdomen from primary GI site.	Nodal involvement II <sub>1</sub> local (paragastric in cases of gastric lymphoma and para-intestinal for intestinal lymphoma) II <sub>2</sub> distant (mesenteric in the case of an intestinal primary, otherwise; para-aortic para-caval, pelvic, inguinal).
Stage IIE	Penetration of serosa to involve adjacent organs or tissues (enumerate actual site of involvement, e.g., IIE <sub>pancreas</sub> , IIE <sub>large intestine</sub> ).	
Where there is both nodal involvement and penetration to involve adjacent organs, stage should be denoted using both a subscript (1 or 2) and E, e.g., II <sub>1</sub> E <sub>pancreas</sub> .		
Stage IV	Disseminated extranodal involvement, or, a GI tract lesion with supra-diaphragmatic nodal involvement.	

**Table 2.**  
*Lugano staging system for gastrointestinal tract lymphoma.*

that best defined prognosis of the EATL is the prognostic index used for peripheral T lymphomas (IPI) [38].

3.4 Treatment

Because at the time of diagnosis the patient is usually in advanced stages and have a poor nutritional status, therapeutic success is scarce.

Surgery plays an important role in reducing tumor burden and decreasing perforations or bleeding during chemotherapy, but on the other hand, it can delay the onset of chemotherapy [39, 40].

The most used chemotherapy is the CHOP scheme. Only 50% of patients will be able to receive chemotherapy, and of these, only 50% will complete it. Of those who complete chemotherapy, 35–40% will achieve a complete remission of the lymphoma. The median duration of the response is approximately 6 months [41].

In those patients who are candidates to receive an ASCT in first remission, it is advisable to do it following the EBMT recommendations [42]. In the most recent study of the EBMT registry, 31 cases of patients with EATL were identified. With a median of 46 months of follow-up, the SLP and the OS at 4 years were 54–59%, respectively [43].

Refractory patients are unlikely to benefit from a second line of chemotherapy. No superiority of any regimen has been demonstrated, so it is advisable to follow usual schemes in the center of origin [44].

4. Monomorphic epitheliotropic intestinal T-cell lymphoma (MEITL)

4.1 General features

The MEITL is the intestinal lymphoma that was previously classified as EATL type II. Because it has shown both clinical and biological differences with the EATL, it has been constituted as a new entity. It is not associated with celiac disease and has a greater incidence in Asian and Hispanic populations. Its frequency is 10–15% of intestinal T lymphomas.

## 4.2 Diagnosis

The tumor is composed of a monomorphic infiltrate. The immunophenotype is CD3 (+), CD8 (+), CD56 (+), TCR- $\beta$  (+), CD4 (–).

In exceptional cases, TCR- $\gamma\delta$  (+) has been demonstrated. Adjacent intraepithelial lymphocytes show an aberrant immunophenotype.

One way to differentiate it from other NK/T and EATL lymphomas is the positivity for the megakaryocyte-associated tyrosine kinase (MAYK).

At the cytogenetic level, gains are observed in MYC (locus 8q24) [45].

The *staging and prognosis* will be carried out in the same way as for the EATL.

## 4.3 Treatment

There are no clinical trials that allow favoring one treatment regimen over another. However, there are retrospective studies where it is confirmed that the anthracycline regimens are the most used (72%). The overall response rate was 46% (CR 38%) [46].

Recently, the potential effect of pralatrexate has been reported in a relapsed patient after anthracycline containing regimen [47] and also the addition of PEG-asparaginase to EPOCH regimen in a non-responding patient [48].

The recommendations to perform an autologous transplant in the first remission are the same as in the EATL following the EBMT experience and recommendation for T-cell neoplasia [42, 49].

# 5. Hepatosplenic T-cell lymphoma (HSTL)

## 5.1 General features

HSTL is a rare entity. It represents 1% of non-Hodgkin's lymphoma and 3% of T-lymphoma. Survival at 5 years does not exceed 7%; therefore, it has a poor clinical prognosis [50].

The etiology is unclear; however, it is postulated that chronic stimulation in patients with immune deficiencies or immune dysregulation could be important. Twenty percent of cases occur in young patients with some degree of immunosuppression (posttransplant, under treatment of leukemia). It has also been associated with the use of TNF $\alpha$  and immunomodulators in patients with inflammatory bowel disease and arthritis [51, 52].

## 5.2 Diagnosis

It is characterized by the proliferation of malignant T cells of medium size in the hepatic sinusoids, in the red pulp of the spleen, and in the bone marrow. The immunophenotype of the tumor cell is CD4–, CD8– (CD8+ alginates), CD2+, CD3+, CD42, CD52, CD76, and CD82. The TCR is usually gamma-delta, although there are cases described alpha-beta. The detected cytogenetic anomalies include isochromosome 7q and trisomy 8 [53].

Recently, the genetic basis of HSTL was described using whole exome sequencing. Some chromatin-modifying genes (INO80, SETD2, and ARID1B) were commonly mutated in HSTL; there are frequent mutations in STAT5B (31%), STAT3 (9%), and PIK3CD (9%) and less frequent events in EZH2, KRAS, and TP53. SETD2 that works as a tumor suppressor gene was the most frequently silenced gene [54]. To further determine the pathogenesis, a multicenter group performed an array-based



DNA methylation profiling and identified eight genes consistently hypermethylated (BCL11B, CXCR6, CD5, GIMAP7, SEPT9, LTA, UBAC2, and UXS1) and four genes hypomethylated (ADARB1, NR1H3, NFIC, and ST3GAL3) [55].

### 5.3 Staging and prognosis

Staging is performed with the Ann Arbor system. A specific prognostic index for this lymphoma has not been described because of its low frequency.

### 5.4 Treatment

The most used treatments are CHOP and hyper-CVAD. The cases that respond can go directly to autologous or allogeneic transplant.

Other regimens described in a retrospective study ( $n = 14$ ) have been ICE and IVAC in first line and also in rescue after CHOP. While it is a small series, the authors emphasize that the use of more intensive schemes followed by precursor transplant hematopoietic agents could improve efficacy data [56].

The relapse-free time and the OS post alloSCT are 18 and 68 months, respectively. The relapse-free time and the OS at 3 years are 42 and 56%, respectively. In this way, it is the only treatment that offers some probability of healing [57].

### Author details

Silvana Novelli<sup>1,2</sup>

<sup>1</sup> Hematology Department, Hospital de la Santa Creu i Sant Pau, Biomedical Research Institute (IIB Sant-Pau), Autonomous University of Barcelona, Spain

<sup>2</sup> José Carreras Leukemia Research Institute, Autonomous University of Barcelona, Spain

\*Address all correspondence to: [snovelli@santpau.cat](mailto:snovelli@santpau.cat)

### IntechOpen

© 2019 The Author(s). Licensee IntechOpen. This chapter is distributed under the terms of the Creative Commons Attribution License (<http://creativecommons.org/licenses/by/3.0>), which permits unrestricted use, distribution, and reproduction in any medium, provided the original work is properly cited. 

## References

- [1] Swerdlow SH. World Health Organization; International Agency for Research on Cancer. WHO Classification of Tumours of Haematopoietic and Lymphoid Tissues. Revised 4th edition. Lyon: International Agency for Research on Cancer; 2017
- [2] Au W et al. ENKL nasal or ex-nasal. *Blood*. 2016;**113**(17):3931-3938
- [3] William BM, Armitage JO. International analysis of the frequency and outcomes of NK/T-cell lymphomas. Best Practice & Research. Clinical Haematology. 2013;**26**(1):23-32
- [4] Harabuchi Y, Yamanaka N, Kataura A, Imai S, Kinoshita T, Osato T. Epstein-Barr virus in nasal T-cell lymphomas in patients with lethal midline granuloma. *Lancet*. 1990;**335**(8682):128-130
- [5] Van Gorp J et al. Epstein-Barr virus in nasal T-cell lymphomas (polymorphic reticulosis/midline malignant reticulosis) in Western China. *The Journal of Pathology*. 1994;**173**(2):81-87
- [6] Chan JK et al. Detection of Epstein-Barr viral RNA in malignant lymphomas of the upper aerodigestive tract. *The American Journal of Surgical Pathology*. 1994;**18**(9):938-946
- [7] Medeiros LJ, Miranda RN. Diagnostic Pathology. Lymph Nodes Extranodal Lymphomas. Second edition. Philadelphia, PA: Elsevier; 2018
- [8] Yamaguchi M, Oguchi M, Suzuki R. Extranodal NK/T-cell lymphoma: Updates in biology and management strategies. Best Practice & Research. Clinical Haematology. 2018;**31**(3):315-321
- [9] Kim SJ et al. Risk stratification on the basis of Deauville score on PET-CT and the presence of Epstein-Barr virus DNA after completion of primary treatment for extranodal natural killer/T-cell lymphoma, nasal type: A multicentre, retrospective analysis. *Lancet Haematology*. 2015;**2**(2):e66-e74
- [10] Guan H, Huang Y, Wen W, Xu M, Zan Q, Zhang Z. Primary central nervous system extranodal NK/T-cell lymphoma, nasal type: Case report and review of the literature. *Journal of Neuro-Oncology*. 2011;**103**(2):387-391
- [11] Barrington SF et al. Role of imaging in the staging and response assessment of lymphoma: Consensus of the International Conference on Malignant Lymphomas imaging Working Group. *Journal of Clinical Oncology*. 2014;**32**(27):3048-3058
- [12] Yan Z et al. A TNM staging system for nasal NK/T-cell lymphoma. *PLoS One*. 2015;**10**(6):1-17
- [13] Lee J et al. Extranodal natural killer T-cell lymphoma, nasal-type: A prognostic model from a retrospective multicenter study. *Journal of Clinical Oncology*. 2006;**24**(4):612-618
- [14] Au W, Pang A, Choy C, Chim C, Kwong Y, Dc W. Quantification of circulating Epstein-Barr virus (EBV) DNA in the diagnosis and monitoring of natural killer cell and EBV-positive lymphomas in immunocompetent patients. *Blood*. 2004;**104**(1):243-249
- [15] Suzuki R et al. Prospective measurement of Epstein-Barr virus-DNA in plasma and peripheral blood mononuclear cells of extranodal NK/T-cell lymphoma, nasal type. *Blood*. Dec 1 2011;**118**(23):6018-6022
- [16] Yang Y et al. Risk-adapted therapy for early-stage extranodal nasal-type NK/T-cell lymphoma: analysis from a multicenter study *Blood*. 2015;**126**:1424-1432
- [17] Juan Huang M et al. Early or up-front radiotherapy improved

survival of localized extranodal NK/T-cell lymphoma, nasal-type in the upper aerodigestive tract. *International Journal of Radiation Oncology, Biology, Physics*. 2008;**70**(1):166-174

[18] Yamaguchi M et al. Phase I/II study of concurrent chemoradiotherapy for localized nasal natural killer/T-cell lymphoma: Japan Clinical Oncology Group Study JCOG0211. *Journal of Clinical Oncology*. 2009;**27**(33):5594-5600

[19] Kim SJ et al. Phase II trial of concurrent radiation and weekly cisplatin followed by VIPD chemotherapy in newly diagnosed, stage IE to IIE, nasal, extranodal NK/T-cell lymphoma: Consortium for improving survival of lymphoma study. *Journal of Clinical Oncology*. 2009;**27**(35):6027-6032

[20] Dong L-H et al. Sequential DICE combined with L-asparaginase chemotherapy followed by involved field radiation in newly diagnosed, stage IE to IIE, nasal and extranodal NK/T-cell lymphoma. *Leukemia & Lymphoma*. 2016;**57**(7):1600-1606

[21] Yamaguchi M et al. Phase II study of SMILE chemotherapy for newly diagnosed stage IV, relapsed, or refractory extranodal natural killer (NK)/T-cell lymphoma, nasal type: The NK-cell tumor study group study. *Journal of Clinical Oncology*. 2011;**29**(33):4410-4416

[22] Kwong Y et al. SMILE for natural killer/T-cell lymphoma: Analysis of safety and efficacy from the Asia Lymphoma Study Group. *Blood*. 2012;**120**(15):2973-2981

[23] Jaccard A et al. Efficacy of L-asparaginase with methotrexate and dexamethasone (AspaMetDex regimen) in patients with refractory or relapsing extranodal NK/T-cell lymphoma, a phase 2 study. *Blood*. 2011;**117**(6):1834-1839

[24] Wang L et al. First-line combination of gemcitabine, oxaliplatin, and L-asparaginase (GELOX) followed by involved-field radiation therapy for patients with stage IE/IIE extranodal natural killer/T-cell lymphoma. *Cancer*. 2013;**119**(2):348-355

[25] Wang H et al. Comparison of gemcitabine, oxaliplatin and L-asparaginase and etoposide, vincristine, doxorubicin, cyclophosphamide and prednisone as first-line chemotherapy in patients with stage IE to IIE extranodal natural killer/T-cell lymphoma: A multicenter retrospective study. *Leukemia & Lymphoma*. 2015;**56**(4):971-977

[26] Ahn HK et al. Gemcitabine alone and/or containing chemotherapy is efficient in refractory or relapsed NK/T-cell lymphoma. *Investigational New Drugs*. 2013;**31**(2):469-472

[27] Kim HJ et al. High-dose chemotherapy with autologous stem cell transplantation in extranodal NK/T-cell lymphoma: A retrospective comparison with non-transplantation cases. *Bone Marrow Transplantation*. 2006;**37**(9):819-824

[28] Tse E et al. Allogeneic haematopoietic SCT for natural killer/T-cell lymphoma: A multicentre analysis from the Asia Lymphoma Study Group. *Bone Marrow Transplantation*. 2014;**49**(7):902-906

[29] Lai J, Xu P, Jiang X, Zhou S, Liu A. Successful treatment with anti-programmed-death-1 antibody in a relapsed natural killer/T-cell lymphoma patient with multi-line resistance: A case report. *BMC Cancer*. 2017;**17**(1):507

[30] Li X et al. Activity of pembrolizumab in relapsed/refractory NK/T-cell lymphoma. *Journal of Hematology & Oncology*. 2018;**11**(1):15

[31] Chan TSY, Li J, Loong F, Khong P-L, Tse E, Kwong Y-L. PD1

blockade with low-dose nivolumab in NK/T cell lymphoma failing L-asparaginase: Efficacy and safety. *Annals of Hematology*. 2018;**97**(1):193-196

[32] Silano M et al. Effect of a gluten-free diet on the risk of enteropathy-associated T-cell lymphoma in celiac disease. *Digestive Diseases and Sciences*. 2008;**53**(4):972-976

[33] Lebwohl B et al. Mucosal healing and risk for lymphoproliferative malignancy in celiac disease: A population-based cohort study. *Annals of Internal Medicine*. 2013;**159**(3):169-175

[34] Chander U, Leeman-Neill RJ, Bhagat G. Pathogenesis of enteropathy-associated t cell lymphoma. *Current Hematologic Malignancy Reports*. 2018;**13**(4):308-317

[35] Stamnaes J, Sollid LM. Celiac disease: Autoimmunity in response to food antigen. *Seminars in Immunology*. 2015;**27**(5):343-352

[36] deLeeuw RJ et al. Whole-genome analysis and HLA genotyping of enteropathy-type T-cell lymphoma reveals 2 distinct lymphoma subtypes. *Gastroenterology*. 2007;**132**(5):1902-1911

[37] Rohatiner A et al. Report on a workshop convened to discuss the pathological and staging classifications of gastrointestinal tract lymphoma. *Annals of Oncology*. 1994;**5**(5):397-400

[38] Delabie J et al. Enteropathy-associated T-cell lymphoma: Clinical and histological findings from the international peripheral T-cell lymphoma project. *Blood*. 2011;**118**(1):148-155

[39] Nijeboer P et al. Treatment response in enteropathy associated T-cell lymphoma; survival in a large multicenter cohort. *American Journal of Hematology*. 2015;**90**(6):493-498

[40] Novakovic BJ, Novakovic S, Frkovic-Grazio S. A single-center report on clinical features and treatment response in patients with intestinal T cell non-Hodgkin's lymphomas. *Oncology Reports*. 2006;**16**(1):191-195

[41] Di Sabatino A, Biagi F, Gobbi PG, Corazza GR. How I treat enteropathy-associated T-cell lymphoma. *Blood*. 2012;**119**(11):2458-2468

[42] Sureda A et al. Indications for allo- and auto-SCT for haematological diseases, solid tumours and immune disorders: Current practice in Europe. *Bone Marrow Transplantation*. 2015;**50**(8):1037-1056, 2015

[43] Jantunen E et al. Autologous stem cell transplantation in adult patients with peripheral T-cell lymphoma: A nation-wide survey. *Bone Marrow Transplantation*. 2004;**33**(4):405-410

[44] Raderer M et al. Second line chemotherapy in patients with enteropathy-associated T cell lymphoma: A retrospective single center analysis. *Annals of Hematology*. 2012;**91**(1):57-61

[45] Chen Y, Tan S-Y, Petersson BF, Khor YM, Gopalakrishnan SK, Tan D. Occult recurrence of monomorphic epitheliotropic intestinal T-cell lymphoma and the role of MATK gene expression in diagnosis. *Hematological Oncology*. 2017;**35**(4):852-855

[46] Tse E et al. Type II enteropathy-associated T-cell lymphoma: A multicenter analysis from the Asia Lymphoma Study Group. *American Journal of Hematology*. 2012;**87**(7):663-668

[47] Tabata R, Tabata C, Okamura M, Takei Y, Ohshima K. Successful treatment of monomorphic epitheliotropic intestinal T cell lymphoma with pralatrexate. *Annals of Hematology*. May 2019;**98**(5):1301-1303



- [48] Gentile C, Qin Q, Barbieri A, Ravi PS, Iyer S. Use of PEG-asparaginase in monomorphic epitheliotropic intestinal T-cell lymphoma, a disease with diagnostic and therapeutic challenges. *ecancermedicalsecience*. 2017;**11**:771
- [49] Jantunen E, Boumendil A, Finel H. Autologous stem cell transplantation for enteropathy-associated T-cell lymphoma: A retrospective study by the EBMT. *Blood*. 2013;**121**(13):2529-2532
- [50] Vose JM, Neumann M, Harris ME. International peripheral T-cell and natural killer/T-cell lymphoma study: Pathology findings and clinical outcomes international T-cell lymphoma project. *Journal of Clinical Oncology*. 2008;**26**(25):4124-4130
- [51] Weidmann E. Hepatosplenic T cell lymphoma. A review on 45 cases since the first report describing the disease as a distinct lymphoma entity in 1990. *Leukemia*. 2000;**14**(6):991-997
- [52] Parakkal D, Sifuentes H, Semer R, Ehrenpreis ED. Hepatosplenic T-cell lymphoma in patients receiving TNF- $\alpha$  inhibitor therapy: Expanding the groups at risk. *European Journal of Gastroenterology & Hepatology*. 2011;**23**(12):1150-1156
- [53] Calvaruso M et al. Challenges and new prospects in hepatosplenic  $\gamma\delta$  T-cell lymphoma. *Leukemia & Lymphoma*. 2014;**55**:1-9
- [54] McKinney M et al. The genetic basis of hepatosplenic T-cell lymphoma. *Cancer Discovery*. 2017;**7**(4):369-379
- [55] Bergmann AK et al. DNA methylation profiling identifies candidate genes for the pathogenesis of hepatosplenic T-cell lymphoma. *Haematologica*. 2018;**2018**:196196
- [56] Voss MH et al. Intensive induction chemotherapy followed by early high-dose therapy and hematopoietic stem cell transplantation results in improved outcome for patients with hepatosplenic T-cell lymphoma: A single institution experience. *Clinical Lymphoma, Myeloma & Leukemia*. 2013;**13**(1):8-14
- [57] Rashidi A, Cashen AF. Outcomes of allogeneic stem cell transplantation in hepatosplenic T-cell lymphoma. *Blood Cancer Journal*. 2015;**5**:e318