

# We are IntechOpen, the world's leading publisher of Open Access books Built by scientists, for scientists

6,900

Open access books available

185,000

International authors and editors

200M

Downloads

Our authors are among the

154

Countries delivered to

TOP 1%

most cited scientists

12.2%

Contributors from top 500 universities



WEB OF SCIENCE™

Selection of our books indexed in the Book Citation Index  
in Web of Science™ Core Collection (BKCI)

Interested in publishing with us?  
Contact [book.department@intechopen.com](mailto:book.department@intechopen.com)

Numbers displayed above are based on latest data collected.  
For more information visit [www.intechopen.com](http://www.intechopen.com)



# Prologue: Introduction to Advanced Concepts in Pericardial Disease

*Takashi Murashita*

## 1. Introduction

Pericardial diseases are common in clinical practice and include a variety of pathologies such as pericarditis (acute, subacute, chronic, and recurrent), pericardial effusion, cardiac tamponade, constrictive pericarditis, and pericardial masses [1, 2]. The etiology of pericardial diseases is classified into infectious, autoimmune, post-myocardial infarction, and autoreactive causes. When etiology is not apparent, it is classified as idiopathic. Multimodality imaging is an essential approach for a modern and comprehensive diagnostic evaluation [3]. The goal of this text is to highlight the current concepts in the clinical characteristics, presentation, diagnosis, and the treatment for pericardial diseases.

## 2. Pericarditis

### 2.1 Acute pericarditis

Acute pericarditis can be diagnosed with at least two of the four following criteria: (1) pericarditic chest pain, (2) pericardial rubs, (3) new widespread ST elevation or PR depression on electrocardiogram, and (4) pericardial effusion (new or worsening). The additional supporting findings include (1) elevation of inflammation markers (C-reactive protein, erythrocyte sedimentation rate, and white blood cell count) and (2) evidence of pericardial inflammation shown by computed tomography or magnetic resonance imaging.

In developing countries, tuberculosis is the leading cause of pericarditis, and it is often associated with HIV infection. In developed countries, more than 80% of the cases are idiopathic, and the cause is often presumed as viral infection [2].

In terms of diagnosis of suspected acute pericarditis, electrocardiogram, trans-thoracic echocardiogram, chest X-ray, and assessment of inflammation markers and myocardial injury are recommended as a class I indication [1].

Predictors of poor prognosis for acute pericarditis include (1) fever  $>38^{\circ}\text{C}$ , (2) subacute onset, (3) large pericardial effusion, (4) cardiac tamponade, and (5) lack of response to aspirin or nonsteroidal anti-inflammatory drugs (NSAIDs) after at least 1 week of therapy. If the patients are categorized in high risk (at least one risk factor of above), hospital admission is recommended. Outpatient management is recommended for low-risk patients.

Regarding treatment, aspirin or NSAIDs are recommended as first-line therapy with gastroprotection. Colchicine is also recommended as first-line therapy as an

adjunct to aspirin/NSAID therapy (**Table 1**). Evaluation of response to anti-inflammatory therapy is recommended after 1 week. Low-dose corticosteroids can be considered in cases of contraindication/failure of aspirin/NSAIDs and colchicine, when an infectious cause is excluded or when there is a specific indication such as an autoimmune disease.

2.2 Recurrent pericarditis

Recurrent pericarditis is the most common complication of acute pericarditis, and it happens in 30% of patients with a first attack of acute pericarditis. Recurrent pericarditis is defined with a symptom-free interval of 4–6 weeks or longer after the first episode of acute pericarditis.

Diagnosis is established by C-reactive protein, computed tomography, and/or cardiac magnetic resonance imaging showing pericardial inflammation.

Commonly prescribed anti-inflammatory therapies for recurrent pericarditis are aspirin, ibuprofen, indomethacin, and colchicine (**Table 2**). Colchicine is recommended for at least 6 months. In cases of incomplete response to aspirin/NSAIDs and colchicine, corticosteroids may be used. However, severe side effects of corticosteroids were reported in about 25% of patients with high oral dose of corticosteroids. In order to avoid systemic side effects of corticosteroids, the intrapericardial route has been proposed [4, 5]; however, this technique requires further investigation. Drugs such as immunoglobulin, anakinra, or azathioprine are considered as third-line therapy in cases of non-response to aspirin/NSAIDS, colchicine, or

Drug	Usual dosing	Therapy duration	Tapering
Aspirin	750–1000 mg every 8 hours	1–2 weeks	Decrease doses by 250–500 mg every 1–2 weeks
Ibuprofen	600 mg every 8 hours	1–2 weeks	Decrease doses by 250–500 mg every 1–2 weeks
Colchicine	0.5 mg per day (<70 kg) 0.5 mg twice a day (≥70 kg)	3 months	Not mandatory

**Table 1.**  
*Commonly prescribed anti-inflammatory therapy for acute pericarditis.*

Drug	Usual dosing	Therapy duration	Tapering
Aspirin	500–1000 mg every 6–8 hours	Weeks–months	Decrease doses by 250–500 mg every 1–2 weeks
Ibuprofen	600 mg every 8 hours	Weeks–months	Decrease doses by 200–400 mg every 1–2 weeks
Indomethacin	25–50 mg every 8 hours	Weeks–months	Decrease doses by 25 mg every 1–2 weeks
Colchicine	0.5 mg per day (<70 kg) 0.5 mg twice a day (≥70 kg)	At least 6 months	Not mandatory

**Table 2.**  
*Commonly prescribed anti-inflammatory therapy for recurrent pericarditis.*

corticosteroids. As a last resort, pericardiectomy is considered after a thorough trail of unsuccessful medical therapy.

C-reactive protein dosage should be considered to guide the treatment duration and assess the response to therapy. After the normalization of C-reactive protein, a gradual tapering of therapies should be considered, tailored to symptoms, stopping a single class of drugs at a time.

### 2.3 Myopericarditis

Pericarditis which has concomitant myocardial involvement is referred to as myopericarditis. The classical presentation of myopericarditis is chest pain with other signs of pericarditis, in addition to the elevation of markers of myocardial damage. Viral infections are the most common cause in developed countries, whereas infectious causes such as tuberculosis are common in developing countries.

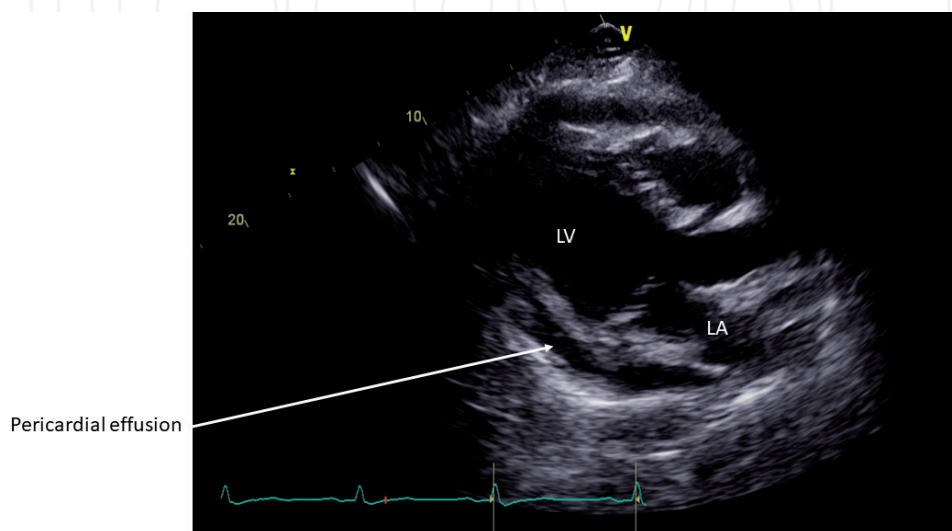
In cases of suspected myopericarditis, coronary angiography is recommended in order to rule out acute coronary syndrome. Cardiac magnetic resonance is also recommended for the confirmation of myocardial involvement. Hospitalization, rest, and avoidance of physical activity beyond normal sedentary activities are recommended in nonathletes and athletes with myopericarditis for a period of 6 months.

### 3. Pericardial effusion and cardiac tamponade

Pericardial effusion is classified according to onset as acute, subacute, and chronic when lasting >3 months. The pericardial effusion, which was caused by inflammation leading to increased production of pericardial fluid, is called exudate pericardial effusion. On the other hand, the accumulation of pericardial fluid caused by decrease reabsorption due to an increase in systemic venous pressure as a result of congestive heart failure or pulmonary hypertension is called transudate pericardial effusion.

As of diagnosis, transthoracic echocardiography is recommended (**Figure 1**), and it can assess the size of the pericardial effusion (mild, < 10 mm; moderate, 10–20 mm; or large, > 20 mm), distribution (circumferential or loculated), and hemodynamic effects.

Pericardial effusion is often associated with known or unknown medical conditions such as infections (viral, bacterial, and tuberculosis), cancer, connective



**Figure 1.**  
*The echocardiographic imaging for pericardial effusion. LA, left atrium; LV, left ventricle.*

tissue diseases, trauma, and metabolic causes (e.g., hypothyroidism). In developed countries, over 50% of the etiology is idiopathic, whereas tuberculosis is the leading etiology in developing countries.

It is recommended that the therapy of pericardial effusion is targeted at the etiology. When pericardial effusion is associated with systemic inflammation, aspirin/NSAIDs/colchicine, and treatment of pericarditis are recommended. For cardiac tamponade, symptomatic moderate to large pericardial effusions not responsive to medical therapy, and suspicion of unknown bacterial or neoplastic etiology, pericardiocentesis or pericardial window is indicated.

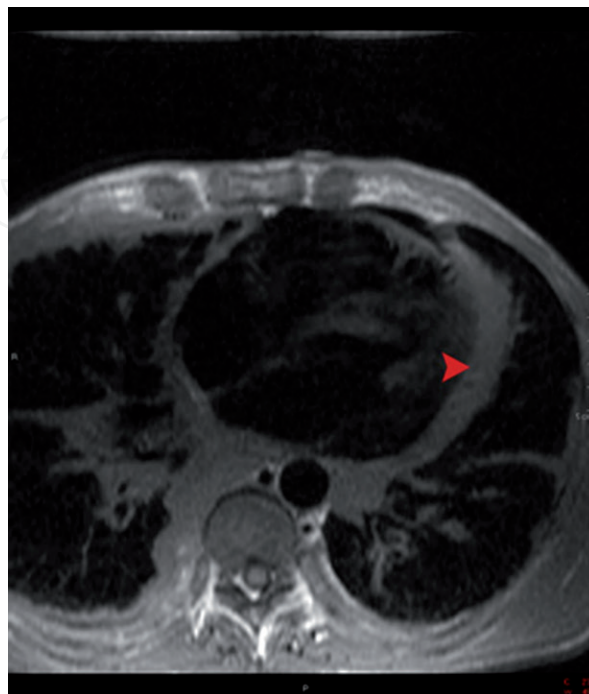
The common causes of cardiac tamponade include pericarditis, tuberculosis, iatrogenesis (invasive procedure-related, post-cardiac surgery), trauma, and neoplasm/malignancy. The other causes include autoimmune diseases (systemic lupus erythematosus, rheumatoid arthritis, scleroderma), radiation, post-myocardial infarction, uremia, aortic dissection, bacterial infection, and pneumopericardium.

#### **4. Constrictive pericarditis**

Constrictive pericarditis is a result from inflammation and fibrosis of the pericardium leading to diastolic dysfunction and right heart failure. Generally speaking, constrictive pericarditis is irreversible, and once the diagnosis is made, surgical pericardiectomy is indicated in patients with symptoms of heart failure.

In Western countries, the etiology of constrictive pericarditis is mainly idiopathic, presumably unrecognized prior viral pericarditis. Previous cardiac surgery and prior mediastinal radiation therapy are becoming more popular. On the other hand, tuberculosis is a major cause of constrictive pericarditis in developing countries.

In constrictive pericarditis, Kussmaul sign and pericardial knock are common physical findings. Electrocardiogram may show low voltages, non-specific ST-T changes, or atrial fibrillation. Chest X-ray shows pericardial calcification in one-third of the cases.



**Figure 2.**  
*Cardiac magnetic resonance imaging shows thickening of the pericardium (arrow).*



Syndrome	Definition	Therapy
Transient constriction	Reversible pattern of constriction following spontaneous recovery or medical therapy	2–3 months of empiric anti-inflammatory drugs
Effusive-constrictive pericarditis	Failure of the right atrial pressure to fall by 50% or to a level below 10 mmHg after pericardiocentesis	Pericardiocentesis followed by medical therapy. Surgery for persistent cases
Chronic constriction	Persistent constriction after 3–6 months	Pericardiectomy, medical therapy for advanced cases or high risk of surgery, or mixed forms with myocardial involvement

**Table 3.**  
*Definition and therapy for constrictive pericarditis.*

For the diagnosis of constrictive pericarditis, transthoracic echocardiography and chest X-ray with adequate technical characteristics are recommended in all patients with suspected constrictive pericarditis. Echocardiography may show septal bounce, pericardial thickening and calcifications, respiratory variation of the mitral peak E velocity of >25% and variation in the pulmonary venous peak D flow velocity of >20%, or color M-mode flow propagation velocity > 45 cm/s. Computed tomography and cardiac magnetic resonance imaging are indicated as second-level imaging techniques to assess calcifications, pericardial thickness (3–4 mm), degree, and extension of pericardial involvement (**Figure 2**). Cardiac catheterization may show “dip and plateau” sign, right ventricular diastolic and left ventricular diastolic pressures usually equal, and ventricular independence.

The definitions and therapy of the main constrictive pericarditis are listed in **Table 3**.

## 5. Surgical treatment for pericardial disease

### 5.1 Pericardial window

A pericardial window is the procedure to create a communication from the pericardial space to the pleural space. The purpose of this procedure is to allow a pericardial effusion (usually malignant) to drain from the pericardial space into the chest cavity to prevent a large accumulation of pericardial fluid and cardiac tamponade.

Subxiphoid pericardial window is done by either local or general anesthesia. A vertical incision about 4 cm is made over the xiphoid process and upper abdomen. The diaphragm is dissected away from the undersurface of the sternum and xiphoid, fat is removed from over the pericardium, and the pericardium is opened under direct vision. All fluid is aspirated, and loculations may be broken up gently with the sucker. As large a pericardial window as possible is made by excision of the pericardium. Pericardial tissue and fluid are sent for bacteriologic and histologic study.

Another way to do a pericardial window is via a left anterolateral approach. A small left anterolateral incision is made, and a simple pericardial window is created, usually of necessity anterior to the phrenic nerve. After evacuation of fluid, chest tubes are placed in the pleural space.

### 5.2 Pericardiectomy

Pericardiectomy is indicated in patients with symptomatic constrictive pericarditis, especially those patients requiring increasing doses of diuretics. It is also

indicated in patients with effusive-constrictive pericarditis who do not respond to anti-inflammatory medications.

Pericardiectomy is typically done through median sternotomy, whereas it can be done via left anterolateral or bilateral thoracotomy. Complete pericardiectomy is defined as removal of the whole pericardium overlying the heart and proximal great vessels except for the pericardium posterior to the left atrium in the oblique sinus and variable amounts of pericardium adjacent to the phrenic nerves. Thus, the anterior pericardium (phrenic nerve to phrenic nerve), the diaphragmatic pericardium, and a portion of the pericardium posterior to the left phrenic nerve should be removed. Failure to remove the pericardium from the diaphragmatic surface may lead to late recurrence of constrictive physiology.

Although cardiopulmonary bypass and systemic heparinization may increase the risk of bleeding, decompression of the heart with extracorporeal circulation is useful and necessary in many patients because circulatory support facilitates dissection of the pericardium and allows wide manipulation of the ventricles. Further, with cardiopulmonary bypass, any injury to the myocardium is more easily repaired. Another advantage is that during cardiopulmonary bypass, the patient's total blood volume is drained into the cardiectomy reservoir, and after pericardiectomy, intravascular volume is adjusted to maintain adequate cardiac output and perfusion.

One of the largest number of pericardiectomy was reported from the Mayo Clinic [6]. They reviewed 1071 pericardiectomy operations for about 80 years. The etiology of constrictive pericarditis was idiopathic in 62%, post-cardiac surgery in 27%, and postradiation in 10% in the contemporary era. The 30-day mortality was 5.2% in the contemporary era and 13.5% in the historical era. The risk factors of overall mortality in the contemporary era were the New York Heart Association class III or IV, etiology of radiation or post-cardiac surgery, and the need for cardiopulmonary bypass.

## 6. Conclusions

Despite the recent advancement in diagnostic images and treatment options, there have been a limited number of randomized controlled studies in the field of pericardial disease. Therefore, contemporary management of pericardial disease is mainly performed empirically. Nowadays new diagnostic techniques have been available in the study of pericardial diseases.

### Author details

Takashi Murashita  
University of Missouri, Columbia, Missouri, USA

\*Address all correspondence to: [tmurashita@gmail.com](mailto:tmurashita@gmail.com)

### IntechOpen

© 2019 The Author(s). Licensee IntechOpen. This chapter is distributed under the terms of the Creative Commons Attribution License (<http://creativecommons.org/licenses/by/3.0>), which permits unrestricted use, distribution, and reproduction in any medium, provided the original work is properly cited. 

## References

- [1] Adler Y, Charron P, Imazio M, Badano L, Barón-Esquivias G, Bogaert J, et al. 2015 ESC guidelines for the diagnosis and management of pericardial diseases: The TaskForce for the Diagnosis and Management of Pericardial Diseases of the European Society of Cardiology (ESC) endorsed by: The European Association for Cardio-Thoracic Surgery (EACTS). *European Heart Journal*. 2015;**36**(42):2921-2964. DOI: 10.1093/eurheartj/ehv318
- [2] Imazio M. Contemporary management of pericardial diseases. *Current Opinion in Cardiology*. 2012;**27**(3):308-317. DOI: 10.1097/HCO.0b013e3283524fbc
- [3] Klein AL, Abbata S, Agler DA, Appleton CP, Asher CR, Hoit B, et al. American society of echocardiography clinical recommendations for multimodality cardiovascular imaging of patients with pericardial disease: Endorsed by the society for cardiovascular magnetic resonance and society of cardiovascular computed tomography. *Journal of the American Society of Echocardiography*. 2013;**26**(9):965-1012. DOI: 10.1016/j.echo.2013.06.023
- [4] Maisch B, Ristić AD, Pankuweit S. Intrapericardial treatment of autoreactive pericardial effusion with triamcinolone: The way to avoid side effects of systemic corticosteroid therapy. *European Heart Journal*. 2002;**23**(19):1503-1508
- [5] Frasiolas JA, Cahoon WD. Intrapericardial triamcinolone administration for autoreactive pericarditis. *The Annals of Pharmacotherapy*. 2010;**44**(10):1641-1646. DOI: 10.1345/aph.1P294
- [6] Murashita T, Schaff HV, Daly RC, Oh JK, Dearani JA, Stulak JM, et al. Experience with pericardiectomy for constrictive pericarditis over eight decades. *The Annals of Thoracic Surgery*. 2017;**104**(3):742-750. DOI: 10.1016/j.athoracsur.2017.05.063