

# We are IntechOpen, the world's leading publisher of Open Access books Built by scientists, for scientists

6,900

Open access books available

185,000

International authors and editors

200M

Downloads

Our authors are among the

154

Countries delivered to

TOP 1%

most cited scientists

12.2%

Contributors from top 500 universities



WEB OF SCIENCE™

Selection of our books indexed in the Book Citation Index  
in Web of Science™ Core Collection (BKCI)

Interested in publishing with us?  
Contact [book.department@intechopen.com](mailto:book.department@intechopen.com)

Numbers displayed above are based on latest data collected.  
For more information visit [www.intechopen.com](http://www.intechopen.com)



# Simultaneous Mastopexy with Augmentation

*Angelo Cuzalina and Landon McLain*

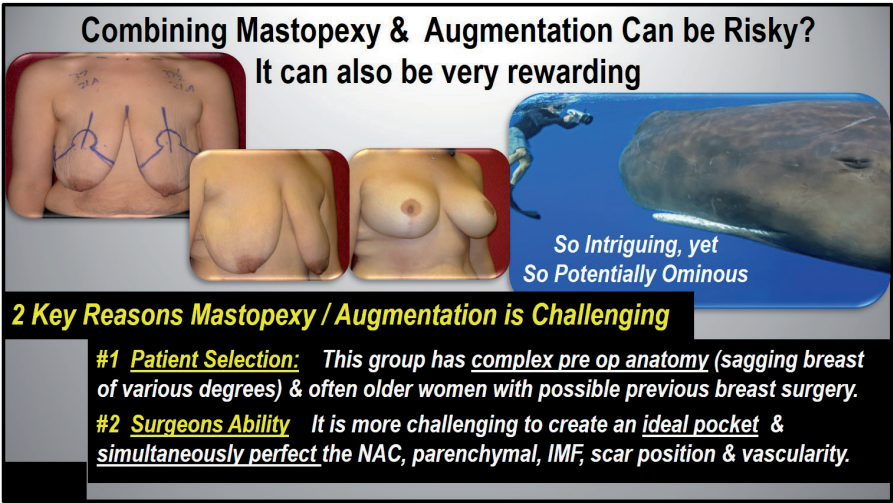
## Abstract

Simultaneous mastopexy and augmentation can be an extremely rewarding surgery for both patient and surgeon. However, it is one of most complex cosmetic surgical procedures with a high revision rate, relatively high complication rate and higher than average litigation rate. Trying to simultaneously adjust two breasts for a new submuscular implant pocket, new NAC position, new parenchymal arrangement, new infra-mammary fold (IMF) position, great symmetry, perfect amount of skin and fat removal, with great scars all while maintaining vascularity is no small task. A clear understanding of the optional procedures and variables involved when combining these techniques will significantly benefit the surgeon in obtaining safe and predictable results while limiting the vast majority of complications.

**Keywords:** mastopexy, breast augmentation, simultaneous breast lift and augmentation, revision breast surgery

## 1. Rationale

The ability to correct both breast ptosis and deflation is a critical component in any successful cosmetic breast practice. In most offices, the percentage of patients desiring correction of both the aforementioned deformities is significant if not a majority. Multiple factors lead to both ptosis and deflation, including pregnancy and lactation, weight loss and congenital abnormalities, any of which can ultimately result in descent of the nipple-areola complex (NAC) below the inframammary crease. This is usually accompanied by some degree of reduction in breast volume, leading to the desire for “larger and perkier” breasts which is a common request from the affected patient population. The required manipulation of these multiple components, the breast skin envelope, glandular area and position, NAC position and size, inframammary fold position and chest wall anatomy is what makes this procedure technically and strategically challenging. However, mastery of this combination procedure will yield far more dramatic and esthetic results than either augmentation or mastopexy alone [1, 2]. The remainder of this chapter will be focused on helping the reader better understand both the obvious and subtle factors in performing this procedure in a reliable and predictable fashion with minimization of risks and complications. Simultaneous breast lift and augmentation carries a high litigation rate because the complication and revision rates are much higher than the majority of cosmetic surgeries. Trying to simultaneously adjust two breasts for a new submuscular implant pocket, new NAC position, new parenchyma arrangement, new infra-mammary fold (IMF) position, great symmetry, perfect amount of skin and fat removal, with great scars all while maintaining vascularity is

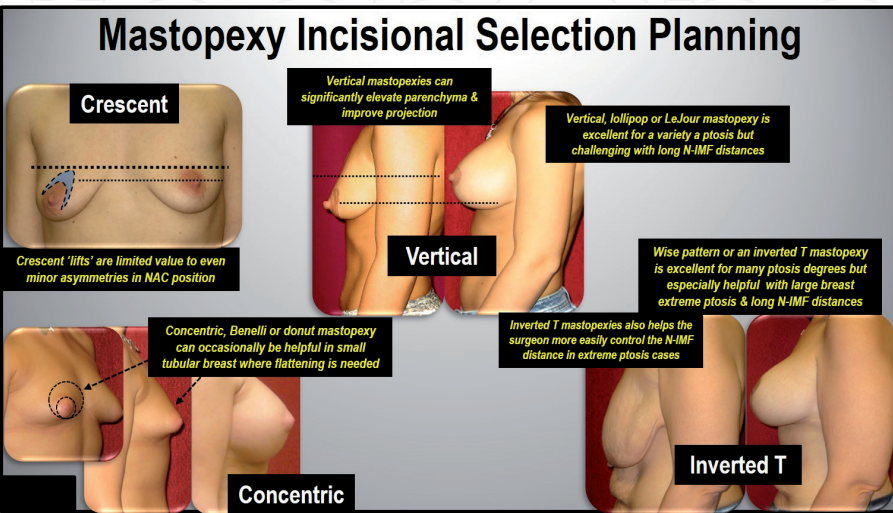


**Figure 1.** Simultaneous breast lift and augmentation is extremely gratifying when it works well but carries a high litigation rate because it is a very challenging procedure and risk are relatively high for complication. Removing and tightening skin at the same time one increases volume of the breast with an implant by its nature risk nipple-areola complex (NAC) necrosis.

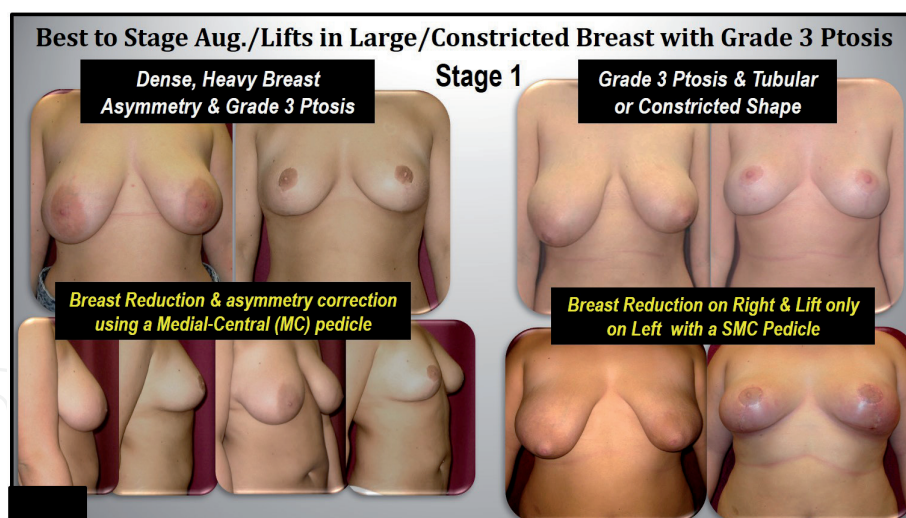
no small task. But, by improving so many issues of the ptotic breast, potential positive changes and patient's happiness can be wonderful and rewarding (**Figure 1**).

2. Options

Of course the basics of this procedure are some combination of augmentation with elevation of the NAC with varying degrees of skin/glandular excision. The simplest form would be a basic augmentation with a crescent lift of one or both areolae, while the more challenging case can require a large reduction/lift using an inverted T incision along with augmentation (**Figure 2**). In either case, the goal is to augment the breast volume and reposition the NAC into a more harmonious relationship with the breast implant while successfully managing the soft tissue envelope and glandular area. In our opinion, the mastopexy portion of the procedure allows one to manipulate and idealize the breast tissues, in other words *match*, the breast tissues around



**Figure 2.** Many incisional options exist for mastopexy but all breasts are different along with patient desires. The basic four options shown above are the crescent, concentric, vertical and inverted T. The vertical and inverted T mastopexies are the most efficient choices for the majority of breast ptosis situations.



**Figure 3.**

*The primary aim of staging is to avoid the devastating complication of ischemia and necrosis to the NAC. Extremely large breast with major ptosis as well as large tubular or constricted breast as shown are ideal for staging when a patient desires both mastopexy/reduction plus implants for a more “rounded” or “perky” appearance.*

a well-placed and selected implant. However, one must consider limitations to both of the components of the surgery, which are stricter in combination than either in isolation. For example, a breast augmentation alone may allow use of larger implants, but when combined with a mastopexy, the volume of implant must often be limited to avoid undue stress on the resultant breast envelope as well as the arterial perfusion and venous drainage of the NAC. Despite using a smaller implant in certain situations to decrease vascular compromise, the breast implant dimensions should still come close to the base width of the breast. This may often require avoiding a higher profile implant in favor of a more moderate profile and smaller implant that still has the desired base width, particularly when more extensive mastopexy is required.

At this point it is worth noting that not all patients are good candidates for this procedure. If there is extreme laxity, desire for extremely large breasts, or large pedunculated or constricted breasts requiring major reduction and tissue rearrangement staging may be the better option. The primary aim of staging is to avoid the devastating complication of ischemia and necrosis to the NAC which is most at risk (**Figure 3**). Medical co-morbidities and prior surgery may also lead one to recommend staging in select cases as well, but for the majority of patients requiring increased breast volume and repositioning of the NAC and reduction of excess skin are better served by combining these procedures. This often allows a type of synergism from matching the breast envelope to a well-positioned and selected implant that can yield a dramatic and pleasing result while minimizing financial burden, as well as anesthesia and recovery times for the patient.

### 3. Pertinent anatomy

The mammary gland begins as an invagination ectoderm that forms a primary bud which results in the development of multiple secondary buds, usually 15–25. Approximately halfway through gestation the buds have lengthened and formed epithelial chords that extend into the chest wall and then begin to form the lactiferous ducts through lumenization. At birth the lactiferous ducts open into the mammary pits that elevate and form the nipple. Failure to do so results in an inverted nipple (2–4% of females). No further development occurs until puberty when hormonal stimulation triggers proliferation and enlargement of the glandular tissues as well as deposition of fat.



### **3.1 Surface anatomy**

The variation in size and shape of the female breast is considerable. Typically, the breast extends from the 2nd or 3rd rib superiorly to the 5th or 6th rib inferiorly where the inframammary crease lies. Medially the breast starts from the sterna-costal junction laterally to the anterior axillary spine and may extend to the middle axillary line with the axillary tail extending supero-laterally into the axilla proper [1]. Ideally, the breast should form a rounded and conical shape with the NAC situated at the apex. The NAC may be of varying size and pigmentation, but ideally the NAC should be roughly 1/3rd of the overall breast diameter and the nipple itself 1/3rd of the overall areolar diameter [2].

### **3.2 Glandular anatomy**

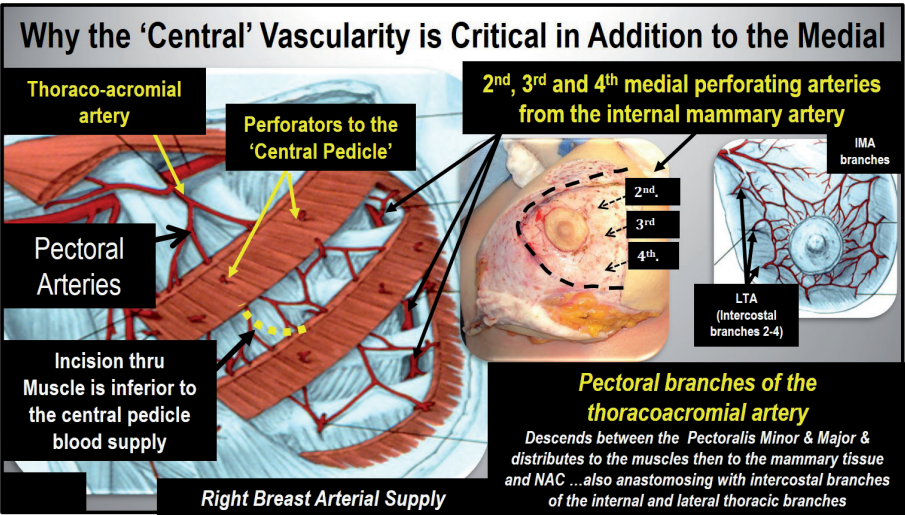
15–25 Lactiferous ductules extend from the deep glandular regions toward the NAC, terminating as openings. Each ductule drains 15–20 lobules which is the functional unit of the breast gland where lactation occurs. The breast gland has no discrete fascia but does have fibrous thickenings scattered throughout the gland which extend from the muscular fascia toward the skin. These Cooper's ligaments provide scaffolding support to the glandular breast. The integrity of these ligaments can be compromised with aging, fluctuations in weight and breast size and pregnancy which may eventually contribute to breast ptosis. Recent anatomic studies have elucidated additional internal supporting structures. The inframammary crease ligament has been identified through cadaver dissection and contributes to a well-defined inframammary crease. It typically extends from the medial aspect of the 5th rib and laterally to the fascia of the 5th and 6th ribs [3]. The ligamentum suspensorium mammae extends from the clavicle down to the upper border of the breast and retromammary space and may explain the propensity of some females to develop ptosis while others do not, as it is well defined in some patients but indistinct in others [4, 5].

## **4. Innervation, lymphatics and blood supply**

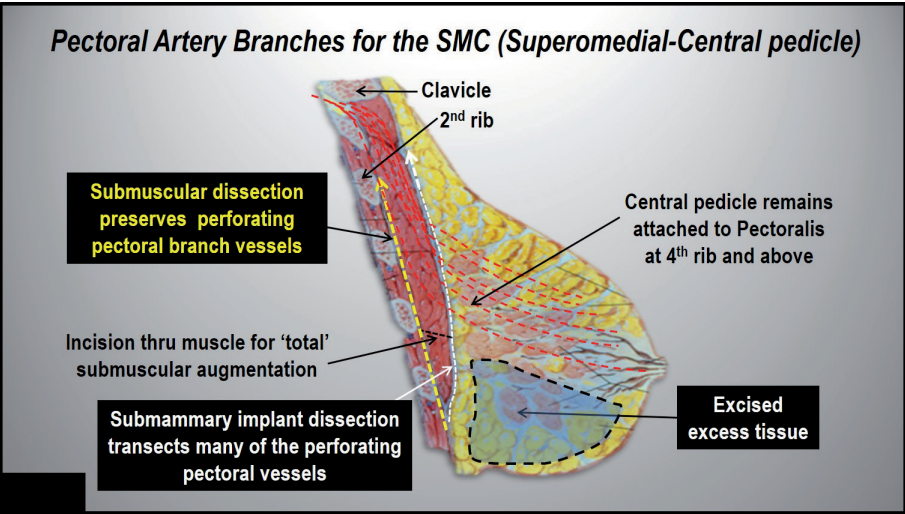
Sensory innervation is derived from cervical plexus, anteromedial and antero-lateral intercostal nerve branches from the 3rd, 4th, 5th and 6th intercostal nerves as well as branches from the 2nd intercostal nerve. Of particular concern for surgeons is the innervation of the nipple, which has crossover innervation from 3rd to 5th nerves medial and laterally, but primarily derived from the 4th lateral cutaneous branch. This branch tends to run along the fascia of pectoralis major before emerging to innervate the nipple from its posterior surface.

Most of the lymphatic drainage of the breast flows into the axilla through the external mammary nodal group, however additional drainage occurs through the medial, transpectoral and postdoctoral routes as well.

The internal mammary artery supplies the majority (approximately 60%) of the blood supply to the breast. Its branches pass through the intercostal muscles, from the 2nd through 5th ribs immediately lateral to the parasternal border. These coalesce once in the breast with additional contributions from lateral thoracic branches, pectoral branches from internal thoracic artery and branches from the posterior intercostal arteries. Venous outflow occurs via an anastomotic plexus in the subcutaneous tissue immediately beneath and around the NAC. This plexus then drains peripherally via large subcutaneous veins that empty into intercostal and axillary veins as well as internal thoracic veins. Importantly, the largest and most reliable venous routes reside in the superomedial and inferior pedicles. Congestion of these routes and the subareolar plexus are usually the primary causes of NAC ischemia and necrosis in mastopexy procedures [1].



**Figure 4.**  
The figure demonstrates the two major sources of blood supply to the Superomedial-Central (SMC) pedicle. The medial source from branches of the internal mammary artery and central component from the pectoral perforators. The 2nd medial perforator supplies the most superomedial area of the SMC pedicle. Maintaining all these sources during dissection produces a robustly vascularized pedicle.



**Figure 5.**  
The central component vascularization of the SMC pedicle is helpful when implant placement is submuscular. Submammary dissection transects most of the central perforators leaving only the medial perforators for blood supply to the NAC. The incision through muscle must be made just inferior to the central blood supply. Incision at the lateral pectoralis border can be used as well but does not work as well for obtaining a total muscular coverage of an implant.

**4.1 Key point**

The 2nd–4th medial perforating arteries from the internal mammary artery along with pectoral arteries branches from the thoracoacromial artery together supply the best blood supply to the NAC and is the primary reason the Superomedial-Central (SMC) pedicle is our pedicle of choice in the majority of combined mastopexy/augmentation cases (**Figures 4 and 5**).

**5. Incision options**

As this chapter is focused on mastopexy with augmentation, we will primarily discuss vertical and Wise pattern mastopexy incision choices. Minimal attention

will be afforded to crescent lift or periareolar (donut) mastopexy which have little major lifting benefit in most cases.

### **5.1 Crescent/circumareolar**

The crescent lift has value mainly as a minor NAC elevation maneuver when one NAC is slightly higher than the other by 1–2 cm. It can help “level” out the position to match the other but has little to no lifting effect on the parenchyma. While the donut or circumareolar lift is best used for limited and isolated cases of a smaller tubular or severely constricted breast where flattening of the NAC may be desired. It is the authors’ belief that the circumareolar lift yields undesirable results in the majority of cases and also has limited ability to manipulate the soft tissue envelope resulting in inadequate projection, poor scarring and lack of longevity.

### **5.2 Wise pattern/inverted T**

This is the most commonly used mastopexy and reduction pattern in the United States and is similarly very popular when combined with augmentation. This can be based on multiple pedicles, with the inferior pedicle being the most preferred historically. However, other pedicles have gained popularity in recent years, particularly superior and medial pedicles. Although related, the skin excision pattern and glandular pedicle are separate components and each component should be selected based on thoughtful surgical planning. The horizontal component on the Inverted T incision is very beneficial in controlled the Nipple to Inframammary fold (N-IMF) distance in patients who have N-IMF distances much greater than 8–10 cm prior to surgery. It can be used with most pedicles and ptosis situations.

### **5.3 Vertical mastopexy/teardrop**

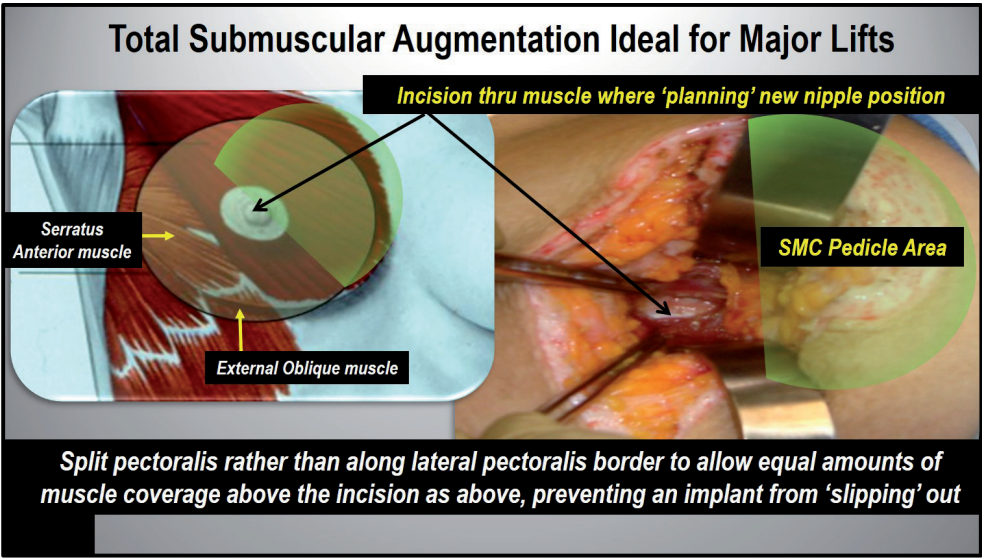
Popularized by Lassus and LeJour and later modified by Findlay-Hall, the vertical mammoplasty traditionally seeks to avoid the horizontal scar relying on gathering excess inferior skin during closure and additional volume reduction is aided by liposuction inferiorly and laterally. Unfortunately, final breast shape can take many months to achieve and may still require skin excision inferiorly if puckering persists. The advantages that this technique offers are less incisional scarring, good projection, and this technique allows a versatile pedicle design. We feel the Superomedial-Central (SMC) pedicle is the most predictable and versatile pedicle due to more robust blood supply and venous drainage and this pedicle works very well with a vertical or inverted T mastopexy.

## **6. Pedicle options/implant location options**

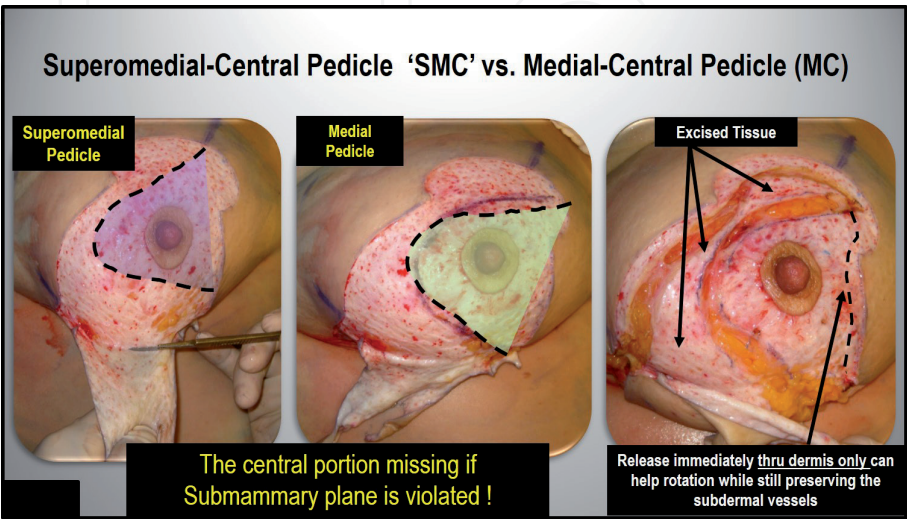
When combined with a central component, the superomedial pedicle has the most robust and unaffected blood supply during a combined mastopexy and augmentation procedure [6]. Hence, our pedicle of choice in the majority of mastopexy augmentations is the Superomedial-Central (SMC) pedicle. This majority of blood supply for this pedicle originates from the internal thoracic artery (via the internal mammary artery) that should be preserved using a SMC. The central component houses trans-pectoral perforators from the internal thoracic artery and medial mammary branches (**Figure 4**). This central component vascularization can only be maintained well when placing implants in a subpectoral or submuscular plane and are sacrificed with development of a subglandular pocket (**Figure 5**). This is an



important consideration when selecting implant plane and in revision surgery when implants may have been placed in a subglandular fashion. For the aforementioned reasons, the authors almost universally use subpectoral or submuscular placement during the augmentation phase of the procedure. This is not only beneficial from a blood supply and venous drainage perspective, but also results in more soft tissue coverage of the implant and likely results in a decreased incidence of capsular contracture. An additional advantage is when utilizing a *total submuscular* plane, the elevated fibers of serratus and external oblique with their corresponding fascia are elevated partially to help cover the implant inferiorly and laterally to dissuade bottoming out and as a further barrier to the external environment and potential microbes should even a small wound dehiscence occur postoperatively (**Figure 6**). This is particularly important when capsular contracture exists above muscle and

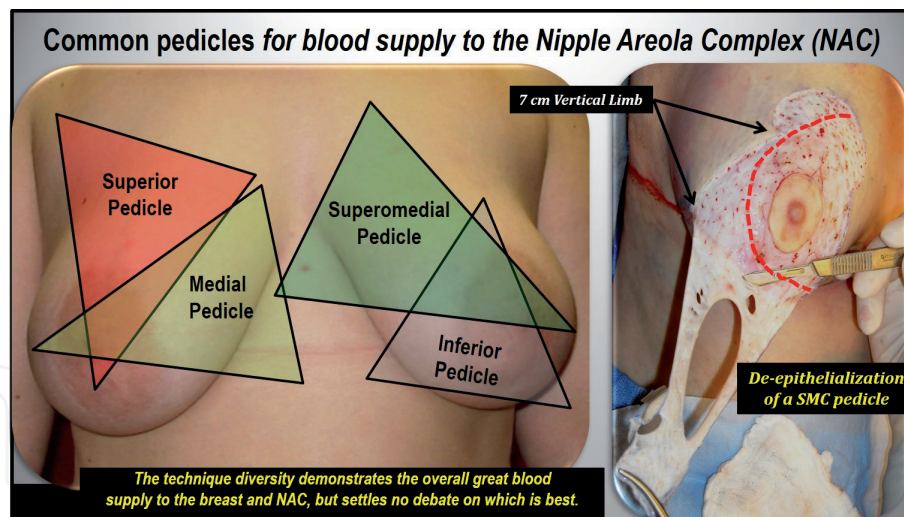


**Figure 6.**  
The SMC pedicle allows for implant placement in a total submuscular location if the incision as shown is made immediately inferior to the central pedicle component that remain attached to the pectoralis major. Total coverage of a new implant gives protection of any incision breakdown and also prevents the implant from “slipping out” of the pocket especially when a submammary implant was simultaneously removed.



**Figure 7.**  
While the SMC can be used in most ever breast ptosis situation, when the sternal notch to nipple (SN-N) distance becomes greater than 30 cm, a MC pedicle improves the arc of rotation to obtain proper NAC elevation with less kinking of the pedicle. Most of the same blood supply exists between a SMC vs. MC pedicle with the occasion loss of the 2nd intercostal in some medial pedicle situations.





**Figure 8.**

*The four most common pedicles as discussed and shown here have specific advantages and disadvantages. Regardless, the surgeon must make sure any of the four if used is treated gently and has an adequate base to allow proper drainage to and from the NAC.*

a complete capsulectomy is performed and a new implant is immediately placed beneath muscle in a new pocket. In this situation, a subpectoral placement only will result in “slipping out” of the implant from the subpectoral position back into the above muscle pocket unless an acellular dermal matrix (ADM) is added to the inferior muscle edge. The total submuscular placement prevents implant slippage and avoids the need for an expensive ADM placement.

Although the SMC pedicle likely offers the most versatility and safety, this can be altered in select situations (**Figure 7**). For instance, a purely Medial-Central (MC) pedicle should be considered in cases of long pedicle length and greater degrees of ptosis ( $SN-N > 30$  cm) such as some massive weight loss patients. This option allows for maintenance of the medial mammary and pectoral arterial branches while allowing an easier or better “arc of rotation” of the pedicle into its final position, without excessive kinking or tension on the pedicle [7]. In cases where the mastopexy component is fairly small and the degree of NAC elevation minor (only 2–3 cm), a purely superior-central (SC) pedicle can often facilitate easier transposition of the NAC into position [8]. A purely SC pedicle will gain some axillary artery contribution as well as some lateral and internal thoracic branches to the pedicle [9]. An inferior pedicle is rarely selected in certain staged procedures where the patient has a very long SN-N along with a relatively short N-IMF distance (**Figure 8**). Because the inferior pedicle bottoms out more than other pedicles, the vertical limbs of an inferior pedicle should be drawn close to 5 cm compared to a 7 cm length of vertical limbs for superior, medial or superomedial pedicles that have very limited stretching comparably.

## 7. Implant selection

The style and type of implant used is quite variable. This technique performs well regardless of implant style used assuming some common considerations. Saline or silicone implants are well suited for this procedure and their selection should be based on similar criteria one would use for augmentation alone typically. However, given that the implant plane is sub muscular, the incidence of rippling is less than with a subglandular plane. As previously mentioned implant size is critical. Utilizing very large implants can stress the mastopexy closure and lead to ischemia

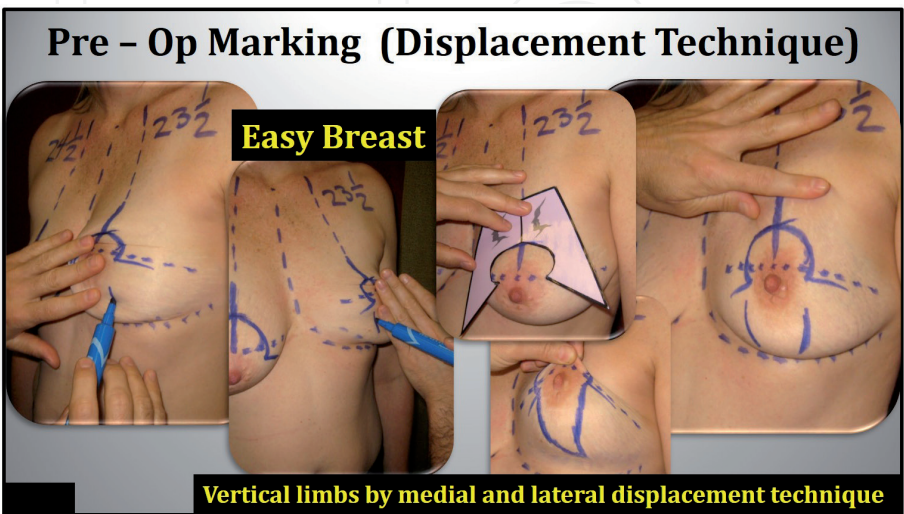
to the NAC. A more conservative approach to implant sizing is preferable and avoidance of excessively high profile implants can help to avoid wound complications. Although textured, anatomically shaped implants have gained popularity, it is the authors' opinion that usually, the smooth round implants perform best in combined mastopexy/augmentation surgery by removing the variable of rotational alignment intraoperatively required with the use of anatomically shaped implants.

## 8. Preferred technique

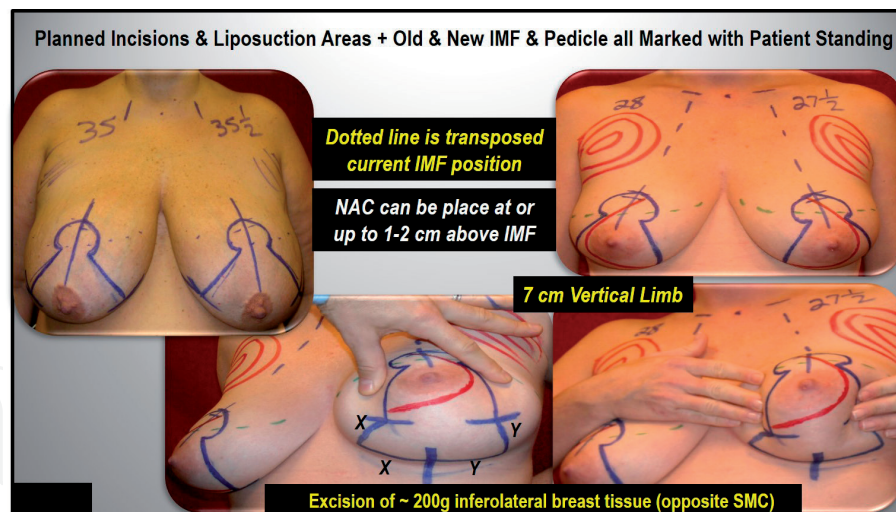
Operative sequence for the authors preferred technique differs from others in that the mastopexy is performed first and implant placement is performed prior to closure. Although, theoretically this could increase the risk of over resection of skin, this has not often been encountered with thoughtful skin marking/resection and implant selection. The primary advantage gained is the ability to place the implant in a total submuscular plane and more fully manipulate the skin and glandular elements of the procedure. It also can be challenging to estimate ideal implant position prior to the mastopexy when there is significant ptosis or asymmetry combined with the typical alteration of the inframammary crease that can occur during mastopexy. It is for these reasons that the mastopexy is initiated first followed by implant placement, then glandular manipulation as required and finally skin closure.

### 8.1 Marking

Mastopexy marking is performed with an indelible marker with the patient in upright or standing position for obvious reasons. A mastopexy template is beneficial and can facilitate symmetry. Either a Wise pattern or vertical pattern is marked with emphasis on positioning the NAC at or slightly above the inframammary crease. In cases where you may be unsure if a horizontal skin excision will be required it is advisable to mark the patient with a vertical excision plan (**Figure 9**). Minor horizontal excision can be done accurately and easily intraoperatively. However, most cases requiring any significant degree of skin resection or NAC elevation, are best served by Wise pattern excision which controls the nipple to fold



**Figure 9.** Marking for a simultaneous lift/augmentation is always performed with the patients standing and arms to the side. As shown for limited ptosis case, the vertical mastopexy marks are along the nature breast axis after lateral and medial displacement of the parenchyma. The base of the vertical must stop 1–2 cm above the IMF to prevent scarring below the fold after closure.



**Figure 10.**

*Marking a planned inverted T incision for a lift/augmentation on a larger breast is similar to marking a vertical mastopexy until vertical limbs are complete. Next, the horizontal incision is typically placed approximately 1 cm above the planned IMF and horizontal limbs kept as short as possible to match the residual skin on each side of the breast axis line as shown (X, Y).*

distance to a greater degree (**Figure 10**). When marking the vertical and horizontal limbs of the pattern, it is advisable to err on the side of more conservative resection, given that volume will be added by the implant. Some flexibility in the surgery is added by using implant sizers during the procedure and having multiple implant sizes available intraoperatively. Occasionally, it may be beneficial to use either a larger or smaller implant than initially planned for.

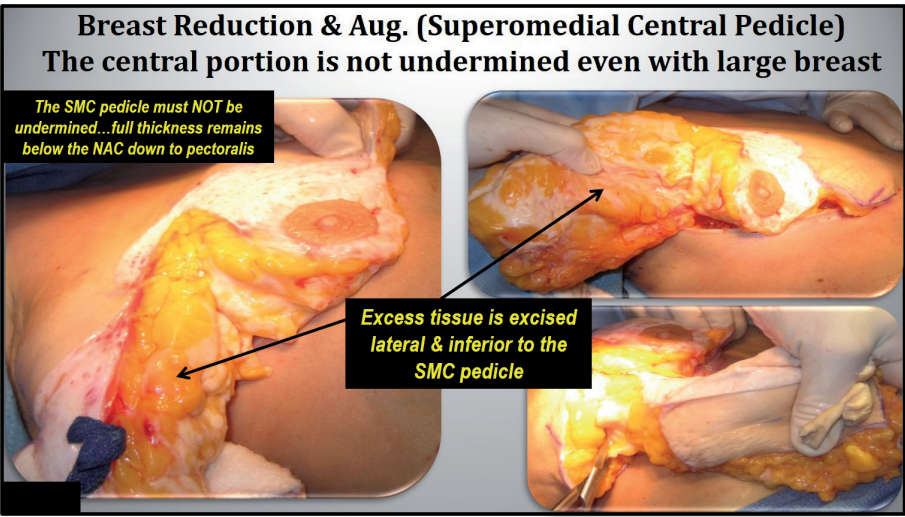
## 8.2 Anesthesia

General anesthesia is required when performing this procedure given the amount of muscle manipulation. However, tumescent local anesthesia can facilitate easier dissection and resection while minimizing the depth of general anesthesia required. This will decrease postoperative pain requirements and risk of nausea and vomiting, both of which can complicate the early postoperative period. A modified Klein solution (0.5% lidocaine with 1:500,000 epinephrine) is injected into the planned incisions, subpectorally and most importantly into the dermis in the areas of planned de-epithelialization. This is typically done preoperatively in the OR with the patient asleep after a quick prep with alcohol or 4% chlorhexidine. Once administered the patient is repped and draped in standard fashion.

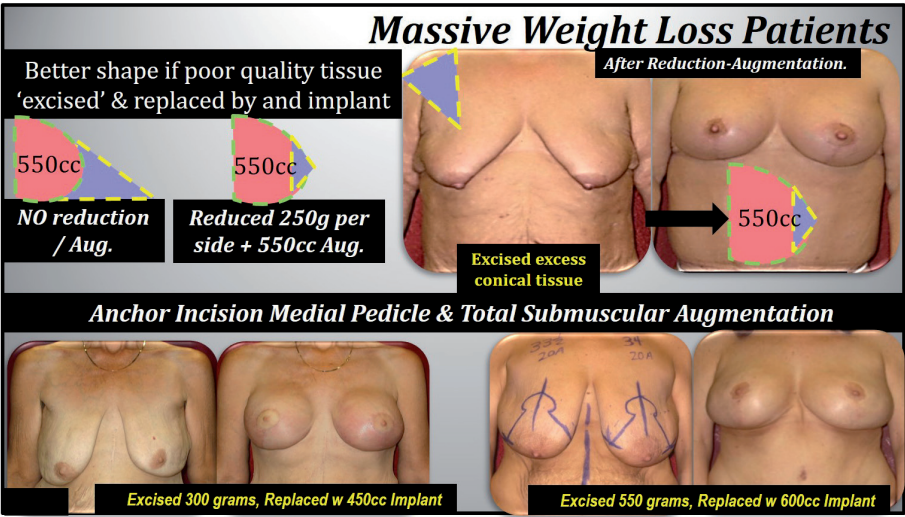
## 8.3 Technique

The surgery is initiated by placing an areolar imprint with an appropriately sized areolar marker centered over the nipple itself. Then, partial thickness incisions are made, followed by de-epithelialization within the planned incisions. Caution is a must so not to undermine the new NAC. While removal of excess fat and gland helps improve shape and longevity, care must be used to leave adequate tissue below the NAC (central pedicle) as well as adequate tissue below each vertical limb. This is followed by development of the pedicle, and en bloc resection of excess or ptotic glandular tissue (**Figure 11**). Typically resecting portions of the inferior, lateral and superolateral area of the keyhole are common for the SMC pedicle. More is removed from the inferior glandular tissues versus less resection superiorly. However sufficient tissue must be removed from the keyhole area to allow inset of the NAC and pedicle without compression or congestion. The inferior excision is completed





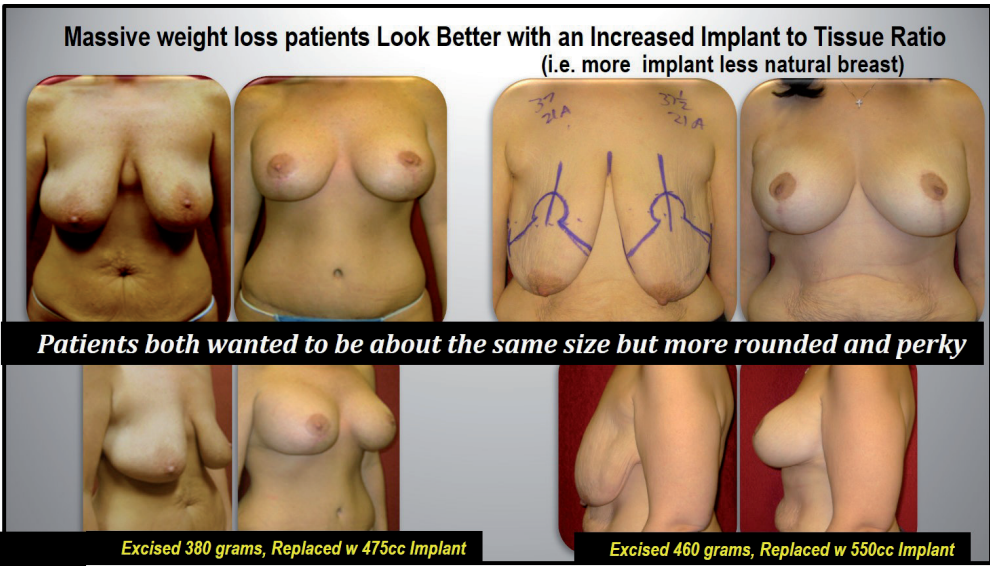
**Figure 11.**  
Excision of redundant skin as well as fat and parenchyma is critical for long term maintenance of the lift. But, as shown, care must be used to not remove too much tissue below the NAC and avoid thinning the flaps below the vertical limbs.



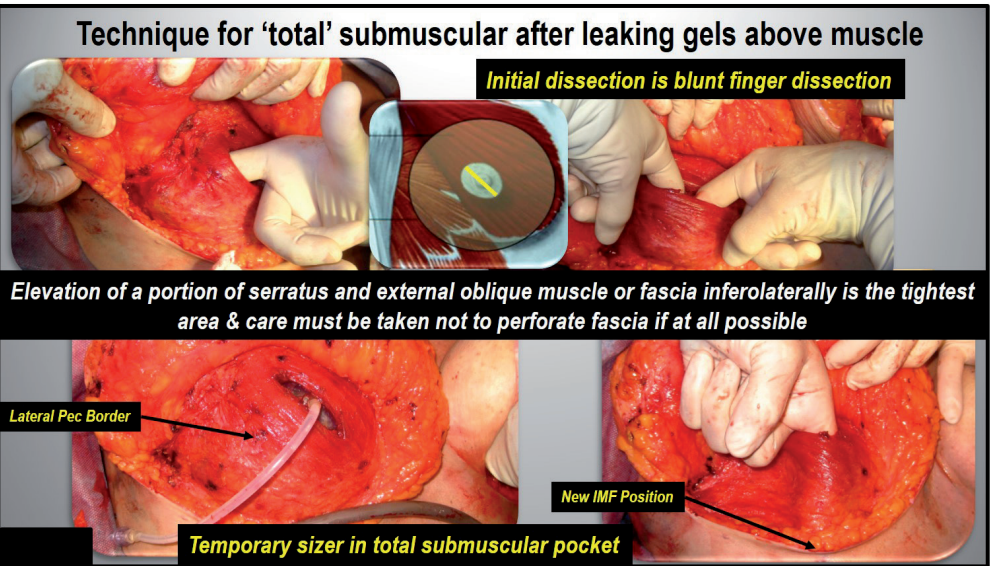
**Figure 12.**  
Three separate patients are shown who lost over 100 lbs. by gastric bypass prior to having simultaneous mastopexy and augmentation. The key for this subset of patients is to remove as much of the excess poor quality mammary tissue and fat as well as skin. This is especially helpful when the breast shape is constricted or conical.

down to the level of the pectoral fascia, but without insult or injury. Excision of tissue is especially important in massive weight loss patients whose residual excess tissue will sag later if not removed (**Figure 12**). Excising as much as possible safely on this subset of patients and allowing a larger implant will produce better longevity and appearance compared to excising little tissue and use of a smaller implant (**Figure 13**). After excision, attention is taken to expose only the inferolateral aspect of the pectoral border for a few centimeters medially. This will allow myotomy paralleling the fibers of the pectoralis major into the postpectoral space while not injuring the central deep component of the glandular pedicle. Once in the postpectoral space, circumferential blunt dissection is initiated with a finger. Inferolaterally, using a sweeping maneuver with the forefinger it is typically easy to lift fibers of the anterior serratus and external oblique muscles (**Figure 14**). Occasionally it may be necessary to utilize limited cutting cautery to aid in pocket development. Once the total submuscular pocket is developed, a lighted retractor will aid in minor sub



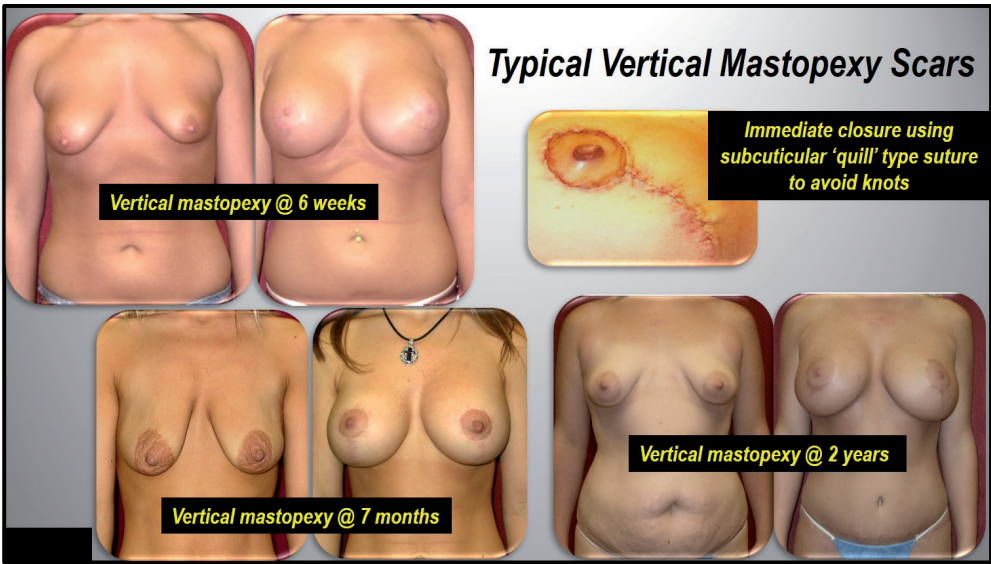


**Figure 13.**  
*Massive weight loss patients who desire to be the “same size” but “round and perky” typically will not be happy with a mastopexy alone because of the poor quality of residual tissue. Reduction and augmentation is required as shown to obtain the results most patients will find pleasing.*

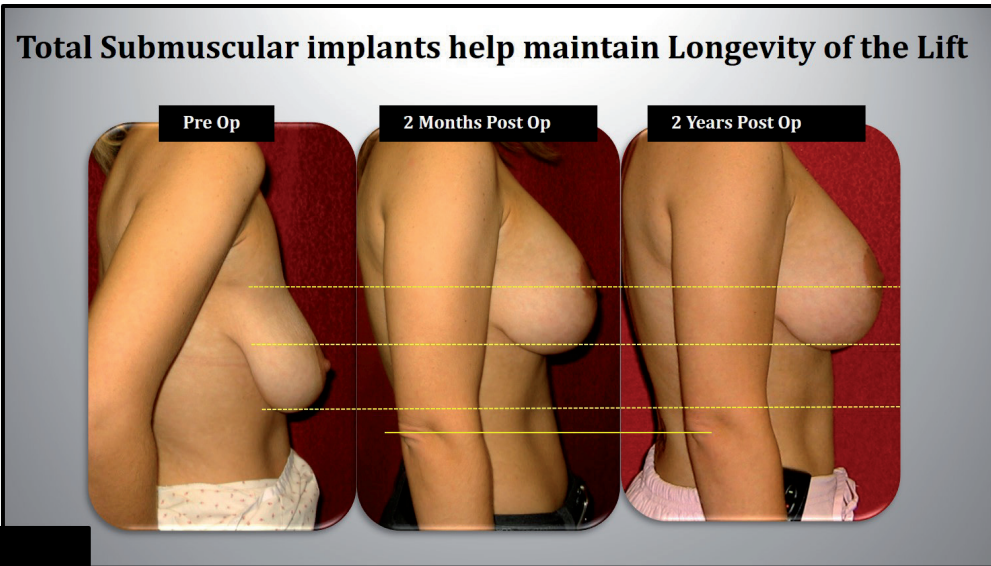


**Figure 14.**  
*Elevation of a “total” submuscular coverage pocket is shown during initial finger sweeping. Slow, cautious elevation inferomedially prevents perforation of the flap that is thinner in that location. Lighted retractors are used past initial finger dissection for residual elevation as required and hemostasis.*

muscular release if needed for inferior pole expansion and with hemostasis within the pocket. Hemostasis must be performed and verified at multiple points throughout the surgery. After verifying the pedicle and NAC transpose easily into position, the superior trifurcation is closed at the deep dermal level and the NAC pexied into position. Preventing excessive tension at this point greatly improves final scar formation (**Figure 15**). Total submuscular coverage also takes some pressure off the incision line and aids in longevity (**Figure 16**). A sizer can then be placed into the sub muscular pocket and inflated to the desired size. This maneuver can help with assessing implant pocket dimensions and expected tension on the NAC and superior trifurcation closure. The sizer can then be replaced with the corresponding implant and the remaining incisions can then be closed in standard layered fashion with care to carefully align the skin edges and evenly distribute pleating throughout the mastopexy incisions. Glandular pillars may be reapproximated gently with 1–2 resorbable



**Figure 15.**  
*The vertical limb of the mastopexy greatly improves the scar appearance around the areolas by decreasing radially pressure away from the center. As the patient examples demonstrate, the vertical incision is often required to decrease the diameter of the NAC or at least prevent widening that can often be seen from a donut mastopexy.*



**Figure 16.**  
*Demonstration of the longevity benefits from excision of excess glandular tissue as well as total submuscular coverage of the implant as shown. Recurrent ptosis is it occurs is typically from patient weight gain and enlargement of tissue above the implant.*

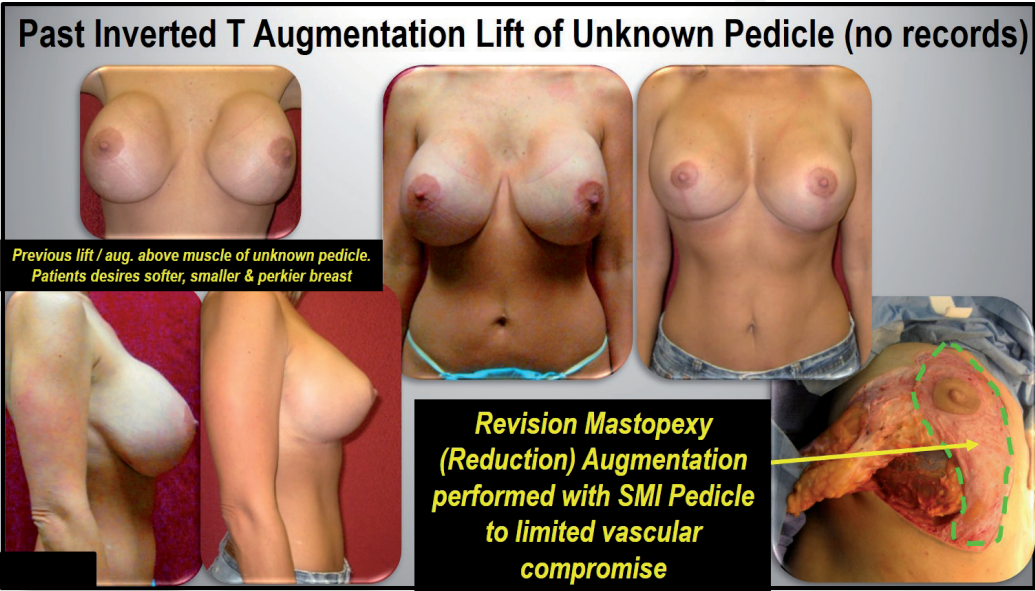
sutures as required to improve shape and projection. Over plication must be avoided. Occasionally, it may be beneficial to perform minor liposuction to the lateral breast if excess fat or fullness at the lateral pole of the incision is present.

## 9. Revision mastopexy/augmentation

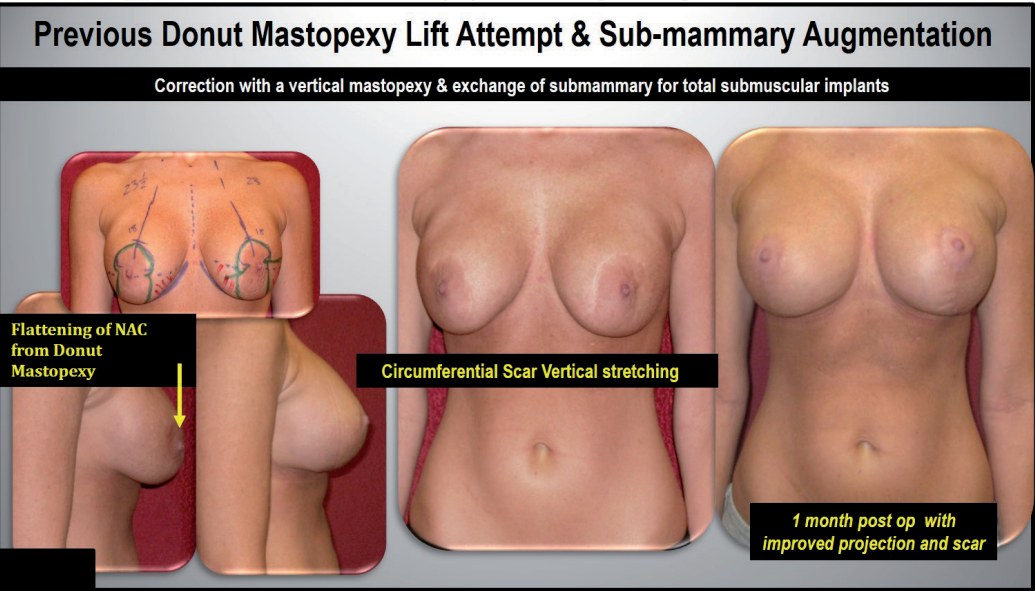
Revision mastopexy/augmentation surgery can be quite difficult but also very rewarding and is a necessary component for anyone offering these procedures. The acknowledgment of an undetermined blood supply and the potential for NAC ischemia is paramount when considering revision surgery. Although prior operative reports may be beneficial, they can be unreliable as to the actual pedicle utilized and great caution must be used. Avoidance of wide excision patterns or significant



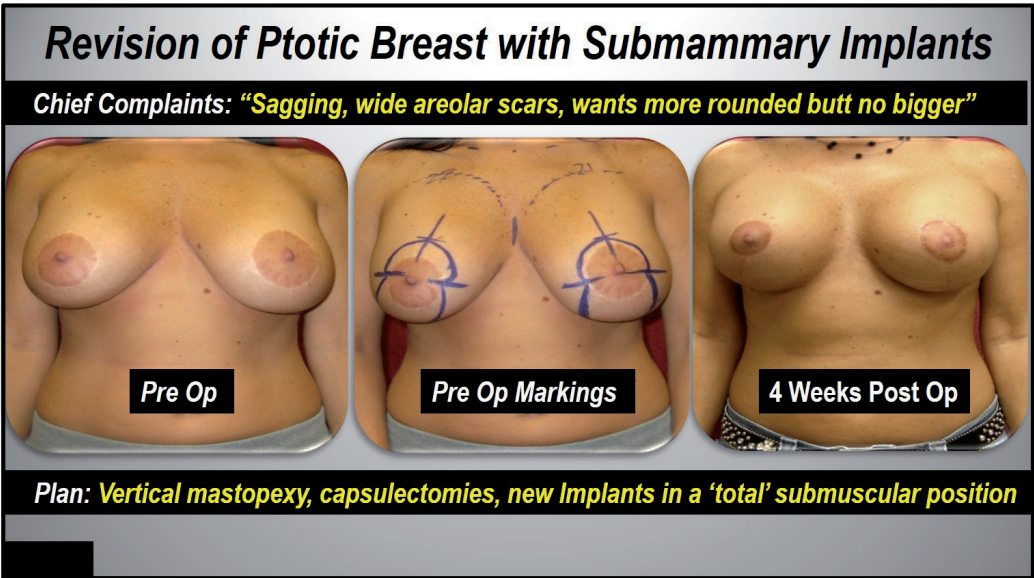
undermining is advisable. Occasionally multiple pedicles can be combined in some situations to help limit ischemia when the prior pedicle use is unknown (**Figure 17**). Foremost, patients requiring a second mastopexy with or without implant replacement should be informed and educated about potential loss of skin and/or the NAC. Some revision cases may require staging, particularly if they have large subglandular implants, due to the inability to depend on accessory central blood supply to the nipple. The addition of capsular contracture and need for capsulectomy adds even more risk. These patients likely require explantation and capsulectomy first followed by revision mastopexy/augmentation secondarily. When choosing to perform a simultaneous revision mastopexy augmentation and pocket exchange the surgeon must be extra diligent to limit any maneuver that compromises vascularity more than absolutely required (**Figure 18**). The pectoral artery branches have



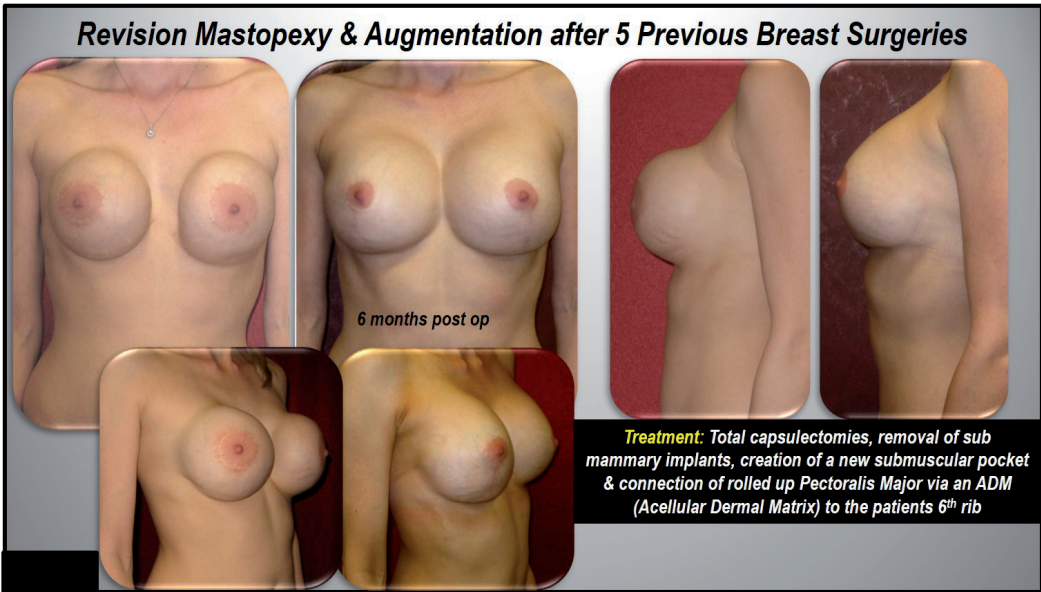
**Figure 17.** Patients who have had previous mastopexy & augmentation of an unknown pedicle type present potentially more risk. When possible, using limited dissection and a combined pedicle such as the superomedial-inferior (SMI) shown can avoid unwanted disruption of already decreased vascularity to the NAC.



**Figure 18.** The patient shown has the classic problem from a circumferential mastopexy that stretched vertically and residual ptosis. She was corrected by complete capsulectomies, new total submuscular implants and revision vertical mastopexy.



**Figure 19.**  
Revision on a patient who had a circumferential mastopexy and the more common widening pattern of scar formation. The patient wanted smaller areola with better scars, perkier breast and slightly smaller size breast than before.

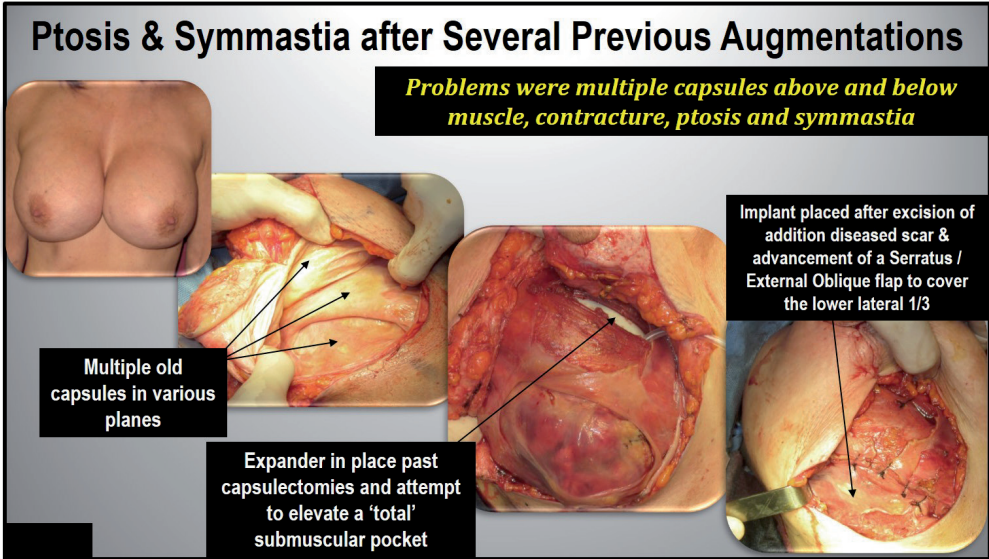


**Figure 20.**  
The figure demonstrates revision on a patient with multiple past surgeries of various types and chronic history of capsular contracture. Damage to the residual muscle necessitates the use of an acellular dermal matrix to connect the residual lateral pectoralis border to the new IMF.

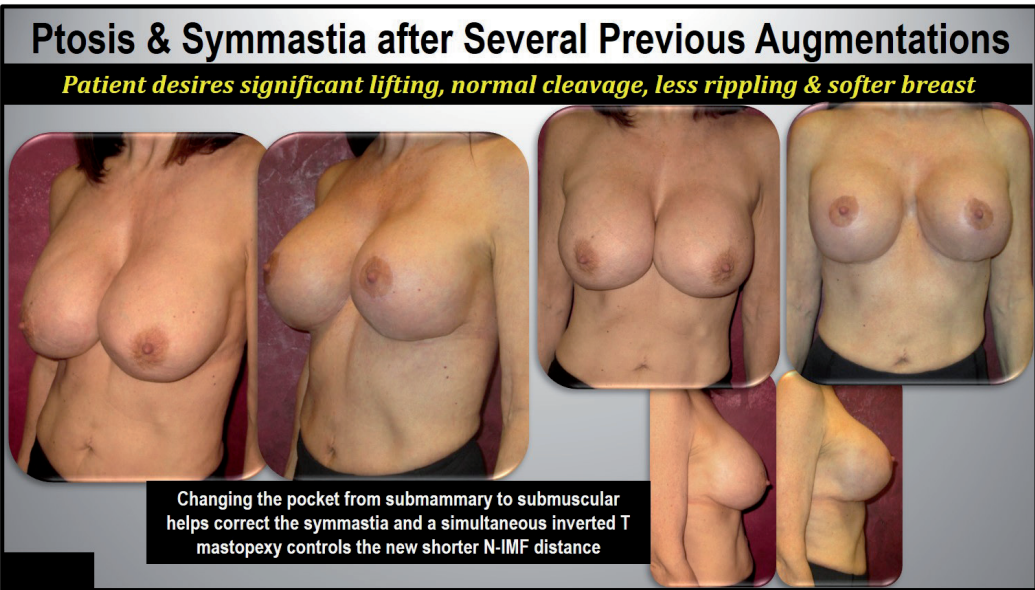
already been severed from the past Submammary augmentation removing the normal central pedicle portion of vascularity.

Unsatisfactory scarring is typically the most required revision and fortunately is often fairly straightforward. The opposing forces of mastopexy skin excision and augmenting breast volume may lead to widened and unsatisfactory scars on occasion. This is usually remedied with standard scar revision techniques and has a high rate of success with a careful tension free closure. NAC irregularity or asymmetry can be seen and is typically improved best by adding a vertical incision to reduce tension around the NAC. Of particular note is the tendency for isolated periareolar lifts to widen with time, independent of suture type used and especially when combined with augmentation (**Figure 19**). The proper correction of this relies on the addition of a small vertical





**Figure 21.**  
*Damage to the residual muscle shown was corrected by excising the old capsules from multiple surgeries and developing an inferolateral submuscular flap to elevate the serratus and external oblique as shown. Recruited muscle and fascia was used in place of an ADM.*



**Figure 22.**  
*Simultaneous correction of ptosis and symmastia was performed using an inverted T mastopexy because of the extent of excess skin and new pocket creation to correct the symmastia.*

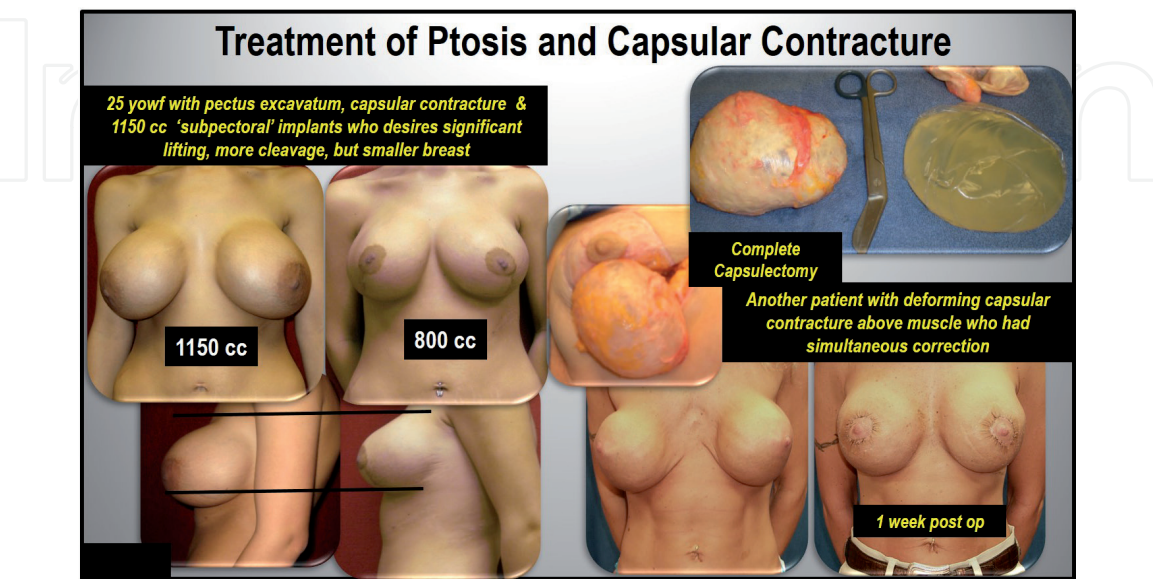
component with periareolar revision. This will take tension off the new areolar diameter and return a more conical appliance to the breast that is often flattened with Benelli-type lifts.

Implant malposition is a common complication with augmentation alone and is certainly encountered with post mastopexy/augmentation. The most common malposition is inferiorly and laterally. Standard pocket modification procedures are similarly beneficial as they are post augmentation alone. However, soft tissue reinforcement may be required as some patients will have less than desired intrinsic tissue integrity. Acellular dermis and bio-resorbable silk derived scaffolds are the mainstays of tissue reinforcement in reconstructive cases and have been used with success in the revision of cosmetic breast cases (**Figure 20**) [3]. This is particularly true when capsular contracture exists and multiple surgeries in the past have taken place. Occasional localized adjacent muscle flaps can be used to

cover the gaps and gain better implant coverage (**Figure 21**). Revision of symmastia if found simultaneously with ptosis issues requires either staging, new pocket development, or ADM usage (**Figure 22**).

## 10. Complications

As with even simple breast surgery, there is a notable complication rate. Consistently, studies have shown 15–25% reoperation rates post primary augmentation, and clinical experience shows that this rate is consistent when augmentation is combined with mastopexy [10]. Interestingly, these studies have shown the complication rates to not be exponential or even additive when combined surgery is performed versus a two stage approach [11, 12]. This is likely explained by the occasional patient specific intrinsic difficulties associated with either mastopexy and augmentation alone along with more careful patient selection when combining procedures. And fortunately, significant complications like implant extrusion, infection and nipple necrosis are very uncommon. Should nipple ischemia be noted intraoperatively, several maneuvers may reverse the impending danger. Evacuation of periareolar hematoma and strict hemostasis is the simplest step, otherwise nitroglycerin paste or spray immediately postoperatively to the NAC for minor ischemia is beneficial by improving venous congestion. However, should the ischemia be more profound, early removal of sutures and/or the implant will likely improve blood supply and venous drainage. Lastly, consideration of hyperbaric therapy in the early postoperative period, although cumbersome and not well defined in the literature, has shown evidence of dramatic reversal in impending necrosis [13]. Fortunately, the most significant reasons for reoperation are typically unfavorable scarring, capsular contracture, hematoma and implant malposition [14]. Excising entire capsules because of capsular contracture increases risk of hematoma especially when combined with ptosis correction (**Figure 23**). These are managed in a similar manner for either augmentation or mastopexy alone and methods to minimize these complications and the need for subsequent revisions are not very different than for either mastopexy or augmentation alone. For instance, the authors do not perform mastopexy surgery on current smokers for well-defined reasons, and of course this



**Figure 23.** Simultaneous correction of ptosis and capsular contracture adds to an already high revision rate and complication rate of simultaneous mastopexy/augmentation. The patients shown are even higher risk because of thin tissue and large implant size.

includes candidates for simultaneous surgery as well. As previously mentioned, a more conservative methodology for implant size selection is recommended in combined surgery in order to minimize wound tension and ischemic stress on the NAC. Otherwise, simultaneous mastopexy and augmentation is planned with a similar risk stratification to other cosmetic breast procedures, albeit with more regard for the rarer more devastating complications discussed above [15].

## 11. Summary

Simultaneous mastopexy and augmentation is challenging, but also highly rewarding and well accepted by informed patients. A clear understanding of not only the individual procedures, but the added variables involved when combining these techniques will greatly aid the surgeon in obtaining safe and predictable results while keeping the vast majority of complications relatively minor.

### Author details

Angelo Cuzalina<sup>1\*</sup> and Landon McLain<sup>2</sup>

1 Tulsa Surgical Arts, USA

2 McLain Surgical Arts, Huntsville, USA

\*Address all correspondence to: [angelo@tulasurgicalarts.com](mailto:angelo@tulasurgicalarts.com)

### IntechOpen

© 2019 The Author(s). Licensee IntechOpen. This chapter is distributed under the terms of the Creative Commons Attribution License (<http://creativecommons.org/licenses/by/3.0>), which permits unrestricted use, distribution, and reproduction in any medium, provided the original work is properly cited. 



## References

- [1] Netter FH. Atlas of Human Anatomy. 2nd ed. Philadelphia: PA, Novartis; 1997. p. 525
- [2] Hauben DJ, Adler N, Silfen R, Regev D. Breast-areola-nipple proportion. *Annals of Plastic Surgery*. 2003;**50**(5):510-513
- [3] Spear SL, Willey SC, Robb GL, Hammond DC, Nahabedian MY. *Surgery of the Breast: Principles and Art*. 2nd ed. Philadelphia: Lippincott Williams and Williams; 2006. p. 1517
- [4] Nahai F. *The Art of Aesthetic Surgery: Principles and Techniques*. 2nd ed. St. Louis: MO, Quality Medical Publishing; 2011. p. 3187
- [5] Hall-Findlay EJ, Spear SL, Davison SP. New trends in reduction and mastopexy vertical breast reduction. *Seminars in Plastic Surgery*. 2004;**18**(3):211-224
- [6] Brown RH, Siy R, Khan K, Izaddoost S. The superomedial pedicle wise-pattern breast reduction: Reproducible, reliable, and resilient. *Seminars in Plastic Surgery*. 2015;**29**(2):94-101
- [7] Nahabedian MY, McGibbon BM, Manson PN. Medial pedicle reduction mammoplasty for severe mammary hypertrophy. *Plastic and Reconstructive Surgery*. Philadelphia: PA; 2000;**105**(3):896-904
- [8] Aston SJ, Steinbrach DS, Walden JL. *Aesthetic Plastic Surgery*. Saunders Elsevier; 2009. p. 946
- [9] Henriksen TF, Fryzek JP, Holmich LR, et al. Surgical intervention and capsular contracture after breast augmentation: A prospective study of risk factors. *Annals of Plastic Surgery*. 2005;**54**:343-351
- [10] Gutowski KA, Mesna GT, Cunningham BL. Saline-filled breast implants: A plastic surgery educational foundation multicenter outcomes study. *Plastic and Reconstructive Surgery*. 1997;**100**:1019-1027
- [11] Adams WP Jr. Discussion: Simultaneous augmentation mastopexy a retrospective 5-year review of 332 consecutive cases. *Plastic and Reconstructive Surgery*. 2013;**131**(1):157-158
- [12] Stevens WG, Macias LH, Spring M, Stoker DA, Chacón CO, Eberlin SA. One-stage augmentation mastopexy: A review of 1192 simultaneous breast augmentation and mastopexy procedures in 615 consecutive patients. *Aesthetic Surgery Journal*. 2014;**34**(5):723-732
- [13] Copeland-Halperin LR, Bruce SB, Mesbahi AN. Hyperbaric oxygen following bilateral skin-sparing mastectomies: A case report. *Plastic and Reconstructive Surgery*. Global Open. 2016;**4**(4):e680
- [14] Stevens WG, Nahabedian MY, Calobrace MB, et al. Risk factor analysis for capsular contracture: A 5-year Sientra study analysis using round, smooth, and textured implants for breast augmentation. *Plastic and Reconstructive Surgery*. 2013;**132**:1115-1123
- [15] Calobrace MB, Herdt DRBS, Cothron KJ. Simultaneous augmentation/mastopexy: A retrospective 5-year review of 332 consecutive cases. *Plastic and Reconstructive Surgery*. 2013;**131**(1):145-156