

We are IntechOpen, the world's leading publisher of Open Access books Built by scientists, for scientists

6,900

Open access books available

186,000

International authors and editors

200M

Downloads

Our authors are among the

154

Countries delivered to

TOP 1%

most cited scientists

12.2%

Contributors from top 500 universities



WEB OF SCIENCE™

Selection of our books indexed in the Book Citation Index
in Web of Science™ Core Collection (BKCI)

Interested in publishing with us?
Contact book.department@intechopen.com

Numbers displayed above are based on latest data collected.
For more information visit www.intechopen.com



Surgical Principles for Spinal and Paraspinal Neurofibromas

Feyzi Birol Sarica

Abstract

Neurofibromas are the most prevalent seen tumor in the neurofibromatosis type 1 (NF1) disease. Spinal neurofibromas, which are the major diagnostic criteria of disease, are seen in approximately 60% of the patients with NF1. They constitute 23% of all of the spinal tumors. While the spinal neurofibromas most frequently show a location in thoracic region, it is followed by their predilection in cervical and lumbar regions, respectively. The spinal neurofibromas located in the sacral region are quite rarely observed and show an asymptomatic course until reaching to the big sizes. Of these spinal neurofibromas, 72% were with intradural extramedullary, 14% with extradural, and 13% with intradural and extradural “dumbbell formation.” Only 1% of the spinal neurofibromas are intramedullary located. The total taking of the single solitary neurofibroma surgically is relatively easier. But, the difficulties can be encountered in taking these tumors surgically since they are characterized by the multiple tumors in the plexiform neurofibromas, especially accompanying to the NF1. In this chapter, the surgical difficulties encountered in the region in which the tumor is localized and different surgical approaches are developed in the course of time in order to exceed these difficulties are described.

Keywords: dumbbell neurofibroma, dumbbell tumor, neurofibromatosis type 1, NF1, paraspinal neurofibroma, spinal nerve sheath tumor, spinal neurofibroma, surgery, surgical approach, surgical treatment, von Recklinghausen disease

1. Introduction

The close follow-up is clinically and radiologically suggested in the asymptomatic spinal neurofibroma cases that do not make pressure on the spinal cord and important nerve roots. But, surgical tumor resection is preferred in the tumors showing rapid growth and/or causing the progressive neurodeficits. The total taking of the single solitary neurofibroma surgically is relatively easier. But, the difficulties can be encountered in taking these tumors surgically since they are characterized by the multiple tumors in the plexiform neurofibromas, especially accompanying to the NF1. Different surgical approaches had been described for the tumor’s total resection in the spinal neurofibroma cases, in which the surgical difficulty is observed at most and which show a *dumbbell formation*. While a single-stage posterior approach was used for dumbbell tumors having a small extraspinal component, the single-stage combined posteroanterior approach had been preferred in those having a big extraspinal component. In time, the two-stage combined posteroanterior approach had been started to be used instead of the

single-stage combined posteroanterior approach in order to eliminate the excessive hemorrhage risk arising from the length of surgery duration. In this approach, the dumbbell tumor is firstly taken by the intraspinal component's posterior approach, and then, by giving a certain period, the tumors' extraspinal component is taken by the anterior approach. In time, the lateral approaches applied by using the extensive posterolateral exposure had been described instead of the single-stage or two-stage combined posteroanterior approaches in order to totally take the dumbbell tumors, in which especially huge extraforaminal component is found. A wider visual angle can be provided by the lateral approaches to the spinal channel lateral, intervertebral foramen, and extraforaminal regions, and the tumor can be totally taken in a single session.

2. Neurofibromatosis type 1

2.1 Epidemiology of the NF1

The neurofibromatosis expressing a tumor-predisposing syndrome group is characterized especially by the tumors found in the CNS and peripheral nervous system. NF1 constituting 96% of the neurofibromatosis patients is the most frequently seen form. It is followed by the neurofibromatosis type 2 with the rate of 3% and Schwannomatosis recently defined. The NF1, of which its most extensive definition had been made by Friedrich von Recklinghausen in 1882 for the first time, is named with "von Recklinghausen disease." Moreover, since it is described by the multiple neurofibromas that are one of the peripheral nerve sheath tumors with benign character, they are also named as the "peripheral neurofibromatosis." The NF1, the most frequently seen phakomatosis, shows an autosomal dominant hereditary transmission, and its prevalence incidence is approximately 1 per 2500–3000 births [1, 2].

2.2 Natural history and genetic alterations of the NF1

The gene that is responsible for the NF1 formation is found in the 17q11.2 chromosome and contains 280 kbp DNAs. The tumor is a suppressor gene. The *NF1 gene* provides the synthesizing protein named as the "neurofibromin" that is found in Schwann cell at a high level and acts as a tumor suppressor [3]. Neurofibromin, which has an activating effect of the GTPaz, also regulates the cellular proliferation and differentiation by inactivating the RAS that is a cytosolic signal transduction proto-oncogene [4]. Neurofibromin level decreases in varying degrees in the "NF1 gene" mutations, and as a result, it leads to a formation of the various ectodermal and mesodermal tumors that are seen in the NF1 together with the different penetration types of NFs. In conclusion, the peripheral nerve sheath tumors frequently occur in particular to the neurofibroma. Moreover, prevalence incidence of the CNS tumors such as glioma, ganglioglioma, and neuroblastoma as well as the other malignancies such as leukemia, pheochromocytoma, Wilms tumor, and sarcoma increases [4, 5]. Fifty percent of the mutations in NF1 gene are in the form of spontaneous mutations of which family history is not found, and the remaining is in the form of hereditary mutations of which family history is found. Even though there are high penetration values in those having a hereditary mutation, the different phenotypic presentations can be observed between the family members due to the probable epigenetic modification [4–6]. One thousand and five hundred different *NF1 gene* mutations have been notified until today, while a slight phenotypic represented by the NF1 table had been observed in the presence of mosaicism;

a serious phenotypic represented by the NF1 table had been observed when the 17q11.2 microdeletion was detected [7].

2.3 Clinical presentations of NF1

Diagnosis in the NF1 bases upon the clinical criteria despite the progressions in the molecular genetics. The criteria listed for the NF1 clinical diagnosis had been determined in the “NIH Consensus Development Conference” in 1987 [8] (Table 1).

2.3.1 Pigmentation abnormalities

Although these criteria observed in the NF1 show a variation between the patients according to the penetration type, at least two of the NIH criteria are found in 30% of the cases to the age of 1 and in 97% of the cases to the age of 8. The café au lait macules seen in 95% of the adult cases with NF1 are the skin macules that are found in an oval shape and are hyperpigmented and light brown colored. They can be observed during birth. But, its number and size increase in the first decade. Being found of the café au lait macule in number of 6 and more with the dimension of 5 mm or larger in the prepubertal period and 15 mm or larger in the postpubertal period according to the NIH criteria is in the common features of NF1. The café au lait macules, which are not only intrinsic to NF1, can be seen by the other genetic syndromes such as McCune Albright syndrome, Legius syndrome, and Silver-Russell dwarfism. The malign transformation potential is not found in these macules since they can be only seen in 10% of population [1, 2, 9]. Another pigmentation anomaly seen in the NF1 is axillary and inguinal freckling. These hyperpigmented spots that can also exist at birth come to existence afterward and are observed in 90% of the cases with NF1 under the age of 7 years [2]. The most frequently encountered eye finding in the adult patients with NF1 is Lisch nodules with the rate of 95%. Lisch nodules are asymptomatic, small, and superficial melanocytic hamartomatous nodules generally observed as multiple in the iris. They are observed in the shape of a dome and in the form of yellow-brown lesions in the slit-lamp examination [1, 10].

2.3.2 Tumors of the optic pathway

The eye finding determined in patients with NF1 in the second frequently observed finding with the rate of 15% is an optic pathway glioma and takes part

| | |
|---|---|
| 1 | The presence of six or more café au lait macules 5 mm or more in size during prepuberty or 15 mm or more in size during postpuberty |
| 2 | The presence of two or more neurofibromas of any type or the presence of one plexiform neurofibroma |
| 3 | The presence of freckling in the axillary and inguinal regions |
| 4 | The presence of optic glioma |
| 5 | The presence of two or more Lisch nodules (iris hamartoma) |
| 6 | The presence of bone anomalies, such as long bones with thin cortex without arthrosis, together with sphenoid aplasia or arthrosis |
| 7 | The presence of NF1 diagnosis in first-degree relatives according to the diagnosis criteria written above |
| *Two or more of the above points should be present in the cases diagnosed with NF1. | |

Table 1.
Neurofibromatosis type-1 diagnosis criteria of the National Institutes of Health [8]*.

between the important diagnosis criteria. The optic pathway glioma is the most frequently observed glioma type in patients with NF1. They are found in the low-grade glial tumors (WHO grades I and II). The region, in which the optic pathway glioma is frequently localized, is prechiasmatic region. They are frequently presented in the form of an optic nerve pilocytic astrocytoma (WHO grade I). The visual field defects give the clinical finding such as a decrease in the visual acuity, proptosis, and diplopia in the optic pathway gliomas that are generally presented to the age of 7 [1, 6, 11, 12]. The brainstem glioma (pilocytic astrocytoma, WHO grade I), glioblastoma multiforme (GBM, WHO grade IV), and ganglioglioma (WHO grade I) can be enumerated between the other gliomas that are less frequently observed in the cases with NF1. The development risk of GBM having a quite aggressive course among them had increased approximately five times in the cases with NF1. The schwannomas and meningiomas originating from any cranial nerve sheath can be enumerated among the other intracranial tumors accompanying to the NF1.

2.3.3 Cognitive function disorders and NF1 bright object

One of the non-tumoral CNS lesions observed in patients with NF1 is the lesions named as “NF1 bright object,” and they are observed at the rate of 43–93%. The hyperintense lesions, of which borders are significant in the magnetic resonance imaging (MRI) T2 sequences, are frequently localized in the subcortical white matter fields, basal ganglions, and capsula interna in the brain. These lesions named as the *NF1 bright object* are held responsible for cognitive malfunctions such as the mental retardation, learning disorder, and speech disorder observed in patients with NF1 [13, 14].

2.3.4 Skeletal manifestations

The deformities observed in the various bones accompany to the cases with NF1. The most frequently observed skeletal deformity is kyphoscoliosis, which develops depending on the vertebral bone deformities, especially in the cervicothoracic region. The neurodeficits at various levels can be observed in the cases with NF1 depending on the rapid increase in the degree of kyphosis and scoliosis. Another vertebral bone anomaly observed at the rate of 10% is the dorsal scalloping in the vertebral bones. These tables develop independently from the spinal neurofibromas observed in the NF1 [15]. Moreover, the tumor's intraspinal part can cause the destruction on the intervertebral foramen walls when extending to the extraspinal cavities by passing through the intervertebral foramen in the spinal neurofibroma cases constituting the *dumbbell formation*, and in this case, the intervertebral foramen enlargement and thinning can be radiologically observed in the adjacent vertebra pedicles.

A thinning had been also observed in cortexes of the long bones such as the radius and tibia and between the other skeletal deformities observed in patients with NF1. The ptosis is accompanied by vitamin D levels in the bone densitometer, osteopenia, and laboratory tests made for patients with NF1 [12]. It had been determined that fracture development risk secondarily increased three to five times in the cases with NF1 according to the normal population in these tables [16]. Although the body rates were normal in many cases with NF1, the growth hormone insufficiency and pubertas praecox had been held responsible as the reason of short stature developed [12].

Moreover, the anomalies also accompany to the cranial bones in the cases with NF1. The parieto-occipital bone defects, sphenoid wing dysplasia or aplasia, and

pulsatile exophthalmia developed depending on the unilateral defect on the orbital superior wall are observed between them. Moreover, the head asymmetry, macrocephaly, and mandibular bone deformities can be also accompanied [1, 10].

2.3.5 Tumors of the gastrointestinal system

The tumoral formations are also observed in the gastrointestinal system in patients with NF1. The most frequently accompanying tumor to the NF1 is gastrointestinal stromal tumors with the rate of 25% between them [17], and they occur as a result of the KIT and PDGFRA mutations. These tumors, of which sizes are small, do not generally give the clinical finding. Moreover, endocrine tumors of the gastrointestinal system such as somatostatinoma, gastrinoma, and insulinoma can be also observed in the cases with NF1. These tumors are most frequently in the tendency to localize in the periampullary region. However, the gastrointestinal system can be held by the focal or prevalent neurofibromas and present the clinical findings characterized by the internal organ dysfunction.

2.3.6 Nodular (intraneural), cutaneous (diffuse), and plexiform neurofibromas

The nodular neurofibromas (*intraneural form*), which are also named as solitary, are the most frequently seen form as sporadic independent from the NF1. The localization predilection is not found in the neurofibroma, which is most frequently seen in the third and fourth decades. Their borders are relatively significant and characterized by slow-growing tumors in an oval and elastic shape since they show an intraneural growth pattern in a single nerve. The nodular neurofibromas, which frequently originate from the dorsal nerve roots, are frequently presented by ache, hearing disorders, and power loss in the clinic [18, 19].

The cutaneous neurofibromas (*diffuse form*) are seen in approximately 10% of the patients with NF1, located in the skin and subcutaneous tissue. They can be seen in the pedunculated and nodular forms or similar forms like the plaque. They are frequently observed in the neonatal and adolescent periods, and an increase is observed in their numbers together with the age [1, 11, 12, 18].

The plexiform neurofibroma is the most frequently seen one with the rate of 30% in patients with NF1. They had taken this name since they presented a plexiform growth pattern in such a way that it would contain more than one fascicule, nerve, or plexus branches. The characteristic “worm bag” term had been also used for these tumors due to their surgical macroscopic appearances. They are characterized by fusiform-formed multiple neurofibromas observed throughout peripheral nerves. They frequently hold the main nerve body including the brachial and lumbar plexuses. If a big nerve is held in the extremities, they can also lead to a local gigantism table in the extremity, which is named as the “elephantiasis neuromatosa.” They frequently develop in the childhood period, and the plexiform neurofibromas, which make pressure to the adjacent tissues with the mass effect by showing a rapid growth tendency, are pathognomonic [1, 11]. Moreover, the plexiform neurofibromas contain the malign transformation potential differently from the cutaneous neurofibromas, and the transformation risk into the malign peripheral nerve sheath tumor (MPNST) varies between 5 and 10% [20]. Therefore, scanning should be made by the FDG-PET in order to make early malign transformation diagnosis in the cases, in which the growth or sudden change was determined in the plexiform neurofibroma size.

3. Spinal neurofibromas and dumbbell formation

3.1 Epidemiology of the spinal neurofibroma

The neurofibromas are the most prevalent seen tumor in the NF1 disease. The schwannoma, MPNST, meningioma, and astrocytoma from the other spinal tumors less often accompany the NF1 [6]. The spinal neurofibromas, which are the major diagnostic criteria of disease, are seen in approximately 60% of the patients with NF1 [2, 6]. They constitute 23% of all of the spinal tumors [18]. While the spinal neurofibromas most frequently show a location in the thoracic region, it is followed by their predilection in cervical and lumbar regions, respectively. The neurofibromas located in the sacral region are quite rarely observed and show an asymptomatic course until reaching to the big sizes [21]. Of these spinal neurofibromas, 72% were with the intradural extramedullary, 14% with the extradural, and 13% with the intradural and extradural “dumbbell formation.” Only 1% of the spinal neurofibromas are intramedullary located [22].

3.2 Dumbbell formation of the spinal neurofibroma

The tumor’s intraspinal component extends throughout the peripheral segment in the extraspinal distance of the nerve through the intervertebral foramen in the dumbbell spinal neurofibroma, of which total resections have difficulty with the neurosurgical techniques required for the multidisciplinary-combined approaches. The extraspinal tumor part is usually larger than the intraspinal tumor part and can reach the giant sizes. The huge dumbbell tumors are generally in a lobule shape and show a cystic degeneration [1, 11].

The extraspinal tumor component can adhere to the adjacent tissue and organs in the body cavities and also gives the clinical finding through the pressure effect. The extraspinal tumor component’s serious respiratory problems are more frequently observed as a result of the pressure of lung parenchyma to the bronchus and bronchioles in the chest cavity due to especially thoracic region predilection of dumbbell neurofibroma. Therefore, nowadays, the surgical treatment in the thoracic dumbbell neurofibromas is frequently carried out by the combined approaches planned together with the thoracic surgeons. Moreover, the progression of cervical neurofibroma in the adjacency of vertebral artery of extraspinal tumor component showing an extension to the subsurface skin is a condition constituting another difficulty in terms of the surgery. Similarly, the intraabdominal and retroperitoneal organ dysfunctions can be also observed in the lumbar *dumbbell neurofibroma* cases, and they make the multidisciplinary-combined approaches a current issue in the surgical treatments of these cases [1, 6, 23].

3.3 Pathology of the spinal neurofibroma

The neurofibromas are macroscopically in gray-white color, gelatinized, and in a soft form. Dissecting the nerve macroscopically from the neurofibroma is quite difficult due to the close relationship between the nerve and neurofibroma [24]. The solitary and plexiform neurofibromas showing the similar microscopic features consist of the thin and long fusiform cells dispersed between the collagen fibers within a mucopolysaccharide-rich matrix. In addition, these cells are in a uniform form and contain the hyperchromatic nucleus. While the cell density is less in the neurofibromas, they contain Schwann cells, neural fibroblasts, cells like the perineural cell, and mast cells [6]. Sometimes, some difficulties can be encountered in separating the neurofibroma from the schwannomas due to their common cell

contents. The nuclear atypia and hyalinizing vascular component observed in the neurofibromas are less often determined as significant according to the schwannoma [20]. It immunohistochemically shows a positive staining feature with S100. But, the stained neurofibromas are more subtle since their immunoreactivity is less often in comparison with the schwannoma [24]. The neurofibromas show a positive staining feature in the different levels together with the epithelial membrane antigen (EMA), which is specific for the perineural cell [20]. Similarly, they have the strong staining features with the vimentin and fibronectin [25]. There is a CD34 positiveness showing immunoreactivity in the cutaneous (*intraneural*) neurofibromas [26]. The myelinated nerve fibers in the neurofibromas can be shown by the silvering paint and myelin paint.

3.4 Clinical presentations of the spinal neurofibroma

The spinal neurofibromas are generally asymptomatic when they are small. The unilateral radicular ache is the most frequently observed symptom with the rate of 80% in early phases of the disease since most of them are originated from the spinal dorsal nerve roots. The paradoxical ache is characterized as increasing during rest and nights. This condition depends on the venous return difficulty developed while sleeping. The other paresthesia symptoms can accompany to this table. Moreover, the deep sensory losses can be also observed as a result of affecting the posterior column. The tumor growing in the intradural extramedullary distance leads to the long-tract findings by making the spinal cord pressure in advanced stages of the disease. The muscle strength losses—motor deficits—observed at the rate of 30% in the spinal neurofibroma cases mostly occur as a result of affecting the lateral and anterior columns by the tumor. The sphincter disorders developed depending on the involvement of autonomous ways are observed at the rate of 25%. The other neurologic deficits can generally develop approximately 3–5 years later following the radicular ache in the spinal neurofibromas like in the other intradural tumors [1, 6, 27].

The tumor's extraspinal component can wrap the peripheral tissues by growing and cause the additional symptoms by making pressure in the dumbbell neurofibroma cases. The neck ache and suboccipital headache can be observed in the cervical localized tumors [28]. The tumors showing an extension to the chest cavity can lead to the respiratory distress by making pressure to the air conduction ways. The patients are asymptomatic for a long time in the dumbbell tumors showing an intraabdominal growth. However, the intraabdominal tumor leads to the related organ dysfunction symptoms by making the displacement and pressure in the abdominal organs when it reaches the big or huge sizes. The ache spreading from the abdomen toward the lumbar region can be seen in the big tumors showing an extension to the retroperitoneal region [29, 30].

3.5 Neurodiagnostic techniques of the spinal neurofibroma

There are variations that will have made a diagnosis in 50% of the cases in the direct graphies. The most frequently seen vertebra radiographies findings are pedicle erosion and scalloping in the vertebral corpus. The enlargement of the interpedicular distance and foramen can regularly and indirectly show a dumbbell tumor existence [27, 31]. It had been notified that the whole block was observed in 50% of the cases and 83% of the myelographic defects were intradural in the myelographic examination [27]. The most used important radiologic imaging method is MRI in order to detect the prevalence of disease, reveal the intraspinal and extraspinal components of spinal neurofibromas in details, evaluate the complications to be developed in the postoperative period, and detect the tumor recurrence in the cases with NF1. The spinal

neurofibromas give an isointense or hypointense appearance in the spinal T1-MRIs and give a hyperintense appearance in the spinal T2-MRIs [27, 31]. The extraspinal tumor component's extensions to the lateral together with the dumbbell neurofibroma's specific appearances can be shown better by the spinal MRI. Moreover, imaging the dumbbell neurofibroma's paravertebral extension and pressure by showing an extension to the adjacent organs by the MRI is quite important in planning the surgical approaches. The MR images of our one NF1 case with multiple dumbbell neurofibromas (cervical, thoracic, and lumbar regions) are presented in **Figure 1** [22].

3.5.1 Radiological alterations of the tumors' growth

The spinal neurofibroma holds the contrast in a significant and homogenous way when its size is small [27, 31]. Especially, the cystic degeneration and

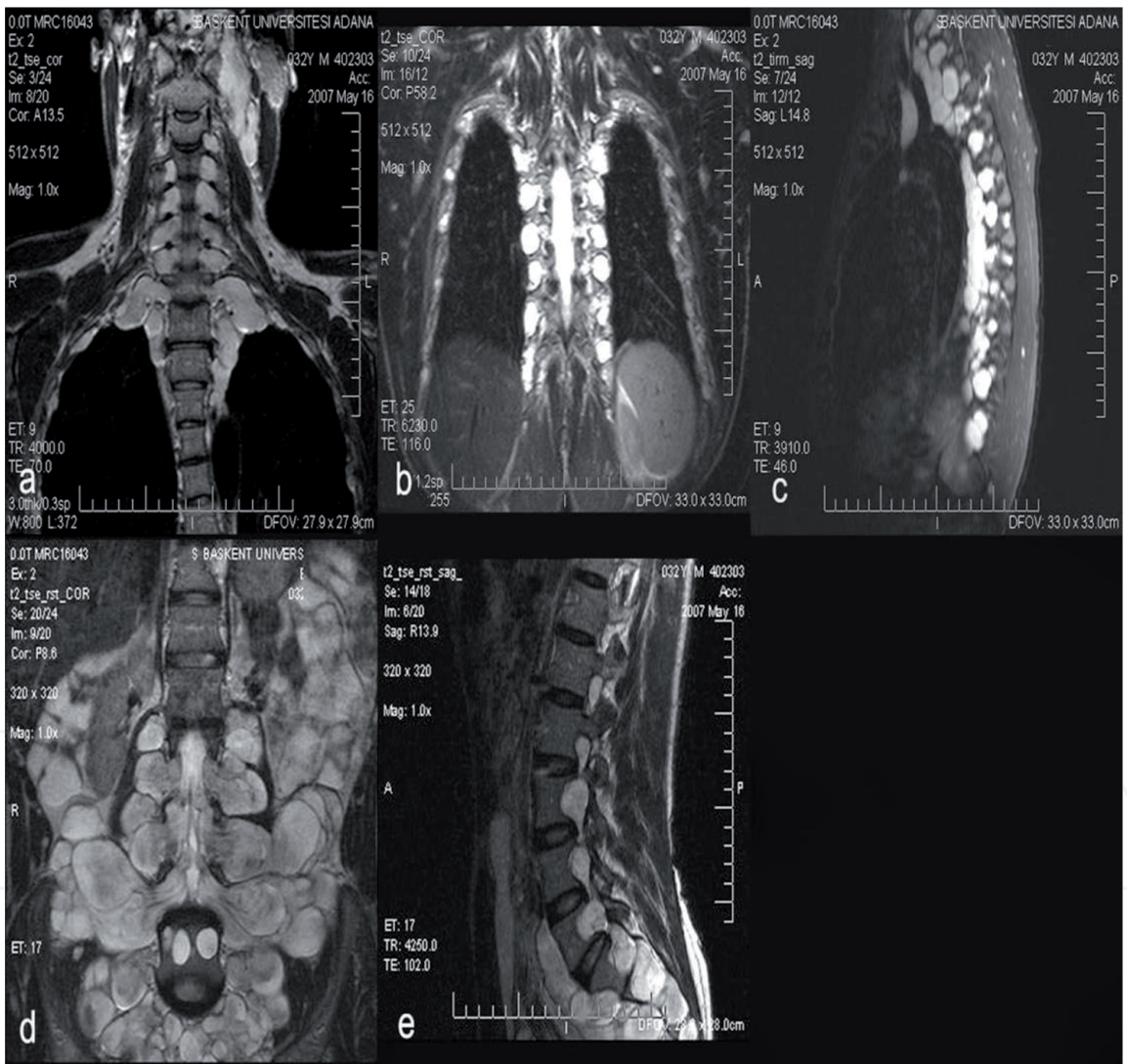


Figure 1. Preoperative, T2-weighted MRI scan of the patient's spinal axis, revealing multiple, massive, hyperintense lesions displaying heterogenous insignificant contrast enhancement in the paraspinal region. These lesions caused neural foraminal extension by filling all cervical and thoracic neural foramen; they were detectable (a) in the coronal plane in the cervical region, (b) in the coronal plane in the thoracic region, and (c) in the sagittal plane in the thoracic region. (d) View of the coronal plane in the lumbosacral region, showing intra-abdominal dumbbell tumor formation due to multiple, massive, hyperintense lesions causing neural foraminal extension through filling of all neural foramen. The lesions were located paraspinally and showed heterogenous insignificant contrast enhancement. (e) Multiple, massive lesions causing scalloping at the posterior parts of the L3 and L4 sacral vertebrae and in the posterior parts of the sacral vertebrae were detected in the lumbosacral region of the sagittal plane. "This figure is presented with Copyright permission of the Turkish Neurosurgery (Turkish Neurosurgical Society) [22]."

hemorrhage fields can be observed depending on the vascular thrombosis and necrosis developed as long as the tumor grows in the plexiform neurofibromas [32]. Therefore, the big dimensional neurofibromas especially present a heterogeneous appearance in the T1-weighted sequences due to the degenerative variations and pseudocystic fields [33]. Moreover, while the regions are observed as a hyperintense in the T2-weighted sequences since the myxoid degeneration is observed in it, the fields showing the collagenous fibrous tissue give a hypointense appearance. Similarly, the heterogeneous contrast involvement is observed in the big spinal neurofibromas [30].

4. Surgical treatment of the spinal neurofibromas

4.1 General surgical principles of the spinal and dumbbell neurofibromas

The neurofibromas consist of a mixture of the proliferous nerve sheath originating from the perineural fibroblasts. The neurofibromas extend to the fascicles by surrounding the axons. The surgical cleavage plan loss develops between the nerve fibers and tumor as a result of the fascicle's complete involvement with the tumor in the neurofibroma cases. This condition constitutes a foundation of the difficulties in the spinal neurofibroma surgery. The axons surrounded by the tumor are generally taken together with the tumor during the surgery. However, the fascicles, in which the tumor shows an extension but is not completely held, can be most often separated by dissecting the tumor during the surgery, and thus, they can be protected [34, 35]. The MR images of our patient, in which the intraspinal tumor component of the cervical dumbbell neurofibroma was surgically removed, are presented in **Figure 2** [22].

The aim in the spinal neurofibromas' surgical treatments is to remove the tumor totally. The nerve root and nerve showing involvement by the tumor are required to be sufficiently exposed in the first stage of the surgery since the spinal neurofibromas are mostly originated from the nerve root. Then, these neural elements should be separated by the sensitive dissection from the tumor, and the total resection should be made to the tumor in the last stage of the surgery. But, nerve root can be sacrificed especially in the patients, in which neural elements' dissection cannot be achieved.

The total removal of the single solitary neurofibroma surgically is relatively easier. But, the difficulties can be encountered in taking these tumors surgically since they are characterized by the multiple tumors in the plexiform neurofibromas, especially accompanying to the NF1. The postoperative neurologic deficit development risk is much more according to the spinal schwannoma resections in the multiple spinal neurofibroma resections due to more than one nerve fiber involvements. Therefore, the activities in the muscles innervated by the functional nerves should be followed up by using the intraoperative EMG monitorization in order to prevent the postoperative neurodeficit development. Moreover, these fascicles can be enlightened whether they are the motor function with the intraoperative electrical stimulation applied to the fascicles by the tumor. The total tumor resection is rarely applied in the plexiform neurofibroma cases [36]. Therefore, removing the symptomatic tumors primarily is suggested in the multiple spinal neurofibroma cases accompanying to the NF1 [37]. For this purpose, the spinal axis regions, to which the surgical intervention will be applied, should be researched and revealed by both the detailed radiologic imaging methods to be made in the preoperative period and detailed neurophysiologic tests.

Sacrificing the nerve root will not cause an additional neurologic deficit for the patient since the nerve root is already nonfunctional due to the degeneration in the

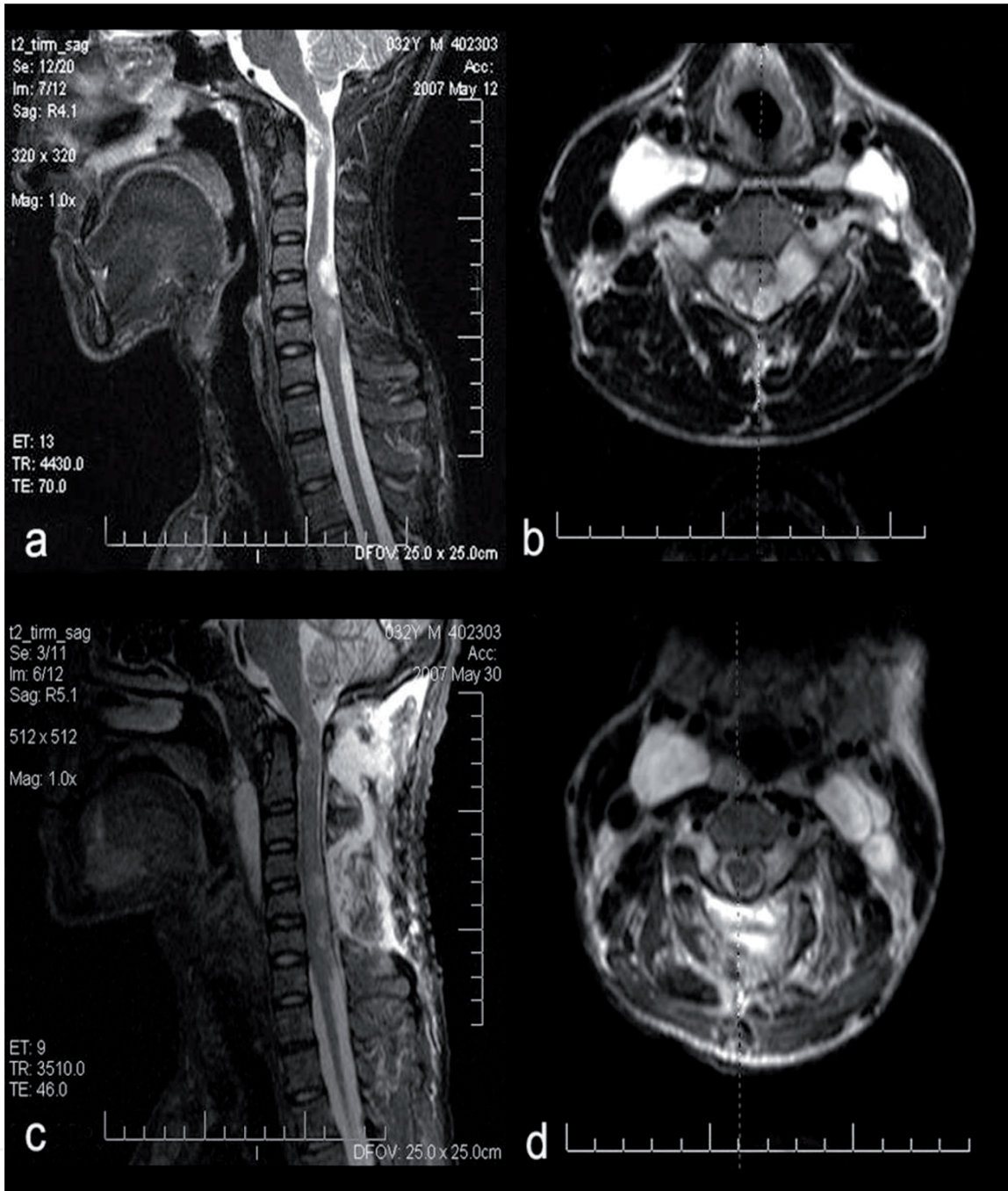


Figure 2. Detection of massive, hyperintense lesion, located paraspinally and displaying heterogenous insignificant contrast enhancement that was causing significant spinal cord compression at the C4–C5 level by filling in the epidural distance. The lesion was visible in preoperative MRI scans of the patient's cervicospinal area: (a) T2 sagittal sequence, (b) T2 axial sequence. After surgical intervention, removal of the lesions was confirmed in (c) a T2-weighted sagittal sequence and (d) a T2-weighted axial sequence. “This figure is presented with Copyright permission of the Turkish Neurosurgery (Turkish Neurosurgical Society) [22].”

multiple neurofibroma cases accompanying to the NF1 and show a malign degeneration [37]. But, protecting the spinal radicular arteries progressing together with them while sacrificing the nerve root is quite important in order to avoid the spinal cord ischemia that will be preoperatively able to develop [38]. The nerve fibers' large part is held by the tumor, especially in the big or giant dimensional dumbbell neurofibroma cases, and it is unfeasible to take these tumors without sacrificing the root. Consequently, the total resections of these big or huge dimensional dumbbell neurofibromas are surgically concluded by the serious neurologic deficits. Therefore, it should be contented with a partial resection of the tumor, in which the neural structures are protected as far as possible in these cases [27, 31, 37].

On the other hand, even the symptomatic spinal neurofibromas are surgically taken in the cases with NF1; the reoperations can be required in these cases as a result of becoming symptomatic by growing the localized asymptomatic spinal neurofibromas in the other regions [27, 31].

4.2 Surgical approach review

4.2.1 Surgical approach of the cervical spinal neurofibromas

The spinal neurofibromas are generally tumors showing a concentric enlargement throughout the spinal nerve [1]. Especially, the spinal cord and nerve roots should be protected during the cervical dumbbell tumors' surgical resections. Moreover, the vertebral artery is also required to be brought under control, especially during the surgery due to the cervical dumbbell tumors' close relationship. The customized ideal surgical approach should be determined, and the tumor should be totally taken by taking the tumor size and spreading pattern into consideration in order to decrease the recurrence rate to be developed due to the cervical dumbbell tumor's insufficient resection. Moreover, the spinal instability risk to be developed should be preoperatively and/or intraoperatively taken into consideration, and if needed, the cervical fusion should be made in the same session [1, 39].

The important difficulties are encountered in the cervical dumbbell tumors' surgical treatment due to the tumor's close adjacency to the vertebral artery and sheath and the vertebral body's involvement. Therefore, various surgical approaches had been defined in order to take these tumors surgically. McCormick had described a single-stage posterior approach for cervical dumbbell tumors. In this approach, a single segmented facetectomy and hemilaminectomy had been used. However, there are also limitations to the single-stage posterior approach. It had been notified between them that the extraspinal component's extension to the tumor's lateral was not required to be more and the component showing an extension to the lateral was required to be maximum 3 cm beginning from the dural sac margin [40]. But, the tumor is not totally taken by the single-stage posterior approach for the cervical dumbbell tumors exceeding these nerves.

A combined posteroanterior approach is totally required to take the tumors, of which extraspinal extension is big in this manner [41, 42]. The surgery duration is longer in this single-stage approach, and intraoperative hemorrhage is much more observed. The combined posteroanterior approach had been planned as two-stage by Mohd Ariff et al. in order to eliminate the excessive hemorrhage risk arising from the surgery duration's length [43]. The cervical dumbbell tumor's intraspinal component is firstly taken by the posterior approach in this approach. Then, by giving a length of time, it is gained time for the spinal cord edema's resorption. In the second stage, the tumor's extraspinal component is taken by the anterior approach [1]. Jiang et al. had notified the Peking University Third Hospital classification that facilitates the surgical approach planning according to the cervical dumbbell tumors' localization and extension pattern based upon the preoperative MRI or CT images. This classification had been described in two stages. In the first stage of this classification, the regions, in which the tumor is localized, had been divided into five groups, and the regions, in which these tumors extended, had been divided into four groups. In the second stage, seven groups had been constituted according to the tumor localization's combination and extension regions, and the suggested surgical approach patterns had been indicated for these seven groups [41]. In the course of time, the lateral approaches had become to be preferred much more by the neurosurgeons instead of the (single-stage or two-stage) combined (instead of postero-anterior approach) approaches because the lateral approaches provide

wider exposure to the spinal axis' lateral, intervertebral foramen and extraforaminal regions in the single session [44].

The first lateral approach had been used by Verbiest in the cervical spondylosis surgery [45]. The various anterolateral approaches had been developed by modifying this lateral approach in the course of time and had been especially used in the cervical tumors' surgical treatments [45–47]. However, these declared anterolateral approaches are the approaches generally and technically containing a difficulty and bearing an injury risk in the adjacent nerves to the vertebral artery and tumor [42]. The transparaspinal approach had been described by Onesti in order to avoid these risk factors and take the paraspinal tumors totally without the necessity of anterior surgery. In this single-stage approach, the vertebra lateral is completely dominated by the combination of cutting the paraspinal muscles with a transverse incision together with the laminectomy. All of the paraspinal tumors localized in the vertebra lateral can be taken by this approach independently from the tumor size. It is a rapid approach that can be used throughout the whole spinal axis as an advantage of this approach. Its disadvantage is that it cannot be used in the dumbbell tumors making an anterior spinal cord pressure since the spinal cord anterior is not seen sufficient with this approach [42].

The extensive posterolateral exposure had been defined by Zhao in 2009 in order to totally take the cervical dumbbell tumors, of which huge extraforaminal component is especially found. It had been notified by this approach that the total tumor resection was made in 16 cases with cervical dumbbell tumor. In this approach, the total lateral mass resection and laminectomy had been used. It had been notified by this approach that the tumors' most lateral part could be reached by the posterolateral wide exposure. Moreover, it had been also notified by this approach that separating tumor from vertebral artery could be easily achieved and tumor component could be resected since it showed an extension to the lateral vertebral body [48, 49].

4.2.2 Surgical approach of the thoracic spinal neurofibromas

The thoracic dumbbell tumors are relatively rarely seen. Taking the thoracic dumbbell tumors surgically shows a difficulty since there are two pieces of extraspinal and intraspinal tumor components connected through the foramen. Therefore, the various approaches had been defined in the course of time in order to take the thoracic dumbbell tumors. The size and position of the thoracic dumbbell tumors and extraspinal components are the most important factors in deciding the surgical approach [50, 51]. In the course of time, although there are various classifications developed by taking these criteria into consideration, nowadays, Eden's classification had been the most frequently preferred one by the neurosurgeons in deciding to the surgical approach [51].

The single-stage posterior approach is frequently preferred in order to take the dumbbell tumor's intraspinal component in the cases having Eden type II and type III tumors according to this classification. The two-stage combined posteroanterior approach is frequently preferred in the cases having a centrally located tumor such as Eden type IV, of which the extraforaminal tumor component is big [51]. The single-stage posterior approach is frequently preferred in the cases, of which extraspinal component is small. The detailed information is obtained about the important peritumoral structures' involvements with the tumor such as the arteries found in the adjacency of the tumor by making 3D-CT scanning in the preoperative period. The patient is taken into surgery under the general anesthesia and in prone position. Then, records of SSEPs and MEPs of patient are monitored by neuromonitorization.

The paraspinal muscles are subperiosteally dissected after a median vertical skin incision in the posterior. The intraspinal component including the tumor's part in the foramen is revealed by making the total facetectomy following the total laminectomy. Then, the costotransverse joint, costa, and transverse process found in the affected side are revealed. The costotransversectomy is made and the tumor's extraspinal component is reached. The dura is opened by the microsurgery method since the tumor's intradural component is firstly required to be taken in the spinal neurofibroma surgery, and the tumor's intradural component is observed. The tumor is firstly separated by the microdissection from the spinal cord and then from the nerve roots. But, the thoracic nerve roots that cannot be separated from the tumor due to the cohesiveness despite the dissection can be sacrificed in this stage of the surgery. Sacrificing the other thoracic nerve roots excluding the T1 nerve root, a part of the brachial plexus, is generally and functionally tolerated better. Nevertheless, when required, the intraoperative stimulation can be also used in this stage in order to evaluate whether the related nerve functions are protected. The tumor's foraminal component is mostly taken by resecting the region together with the surrounding dura. In this stage, the radicular artery's progression coming into existence from the descending aorta's segmental intercostal branches by passing through the foramen toward the spinal cord should be paid attention to, and this artery should be protected in order to avoid the spinal cord damage [52–55].

The combined posteroanterior approach made by the laminectomy and thoracotomy had been described for total resection of the tumor, of which big extraspinal component is found in the chest cavity. This is a two-stage approach, and the laminectomy and costotransversectomy are firstly made by a neurosurgeon with the posterior approach, and the tumor's extraspinal part is taken. Then, the tumor's extraspinal big component is taken by a thoracic surgeon by making the thoracotomy with the anterior approach. An arcuate arc incision is used. One piece of costa part, which is found between the costochondral junction and costotransverse joint, is taken by making it independent from the surrounding tissues. Next, the parietal pleura is opened in the costa bed, and the chest cavity is entered. The lung, which is found on the side in which the surgery is made, is damped with the help of a double-lumen endotracheal tube. The tumor's big extraspinal component found in the chest cavity is taken after providing the sufficient view field [55, 56]. The remaining spinal cord's dura defect is closed as waterproof by the duraplasty made with the help of dura graft after taking the thoracic dumbbell tumor and sacrificing all of the nerve roots affected. Then, the fibrin tissue adhesives are put on it, and the fatty tissue obtained from the subcutaneous tissue is located in this field.

In the course of time, the open thoracotomy gives its place to the thoracoscopic interventions that are more minimally invasive intervention depending on the developments in the endoscopy field. In 1999, it had been firstly notified that the thoracic dumbbell neurofibroma was taken by Citow et al. with the single-stage combined laminectomy and thoracoscopy approach. It had been notified between the advantages of this approach that the potential morbidity observed in the thoracotomy was not observed in this approach and, moreover, the wide muscle dissection observed in the single-stage posterior approach was not needed in this approach, and consequently, the postoperative ache was less often [57]. In 2001, Konno et al. had notified that there were three dumbbell neurofibroma cases and two paraspinal neurofibroma cases that they similarly treated by the single-stage combined laminectomy and thoracoscopy approach. It had been also indicated that the extraforaminal component could be safely and successfully taken by the thoracoscopy and the instability risk following the unilateral laminectomy and medial facetectomy used in this approach was low, and consequently, the fusion was not required. But, it had been notified as a disadvantage

of this approach that the chest tubes to be specially used in the postoperative period had many complication risks such as the postoperative ache, pulmonary infection, and pulmonary dysfunction [58].

The T1 nerve root is a part of the brachial plexus and progresses in the adjacency of subclavian artery and vertebral artery. It had been notified that the T1 nerve root dumbbell tumors had a serious hemorrhage risk depending on these big artery injuries during surgically taking the tumor due to the cohesiveness to the big arteries such as subclavian artery and vertebral artery. Also, while sacrificing the other thoracic nerve roots except the T1 can be functionally tolerated due to the tumor cohesiveness, sacrificing the T1 root, a part of the brachial plexus, cannot be functionally tolerated. Therefore, it is especially required to protect the T1 nerve root in dumbbell tumor surgery. As specified above, a standard surgical approach had not been notified in the surgery of dumbbell tumors arising from the T1 nerve root having the different functional and anatomic features rather than the other thoracic nerves [59].

In the course of time, the video-assisted thoracic surgery (VATS), a minimal invasive intervention, had been described by the thoracic surgeons as a result of the developments in the video technology field. In 2015, the T1 nerve root dumbbell tumor had been safely taken by Ohya et al. for the first time with the posterior spinal surgical combination applied after the VATS. In this combined approach, the subclavian artery and vertebral arteries are firstly assured by the thoracic surgeons by making them independent from the T1 nerve root by using the VATS in the anterior approach. Thus, the serious hemorrhages to be developed depending on these artery injuries will have been prevented during the posterior spinal surgery that will be subsequently applied. The tumor is taken by making the partial costotransversectomy in the posterior spinal surgery. It had been indicated that 3D-CT was required to be used in the preoperative period in order to evaluate the tumor's relationship with the structures in the adjacency of it in details in the cases, for which this combined approach was planned [59]. Moreover, in these cases, it had been also notified that the intraoperative stimulation and neuromonitorization were required to be used in order to evaluate whether the T1 nerve function was protected.

In 2018, comparative analyses of the single-stage posterior approach used in those having Eden type II and type III tumors and combined laminectomy and thoracoscopy used in those having Eden type IV tumor had been made in the cases having the thoracic dumbbell neurofibroma in a retrospective study declared by Li YW et al. In conclusion, it had been indicated that the thoracic dumbbell neurofibromas could be effectively and safely taken by both the surgical approaches. However, it had been also notified that the single-stage posterior approach's operative results were better than the combined laminectomy and thoracoscopy approach and the complications related to the approach pattern were less often observed [60].

4.2.3 Surgical approach of the lumbar spinal neurofibromas

The lumbar dumbbell neurofibromas show an extension to the abdomen cavity from the paraspinal muscles and retroperitoneal field and can wrap the surrounding of abdominal organs. These tumors symptomatically make pressure to the abdominal organs with the organ dysfunction findings when they reached the big or huge sizes since they usually show an intraabdominal asymptomatic growth [61, 62]. While the lumbar dumbbell tumors' intraspinal part is taken by posterior approach, big dimensional extraspinal part is especially taken by the anterior approach [62, 63]. But, the common iliac vein laceration, renal pedicle avulsions, and massive hemorrhages had been notified by the single-stage anterior approach, in which the total resection of the dumbbell tumor's intraspinal and extraspinal

components was planned [64, 65]. Therefore, the combined posteroanterior approaches had become a current issue, especially for the big or huge dimensional lumbar dumbbell tumors.

The lumbar dumbbell tumors' extraspinal part can reach the big and huge sizes in the retroperitoneal field and intraabdominal region. Park et al. had used the "huge" term for the tumors, of which size exceeds 2.5 cm beginning from the extraspinal component's dural margin [66]. On the contrary, many neurosurgeons had notified that using the "huge" tumor term would be more appropriate in the case where the tumor's extraspinal component caused a pushing or pressure in the retroperitoneal and/or internal organs when they were shown by the radiologic examinations [64]. The surgical approaches used in the conditions, in which the lumbar dumbbell tumors' extraspinal component was big, had been notified in limited number in the literature, and not any guideline describing the surgical approaches to be selected according to the tumor's localization and spreading patterns had been notified. The combined posteroanterior approach had been generally used in taking the big dumbbell tumors. In this approach, the tumor's intraspinal component had been firstly taken by the posterior approach. Then, the anterior approach had been made together with a general surgeon or urologist included in the surgery, and the retroperitoneal and/or intraabdominal components, by which the tumor showed an extraspinal extension, had been taken [67, 68]. There are disadvantages such as being long of the operation duration and being more of the intraoperative hemorrhage amount in the single-stage combined posteroanterior approaches.

Therefore, the single-stage extensive posterior approach, a posterolateral approach pattern, had been developed in the lumbar dumbbell tumors, of which extraspinal component was especially big like in the surgery of cervical and thoracic dumbbell tumors instead of the combined posteroanterior approach. In this approach, a midline skin incision is made like in posterior approach. But, unilateral muscle dissection is made until the transverse process lateral differently from the posterior approach. Then, a wide visual angle is obtained toward the retroperitoneal field from the lateral by making two transverse process resections. In the cases where the visual angle is insufficient despite the transverse process resection, the paraspinal muscles are longitudinally cut by making a second subcutaneous incision in the lateral, and thus, the paraspinal approach is carried out. After revealing the tumor's extraspinal component in this manner, the intraspinal component is also revealed by making the unilateral laminectomy and facetectomy in the second stage. The tumor's intraspinal component is firstly taken following the stages specified in the combined posteroanterior approach. Then, the cohesiveness of the tumor's extraspinal component with the retroperitoneal and intraabdominal organs is tried to be separated as far as possible by making a blunt dissection, and the extraspinal component is taken by resecting gross totally and/or totally. Sometimes, the debulking can be applied in order to minimize the tumor size in the lumbar dumbbell tumors having a huge extraspinal component [64].

4.3 Management of the postoperative complications in the spinal neurofibroma

4.3.1 Spinal deformity and instability

It had been notified that the cervical instability developed in 20% of the cases as a result of the posterior surgical approaches applied in the cervical spinal neurofibromas. Moreover, it had been also notified that scoliosis or kyphoscoliosis developed at the rate of 50% when the fusion is not made in the cases, in which the facetectomy is applied and cervical instability is observed. Therefore, the fusion surgery should be added in the intraoperative period, or the fusion should be made

in the essential cases by making a close radiologic follow-up to the patients in the postoperative period in order to prevent the cervical instability to be developed after the posterior approach surgeries [41]. The thoracic instability development risk is quite low even in the combined posteroanterior approaches, in which the total facetectomy and costotransversectomy are made in the thoracic spinal neurofibroma cases. Generally, the fusion is not needed. The principal factor preventing the instability in the thoracic region is originated from a more stable nature of the thoracic spinal axis compared to the cervical and lumbar regions [50, 69]. But, the transpedicular stabilization can be made by putting a pedicle screw following the reconstruction made by putting a cage or bone strut to the defective field when the vertebra destruction developed as a result of the tumor pressure in the adjacency of vertebra body observed in the thoracic paravertebral neurofibroma cases showing an extension to the lateral [64]. The fusion with the similar instrumentation is planned since the postoperative instability development risk is high due to the thoracic vertebra scalloping lesions accompanying to the NF1 [70]. Similarly, making the stabilization with the reconstruction and instrumentation is suggested in over half of the vertebral body in the lumbar spinal neurofibroma cases when the destruction is developed by the tumor [64, 71, 72]. Moreover, the lamina reconstruction is added to the surgical approaches by using an autologous iliac crest bone or allograft in order to prevent the postlaminectomy kyphotic deformity to be developed in the cases, which are the common point of thoracic and lumbar surgical approaches, and to which more than one laminectomy is specially made [73]. In conclusion, the spinal instability risks to be developed should be preoperatively and/or intraoperatively evaluated in the spinal neurofibroma cases, and if needed, making the cervical fusion in the same session will be more appropriate [1, 39].

4.3.2 Recurrence of the tumor

The recurrence rate is quite less for those, for which the total tumor resection is made in the spinal neurofibroma cases. The 5-year and 10–15-year recurrence rates had been notified as 10.7 and 28.2%, respectively, in the localized nerve sheath tumors within the cervical region accompanying the NF1 [39]. It had been also notified by Levy et al. that the recurrence was observed 3 years later in only 1 case of 66 paraspinal neurofibroma cases operated by them [37]. Fifteen patients, to whom the thoracic neurofibroma resection was made by using the single-stage posterior approach with the costotransversectomy, had been followed up for at least 5–10 years, and it had been notified that no recurrence was observed in these cases [53]. Taking the tumor totally has difficulties although the surgical approaches are described in these spinal neurofibroma cases, in which the surgical cleavage plane was lost between nerve fibers and tumor. Moreover, their close relationships with the adjacent important vascular and visceral organs especially affect the dumbbell neurofibromas' total resections in a negative way [1, 34, 35, 39]. Therefore, the tumors' relationships with the peritumoral structures such as the vertebra, costa, and arteries should be researched in details by the MRI and 3D-CT images that will be made in the preoperative period for the spinal neurofibroma cases in order to prevent tumor recurrence, and the appropriate surgical approach should be selected [54]. Although the protection of the held nerve roots is always given precedence, sometimes, the total resection cannot be achieved. Therefore, especially insufficient tumor resections are the most important factor causing the increase in the tumor recurrence. Moreover, it had been notified that the tumor recurrence was generally asymptomatic in the cases accompanying to the NF1. The most important factor in deciding to the surgery in the recurrence cases is whether the patients are symptomatic or not. The surgical tumor resection should be planned in the symptomatic cases [1, 34, 35, 39].

4.3.3 Protection of the nerve roots and fascicules

The fascicules, to which the tumors show an extension but in which they are not completely held in the spinal neurofibroma surgery, can be most often separated and protected by dissecting the tumor during the surgery [34, 35]. However, the nerve roots' protection problems increase, and the nerve root can be sacrificed in the cases, in which dumbbell tumor formation is especially observed. In the literature, in the cases of cervical dumbbell neurofibromas operated with combined posteroanterior approach, the rate of protection of the nerve root has been reported as 18% [44]. Sacrificing the T1 nerve root participated in the brachial plexus together with the cervical and lumbar spinal roots cannot be functionally tolerated better for the patients in the surgery and causes the neurodeficits at the different levels. However, sacrificing the thoracic nerve roots is generally tolerated better in the patients. Therefore, the intraoperative stimulation and neuromonitorization are required to be used in order to detect the functional fascicules during the surgery in the neurofibroma cases, especially arising from the cervical, lumbar, and T1 nerve root [44, 74].

4.3.4 Techniques of the artery protection

The tumor's extraspinal component can show a close adjacency with the vertebral artery in the cervical dumbbell neurofibromas. The vertebral artery is generally pushed toward the anteromedial due to the tumor's extraspinal component. There is mostly a thin periosteum layer and perivertebral venous plexus layer between the tumor and vertebral artery. If the dissection is made from this surgical cleavage region, the ischemic injury probability is much more limited [75, 76]. Adamkiewicz artery should be specially paid attention for not being injured in order to protect it from the serious spinal cord ischemia in the inferior thoracic surgery and upper lumbar region dumbbell neurofibroma cases. Therefore, the enucleation should be made, and the aorta's segmental arteries should be protected in order to minimize the tumor size, especially in the resections of the dumbbell tumors' foraminal and extraforaminal components [64, 77].

4.3.5 Cerebrospinal fluid leakage and intralodge hemorrhage

The incision on the nerve root is taken forward by making a dural incision toward the medial during the dumbbell neurofibroma surgery. Following sacrificing the tumor resection and nerve root, the dura defect is closed to the intervertebral foramen by filling the fibrin tissue adhesive and fat. In this approach, the lateral mass fixation is used by mostly using the lateral mass instrumentation. The cerebrospinal fluid leakage can be observed in the cases, in which the dural defect cannot be successfully made. Moreover, the hemorrhage, hemothorax, and/or intraabdominal hemorrhage can be observed depending on the surgery's duration length, especially in the combined posteroanterior approaches. One piece of a hemorrhagic drain inside of the lodge in the posterior and one piece of an intraabdominal drain in the anterior should be placed at the end of surgery in order to prevent these complications to be developed in the postoperative period [50, 52, 58, 59, 64, 69].

5. Prognosis of the spinal neurofibromas

The patients' lifetimes are quite long depending on the tumor's benign nature in the spinal neurofibroma. The most important factor affecting the prognosis in

the spinal neurofibroma cases is tumor's surgical resection pattern. The prognosis is exceptionally good in the cases, in which the total resection is made. The ache complaint is completely recovered in 80% of the cases after the total resection, and the whole remission is provided in 60% of the cases. The tumor recurrence is quite rarely observed in the cases, in which the total resection is made. It had been notified that the recurrence was observed 3 years later on only 1 case of 66 paraspinal neurofibroma cases operated by Levy et al. [37, 40]. Another factor affecting the prognosis is the functional nerve roots' protection during the surgery. In this point, the tumor's localization comes into prominence much more. The thoracic spinal neurofibroma cases' prognosis is better since it is functionally tolerated in most cases by sacrificing the thoracic nerve root [75]. Another prognostic factor is the spinal instability developed depending on the vertebral deformities. Causing the destruction by the tumor's extraspinal component in the intervertebral foramen and the vertebral body lateral leads to spinal instability, especially in the dumbbell neurofibroma cases. Moreover, the total laminectomy, total facetectomy, costo-transversectomy, and multiple costa resections made depending on the surgical approach pattern can also lead to spinal instability. The vertebral scalloping lesions observed in patients with NF1 independent from the spinal neurofibroma also cause spinal instability [53, 77]. Making the fusion surgery with the intraoperative instrumentation will positively affect the prognosis in these tables. Therefore, the customized surgical approach should be planned depending on the tumor's localization and extension pattern in the cases with spinal neurofibroma.

6. Conclusion

In conclusion, a customized ideal surgical approach should be determined, and the tumor should be totally taken by taking the tumor's size and spreading pattern into consideration in order to decrease the recurrence rate to be developed due to the tumor's insufficient resection in the spinal neurofibroma cases. The surgical tumor resection should be carried out in company with the intraoperative stimulation and neuromonitorization. Moreover, if possible, the reconstruction and fusion surgery with instrumentation should be also made in the same session in the cases having a spinal instability risk to be developed.

Conflict of interest

The author reports no conflict of interest concerning the materials or methods used in this study or the findings specified in this paper. And the author has no personal financial or institutional interest in this research described in this article.

IntechOpen

IntechOpen

Author details

Feyzi Birol Sarica
Department of Neurosurgery, Faculty of Medicine, Giresun University,
Giresun, Turkey

*Address all correspondence to: saricafb@gmail.com

IntechOpen

© 2019 The Author(s). Licensee IntechOpen. This chapter is distributed under the terms of the Creative Commons Attribution License (<http://creativecommons.org/licenses/by/3.0>), which permits unrestricted use, distribution, and reproduction in any medium, provided the original work is properly cited. 

References

- [1] Hirsch NP, Murphy A, Radcliffe JJ. Neurofibromatosis: Clinical presentations and anaesthetic implications. *British Journal of Anaesthesia*. 2001;**86**:555-564
- [2] DeBella K, Szudek J, Friedman JM. Use of the national institutes of health criteria for diagnosis of neurofibromatosis 1 in children. *Pediatrics*. 2000;**105**(3 Pt 1):608-614
- [3] Abramowicz A, GosM. Neurofibromin in neurofibromatosis type 1—Mutations in NF1gene as a cause of disease. *Developmental Period Medicine*. 2014;**18**(3):297-306
- [4] Ferner RE. Neurofibromatosis 1. *European Journal of Human Genetics*. 2007;**15**(2):131-138
- [5] Weiss SW, Goldblum JR. Benign tumors of peripheral nerve. In: Goldblum JR, Folpe AL, Weiss SW, editors. *Enzinger and Weiss's Soft Tissue Tumors*. 6th ed. Philadelphia: Elsevier Saunders; 2014. pp. 784-854
- [6] Sampson JH, Martuza RL. Neurofibromatosis and other phakomatoses. In: Wilkins RH, Rengachary SS, editors. *Neurosurgery*. 2nd ed. Vol. IB. New York: Mc-Graw-Hill Book Company; 1996. pp. 673-685
- [7] Abramowicz A, Gos M. Neurofibromin in neurofibromatosis type 1—Mutations in NF1gene as a cause of disease. *Developmental Period Medicine*. 2014;**18**(1):124-133
- [8] National Institute of Health Consensus Development Conference: Neurofibromatosis conference statement. *Archives of Neurology*. 1988;**45**:579-588
- [9] Scoles DR, Nguyen VD, Qin Y, Sun CX, Morrison H, Gutmann DH, et al. Neurofibromatosis 2 (NF2) suppressor schwannomin and its interacting protein HRS regulate STAT signaling. *Human Molecular Genetics*. 2002;**11**(25):3179-3189
- [10] Ng HK, Lau KM, Tse JYM, Lo KW, Wong JHC, Poon WS, et al. Combined molecular genetic studies of chromosome 22q and neurofibromatosis type 2 gene in central nervous system tumours. *Neurosurgery*. 1995;**37**:764-773
- [11] Eastwood JD, Florella DJ, Macfall JF, Delong DM, Provenzale JM, Greenwood RS. Increased brain apparent diffusion coefficient in children with neurofibromatosis type 1. *Radiology*. 2001;**219**:354-358
- [12] Hirbe AC, Gutmann DH. Neurofibromatosis type 1: A multidisciplinary approach to care. *Lancet Neurology*. 2014;**13**(8):834-843
- [13] Korf BR. Malignancy in neurofibromatosis type 1. *The Oncologist*. 2000;**5**:477-485
- [14] Goh WH, Khong PL, Leung CS, et al. T2-weighted hyperintensities (unidentified bright objects) in children with neurofibromatosis 1: Their impact on cognitive function. *Journal of Child Neurology*. 2004;**19**:853-858
- [15] Chapparo MJ, Young RF, Moyra S, Shen V, Choi BH. Multiple spinal meningiomas: A case of 47 distinct lesions in the absence of neurofibromatosis or identified chromosomal abnormality. *Neurosurgery*. 1993;**32**:298-302
- [16] Tucker T, Schnabel C, Hartmann M, et al. Bone health and fracture rate in individuals with neurofibromatosis 1 (NF1). *Journal of Medical Genetics*. 2009;**46**(4):259-265

- [17] Agaimy A, Vassos N, Croner RS. Gastrointestinal manifestations of neurofibromatosis type 1 (Recklinghausen's disease): Clinicopathological spectrum with pathogenetic considerations. *International Journal of Clinical and Experimental Pathology*. 2012;5(9):852-862
- [18] Russell DS, Rubinstein LJ. *Pathology of Tumors of the Nervous System*. 5th ed. Baltimore: Williams & Wilkins; 1989. pp. 531-571
- [19] Halliday AL, Sobel RS, Martuza RL. Benign spinal nerve sheath tumors: Their occurrence sporadically and in neurofibromatosis type 1 and 2. *Journal of Neurosurgery*. 1991;74(2):248-253
- [20] Enzinger FM, Weiss SW. Benign tumors of peripheral nerves. In: Enzinger FM, Weiss SW, editors. *Soft Tissue Tumors*. 3rd ed. St Louis: Mosby-Year Book; 1995. pp. 821-888
- [21] Rao SB. Spinal neurinoma. A study of 80 operated cases. *Neurology India*. 1975;23(1):1-12
- [22] Sarica FB, Cekinmez M, Tufan K, Erdogan B, Sen O, Altinors MN. A rare case of massive NF1 with invasion of entire spinal axis by neurofibromas: Case report. *Turkish Neurosurgery*. 2008;18(1):99-106
- [23] Webb WR, Goodman PC. Fibrosing alveolitis in patients with neurofibromatosis. *Radiology*. 1977;122:289-293
- [24] Conti P, Pascini G, Mouchaty H, Capuano C, Conti R. Spinal neuromas: Retrospective analysis and long-term outcome of 179 consecutively operated cases and review of the literature. *Surgical Neurology*. 2004;61(1):34-43
- [25] Hirose T, Sano T, Hizawa K. Ultrastructure localization of S-100 protein in neurofibroma. *Acta Neuropathology (Berl)*. 1986;69(1-2):103-110
- [26] D'Alessandro G, Di Giovanni M, Iannizzi L, Guidetti E, Bottachci E. Epidemiology of primary intracranial tumors in the Valle d'Aosta (Italy) during the 6-year period 1986-1991. *Neuroepidemiology*. 1995;14:139-146
- [27] Canbaz B, Tanriverdi T. Nörofibromatozis. In: Aksoy K, Palaoglu S, Pamir TR, editors. *Temel Nöroşirürji*. Ankara: Turkish Neurosurgery Society Publishing; 2005. pp. 823-829
- [28] Leonard JR, Ferner RE, Thomas N, Gutmann DH. Cervical cord compression from plexiform neurofibromas in neurofibromatosis 1. *Journal of Neurology, Neurosurgery, and Psychiatry*. 2007;78(12):1404-1406
- [29] Wagenknecht LV, Schumpelick V, Winkler R. Urological aspects of primary retroperitoneal tumors. *European Urology*. 1976;2:15-20
- [30] Sakai F, Sone S, Kiyono K, Maruyama A, Ueda H, Aoki J, et al. Intrathoracic neurogenic tumors: MR pathologic correlation. *AJR. American Journal of Roentgenology*. 1992;159:279-283
- [31] Unal F. Spinal intradural ekstramedüller tümörler. In: Aksoy K, Palaoglu S, Pamir TR, editors. *Temel Nöroşirürji*. Ankara: Turkish Neurosurgery Society Publishing; 2005. pp. 1121-1128
- [32] Bhatia S, Khosla A, Dhir R, Bhatia R, Banerji AK. Giant lumbosacral nerve sheath tumors. *Surgical Neurology*. 1992;37:118-122
- [33] Lin J, Martel W. Cross-sectional imaging of peripheral nerve sheath tumors: Characteristic signs on CT,

MR imaging, and sonography. *American Journal of Roentgenology*. 2001;**176**:75-82

[34] Donner TR, Vorrhies RM, Kline DG. Neural sheath tumors of major nerves. *Journal of Neurosurgery*. 1994;**81**:362-373

[35] Haraida S, Nerlich AG, Bise K, Wiest I, Schleicher E. Comparison of various basement membrane components in benign and malignant peripheral nerve tumours. *Virchows Archiv A*. 1992;**421**(4):331-338

[36] Ozerdem U. Targeting neovascular pericytes in neurofibromatosis type 1. *Angiogenesis*. 2005;**7**(4):307-311

[37] Levy WJ Jr, Latchaw J, Hahn JF. Spinal neurofibromas: A report of 66 cases and a comparison with meningiomas. *Neurosurgery* 1986;**18**:331-334

[38] Iradi G, Peserica L, Salar G. Intraspinial neuromas and meningiomas: A clinical survey of 172 cases. *International Surgery*. 1971;**56**:289-303

[39] Klekamp J, Samii M. Surgery of spinal nerve sheath tumors reference to neurofibromatosis. *Neurosurgery*. 1998;**42**(2):279-290

[40] McCormick PC. Surgical management of dumbbell tumors of the cervical spine. *Neurosurgery*. 1996;**38**:294-300

[41] Jiang L, Lv Y, Liu XG, Ma QJ, Wei F, Dang GT, et al. Results of surgical treatment of cervical dumbbell tumors: Surgical approach and development of an anatomic classification system. *Spine*. 2009;**34**(12):1307-1314

[42] Onesti ST, Ashkenazi E, Michelsen WJ. Transparaspinal exposure of dumbbell tumors of the spine. *Journal of Neurosurgery*. 1998;**88**(1):106-110

[43] Mohd Ariff S, Joehaimey J, Ahmet Sabri O, Abdul Halim Y. Two-stage surgery for a large cervical dumbbell tumour in neurofibromatosis 1: A case report. *Malaysian Orthopaedic Journal*. 2011;**5**(3):24-27

[44] Lot G, George B. Cervical neuromas with extradural components: Surgical management in a series of 57 patients. *Neurosurgery*. 1997;**41**:813-822

[45] Verbiest H. A lateral approach to the cervical spine: Technique and indications. *Journal of Neurosurgery*. 1968;**22**:191-203

[46] George B, Zerah M, Lot G, Hurth M. Oblique transcorporeal approach to anteriorly located lesions in the cervical spinal canal. *Acta Neurochirurgica*. 1993;**121**:187-190

[47] Sen C, Eisenberg M, Casden AM, Sundaresan N, Caalano PJ. Management of the vertebral artery in excision of extradural tumors of the cervical spine. *Neurosurgery*. 1995;**36**(1):106-115

[48] Zhao B, Xu J. Extensive posterolateral exposure and total removal of the giant extraforaminal dumbbell tumors of cervical spine: Surgical technique in a series of 16 patients. *Spine Journal*. 2009;**9**(10):822-829

[49] Kyoshima K, Uehara T, Koyama J, Idomari K, Yomo S. Dumbbell C2 schwannomas involving both sensory and motor rootlets: Report of two cases. *Neurosurgery*. 2003;**53**(2):436-439

[50] Grillo HC, Ojemann RG, Scannell JG, ark v. Combined approach to "dumbbell" intrathoracic and intraspinal neurogenic tumors. *The Annals of Thoracic Surgery*. 1983;**36**:402-407

[51] Eden K. The dumb-bell tumours of the spine. *The British Journal of Surgery*. 1941;**28**:549-570

- [52] Ando K, Imagama S, Wakao N, Hirano K, Tauchi R, Muramoto A, et al. Single-stage removal of thoracic dumbbell tumors from a posterior approach only with costotransversectomy. *Yonsei Medical Journal*. 2012;**53**(3):611-617
- [53] Ando K, Imagama S, Ito Z, Tauchi R, Muramoto A, Matsui H, et al. Removal of thoracic dumbbell tumors through a single-stage posterior approach: Its usefulness and limitations. *Journal of Orthopaedic Science*. 2013;**18**:380-387
- [54] Takamura Y, Uede T, Igarashi K, Tatewaki K, Morimoto S. Thoracic dumbbell-shaped neurinoma treated by unilateral hemilaminectomy with partial costotransversectomy—Case report. *Neurologia Medico-Chirurgica (Tokyo)*. 1997;**37**:354-357
- [55] Akbay A. Torakal anterior yaklaşımlar. In: Aksoy K, Palaoglu S, Pamir, Tuncer R, editors. *Temel Nöroşirürji*. Ankara: Turkish Neurosurgery Society Publishing; 2005. pp. 994-998
- [56] Fager CA. *Atlas of Spinal Surgery*. London: Lea & Febiger; 1989. pp. 201-213
- [57] Citow JS, MacDonald RL, Ferguson MK. *Neurosurgery*. 1999;**45**(5):1263-1265
- [58] Konno SI, Yabuki S, Kinoshita T, Kikuchi SI. Combined laminectomy and thoracoscopic resection of dumbbell—Type thoracic cord tumor. *Spine (Phila Pa 1976)*. 2001;**26**(6):E130-E134
- [59] Ohya J, Miyoshi K, Kitagawa T, Sato Y, Maehara T, Mikami Y. Combined video-assisted thoracic surgery and posterior spinal surgery for the treatment of dumbbell tumor of the first thoracic nerve root. *Asian Spine Journal*. 2015;**9**(4):595-599
- [60] Li YW, Wang B, Li L, Lu G. Posterior surgery versus combined laminectomy and thoracoscopic surgery for treatment of dumbbell-type thoracic cord tumor: A long-term follow-up. *Clinical Neurology and Neurosurgery*. 2018;**166**:31-35
- [61] Kao TH, Shen CC, Chen CC, Kwan PH. “Primary” benign retroperitoneal and intraspinal dumbbell-shaped cystic teratoma: Case report. *Spine (Phila, PA, 1976)*. 2005;**30**(15):E439-E443
- [62] Yu NH, Lee SE, Jahng TA, Chung CK. Giant invasive spinal schwannoma: Its clinical features and surgical management. *Neurosurgery*. 2012;**71**(1):58-66
- [63] Ravník J, Potrc S, Kavalar R, Ravník M, Zakotnik B, Bunc G. Dumbbell synovial sarcoma of the thoracolumbar spine: A case report. *Spine*. 2009;**34**(10):E363-E366
- [64] Yang M, Wang XB, Li J, Xiong GZ, Lu C, Lu GH. Surgical treatment of large abdominally dumbbell tumor in the lumbar region. *Journal of Spinal Disorders & Techniques*. 2014;**27**(7):E268-E275
- [65] Agrawal A, Srivastava S, Joharapurkar SR, Gharde P, Ubeja G. Single stage complete excision of large thoracic dumbbell schwannoma by modified posterior approach. *Surgical Neurology*. 2008;**70**:432-436
- [66] Park SC, Chung SK, Choe G, Kim HJ. Spinal intraosseous schwannoma: A case report and review. *Journal of Korean Neurosurgical Association*. 2009;**46**:403-408
- [67] Pollo C, Richard A, De Preux J. Resection of a retroperitoneal schwannoma by a combined approach. *Neuro-Chirurgie*. 2004;**50**:53-56
- [68] Jankowski R, Szmeja J, Nowak S, et al. Giant schwannoma of the lumbar

spine. A case report. *Neurologia i Neurochirurgia Polska*. 2010;**44**:91-95

[69] Levy DI, Bucci MN, Weatherbee L, Chandler WF. Intradural extramedullary ganglioneuroma: Case report and review of the literature. *Surgical Neurology*. 1992;**37**(3):216-218

[70] Chiang ER, Chang MC, Chen TH. Giant retroperitoneal schwannoma from the fifth lumbar nerve root with vertebral body osteolysis: A case report and literature review. *Archives of Orthopaedic and Trauma Surgery*. 2009;**129**:495-499

[71] Sridhar K, Ramamurthi R, Vasudevan MC, Ramamurthi B. Giant invasive spinal schwannomas: Definition and surgical management. *Journal of Neurosurgery*. 2001;**94**(2 Suppl):210-215

[72] Theodosopoulos T, Stafyla VK, Tsiantoula P, Yiallourou A, Marinis A, Kondi-Pafitis A, et al. Special problems encountering surgical management of large retroperitoneal schwannomas. *World Journal of Surgical Oncology*. 2008;**6**:107

[73] Matsuoka H, Itoh Y, Numazawa S, Tomii M, Watanabe K, Hirano Y, et al. Recapping hemilaminoplasty for spinal surgical disorders using ultrasonic bone curette. *Surgical Neurology International*. 2012;**3**:70

[74] Kwok K, Davis B, Kliot M. Resection of a benign brachial plexus nerve sheath tumor using intraoperative electrophysiological monitoring. *Neurosurgery*. 2007;**60**(4 Suppl 2):316-320

[75] Schultheiss R, Gullotta G. Resection of relevant nerve roots in surgery of spinal neurinomas without persisting neurological deficit. *Acta Neurochirurgica*. 1993;**122**:91-96

[76] Sarica FB, Tufan K, Cekinmez M, Erdogan B, Sen O. Dumbbell-shaped neurofibroma of the upper cervical spine: A case report. *Journal of Nervous System Surgery*. 2008;**1**(3):190-194

[77] Payer M, Radovanovic I, Jost G. Resection of thoracic dumbbell neurinomas: Single postero-lateral approach or combined posterior and transthoracic approach? *Journal of Clinical Neuroscience*. 2006;**13**:690-693