

# We are IntechOpen, the world's leading publisher of Open Access books Built by scientists, for scientists

6,900

Open access books available

185,000

International authors and editors

200M

Downloads

Our authors are among the

154

Countries delivered to

TOP 1%

most cited scientists

12.2%

Contributors from top 500 universities



WEB OF SCIENCE™

Selection of our books indexed in the Book Citation Index  
in Web of Science™ Core Collection (BKCI)

Interested in publishing with us?  
Contact [book.department@intechopen.com](mailto:book.department@intechopen.com)

Numbers displayed above are based on latest data collected.  
For more information visit [www.intechopen.com](http://www.intechopen.com)



# Corneal Dystrophies and Degenerations

*Hind Alkatan, Norah Alkheraiji and Tariq Alzahem*

## Abstract

The cornea is a complex structure with complex functions aiming to protect the internal ocular tissues and transmit and refract the coming light rays. Corneal dystrophies are a group of relatively infrequent genetic corneal disorders in which an abnormal material accumulates in the cornea causing variable loss of its clarity. On the other hand, corneal degenerations are more common and usually result from physiologic changes related to aging, particular disease, or long-standing environmental insults to the cornea. Ectatic corneal disorders are usually characterized by bilateral loss of corneal biomechanical strength leading to progressive thinning and bulging of the cornea with resultant astigmatism and decreased visual acuity. In this chapter, we will describe the basic embryological, anatomical, histologic, and physiological features of the cornea. Then, we will go over the clinical, histopathologic, medical, and surgical aspects of dystrophic, degenerative, and ectatic corneal disorders.

**Keywords:** cornea, physiology, embryology, anatomy, histopathology, genetic, classification, epidemiology, clinical, topography, dystrophy, degeneration, ectasia, keratoconus, keratopathy, keratoplasty

## 1. Introduction

The wall of the eye globe is composed of the cornea and the sclera. The latter covers the posterior four-fifths of the globe with anterior and posterior openings for the cornea and the optic nerve, respectively. The cornea is the most anterior part of the globe and is normally optically clear. A healthy overlying tear film is important for the optimal function of the cornea and the esthetic wellness of the ocular surface.

The cornea is a complex structure that is responsible for protection and about three-quarters of the optical power of the natural eye with the remainder coming from the crystalline lens. The normal cornea is devoid of blood vessels to insure optimal transmission of light rays. Oxygen and nutrients are supplied, and metabolic products are eliminated primarily through the tear film anteriorly and aqueous humor posteriorly. The cornea is one of the most densely innervated tissues in the body. Thus, traumatic corneal abrasions, bacterial keratitis, and bullous keratopathy are associated with severe pain, tearing, and photophobia. The corneal nerve plexuses are supplied by the first division (ophthalmic nerve) of the fifth cranial nerve (trigeminal nerve) [1].

Corneal dystrophies are defined as a group of slowly progressive, usually inherited, bilateral, and symmetric corneal opacifying disorders that might be associated

with variable degrees of decreased vision and discomfort. Typically, they are not linked to environmental or systemic factors. Nevertheless, there are exceptions to each portion of the corneal dystrophies' definition, as some dystrophies are unilateral and asymmetric and have no recognizable heredity and have associated systemic findings [2]. Based on the cellular origin of corneal dystrophy, a modified anatomic classification is proposed consisting of epithelial and subepithelial, epithelial-stromal, stromal, and endothelial dystrophies [3].

Degenerations generally result from steady deterioration of the tissues that was previously normal with subsequent loss of their functional activity. Corneal degenerations are characterized by the deposition of a specific material, stromal thinning, and vascularization. They are not hereditary and can be unilateral. The cornea may undergo changes associated with ultraviolet light stimulation and oxidative stress that are thought to be responsible for the progression of degenerative processes [4, 5].

Corneal ectasia refers to a group of noninflammatory conditions characterized by bilateral loss of corneal biomechanical strength leading to progressive thinning and bulging of the cornea with resultant irregular astigmatism and decreased visual acuity. Examples include keratoconus, post laser-assisted in situ keratomileusis (LASIK) ectasia, pellucid marginal degeneration, and keratoglobus [1].

We will start this chapter by describing the basic sciences of the normal human cornea including embryological, anatomical, histologic, and physiological features of the cornea with mentioning selected related functional aspects. Later, we will discuss the most important corneal dystrophies, degenerations, and ectasia from clinical, histopathologic, and management points of view.

## **2. The basic sciences of the cornea**

### **2.1 Corneal embryology**

Corneal development and differentiation are the last in the well-organized series of ocular tissue formation. Thus, normal corneal development depends on normal development of the lens and optic cup. The corneal epithelium is derived from the surface ectoderm, while the corneal stroma, including Bowman's layer, and endothelium are derived from the neural crest cells. The Descemet's membrane is synthesized by endothelial cells and acts as the basement membrane of the corneal endothelium [6, 7].

The corneal development begins on the 22nd day of gestation as the surface ectoderm, the primordium of the corneal epithelium, and can be identified at the start of the 6th week of intrauterine age [8]. The neural crest cells come in three distinct waves. The first wave, in the 7th week, migrates between the primitive corneal epithelium and the lens epithelium to form the corneal endothelium. The second wave migrates to the area situated between the future corneal endothelium and the corneal epithelium and gives rise to keratocytes, the cells of the corneal stroma. The third wave of neural crest cells is located in the primitive anterior chamber to form the iris stroma [9–12].

Keratan sulfate is a proteoglycan that is produced by keratocytes and can be demonstrated at the 8th week of gestation. It is present in keratocytes and endothelial cells but not the epithelial cells [13–15]. The early corneal epithelium is composed of two layers, apical and basal layers. The outer (apical) cells are cuboidal without microvilli and are joined together by junctional complexes: zonula occludens and zonula adherens. They are connected to the basal cell by desmosomes [16]. The epithelium increases to three cell layers at 10-day postpartum and continues to thicken until reaching the adult thickness of about six layers by the 4th week of life [17].

## 2.2 Corneal anatomy, histology, and physiology

### 2.2.1 Corneoscleral limbus

The corneal limbus is simply described as the transition zone between the peripheral corneal margin and the anterior sclera. Its width is approximately 1–1.5 mm. One of the important characteristics of the limbus is that it contains the corneal stem cells detected in the basal cell layer. The limbus can be defined from histological, pathological, and surgical points of view.

From histological aspects, the anterior margin of the limbus is bounded by a line connecting the peripheral termination of Bowman's layer from the corneal epithelial side and the peripheral termination of Descemet's membrane, known as Schwalbe line, from the endothelial side. The peripheral margin is bordered by the scleral spur. From pathologists' point of view, a vertical line that is perpendicular to the scleral spur was added to define the peripheral margin [18]. Surgeons divide the limbus into two zones: a central blue zone and a peripheral concentric white zone. The area containing Bowman's layer and Descemet's membrane is seen as blue. The trabecular meshwork is located under the white zone [19].

### 2.2.2 Corneal anatomy

The cornea is the round transparent portion of the eyeball. It is the strongest refractive component of the optical system of the eye. To maintain its transparency, the normal cornea is avascular, relatively acellular, and relatively dehydrated with extraordinary organization of the stromal collagen lamellae. The diameter of the cornea measures 11–12 mm in horizontal meridian and 10–11 in vertical meridian. The average central thickness of the cornea is 520 and 650  $\mu\text{m}$  peripherally. The corneal stroma is 78% water. This percentage is controlled by an intact epithelium and a normally functioning endothelial pump. The refractive index of the cornea is 1.376 [18].

In the following subsections, we will describe the histology and physiology of different layers of the cornea from the front to the back: epithelium, Bowman's layer, stroma, Descemet's membrane, and endothelium.

### 2.2.3 Corneal epithelium

As previously mentioned, the corneal epithelium is derived from the embryonic surface ectoderm and lies on the outer surface of the cornea. The epithelium is composed of 5–6 layers of nonkeratinized stratified squamous epithelium overlying a single layer of basal cells. It is 50  $\mu\text{m}$  thick. Complete renewal of the epithelial cells occurs in 7–10 days. Three distinct layers of epithelial cells are identified: superficial flattened cells, middle wing cells, and deep basal cells [18].

The superficial and the wing cells differentiate from the basal cells. There are approximately 6000 basal cells/ $\text{mm}^2$  in a normal cornea. They are derived from the corneal limbal stem cells. The new cells migrate from the limbus in a centripetal fashion at a speed of approximately 120  $\mu\text{m}/\text{week}$ . Gap junctions serve to provide communication channels between basal cells. A basal lamina that is 50 nm thick, and is composed of type IV collagen, is actively secreted by the basal cells. The cells are attached to the underlying basal lamina via hemidesmosomes. Recurrent epithelial erosions, seen in patients with epithelial basement membrane dystrophy (EBMD), are caused by alteration of hemidesmosomes [18].

On the top of basal cells are 2–3 cell layers of wing cells. They resemble wings in cross section. Wing cells are joined together by zonulae occludentes forming a semi-permeable membrane preventing components of the tear film from gaining entry

to the corneal stroma. The superficial layer is composed of 2–3 rows of flattened cells. They shed in the tear film and are replenished by other cells. Microplicae and microvilli are observed on the apical surface of the superficial cells. Epithelial cells are attached to each other by desmosomes. Topical anesthetic abuse causes a decline in the number of desmosomes with resultant impaired healing [20].

#### 2.2.4 Bowman's layer

Bowman's layer represents the most anterior part of the stroma and lies directly posterior to the basal lamina of the corneal epithelium. Bowman's layer is not considered a true membrane and does not stain with periodic acid-Schiff (PAS). It is 8–12  $\mu\text{m}$  thick and composed of type I and type V collagen. After injury, Bowman's layer does not regenerate and, thus, a scar will form. In contrast to the stroma, the collagen lamellae are smaller and randomly organized [18].

Bowman's layer is critical in supporting the corneal biomechanics through its stiff and strong nature. Weakening of this layer can result in ectatic corneal disorders, such as keratoconus, due to loss of the biomechanical support [21].

#### 2.2.5 Corneal stroma

The corneal stroma is derived from the neural crest cells. It constitutes around 90–95% of the corneal thickness. Numerically, the central corneal thickness measures about 0.52 mm and thickens to 0.65 mm in the periphery. It has corneal stromal collagen lamellae, 200–250 lamellae that are arranged parallel to the surface of the cornea. They are predominantly made from type I and type V collagens. Keratan sulfate and dermatan sulfate are the primary proteoglycans of the stroma. These proteoglycans are located between the lamellae maintaining a constant interlamellar distance, an important factor in eliminating light scatter and, thus, a clear cornea [18]. In 2013, an acellular layer measuring approximately 10  $\mu\text{m}$  in the posterior stroma, named the pre-Descemet's layer (or Dua's layer), was introduced [22].

There are approximately 2.4 million keratocytes in the corneal stroma scattered in between the lamellae. They synthesize collagen and proteoglycans. Keratocytes are abundant in mitochondria, rough endoplasmic reticulum, and Golgi apparatuses. The plasma membranes are fenestrated, and they communicate via gap junctions. There is a documented decline in the cell density associated with age [18].

The anterior part of the stroma is typically drier than the posterior part. This is caused by the drying effect of the atmosphere anteriorly and the wetting effect of the aqueous humor posteriorly. An enlarged spacing between the lamellae, as in cases of corneal stromal edema from endothelial injury, will result in hazy cornea and decreased visual acuity [18].

#### 2.2.6 Descemet's membrane (DM)

Descemet's membrane is a true basement membrane, for corneal endothelium, that is PAS positive. The thickness of DM varies according to the age of the individual. It is continuously secreted by the endothelium through life. In newborns, it measures about 2–4  $\mu\text{m}$  in thickness and reaches to 10–12  $\mu\text{m}$  in adults [18].

Histologically, DM has two layers: an anterior banded layer produced during fetal life and a posterior non-banded layer produced after birth. It is made of type IV collagen, laminin, and fibronectin [18].

DM provides support and adhesion to endothelial cells. Under pathologic conditions, it works as a biologic barrier to the phagocytic, toxic, and



enzymatic degradation. Notably, DM is weakly attached to the overlying stroma, or pre-Descemet's layer, and can be surgically dissected as one piece (Descemetorrhexis) [18].

### *2.2.7 Corneal endothelium*

The corneal endothelium is the innermost layer of the cornea. It is about 4–6  $\mu\text{m}$  thick. As mentioned earlier, the endothelium originates from neural crest cells. The cells cannot be replenished if lost. There are about 500,000 endothelial cells covering the posterior surface of the cornea with a density of 3000 cells/ $\text{mm}^2$ . There is approximately 0.6% endothelial cell loss per year, and this rate increases significantly after traumatic, iatrogenic, inflammatory, or infectious conditions affecting the endothelium. The most common normal cell shape is hexagonal with minimal polymegathism and pleomorphism [18].

To maintain the corneal clarity, the endothelium works as a barrier and as a metabolic pump. Endothelial cells are linked together by interdigitations and focal tight junctions. They communicate via gap junctions. Some nutrients are allowed to pass paracellularly to the remaining corneal layers indicating a semipermeable nature of the endothelial cell layer [18].

The corneal endothelium is a highly active tissue. This is evident by the presence of numerous mitochondria, the prominent endoplasmic reticulum, ribosomes, and Golgi apparatus. The fluid is pumped out of the corneal stroma into the anterior chamber via pinocytotic vesicles [18].

Hassall-Henle bodies, or peripheral cornea guttae, are considered a natural aging process in which small excrescences are observed in the peripheral part of Descemet's membrane. They denote focal areas of thickening of Descemet's membrane. On the other hand, central cornea guttae are pathologic in nature and are associated with progressive corneal stromal and epithelial edema as in patients with Fuchs' endothelial dystrophy [18].

## **3. Corneal dystrophies**

Generally, corneal dystrophies are defined as a group of progressive, inherited, mostly bilateral, and symmetric, variable corneal opacifying disorders, which are usually not related to environmental or systemic conditions. They can be associated with blurred vision and ocular discomfort. Their onset is usually early in life but they manifest later clinically. They are slowly progressive and become more prominent with age. There are exceptions to the corneal dystrophies definition: some dystrophies are unilateral or bilateral asymmetric, some have no obvious heredity, and some have related systemic abnormalities [1, 2].

In 2015, the International Committee on the Classification of Corneal Dystrophies (IC3D) proposed a modified anatomic classification on the basis of the cellular origin of the corneal dystrophies consisting of [3]:

1. Epithelial and subepithelial dystrophies
2. Epithelial-stromal transforming growth factor  $\beta$ -induced gene (TGFB1) dystrophies
3. Stromal dystrophies
4. Endothelial dystrophies

An evidence-based category system was suggested to indicate the level of evidence that supports the existence of a given corneal dystrophy. In this system, each dystrophy is organized according to the clinical phenotype, with a template summarizing genetic, clinical, and pathologic information. The system is upgradable and can be retrieved at [www.corneasociety.org](http://www.corneasociety.org). The categories are as follows [23]:

**Category 1 (C1):** a well-defined corneal dystrophy in which the gene has been mapped and identified and the specific mutations are known.

**Category 2 (C2):** a well-defined corneal dystrophy that has been mapped to one or more specific chromosomal loci, but the gene(s) remains to be identified.

**Category 3 (C3):** a well-defined corneal dystrophy in which the disorder has not yet been mapped to a chromosomal locus.

**Category 4 (C4):** this category is reserved for a suspected, new, or previously documented corneal dystrophy, although the evidence for it, being a distinct entity, is not yet convincing.

In the following subsections, we will describe the clinical, genetic, and histopathologic characteristics of the common corneal dystrophies from anterior to posterior: epithelial and subepithelial, epithelial-stromal (TGFBI), stromal, and endothelial dystrophies.

### 3.1 Epithelial and subepithelial corneal dystrophies

The included dystrophies are:

1. Epithelial basement membrane dystrophy (EBMD)
2. Epithelial recurrent erosion dystrophies (EREDs)—Franceschetti corneal dystrophy (FRCD), Dystrophia smolandensis (DS), and Dystrophia helsinglandica
3. Subepithelial mucinous corneal dystrophy (SMCD)
4. Meesmann corneal dystrophy (MECD)
5. Lisch epithelial corneal dystrophy (LECD)
6. Gelatinous drop-like corneal dystrophy (GDLD)

#### 3.1.1 Epithelial basement membrane dystrophy (EBMD)

EBMD, also known as map-dot-fingerprint dystrophy [24], Cogan's microcystic epithelial dystrophy [25], and anterior basement membrane dystrophy, is the most common anterior corneal dystrophy. It can reach up to 70% in individuals above the age of 50 years and is found to be infrequent in the pediatric population [26]. It was found to be more common in females [27].

*Inheritance:* mostly sporadic with familial cases have been reported. Thus, they are thought to be degenerative or caused by previous trauma.

*Genetic locus and gene:* 5q31. One report has identified TGFBI in two families.

*Category:* most cases are sporadic. C1 in rare cases.

*Onset:* usually in the second decade.

*Symptoms:* it maybe asymptomatic or associated with recurrent epithelial erosions in 10% of patients due to poor adhesion of basal epithelial cells to the basal

laminar material. Irregular astigmatism might cause decreased vision and monocular diplopia. The severity of pathology can fluctuate with time.

*Signs:* can be isolated or combined and unilateral or bilateral.

- Maps: central or paracentral thickened, scalloped, circumscribed borders resembling coastlines, associated with faint haze.
- Fingerprints: paracentral, hair-like, curvilinear concentric lines, best visualized with retro-illumination.
- Dots: central, round or oval, non-staining, intraepithelial opacities. These lesions contain debris of degenerated epithelial cells.
- Bleb pattern: subepithelial bleb or cobble stone-like pattern, best seen by retro-illumination.

*Histopathology:*

- Maps: thickened intraepithelial, multilamellar, basement membrane.
- Fingerprints: intraepithelial extensions of basement membrane that are rib-like.
- Dots: intraepithelial cyst-like lesions containing degenerated cytoplasmic debris.
- Bleb pattern: subepithelial fibrillo-granular material accumulation.
- Bowman's layer is not affected.

*Management:* in asymptomatic cases no intervention is required. When symptoms occur, the frequent use of lubricants is recommended (preferably preservative-free lubricants). Hypertonic drops (i.e., sodium chloride 3–5%) during the daytime and an ointment at night can be helpful. Topical antibiotics are needed in cases where there are erosions. Cautious wear of a bandage contact lens may help in providing comfort and healing. In severe cases, debridement of the epithelial surface might be needed, and, in some cases, a phototherapeutic keratectomy (PTK) might be helpful.

### 3.1.2 Epithelial recurrent erosion dystrophies (EREDs)

*Inheritance:* autosomal dominant.

*Variants:*

- Franceschetti corneal dystrophy (FRCD)
- Dystrophia smolandiensis (DS)
- Dystrophia helsinglandica (DH)

*Genetic locus and gene:* unknown.

*Category:* C3.

*Onset:* childhood.

*Symptoms:* recurrent epithelial erosion attacks that start in childhood and continue in adulthood. The attacks are usually nocturnal. Corneal opacification, which



may be visually significant if located centrally, occurs in about half of the cases. Painful erosive episodes usually decrease with age.

*Signs:* repeated epithelial erosions lasting up to 7 days in duration. Typically, no signs can be detected after healing of the attack. However, central subepithelial opacities, subepithelial fibrosis, or corneal keloids may develop later in life.

*Histopathology:* the basal epithelial cells are irregular with distended intercellular spaces. Intracellular and intercellular Alcian blue-positive deposits are present. Bowman's layer is partial or completely destroyed. Avascular pannus is between the basal epithelium and the Bowman layer [3].

*Management:* in asymptomatic patients, treatment is not required. Recurrent erosive episodes are treated as for recurrent epithelial erosions. Epithelial debridement may be necessary in patient with irregular astigmatism.

### 3.1.3 Subepithelial mucinous corneal dystrophy (SMCD)

*Inheritance:* mostly autosomal dominant.

*Genetic locus and gene:* unknown.

*Category:* C4.

*Onset:* early childhood.

*Symptoms:* painful epithelial erosions that might decrease in frequency with age.

The vision tends to deteriorate with time.

*Signs:* subepithelial haze denser in the center.

*Histopathology:* subepithelial band of eosinophilic, periodic acid-Schiff (PAS)-positive, Alcian blue-positive, hyaluronidase-sensitive material is present anterior to the Bowman layer [3].

*Management:* recurrent erosive episodes are treated as for recurrent epithelial erosions.

### 3.1.4 Meesmann corneal dystrophy (MECD)

MECD is also known as Meesmann-Wilke syndrome and Meesmann's juvenile epithelial corneal dystrophy [28, 29].

*Inheritance:* mostly autosomal dominant.

*Variant:* stocker-Holt variant.

*Genetic locus and gene:* 2 loci and 2 genes.

- Locus 12q13 (KRT3 gene)
- Locus 17q12 (KRT12 gene) in Stocker-Holt variant

*Category:* C1.

*Onset:* usually in the first decade.

*Symptoms:* most patients are asymptomatic. Glare, photophobia, decreased vision, or recurrent epithelial erosions may occur. It is slowly progressive or even nonprogressive. Patients affected with Stocker-Holt variant show more severe signs and symptoms with earlier onset.

*Signs:* bilateral and symmetric numerous central and peripheral intraepithelial vesicles most dense in the interpalpebral area. Gray opacities usually having a distinct border with some areas being spared. Microcysts are seen in about 80% of corneas and are more evident with retro-illumination. These cysts coalesce resulting in refractile linear opacities. Mild corneal thinning or reduced sensation may occur. In patients with Stocker-Holt variant, diffuse grayish punctate superficial opacities that stain with fluorescein are observed.

**Histopathology:** the epithelium is thickened and disorganized exhibiting intraepithelial cysts filled with PAS-positive cellular debris. There is a multilaminar, thickened basement membrane extending into the basal epithelium. Bowman's layer and corneal stroma that remain are not affected [3].

**Management:** in symptomatic cases, strategies for relief of the epithelial erosions include topical antibiotics to protect against infection, heavy lubrication, and contact lens application. In more severe cases, epithelial debridement and corneal keratoplasty are considered [30].

### 3.1.5 Lisch epithelial corneal dystrophy (LECD)

**History:** Lisch epithelial corneal dystrophy (LECD) was first described in 1992 in five family members and three unrelated individuals who presented with unilateral or bilateral bands of grayish granular opacifications on the cornea [31].

**Inheritance:** X-chromosomal dominant.

**Genetic locus and gene:** Xp22.3, the gene is unknown.

**Category:** C2.

**Onset:** childhood.

**Symptoms:** asymptomatic if the dystrophy is not involving the pupillary axis. Slowly progressive with decreased visual acuity if the corneal center is involved.

**Signs:** gray opacities that come in different patterns including band-shaped, radial, feathery, and whorl-like. Multiple clear cysts are seen with indirect illumination resembling MECD. However, the difference is in the molecular genetics.

**Histopathology:** PAS-positive vacuolated cells are present in the epithelial surface [3].

**Management:** treatment only if the individual is symptomatic with heavy lubrication. In some cases, debridement might be helpful. Phototherapeutic keratectomy (PTK) can be beneficial in some cases [32].

### 3.1.6 Gelatinous drop-like corneal dystrophy (GDLD)

GDLD was first described by Nakaizumi (1914) [33]. It was found to be more common in Japan.

**Inheritance:** autosomal recessive.

**Genetic locus and gene:** 1p32, tumor-associated calcium signal transducer 2 (TACSTD2).

**Category:** C1.

**Onset:** during the first 2 decades.

**Symptoms:** blurred vision, photophobia, foreign body sensation, and tearing.

**Signs:** subepithelial lesions may look like band keratopathy initially. Mulberry configuration of nodules that stain with fluorescein can occur. This configuration indicates epithelial hyperpermeability. Vascularization and stromal scarring are seen later in the course of the disease.

**Histopathology:** amyloid deposits in the subepithelial and stromal [3].

**Management:** treatment for symptomatic cases includes heavy lubrication. Superficial keratectomy or keratoplasty can be helpful when there is visual impairment. Recurrence is common following superficial keratectomy, lamellar keratoplasty, and penetrating keratoplasty [34].

## 3.2 Epithelial-stromal TGFBI dystrophies

The included dystrophies are:

### 1. Reis-Bücklers corneal dystrophy (RBCD)

2. Thiel-Behnke corneal dystrophy (TBCD)
3. Lattice corneal dystrophy, type 1 (LCD1)
4. Granular corneal dystrophy, type 1 (GCD1)
5. Granular corneal dystrophy, type 2 (GCD2)

### 3.2.1 Reis-Bucklers corneal dystrophy (RBCD)

RBCD was first described in 1917. It is also known as geographic corneal dystrophy of Weidle, superficial granular corneal dystrophy, atypical granular corneal dystrophy, granular corneal dystrophy type 3, and anterior limiting membrane dystrophy type 1 [35].

*Inheritance:* autosomal dominant.

*Genetic locus and gene:* 5q31, transforming growth factor  $\beta$ -induced gene (TGFB1).

*Category:* C1.

*Onset:* during the first decade of life.

*Symptoms:* blurred vision and recurrent corneal epithelial erosions. It is slowly progressive. The frequency of recurrent corneal erosions tends to decline with age. It has a more aggressive course than Thiel-Behnke corneal dystrophy (TBCD). In addition, the diagnosis can be confused between RBCD and TBCD.

*Signs:* early in the course of the disease, there are varying densities of bilateral irregular geographic-like opacities with clear interruptions at the level of Bowman's layer and anterior stroma. They are discrete in early stages and become diffuse with deeper involvement. As the disease progresses, these fine reticular lesions coalesce to form a confluent gray whitish opacity that might affect vision as the surface becomes more irregular. At later stages, the corneal sensation is reduced, and ring-shaped (sometimes crescent-shaped) opacifications cover the central cornea and can extend to the mid-periphery. The most peripheral cornea remains clear.

*Histopathology:* granular sheet-like deposits replace Bowman's layer. These deposits stain red with Masson trichrome. The anterior, middle, and even posterior stroma can be involved in advanced cases. Electron microscopy is required to distinguish RBCD from TBCD. In RBCD, rod-shaped subepithelial bodies are seen, while curly fibers are characteristic for TBCD [3].

*Management:* treatment of corneal erosions is similar to that of other dystrophies. Phototherapeutic keratectomy (PTK) can be beneficial in some cases. In advanced corneal involvement, keratoplasty might be helpful.

### 3.2.2 Thiel-Behnke corneal dystrophy (TBCD)

TBCD is also known as corneal dystrophy of Bowman's layer type II, curly fibers corneal dystrophy, Waardenburg-Jonkers corneal dystrophy, and, most commonly, "honeycomb dystrophy." It was first described in 1967 [36–38].

*Inheritance:* autosomal dominant.

*Genetic locus and gene:* 5q31, TGFB1.

*Category:* C1.

*Onset:* during the first decade of life.

*Symptoms:* visual deterioration occurs later, and recurrent corneal epithelial erosions are less frequent than in RBCD. Slowly progressive corneal scarring is the main cause of decreased vision. The recurrence of corneal erosions decreases with time.

*Signs:* irregularly shaped scattered opacities and solitary flecks at the level of the Bowman's layer are present in the initial stages. Then, central honeycomb opacities

are observed in the subepithelial area. As in patients with RBCD, corneal opacities can progress peripherally and to deeper stromal layers. Prominent corneal nerves can be seen. The corneal periphery remains clear even as the lesions progress. Corneal sensation might be affected. Reis-Buckler's dystrophy and Thiel-Behnke can be clinically distinguished by the minimal loss of corneal sensation and honeycomb opacity that occurs with Thiel-Behnke dystrophy [37, 39].

*Histopathology:* irregular thickening and thinning of the epithelial layer due to irregular underlying stroma with focal absence of the epithelial basement membrane. Wavy saw-toothed superficial fibro-cellular pannus replaces the Bowman's layer [3].

*Management:* treatment is indicated only in symptomatic cases. The episodes of recurrent erosion are treated like the previous dystrophies. Hypertonic drops and ointment may be beneficial. In some cases, debridement of the corneal epithelium may be necessary. Phototherapeutic keratectomy (PTK) can also help with recurrent erosions or superficial opacifications [37, 39]. Keratoplasty is reserved for deeper lesions, but the dystrophy may recur in the donor graft.

### 3.2.3 Lattice corneal dystrophy, type 1 (LCD1) and variants

*Inheritance:* autosomal dominant.

*Variants:* LCD (III, IIIA, I/IIIA, IV). Lattice corneal dystrophy type 2 (LCD2) is a misnomer and should be termed familial amyloidosis, Finnish type, or gelsolin type as suggested by the IC3D. LCD2 is also known as Meretoja syndrome.

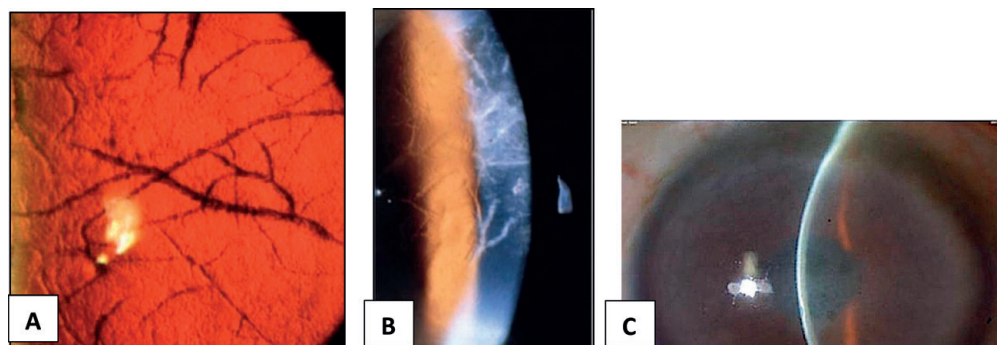
*Genetic locus and gene:* 5q31, TGFBI.

*Category:* C1.

*Onset:* during the first two decades of life.

*Symptoms:* visual deterioration, discomfort, and pain. Recurrent attacks of corneal erosions occur early in the course of LCD1. Patients with progressive visual impairment are seen within the fourth decade.

*Signs:* central superficial fleck-like opacities are seen initially. By using retro-illumination technique, sparse peripheral lattice lines are visible initially in the superficial stroma (**Figure 1A**). Centrally located, superficial branching refractile lines resembling tree branches and round/ovoid whitish dots are also detected in the first decade (**Figure 1B**). Central and paracentral diffuse subepithelial haze develops alongside the lattice lines. They typically spare the limbus, Descemet's membrane, and endothelium. The average depth in the stroma is about 79  $\mu\text{m}$  [40]. Reduction of visual acuity is caused by the progression of the stromal haze (**Figure 1C**). LCD1 may be asymmetric or even unilateral. Central thicker lattice lines are seen in variant LCD type IIIA, while LCD type IV is characterized by deeper deposits without epithelial erosion.



**Figure 1.**  
(A) The appearance of the lattice deposits with retro-illumination, (B) slit lamp appearance of the lattice configuration of the stromal deposits in this type of dystrophy, and (C) clinical appearance of an advanced case of lattice dystrophy.



**Histopathology:** the corneal epithelium is atrophic with degenerative changes of basal epithelial cells. The Bowman's layer is disrupted or even absent. Subepithelial accumulation and stromal accumulation of amyloid deposits alter the architecture of corneal collagen lamellae (**Figure 2**). These deposits stain positive with Congo red and show birefringence with polarizing light (**Figure 3**) [41]. Metachromasia and fluorescence are demonstrated with crystal violet and thioflavin T staining, respectively. Descemet's membrane and the endothelium are normal [3].

**Management:** treatment is based on the symptoms and the depth of the deposits. Options might include phototherapeutic keratectomy (PTK) with anterior lesions and where there are recurrent corneal erosions, lamellar keratoplasty (LKP) and penetrating keratoplasty (PKP) for deeper lesions. Reports on recurrence after DLKP that was associated with incomplete removal of corneal stroma [42]. Overall, recurrence was reported to be earlier compared to macular and granular corneal dystrophies [43].

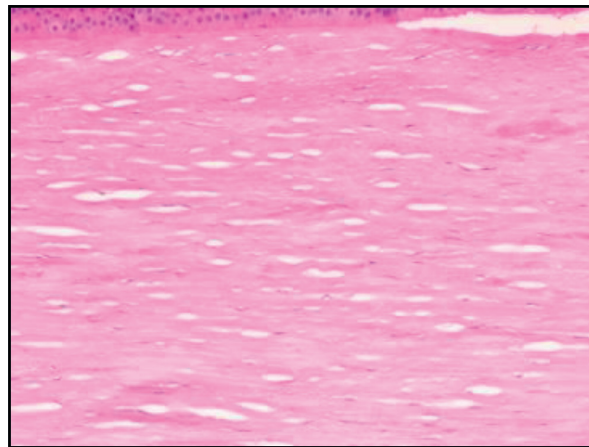
#### 3.2.4 Granular corneal dystrophy, type 1 (classic) (GCD1)

**Inheritance:** autosomal dominant.

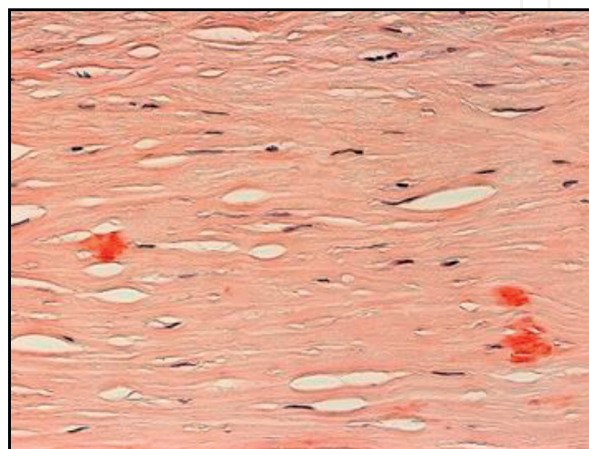
**Genetic locus and gene:** 5q31, TGFBI.

**Category:** C1.

**Onset:** early childhood.



**Figure 2.**  
*The amyloid deposits within the stroma in lattice dystrophy (original magnification 200× hematoxylin & eosin).*



**Figure 3.**  
*The same amyloid deposits staining with Congo red stain (original magnification 400× Congo red).*



**Symptoms:** patients usually complain of glare, photophobia, and recurrent erosions. Visual deterioration occurs as corneal opacification progresses with time as the opacities become more confluent.

**Signs:** initially, subepithelial verticillate-like opacities are evident by retro- and direct illumination. Later, there will be white well-defined granules with clear intervening stroma (**Figure 4**). Typically, opacities do not extend to the limbus. With age, granules extend deeper into the corneal stroma close to Descemet's membrane.

**Histopathology:** multiple stromal deposits may extend from deep epithelium to Descemet's membrane. Hyaline opacities stain with Masson trichrome (**Figure 5A and B**) [3, 41].

**Management:** treatment options if symptomatic include lubrication, hypertonic solution, and bandage contact lenses. Phototherapeutic keratectomy (PTK) and keratoplasty for deeper lesions. Recurrence occurred in all grafts within 4 years [44].

### 3.2.5 Granular corneal dystrophy, type 2 (GCD2)

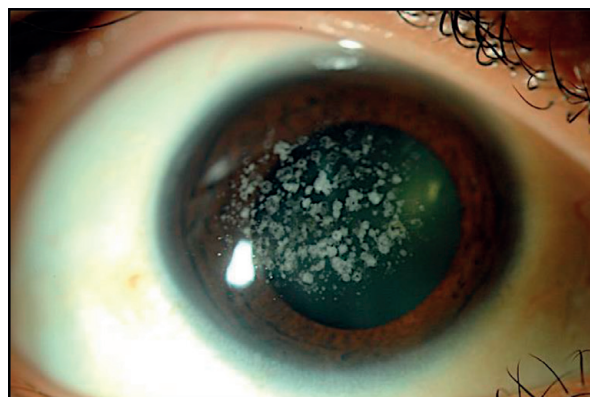
**Nomenclature:** also called combined granular-lattice corneal dystrophy or Avellino corneal dystrophy. It was named after the Avellino region in Italy, where first cases have been reported.

**Inheritance:** autosomal dominant.

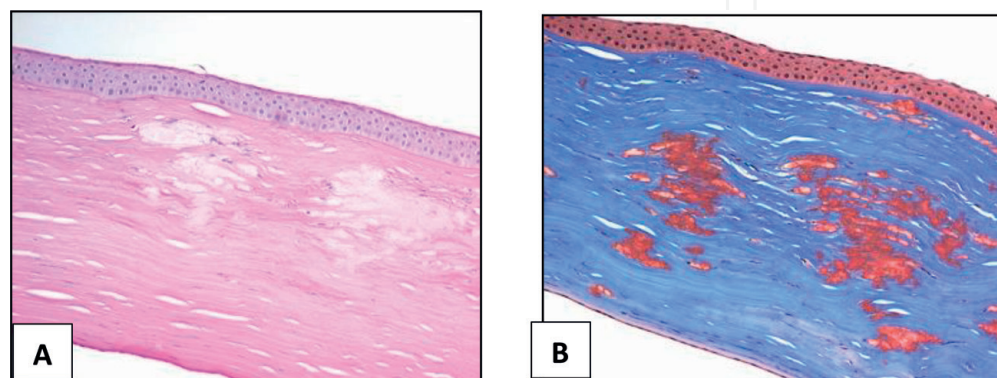
**Genetic locus and gene:** 5q31, TGFBI.

**Category:** C1.

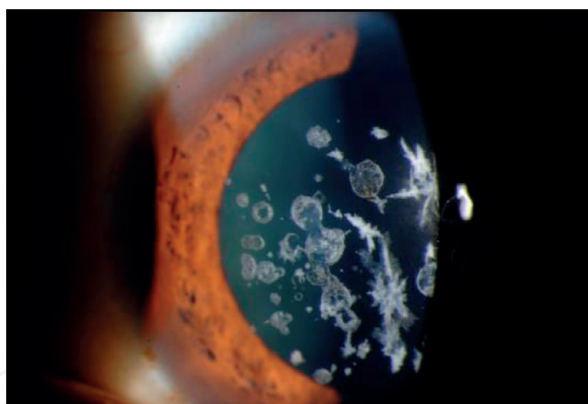
**Onset:** in homozygous patients, the onset is in early childhood. Heterozygous patients present in late childhood.



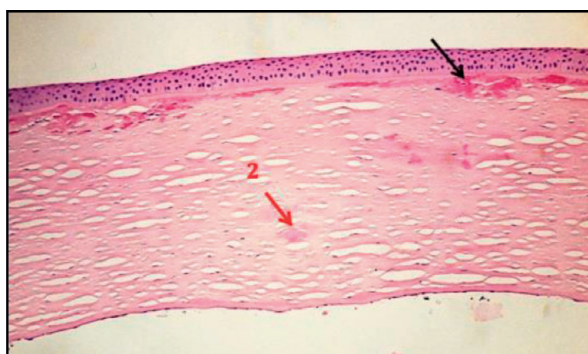
**Figure 4.**  
The clinical appearance of granular dystrophy (courtesy of Dr. Hatem Kalantan, associate professor, Department of Ophthalmology, King Saud University, Riyadh, SA).



**Figure 5.**  
(A) The histopathological appearance of the hyaline deposits in granular dystrophy (original magnification 200× periodic acid-Schiff) and (B) the same deposits highlighted using special stain (original magnification 200× Masson Trichrome).



**Figure 6.**  
The clinical appearance of Avellino dystrophy with classic combined spiky opacities as well as the granular deposits (courtesy of Dr. Majed Alkharashi, FRCS C, assistant professor, Department of Ophthalmology, King Saud University, Riyadh, SA).



**Figure 7.**  
The histopathological appearance of the two kinds of deposits: superficial hyaline deposits (black arrow) and the amyloid deposits (labeled as #2 with red arrow) deeper in the stroma (original magnification 100× periodic acid-Schiff).

**Symptoms:** recurrent erosive attacks. Visual deterioration occurs when visual axis is involved. Homozygotes are having a more rapid course.

**Signs:** initially, very small superficial stromal tiny whitish dots with small spokes that are usually arranged linearly like a string of pearls. With time, the center of the opacity fades resembling a ring. The anterior stromal deposits take the shape of spiky stars, icicles, or spider. The posterior corneal stroma may demonstrate linear or dot-like branching stromal opacities. The lines or dashes in GCD2 can be differentiated from LCD in that in GCD2 the lines are whiter, compared to the refractile nature of lattice lines in LCD. In addition, in GCD2, typically, the lines do not cross, while lattice lines in LCD characteristically intersect resulting in the lattice configuration. Compared to GCD1, patients with GCD2 have fewer stromal opacities (**Figure 6**). Homozygote patients present earlier with frequent superficial small dots and larger, dense superficial opacities in stroma that become deeper with age.

**Histopathology:** the abnormal corneal deposits extend from the basal epithelium to the deep stroma. Hyaline and amyloid materials are deposited and stain with Masson trichrome and/or Congo red (**Figure 7**). More severe histopathological findings are seen in homozygotes [3].

**Management:** treatment is usually not required. Refractive surgery is contraindicated.

### 3.3 Stromal dystrophies

The included dystrophies are:

1. Macular corneal dystrophy (MCD)
2. Schnyder corneal dystrophy (SCD)
3. Congenital stromal corneal dystrophy (CSCD)
4. Fleck corneal dystrophy (FCD)
5. Posterior amorphous corneal dystrophy (PACD)
6. Central cloudy dystrophy of François (CCDF)
7. Pre-Descemet corneal dystrophy (PDCD)

### 3.3.1 Macular corneal dystrophy (MCD)

*Nomenclature:* macular corneal dystrophy (MCD) is also known as Groenouw corneal dystrophy type II and Fehr spotted dystrophy [45, 46].

*Inheritance:* autosomal recessive.

*Variants:* Three variants that are clinically indistinguishable but on the basis of immunoreactivity of specific sulfated epitopes of antigenic keratan sulfates (AgKS) in the cornea and the serum:

1. MCD type I: no AgKS reactivity in the cornea and in the serum.
2. MCD type IA: keratocytes demonstrate AgKS reactivity, but not the extracellular tissue. No AgKS in the serum.
3. MCD type II: all deposits react with AgKS. Serum has normal or low levels of AgKS.

*Genetic locus and gene:* 16q22, carbohydrate sulfotransferase 6 gene—CHST6.

*Category:* C1.

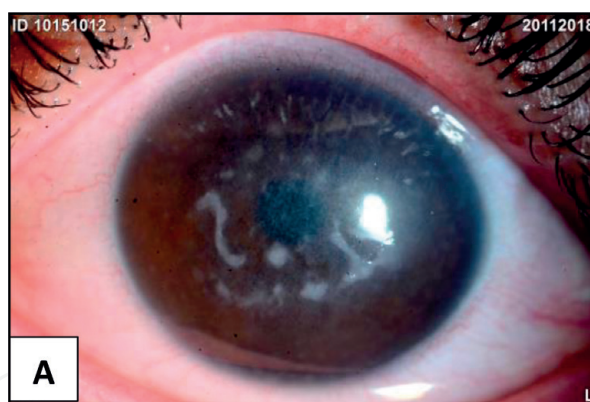*Onset:* during the first decade of life.

*Symptoms:* slowly progressive visual deterioration which becomes severe during the second and third decades. Light sensitivity and recurrent epithelial erosions can rarely be seen. Corneal sensation is reduced.

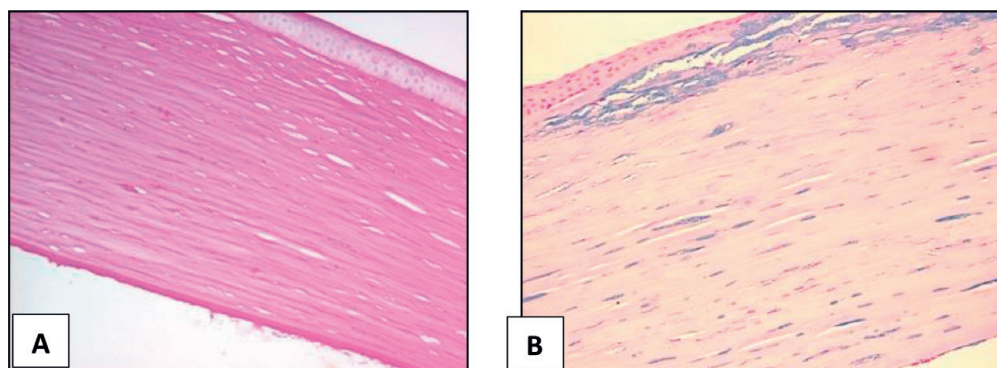
*Signs:* early in the course of the disease, central superficial whitish fleck-like opacities develop. Compared to GCD, these opacities extend peripherally to the limbus and the deep stroma down to Descemet's membrane. The intervening corneal stroma develops a progressive and diffuse haze (**Figure 8**). The epithelium is typically intact and, thus, corneal epithelial erosions are rare. The corneal thickness is reduced. Later in the course of the disease, corneal guttata and, rarely, endothelial decompensation occur.

*Histopathology:* glycosaminoglycans (GAGs) accumulate intracellularly and in the extracellular space and are better demonstrated with Alcian blue stain (**Figure 9A and B**). Breaks in the Bowman layer are observed. Stromal thinning and an overlying epithelial hyperplasia. Descemet's membrane and endothelium are involved. Descemet's membrane thickening and guttata are seen infrequently [3, 41]. Ultrastructural imaging and three-dimensional imaging of corneas with MCD demonstrate a clear organization of proteoglycans around the collagen fibrils. The collagen fibril diameter is significantly smaller than those of the normal cornea [47].





**Figure 8.**  
*The clinical appearance of macular dystrophy.*



**Figure 9.**  
*(A) The histopathological appearance of the deposits in a case of macular dystrophy involving the full stromal thickness and the endothelium with secondary guttata (original magnification 200× periodic acid-Schiff) and (B) the glycosaminoglycan deposits in this dystrophy are demonstrated using Alcian blue stain (original magnification 200×).*

**Management:** the treatment depends on the symptoms. Photophobia may be treated with lubrication and tinted contact lens. Superficial opacities can be treated with PTK and keratoplasty with deeper lesions. Recurrence may appear on the donor grafts [48].

### 3.3.2 Schnyder corneal dystrophy (SCD)

**Inheritance:** autosomal dominant.

**Genetic locus and gene:** 1p36, UbiA prenyltransferase domain containing 1—UBIAD1.

**Category:** C1.

**Onset:** the diagnosis is usually made during the second or third decade although onset may be in childhood. In patients with the crystalline form, diagnosis may be further delayed.

**Symptoms:** slowly progressive visual loss and glare. Scotopic vision is better than photopic vision. Corneal sensation decreases with age. It may be associated with hyperlipoproteinemia (type IIa, III, or IV). Significant visual deterioration usually occurs during the sixth decade.

**Signs:** clinical findings largely depend on the age of the patient. In patients who are 23 years or younger, a central round ring-like opacity or central comma-shaped subepithelial crystals are seen. Arcus lipoides usually develops in patients between 23 and 38 years of age. Diffuse stromal haze also develops after the age of 38. Almost 50% of patients demonstrate corneal crystals, which may be unilateral, and can occur late in the disease course.

*Histopathology:* intracellular and extracellular esterified and unesterified phospholipids and cholesterol are deposited in basal epithelial cells, Bowman's layer, and stroma. Fresh tissue stains positive with Oil Red O or Sudan black. Moreover, secondary amyloid and GAG depositions in cases with SCD were published [3].

*Management:* treatment is by excimer keratectomy or corneal transplantation procedures.

### 3.3.3 Congenital stromal corneal dystrophy (CSCD)

*Inheritance:* autosomal dominant.

*Genetic locus and gene:* 12q21.33, decorin, DCN.

*Category:* C1.

*Onset:* at birth.

*Symptoms:* variable degree of visual deterioration and less commonly photophobia. It is slowly progressive or even stationary.

*Signs:* diffuse, bilateral corneal clouding with whitish pan-stromal opacities. The corneal epithelium is intact. The corneal stroma is thicker than in normal individuals.

*Histopathology:* irregular separation of the corneal stromal lamellae that might contain amorphous material [3].

*Management:* spectacles or contact lenses for refractive errors, penetrating keratoplasty.

### 3.3.4 Fleck corneal dystrophy (FCD)

*Inheritance:* autosomal dominant.

*Genetic locus and gene:* 2q34, phosphoinositide kinase, FYVE finger containing— PIKFYVE.

*Category:* C1.

*Onset:* at birth or during the first years of life.

*Symptoms:* FCD is typically asymptomatic or associated with photophobia. It is a stationary dystrophy.

*Signs:* small, discrete, translucent, dandruff-like opacities scattered at any level of the corneal stroma and may extend to the limbus. The epithelium, Bowman's layer, Descemet's membrane, and endothelium are usually normal. The involvement can be asymmetric or unilateral.

*Histopathology:* the keratocytes are swollen and vacuolated and contain GAGs and complex lipids [3].

*Management:* treatment is usually not required.

### 3.3.5 Posterior amorphous corneal dystrophy (PACD)

*Inheritance:* autosomal dominant.

*Genetic locus and gene:* 12q21.33, deletion of keratocan (KERA), lumican (LUM), decorin (DCN), and epiphykan (EPYC).

*Category:* C1.

*Onset:* it is usually in the first decade of life.

*Symptoms:* mild slowly progressive, or nonprogressive, reduction of visual acuity.

*Signs:* diffuse gray sheet-like stromal opacities most prominent posteriorly. Corneal thinning is noted. Characteristic corneal flattening to less than 41 diopters with hyperopia. Descemet's membrane may be indented by the opacities.



Endothelial abnormalities have been reported. Other ocular associations include prominent Schwalbe's line, fine iris processes, pupillary remnants, iridocorneal adhesions, and iris hypoplasia. Notably, there is no associated glaucoma.

*Histopathology:* irregular posterior stromal lamellae. Positive staining with colloidal iron anterior to the Descemet's membrane. Localized attenuation of endothelial cells [3].

*Management:* if visual impairment is significant, penetrating keratoplasty is indicated.

### 3.3.6 Central cloudy dystrophy of Francois

*Inheritance:* mostly unknown. Autosomal dominant inheritance has been reported.

*Genetic locus and gene:* none.

*Category:* C4.

*Onset:* it usually presents in the first decade of life.

*Symptoms:* typically, asymptomatic.

*Signs:* nonprogressive central cloudy or rounded stromal opacities that are surrounded by clear tissue. It is clinically indistinguishable from posterior crocodile shagreen, a corneal degeneration. It has been associated with pseudoxanthoma elasticum, pre-Descemet's dystrophy, glaucoma, polymorphic amyloid degeneration, and keratoglobus.

*Histopathology:* no description has been reported in familial cases. Positive staining for GAGs [3].

*Management:* if visual impairment is significant, penetrating keratoplasty is indicated.

### 3.3.7 Pre-Descemet corneal dystrophy (PDCD)

*Inheritance:* there is no clear pattern of inheritance. It can be isolated although it has been described in certain families up to four generations. Autosomal dominant inheritance in 1 pedigree has been reported in the punctiform and polychromatic PDCD. Deep corneal stromal opacities are frequently seen in X-linked ichthyosis.

*Genetic locus and gene:* isolated PDCD—unknown genetic locus and gene. PDCD associated with X-linked ichthyosis—Xp22.31, steroid sulfatase (STS).

*Category:* C1 in PDCD associated with X-linked ichthyosis. C4 in isolated PDCD.

*Onset:* usually during the fourth. However, it has been reported in children as young as 3 years.

*Symptoms:* typically, asymptomatic. Punctiform and polychromatic PDCD are stationary. Other forms are progressive.

*Signs:* the specific signs depend on the PDCD subgroups. Notably, many of the subgroups may represent sporadic or age-related degenerative changes. Deep stromal focal, fine opacities that may be central, annular, or diffuse. The changes are more uniform and polychromatic in an otherwise normal cornea in the punctiform and polychromatic subtypes.

*Histopathology:* enlarged keratocytes in the posterior corneal stroma containing vacuoles and intracytoplasmic inclusions of lipid-like material [3].

*Management:* usually not required.

## 3.4 Endothelial dystrophies

The included dystrophies are:

1. Fuchs endothelial corneal dystrophy (FECD)

2. Posterior polymorphous corneal dystrophy (PPCD)
3. Congenital hereditary endothelial dystrophy (CHED)
4. X-linked endothelial corneal dystrophy (XECD)

#### 3.4.1 Fuchs endothelial corneal dystrophy (FECD)

FECD was first described in 1910 [49]. It is a noninflammatory, slowly progressive degeneration of endothelial cells which leads to corneal decompensation edema.

*Inheritance:* the genetic basis of FECD is complex and heterogeneous. Most cases are without a known inheritance pattern. Some autosomal dominant cases were reported.

*Genetic locus and gene:*

1. Early-onset FECD: 1p34.3-p32 (FECD1), collagen type VIII, alpha-2, COL8A2.
2. Late-onset FECD: reported genetic loci include 13pter-q12.13 (FECD2), 18q21.2-q21.3 (FECD3), 20p13-p12 (FECD4), 5q33.1-q35.2 (FECD5), 10p11.2 (FECD6), 9p24.1-p22.1 (FECD7), and 15q25 (FECD8). The gene is not identified.

*Category:* C1 in early-onset FECD, C2 in patients with identified genetic loci, and C3 in patients without known inheritance.

*Onset:* the patients are usually in the fourth decade or older. Early-onset FECD starts in the first decade. There is a female predominance at a ratio of 2.5:1 to 3:1.

*Symptoms:* progressive intermittent reduction in vision worse in the morning from epithelial/stromal edema caused by overnight eye closure. Epithelial erosions resulting from ruptured epithelial bullae typically cause pain, photophobia, and tearing. Patients also complain of progressive visual deterioration.

*Signs:* the signs of FECD can be reflected in four stages:

Stage 1: central cornea guttata that spreads peripherally. Some never progress to later stages. Corneal guttae in late-onset FECD are larger than those seen in early-onset FECD.

Stage 2: endothelial decompensation and stromal edema. Corneal endothelium has a beaten metal-like appearance with a thickened Descemet's membrane.

Stage 3: intraepithelial and interepithelial edema with epithelial bullae (bullous keratopathy).

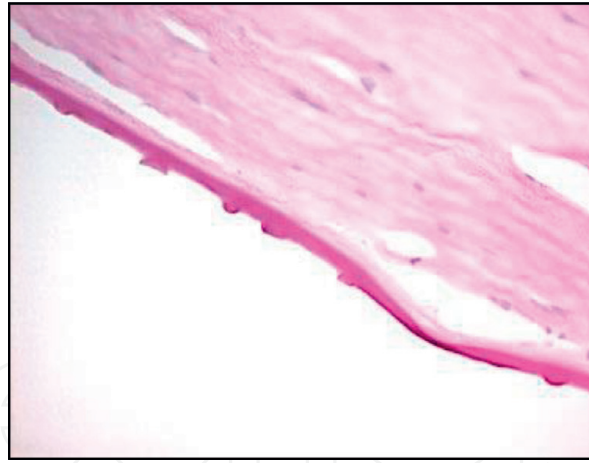
Stage 4: subepithelial fibrosis, scarring, and peripheral superficial vascularization occurring in long-standing cases.

*Histopathology:* thickening and multilaminar Descemet's membrane with hyaline excrescences and atrophic endothelial cells that are reduced in number (**Figure 10**). There is an increasing waviness of the stromal collagen lamellae [3].

*Management:* treatment in early stages can be done by conservative measure. Hypertonic sodium chloride drops or ointment can be helpful [50]. Bandage contact lenses may alleviate pain from ruptured epithelial bullae. In advance cases a Descemet stripping endothelial keratoplasty (DSEK) procedure might be required either combined with cataract extraction or alone. In cases where there is opacification of the stroma, a full penetrating keratoplasty might be necessary [51].

#### 3.4.2 Posterior polymorphous corneal dystrophy (PPCD)

*Inheritance:* autosomal dominant. Isolated nonhereditary unilateral cases have been reported.



**Figure 10.**

*Descemet's membrane appearance in a case of Fuchs' endothelial dystrophy with typical excrescences (original magnification 400× periodic acid-Schiff).*

*Genetic locus and gene:* there are three known loci as follows:

PPCD 1: 20p11.2-q11.2, unknown gene

PPCD 2: 1p34.3-p32.3, collagen, type VIII, alpha-2 (COL8A2)

PPCD 3: 10p11.22, zinc finger E box-binding homeobox 1 (ZEB1)

*Category:* C2 in PPCD 1, C1 in PPCD 2 and PPCD 3.

*Onset:* during the first decade of life.

*Symptoms:* initially asymptomatic. Gradual visual loss occurs secondary to corneal edema. Endothelial changes often are possibly slowly progressive over years. Those changes may eventually lead to corneal decompensation.

*Signs:* asymmetric geographic gray opacities, vesicular lesions that can be single or grouped, usually in the inferior paracentral cornea. Gray-white endothelial bands with white flaky material along the bands. Diffuse opacification of Descemet's membrane and large vesicular endothelial opacities are seen in some cases. Guttata can be rarely seen. Corneal steepening has been reported, especially in PPCD 3, with corneal keratometry power of more than 48.0 diopters. Visually significant corneal edema, peripheral iridocorneal adhesions, and glaucoma are well-documented manifestations of PPCD.

*Histopathology:* focal fusiform or nodular excrescences formed by multiple layers of collagen on the posterior surface of Descemet's membrane. In addition, reduplication of the endothelial cell layer, blebs, or discontinuities is observed [3].

*Management:* treatment in the majority of patients is not indicated unless the patient is symptomatic; then treatment steps are similar to that of Fuchs endothelial corneal dystrophy.

### 3.4.3 Congenital hereditary endothelial dystrophy (CHED)

*Inheritance:* autosomal recessive.

*Genetic locus and gene:* 20p13, solute carrier family 4, sodium borate transporter, member 11—(SLC4A11) gene mutations.

*Category:* C1, C3 in cases without SLC4A11 mutations.

*Onset:* at birth.

*Symptoms:* nonprogressive congenital corneal clouding associated with blurred vision and nystagmus. Usually no tearing or photophobia.

*Signs:* bilateral variable limbus-to-limbus corneal clouding with occasional focal gray spots. Extensive corneal thickening (double or triple the normal corneal thickness). Rarely, secondary band keratopathy and elevated intraocular pressure. Significantly lower than normal endothelial cell count.

**Histopathology:** diffuse epithelial and pan-stromal edema associated with defects in the Bowman's layer. Degenerative and atrophic endothelial cells and a thickened laminated Descemet's membrane (**Figure 11**) [3]. Subepithelial amyloid deposition was found in 6.6% (**Figure 12**) [52].

**Management:** most CHED patients require corneal transplantation for visual rehabilitation. Better outcomes were seen with patients with delayed onset of the disease. Descemet stripping endothelial keratoplasty (DSEK) is an alternative to full-thickness keratoplasty for CHED with promising results [53–55].

#### 3.4.4 X-linked endothelial corneal dystrophy (XECD)

**Inheritance:** X-chromosomal dominant.

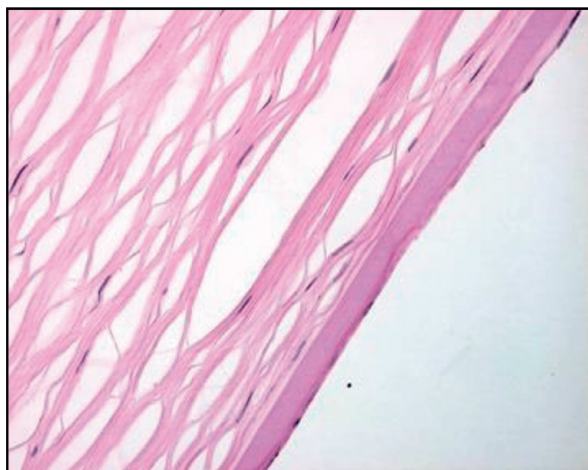**Genetic locus and gene:** Xq25, unknown gene.

**Category:** C2.

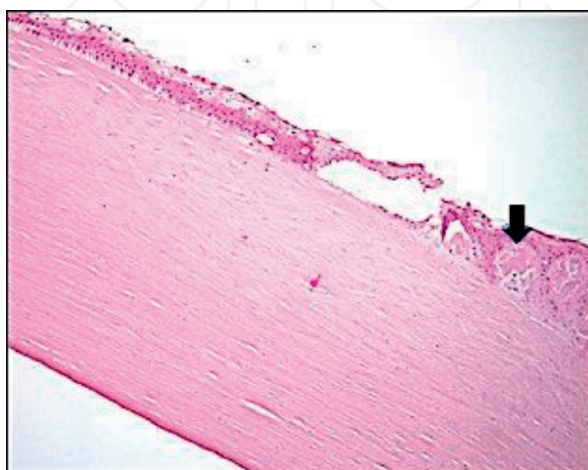
**Onset:** at birth.

**Symptoms:** asymptomatic and nonprogressive in females, minimally progressive decrease in vision in males.

**Signs:** in males, congenital corneal clouding that can range from diffuse haze to ground-glass and milky appearance of the cornea with possible nystagmus. It can present only with moon crater-like endothelial changes with or without secondary band keratopathy. In females, moon crater-like endothelial changes are observed.



**Figure 11.**  
*The appearance of thick Descemet's membrane with attenuated endothelium in CHED (original magnification 400× periodic acid-Schiff).*



**Figure 12.**  
*Subepithelial amyloid deposits (black arrow head) in another case of CHED (original magnification 100× hematoxylin & eosin).*



**Histopathology:** irregularity and thinning of the epithelium and Bowman’s layer. Moon crater-like endothelial changes and subepithelial keratopathy. Irregularly arranged stromal collagen lamellae. Irregular thickening of Descemet’s membrane with atypically appearance or loss of endothelial cells [3].

**Management:** a penetrating keratoplasty may be indicated in males in which corneal opacification significantly impairs vision.

## 4. Corneal degenerations

Corneal degenerations represent physiological decomposition or alteration of tissue elements and/or functions. They usually occur later in life with variable rate of progression and can be asymmetrical.

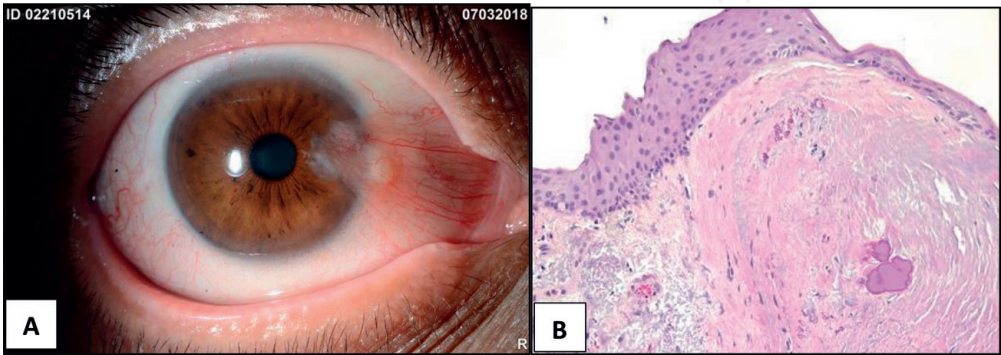
### 4.1 Epithelial and subepithelial degenerations

#### 4.1.1 Pterygium

It is similar to pinguecula histopathologically where the substantia propria shows pseudo-elastotic changes, numerous blood vessels, and curly fibers but invades the cornea resulting in loss of Bowman’s layer and epithelial changes (**Figure 13A and B**). They can cause astigmatism, interfere with contact lens fitting, and may cause ocular motility restriction. Advanced pterygia are treated surgically with the use of antimetabolites or conjunctival graft [56].

#### 4.1.2 Environmental proteinaceous corneal degeneration (EPCD)

Previously known as “spheroidal degeneration” or “climatic droplet keratopathy.” It is characterized by the presence of yellowish aggregates that accumulate near the limbus and then progressively extend toward the central part of the cornea within the palpebral fissure. The globular amorphous material is primarily deposited in the area of Bowman’s layer and can be demonstrated using an elastic stain (**Figure 14**). It can be primary or secondary, affecting males, and is related to cornea microtrauma caused by wind, dust, and ultraviolet radiation [57, 58].



**Figure 13.**  
(A) The clinical appearance of a nasal pterygium and (B) pterygium showing pseudo-elastotic degeneration with an area of limbal stroma and climatic droplet keratopathy (CDK) deposits (original magnification 200× hematoxylin & eosin).



## 4.2 Stromal (central)

Central stromal degenerations include:

1. Mosaic (crocodile) shagreen
2. Cornea farinata
3. Polymorphic amyloid degeneration

## 4.3 Peripheral stromal

Peripheral stromal degenerations include:

1. White limbal girdle of Vogt: types I and II
2. Corneal arcus
3. Senile furrow degeneration
4. Terrien's marginal degeneration

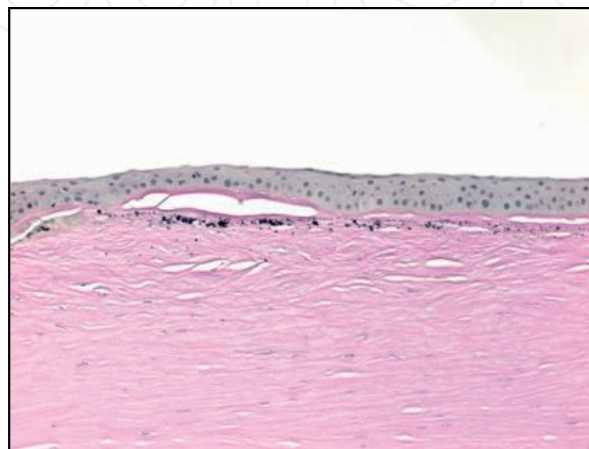
## 4.4 Post-inflammatory corneal degenerations

### 4.4.1 Band-shaped keratopathy

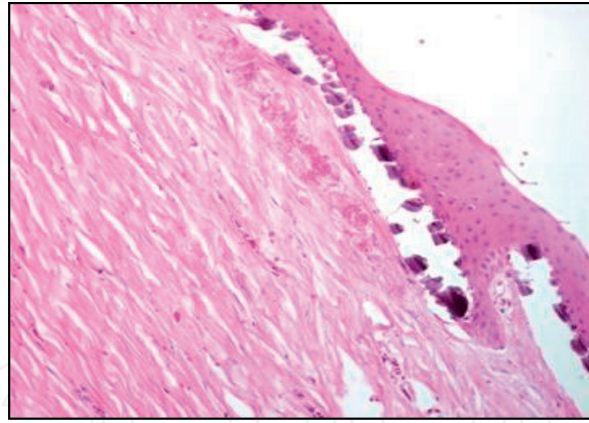
Occurs as dense calcium deposits in the form of whitish calcium hydroxyapatite or yellowish hydroxyl apatite and phosphate within the superficial cornea and Bowman's layer across the interpalpebral fissure (**Figure 15**). Common causes include hypercalcemia of variable etiology, chronic ocular diseases such as uveitis, and gout, and it can be idiopathic. It can be safely treated by calcium chelation using warm neutral disodium ethylenediaminetetraacetic acid (EDTA) [59].

### 4.4.2 Salzmann's nodular degeneration

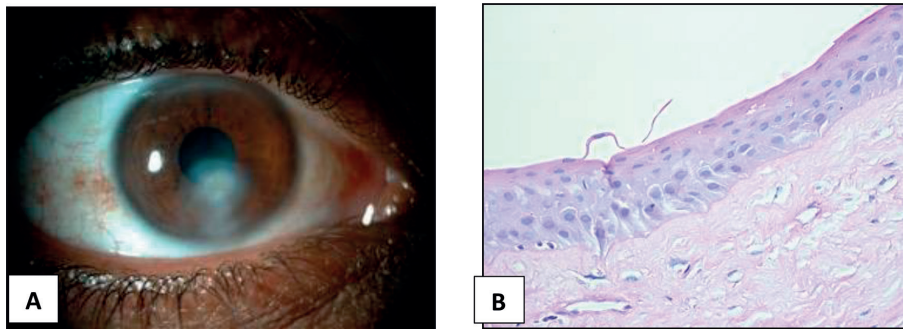
Initially described in 1925 as a nodular post-inflammatory keratopathy resulting in disruption of Bowman's layer, subepithelial fibrosis and vascularization [60].



**Figure 14.**  
*An early case of CDK with the deposits at Bowman's layer level (original magnification 200× elastic stain).*



**Figure 15.**  
The corresponding subepithelial calcium deposits (original magnification 400× hematoxylin & eosin).



**Figure 16.**  
(A) Clinical case of peripheral hypertrophic subepithelial corneal degeneration (PHSD) and (B) epithelial thickening, absence of Bowman's layer and subepithelial fibrosis in a similar case of PHSD (original magnification X400 periodic acid-Schiff).

It appears to affect middle-aged women and to have good prognosis if properly treated medically using lubrication and surgically by superficial keratectomy [61].

The electron microscopy of these nodules shows irregular lamellae, and keratocytes that are covered by an interrupted basement membrane. Bowman's layer is replaced by collagenous material, which shows positive vimentin staining [57].

#### 4.4.3 Peripheral hypertrophic subepithelial corneal degeneration

It is a more recently recognized uncommon corneal degeneration, which is typically peri-limbal, slowly progressive, and bilateral. It tends to occur in white women with unknown etiology and, however, resembles Salzmann's nodular degeneration in appearance (**Figure 16A and B**) [62, 63]. Ultraviolet radiation and limbal insufficiency have been proposed in the pathogenesis [64].

The fibrotic process has been linked to low-grade inflammation with low TGF F-B1 concentrations [62]. Surgical excision might be required for treatment of symptomatic cases, and the recurrence is not common [63].

#### 4.4.4 Others

Amyloid degeneration and lipid keratopathy.

### 4.5 Endothelial

Hassall-Henle bodies.

## 4.6 Corneal pigmentations

Iron lines: there are multiple theories behind the formation of such lines with iron deposits typically within the corneal epithelium at various levels [57]. They include:

1. Hudson-Stahli line: in aging cornea
2. Stocker's line: at the edge of chronic pterygium
3. Fleischer's ring: at the base of the corneal protruding cone in keratoconus
4. Ferry's line: in front of a filtering bleb

## 5. Ectatic corneal disorders

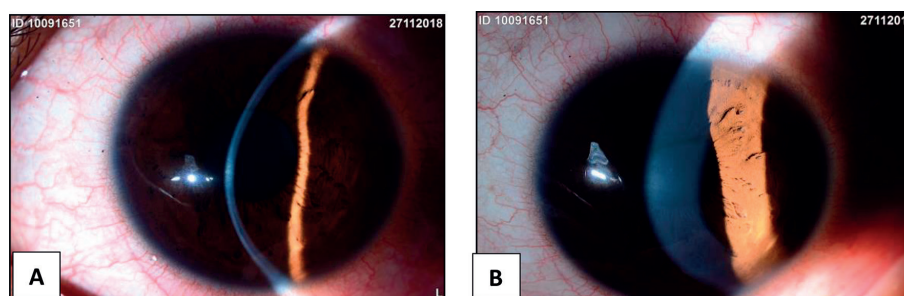
### 5.1 Keratoconus

Dudell in 1729 described a patient with protruding cornea and deteriorating vision; this was the earliest references to keratoconus [65]. Initial classification of the disease was dependent on the clinical pattern of the ectatic cone and included round or nipple cones with a central or oval protrusion and oval cones (**Figure 17A**). Amsler contributed to the disease detection by using a Placido's disk to determine early cases [66]. In the 1980s, the first color-coded Placido map of corneal curvature was published and led to multiple commercially available computerized video-keratoscopes [67, 68]. Then the more detailed elevation-based topographic devices and pachymetric mapping were developed and enabled more through assessment of the condition.

The onset of keratoconus typically begins at puberty but might begin during childhood and undergoes variable progression until the third or fourth decade [69–71]. It is a bilateral condition that is highly asymmetrical that can be associated with atopy, Down's syndrome, Leber's congenital amaurosis, retinitis pigmentosa, Marfan's syndrome, and mitral valve prolapse [65, 72].

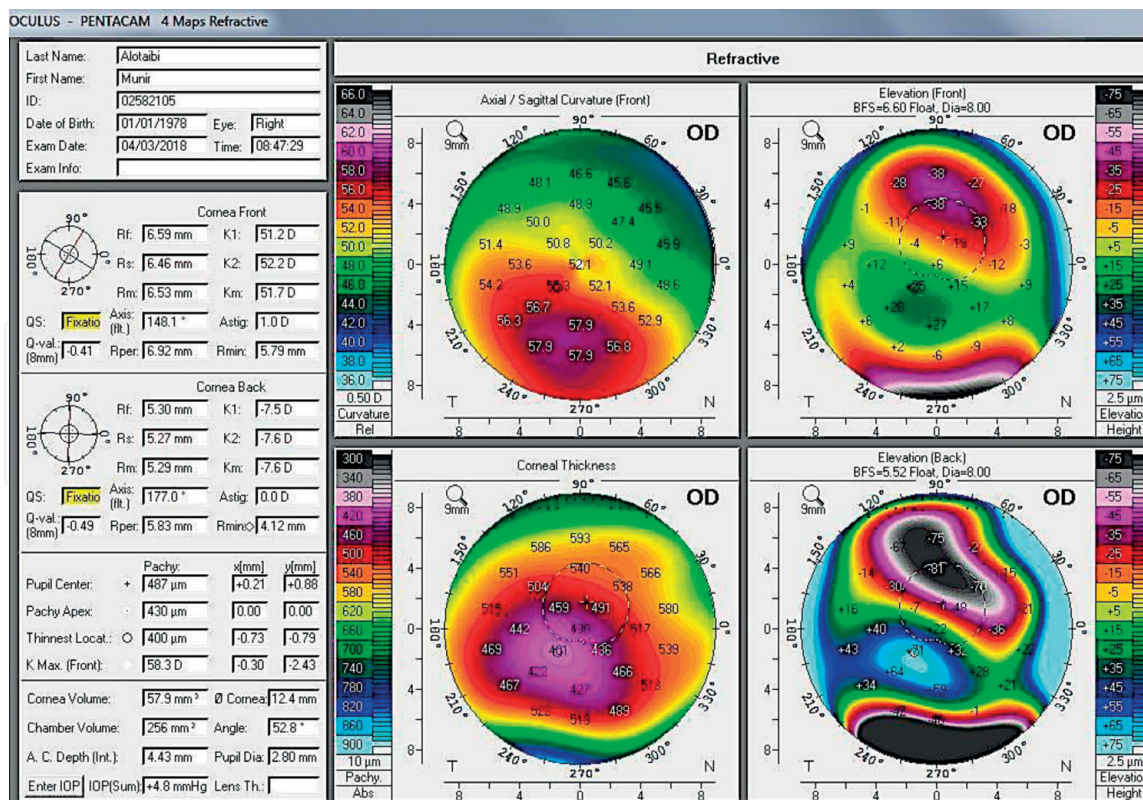
It can present as a sporadic condition; a positive family history has been documented not infrequently. It is suggested that there is an autosomal dominant form of the disorder with variable phenotypic expression in 90% of those with familial keratoconus [65, 73].

The symptoms may vary widely depending on the degree of astigmatism, degree of irregularity, and presence of scarring. Slit lamp findings may include the presence of a Fleischer's ring, which is iron epithelial deposits (described earlier), and can be



**Figure 17.**  
(A) The clinical thinning of the ectatic cornea in keratoconus (KC) and (B) a Fleischer ring indicating iron deposition around the cone in a case of keratoconus.





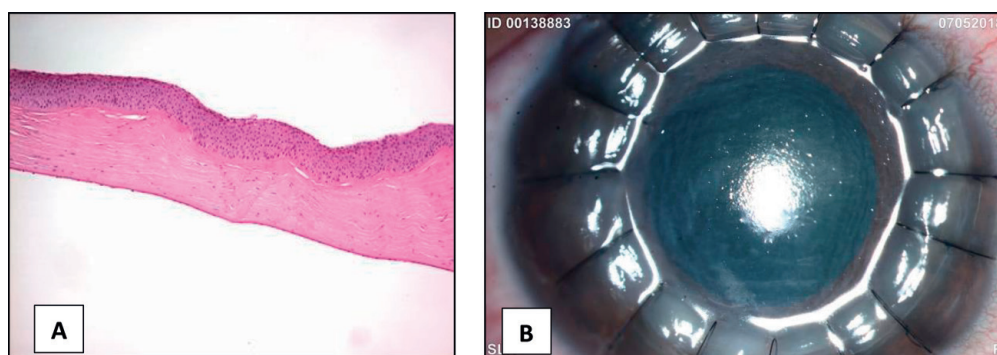
**Figure 18.**  
*Topography showing steep keratometry maps with irregular astigmatism mirroring the area of thinning with high reading on anterior and posterior elevation maps.*

seen better with the use of the cobalt blue filter (**Figure 17B**) [72]. Reticular scarring at the level of bowman's lay can be seen as well as striations in Descemet's membrane and the deep stroma (Vogt's striae). These striations represent corneal stress lines that parallel the axis of the cone [65, 74]. In advanced cases of keratoconus, Munson's sign and Rizzuti's sign can also be seen on gross inspection [75]. Ophthalmoscopy can show the outline of the early cone as an oil droplet against the background red reflex of the fundus. Retinoscopy on a patient with early keratoconus may show scissoring of the retinoscopic reflex. In cases of severe keratoconus, individuals might develop an acute onset of pain, blurred vision, and photophobia. Examination reveals diffuse corneal edema that results from a break in Descemet's membrane.

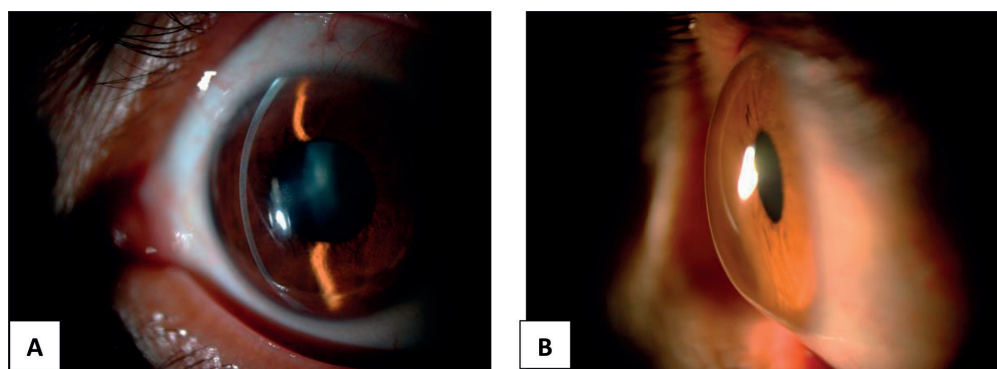
The ability to detect early and subclinical (forme fruste) keratoconus might be difficult depending on clinical examination alone. The use of corneal topographies has improved our ability to distinguish very early cases. Many indices were proposed and artificial intelligence methods such as the KISA% index and the Rabinowitz-McDonnell test have all been developed to help diagnose keratoconus in different stages of the disease and most importantly in early cases. Recent efforts looking at the relational thickness of the central and peripheral cornea have been helpful in the early detection of disease [76]. Modern elevation-based corneal topography provides three-dimensional reconstruction of the cornea enabling evaluation of the anterior and posterior corneal surfaces and assessing the thickness maps (**Figure 18**).

Histopathological studies of corneas with keratoconus demonstrated breaks in Bowman's layer or the complete absence of the layer, stromal collagen disorganization, scarring, and generalized central thinning of the stroma (**Figure 19A**).

Treatment options start with spectacle correction, toric soft contact lens, and hard contact lens wear. In some cases, the use of intrastromal corneal implants might be helpful. Keratoplasty (lamellar or penetrating) is reserved for more advanced cases with an overall good success rate (**Figure 19B**).



**Figure 19.**  
 (A) The evident stromal thinning with compensatory thickening of the epithelium and breaks in Bowman's layer in KC (original magnification 100× periodic acid-Schiff) and (B) the postoperative appearance of lamellar keratoplasty done for a patient with keratoconus.



**Figure 20.**  
 (A) Slit lamp lit appearance of peripheral corneal thinning in a case of pellucid marginal degeneration (PMD) and (B) side view of the inferior corneal bulge in PMD.

## 5.2 Pellucid marginal degeneration

Pellucid marginal degeneration (PMD) is an ectatic corneal disease that is progressive, bilateral noninflammatory, with thinning involving the inferior cornea in a crescentic pattern [65]. Typically, this thinning occurs inferiorly 1–3 mm from the limbus (**Figure 20A and B**). A band of normal cornea is found inferior to the ectatic area. This configuration causes the superior cornea to protrude over the ectasia causing a “beer belly” configuration [77]. PMD affecting the superior cornea is documented in the literature [78–81]. There might be an association with vernal keratoconjunctivitis, atopy, and frequent rubbing of the ocular surface [65].

It can be managed by hard contact lenses or soft toric contact lens. Surgical treatment options are technically difficult and have lower success rates than in keratoconus. Crescentic lamellar keratoplasty, epikeratoplasty, and corneal wedge/resection all have been attempted with variable results.

## 5.3 Keratoglobus

Keratoglobus is a rare, noninflammatory ectatic disorder characterized by bilateral corneal from limbus to limbus. The corneal diameter is typically normal, and the cornea is clear, except in cases of hydrops. It can be associated with two autosomal recessive diseases, Ehlers-Danlos and Blue-Sclera syndrome. Acquired keratoglobus may appear de novo or may be associated with other ocular diseases, such as vernal keratoconjunctivitis, blepharitis, Leber's congenital amaurosis, and thyroid ophthalmopathy [82].



Penetrating keratoplasty, while the classical surgical treatment for other corneal diseases, is not appropriate in keratoglobus patients. Other procedures, such as inlay lamellar keratoplasty and limbus-to-limbus epikeratoplasty, have been attempted with variable results [83–85]. Preferably a spectacle correction as this also provides protection from rupture. Contact lenses can also be used.

### **Conflict of interest**

We do not have any financial interests in any of the listed items in this manuscript.

### **Author details**

Hind Alkatan\*, Norah Alkheraiji and Tariq Alzahem  
King Saud University, Riyadh, Kingdom of Saudi Arabia

\*Address all correspondence to: hindkatan@yahoo.com

### **IntechOpen**

© 2019 The Author(s). Licensee IntechOpen. This chapter is distributed under the terms of the Creative Commons Attribution License (<http://creativecommons.org/licenses/by/3.0>), which permits unrestricted use, distribution, and reproduction in any medium, provided the original work is properly cited. 

## References

- [1] Kanski JJ, Bowling B, Nischal KK, Pearson A. *Cornea. Clinical Ophthalmology: A Systematic Approach*. 8th ed. Edinburgh, New York: Elsevier/Saunders; 2016. pp. 168-237
- [2] AAO O. *Basic and Clinical Science Course Section 8: External Disease and Cornea*. San Francisco, CA: American Academy of Ophthalmology; 2015. pp. 253-287
- [3] Weiss JS, Moller HU, Aldave AJ, Seitz B, Bredrup C, Kivela T, et al. IC3D classification of corneal dystrophies—Edition 2. *Cornea*. 2015;**34**(2):117-159
- [4] Friedlaender MH, Smolin G. Corneal degenerations. *Annals of Ophthalmology*. 1979;**11**(10):1485-1495
- [5] Sacca SC, Roszkowska AM, Izzotti A. Environmental light and endogenous antioxidants as the main determinants of non-cancer ocular diseases. *Mutation Research*. 2013;**752**(2):153-171
- [6] Harayama K, Amemiya T, Nishimura H. Development of the cornea during fetal life: Comparison of corneal and bulbar diameter. *The Anatomical Record*. 1980;**198**(3):531-535
- [7] Graw J. Eye development. *Current Topics in Developmental Biology*. 2010;**90**:343-386
- [8] Robert A Copeland J, Afshari NA, Dohlman CH. *Corneal Embryology, Copeland and Afshari's Principles and Practice of Cornea*. Vol. 1. New Delhi; London: Jaypee Brothers Medical Publishers; 2013. pp. 16-25
- [9] Ehlers N, Hjortdal J. *The biology of the eye*. 1st ed. Bittar EE, editor. Amsterdam: Elsevier; 2006. 87 p.
- [10] Hay ED. Development of the vertebrate cornea. *International Review of Cytology*. 1980;**63**:263-322
- [11] Bannister LH, Berry MM, Collins P, et al. *Gray's Anatomy*. 38th ed. Edinburgh: Churchill Livingstone; 1999. 259 p
- [12] Moore KL, Persaud TVN, Shiota K. *Color Atlas of Clinical Embryology*. Philadelphia: WB Saunders; 1994
- [13] Harayama K, Amemiya T, Nishimura H. Development of the eyeball during fetal life. *Journal of Pediatric Ophthalmology and Strabismus*. 1981;**18**(4):37-40
- [14] Trevor-Roper PD. The eye and its disorders. 1. The eyeball. *International Ophthalmology Clinics*. 1974;**14**(1-2):3-25
- [15] Styszyński A, Bruska M, Woźniak W. Morphometric study of the cornea in human embryos. Morphometric study of the cornea in human embryos. *Folia Morphologica*. 2001;**60**(1):57-59
- [16] Wulle KG, Richter J. Electron microscopy of the early embryonic development of the human corneal epithelium. *Albrecht von Graefes Archiv fur klinische und experimentelle Ophthalmologie—Albrecht von Graefe's Archive for Clinical and Experimental Ophthalmology*. 1978;**209**(1):39-49
- [17] Sowden JC. Molecular and developmental mechanisms of anterior segment dysgenesis. *Eye (London, England)*. 2007;**21**(10):1310-1318
- [18] Copeland Jr RA, Afshari NA, Dohlman CH. *Basic Structure and Function of the Human Cornea and Adnexal Structures, Corneal Embryology, Copeland and Afshari's Principles and Practice of Cornea*. Vol. 1. New Delhi; London: Jaypee Brothers Medical Publishers; 2013. pp. 3-18
- [19] AAO O. *Basic and Clinical Science Course. Section 2: Fundamentals and Principles of Ophthalmology*. San

- Francisco, CA: American Academy of Ophthalmology; 2014. pp. 44-45
- [20] Ophthalmology AAo. Basic and Clinical Science Course Section 8: External Disease and Cornea. San Francisco, CA: American Academy of Ophthalmology; 2014. p. 74
- [21] Ophthalmology AAo. Basic and Clinical Science Course. Section 8: External Disease and Cornea. San Francisco, CA: American Academy of Ophthalmology; 2014. p. 9
- [22] Dua HS, Faraj LA, Said DG, Gray T, Lowe J. Human corneal anatomy redefined: A novel pre-Descemet's layer (Dua's layer). *Ophthalmology*. 2013;**120**:1778-1785
- [23] The IC3D Classification of the Corneal Dystrophies. *Cornea*. 2008;**27**:S1-S42
- [24] Cogan DG, Donaldson DD, Kuwabara T, et al. Microcystic dystrophy of the corneal epithelium. *Transactions of the American Ophthalmological Society*. 1964;**62**:213-225
- [25] Laibson PR, Krachmer JH. Familial occurrence of dot, map, fingerprint dystrophy of the cornea. *Investigative Ophthalmology & Visual Science*. 1975;**14**:397-399
- [26] Werblin TP, Hirst LW, Stark WJ, et al. Prevalence of map-dot-fingerprint changes in the cornea. *The British Journal of Ophthalmology*. 1981;**65**:401-409
- [27] Boutboul S, Black GCM, Moore JE, et al. A subset of patients with epithelial basement membrane corneal dystrophy have mutations in TGFBI/BIGH3. *Human Mutation*. 2006;**27**:553-557
- [28] Meesmann A, Wilke F. Klinische und anatomische Untersuchungen über eine bisher unbekannte, dominant vererbte Epithel Dystrophie der Horn haut. *Klinische Monatsblätter für Augenheilkunde*, Stuttgart. 1939;**103**:361-391
- [29] Burns RP. Meesmann's corneal dystrophy. *Transactions of the American Ophthalmological Society*. 1968;**66**:530-635
- [30] Chiou AG, Florakis GJ, Copeland RL, et al. Recurrent Meesmann's corneal epithelial dystrophy after penetrating keratoplasty. *Cornea*. 1998;**17**:566-570
- [31] Lisch W, Steuhl KP, Lisch C, et al. A new, band-shaped and whorled microcystic dystrophy of the corneal epithelium. *American Journal of Ophthalmology*. 1992;**114**:35-44
- [32] Wessel MM, Sarkar J, Jakobiec FA, et al. Treatment of Lisch corneal dystrophy with photorefractive keratectomy and Mitomycin C. *Cornea*. 2011;**30**:481-485
- [33] Nakaizumi GA. A rare case of corneal dystrophy. *Acta Societatis Ophthalmologicae Japonicae*. 1914;**18**:949-950
- [34] Zhang B, Yao YF. Gelatinous drop-like corneal dystrophy with a novel mutation of TACSTD2 manifested in combination with spheroidal degeneration in a Chinese patient. *Molecular Vision*. 2010;**16**:1570-1575
- [35] Reis W. Familiäre, fleckige Hornhautentartung. *Deutsche Medizinische Wochenschrift*. 1917;**43**:575
- [36] Thiel HJ, Behnke H. Eine bisher unbekannte subepitheliale hereditäre Hornhautdystrophie. *Klinische Monatsblätter für Augenheilkunde*. 1967;**150**:862-874
- [37] Gear HC, Ramaesh K, Roberts F. Recurrence of Thiel-Behnke corneal dystrophy: An electron microscopic

study. *The British Journal of Ophthalmology*. 2005;**89**:518-520

[38] Wittebol-Post D, Van Schooneveld MJ. The corneal dystrophy of Waardenburg and Jonkers. *Ophthalmic Paediatrics and Genetics*. 1989;**10**:249-255

[39] Ridgway AE, Akhtar S, Munier FL, et al. Ultrastructural and molecular analysis of Bowman's layer corneal dystrophies: An epithelial origin? *Investigative Ophthalmology & Visual Science*. 2000;**41**:3286-3292

[40] Seitz B, Behrens A, Fischer M, et al. Morphometric analysis of deposits in granular and lattice corneal dystrophy: Histopathologic implications for phototherapeutic keratectomy. *Cornea*. 2004;**23**(4):380-385

[41] Alzuhairy S, Alkatan HM, Al-Rajhi AA. Prevalence and histopathological characteristics of corneal stromal dystrophies in Saudi Arabia. *Middle East African Journal of Ophthalmology*. 2015;**22**(2):179-185

[42] Yao YF, Jin YQ, Zhang B, et al. Recurrence of lattice corneal dystrophy caused by incomplete removal of stroma after deep lamellar keratoplasty. *Cornea*. 2006;**25**(10 Suppl. 1):S41-S46

[43] Meyer HJ. Prognosis of keratoplasty in hereditary stromal dystrophies. *Klinische Monatsblätter für Augenheilkunde*. 1996;**208**(6):446-449

[44] Lyons CJ, McCartney AC, Kirkness CM. Granular corneal dystrophy. Visual results and pattern of recurrence after lamellar or penetrating keratoplasty. *Ophthalmology*. 1994;**101**(11):1812-1817

[45] Di Iorio E, Barbaro V, Volpi N, et al. Localization and expression of CHST6 and keratan sulfate proteoglycans in the human cornea. *Experimental Eye Research*. 2010;**91**(2):293-299

[46] Waring GO 3rd, Rodrigues MM, Laibson PR. Corneal dystrophies: Dystrophies of the epithelium, Bowman's layer and stroma. *Survey of Ophthalmology*. 1978;**23**(2):71-122

[47] Akhtar S, Alkatan HM, Kirat O, Khan AA, Almubrad T. Collagen fibrils and proteoglycans of macular dystrophy cornea: Ultrastructure and 3D transmission electron tomography. *Microscopy and Microanalysis: The Official Journal of Microscopy Society of America, Microbeam Analysis Society, Microscopical Society of Canada*. 2015;**21**(3):666-679

[48] Szentmary N, Seitz B, Langenbucher A, et al. Histologic and ultrastructural changes in corneas with granular and macular dystrophy after excimer laser phototherapeutic keratectomy. *Cornea*. 2006;**25**(3):257-263

[49] Fuchs E. Dystrophie epithelialis corneae. *Graefes Archive for Clinical and Experimental Ophthalmology*. 1910;**76**:48-508

[50] Adamis AP, Filatov V, Tripathi BJ, et al. Fuchs' endothelial dystrophy of the cornea. *Survey of Ophthalmology*. 1993;**38**:149-168

[51] Price MO, Price DA, Fairchild KM, et al. Rate and risk factors for cataract formation and extraction after Descemet stripping endothelial keratoplasty. *The British Journal of Ophthalmology*. 2010;**94**:1468-1471

[52] Al-Shehah A, Al-Rajhi A, Alkatan H. Amyloid corneal deposition in corneal buttons of congenital hereditary endothelial dystrophy (CHED)—A clinical and histopathological case series. *Saudi Journal of Ophthalmology: Official Journal of the Saudi Ophthalmological Society*. 2010;**24**(4):111-118

[53] Sajjadi H, Javadi MA, Hemmati R, et al. Results of penetrating keratoplasty



in CHED. Congenital hereditary endothelial dystrophy. *Cornea*. 1995;**14**:18-25

[54] Busin M, Beltz J, Scorgia V. Descemet-stripping automated endothelial keratoplasty for congenital hereditary endothelial dystrophy. *Archives of Ophthalmology*. 2011;**129**:1140-1146

[55] Schmid E, Lisch W, Philipp W, et al. A new, X-linked endothelial corneal dystrophy. *American Journal of Ophthalmology*. 2006;**141**:478-487

[56] Kim KW, Kim JC. Current approaches and future directions in the management of pterygium. *International Journal of Ophthalmology*. 2018;**II**(5):709-711

[57] Tabarra KF, Alkatan HM. Climatic droplet keratopathy. In: Copeland and Afshari's Principles and Practice of Cornea, Chapter 46. India: Jaypee-Highlights Medical Publishers; 2013. pp. 559-566

[58] Serra HM, Suarez MF, Urrets-Zavalía JA. Environmental protenaceous corneal degeneration: A rare disease. In: Chapter 1 in Rare Disease. Available from: [www.avidscience.com](http://www.avidscience.com)

[59] Al-Hilty A, Ramaesh K, Lockington D. EDTA chelation for symptomatic band Keratopathy: Results and recurrence. *Eye (London, England)*. 2018;**32**(1):26-31. DOI: 10.1038/eye.2017.264

[60] Lanier JD. Salzmann's nodular degeneration (subepithelial fibrosis). *Ophthalmic Surgery, Laser and Imaging*. 2011;**42**(4):350-352

[61] Farjo AA, Halperin GI, Syed N, Sutphin JE, Wagoner MD. Salzmann's nodular corneal degeneration clinical characteristics and surgical outcomes. *Cornea*. 2006;**25**(1):11-15

[62] Jarventausta PJ, Tervo TMT, Kivela T, Holopainen JM. Peripheral

hypertrophic subepithelial corneal degenerate clinical and histopathological features. *Acta Ophthalmologica*. 2014;**92**:774-782

[63] Gore DM, Iovieno A, Connel BJ, Alexander A, Meligoni G, Dart JK. Peripheral hypertrophic subepithelial corneal degeneration: Nomenclature, phenotypes, and long-term outcomes. *Ophthalmology*. 2013;**120**:892-898

[64] Schargus M, Kusserow C, Schlotzer-Schrehan U, Hofmann Rummelt C, Schlunk G, Geerlong G. Peripheral hypertrophic subepithelial corneal degeneration presenting with bilateral nasal and temporal corneal changes. *Eye*. 2015;**29**:88-97

[65] Krachmer JH, Feder RS, Belin MW. Keratoconus and related noninflammatory corneal thinning disorders. *Survey of Ophthalmology*. 1984;**28**:293-322

[66] Amsler M. Keraton classique et keratocone fruste, augments unitaires. *Ophthalmologica*. 1946;**11**:96-101

[67] Rabinowitz YS, McDonnell PJ. Computer-assisted corneal topography in keratoconus. *Refractive & Corneal Surgery*. 1989;**5**:400-408

[68] Maeda N, Klyce SD, Smolek MK, et al. Automated keratoconus screening with corneal topography analysis. *Investigative Ophthalmology & Visual Science*. 1994;**35**:2749-2757

[69] Wagner H, Barr JT, Zadnik K. Collaborative longitudinal evaluation of Keratoconus (CLEK) study: Methods and findings to date. *Contact Lens & Anterior Eye*. 2007;**30**:223-232

[70] Owens H, Gamble G. A profile of keratoconus in New Zealand. *Cornea*. 2003;**22**:122-125

[71] Crews MJ, Driebe WT, Stern GA. The clinical management of keratoconus: A

6 year retrospective study. The CLAO Journal. 1994;**20**:194-197

degeneration with superior thinning. Cornea. 1997;**16**:483-485

[72] Wilson SE, Klyce SD. Advances in the analysis of corneal topography. Survey of Ophthalmology. 1991;**35**:269-277

[82] Gonzalez V, McDonnell PJ. Computer-assisted corneal topography in parents of patients with keratoconus. Archives of Ophthalmology. 1992;**110**:1413-1414

[73] Falls HF, Allen AW. Dominantly inherited keratoconus. Journal de Génétique Humaine. 1969;**17**:317-324

[83] Jones D, Kirkness C. A new surgical technique for keratoglobus—tectonic lamellar keratoplasty followed by secondary penetrating keratoplasty (case reports). Cornea. 2001;**20**:885-887

[74] Zadnik K, Barr JT, Gordon MO, et al. Biomicroscopic signs and disease severity in keratoconus. Collaborative longitudinal evaluation of Keratoconus (CLEK) study group. Cornea. 1996;**15**:139-146

[84] Kanellopoulos J, Lawrence H. An alternative surgical procedure for the management of keratoglobus. Cornea. 2005;**24**:1024-1026

[75] Ihalainen A. Clinical and epidemiological features of keratoconus genetic and external factors in the pathogenesis of the disease. Acta Ophthalmologica. Supplement. 1986;**178**:1-64

[85] Vajpayee R, Bhartiya P, Sharma N. Central lamellar keratoplasty with peripheral intralamellar tuck: A new surgical technique for keratoglobus. Cornea. 2002;**21**:657-660

[76] Ambrosio R, Alonso RS, Luz A, et al. Corneal-thickness spatial profile and corneal-volume distribution: Tomographic indices to detect keratoconus. Journal of Cataract and Refractive Surgery. 2006;**32**:1851-1859

[77] Tzelikis PF, Cohen EJ, Rapuano CJ, et al. Management of pellucid marginal corneal degeneration. Cornea. 2005;**24**:555-560

[78] Wagenhorst BB. Unilateral pellucid marginal degeneration in an elderly patient. The British Journal of Ophthalmology. 1996;**80**:927-928

[79] Ertan A, Bahadır M. Management of superior pellucid marginal degeneration with a single intracorneal ring segment using femtosecond laser. Journal of Refractive Surgery. 2007;**23**:205-208

[80] Sridhar MS, Mahesh S, Bansal AK, et al. Superior pellucid marginal corneal degeneration. Eye. 2004;**18**:393-399

[81] Bower KS, Dhaliwal DK, Barnhorst DA, et al. Pellucid marginal