

We are IntechOpen, the world's leading publisher of Open Access books Built by scientists, for scientists

6,900

Open access books available

186,000

International authors and editors

200M

Downloads

Our authors are among the

154

Countries delivered to

TOP 1%

most cited scientists

12.2%

Contributors from top 500 universities



WEB OF SCIENCE™

Selection of our books indexed in the Book Citation Index
in Web of Science™ Core Collection (BKCI)

Interested in publishing with us?
Contact book.department@intechopen.com

Numbers displayed above are based on latest data collected.
For more information visit www.intechopen.com



Gamma-Delta T-cell Lymphoma: An Overview

*Preethi Ramachandran, Alok Aggarwal
and Jen Chin Wang*

Abstract

Gamma-delta T-cell lymphomas are very rare and aggressive T-cell neoplasms with complex heterogeneity and diagnostic complexity. Gamma-delta T lymphocytes originate from CD4[−] CD8[−] (double negative) thymocytes in the bone marrow and are distinct from alpha beta subtype. Four entities of gamma-delta lymphomas recognized by 2016 WHO classification of lymphoid neoplasms include: hepatosplenic T $\gamma\delta$ lymphoma (HS $\gamma\delta$ TL), primary cutaneous gamma-delta TCL (PCTCL), monomorphic epitheliotropic intestinal T-cell lymphoma (MEITL) and large granular lymphocytic leukemias (T-LGL). Extensive literature search based on small case series and case reports identifies few more subtypes of gamma-delta T-lymphomas which were not previously classified by World Health Organization. There remains a critical gap in our understanding of the subtypes of gamma-delta T-cell lymphomas and a lack of updated summarization. In this review, we summarize in detail on the classification, biology, heterogeneity, diagnosis, clinical behavior and treatment options of these rare but clinically important entities.

Keywords: gamma-delta T-cell, T cell lymphoma, non-Hodgkin lymphoma, T-cell receptor, hepatosplenic T cell lymphoma

1. Introduction

T/NK (natural killer) cell lymphomas are uncommon lymphomas accounting for about 6% of all non-Hodgkin lymphoma (NHL). B-cell lymphomas account for the majority being 80% and Hodgkin lymphoma accounts for 7% of NHLs in the United States according to the Surveillance, Epidemiology, and End Results program (SEER) over a 10-year period from 1997 till 2006 [1]. According to the updated 2016 revision of World Health Organization Classification (WHO) of T-cell lymphoid neoplasms, there are about 27 types of mature T and NK cell neoplasms. Amongst all types, gamma-delta T-cell lymphoma ($\gamma\delta$ -TCL) accounts for only <1% of lymphoid tumors [2].

T lymphocytes recognize antigens through T-cell receptors (TCRs). TCRs are polypeptide heterodimers which mostly constitutes α and β chains and rarely γ and δ chains. Alpha-beta T cells (T $\alpha\beta$) constitute 95% of all T cells while gamma-delta T cells (T $\gamma\delta$) make up only a small proportion accounting to <5% of all circulating lymphocytes. Majority of lymphoid tissues are made of $\alpha\beta$ T cells than $\gamma\delta$ subtype. Gamma-delta ($\gamma\delta$) subtype shows selective tropism for the red pulp of the spleen, mucosal tissues, gastrointestinal epithelial tissues, skin and rarely lymphoid tissue. Hence the

$\gamma\delta$ T cells have a higher representation of about 30% in some epithelial-rich tissues, such as intestine and sinusoidal red pulp of the spleen [3]. Most of the T-cell lymphomas have alpha-beta TCRs while only 5% of the T-NHLs have gamma-delta TCRs [4].

2. T-cell receptor

T-cell receptors are complex membrane proteins which are found on the surface of T lymphocytes through which the T cells recognize the antigens. The antigens are recognized as peptides linked to major histocompatibility complex (MHC) molecules [5]. T lymphocytes recognize antigens through T cell receptors (TCRs). TCRs are polypeptide heterodimers composed of two different protein chains. These two chains mostly consist of alpha (α) chain and a beta (β) chain in 95% of the cases whereas in 5%, these chains are composed of gamma and delta (γ/δ) chains. Alpha and beta chains are encoded by T-cell receptor alpha (TRA) at 14q11.2 and T-cell receptor beta (TRB) gene at 7q34. The gamma and delta chains are encoded by T cell receptor gamma locus (TRG) (7p14) and T cell receptor delta locus (TRD) (14q11.2) genes respectively [6]. $TR\alpha\beta$ recognizes processed antigens presented by MHC proteins whereas $TR\gamma\delta$ recognizes non-peptide antigens.

After the T cell lineage commitment is made, the progenitors make their first lineage decision to be either $\alpha\beta$ or $\gamma\delta$. $CD4^- CD8^-$ (double negative) thymocytes rearrange three out of four TCR loci: *Tcrb*, *Tcrg*, and *Tcrd*. The cells which are arrested

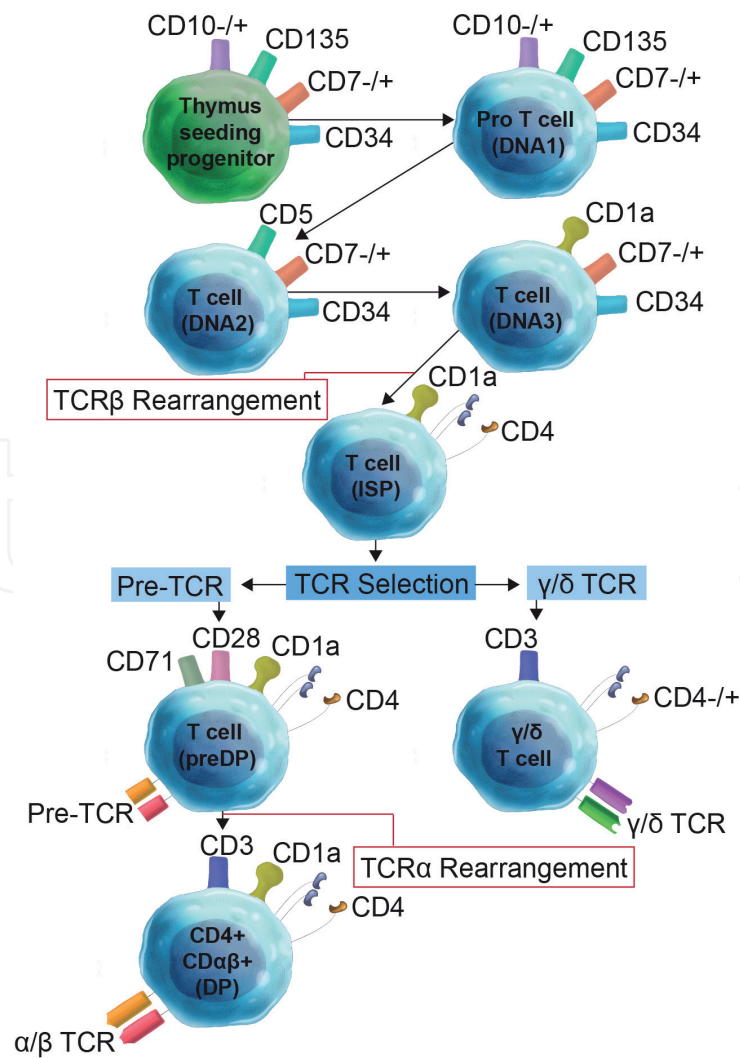


Figure 1.
Illustration of T cell development.

in proliferation at this stage require expression of TCR to re-enter the cell cycle. If there is a success in an in-frame Tcrb rearrangement, TCR β is expressed which forms a complex with the germline-encoded pre-TCR α (pT α) chain [3]. Increased upregulation of CD4 and CD8 receptors along with increased proliferation occurs when this complex is expressed. Tcrq is silenced and Tcra rearrangement starts thus resulting in excision of Tcrd locus. CD4+ CD8+ [double positive (DP)] thymocytes express TCR $\alpha\beta$ and further differentiate into CD4+ or CD8+ lineages when there is a rearrangement of T cell receptor alpha chain (Tcra). Progression through the DP stage is believed to be a hallmark of $\alpha\beta$ lineage commitment. Thymocyte progenitors which have a rearrangement of Tcrg and Tcrd will express $\gamma\delta$ TCR at the cell surface. These cells also undergo increased proliferation but tend to avoid going through the DP stage thus arriving at the periphery as CD4– CD8– (or, more rarely, with CD4– CD8+ or CD4+ CD8–) cells. Hence the lineage toward $\alpha\beta$ or $\gamma\delta$ is based on the progression towards the DP stage [7]. See **Figure 1** for illustration of T-cell development.

3. Gamma-delta T cells

Gamma-delta T lymphocytes originate from CD4– CD8– (double negative) thymocytes in the bone marrow and do not need recognition by the major histocompatibility complex [8]. The antigenic stimulus that activates these subtype of cells is unknown. These lymphocytes have properties of cytotoxicity, phagocytosis [9, 10] and also play a major role in both innate immunity and non-specific immune responses [11–13].

There are two variable receptor regions within the T cell receptor in gamma delta T cells which divide them into two subtypes—Vdelta1 and Vdelta2 gamma delta T-cells [14, 15]. These two subtypes further differ in their phenotypes and the regions of distribution

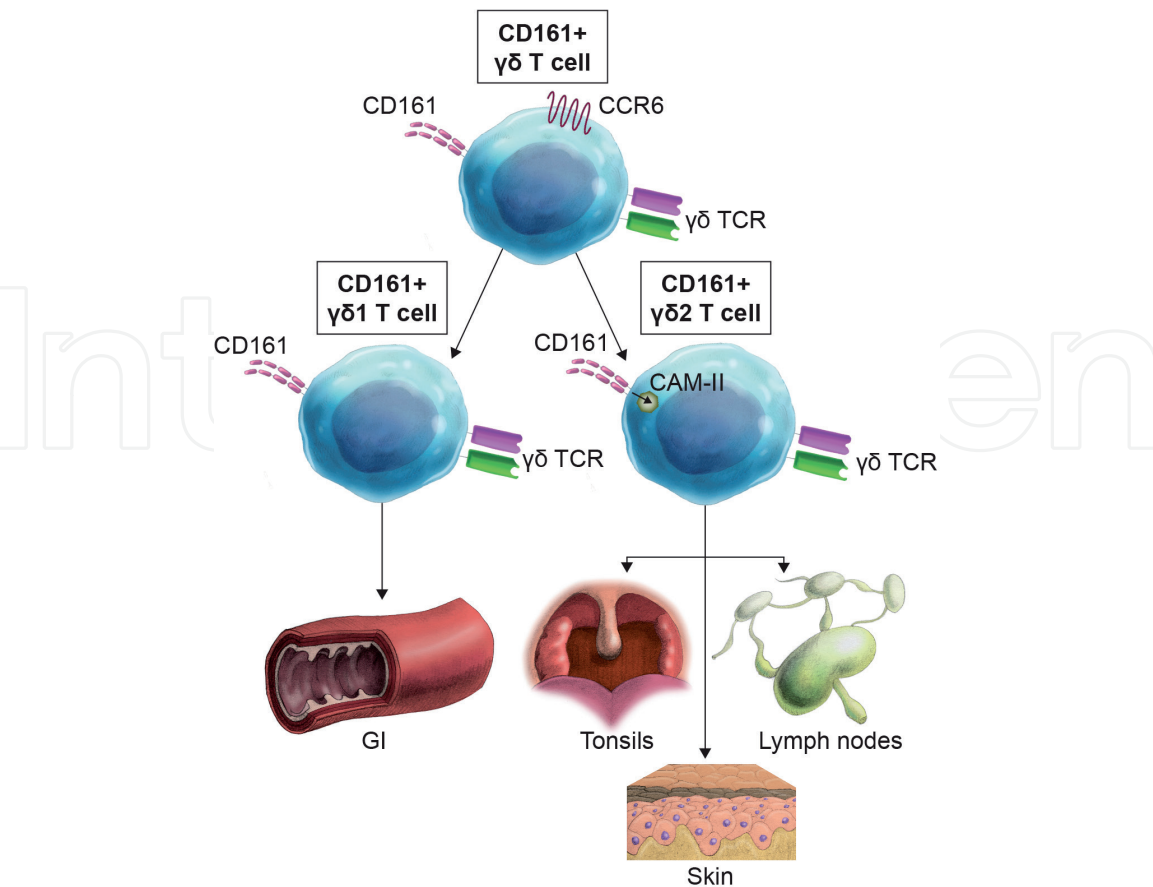


Figure 2.
Illustration $\gamma\delta$ of T cell function and the roles of specific subsets. Vdelta1 T cells are more predominant in gastrointestinal tract and Vdelta2 cells in skin, lymphoid tissue and tonsils.

within the body. While Vdelta1 T cells are more predominant in gastrointestinal tract, Vdelta2 T cells are seen mostly in skin, lymphoid tissue and tonsils. See **Figure 2** for illustration of summary of $\gamma\delta$ T-cell functions and the roles of specific subsets.

4. WHO 2016 revised classification

Gamma-delta T-cell lymphomas constitute a very rare and aggressive subtype of lymphomas with a very poor prognosis [16]. The gamma delta T-cell lymphomas were classified into two groups in 2008 by the World Health Organization (WHO) as hepatosplenic $T\gamma\delta$ cell lymphoma (HS $\gamma\delta$ TL) and primary cutaneous TCL (PCTCL) [17]. In 2016, the WHO classification of T $\gamma\delta$ cell lymphoma added few more subgroups.

As per 2016 revision of the WHO classification of lymphoid neoplasms, the four recognized entities of $T\gamma\delta$ cell lymphoma identified includes,

1. Hepatosplenic $T\gamma\delta$ cell lymphoma (HS $\gamma\delta$ TL)
2. Primary cutaneous gamma delta TCL (PCTCL)
 - a. Aggressive variant
 - b. Mycosis fungoides like (Indolent variant)
3. Monomorphic epitheliotropic intestinal TCL (MEITL)
4. Gamma-delta large granular lymphocytic leukemias (T-LGL)

Although the WHO classification is helpful in defining the subtypes of lymphomas, there are other rare variants of gamma-delta T-cell lymphomas in literature in the form of case reports which still remains unclassifiable. Based on an extensive literature search, we classify gamma delta T-cell lymphomas into the five subtypes as illustrated in **Table 1**.

1. Hepatosplenic $T\gamma\delta$ cell lymphoma (HS $\gamma\delta$ TL)
2. Primary cutaneous gamma-delta T-cell lymphoma (PCTCL)
 - a. Aggressive variant
 - b. Mycosis fungoides like (indolent variant)
 - c. Subcutaneous panniculitis-like
3. Mucosal gamma-delta T-cell lymphoma
 - a. Gastrointestinal
 - b. Nasal
 - c. Pulmonary
 - d. Laryngeal
4. Gamma-delta T-LGL
5. Nodal gamma-delta T-cell lymphoma

Types	Age	Incidence	Gender	Median survival	Subtypes	EBV association	Clinical features	Treatment
Hepatosplenic Gamma delta T-cell lymphoma	Young adults (35 yrs)	<1%	Male	<2 yrs	None	Yes	Cytopenia, Infiltration of liver, spleen and BM. LN rare	CHOP like regimen Allogenic stem cell transplant Relapsed cases - Bendamustine, bortezomib, lenlidomide, vorinostat.
Primary cutaneous gamma delta T-cell lymphoma	Adults	<1%	None	15 months	Aggressive Mycosis fungoides-like Subcutaneous panniculitis-like	No	Papule, plaque or nodule with ulceration and overlying epidermal necrosis	CHOP-like regimen Steoid, MTX, UV radiation, Bexarotene
Mucosal Gamma delta T-cell lymphoma	>48 yrs	NK	None	1-1.5 yrs	Gastrointestina Nasal Pulmonary Laryngeal	Yes	HSM, Nasal destruction GI perforation LN and BM involvement rare	CHOP like regimen Allogenic stem cell transplantation
Gamma delta T-LGL	45-75 yrs	2-3%	None	Indolent	None	Yes, in few cases	Cytopenia, splenomegaly, BM involved	Steroids, MTX, cyclosporine, cyclophosphamide, fludarabine, pentostatin
Nodal gamma delta T-Cell lymphoma	NK	<2%	NK	<1 yr	None	yes	LN, BM infiltration, HSM	CHOP-like regimen Allogenic stem cell transplant

Table 1.
Classification of gamma-delta T-cell lymphomas.

5. Gene expression profiling of gamma delta lymphoma

Research studies have shown that the different molecular profiling exists between $\gamma\delta$ TCL and $\alpha\beta$ TCL as well as the existence of a distinct molecular signature in hepatosplenic gamma delta T cell lymphoma.

Kana Miyazaki et al. analyzed RNA from seven patients with gamma delta T cell lymphoma (four hepatosplenic, one cutaneous, one intestinal and one thyroidal) and 27 patients with alpha beta T cell lymphoma (11 peripheral TCL unspecified, 15 angioimmunoblastic TCL and one hepatosplenic) using oligonucleotide microarrays. Based on the genetic analysis, they classified hepatosplenic $\gamma\delta$ TCL as a single cluster, whereas other $\gamma\delta$ TCL were more heterogeneous and were scattered within the $\alpha\beta$ distribution. Gene expression profiles were compared between $\gamma\delta$ TCL and $\alpha\beta$ TCLs, using 291 genes. Webgestalt analysis using Gene Ontology (GO) hierarchies for categorizing functional gene groups and Kyoto Encyclopedia of gene and genomes (KEGG) pathway was used for identifying signaling pathways. They concluded that five in $\gamma\delta$ TCL and 20 in $\alpha\beta$ TCL gene groups were expressed under the GO category and three $\gamma\delta$ TCL pathways and one $\alpha\beta$ TCL pathway were found to be altered in KEGG-signaling analyses. These studies concluded that no signature genes were shared between $\gamma\delta$ TCL and $\alpha\beta$ TCL thereby confirming different functional profiling between them. Genes encoding KIRs and killer cell lectin-like receptors were seen in four out of five $\gamma\delta$ TCL enriched GO categories and two out of three KEGG signaling pathways, thus becoming a very important marker in differentiating $\gamma\delta$ TCL from $\alpha\beta$ TCL [18].

6. Types of gamma delta T-cell lymphoma

6.1 Hepatosplenic T $\gamma\delta$ cell lymphoma (HS $\gamma\delta$ TL)

Hepatosplenic gamma delta T cell lymphoma is one of the types of gamma delta T-cell lymphoma with an aggressive clinical course and poor overall survival rates [19]. The average length of survival seems to be <16 months [20]. The unique feature of this type of T cell lymphoma is the extranodal involvement with a specific sinusoidal pattern of infiltration of the liver, red pulp of spleen and bone marrow [21]. It also has unique immunophenotypical and chromosomal abnormality distinguishing it from other subtypes of gamma delta T cell lymphomas [22].

6.1.1 Incidence and etiology

Hepatosplenic T $\gamma\delta$ cell lymphoma seems to be predominantly a disease of young age mostly affecting teenage and young adults. They represent <5% of all peripheral T cell lymphomas. Males are affected more than females with a male/female ratio of 10/1. Although chronic antigenic stimulation and immune dysregulation seems to be likely causative factor in the evolution of this disorder [23], most of the cases (72%) of HSGDTCL occurs in patients with no underlying immunosuppression. Only around 18% of patients have underlying immunosuppression in the form of either previous organ transplants, chronic steroids use, inflammatory bowel disease, autoimmune disorders and hematological malignancies especially of acute myeloid leukemia, multiple myeloma, and Hodgkin lymphoma. About 10% of the patients have a history of previous treatment with immunosuppressive or biologics especially azathioprine and infliximab [24]. There are few cases reporting associations with Epstein-Barr Virus (EBV) and hepatitis B infections in the literature [25].

6.1.2 Pathology

The histopathological feature of HSGDTL includes monomorphous infiltration of medium-sized lymphocytes with a moderate amount of large pale basophilic cytoplasm [23, 26–28]. These cells have loosely condensed nuclear chromatin with small inconspicuous nucleoli. Spleen shows an involvement of sinuses of red pulp with atrophic white pulp. Involvement of liver is predominantly in the sinusoids. Bone marrow involvement occurs with predominantly intrasinusoidal distribution. An interstitial pattern of bone marrow involvement with a shift towards blastic cells are features of disease progression. Lymph node involvement is very rare.

Immunophenotypic origin is from double negative CD4[–] CD8[–] cells which show CD2⁺ CD3⁺ CD5[–] CD7⁺, TCR $\gamma\delta$ ⁺ [28, 29]. NK cell markers (DC16, CD56, CD57) may occasionally be expressed. They also show expression of cytotoxic granule-associated proteins such as TIA1 and granzyme M but are negative for granzyme B and perforin [22, 29]. A minority of variant forms of HSGDTL shows TCR $\alpha\beta$ expression.

The most common cytogenetic abnormality seen in HSGDTL is isochromosome 7q abnormality [i(7q)]. Trisomy 8 and deletion of Y chromosome are other genetic abnormalities sometimes encountered. The primary cytogenetic event which occurs initially is i(7q) while the other genomic alteration occurs when the disease progresses [30–32].

6.1.3 Molecular genetics of HSGDTL

Although isochromosome 7q is the most common chromosomal abnormality detected so far in HSTL, recent genomic analysis by Julio Finalet Ferreiro et al. identified a rare variant aberration of ring 7 [r(7)], thereby narrowing down the

critical 7p/7q regions and identifying the targeted genes. They did genomic and transcriptomic study of six i(7) (q10) and ring 7 [r(7)] cases of HSTL, thereby mapping the common deleted region (CDR) at 7p22.1p14.1 (34.88 Mb; 3,506,316–38,406,226 bp) and the common gained region (CGR) at 7q22.11q31.1 (38.77 Mb; 86,259,620–124,892,276 bp). They postulated that loss of 7p22.1p14.1 enhanced the expression of CHN2 (7p14.1)/b2-chimerin leading to downmodulation of the NFAT pathway thereby increasing proliferation. They also hypothesized that the multidrug resistance gene ABCB1, RUNDC3B, PPP1R9A have an increased expression with the amplification of 7q22.11q31.1, thereby providing a growth advantage for the tumor cells further increasing their intrinsic chemoresistance. They distinguished HSTL from other malignancies by identifying a set of 24 genes by doing gene expression profile of HSTL, including three located on chromosome 7 (CHN2, ABCB1, and PPP1R9A) [33].

McKinney et al. did detailed study on the whole exome sequencing of 68 HSTL cases and identified the commonly mutated genes including SETD2, INO80, and ARID1B in 62% of HSTL cases. Mutations were also identified in STAT5B (31%), STAT3 (9%), and PIK3CD (9%) which has targeted treatments currently. The most commonly silenced gene was found to be SETD (tumor suppressor gene). Cell survival in HSTL was linked to the mutations in STAT5B and PIK3CD which activates the critical signaling pathways [34].

6.1.4 Staging

Staging of HSGDTL is based on the physical examination, hematological and biochemical parameters, imaging studies including computed tomography (CT) and positron emission tomography (PET) scans, bone marrow biopsy and gastrointestinal tract examination. Experience of PET imaging in T cell lymphomas is anecdotal when compared to B cell lymphomas [35–37]. Ann-Arbor staging system is used for staging of HSGDTL like any other NHL [38]. As per this staging, HSGDTL is classified as stage IV disease commonly presenting with systemic symptoms, hepatosplenic involvement with rare occurrence of bulky disease.

6.1.5 Postulated cell of origin

HSGDTCL is believed to arise from the immature non-activated gamma-delta T cells (T $\gamma\delta$) of Vdelta1 subtype which are predominantly seen in the gastrointestinal tract [39–41].

6.1.6 Clinical presentation

HSGDTL is mainly a disease of young men affecting in their second or third decade of life [42]. Main presenting features include systemic symptoms, hepatosplenomegaly and the absence of lymphadenopathy. The presenting feature of HSGDTL as per literature review include cytopenia, splenomegaly, fever, weight loss, fatigue and easy bruising. Laboratory abnormality included anemia, thrombocytopenia, neutropenia, mildly elevated AST, ALT and alkaline phosphatase. Markedly elevated lactate dehydrogenase (LDH) is a frequently observed phenomenon. Fifty to 80% of cases can have peripheral neoplastic lymphocytes [20]. Very rarely can present with autoimmune hemolytic anemia [43]. Bone marrow involvement is very frequent at diagnosis [20, 44] Cytopenia is related to bone marrow infiltration, hypersplenism, and cytokine-induced hemophagocytic histiocytosis [45]. Re-appearance of thrombocytopenia is used as an indicator of relapse of disease in a patient who is in complete remission. Cutaneous and mediastinal

involvement is very unusual. Presence of lymphadenopathy is very rare and would virtually rule out the possibility of HSGDTL.

6.1.7 Treatment and prognosis

There exists no consensus in the treatment of these lymphomas due to its rarity and limited possibility of prospective trials. Most commonly used treatment regimen is CHOP (cyclophosphamide, doxorubicin, vincristine, and prednisone) regimen with an acceptable response rate between 30 and 45%. But even with those who achieve complete remission, the median time to relapse remains around 4 months [22, 46, 47]. Few other treatment options previously tried includes corticosteroids, alkylating agents, anthracycline-containing agents like CHOP/HYPERCVAD regimen, purine analogs and cytarabine-cisplatin combination. Few cases have reported clinical response with alemtuzumab combined with purine analogs but no overall survival benefit was noted [48–50]. But this combination causes significant hematological toxicity causing deeper immunosuppression and the risk of infection reactivations.

Autologous and allogeneic stem cell transplantations have been used as a modality of treatment with good response. There are case reports which support bortezomib in combination with high dose CHOP chemotherapy followed by BEAM autograft as well as CHOP regimen followed by high dose methotrexate, high dose cyclophosphamide with subsequent autograft using conditioning regimen containing etoposide, ifosfamide, and ranimustine [51]. Allogeneic stem cell transplantation has previously been tried with encouraging results but at the expense of treatment-related mortality. Various myeloablative conditioning regimen has been tried usually including total body irradiation. Relapse-free interval has been shown to be between 12 and 58 months after treatment of aggressive disease with allogeneic transplant. Relapsed/refractory disease is usually resistant to conventional chemotherapy and there are previous case reports of successful second allogeneic transplant for patients who failed the first allograft [52]. Relapse of the disease is usually seen in the initially involved sites but lymphadenopathy is uncommon which signifies the homing of these neoplastic cells.

Treatment of relapsed/refractory disease with single agents like bevacizumab, vorinostat, lenalidomide, bortezomib, bendamustine and etoposide has been reported in single cases but no large case series data exist about their efficacy [53–59]. HSGDTL is a very aggressive disease which is resistant to most of the conventional chemotherapeutic agents. The median survival has been estimated to be <1 year for those treated with a CHOP-like regimen. Most of the patients do not live longer than 2 years [14]. Even though there is a lack of clear prognostic factors, data from small case series suggests male sex, lack of TCR rearrangements and failure of response has been shown to have negative outcomes [42]. New onset thrombocytopenia has been linked to the recurrence and severity of the disease in few cases [20].

6.2 Primary cutaneous gamma delta T-cell lymphoma (PCGD-TCL)

As per 2016 WHO classification of mature lymphoid, histiocytic and dendritic neoplasms, cutaneous T cell lymphomas are classified as subcutaneous panniculitis-like T cell lymphoma, mycosis fungoides (MF), Sezary syndrome, primary cutaneous gamma delta T cell lymphomas (PCGD-TCL), lymphoid polyposis, CD30+ primary cutaneous anaplastic large cell lymphoma, primary cutaneous CD8+ aggressive epidermotropic cytotoxic T cell lymphomas, primary cutaneous acral CD8+ T-cell lymphoma, primary cutaneous lymphomas, not otherwise classified (PCTL, NOS), extranodal nasal-type NK/T-cell lymphomas and primary cutaneous CD4+ small/medium T-cell lymphoproliferative disorder.

Primary cutaneous gamma delta T-cell lymphomas is a rare malignancy with a very aggressive course. There also exists rarer variants which have an indolent course as per few case reports [60]. Primary cutaneous gamma delta T-cell lymphomas have a preference for extremities and can present either as plaque, tumor or subcutaneous nodules. They do not exhibit EBV positivity and mostly have a mature cytotoxic phenotype.

6.2.1 Incidence and risk factors

PCGD-TCL accounts for <1% of all cutaneous TCLs [17]. It arises from clonal proliferation of cytotoxic gamma-delta T-cells in the skin. Mostly all cases are grouped as either mycosis fungoides-like or subcutaneous panniculitis-like cutaneous lymphomas. Generally, these mucocutaneous subtypes are not related to Epstein-Barr virus infections [61].

Chronic antigenic stimulation along with decreased immunity remains the underlying risk factor for developing this disease. Some of the other risk factors seem to be underlying autoimmunity, malignancy, viral hepatitis and other lymphoproliferative disorders.

6.2.2 Pathology

Histologically the infiltration patterns can involve epidermis, dermis and subcutaneous tissue. These patterns can be present separately or can be seen within the same lesion [23]. The presentation can be disseminated, necrotizing or ulcerative. Pathological features involve angioinvasion, angiodestruction, and necrosis. Epidermal involvement may vary from being mild epidermotrophic to a marked pagetoid variety [62]. In the subcutaneous panniculitis type, infiltration with medium to large neoplastic cells with clumped chromatin is seen around adipose tissues. Occasionally blastoid cells with prominent nucleoli are noted.

The neoplastic cells usually express CD2 and CD3 and are usually negative for CD4 and CD8. They also express CD7, CD56 and frequently are positive for cytotoxic proteins like TIA-1, granzyme B, and perforin. They do not express β F1.

TCR γ expression has also been reported in other primary cutaneous TCLs especially in mycosis fungoides and lymphomatoid papulosis. Even though these lymphomas are CD8 negative, few cases of CD8+ PCGD-TCLs have been reported [16].

6.2.3 Molecular genetics

Neoplastic cells always express TCR γ and TCR δ genetic rearrangements. They are also negative for EBV encoded RNA emphasizing that EBV infection does not play any role in their pathogenesis [23]. PCGD-TCLs show very complex cytogenetic alterations which include translocations involving breakpoints at 9p21, 14q11.2, 14q32.1 or 16q23.1. This suggests that the tumor evolution is related to WWOX, TCL gene cluster, and BCL11B [63].

Other pathways involved in tumorigenesis includes pathways related to RAS, P13KT/MTOR, TP53 and MYC related signaling [26]. There are no characteristic mutations identified so far.

6.2.4 Staging

Staging involves a complete workup including hematological evaluation, biochemical evaluation, gastrointestinal evaluation, bone marrow biopsy, PET CT and/or computed tomography scans. Most commonly used staging system for PCGD-TCL

is the International Society for Cutaneous Lymphoma/European Organization of Research and Treatment of Cancer (ISCL/EORTC) TNM classification system of cutaneous lymphoma other than mycosis fungoides and Sezary syndrome [64].

6.2.5 Clinical presentation

Most of the cases occur in older adults with a median age of 60 years. There seems to be no gender preference and both sexes are equally affected [65]. PCGD-TCL shows diffuse skin involvement with a predilection for extremities, thighs, and buttocks and spares the trunk. They may present either as a papule, plaque or nodule with ulceration and overlying epidermal necrosis. Few cases present as panniculitis either with dermal or subcutaneous infiltration [61].

In one of the study gamma delta cutaneous T-cell lymphomas have been shown to have a poor survival when compared with alpha-beta subtype. The median survival for the former was 15 months whereas it was 166 months for latter. It was also found that patients who had subcutaneous involvement had decreased survival (13 months) compared to those who had epidermotrophic or dermal involvement (29 months). Poor prognostic factors included gamma delta phenotype, subcutaneous involvement, and presentation as clinical tumors [16].

Most of the patients have B symptoms like fever, weight loss, and an elevated LDH. Hemophagocytic syndrome is more likely with panniculitis like presentation [61]. Although most of the cases of PCGD-TCL is aggressive, there are also cases which are indolent. This indolent variety has been described previously as “ketron-goodman type” presenting as verrucoid lesions [53]. Mucosal and extranodal dissemination mainly to GI tract and nasopharynx are seen [66–72]. Widespread dissemination is rare and involvement if spleen, liver and bone marrow are infrequent. Only very few cases have lymph node involvement [73]. Rare cases of metastasis to testis and central nervous system have been reported.

6.2.6 Treatment and prognosis

No standard treatment exists due to the rarity of this disease. Hence the treatment guidelines are mostly based on case reports. Most commonly used regimen remains to be doxorubicin-based regimen like CHOP. About 50% of the patients showed response but subsequently had a relapse of the disease with tumor progression and death. Steroids have been used with increased remission rate [74]. Low dose methotrexate and narrow-band ultraviolet radiation have also been used in few types of PCGDTL presenting as patch/plaque [75]. Bexarotene as a single agent and in combination was used as maintenance after CHOP-like regimen showing good response [76].

Due to the aggressive nature of the disease, autologous and allogeneic stem cell transplant has also been tried. In a small case series (n = 13) complete remission rate of 92% was achieved with stem cell transplant. But this study included alpha/beta phenotype as well which impairs the application of the results. The more indolent subtype remains responsive to steroids without the need for a more aggressive approach [60].

The overall prognosis seems to be very poor due to aggressive nature and chemotherapy resistance of these lymphomas. They have a median survival of 15 months and a 5-year overall survival is around 10% [16]. But the more indolent subtypes usually have slightly better prognosis when compared to aggressive subtype. Poor prognostic factors included subcutaneous involvement, age > 40 years, associated cytopenias, tumors expressing CD56, CD95 without expressing CD8, extensive ulcerated lesions at presentation, central nervous system (CNS) involvement and the presence of hemophagocytic syndrome as per the largest reported series [77, 78].

6.3 Mucosal gamma delta TCL

This type of lymphoma affects the mucosal tract lining nasopharynx, intestine, breast, larynx, lung, and testis indicating the homing of these $\gamma\delta$ T-cells. These are very aggressive lymphomas and due to the rarity of the disease, information regarding the presentation and treatment is only from small case series.

6.3.1 Incidence and risk factors

Mucosal gamma-delta lymphoma is very rare aggressive tumor whose incidence cannot be predicted due to rarity and limited literature evidence. Chronic antigenic stimulation along with prolonged immune suppression seems to be a major risk factor in the development of this disease. Patients with underlying hypogammaglobulinemia, selective IgA deficiency, and T cell deficiency are more prone to develop this disease. In one of the case series, it was found that patients who developed nasal lymphoma had past history of chronic sinusitis. Similarly, pulmonary lymphomas developed in a background of opportunistic pulmonary infections. Gastric and intestinal lymphomas had a predisposing factor of *H. pylori* and coeliac sprue [26, 66, 79].

6.3.2 Pathology

Morphologically they are variable in nature presenting either as small to medium-sized cells or as large pleomorphic variants. Occasionally cells had abundant clear cytoplasm with irregular nuclei with condensed chromatin. Other features commonly seen include angioinvasion, angiocentrism, epitheliotropism and necrosis [42].

Most of them express TCR $\gamma\delta$ (δ TCR1+) but are negative for TCR $\alpha\beta$. They commonly express CD2 and CD3 but did not express CD4, CD8, and CD5. CD7 may be variable. CD56 is expressed mostly by nasal T-cell lymphomas and are infrequent in other types. Since the tumor arises from activated cytotoxic T cells, there is a positive expression for T cell intracellular antigen 1 (TIA1), granzyme B, and perforin. EBV association has been reported in nasal, laryngeal and gastrointestinal mucosal gamma-delta T-cell lymphoma. EBV-encoded latent membrane protein studied by immunohistochemistry is found positive in these variants [42].

6.3.3 Genetic abnormality

Neoplastic cells showed clonal γ chain rearrangement showing evidence of T cell lineage and clonality. They show positivity for EBV encoded RNA emphasizing that EBV infection does play a role in their pathogenesis. No other characteristic mutations have been identified so far.

6.3.4 Clinical presentation

Mucosal gamma-delta T-cell lymphomas usually have an aggressive course with high recurrence rate presenting both with a local and systemic disease. In one of the case series, the median age of the patient was 48 years. Nasal lymphomas present as destructive nasal lesions as well as nasal obstruction. Gastrointestinal lymphomas usually involve either localized or diffuse areas of the gut thereby presenting as peritonitis and perforation [66]. Most of the patients present with B symptoms but rarely have any lymphadenopathy or bone marrow involvement. Elevated LDH and hypogammaglobulinemia were observed in few cases [66].

6.3.5 Treatment and prognosis

Due to the rarity of the disease, no guidelines exist. Literature evidences are available for treatment with CHOP-like regimen and stem cell transplantation. Clinical outcome is mostly associated with short overall survival. Durable remission was seen only in few cases. In a small case series of 11 patients, most of the patients died within 1 year and only three had some durable response lasting more than a year [66].

6.4 Gamma delta T-LGL

Gamma-delta T-LGL represents 2–3% of all mature lymphocytic leukemia. Most of the T-LGL have $\alpha\beta$ rearrangements and are positive for CD8, CD16, CD57. $\gamma\delta$ T-cell large granular lymphocytic (T-LGL) is a very rare heterogeneous disorder of mature lymphocytes with unique morphology and an indolent clinical course. Although this variant is similar to the common T-LGL, some differences exist in clinical presentation, immunophenotype and organ involvement.

6.4.1 Incidence and risk factors

$\gamma\delta$ T-LGL accounts for <5% of all T-LGLs. Usually, this type of lymphoma presents in patients >50 years old. Underlying immunosuppression is an associated risk factor for its development. Association with rheumatoid arthritis has been reported in about 20% of cases of $\gamma\delta$ T-LGL and 25% of $\alpha\beta$ T-LGL [80–82].

6.4.2 Pathology

Neoplastic cells can be infiltrated most commonly in bone marrow and spleen. When present in peripheral blood, they appear as large granular lymphocytes with azurophilic granules. Bone marrow involvement is characterized by lymphoid aggregates especially in the interstitial and intrasinusoidal areas [83]. Splenic involvement is characterized by infiltration of small lymphocytes with dense chromatin mostly concentrated in the red pulp rather than the white pulp [84, 85].

The neoplastic cells show positivity for pan T cell antigens CD2, CD3, and CD7. CD5 may be variable. They are usually CD8 positive and CD4 negative but cases with CD8 positivity has been reported previously [80, 81, 83, 86]. They show variable expression for CD16, CD56, and CD57. Cytotoxic markers like granzyme B and TIA-1 are seen in all cases. Flow cytometry usually shows positive expression for TCR $\gamma\delta$ (δ TCR1+) and is negative for TCR $\alpha\beta$. Immunohistochemical studies show TCR γ and negative for β F1 (marker for TCR β).

6.4.3 Genetics

Neoplastic cells showed clonal γ chain rearrangement showing evidence of T cell lineage and clonality. Due to similar immunophenotype, especially of CD4-CD8–T-LGL with hepatosplenic gamma-delta T-cell lymphoma, further cytogenetic and FISH analysis need to be done to prove negativity for isochromosome 7q (i7q) [80, 83].

6.4.4 Clinical presentation

B symptom is common particularly with fever and fatigue predominating. The lab abnormality includes anemia, neutropenia, and thrombocytopenia with some

cases presenting with increased severity. Not all patients present with lymphocytosis and occasionally lymphopenia is also observed. The peripheral smear shows large lymphocytes with prominent azurophilic granules in patients presenting with lymphocytosis. Splenomegaly is a common finding, but lymphadenopathy is rare. Bone marrow involvement is present mostly and shows predominantly an interstitial or less commonly intrasinusoidal pattern of infiltration. Associated autoimmune disorders like autoimmune hemolytic anemia (AIHA), immune thrombocytopenic purpura (ITP), rheumatoid disorder, pure red cell aplasia is also commonly observed [83].

6.4.5 Treatment and prognosis

The clinical course is mostly indolent. T-LGL generally is a chronic disorder with a good 10-year survival of 80% with around half of the patients not requiring any therapy [80, 81, 83, 87]. Spontaneous regression has been seen in few cases [88, 89]. The common reason for therapy remains to be low blood counts followed by hemolysis and splenomegaly. Several treatments like methotrexate, cyclophosphamide, cyclosporine, fludarabine, pentostatin either alone or in combination with steroids have been tried [90–93]. More resistant or advanced disease needs cytotoxic chemotherapy. Clinical course can be aggressive especially if they express CD56 antigen [94]. Splenectomy was also done as part of the treatment of ITP associated with this disorder.

6.5 Nodal gamma delta TCL

Nodal gamma delta TCL is a very rare subtype within gamma delta T-cell lymphomas. Very limited information is available in the literature due to the extreme rarity of this variant. So far only six cases of nodal gamma delta lymphomas have been reported. Usually, the presentation is in the form of disseminated nodal involvement.

6.5.1 Incidence and risk factors

Incidence difficult to predict due to the rarity of the disease. Chronic antigenic stimulation associated with immunosuppression plays a major role in the pathogenesis. Few case reports also suggest the role of EBV in lymphomagenesis.

6.5.2 Pathology

Neoplastic cells are very variable. They can present as a diffuse pleomorphic proliferation of small to medium-sized lymphoid cells with an irregular nucleus and moderate cytoplasm. They can also present as large pleomorphic cells or anaplastic or angioimmunoblastic like cells [42]. In one case report describing two cases of nodal gamma delta T-cell lymphoma, nodal preservation was noted in the first case whereas complete destruction of architecture was observed in the other [95]. The second case presented with lymphadenopathy and hepatosplenomegaly and had infiltration of lymphoid cells in the intrasinusoidal area of the lymph node. Predominant involvement of T zones was observed in one case [96]. Hence there may be two different patterns of presentation with diffuse pleomorphic involvement mimicking classical $\alpha\beta$ T-cell lymphoma or hepatosplenic involvement mimicking hepatosplenic gamma-delta lymphoma [97].

The neoplastic cells express CD2, CD3, CD43, CD45. They also exhibit positivity for TIA-1, granzyme B and displayed a gamma delta phenotype (deltaTCR1+, Vdelta1+, Vdelta2–, Vdelta3–, betaF1–).

6.5.3 Genetic abnormality

The genotypic analysis shows TCR gamma-chain gene rearrangement pattern. The neoplastic cells also show expression of the latent membrane protein-1 by immunohistochemistry and EBV-encoded small RNAs by in situ hybridization. EBV positivity was also observed in tumor recurrence as reported in one case report [98]. A complex cytogenetic abnormality is seen in few cases, but no specific cytogenetic abnormality exists for this variant.

6.5.4 Clinical presentation

Patients most commonly present with lymphadenopathy. Usually, there is a past history of immunosuppression. In one case report, nodal gamma delta T-cell lymphoma presented post renal transplant in one case and after cytomegalovirus (CMV) infection in another case. Bone marrow infiltration and hepatosplenomegaly have also been reported [95].

6.5.5 Treatment and prognosis

This subtype is very resistant to conventional chemotherapy and has a very poor prognosis. Patients presenting with this type of lymphoma died within a short time after diagnosis [95].

7. Conclusion

Even though WHO 2016 classification of lymphoid malignancies recognizes four entities of gamma delta lymphomas, few more subtypes have been reported in literature which remains unclassified. These clinically important lymphomas pose a clinical challenge in diagnosis and management due to rarity and critical gap in consensus of treatment. Combination of clinical picture, morphology, immunophenotyping, molecular techniques are used in combination due to the diagnostic difficulties of these lymphomas. The poor prognosis associated with these subtypes is related to the rapidly evolving clinical picture and refractoriness to standard chemotherapies. Cytarabine combined with platinum-based regimen followed by stem cell transplantation seems to be the optimal management option for eligible patients. Encouraging prompt reporting of these rarer entities needs to be encouraged to further advance our understanding thus allowing newer perspective in the management.

Acknowledgements

1. Ramachandran Lakshmipathy, FRCPath, Bristol, UK.
2. Saravanan S. Karuppagounder, PhD, Burke Neurological Institute and Brain and Mind Research Institute, Weill Cornell Medicine, White Plains, NY 10605.
3. Oleg Reznik, Illustrator.

Conflict of interest

None.

IntechOpen

Author details

Preethi Ramachandran^{1*}, Alok Aggarwal² and Jen Chin Wang¹

¹ Division of Hematology/Oncology, Brookdale University Hospital Medical Center, Brooklyn, New York, USA

² Department of Hepatobiliary and General Surgery, Brookdale University Hospital and Medical Center, Brooklyn, New York, USA

*Address all correspondence to: drpreethiram@hotmail.com

IntechOpen

© 2019 The Author(s). Licensee IntechOpen. This chapter is distributed under the terms of the Creative Commons Attribution License (<http://creativecommons.org/licenses/by/3.0>), which permits unrestricted use, distribution, and reproduction in any medium, provided the original work is properly cited. 

References

- [1] Wang SS, Vose JM. Epidemiology and prognosis of T-cell lymphoma. In: Foss F, editor. *T-Cell Lymphomas*. Totowa, NJ: Humana Press; 2013. pp. 25-39
- [2] Swerdlow SH, Campo E, Pileri SA, et al. The 2016 revision of the World Health Organization classification of lymphoid neoplasms. *Blood*. 2016;**127**:2375-2390
- [3] Bordessoule D, Gaulard P, Mason DY. Preferential localisation of human lymphocytes bearing gamma delta T cell receptors to the red pulp of the spleen. *Journal of Clinical Pathology*. 1990;**43**(6):461-464
- [4] Sindhu H, Chen R, Chen H, Wong J, Chaudhry R, Xu Y, et al. Gamma-delta (gammadelta) T-cell lymphoma—Another case unclassifiable by World Health Organization classification: A case report. *Journal of Medical Case Reports*. 2017;**11**(1):163
- [5] Kindt TJ, Goldsby RA, Osborne BA, Kuby J. *Kuby Immunology*. USA: Macmillan; 2007. p. 223. ISBN 978-1-4292-0211-4 [Retrieved 28 November 2010]
- [6] Janeway CA Jr, Travers P, Walport M, et al. *Immunobiology: The Immune System in Health and Disease*. 5th ed. USA: Glossary, Garland Science; 2001
- [7] Kreslavsky T, Gleimer M, Garbe AI, von Boehmer H. Alphabeta versus gammadelta fate choice: Counting the T-cell lineages at the branch point. *Immunological Reviews*. 2010;**238**(1):169-181
- [8] Bluestone JA, Khattri R, Sciammas R, Sperling AI. TCR gamma delta cells: A specialized T-cell subset in the immune system. *Annual Review of Cell and Developmental Biology*. 1995;**11**:307-353
- [9] Holtmeier W, Kabelitz D. Gammadelta T cells link innate and adaptive immune responses. *Chemical Immunology and Allergy*. 2005;**86**:151-183
- [10] Hoft DF, Brown RM, Roodman ST. Bacille Calmette-Guerin vaccination enhances human gamma delta T cell responsiveness to mycobacteria suggestive of a memory-like phenotype. *Journal of Immunology*. 1998;**161**(2):1045-1054
- [11] Boismenu R, Havran WL. An innate view of gamma delta T cells. *Current Opinion in Immunology*. 1997;**9**(1):57-63
- [12] Williams N. T cells on the mucosal frontline. *Science*. 1998;**280**(5361):198-200
- [13] Born WK, Reardon CL, O'Brien RL. The function of gammadelta T cells in innate immunity. *Current Opinion in Immunology*. 2006;**18**(1):31-38
- [14] Tripodo C, Iannitto E, Florena AM, Pucillo CE, Piccaluga PP, Franco V, et al. Gamma-delta T-cell lymphomas. *Nature Reviews. Clinical Oncology*. 2009;**6**(12):707-717
- [15] Rajoriya N, Fergusson JR, Leithead JA, Klenerman P. Gamma Delta T-lymphocytes in hepatitis C and chronic liver disease. *Frontiers in Immunology*. 2014;**5**:400
- [16] Toro JR, Liewehr DJ, Pabby N, Sorbara L, Raffeld M, Steinberg SM, et al. Gamma-delta T-cell phenotype is associated with significantly decreased survival in cutaneous T-cell lymphoma. *Blood*. 2003;**101**(9):3407-3412
- [17] Sabattini E, Bacci F, Sagramoso C, Pileri SA. WHO classification of tumours of haematopoietic and lymphoid tissues in 2008: An overview. *Pathologica*. 2010;**102**(3):83-87

- [18] Miyazaki K et al. Gene expression profiling of peripheral T-cell lymphoma including $\gamma\delta$ T-cell lymphoma. *Blood*. 2009;**113**(5):1071-1074
- [19] Ferreri AJ, Govi S, Pileri SA. Hepatosplenic gamma-delta T-cell lymphoma. *Critical Reviews in Oncology/Hematology*. 2012;**83**(2):283-292
- [20] Belhadj K, Reyes F, Farcet JP, Tilly H, Bastard C, Angonin R, et al. Hepatosplenic gammadelta T-cell lymphoma is a rare clinicopathologic entity with poor outcome: Report on a series of 21 patients. *Blood*. 2003;**102**(13):4261-4269
- [21] Gaulard P, Bourquelot P, Kanavaros P, Haioun C, Le Couedic JP, Divine M, et al. Expression of the alpha/beta and gamma/delta T-cell receptors in 57 cases of peripheral T-cell lymphomas. Identification of a subset of gamma/delta T-cell lymphomas. *The American Journal of Pathology*. 1990;**137**(3):617-628
- [22] Weidmann E. Hepatosplenic T cell lymphoma. A review on 45 cases since the first report describing the disease as a distinct lymphoma entity in 1990. *Leukemia*. 2000;**14**(6):991-997
- [23] Campo E, Swerdlow SH, Harris NL, Pileri S, Stein H, Jaffe ES. The 2008 WHO classification of lymphoid neoplasms and beyond: Evolving concepts and practical applications. *Blood*. 2011;**117**(19):5019-5032
- [24] Mackey AC, Green L, Liang LC, Dinndorf P, Avigan M. Hepatosplenic T cell lymphoma associated with infliximab use in young patients treated for inflammatory bowel disease. *Journal of Pediatric Gastroenterology and Nutrition*. 2007;**44**(2):265-267
- [25] Ozaki S, Ogasahara K, Kosaka M, Inoshita T, Wakatsuki S, Uehara H, et al. Hepatosplenic gamma delta T-cell lymphoma associated with hepatitis B virus infection. *The Journal of Medical Investigation*. 1998;**44**(3-4):215-217
- [26] de Wolf-Peeters C, Achten R. Gammadelta T-cell lymphomas: A homogeneous entity? *Histopathology*. 2000;**36**(4):294-305
- [27] Cooke CB, Krenacs L, Stetler-Stevenson M, Greiner TC, Raffeld M, Kingma DW, et al. Hepatosplenic T-cell lymphoma: A distinct clinicopathologic entity of cytotoxic gamma delta T-cell origin. *Blood*. 1996;**88**(11):4265-4274
- [28] Farcet JP, Gaulard P, Marolleau JP, Le Couedic JP, Henni T, Gourdin MF, et al. Hepatosplenic T-cell lymphoma: Sinusal/sinusoidal localization of malignant cells expressing the T-cell receptor gamma delta. *Blood*. 1990;**75**(11):2213-2219
- [29] Swerdlow S, McColl K, Rong Y, Lam M, Gupta A, Distelhorst CW. Apoptosis inhibition by Bcl-2 gives way to autophagy in glucocorticoid-treated lymphocytes. *Autophagy*. 2008;**4**(5):612-620
- [30] Alonsozana EL, Stamberg J, Kumar D, Jaffe ES, Medeiros LJ, Frantz C, et al. Isochromosome 7q: The primary cytogenetic abnormality in hepatosplenic gammadelta T cell lymphoma. *Leukemia*. 1997;**11**(8):1367-1372
- [31] Colwill R, Dube I, Scott JG, Bailey D, Deharven E, Carstairs K, et al. Isochromosome 7q as the sole abnormality in an unusual case of T-cell lineage malignancy. *Hematologic Pathology*. 1990;**4**(1):53-58
- [32] Jonveaux P, Daniel MT, Martel V, Maarek O, Berger R. Isochromosome 7q and trisomy 8 are consistent primary, non-random chromosomal abnormalities associated with hepatosplenic T gamma/delta lymphoma. *Leukemia*. 1996;**10**(9):1453-1455

- [33] Finalet Ferreira J, Rouhigharabaei L, Urbankova H, et al. Integrative Genomic and Transcriptomic Analysis Identified Candidate Genes Implicated in the Pathogenesis of Hepatosplenic T-Cell Lymphoma. Hoheisel JD, ed. PLoS ONE. 2014;**9**(7):e102977. DOI: 10.1371/journal.pone.0102977
- [34] McKinney M, Moffitt AB, Gaulard P, et al. The genetic basis of hepatosplenic T cell lymphoma. *Cancer Discovery*. 2017;**7**(4):369-379. DOI: 10.1158/2159-8290.CD-16-0330
- [35] Khong PL, Pang CB, Liang R, Kwong YL, Au WY. Fluorine-18 fluorodeoxyglucose positron emission tomography in mature T-cell and natural killer cell malignancies. *Annals of Hematology*. 2008;**87**:613-621
- [36] Kako S, Izutsu K, Ota Y, Minatani Y, Sugaya M, Momose T, et al. FDG-PET in T-cell and NK-cell neoplasms. *Annals of Oncology*. 2007;**18**(10):1685-1690
- [37] Storto G, Di Giorgio E, De Renzo A, Pizzuti LM, Cerciello G, Nardelli A, et al. Assessment of metabolic activity by PET-CT with F-18-FDG in patients with T-cell lymphoma. *British Journal of Haematology*. 2010;**151**(2):195-197
- [38] Carbone PP, Kaplan HS, Musshoff K, Smithers DW, Tubiana M. Report of the committee on Hodgkin's disease staging classification. *Cancer Research*. 1971;**31**(11):1860-1861
- [39] Gaulard P, de Leval L. Pathology of peripheral T-cell lymphomas: Where do we stand? *Seminars in Hematology*. 2014;**51**:5-16
- [40] Kanavaros P, Farcet JP, Gaulard P, Haioun C, Divine M, Le Couedic JP, et al. Recombinative events of the T cell antigen receptor delta gene in peripheral T cell lymphomas. *The Journal of Clinical Investigation*. 1991;**87**(2):666-672
- [41] Przybylski GK, Wu H, Macon WR, Finan J, Leonard DG, Felgar RE, et al. Hepatosplenic and subcutaneous panniculitis-like gamma/delta T cell lymphomas are derived from different Vdelta subsets of gamma/delta T lymphocytes. *The Journal of Molecular Diagnostics*. 2000;**2**(1):11-19
- [42] Gaulard P, Belhadj K, Reyes F. Gammadelta T-cell lymphomas. *Seminars in Hematology*. 2003;**40**(3):233-243
- [43] Sallah S, Smith SV, Lony LC, Woodard P, Schmitz JL, Folds JD. Gamma/delta T-cell hepatosplenic lymphoma: Review of the literature, diagnosis by flow cytometry and concomitant autoimmune hemolytic anemia. *Annals of Hematology*. 1997;**74**(3):139-142
- [44] Vega F, Medeiros LJ, Bueso-Ramos C, Jones D, Lai R, Luthra R, et al. Hepatosplenic gamma/delta T-cell lymphoma in bone marrow. A sinusoidal neoplasm with blastic cytologic features. *American Journal of Clinical Pathology*. 2001;**116**(3):410-419
- [45] Florena AM, Tripodo C, Porcasi R, Ingrao S, Fadda MR, De Cantis S, et al. Immunophenotypic profile and role of adhesion molecules in splenic marginal zone lymphoma with bone marrow involvement. *Leukemia & Lymphoma*. 2006;**47**(1):49-57
- [46] Petit B, Leroy K, Kanavaros P, Boulland ML, Druet-Cabanac M, Haioun C, et al. Expression of p53 protein in T- and natural killer-cell lymphomas is associated with some clinicopathologic entities but rarely related to p53 mutations. *Human Pathology*. 2001;**32**(2):196-204
- [47] Sayers TJ, Brooks AD, Ward JM, Hoshino T, Bere WE, Wiegand GW, et al. The restricted expression of granzyme M in human lymphocytes. *Journal of Immunology*. 2001;**166**(2):765-771
- [48] Mittal S, Milner BJ, Johnston PW, Culligan DJ. A case of hepatosplenic

gamma-delta T-cell lymphoma with a transient response to fludarabine and alemtuzumab. *European Journal of Haematology*. 2006;**76**(6):531-534

[49] Jaeger G, Bauer F, Brezinschek R, Beham-Schmid C, Mannhalter C, Neumeister P. Hepatosplenic gammadelta T-cell lymphoma successfully treated with a combination of alemtuzumab and cladribine. *Annals of Oncology*. 2008;**19**(5):1025-1026

[50] Chanan-Khan A, Islam T, Alam A, Miller KC, Gibbs J, Barcos M, et al. Long-term survival with allogeneic stem cell transplant and donor lymphocyte infusion following salvage therapy with anti-CD52 monoclonal antibody (Campath) in a patient with alpha/beta hepatosplenic T-cell non-Hodgkin's lymphoma. *Leukemia & Lymphoma*. 2004;**45**(8):1673-1675

[51] Ooi J, Iseki T, Adachi D, Yamashita T, Tomonari A, Tojo A, et al. Successful allogeneic bone marrow transplantation for hepatosplenic gammadelta T cell lymphoma. *Haematologica*. 2001;**86**(10):E25

[52] Voss MH, Lunning MA, Maragulia JC, Papadopoulos EB, Goldberg J, Zelenetz AD, et al. Intensive induction chemotherapy followed by early high-dose therapy and hematopoietic stem cell transplantation results in improved outcome for patients with hepatosplenic T-cell lymphoma: A single institution experience. *Clinical Lymphoma, Myeloma & Leukemia*. 2013;**13**(1):8-14

[53] Advani RH, Hong F, Horning SJ, Kahl BS, Manola J, Swinnen LJ, et al. Cardiac toxicity associated with bevacizumab (Avastin) in combination with CHOP chemotherapy for peripheral T cell lymphoma in ECOG 2404 trial. *Leukemia & Lymphoma*. 2012;**53**(4):718-720

[54] Zinzani PL, Musuraca G, Tani M, Stefoni V, Marchi E, Fina M, et al.

Phase II trial of proteasome inhibitor bortezomib in patients with relapsed or refractory cutaneous T-cell lymphoma. *Journal of Clinical Oncology*. 2007;**25**(27):4293-4297

[55] Dueck G, Chua N, Prasad A, Finch D, Stewart D, White D, et al. Interim report of a phase 2 clinical trial of lenalidomide for T-cell non-Hodgkin lymphoma. *Cancer*. 2010;**116**(19):4541-4548

[56] Zinzani PL, Pellegrini C, Broccoli A, Stefoni V, Gandolfi L, Quirini F, et al. Lenalidomide monotherapy for relapsed/refractory peripheral T-cell lymphoma not otherwise specified. *Leukemia & Lymphoma*. 2011;**52**(8):1585-1588

[57] O'Connor OA, Pro B, Pinter-Brown L, Bartlett N, Popplewell L, Coiffier B, et al. Pralatrexate in patients with relapsed or refractory peripheral T-cell lymphoma: Results from the pivotal PROPEL study. *Journal of Clinical Oncology*. 2011;**29**(9):1182-1189

[58] Mann BS, Johnson JR, Cohen MH, Justice R, Pazdur R. FDA approval summary: Vorinostat for treatment of advanced primary cutaneous T-cell lymphoma. *The Oncologist*. 2007;**12**(10):1247-1252

[59] Woo S, Gardner ER, Chen X, Ockers SB, Baum CE, Sissung TM, et al. Population pharmacokinetics of romidepsin in patients with cutaneous T-cell lymphoma and relapsed peripheral T-cell lymphoma. *Clinical Cancer Research*. 2009;**15**(4):1496-1503

[60] Endly DC, Weenig RH, Peters MS, Viswanatha DS, Comfere NI. Indolent course of cutaneous gamma-delta T-cell lymphoma. *Journal of Cutaneous Pathology*. 2013;**40**(10):896-902

[61] Toro JR, Beaty M, Sorbara L, Turner ML, White J, Kingma DW, et al. Gamma delta T-cell lymphoma of the skin: A

clinical, microscopic, and molecular study. *Archives of Dermatology*. 2000;**136**(8):1024-1032

[62] Ralfkiaer E, Wollf-Sneedorff A, Thomsen K, Geisler C, Vejlsgaard GL. T-cell receptor gamma delta-positive peripheral T-cell lymphomas presenting in the skin: A clinical, histological and immunophenotypic study. *Experimental Dermatology*. 1992;**1**(1):31-36

[63] Yamamoto K, Matsuoka H, Yakushijin K, Funakoshi Y, Okamura A, Hayashi Y, et al. A novel five-way translocation, t(3;9;13;8;14)(q27;p13;q32;q24;q32), with concurrent MYC and BCL6 rearrangements in a primary bone marrow B-cell lymphoma. *Cancer Genetics*. 2011;**204**(9):501-506

[64] Kim YH, Willemze R, Pimpinelli N, Whittaker S, Olsen EA, Ranki A, et al. TNM classification system for primary cutaneous lymphomas other than mycosis fungoides and Sezary syndrome: A proposal of the International Society for Cutaneous Lymphomas (ISCL) and the cutaneous lymphoma task force of the European Organization of Research and Treatment of Cancer (EORTC). *Blood*. 2007;**110**(2):479-484

[65] Hoefnagel JJ, Vermeer MH, Jansen PM, Heule F, van Voorst Vader PC, Sanders CJ, et al. Primary cutaneous marginal zone B-cell lymphoma: Clinical and therapeutic features in 50 cases. *Archives of Dermatology*. 2005;**141**(9):1139-1145

[66] Arnulf B, Copie-Bergman C, Delfau-Larue MH, Lavergne-Slove A, Bosq J, Wechsler J, et al. Nonhepatosplenic gammadelta T-cell lymphoma: A subset of cytotoxic lymphomas with mucosal or skin localization. *Blood*. 1998;**91**(5):1723-1731

[67] Katoh A, Ohshima K, Kanda M, Haraoka S, Sugihara M, Suzumiya J,

et al. Gastrointestinal T cell lymphoma: Predominant cytotoxic phenotypes, including alpha/beta, gamma/delta T cell and natural killer cells. *Leukemia & Lymphoma*. 2000;**39**(1-2):97-111

[68] Al Omran S, Mourad WA, Ali MA. Gamma/delta peripheral T-cell lymphoma of the breast diagnosed by fine-needle aspiration biopsy. *Diagnostic Cytopathology*. 2002;**26**(3):170-173

[69] Scolnik MP, Burgos RA, Paz A, Weinreiter M, del Carmen Ardaiz M, Bare P, et al. Nonhepatosplenic gamma delta T-cell lymphoma with initial testicular compromise. *American Journal of Hematology*. 2000;**65**(3):260-262

[70] Tsujikawa T, Itoh A, Bamba M, Andoh A, Hodohara K, Inoue H, et al. Aggressive jejunal gamma delta T-cell lymphoma derived from intraepithelial lymphocytes: An autopsy case report. *Journal of Gastroenterology*. 1998;**33**(2):280-284

[71] Kumar S, Krenacs L, Medeiros J, Elenitoba-Johnson KS, Greiner TC, Sorbara L, et al. Subcutaneous panniculitic T-cell lymphoma is a tumor of cytotoxic T lymphocytes. *Human Pathology*. 1998;**29**(4):397-403

[72] Willemze R, Jansen PM, Cerroni L, Berti E, Santucci M, Assaf C, et al. Subcutaneous panniculitis-like T-cell lymphoma: Definition, classification, and prognostic factors: An EORTC cutaneous lymphoma group study of 83 cases. *Blood*. 2008;**111**(2):838-845

[73] Berti E, Cerri A, Cavicchini S, Delia D, Soligo D, Alessi E, et al. Primary cutaneous gamma/delta T-cell lymphoma presenting as disseminated pagetoid reticulosis. *The Journal of Investigative Dermatology*. 1991;**96**(5):718-723

[74] Go RS, Wester SM. Immunophenotypic and molecular

features, clinical outcomes, treatments, and prognostic factors associated with subcutaneous panniculitis-like T-cell lymphoma: A systematic analysis of 156 patients reported in the literature. *Cancer*. 2004;**101**(6):1404-1413

[75] Fujii M, Uehara J, Honma M, Ito Y, Takahashi H, Ishida-Yamamoto A, et al. Primary cutaneous gammadelta-T-cell lymphoma treated with low-dose methotrexate and narrowband ultraviolet B irradiation: Report of a case with testicular involvement. *The Journal of Dermatology*. 2011;**38**(4):368-372

[76] Mehta N, Wayne AS, Kim YH, Hale GA, Alvarado CS, Myskowski P, et al. Bexarotene is active against subcutaneous panniculitis-like T-cell lymphoma in adult and pediatric populations. *Clinical Lymphoma, Myeloma & Leukemia*. 2012;**12**(1):20-25

[77] Guitart J, Weisenburger DD, Subtil A, Kim E, Wood G, Duvic M, et al. Cutaneous gammadelta T-cell lymphomas: A spectrum of presentations with overlap with other cytotoxic lymphomas. *The American Journal of Surgical Pathology*. 2012;**36**(11):1656-1665

[78] Takeshita M, Imayama S, Oshiro Y, Kurihara K, Okamoto S, Matsuki Y, et al. Clinicopathologic analysis of 22 cases of subcutaneous panniculitis-like CD56- or CD56+ lymphoma and review of 44 other reported cases. *American Journal of Clinical Pathology*. 2004;**121**(3):408-416

[79] Ott MM, Ott G, Klinker H, Trunk MJ, Katzenberger T, Muller-Hermelink HK. Abdominal T-cell non-Hodgkin's lymphoma of the gamma/delta type in a patient with selective immunoglobulin A deficiency. *The American Journal of Surgical Pathology*. 1998;**22**(4):500-506

[80] Sandberg Y, Almeida J, Gonzalez M, Lima M, Barcena P, Szczepanski T, et al. TCRgammadelta+ large granular

lymphocyte leukemias reflect the spectrum of normal antigen-selected TCRgammadelta+ T-cells. *Leukemia*. 2006;**20**(3):505-513

[81] Bourgault-Rouxel AS, Loughran TP Jr, Zambello R, Epling-Burnette PK, Semenzato G, Donadieu J, et al. Clinical spectrum of gammadelta+ T cell LGL leukemia: Analysis of 20 cases. *Leukemia Research*. 2008;**32**(1):45-48

[82] Makishima H, Ishida F, Saito H, Ichikawa N, Ozaki Y, Ito S, et al. Lymphoproliferative disease of granular lymphocytes with T-cell receptor gamma delta-positive phenotype: Restricted usage of T-cell receptor gamma and delta subunit genes. *European Journal of Haematology*. 2003;**70**(4):212-218

[83] Chen YH, Chadburn A, Evens AM, Winter JN, Gordon LI, Chenn A, et al. Clinical, morphologic, immunophenotypic, and molecular cytogenetic assessment of CD4-/CD8-gammadelta T-cell large granular lymphocytic leukemia. *American Journal of Clinical Pathology*. 2011;**136**(2):289-299

[84] Osuji N, Matutes E, Catovsky D, Lampert I, Wotherspoon A. Histopathology of the spleen in T-cell large granular lymphocyte leukemia and T-cell prolymphocytic leukemia: A comparative review. *The American Journal of Surgical Pathology*. 2005;**29**(7):935-941

[85] Gentile TC, Uner AH, Hutchison RE, Wright J, Ben-Ezra J, Russell EC, et al. CD3+, CD56+ aggressive variant of large granular lymphocyte leukemia. *Blood*. 1994;**84**(7):2315-2321

[86] Vartholomatos G, Alymara V, Dova L, Kolaitis N, Bourantas KL. T-cell receptor gammadelta-large granular lymphocytic leukemia associated with an aberrant phenotype and TCR-Vbeta20 clonality. *Haematologica*. 2004;**89**(5):ECR16

- [87] Dhodapkar MV, Li CY, Lust JA, Tefferi A, Phyliky RL. Clinical spectrum of clonal proliferations of T-large granular lymphocytes: A T-cell clonopathy of undetermined significance? *Blood*. 1994;**84**(5):1620-1627
- [88] Shichishima T, Kawaguchi M, Ono N, Oshimi K, Nakamura N, Maruyama Y. Gammadelta T-cell large granular lymphocyte (LGL) leukemia with spontaneous remission. *American Journal of Hematology*. 2004;**75**(3):168-172
- [89] Takeuchi M, Tamaoki A, Soda R, Takahashi K. Spontaneous remission of large granular lymphocyte T cell leukemia. *Leukemia*. 1999;**13**(2):313-314
- [90] Lamy T, Loughran TP Jr. Clinical features of large granular lymphocyte leukemia. *Seminars in Hematology*. 2003;**40**(3):185-195
- [91] Osuji N, Matutes E, Tjonnfjord G, Grech H, Del Giudice I, Wotherspoon A, et al. T-cell large granular lymphocyte leukemia: A report on the treatment of 29 patients and a review of the literature. *Cancer*. 2006;**107**(3):570-578
- [92] Gentile TC, Loughran TP Jr. Resolution of autoimmune hemolytic anemia following splenectomy in CD3+ large granular lymphocyte leukemia. *Leukemia & Lymphoma*. 1996;**23**(3-4):405-408
- [93] Pandolfi F, Loughran TP Jr, Starkebaum G, Chisesi T, Barbui T, Chan WC, et al. Clinical course and prognosis of the lymphoproliferative disease of granular lymphocytes. A multicenter study. *Cancer*. 1990;**65**(2):341-348
- [94] Alekshun TJ, Tao J, Sokol L. Aggressive T-cell large granular lymphocyte leukemia: A case report and review of the literature. *American Journal of Hematology*. 2007;**82**(6):481-485
- [95] Charton-Bain MC, Brousset P, Bouabdallah R, Gaulard P, Merlio JP, Dubus P, et al. Variation in the histological pattern of nodal involvement by gamma/delta T-cell lymphoma. *Histopathology*. 2000;**36**(3):233-239
- [96] Ohno T, Komada F, Yamaguchi M, Oka K, Nishii K, Tsuda M, et al. Gamma/delta T-cell lymphoma with hepatosplenomegaly: Report of a case. *International Journal of Hematology*. 1993;**57**(3):269-276
- [97] Saito T, Matsuno Y, Tanosaki R, Watanabe T, Kobayashi Y, Tobinai K. Gamma delta T-cell neoplasms: A clinicopathological study of 11 cases. *Annals of Oncology*. 2002;**13**(11):1792-1798
- [98] Kagami Y, Nakamura S, Suzuki R, Yatabe Y, Okada Y, Kobayashi T, et al. A nodal gamma/delta T-cell lymphoma with an association of Epstein-Barr virus. *The American Journal of Surgical Pathology*. 1997;**21**(6):729-736