

We are IntechOpen, the world's leading publisher of Open Access books Built by scientists, for scientists

6,900

Open access books available

186,000

International authors and editors

200M

Downloads

Our authors are among the

154

Countries delivered to

TOP 1%

most cited scientists

12.2%

Contributors from top 500 universities



WEB OF SCIENCE™

Selection of our books indexed in the Book Citation Index
in Web of Science™ Core Collection (BKCI)

Interested in publishing with us?
Contact book.department@intechopen.com

Numbers displayed above are based on latest data collected.
For more information visit www.intechopen.com



The Role of MRI-TRUS Fusion Biopsy in the Diagnosis of Clinical Significant Prostate Cancer (CsPca)

*Benelli Andrea, Vaccaro Chiara, Guzzo Sonia,
Varca Virginia and Gregori Andrea*

Abstract

Despite its limitations, ultrasound-guided biopsy is still the “gold standard” for the diagnosis of prostate cancer (PCa). Multiparametric magnetic resonance imaging (mp-MRI) plays an increasingly important role in patients with prior negative biopsy; several studies report an improved clinically significant prostate cancer (Cs PCa) detection rate for MRI-targeted biopsy compared to the standard biopsy. There are currently three techniques for the MRI-targeted biopsy: the cognitive registration, the software-assisted fusion registration, and the in-bore biopsy. The best MRI-targeted biopsy technique is still a matter of debate in literature; however, MRI/TRUS fusion-guided biopsy is often described as the most accurate and cost-effective approach; we describe the technique and its results.

Keywords: fusion biopsy, prostate cancer, prostate biopsy, prostate magnetic resonance, PI-RADS score

1. Introduction

Prostate cancer is the most common cancer expected to occur in men, accounting for 19% of the new cancer cases diagnosed worldwide [1, 2].

Currently, the only way to make a definitive diagnosis of prostate cancer is considered to be the prostate biopsy and the subsequent histopathological examination. For many years, the transrectal ultrasound (TRUS)-guided biopsy has been considered the gold standard in the diagnosis of prostate adenocarcinoma. This standard technique makes use of random 12-cores to sample the entire prostate gland [3].

The criteria for submitting patients to prostate biopsy are either a persistently elevated/rising prostate-specific antigen (PSA) level or an abnormal digital rectal examination (DRE). Prostate biopsy may also be recommended on the basis of the pathologic results of previous biopsy specimens: men who are found to have a high-grade prostatic intraepithelial neoplasia (HG-PIN), atypical small acinar proliferation (ASAP), or low-risk prostate cancer should be subjected to a follow-up biopsy [2]. The TRUS-guided biopsy has significant limitations; several nonmalignant conditions of the prostate (such as inflammation, prostatitis, and benign prostatic

hyperplasia) can appear hypoechoic, and some carcinoma can appear isoechoic [4]. A cancer detection rate (DR) of 33–57% can be achieved with the standard biopsy, and following the first negative biopsy, the detection rate decreases further [5]. Furthermore, the standard biopsy may lead to an underdiagnosis of clinically significant prostate cancers, missing 50–80% of cases [6]. The multiparametric magnetic resonance imaging plays nowadays an increasingly important role in the diagnostic approach to prostate cancer. It provides anatomic and functional images allowing detection and localization of the suspicious lesions that could harbor prostate cancer.

Several studies indicate that the MRI-targeted biopsy approach improves the overall and clinically significant PCa detection rate. It also strongly reduces the number of clinically insignificant prostate cancers diagnosed, therefore preventing overtreatment.

According to the European Association of Urology (EAU) guidelines, an mp-MRI evaluation and a subsequent MRI-targeted biopsy should be recommended for patients with persistent clinical suspicion of prostate cancers even if a previous standard biopsy has provided negative results. Based on the guideline recommendations, if the targeted and standard biopsies are used in conjunction, significantly better results can be achieved [7].

The role of mp-MRI in the diagnostic pathway of biopsy-naïve patients is instead still a matter of debate.

2. Technology and techniques

2.1 Interpretation and reporting of multiparametric MRI

The magnetic resonance imaging (MRI) has been used for locoregional staging in patients with proven prostate cancers since the 1980s [8]. The multiparametric protocol has been introduced to discriminate nonmalignant tissue and potentially cancerous lesions. Since its introduction, the field of PCa diagnosis has been revolutionized.

According to the European Society of Urogenital Radiology (ESUR) guidelines, the multiparametric MRI protocol should include three MRI modalities: triplanar T2-weighted (T2W) sequences, axial diffusion-weighted imaging (DWI) with apparent diffusion coefficient (ADC) mapping, and dynamic contrast-enhanced images (DCE) [8, 9].

To standardize the evaluation and reporting of prostate mp-MRI examinations, a consensus-based guideline, known as Prostate Imaging Reporting and Data System (PI-RADS) version 1, was introduced in 2012. Most recently, a revised version of the document (PI-RADS v2) was published.

One of the main aims of the PI-RADS v2 document was to develop categories summarizing the levels of suspicion; each detected lesion in the prostate gland is assigned a score that goes from 1 to 5. The 5-point scoring, based on the likelihood that MRI findings correlate with the presence of Cs PCa, is defined as follows:

1. very low risk (clinically significant PCa is highly unlikely to be present)
2. low risk (clinically significant PCa is unlikely to be present)
3. intermediate risk (the presence of clinically significant PCa is equivocal)

- 4. high risk (clinically significant PCa is likely to be present)
- 5. very high risk (clinically significant PCa is highly likely to be present)

According to PI-RADS v2, a cancer is considered to be clinically significant when Gleason score (GS) >7, and/or tumor volume >0.5 ml, and/or an extraprostatic extension is diagnosed [8, 9].

A meta-analysis related to the diagnostic accuracy of PI-RADS v2 shows that the PCa detection sensitivity is 0.85 and the specificity is 0.71 [10].

The most significant difference between PI-RADS v1 and PI-RADS v2 is that DWI and T2W are used as the primary determining sequences, respectively, for peripheral zone (PZ) and transitional zone (PZ) (refer to **Tables 1** and **2**), while DCE plays a limited role in the detection of PZ lesions classified as PI-RADS 3. Likewise, when a TZ lesion has a T2W score 3, DWI may increase the likelihood that the finding corresponds to a score 4.

Another significant difference is that a size criterion (smaller or larger than 1.5 cm) is taken into account by PI-RADS v2 to differentiate score 4 from 5 in both the peripheral and transitional zones. Moreover, a 39-sector map has been introduced to locate the suspicious findings [8, 9]. This has led to an improvement of the interdisciplinary communications between radiologists and urologists.

Following the PI-RADS score assignment to the suspicious lesion, the region of interest (ROI) detected through mp-MRI can be biopsied to confirm the diagnosis.

DWI score	Peripheral zone lesion	PI-RADS category
1	No abnormality on ADC and high b-value DWI	1
2	Indistinct hypointense on ADC	2
3	Focal mildly/moderately hypointense on ADC and isointense/mildly hyperintense on high b-value DWI	3 if DCE is negative 4 if DCE is positive
4	Focal markedly hypointense on ADC and markedly hyperintense on high b-value DWI; <1.5 cm in greatest dimension	4
5	Same as 4, but >1.5 cm in greatest dimension or definite extraprostatic extension/invasive behavior	5

Table 1.
PI-RADS v2 categories assignment to peripheral zone lesions based on the scoring of DWI sequence.

T2W score	Transition zone lesion	PI-RADS category
1	Homogeneous intermediate signal intensity (normal)	1
2	Circumscribed hypointense or heterogeneous encapsulated nodules	2
3	Heterogeneous signal intensity with obscured margins Includes others that do not qualify as 2, 4, or 5	3 if DWI score is <4 4 if DWI score is 5
4	Lenticular or noncircumscribed, homogeneous, moderately hypointense, and <1.5 cm in greatest dimension	4
5	Same as 4, but >1.5 cm in greatest dimension or definite extraprostatic extension/invasive behavior	5

Table 2.
PI-RADS v2 categories assignment to transitional zone lesions based on the scoring of T2W sequence.

Several studies recommend that the MRI-targeted biopsy be performed for findings classified as PI-RADS 4 and 5 [11–13]. According to the ESUR guidelines, biopsy for PI-RADS 3 lesions may or may not be appropriate. Clinical factors should be considered for lesions pertaining to this category. For findings with PI-RADS 1 or 2, biopsy is not recommended [8, 9].

2.2 Methods of MRI-targeted biopsy

There are currently three techniques for the MRI-targeted biopsy: the cognitive registration, the software-assisted fusion registration and the in-bore biopsy [14–17]. This paragraph provides an overview of the pro and cons of these techniques (Table 3).

In the cognitive registration, also known as visual registration, a prebiopsy mp-MRI is performed to localize the suspicious lesions. The targeted biopsy is then performed using TRUS guidance with the objective of estimating the area where the lesion is [14, 15].

Despite its low cost, the cognitive registration technique is strictly operator-dependent and is more prone to errors when compared to the other techniques. In addition, with this technique it is not possible to track the location of each biopsy core [15, 18].

In the software-assisted fusion registration, known as MRI/TRUS fusion-guided biopsy, the region of interest is identified in the mp-MRI images. Through a specific software platform, the MRI images are fused with the real-time ultrasound images [14, 17, 19].

The targeted prostate biopsy based on mp-MRI and TRUS imaging combine the advantages of both techniques, i.e., the superior sensitivity of MRI for targeting suspicious lesions and the practicality of TRUS [5, 18]. The greater reproducibility, high precision, and lower operator dependence represent some of the main advantages of the MRI/TRUS fusion-guided biopsy [17].

Various fusion platforms are currently registered by the Food and Drug Administration (FDA), which differ with respect to image registration (rigid or elastic), tracking (electromagnetic tracking, mechanical position encoders, and image-based software tracking) and biopsy approaches (transrectal or transperineal) [19].

In our institution the MRI/TRUS fusion-guided biopsy is performed in an outpatient setting; we use the BioJet system (DK Technologies GmbH) which is one of the most approved systems by the FDA [19] (Figure 1).

Techniques	Advantages	Disadvantages
Cognitive registration	<ul style="list-style-type: none">• Low cost• Additional training not required	<ul style="list-style-type: none">• Operator-dependent• Less accurate
MRI/TRUS fusion-guided biopsy	<ul style="list-style-type: none">• High precision• Less operator-dependent	<ul style="list-style-type: none">• Additional software platform required• Specialized operators required
In-bore biopsy	<ul style="list-style-type: none">• High precision	<ul style="list-style-type: none">• Few sampled cores can be taken• Specialized MRI equipment and operators required• High cost• Long time required

Table 3. Comparison between the three techniques for the MRI-targeted biopsy.

T2 traversal MRI images are used to contour the prostate and the lesions; then, the system fuses the marked MRI images with live transrectal ultrasound on both the axial and sagittal image planes to guarantee the best needle placement.

During the biopsy procedure, the TRUS probe is fixed to a stepper provided with position sensors that transmit the exact position of the probe to the software.

The location of biopsy cores can be tracked and recorded on a 3D map of the prostate, and a report of the cores collected is provided at the end of the procedure; it guarantees reproducible re-biopsies which is a very important advantage particularly for patients in active surveillance (**Figures 2–5**).

The system supports both transrectal and transperineal biopsies depending on the surgeon preference; the transperineal route with patients placed in lithotomy position is our preferred approach. All biopsy samples are obtained after a local anesthesia with 2% lidocaine and ropivacaine. At least three biopsy cores from each lesion are taken. Standard 12-core biopsies from the lateral and medial aspects of the base, mid, and apical prostate are taken during the same procedure.

With the in-bore biopsy technique the target lesion is biopsied with the patient placed in a fixed position inside the mp-MRI scanner.

Unlike the MRI/TRUS fusion-guided biopsy, the in-bore biopsy procedure is performed and tracked under MRI fluoroscopy guidance; real-time ultrasound images are not used. A transrectal, transperineal or transgluteal approach can be used during the in-bore biopsy [14, 15].

One of the main advantages of this technique is the high precision of the targeted cores as the high-quality MRI images provide a visual feedback of the biopsy needle localization [12, 15, 16]. However, the significant time required in the MRI scanner and the availability of specialized MRI equipment make the costs associated with this technique higher than the others [14–16].

Even if the determination of the most effective MRI-targeted biopsy technique is still a matter of debate in literature, some authors have concluded that the MRI/

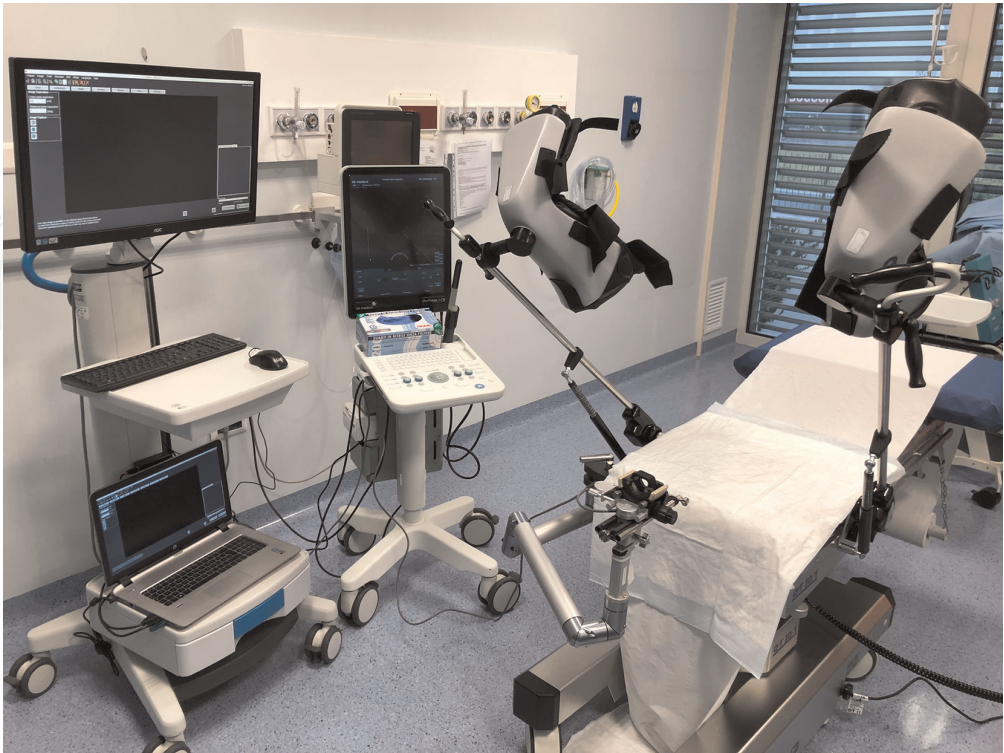

Figure 1.
Biojet system.

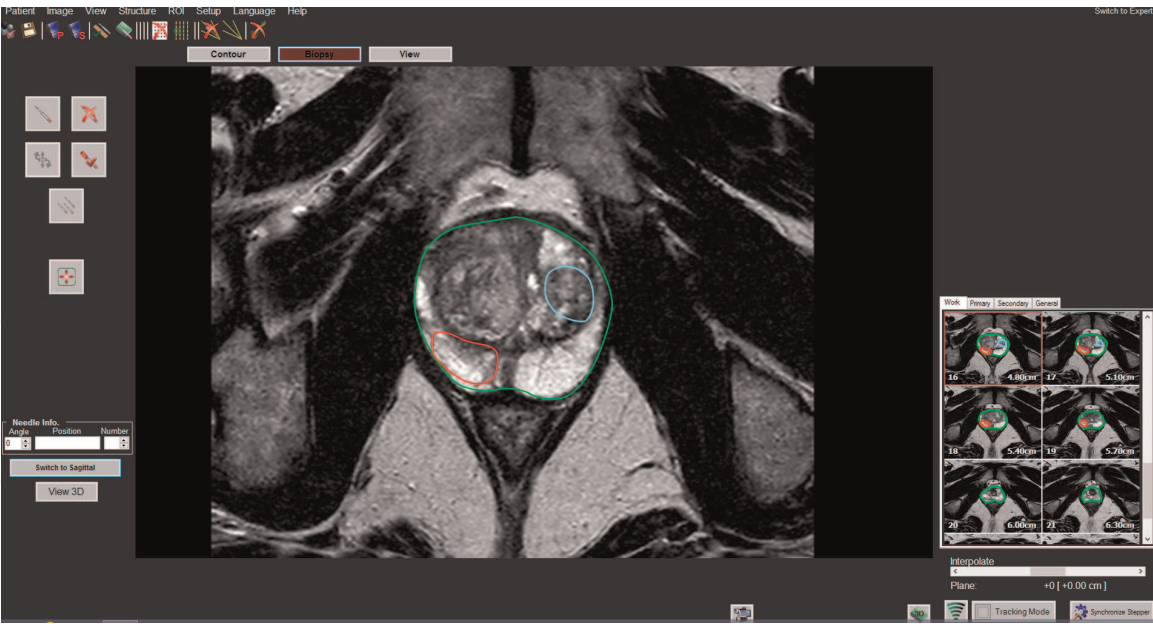


Figure 2.
Lesions contour.

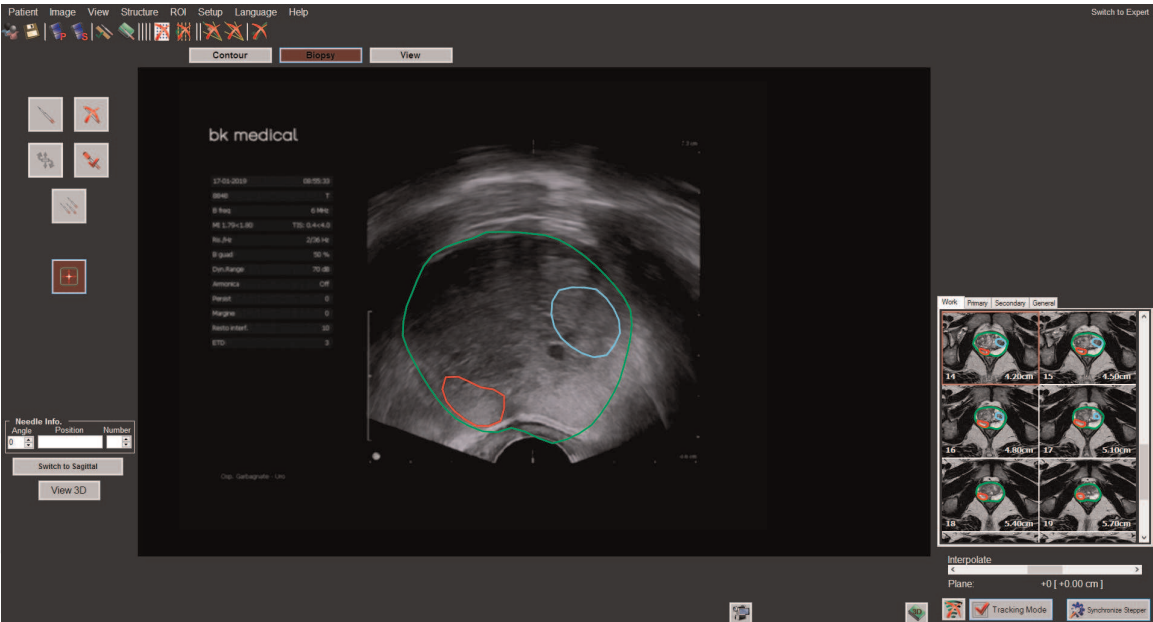


Figure 3.
Fusion process trasverse.

TRUS fusion-guided biopsy is much more accurate and cost-effective than the other techniques [3, 14, 20–22].

Oberlin et al. have recently compared the MRI/TRUS fusion biopsy with the cognitive approach. About 231 patients have been enrolled in the study. The study shows that the targeted biopsy has a greater overall detection rate for prostate cancer (48.1 vs. 34.6%) and clinically significant PCa when compared with cognitive registration [20]. Similar results were obtained by Cool that performed a study on 100 patients with the objective of comparing targeted biopsy accuracies of cognitive registration using 2D or 3D TRUS guidance with MRI/TRUS fusion biopsy. The detection rate of cognitive registration, with both 2D and 3D TRUS probe, appears to be lower than that achieved through the MRI/TRUS fusion biopsy, with less than 50% of the clinically significant PCa successfully sampled (48 and 45%, respectively, for 2D and 3D TRUS). Even when the Cs PCa is successfully

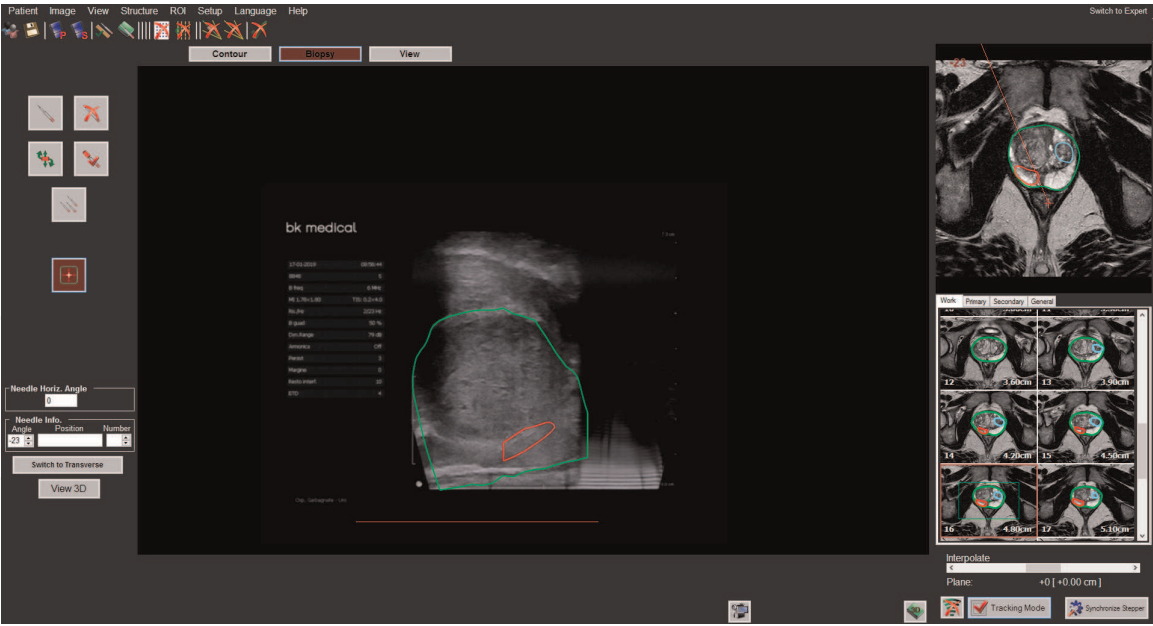

Figure 4.
Fusion process sagittal.

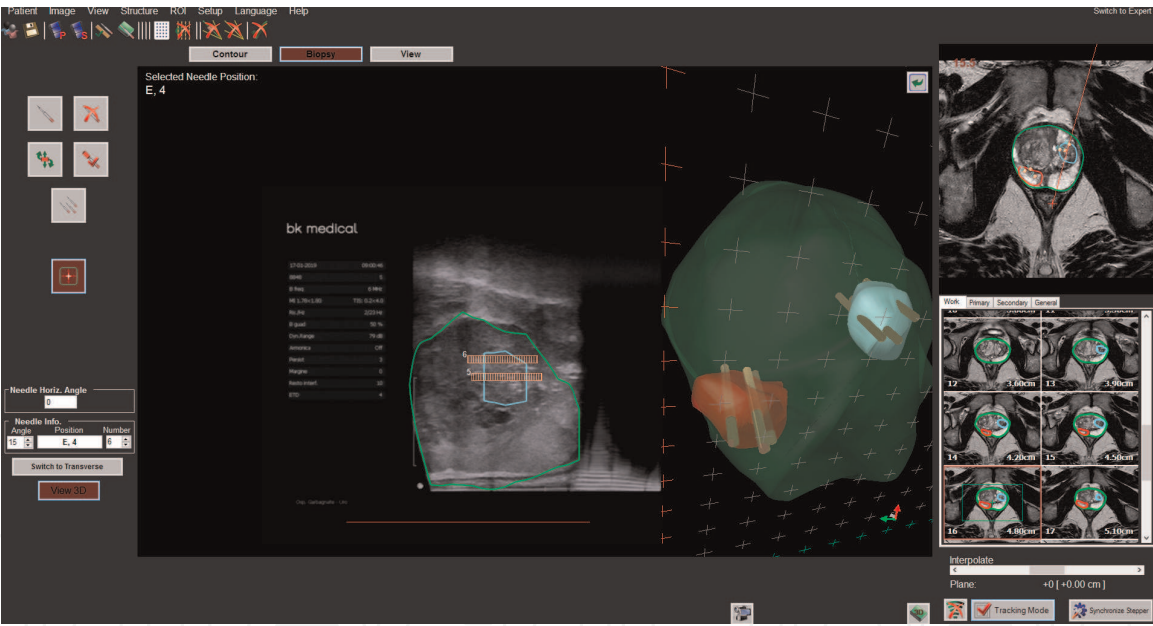


Figure 5.
Biopsy.

sampled by cognitive registration, the percentage of cancerous tissue detected by the MRI/TRUS fusion biopsy in each biopsy core was significantly higher [21].

A randomized trial was carried out on 210 patients to compare the MRI/TRUS fusion biopsy and the in-bore technique [23]. No significant difference in the overall and Cs PCa detection rates was observed between the two groups; the first constituted of 104 patients that were subjected to fusion biopsy (39 and 32%, respectively, for the PCa and Cs PCa detection rate), while an in-bore biopsy was performed on the other 106 patients (37 and 29%, respectively, for the PCa and Cs PCa detection rate). This is in agreement with the study performed by Vanderink et al. according to which there is no significant difference in the detection rate between the two biopsy techniques [24].

It should be noted however that, due to its significant costs, the in-bore technique is less commonly adopted than visual registration and fusion biopsy.

2.3 Route of biopsy

The route of prostate biopsy (transrectal, transperineal, or transgluteal) may differ between the various operators, but the transrectal (TR) and transperineal (TP) are the two primary approaches through which the prostate tissue can be taken [15, 16].

The TP biopsy is performed with the patient in the lithotomy position with the needle passing through the perineum skin; the TR biopsy is instead performed in the left lateral decubitus with the knees and hips flexed 90° and the needle passing through the anterior rectal wall [25].

Both the TP and TR biopsies are very effective in diagnosing PCa and provide a superimposable detection rate. However, the TP approach allows a better sampling of the lesions located in the anterior part of the gland, therefore resulting in a greater percentage of PCa of the anterior zone compared with the TR approach (86.7 vs. 46.7%) [26, 27].

Even if there is no significant difference between the TP and TR biopsies in terms of the overall complication rate, rectal bleeding and infection-related complications are more frequently observed when adopting the TR approach [25, 26, 28, 29]. As the access to the prostate is via the rectal mucosa, the TR biopsy increases the likelihood of introducing rectal flora into the urinary tract and the blood circulation. Most of the reported infections result from *Escherichia coli* [29]. The overall risk of infectious complications, including bacteriuria, bacteremia, fever, urinary tract infections and sepsis may be up to 6.3% [15, 28].

The likelihood of infections may be reduced by adopting the TP biopsy approach [15, 28]. To further minimize infectious complications, patients are required to have antibiotic prophylaxis [28].

According to the EAU guidelines, quinolones are recommended as the first-line option: ciprofloxacin is prescribed in more than 90% of cases. Although no different outcomes were observed between oral and systemic administration, a single oral dose is usually preferred. In the event of antimicrobial resistance to quinolones, alternative antibiotics of choice are cephalosporins and aminoglycosides [28].

On the other hand, pain management is more challenging with the TP approach [26]. The average VAS score, used to measure the symptom severity and pain control, is higher than that related to the TR biopsy. To ensure pain control, the TP biopsy is usually performed under local anesthesia of both the perineum skin and the periprostatic region [25, 26, 29].

Another issue to consider is that the TP-targeted biopsy is a relatively complex procedure requiring a longer learning curve.

In conclusion, the choice of the biopsy method depends on several factors, such as lesion localization, patients' risk factors, operators' preference, and technique availability.

3. Outcomes

3.1 Overall results

Urologists frequently face the dilemma of patients with a negative prostate biopsy and an elevated PSA value or a suspicious digital rectal examination (DRE) [2].

Prior to the introduction of the MRI/TRUS fusion biopsy, patients with negative TRUS-guided biopsies were regularly subjected to multiple biopsy procedures. This approach resulted in a higher detection rate of insignificant low-grade tumors,

therefore increasing overtreatment. The MRI/TRUS fusion biopsy is considered to be a significant enhancement through which the weaknesses of the systematic random biopsy can be overcome. Through the use of the mp-MRI for the identification of suspicious lesions and the execution of the subsequent targeted biopsy, a greater number of prostate cancers can be detected [3, 6, 30–34].

The most significant strength of the targeted biopsy, when compared to the standard technique, is related to its improved detection capability of Cs PCas needing a definitive treatment. Another advantage relates to the possibility of avoiding biopsy for patients with a normal mp-MRI therefore reducing the detection of clinically insignificant cancers and preventing overtreatment of indolent tumors.

A summary of the results in terms of the overall and Cs PCa detection rates in the available literature is provided in **Table 4**. The systematic review performed by Valerio et al. is aimed to compare the standard and MRI/TRUS fusion biopsy in terms of detection rate and efficiency [3]. The overall detection rate reported is 43.4 and 50.5%, respectively, whereas the detection rate for clinically significant PCa is 23.6 and 33.3%, respectively. The above study also shows that a considerable number of Cs PCas can be detected only if a targeted biopsy is performed, particularly if the anatomical locations of cancer are the transition zone and the anterior fibromuscular stroma [35].

Moreover, according to Valerio et al., fewer core samples (9.2 vs. 37.2%) are required to detect the same number of clinically significant cancers making the targeted approach less uncomfortable for patients [3].

In another study involving more than 1000 patients, Siddiqui et al. show that the standard and targeted biopsies have diagnosed a similar number of prostate cancers (469 vs. 461). The significant difference highlighted is that the MRI/TRUS fusion biopsy has diagnosed a greater percentage (+30%) of high-risk cancers and a lower percentage (–17%) of low-risk cancers than the standard biopsy [30]. Similar results were obtained by other recent studies [12, 13, 35–37].

However, the diagnostic accuracy of the MRI/TRUS fusion-guided biopsy does not allow the prostate standard biopsy to be avoided: the combined execution of the standard and targeted biopsy will result in the detection of a greater number of PCa cases [30, 36, 38].

The most significant predictive factor for the detection of prostate cancers through the targeted biopsy is the ROI grade. As several studies have demonstrated, the likelihood of diagnosing clinically significant PCas increases with the PI-RADS score, i.e., the greater is the PI-RADS score, the higher is the probability of detecting PCas [12, 13, 36, 37, 39, 40].

The study performed by Borkowetz et al., including 625 patients subjected to standard and MRI/TRUS fusion-guided biopsies, shows that PCa was detected in 20, 33 and 70% of patients with PI-RADS 3, 4 and 5 lesions, respectively [37].

These results are consistent with the data recently published by Kasivisvanathan and Cash [13, 39]. In particular, the Cs PCa detection rates resulting from the latter study were 16.8, 46.1 and 84.7%, respectively, for PI-RADS categories 3, 4 and 5 [39]. Based on the above, the ESUR guidelines recommend that an MRI-targeted biopsy be performed in patients with PI-RADS 4 and 5 lesions [8, 9]. The management of PI-RADS 3 lesions still remains a challenge. An mp-MRI presenting PI-RADS 3 lesions should be assessed considering clinical parameters such as PSA density (PSAD) and total PSA value [36, 33]. An increased PSA density, i.e., the PSA level related to the total prostate volume, is considered to be the most significant clinical predictive factor for prostate cancers. Some studies recommend that the patient should be subjected to targeted biopsy if the PSA density >0.10 ng/ml/cc [33].

Method	Study	Definition for Cs PCa	Sample size	Overall DR	DR Cs PCa	DR PI-RADS 3 (Cs PCa)	DR PI-RADS 4 (Cs PCa)	DR PI-RADS 5 (Cs PCa)
Cognitive registration	Puech et al. [51]	$GS \geq 3 + 4$	95	47%	NR	NR	NR	NR
	Delongchamps et al. [52]	$CCL \geq 5$ mm or $GS \geq 3 + 4$	127	74.1%	NR	NR	NR	NR
	Wysock et al. [53]	$GS \geq 3 + 4$	125	26.7%	15.1%	NR	NR	NR
	Cool et al. [21]	$GS \geq 3 + 4$ or tumor involvement in the core >50%	100	NR	48% (2D TRUS) 45% (3D TRUS)	NR	NR	NR
	Oberlin et al. [20]	$GS \geq 3 + 4$	150	34.6%	16.7%	NR	NR	NR
	John et al. [22]	$GS \geq 3 + 4$	131	NR	17.6%	40.7% (11.1%)	67.9% (42.9%)	69.5% (35.6%)
	Osses et al. [54]	$GS \geq 3 + 4$	64	56.2%	NR	16.7%	68.7%	95.2%
In-bore biopsy	Pokorny et al. [55]	NR	142	56.4%	NR	10.5%	69.9%	
	Kaufmann et al. [56]	$GS \geq 3 + 4$, PSA >10 ng/ml and PSAD >0.15 ng/ml/cm ³	35	46%	46%	NR	NR	NR
	Quentin et al. [57]	$CCL > 5$ mm or $GS \geq 3 + 4$	128	53.1%	45.3%	NR	NR	NR
	Arsov et al. [23]	$GS \geq 3 + 4$	106	37%	29%	NR	NR	NR
	Penzkofer et al. [58]	$GS \geq 3 + 4$	87	56.7%	27.8%	NR	NR	NR
	Felker et al. [59]	$GS \geq 3 + 4$	461	37.3%	27.9%	16.4% (10.4%)	57.8% (42.7%)	96.3% (84%)
	Schimmoller et al. [60]	$GS \geq 3 + 4$	148	49.8%	41.1%	NR	NR	NR
	Tan et al. [61]	$GS \geq 3 + 4$	106	53.7%	36.6%	19.4% (9.7%)	78% (54%)	82.8% (62.1%)
	Vanderink et al. [24]	$GS \geq 3 + 4$	227	85%	61.2%	NR	72.7% (49.4%)	91.3% (67.3%)
	Osses et al. [54]	$GS \geq 3 + 4$	155	64.5%	NR	10.3%	77.4%	88.9%

Method	Study	Definition for Cs PCa	Sample size	Overall DR	DR Cs PCa	DR PI-RADS 3 (Cs PCa)	DR PI-RADS 4 (Cs PCa)	DR PI-RADS 5 (Cs PCa)
MRI/TRUS fusion-guided biopsy	Kuru et al. [62]	NCCN criteria	347	50.6%	41.1%	NR	NR	NR
	Rastinehad et al. [63]	Epstein criteria	105	50.5%	44.8%	NR	NR	NR
	Wysock et al. [53]	$GS \geq 3 + 4$	125	32%	20.3%	NR	NR	NR
	Sonn et al. [18]	$CCL \geq 4$ mm or $GS \geq 3 + 4$	105	34%	25%	NR	NR	NR
	Valerio et al. [3]	NR	2293	50.5%	33.3%	NR	NR	NR
	Shoji et al. [64]	$CCL > 4$ mm or $GS \geq 3 + 4$	20	31.8%	NR	13.3%	33.3%	88.9%
	Junker et al. [34]	NR	50	46%	NR	28.6%	54.3%	100%
	Borkowetz et al. [31]	Epstein criteria	263	44.1%	35.7%	24.2%	41.6%	
	Mozer et al. [46]	$CCL > 4$ mm or $GS \geq 3 + 4$	152	53.9%	43.4%	NR	NR	NR
	Siddiqui et al. [30]	NR	1003	46%	37.5%	NR	NR	NR
	Salami et al. [35]	Epstein criteria	140	52.1%	47.9%	26.7%	66.7%	95.8%
	Oberlin et al. [20]	$GS \geq 3 + 4$	81	48.1%	28.6%	NR	NR	NR
	Cash et al. [39]	$CCL \geq 4$ mm or $GS \geq 3 + 4$	408	56%	NR	26% (16.8%)	62% (46.1%)	89% (84.7%)
	Filson et al. [36]	$GS \geq 3 + 4$	1042	43.6%	27.8%	NR (16%)	NR (33%)	NR (69%)
	Borkowetz et al. [37]	$GS \geq 3 + 4$	625	43%	34%	20% (12%)	33% (27%)	70% (61%)
	Tan et al. [33]	$GS \geq 3 + 4$	115	35.7%	30.4%	21.4% (15.7%)	52.9% (47.1%)	72.7% (72.7%)
	Hansen et al. [65]	$GS \geq 3 + 4$	487	51.1%	30.6%	43.7% (19.5%)	58% (32%)	82.6% (70.4%)
	Osses et al. [32]	$GS \geq 3 + 4$	664	64.5%	40.6%	10.3% (3.5%)	77.3% (45.2%)	88.9% (66.7%)
	Boesen et al. [12]	Epstein criteria	206	33.8%	26.4%	22.2%	62.7%	94.1%

Method	Study	Definition for Cs PCa	Sample size	Overall DR	DR Cs PCa	DR PI-RADS 3 (Cs PCa)	DR PI-RADS 4 (Cs PCa)	DR PI-RADS 5 (Cs PCa)
	Porpiglia et al. [44]	Epstein criteria	212	60.5%	56.8%	12.5% (12.5%)	80% (75%)	87.5% (81.3%)
	Hofbauer et al. [40]	GS ≥ 3 + 4	704	63%	45%	39% (23%)	72% (49%)	91% (77%)
	Kasivisvanathan et al. [13]	GS ≥ 3 + 4	252	47%	38%	34% (12%)	69% (60%)	94% (83%)
Our results	Epstein criteria	352	50.9%	36.5%	38.2% (15.9%)	63.7% (44.9%)	86.5% (74.2%)	

MRI, magnetic resonance imaging; Cs PCa, clinically significant prostate cancer; DR, detection rate; PI-RADS, prostate imaging reporting and data system; GS, Gleason score; NR, not reported; CCL, maximum cancer core length; PSA, prostate-specific antigen; PSAD, prostate-specific antigen density; NCCN, National Comprehensive Cancer Network.

Table 4.
Biopsy procedure results published in literature.

Another issue to consider is that, prior to the introduction of the MRI/TRUS fusion biopsy, literature did not describe a strong concordance between biopsy and radical prostatectomy Gleason score (GS). A significant pathological GS (pGS) upgrading, when compared with that of standard biopsy specimens (bGS), was observed in 50% of patients, while up to 80% of patients were downgraded [41, 42].

As the GS is a significant decision-making tool for patient treatment, its correct attribution is absolutely essential [2, 41].

With the introduction of the MRI/TRUS fusion biopsy, a high consistency between bGS and pGS has been achieved. Its accuracy in predicting the pathological GS allows minimizing the risk of possible cancer upgradings or downgradings [37, 42].

The MRI/TRUS fusion biopsy superior performance has been demonstrated by Porpiglia. About 246 patients subjected to robot-assisted RP were enrolled. For 91.5% of patients the anatomopathological results of surgical specimens were consistent with those achieved through biopsy cores. Also, with the targeted biopsy, the GS upgrading and downgrading was 7.8 and 0.8%, respectively, significantly lower than the rates achieved with the standard biopsy (39.3 and 6.8%, respectively) [42].

3.2 Naïve-biopsy patients

The current guidelines of the European Association of Urology and National Institute for Health and Care Excellence (NICE) recommend that an mp-MRI evaluation and a subsequent targeted biopsy be performed in patients with a persistent clinical suspicion of PCa (elevated PSA level and/or abnormal DRE) after a previous negative biopsy [7, 43].

The use of mp-MRI as the primary diagnostic tool for biopsy-naïve patients is controversial. However, recent studies support the excellent performance of mp-MRI in the detection of PCa in biopsy-naïve patients [30, 38, 44–46].

A clinical trial was recently performed with 212 biopsy-naïve patients randomly assigned to either the targeted or the standard biopsy group. Results shows that targeted biopsy provides a greater detection rate for both PCa (50.5 vs. 29.5%) and clinically significant PCa (43.9 vs. 18.1%) [44]. These results agree with those achieved by a multicentric trial involving 214 biopsy-naïve patients with at least one suspicious lesion detected through mp-MRI [38].

Although further confirmation is required, men who have never been biopsied before may benefit from the use of mp-MRI as a preliminary test. In case of a positive MRI, the combined execution of MRI/TRUS fusion and standard biopsies would then be recommended and improve the detection of CsPca [38, 45].

A critical issue to consider are the economic resources required if the MRI were used as the primary diagnostic tool in all patients with clinical suspicious of PCa. Nevertheless, recent analyses have shown that mp-MRI for the initial detection of PCa appears to be cost-effective when compared with repeated standard biopsies [38, 45].

3.3 Patients on active surveillance

Active surveillance (AS) is the strategy of choice in men with localized and very low/low-risk prostate cancer to avoid or delay treatment that might not be immediately necessary [47–49].

Even if there is still no definitive agreement with regard to the selection criteria for AS candidates, a widely accepted criteria is based on the following: clinical T1c or T2a, PSA <10 ng/ml, fewer than two to three positive cores with <50% cancer

involvement of every positive core, and GS 3 + 3 [7]. Patients fulfilling this criteria may benefit from AS, reducing treatment-related complications without compromising their survival.

AS consists of a close disease monitoring through clinical and histological parameters: commonly used tools are serial PSA measurements, DRE, and repeat biopsies [2, 7]. If biochemical or histological evidence of cancer progression is observed, a radical treatment will then be proposed [2, 47, 48].

The main limitation associated with the AS protocol is the risk of underestimating the extent and aggressiveness of prostate cancer. Some authors have reported that TRUS-guided biopsies may lead to an underestimation in one third of cases [47, 48, 50].

mp-MRI is currently emerging as a significant diagnostic tool through which the above risk can be minimized. It can be used in one of the three following stages: at the time of initial diagnosis of men with low-risk cancer, before confirmatory biopsy and during follow-up [49].

At the time of initial diagnosis, the mp-MRI is much more accurate in the identification and characterization of prostate cancers, resulting in a more accurate patients enrollment for the AS protocol. Its use is recommended to rule out significant PCas that were missed by the initial biopsy.

Before the confirmatory biopsy, usually performed within the first year from the initial diagnosis, the mp-MRI can reveal the need to perform a targeted biopsy in addition to the commonly adopted standard biopsy. The combined use of these two techniques may lead to a more accurate evidence of disease progression [47–49]. This is in line with the review performed by Schoots et al. [48] according to which the combined execution of targeted and standard biopsies resulted in 27% cancer upgrading. It is therefore recommended that both biopsy techniques be adopted at the stage of the confirmatory biopsy [48, 49].

During the follow-up period, a yearly mp-MRI might allow the annual biopsy to be avoided for those patients with stable MRI findings. The repeat biopsy should be performed only in the event that a disease progression is detected by the mp-MRI [47]. It should be noted however that there is still no definitive agreement on the use of the mp-MRI as a replacement for the repeat biopsy during the follow-up period [49].

Key points

- For many years the TRUS-guided biopsy has been considered as the gold standard in the diagnosis of PCa. Even if the ultrasound-based imaging is a great tool for guiding a biopsy needle, it cannot identify regions of interest that could harbor PCa in all cases. This is the reason why in the last decade, the research activities have focused on the development of imaging methods that can differentiate between noncancerous tissue and malignant lesions with greater accuracy.
- The introduction of mp-MRI as an imaging modality for the detection and localization of regions of interest has nowadays revolutionized the way through which PCa is managed and treated. According to the ESUR guidelines, the mp-MRI protocol should include T2W, DWI, and DCE sequences.
- PI-RADS v2 was introduced by the ESUR to standardize the evaluation and reporting of mp-MRI examinations. This 5-point scoring system is based on the likelihood that MRI findings correlate with the presence of Cs PCa.

- According to the EAU guidelines, an mp-MRI followed by an MRI-targeted biopsy should be recommended for patients with persistent clinical suspicion of prostate cancer (elevated PSA level and/or abnormal DRE) after a previous negative standard biopsy.
- mp-MRI is currently emerging as a significant diagnostic tool in patients on active surveillance protocol both for the enrollment of patients with low-risk indolent disease and before the confirmatory biopsy.
- The role of mp-MRI in the management of biopsy-naïve patients is still a matter of debate. However, its diagnostic accuracy is such that recent studies support the use of mp-MRI as a preliminary test in patients with no prior biopsies.
- The cognitive registration, software-assisted fusion registration, and in-bore biopsy are the techniques currently available for the MRI-targeted biopsy. The MRI/TRUS fusion-guided biopsy appears to be the most accurate and cost-effective approach when compared with other biopsy procedures.
- A greater number of prostate cancers can be diagnosed through the MRI-targeted biopsy, resulting in an increased overall detection rate. The great advantage of this technique is that it increases the detection rate of Cs PCas, reducing the detection of clinically insignificant cancers.
- The MRI-targeted biopsy has been shown to be more accurate in predicting the pathological GS, providing a strong consistency between bGS and pGS. The rate of a possible cancer underestimation or overestimation is therefore minimized.

Acknowledgements

Funder: TECNOGAMMA snc; Corso Lombardia 75; San Mauro Torinese; Italy.

Conflict of interest

The authors declares that there is no conflict of interest.

IntechOpen

IntechOpen

Author details

Benelli Andrea*, Vaccaro Chiara, Guzzo Sonia, Varca Virginia and Gregori Andrea
Department of Urology, ASST Rhodense, G. Salvini Hospital, Milan, Italy

*Address all correspondence to: abenelli@asst-rhodense.it

IntechOpen

© 2019 The Author(s). Licensee IntechOpen. This chapter is distributed under the terms of the Creative Commons Attribution License (<http://creativecommons.org/licenses/by/3.0>), which permits unrestricted use, distribution, and reproduction in any medium, provided the original work is properly cited. 

References

- [1] Siegel R, Miller K, Jemal A. Cancer statistics, 2018. *CA: A Cancer Journal for Clinicians*. 2018;**69**:7-34
- [2] Wein A, Kavoussi L, Partin A, Peters C. *Campbell-Walsh Urolog*. 10th ed. Saunders: Elsevier; 2012
- [3] Valerio M, Donaldson I, Emberton M, et al. Detection of clinically significant prostate cancer using magnetic resonance imaging-ultrasound fusion targeted biopsy: A systematic review. *European Urology*. 2015;**68**:8-19
- [4] Sarkar S, Das S. A review of imaging methods for prostate cancer detection. *Biomedical Engineering and Computational Biology*. 2016;**7**(S1):1-15
- [5] Gayet M, van der Aa A, Beerlage HP, et al. The value of magnetic resonance imaging and ultrasonography (MRI/US)-fusion biopsy platforms in prostate cancer detection: A systematic review. *BJU International*. 2016;**117**:392-400
- [6] Wu J, Ji A, Xie B, et al. Is magnetic resonance/ultrasound fusion prostate biopsy better than systematic prostate biopsy? An updated meta- and trial sequential analysis. *Oncotarget*. 2015;**6**(41):43571-43580
- [7] Mottet NN, Bellmunt J, Bolla M, et al. EAU-ESTRO-SIOG guidelines on prostate cancer. Part 1: Screening, diagnosis, and local treatment with curative intent. *European Urology*. 2017;**71**(4):618-629
- [8] Weinreb JC, Barentsz JO, Choyke PL, et al. PI-RADS prostate imaging - reporting and data system: 2015, version 2. *European Urology*. 2016;**69**:16-40
- [9] Barentsz J, Weinreb J, Verma S, et al. Synopsis of the PI-RADS v2 guidelines for multiparametric prostate magnetic resonance imaging and recommendations for use. *European Urology*. 2016;**69**:41-49
- [10] Zhang L, Tang M, Chen S, et al. A meta-analysis of use of prostate imaging reporting and data system version 2 (PI-RADS V2) with multiparametric MR imaging for the detection of prostate cancer. *European Radiology*. 2017;**27**(12):5204-5214
- [11] Rosenkrantz A, Verma A, Choyke P, et al. Prostate magnetic resonance imaging and magnetic resonance imaging targeted biopsy in patients with a prior negative biopsy: A consensus statement by AUA and SAR. *The Journal of Urology*. 2016;**196**:1616-1618
- [12] Boesen L, Nørgaard N, Løgager V, et al. A prospective comparison of selective multiparametric magnetic resonance imaging fusion-targeted and systematic transrectal ultrasound-guided biopsies for detecting prostate cancer in men undergoing repeated biopsies. *Urologia Internationalis*. 2017;**99**:384-391
- [13] Kasivisvanathan V, Rannikko A, Borghi M, et al. MRI-targeted or standard biopsy for prostate-cancer diagnosis. *The New England Journal of Medicine*. 2018;**278**(19):1767-1777
- [14] Giganti F, Moore C. A critical comparison of techniques for MRI-targeted biopsy of the prostate. *Translational Andrology and Urology*. 2017;**6**(3):432-443
- [15] Kongnyuy MM, George AKA, Rastinehad A, Pinto P. Magnetic resonance imaging-ultrasound fusion-guided prostate biopsy: Review of technology, techniques, and outcomes. *Current Urology Reports*. 2016;**17**(4):32
- [16] Robertson N, Emberton M, Moore C. MRI-targeted prostate biopsy: A

review of technique and results. *Nature Reviews. Urology*. 2013;**10**:589-597

[17] Bjurlin M, Rosenkrantz A, Taneja S. MRI-fusion biopsy: The contemporary experience. *Translational Andrology and Urology*. 2017;**6**(3):483-489

[18] Sonn G, Margolis D, Marks L. Target detection: Magnetic resonance imaging-ultrasound fusion-guided prostate biopsy. *Urologic Oncology*. 2014;**32**(6): 903-911

[19] Tewes S, Hueper K, Hartung D, et al. Targeted MRI/TRUS fusion-guided biopsy in men with previous prostate biopsies using a novel registration software and multiparametric MRI PI-RADS scores: First results. *World Journal of Urology*. 2015;**33**:1707-1714

[20] Oberlin D, Casalino D, Miller F, et al. Diagnostic value of guided biopsies: Fusion and cognitive-registration magnetic resonance imaging versus conventional ultrasound biopsy of the prostate. *Urology*. 2016;**92**: 75-79

[21] Cool D, Zhang X, Romagnoli C, et al. Evaluation of MRI-TRUS fusion versus cognitive registration accuracy for MRI-targeted, TRUS-guided prostate biopsy. *AJR*. 2015;**204**:83-91

[22] John S, Cooper S, Breau R, et al. Multiparametric magnetic resonance imaging-transrectal ultrasound-guided cognitive fusion biopsy of the prostate: Clinically significant cancer detection rates stratified by the prostate imaging and data reporting system version 2 assessment categories. *Canadian Urological Association Journal*. 2018; **12**(12):401-406

[23] Arsov C, Rabenalt R, Blondin D, et al. Prospective randomized trial comparing magnetic resonance imaging (MRI)-guided in bore biopsy to MRI-ultrasound fusion and transrectal ultrasound-guided prostate biopsy in

patients with prior negative biopsy. *European Urology*. 2015;**68**:713-720

[24] Venderink W, van der Leest M, van Luijckelaar A, et al. Retrospective comparison of direct in-bore magnetic resonance imaging (MRI)-guided biopsy and fusion-guided biopsy in patients with MRI lesions which are likely or highly likely to be clinically significant prostate cancer. *World Journal of Urology*. 2017;**35**:1849-1855

[25] Guo L, Wu R, Xu H, et al. Comparison between ultrasound guided transperineal and transrectal prostate biopsy: A prospective, randomized, and controlled trial. *Scientific Reports*. 2015;**5**:16089

[26] Tewes S, Peters I, Tiemeyer A, et al. Evaluation of MRI/ultrasound fusion-guided prostate biopsy using transrectal and transperineal approaches. *BioMed Research International*. 2017:2176471

[27] Pepe P, Garufi A, Priolo G, Pennisi M. Multiparametric MRI/TRUS fusion prostate biopsy: Advantages of a transperineal approach. *Anticancer Research*. 2017;**37**:3291-3294

[28] Ploussard G, Scattoni V, Giannarini G, Jones J. Approaches for initial prostate biopsy and antibiotic prophylaxis. *European Urology*. 2015;**1**: 109-116. *Focus*

[29] Loeb S, Vellekoop A, Ahmed H, et al. Systematic review of complications of prostate biopsy. *European Urology*. 2013;**64**:876-892

[30] Siddiqui M, Rais-Bahrami S, Turkbey B, et al. Comparison of MR/ultrasound fusion-guided biopsy with ultrasound-guided biopsy for the diagnosis of prostate cancer. *Journal of the American Medical Association*. 2015; **313**(4):390-397

[31] Borkowetz A, Platzek I, Toma M, et al. Comparison of systematic

transrectal biopsy to transperineal magnetic resonance imaging/ultrasound-fusion biopsy for the diagnosis of prostate cancer. *BJU International*. 2015;**116**:873-879

[32] Osses D, van Asten J, Kleef G, Tijsterman J. Prostate cancer detection rates of magnetic resonance imaging-guided prostate biopsy related to prostate imaging reporting and data system score. *World Journal of Urology*. 2017;**35**:207-212

[33] Tan T, Siang Png K, Lee C, et al. MRI fusion-targeted transrectal prostate biopsy and the role of prostate-specific antigen density and prostate health index for the detection of clinically significant prostate cancer in southeast asian men. *Journal of Endourology*. 2017;**31**(11):1111-1116

[34] Junker D, Schäfer G, Heidegger I, et al. Multiparametric magnetic resonance imaging/transrectal ultrasound fusion targeted biopsy of the prostate: Preliminary results of a prospective single-Centre study. *Urologia Internationalis*. 2015;**94**: 313-318

[35] Salami S, Ben-Levi E, Yaskiv O, et al. In patients with a previous negative prostate biopsy and a suspicious lesion on magnetic resonance imaging, is a 12-core biopsy still necessary in addition to a targeted biopsy? *BJU International*. 2015;**115**: 562-570

[36] Filson C, Natarajan S, Margolis D, et al. Prostate cancer detection with magnetic resonance-ultrasound fusion biopsy: The role of systematic and targeted biopsies. *Cancer*. 2016;**122**: 884-892

[37] Borkowetz A, Platzek I, Toma M, et al. Evaluation of prostate imaging reporting and data system classification in the prediction of tumor aggressiveness in targeted magnetic resonance

imaging/ultrasound-fusion biopsy. *Urologia Internationalis*. 2017;**99**(2): 177-185

[38] Borkowetz A, Hadaschik B, Platzek I, et al. Prospective comparison of transperineal magnetic resonance imaging/ultrasonography fusion biopsy and transrectal systematic biopsy in biopsy-naïve patients. *BJU International*. 2018;**121**:53-60

[39] Cash H, Maxeiner A, Stephan C, et al. The detection of significant prostate cancer is correlated with the prostate imaging reporting and data system (PI-RADS) in MRI/transrectal ultrasound fusion biopsy. *World Journal of Urology*. 2016;**34**:252-232

[40] Hofbauer S, Kittner B, Maxeiner A, et al. Validation of PI-RADS version 2 for the detection of prostate cancer. *The Journal of Urology*. 2018;**200**(4):767-773

[41] Grasso A, Cozzi G, Palumbo C, et al. Concordance between biopsy and radical prostatectomy specimen Gleason score in internal external pathology facilities. *Anticancer Research*. 2014;**34**: 5585-5588

[42] Porpiglia F, De Luca S, Passera R, et al. Multiparametric-magnetic resonance/ultrasound fusion targeted prostate biopsy improves agreement between biopsy and radical prostatectomy Gleason score. *Anticancer Research*. 2016;**36**: 4833-4840

[43] Graham J, Kirkbride P, Cann K, et al. Prostate cancer: Summary of updated NICE guidance. *BMJ*. Jun 8, 2014;**348**:f7524

[44] Porpiglia F, Manfredi M, Mele F, et al. Diagnostic pathway with multiparametric magnetic resonance imaging versus standard pathway: Results from a randomized prospective study in biopsy-naïve patients with

suspected prostate cancer. *European Urology*. 2017;**72**:282-288

[45] Maxeiner A, Kittner B, Blobel C, et al. Primary magnetic resonance imaging/ultrasonography fusion-guided biopsy of the prostate. *BJU International*. 2018;**122**(2):211-218

[46] Mozer P, Roupert M, Le Cossec C, et al. First round of targeted biopsies using magnetic resonance imaging/ultrasonography fusion compared with conventional transrectal ultrasonography-guided biopsies for the diagnosis of localised prostate cancer. *BJU International*. 2015;**115**:50-57

[47] Barrett T, Haider M. The emerging role of MRI in prostate cancer active surveillance and ongoing challenges. *AJR - Genitourinary Imaging*. 2017;**208**: 131-139

[48] Schoots I, Nieboer D, Giganti F, et al. Is magnetic resonance imaging-targeted biopsy a useful addition to systematic confirmatory biopsy in men on active surveillance for low-risk prostate cancer? A systematic review and meta-analysis. *BJU International*. 2018;**122**(6):946-958

[49] Briganti A, Fossati N, Catto J, et al. Active surveillance for low-risk prostate cancer: The European Association of Urology position in 2018. *European Urology*. 2018;**74**:357-368

[50] Ma T, Tosoian J, Schaeffer E, et al. The role of multiparametric magnetic resonance imaging/ultrasound fusion biopsy in active surveillance. *European Urology*. 2017;**71**:174-180

[51] Puech P, Rouviere O, Renard-Penna R, et al. Prostate cancer diagnosis: Multiparametric MR-targeted biopsy with cognitive and transrectal US-MR fusion guidance versus systematic biopsy - prospective multicentre study. *Radiology*. 2013;**268**:461-469

[52] Delongchamps N, Peyromaure M, Schull A, et al. Prebiopsy magnetic resonance imaging and prostate cancer detection: Comparison of random and targeted biopsies. *The Journal of Urology*. 2013;**189**:493-499

[53] Wysock J, Rosenkrantz A, Huang W, et al. A prospective, blinded comparison of magnetic resonance (MR) imaging-ultrasound fusion and visual estimation in the performance of MR-targeted prostate biopsy: The PROFUS trial. *European Urology*. 2014;**66**:343-351

[54] Osses D, van Asten J, Tijsterman J. Cognitive-targeted versus magnetic resonance imaging-guided prostate biopsy in prostate cancer detection. *Current Urology*. 2017;**11**:182-188

[55] Pokorny M, de Rooij M, Duncan E, et al. Prospective study of diagnostic accuracy comparing prostate cancer detection by transrectal ultrasound-guided biopsy versus magnetic resonance (MR) imaging with subsequent MR-guided biopsy in men without previous prostate biopsies. *European Urology*. 2014;**66**:22-29

[56] Kaufmann S, Kruck S, Kramer U, et al. Direct comparison of targeted MRI-guided biopsy with systematic transrectal ultrasound-guided biopsy in patients with previous negative prostate biopsies. *Urologia Internationalis*. 2015;**94**(3):319-325

[57] Quentin M, Blondin D, Arsov C, et al. Prospective evaluation of MRI-guided in-bore prostate biopsy versus systematic transrectal ultrasound transrectal ultrasound guided prostate biopsy in biopsy-naïve men with elevated prostate-specific antigen levels. *The Journal of Urology*. 2014;**192**(5): 1374-1379

[58] Penzkofer T, Tuncali K, Fedorov A, et al. Transperineal in-bore 3-T MR imaging-guided prostate biopsy: A

- prospective clinical observational study. *Radiology*. 2015;**274**(1):170-180
- [59] Felker E, Lee-Felker S, Fel J, et al. In-bore magnetic resonance-guided transrectal biopsy for the detection of clinically significant prostate cancer. *Abdominal Radiology*. 2016;**41**(5): 954-962
- [60] Schimmöller L, Blondin D, Arsov C, et al. MRI-guided in-bore biopsy: Differences between prostate cancer detection and localization in primary and secondary biopsy settings. *AJR - Genitourinary Imaging*. 2016;**206**:92-99
- [61] Tan N, Lin W, Khoshnoodi P, et al. In-bore 3-T MR-guided transrectal targeted prostate biopsy: Prostate imaging reporting and data system version 2 - based diagnostic performance for detection of prostate cancer. *Radiology*. 2017;**283**(1):130-139
- [62] Kuru T, Roethke M, Seidenar J, et al. Critical evaluation of magnetic resonance imaging targeted, transrectal ultrasound guided transperineal fusion biopsy for detection of prostate cancer. *The Journal of Urology*. 2013;**190**: 1380-1386
- [63] Rastinehad A, Turkbey B, Salami S, et al. Improving detection of clinically significant prostate cancer: Magnetic resonance imaging/transrectal ultrasound fusion guided prostate biopsy. *The Journal of Urology*. 2014; **191**:1749-1754
- [64] Shoji S, Hiraiwa S, Endo J, et al. Manually controlled targeted prostate biopsy with real-time fusion imaging of multiparametric magnetic resonance imaging and transrectal ultrasound: An early experience. *International Journal of Urology*. 2015;**22**:173-178
- [65] Hansen N, Kesch C, Barre T, et al. Multicentre evaluation of targeted and systematic biopsies using magnetic resonance and ultrasound image-fusion guided transperineal prostate biopsy in patients with a previous negative biopsy. *BJU International*. 2017;**120**: 631-638