

# We are IntechOpen, the world's leading publisher of Open Access books Built by scientists, for scientists

6,900

Open access books available

186,000

International authors and editors

200M

Downloads

Our authors are among the

154

Countries delivered to

TOP 1%

most cited scientists

12.2%

Contributors from top 500 universities



WEB OF SCIENCE™

Selection of our books indexed in the Book Citation Index  
in Web of Science™ Core Collection (BKCI)

Interested in publishing with us?  
Contact [book.department@intechopen.com](mailto:book.department@intechopen.com)

Numbers displayed above are based on latest data collected.  
For more information visit [www.intechopen.com](http://www.intechopen.com)



# Breast Recontouring

*Yueh-Bih Tang, Shihheng Chen and Yo-Shen Chen*

## Abstract

The breast is an important structure of the human body in terms of function and esthetics. Derangements in breast mount—breast form/volume/profile/silhouette and nipple-areolar complex—size/shape/nipple projection are all concerns for not only females but also males. Simply esthetic problems of breasts encompass hypoplasia, atrophy, displacement of nipple-areolar complex, widened areola, redundant nipple, breast ptosis, macromastia, etc. Congenital anomalies of breast—Poland syndrome, pectus excavatum, pectus carinatum, etc.—all need to be taken care for restructuring of the body contour. Nowadays, breast cancer of different stages may need different reconstruction modality. Postmastectomy breast reconstruction is another big issue for plastic surgeons. This chapter on breast recontouring will address on every specific kind of breast contour disorders and imperfection, along with individualized strategies of refining, restoring, and reconstruction approaches.

**Keywords:** breast, recontouring, reshaping, reconstruction

## 1. Augmentation of breast

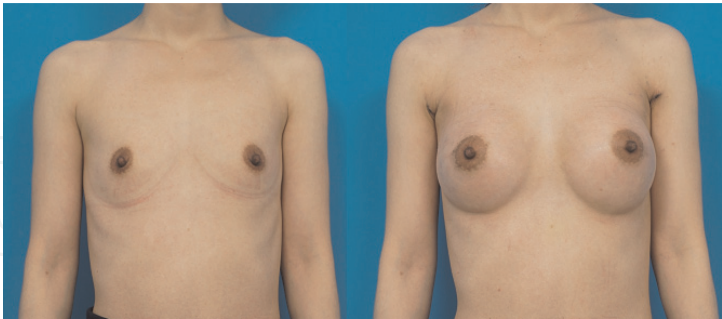### 1.1 Augmentation of breasts with implants

1. A 34-year-old lady with breast hypoplasia received augmentation of breasts (275 ml on both sides) (**Figures 1–3**) [1].
2. A 38-year-old lady with atrophy of breasts after breast feeding received augmentation of breasts with 300 ml gel implant on each side (**Figure 4**).
3. A 26-year-old lady with hypoplasia of breasts; right side is a little smaller. Dark areola is also complained. After breast augmentation with gel implants, 200 ml in each side, areolar hyperpigmentation was greatly alleviated (**Figures 5 and 6**).

### 1.2 Augmentation of breasts with fat graft injection

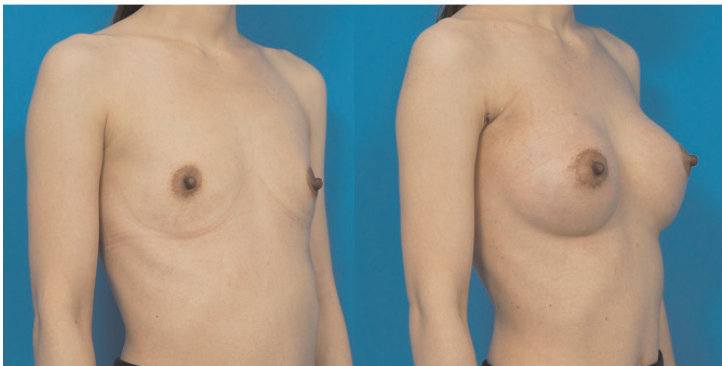
1. A 25-year-old unmarried lady wished to have a more prominent breast profile; aspiration of abdominal fat for lipofilling of breasts 150 ml for each side was performed (**Figures 7–9**).

Breast Hypoplasia—Breast Augmentation  
with Implant  
Pre-op Post-op 3 M



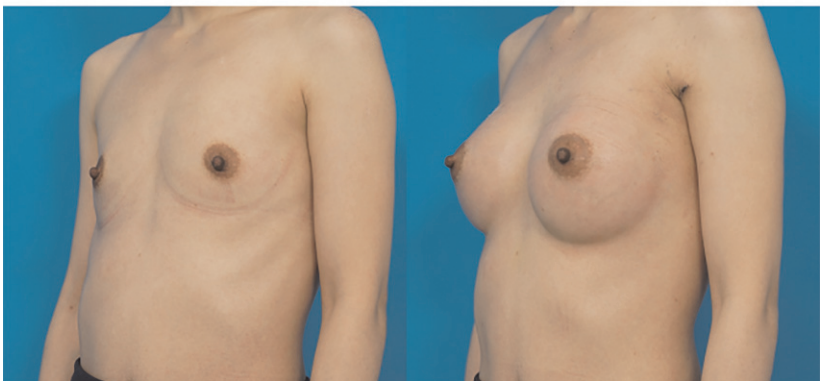**Figure 1.**  
*Front view; left, pre-op; right, post-op; after breast augmentation with 275 ml gel breast implants.*

Breast Hypoplasia—Breast Augmentation  
with Implant  
Pre-op Post-op 3 M

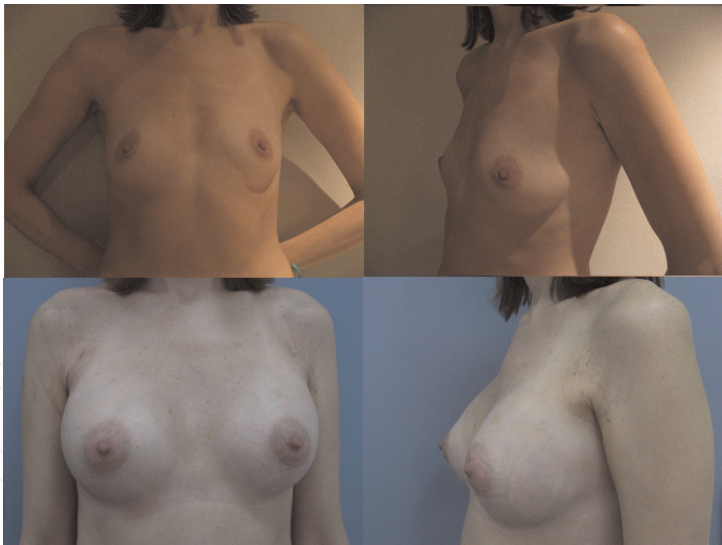


**Figure 2.**  
*Three-quarter view; left, pre-op; right, post-op.*

Breast Hypoplasia—Breast Augmentation  
with Implant  
Pre-op Post-op 3 M

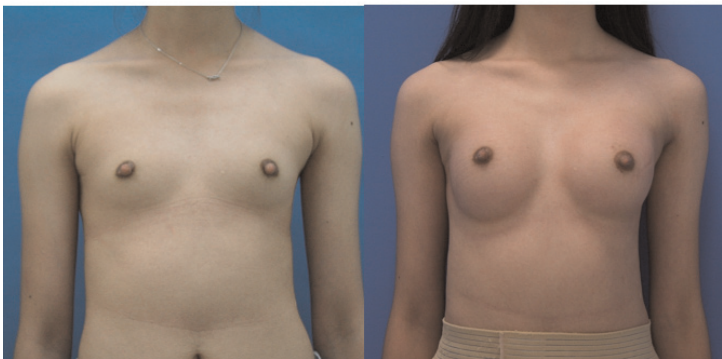

**Figure 3.**  
*Three-quarter view; left, pre-op; right, post-op.*



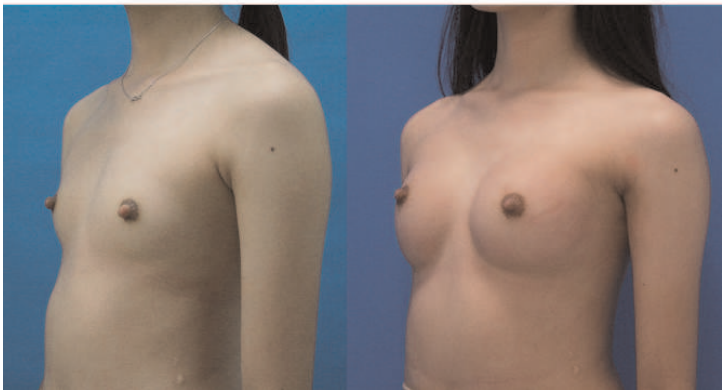**Figure 4.**  
*Breast atrophy. Upper row, pre-op; lower row, breast augmentation with 300 ml gel implants at both sides.*

Breast Hypoplasia  
Augmentation with 200 ml gel implant  
Pre-op                      Post-op



**Figure 5.**  
*Left, pre-op; right, post-op.*

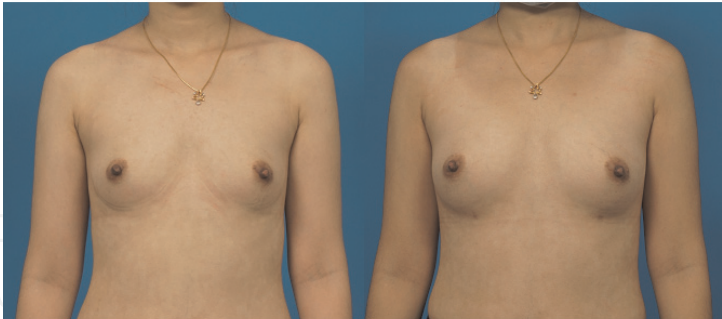Breast Hypoplasia  
Augmentation with 200 ml gel implant  
Pre-op                      Post-op



**Figure 6.**  
*Three-quarter view. Left, pre-op; right, post-op.*

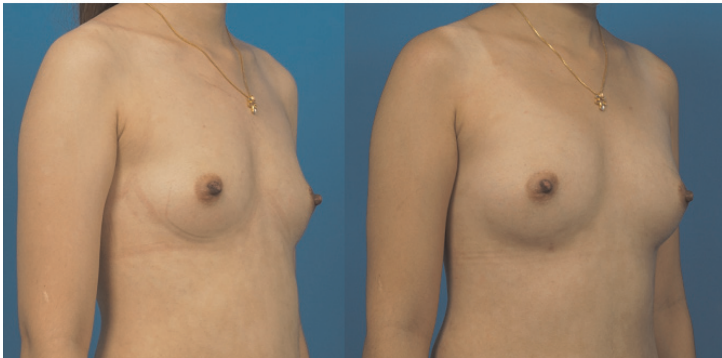


Breast Atrophy--Fat Graft Breast Augmentation  
Pre-op                      Post-op 4M



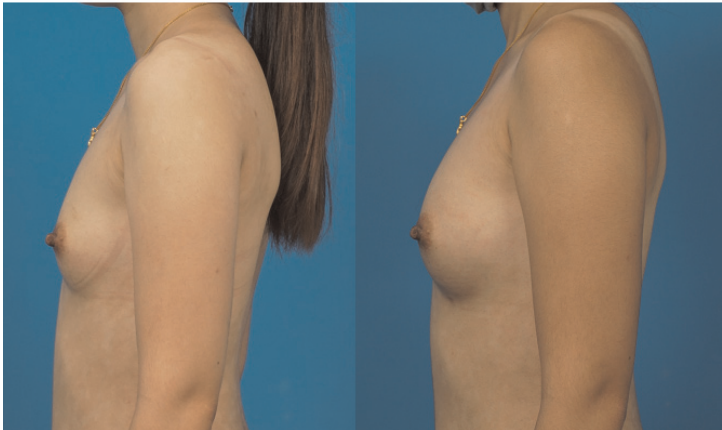
**Figure 7.**  
*Front view. Left, pre-op; right, 4 months post-op.*

Breast Atrophy--Fat Graft Breast Augmentation  
Pre-op                      Post-op 4M



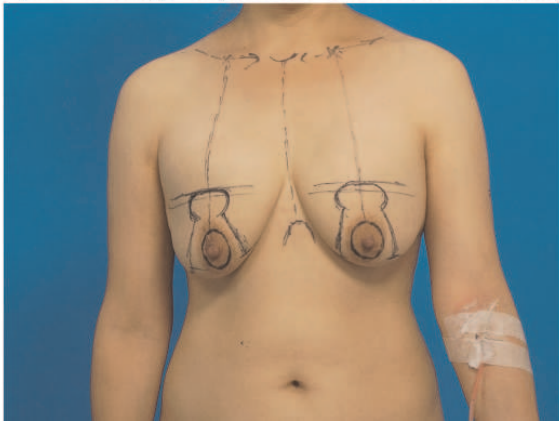
**Figure 8.**  
*Three-quarter view; left, pre-op; right, 4 months post-op.*

Breast Atrophy--Fat Graft Breast Augmentation  
Pre-op                      Post-op 4M



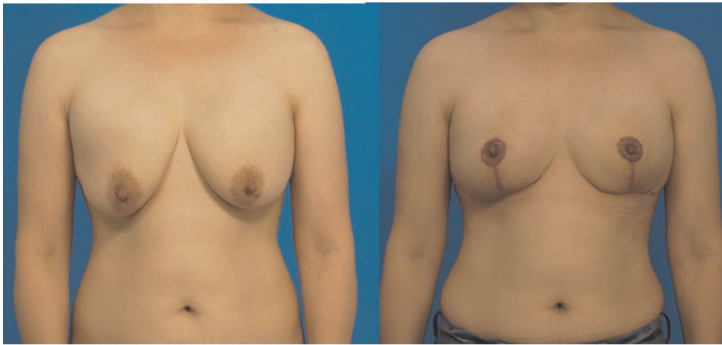**Figure 9.**  
*Lateral view; left, pre-op; right, post-op.*

Breast Implant Capsular Contracture and Upward  
Displacement  
Capsulectomy, Implant Removal, Mastopexy



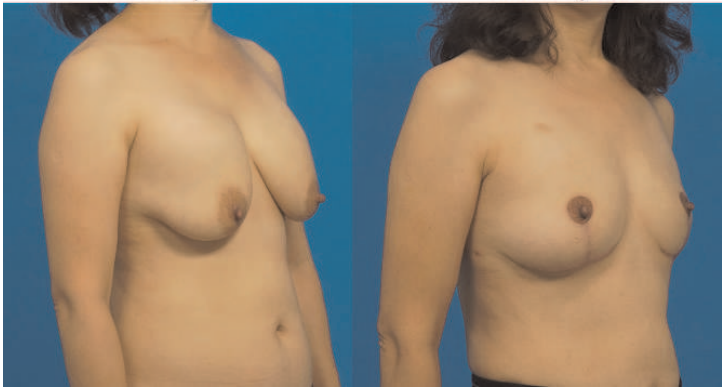**Figure 10.**  
*Pre-op, upward displacement of augmented breasts with capsular contracture resulting in ptosis of breasts and displacement of nipple-areolar complex.*

Before                      After 5M

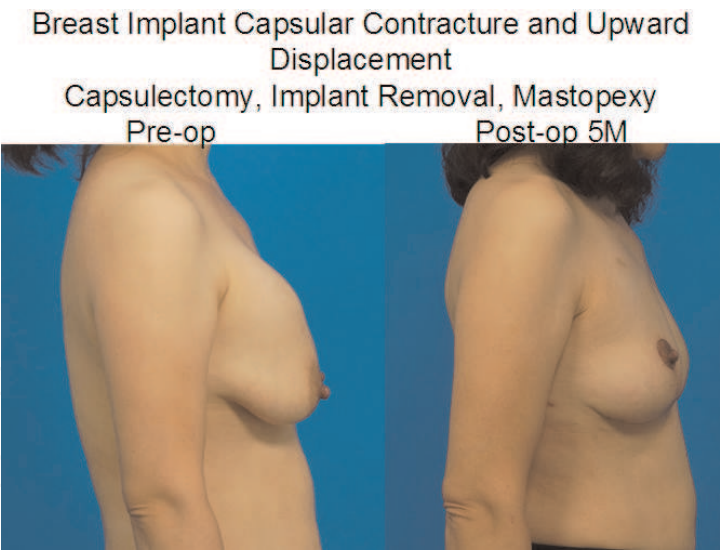


**Figure 11.**  
*Front view; left, pre-op; right, post-op.*

Breast Implant Capsular Contracture and Upward  
Displacement  
Capsulectomy, Implant Removal, Mastopexy  
Pre-op                      Post-op 5M



**Figure 12.**  
*Three-quarter view; left, pre-op; right, post-op.*



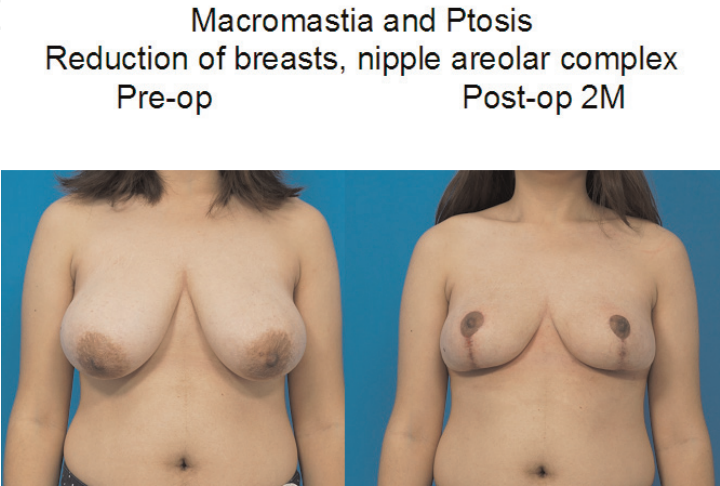
**Figure 13.**  
*Lateral view; left, pre-op; right, post-op.*

2. A 43-year-old lady with upward displacement of augmented breasts with capsular contracture [2] resulting in ptosis of breasts and displacement of nipple-areolar complex.

She received removal of breast prostheses and surrounding capsules with mastopexy and reduction and reposition of nipple-areolar complex (**Figures 10–13**).

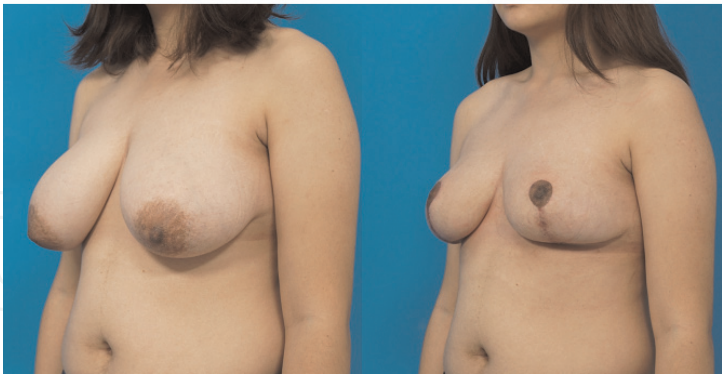
## 2. Reduction of hypertrophic breasts

1. A 20-year-old young lady, suffered from bilateral macromastia and received reduction of breasts with inferior pedicle technique (**Figures 14–16**) [3, 4].
2. A 41-year-old lady, augmentation of breasts at lower pole with gel implant and reduction with elevation and refinement of nipple-areolar complex (**Figures 17–19**).



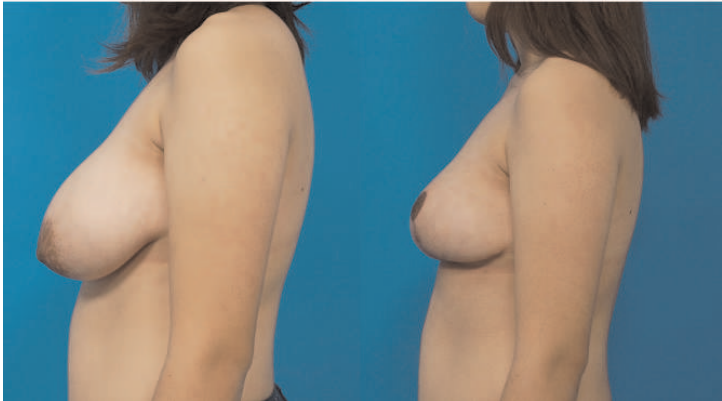**Figure 14.**  
*Macromastia. Front view; left, pre-op; right, post-op.*

Macromastia and Ptosis  
Reduction of breasts, nipple areolar complex  
Pre-op                      Post-op 2M



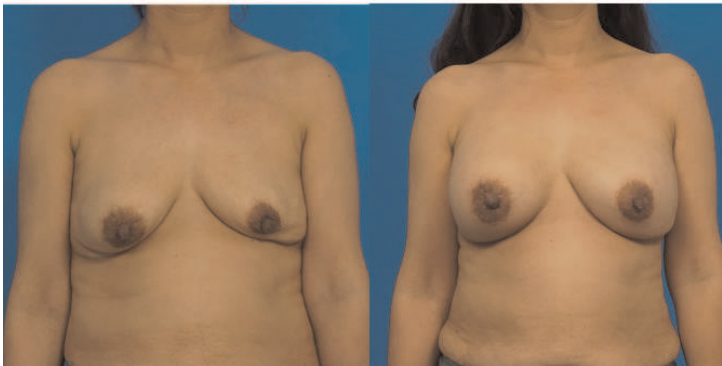**Figure 15.**  
*Macromastia. Three-quarter view; left, pre-op; right, post-op.*

Macromastia and Ptosis  
Reduction of breasts, nipple areolar complex  
Pre-op                      Post-op 2M



**Figure 16.**  
*Macromastia. Lateral view; left, pre-op; right, post-op.*

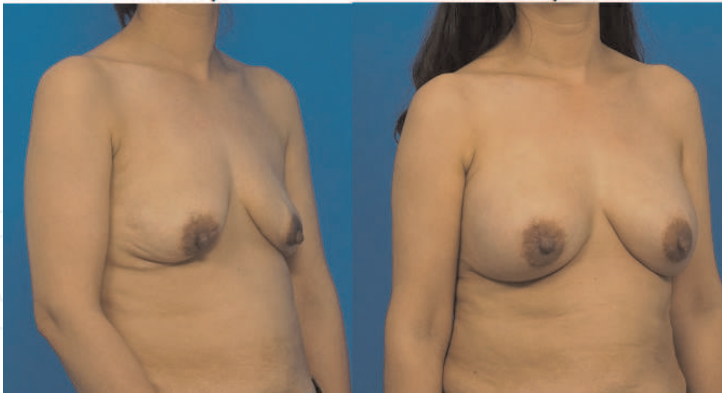Breast Atrophy, Ptosis  
Breast augmentation with implant  
Reduction, elevation of nipple-areolar complex  
Pre-op                      Post-op 2 M



**Figure 17.**  
*Front view; left, pre-op; right, post-op.*

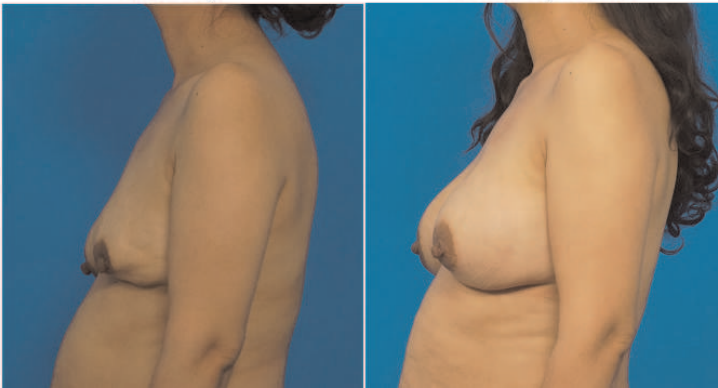


Breast Atrophy, Ptosis  
Breast augmentation with implant  
Reduction, elevation of nipple-areolar complex  
Pre-op                      Post-op 2 M



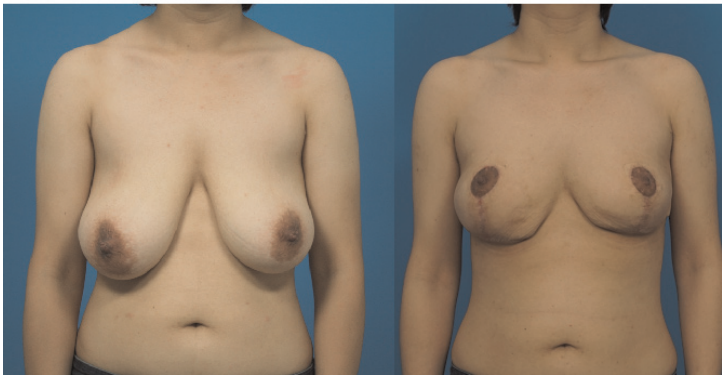**Figure 18.**  
*Three-quarter view; left, pre-op; right, post-op.*

Breast Atrophy, Ptosis  
Breast augmentation with implant  
Reduction, elevation of nipple-areolar complex  
Pre-op                      Post-op 2 M

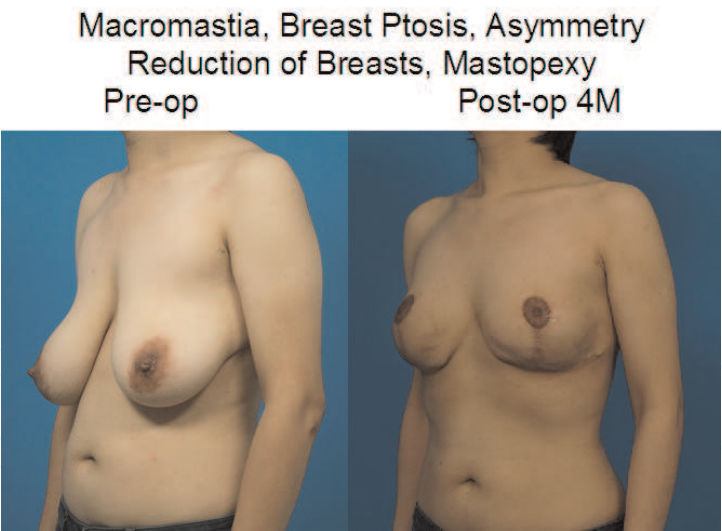


**Figure 19.**  
*Lateral view; left, pre-op; right, post-op.*

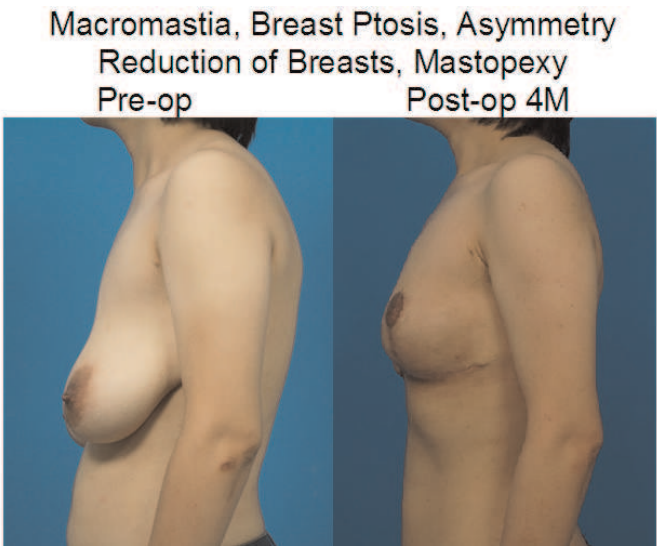Macromastia, Breast Ptosis, Asymmetry  
Reduction of Breasts, Mastopexy  
Pre-op                      Post-op 4M



**Figure 20.**  
*Macromastia; left, pre-op; right, post-op.*



**Figure 21.**  
*Three-quarter view; left, pre-op; right, post-op.*



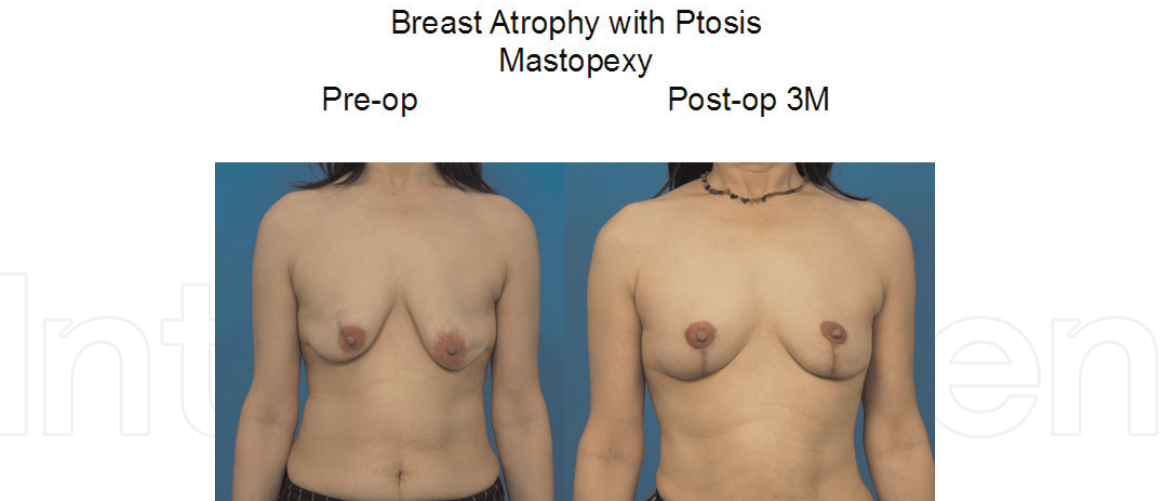
**Figure 22.**  
*Lateral view of macromastia and breast ptosis. Left, pre-op; right, post-op.*

3. A 26-year-old young lady suffered from macromastia, which became breast ptosis and asymmetry after weight reduction. She received reduction of breast, mastopexy, and correction of breast asymmetry (**Figures 20–22**).

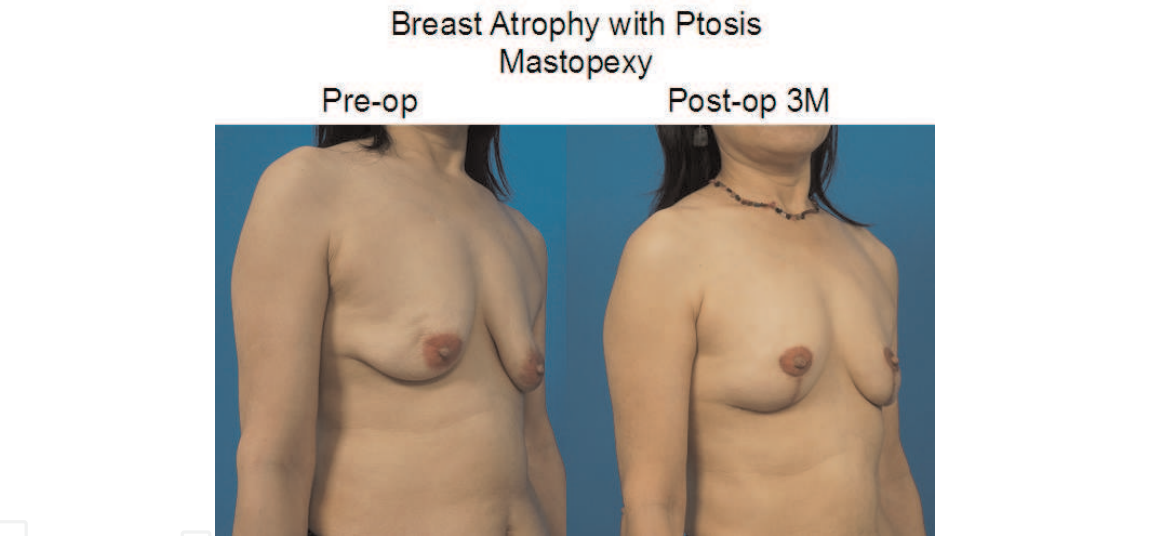
### 3. Mastopexy

1. A 57-year-old lady, with breast atrophy, ptosis, and significant breast asymmetry, left side more ptotic [5].

Mastopexy with dissecting medial and lateral flaps from the underlying breast tissue was brought together with upward mobilization of the nipple-areolar complex to build up more esthetic and symmetric breasts. The operation was carried out under local anesthesia (**Figures 23 and 24**).



**Figure 23.**  
*Atrophic and ptotic breasts with significant asymmetry and disfigurement of nipple-areolar complex. Front view; left, pre-op; right, post-op.*



**Figure 24.**  
*Atrophic and ptotic breasts with significant asymmetry and disfigurement of nipple-areolar complex. Three-quarter view; left, pre-op; right, post-op.*

**4. Postmastectomy breast reconstruction**

Nowadays, breast cancer patients are increasing, and different breast cancer treatment modalities are evolving, which may result in miscellaneous breast deformities, asymmetry, and disfigurements [6–9].

The patients may suffer from breast deformities, asymmetries, radiation injuries, loss or deformities of nipple-areolar complex, scar contracture, or even lymphedema of the affected side upper extremity.

Breast cancer of different stages may need different reconstruction modality. Postmastectomy breast reconstruction is another big issue for plastic surgeons.

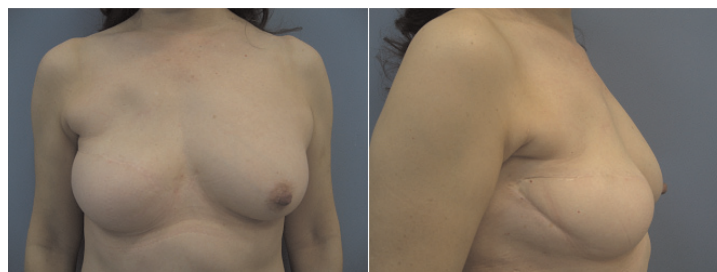1. This 38-year-old lady had modified radical mastectomy on her right breast. She received postmastectomy breast reconstruction 3 years later. Transverse

rectus abdominis myocutaneous flap [6, 9] was harvested from lower abdomen to reconstruct the right breast defect. The photo showed the breast figure 25 years after operation (**Figure 25**).

2. Twenty-eight-year-old lady with right side post-modified radical mastectomy received secondary breast reconstruction with free DIEP flap [9], followed by nipple-areolar reconstruction (**Figure 26**).
3. This 38-year-old patient received partial mastectomy followed by radiotherapy at left breast for breast cancer, resulted in a contracted and deformed breast [10]. The patient felt embarrassed with the breast asymmetry. Therefore she received differential augmentation of the breasts with gel implant (Mentor Memory gel) (right side 250 ml, left side 300 ml) (**Figures 27–29**).
4. This 51-year-old lady suffered from breast asymmetry and capsular contractures at both breasts [2], s/p breast cancer surgery and reconstruction with implants. The problems included nipple-areolar complex enlargement at right side, deficient areola at left side, and hardened breast at right side, which were corrected with nipple areolar sharing from right side to left side, change of breast implant size with capsulectomy, and differential augmentation (**Figures 30–32**).
5. This 37-year-old lady received left side partial mastectomy with irradiation at medial lower quadrant, resulting in significant breast deformity and asymmetry [10]. Her right breast was atrophic and ptotic. Therefore differential mastopexy of right breast and left breasts were performed, intending to achieve symmetry of the breasts (**Figures 33–35**).
6. Chest wall deformity due to pectus excavatum [11–14] is corrected with “revascularization of turnover sternum,” which is a definitive treatment for intractable funnel chest [15].

Intractable funnel chest in this 16-year-old young adult was treated with revascularization of the turnover sternum. The sternum and costal composite tissue were

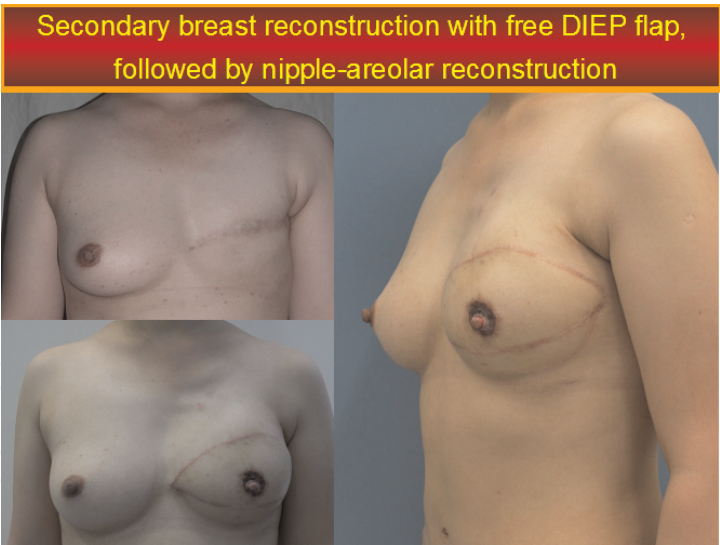23 years after  
Pedicle TRAM Flap  
Breast Reconstruction



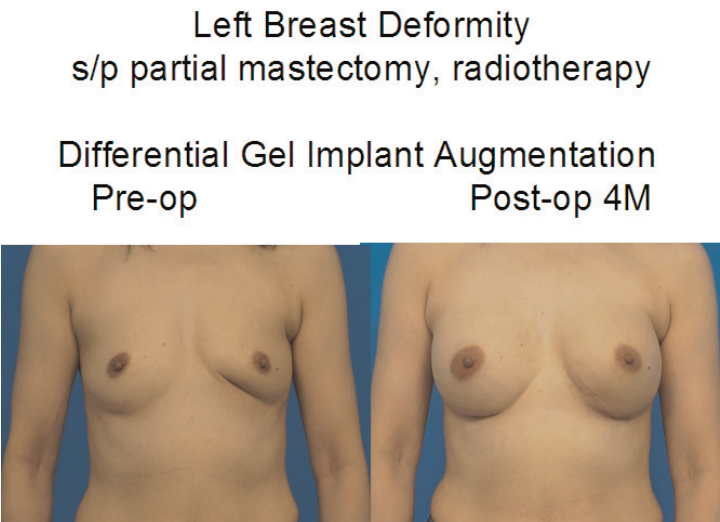
**Figure 25.**

Twenty-five years after postmastectomy breast reconstruction with pedicled transverse rectus abdominis myocutaneous flap.

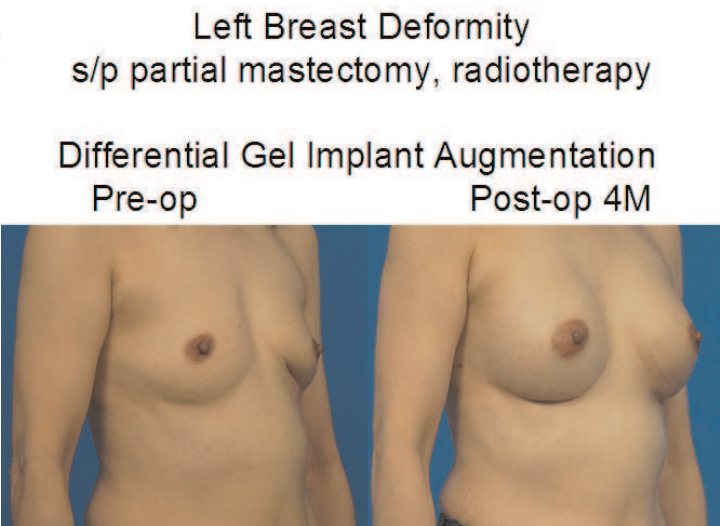




**Figure 26.**  
*Secondary breast reconstruction with free DIEP flap, followed by nipple-areolar reconstruction.*



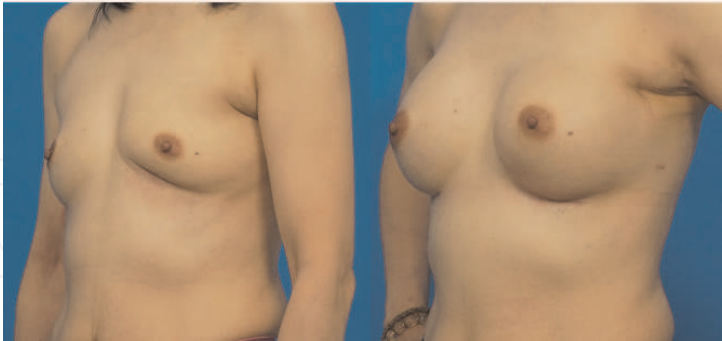**Figure 27.**  
*Front view. Differential augmentation of the breasts with gel implant (Mentor Memory gel) (right side 250 ml, left side 300 ml). Left, pre-op; right, post-op.*



**Figure 28.**  
*Right three-quarter view. Differential augmentation of the breasts with gel implant (Mentor Memory gel) (right side 250 ml, left side 300 ml). Left, pre-op; right, post-op.*

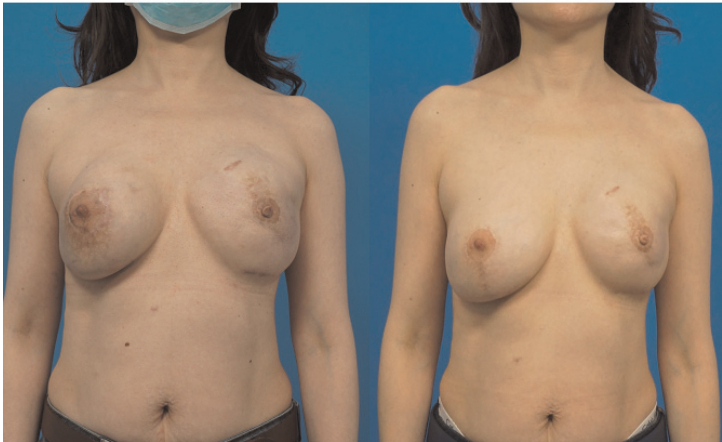Left Breast Deformity  
s/p partial mastectomy, radiotherapy

Differential Gel Implant Augmentation  
Pre-op                      Post-op 4M



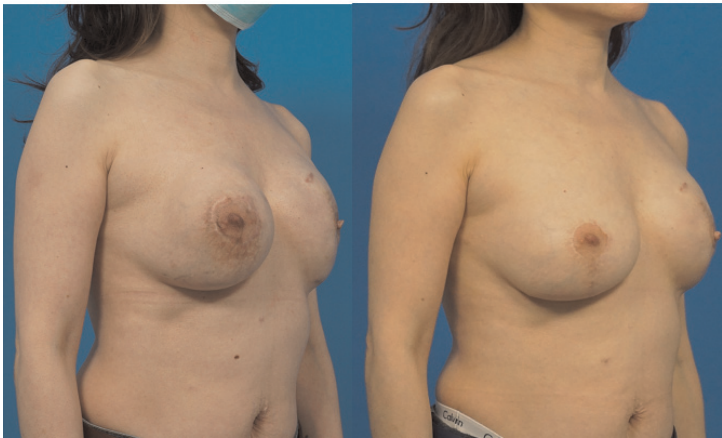**Figure 29.**  
*Left three-quarter view. Differential augmentation of the breasts with gel implant (Mentor Memory gel) (right side 250 ml, left side 300 ml). Left, pre-op; right, post-op.*

Pre-op                      Post-op 30M



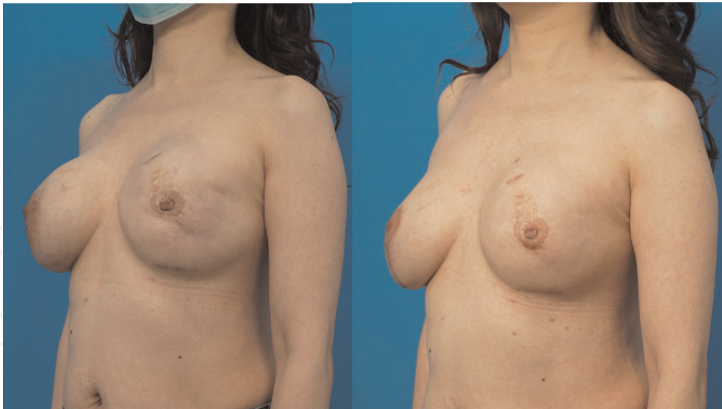**Figure 30.**  
*Mastopexy, capsulectomy, change of prosthesis at right breast and capsulectomy, change of prosthesis, and areolar graft at left breast. Left, pre-op; right, post-op. 2.5 years.*

Pre-op                      Post-op 30M



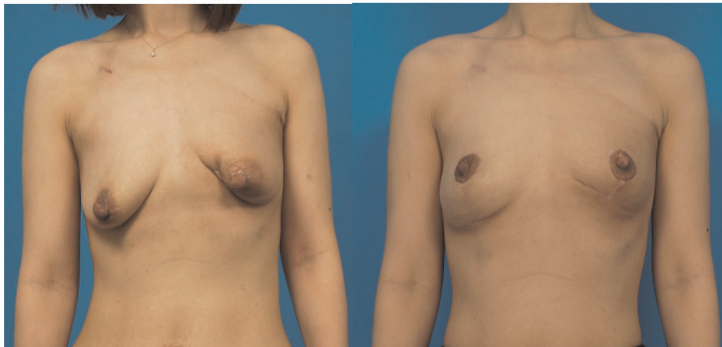**Figure 31.**  
*Release of scar contracture with differential augmentation and nipple areolar sharing. Mastopexy at right breast. Right three-quarter view; left, pre-op; right, post-op.*

Pre-op Post-op 8M



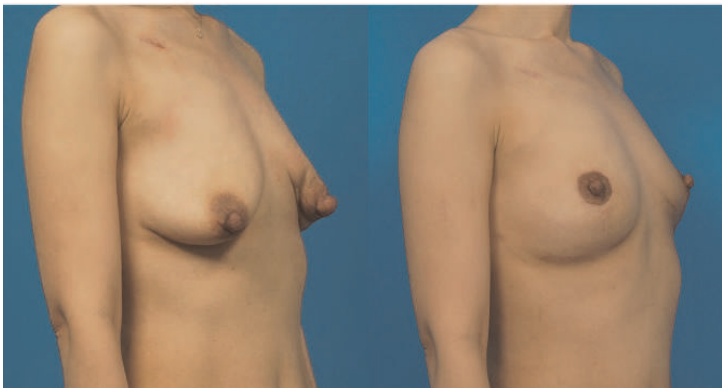**Figure 32.**  
*Release of scar contracture with differential augmentation and nipple areolar sharing. Left three-quarter view; left, pre-op; right, post-op.*

Breast Ptosis/ Breast Deformity, s/p R/T  
Correction with Modified Mastopexy  
Pre-op Post-op 5M



**Figure 33.**  
*Left, ptosis of right breast; deformity of left breast after partial mastectomy with R/T; left, pre-op; right, right breast corrected with mastopexy; left breast with modified mastopexy with subsequent fat graft.*

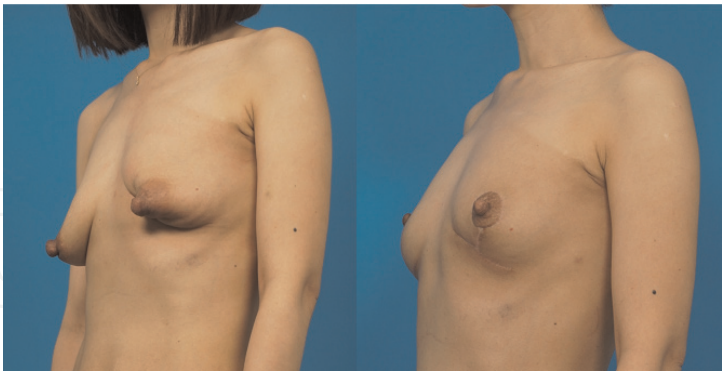
Breast Ptosis/ Breast Deformity, s/p R/T  
Correction with Modified Mastopexy  
Pre-op Post-op 5M



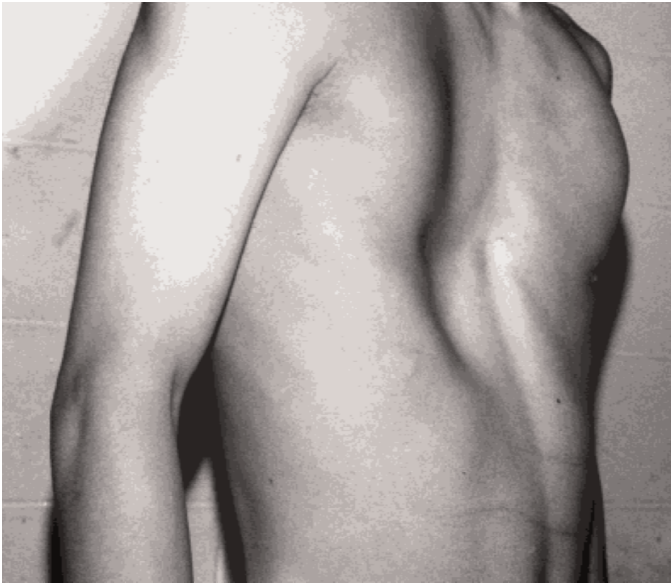**Figure 34.**  
*Correction of right breast with mastopexy.*



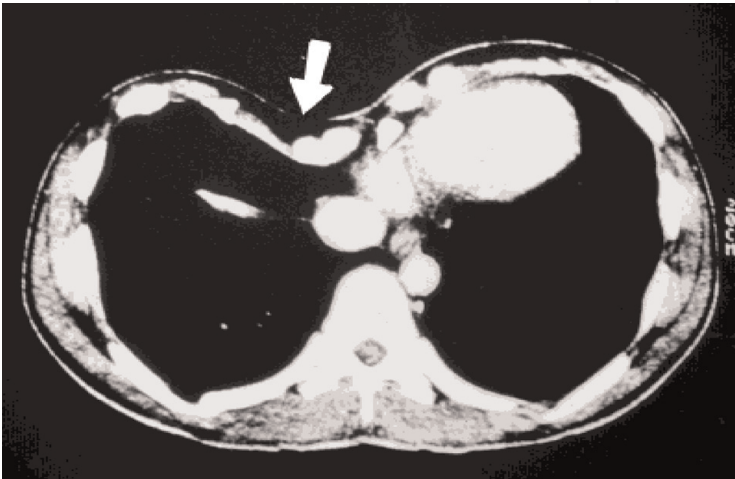Breast Ptosis/ Breast Deformity, s/p R/T  
Correction with Modified Mastopexy  
Pre-op                      Post-op 5M



**Figure 35.**  
*Deformity of left breast after partial mastectomy with R/T, corrected with modified mastopexy with subsequent fat graft. Left, pre-op; right: Post-op. 5 months.*

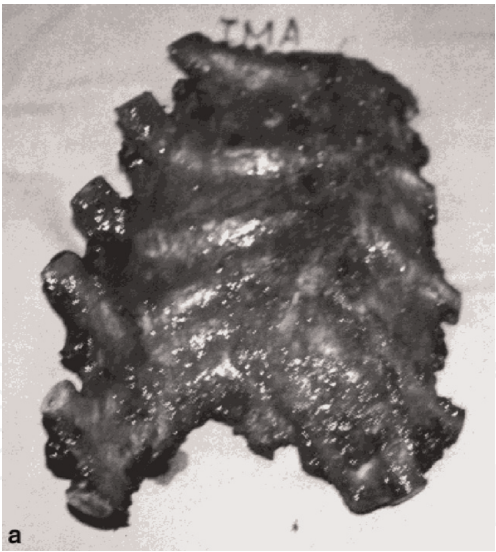

**Figure 36.**  
*Intractable funnel chest.*

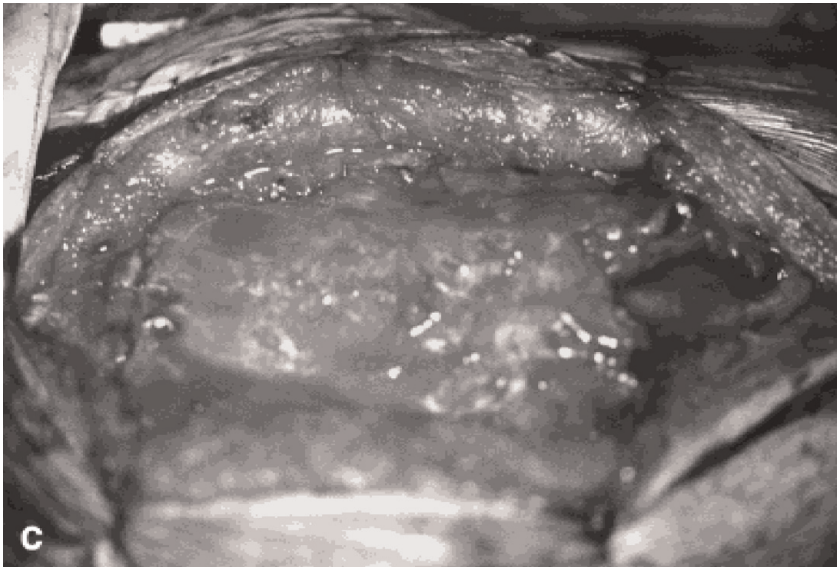


**Figure 37.**  
*CT showed compression of sternum on heart.*

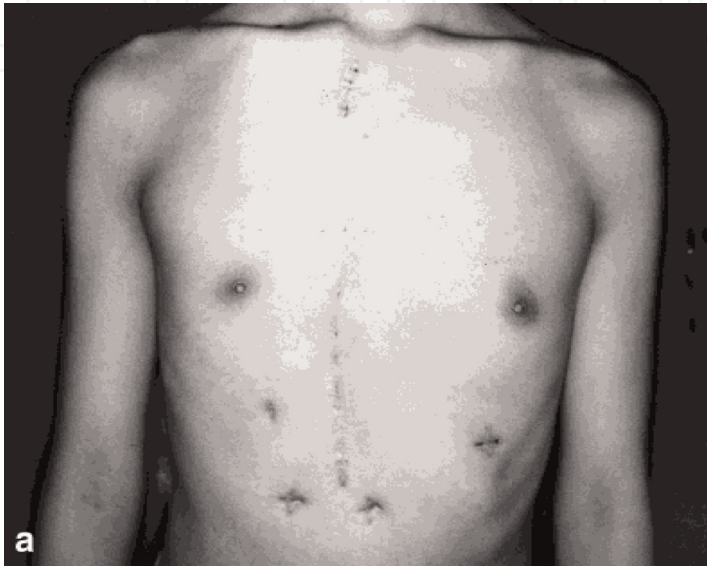



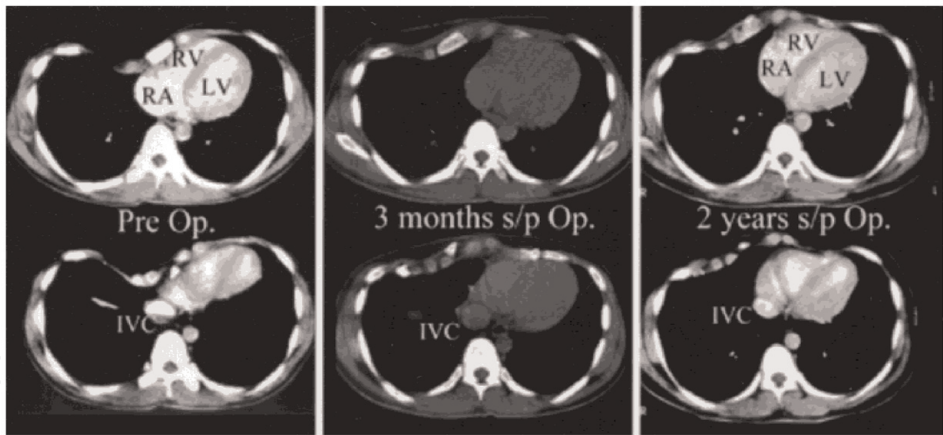
**Figure 38.**  
*Resected sternal block.*



**Figure 39.**  
*Sternal turnover with revascularization.*



**Figure 40.**  
*Post-op front view.*

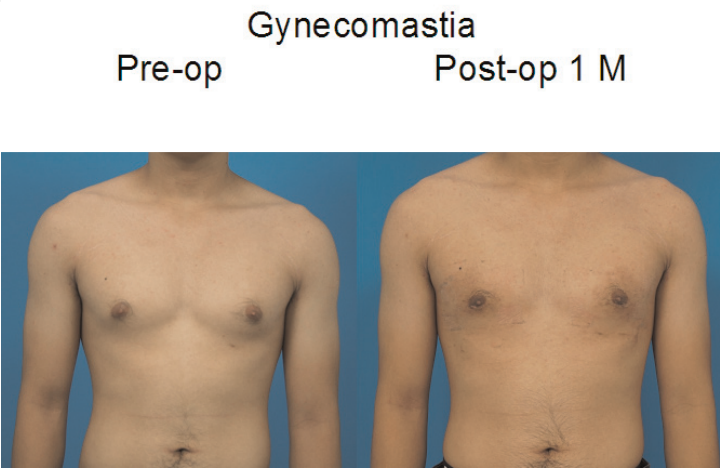

**Figure 41.**  
*Sequential CT follow-up showed definitive improvement of function, stability, and configuration of reconstructed sternum.*

resected at the outskirts of the depressed area. Special attention was paid to the dissection of the vascular pedicle at both sides of the internal mammary vessels. The recipient vessels at one side were left long, so were the donor vessels at the other side. A segment of the rib at the exit of the recipient internal mammary vessels had to be removed to accommodate the vessels and to facilitate vascular anastomosis. Vascular anastomosis was accomplished with loupes (Keeler, sixfold magnification). Revascularization of the turnover sternum was performed successfully without vascular compromise. The patient recovered well with much improved physical condition. Postoperative three-dimensional computed tomographic (CT) scan revealed increment of thoracic cage volume for 9–17%. A follow-up CT scan 2 years later revealed even more improved thoracic cage expansion (**Figures 36–41**).

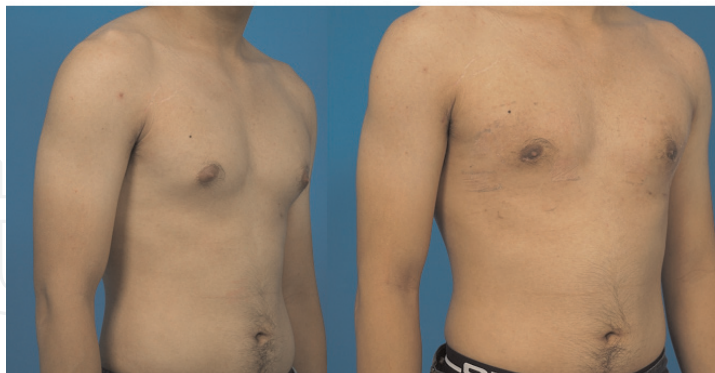5. Gynecomastia

1. This 19-year-old young man had bilateral gynecomastia and out-projecting nipple, which made him feel embarrassed. Subcutaneous mastectomy with liposuction via tiny intra-areolar incision approach can achieve flatness of the breasts without leaving conspicuous scar (**Figures 42 and 43**).



**Figure 42.**  
*A 19-year-old young man received correction of gynecomastia, showing flattening of breasts and bilateral nipple-areolar complex. Left, pre-op; right, 1 month post-op.*

Gynecomastia  
Pre-op                      Post-op 1 M



**Figure 43.**

*A 19-year-old young man received correction of gynecomastia, showing flattening of breasts and bilateral nipple-areolar complex. Three-quarter view; left, pre-op; right, 1 month post-op.*

## 6. Discussion

Breasts and forechest are important structures in esthetics and function in the human body [16]. Pursuing for a presentable breast and forechest contour has always been a goal for people. Imperfection at these specific areas is a common concern that brought to plastic surgeons.

This chapter introduces many kinds of breast problems, from simple to intriguing, with in-depth solutions. The breast with its unique role in esthetics and function brings about beauty and sorrow in a woman's lifelong journey.

The problems are:

1. Breast asymmetry
2. Breast volume—atrophy, and hypertrophy
3. Breast form disfigurement
4. Breast tissue and its enveloping skin incompatibility—breast ptosis and significant asymmetry
5. Deformity and displacement of nipple-areolar complex—in size, shape, length, and color

Breast cancer-associated complications:

1. Mastectomy-modified radical mastectomy.
2. Partial mastectomy
3. Total mastectomy
4. Subcutaneous mastectomy

5. Loss of nipple-areola complex
6. Radiation contracture
7. Radiation necrosis
8. Breast deformity
9. Scar contracture
10. Breast asymmetry
11. Chest wall deformity
12. Lymphedema at the afflicted upper extremity

Refinements in breast shape involve thorough evaluation for not only the inherent problem but also the status of the counterpart breast shape and form.

The nipple-areola complex is also an important esthetic unit that should be taken into consideration as a whole, which encompasses the size, form, length, color, etc.

Breast cancer surgery/radiation treatment [10] may create deformity, scar contracture, loss of nipple-areola complex, chest wall tightness, or even recurrence, radiation necrosis, infection, and cardiac tamponade of the severely afflicted individuals [10].

Reconstructions of the breast cancer surgery/treatment-associated problems involve placement of implant, with differential augmentation or reduction mammoplasty/mastopexy at the contralateral side. Nipple-areolar reconstruction can be elaborated with nipple areola sharing from the contralateral side, or by using local flap, followed by full-thickness skin graft and diced cartilage graft to create areola. The implant breast reconstructions are suitable for skin-sparing mastectomy patients.

Transverse rectus abdominis myocutaneous flap and free deep inferior epigastric perforator flap breast reconstruction are options for those with skin deficiencies or secondary reconstructions.

Choice of reconstruction modalities should consider the severity and general condition of the patient, expectation of the patients, and operation times that are desirable to the patients.

Pursuing excellence has been always the ultimate goal for breast surgeries and reconstructions.

## **7. Conclusion**

Breast recontouring is a common request in the modern era. Introduction of the problems regarding this issue is well described and depicted in this chapter. With the advent of the current plastic and reconstructive surgery modality, almost all the problems can be solved to significantly improve the figure and life quality of the afflicted individuals. Pursuing excellence in plastic surgery and bringing excellence to life have always been our ultimate goals.



IntechOpen

## Author details

Yueh-Bih Tang<sup>1,2\*</sup>, Shihheng Chen<sup>3</sup> and Yo-Shen Chen<sup>4</sup>

1 Director of Center for Human Appearance, Far-Eastern Memorial Hospital, Banquo, New Taipei City, Taiwan

2 Department of Plastic Surgery, National Taiwan University Hospital, Taipei, Taiwan

3 Department of Plastic and Hand Surgery, Chang-Gung Memorial Hospital, Linko, Taiwan

4 Department of Plastic Surgery, Far-Eastern Memorial Hospital, Banquo, New Taipei City, Taiwan

\*Address all correspondence to: phoebetang0103@gmail.com

## IntechOpen

© 2019 The Author(s). Licensee IntechOpen. This chapter is distributed under the terms of the Creative Commons Attribution License (<http://creativecommons.org/licenses/by/3.0>), which permits unrestricted use, distribution, and reproduction in any medium, provided the original work is properly cited. 

## References

- [1] McGrath MG, Burkhardt BR. The safety and efficacy of breast implants for augmentation mammoplasty. *Plastic and Reconstructive Surgery*. 1984;**74**: 550
- [2] Nelson GD. Complications from the treatment of fibrous capsular contracture of the breast. *Plastic and Reconstructive Surgery*. 1981;**68**:969
- [3] McKissock PK. Reduction mammoplasty by the vertical bipedicle flap technique: Rationale and results. *Clinics in Plastic Surgery*. 1976;**3**:309
- [4] Ribeiro L, Backer E. Inferior Based Pedicles in Mammoplasties. Georgiade NG, editor. *Aesthetic Breast Surgery*. Baltimore: Williams & Wilkins Company; 1983. p. 260
- [5] Georgiade NG, editor. *Aesthetic Breast Surgery*. Baltimore: Williams & Wilkins Company; 1983. p. 260
- [6] Hartrampf CR, Scheflan M, Black PW. Breast reconstruction following mastectomy with a transverse abdominal island flap anatomical and clinical observations. *Plastic and Reconstructive Surgery*. 1982;**69**:216
- [7] Elliott LF, Hartrampf CR Jr. Tailoring of the new breast using the transverse abdominal island flap. *Plastic and Reconstructive Surgery*. 1983;**72**:887
- [8] Georgiade GS, Riefkohl R, Cox E, McCarty KS, Siegler HF, et al. Long-term clinical outcome of immediate reconstruction after mastectomy. *Plastic and Reconstructive Surgery*. 1985;**76**:415
- [9] Bostwick J. Breast reconstruction following mastectomy. *Contemporary Surgery*. 1987;**30**:16
- [10] Bostwick J, Stevenson TR, Nahai F, Hester TR, Coleman JJ, Jurkiewicz MJ. Radiation to the breast. Complications amenable to surgical treatment. *Annals of Surgery*. 1984;**200**:543
- [11] Crump HW. Pectus excavatum. *American Family Physician*. 1992;**46**: 173-179
- [12] Hirayama T, Nozaki M, Wakamatsu S. A new surgical method for repair of funnel chest. *Annals of Plastic Surgery*. 1985;**14**:23-32
- [13] Haller JA Jr, Kramer SS, Lietman SA. Use of CT scans in selection of patients for pectus excavatum surgery: A preliminary report. *Journal of Pediatric Surgery*. 1987;**22**:904-906
- [14] Wada J. Sternal turnover. *The Annals of Thoracic Surgery*. 1974;**17**: 296-298
- [15] TangChen YB, Chen SJ, Lee YC, Huang KF, Chen HC. Revascularization of turnover sternum: A definitive treatment for intractable funnel chest. *Microsurgery*. 1999;**19**:296-302
- [16] McCarty KS Jr, Glaubitz LC, Thienemann M, Riefkohl R. The breast: Anatomy and physiology. In: Georgiade NG, editor. *Aesthetic Breast Surgery*. Baltimore: Williams & Wilkins Company; 1983. p. 1