

We are IntechOpen, the world's leading publisher of Open Access books Built by scientists, for scientists

6,900

Open access books available

186,000

International authors and editors

200M

Downloads

Our authors are among the

154

Countries delivered to

TOP 1%

most cited scientists

12.2%

Contributors from top 500 universities



WEB OF SCIENCE™

Selection of our books indexed in the Book Citation Index
in Web of Science™ Core Collection (BKCI)

Interested in publishing with us?
Contact book.department@intechopen.com

Numbers displayed above are based on latest data collected.
For more information visit www.intechopen.com



Wide-Field Retinal Imaging in Adults and Children

Mustafa Değer Bilgeç, Nazmiye Erol and Seyhan Topbaş

Abstract

Wide-field retinal imaging has become an important standard of care imaging modality in many retinal disorders both in adults and children. The recently developed wide-field retinal imaging systems enable approximately 200° imaging of retina. In this chapter, we would like to review the use of wide-field retinal imaging in disorders such as retinal vascular diseases, uveal and retinal inflammatory diseases, intraocular tumors, peripheral retinal pathologies, and retinal disorders in children such as retinopathy of prematurity, familial exudative vitreoretinopathy, and Coats' disease. Also, we would like to address the rapidly expanding role of peripheral retinal imaging in treating systemic diseases. The use of wide-field imaging technologies in screening, diagnosis, treatment, and documentation of retinal pathologies and the new information provided by wide-field angiography for retinal vascular diseases and macular problems will be discussed.

Keywords: retinal imaging, wide-field, ultra-wide-field, wide-angle, fluorescein angiography, optomap, scanning laser ophthalmoscope

1. Introduction

Wide-field retinal imaging gives the opportunity to simultaneously visualize the central and peripheral retina in a single session. Older wide-field retinal imaging systems had significant downsides such as the requirement of a contact lens and a clear ocular media [1]. Acquiring images from the far peripheral retina was difficult, requiring a skilled technician and demanded difficult tasks from the patient such as performing extreme gazes. Systems that utilized image montaging could only capture up to 75° of the retina and were disadvantaged due to frequent montage errors [1–3]. New-generation devices were able to obtain up to 140° at one session [1–3].

The Optos Optomap Panoramic 200A imaging system (Optos® camera, Optos PLC, Dunfermline, UK) revolutionized wide-field retinal imaging by increasing the field of view to 200° [4]. This system implements a scanning laser ophthalmoscope technology with an ellipsoid mirror and covers approximately 82% of the retina in a single image by forming a virtual scanning head within the patient's eye [1]. Compared with conventional digital imaging systems, ultra-wide-field fluorescein angiography (UWFA) using the Optos system captures twice as much retinal area [5]. Heidelberg (Heidelberg Engineering, Germany) introduced a noncontact lens that attaches to the Heidelberg Spectralis and Retinal Angiography systems allowing ultra-wide-field photography and angiography [6].

Endowed with high resolution and multimodal capabilities, ultra-wide-field imaging is destined to become the standard-of-care in retinal imaging. These

Confocal scanning laser ophthalmoscope(CSLO)-based systems	Optos, Heidelberg
Optics-based systems	RetCam, Panoret 1000
Contact lens-based systems	Staurenghi, Rodenstock lens

Table 1.
Classification of wide-field devices according to their working principles.

devices have also found their place in research applications and have the potential to be utilized in telemedicine [7]. Wide-angle imaging systems using different systems are summarized in **Table 1**.

2. The history and evolution of retinal imaging

Hermann von Helmholtz was the founder of the first direct ophthalmoscope in 1851 [8]. The first available fundus camera, produced by Carl Zeiss in 1955, had a 20° field of vision. Development of fluorescein angiography (FA) in 1961 brought another format to retinal imaging [9]. The first camera that was able to visualize beyond the equator was developed by Oleg Pomerantzeff in 1977 and this device could image 148° of the retinal area. A disadvantage of this modality was the requirement of a contact lens and transscleral illumination [10]. In the meantime, montage methods had been developed to image the peripheral retina such as the 75° views compiled for the ETDRS seven-standard fields [1, 3]. A further development in the wide-field imaging systems was the introduction of RetCam (Clarity Medical Systems, Inc., Pleasanton, CA, USA) by Bert Messie in 1997 which was able to image up to 130°. This device which brought significant convenience in pediatric retinal imaging was quickly popularized [9]. The main disadvantage of this device is its optical method of illumination, necessitating a clear media. In 2003, Medibell introduced the Panoret-1000 (Medibell Medical Vision Technologies, Inc., Haifa, Israel), incorporating a non-mydratic camera which could image up to 100° of the retina. However, this technique was technically demanding as it required technicians for image acquisition. In general, although it was able to capture high-resolution images of the retina, it did not perform well in dark pigmented fundus due to decreased transscleral illumination [9, 11]. A milestone in wide-field retinal imaging systems was the development of Optos in 2005 (Optos® camera, Optos PLC, Dunfermline, UK) which, by utilizing an ellipsoidal mirror, was capable of capturing up to 200° of the internal viewing angle of the retina [4]. Both UWFA and fundus autofluorescence are available. Furthermore, this UWFA system allowed better detection of peripheral capillary non-perfusion. An indocyanine green (ICG) angiography upgrade was also recently made available [6, 9]. In 2005, Giovanni Staurenghi developed the handheld Staurenghi 230 SLO Retina Lens (Ocular Staurenghi 230 SLO Retina Lens; Ocular Instrument Inc., Bellevue, WA, USA) which was later incorporated into a confocal scanning laser ophthalmoscopy system by Heidelberg. Addition of this lens increased the original field of view of Heidelberg Retinal Angiography (HRA) Spectralis system from 100° to 150° of the retina [12].

In summary, apart from Optos, other notable systems for wide-field imaging include the Pomerantzeff Camera/Equator-plus, Panoret-1000, the Staurenghi lens, HRA Spectralis and RetCam 3 system [11–15]. Each of the former devices has its specific inherent limitations such as the requirement of a contact lens, illumination difficulties, low resolution, optical aberrations limiting angiographic view, incapability to obtain ultra-wide-field retinal images, and absence of ultra-wide-field

autofluorescence imaging. Although the montage method using standard fundus photography is also able to obtain wide-angle images of the retina, the final assembled image may not be synchronous as none of the images have been captured simultaneously [16].

3. Advantages of modern digital wide-field imaging systems

- Enhanced resolution
- Faster image processing time
- Faster image acquisition
- Ease of image duplication and manipulation
- Possibility of image transmission via electronic route
- Better acquisition in eyes with hazy ocular media (such as cataract) than a traditional fundus camera
- Simultaneous imaging of central and peripheral retina [17].

4. Confocal scanning laser ophthalmoscopy imaging (CSLO) systems

CSLO systems use laser light to illuminate the retina, instead of bright flashes of light. This reduces scatter of light in images acquired. Two different wavelengths of laser are used (532 nm-green, 633 nm-red). Green laser provides more detailed information about the superficial layers of the retina and the retinal vessels. Red laser (633 nm) owing to a longer wavelength gives more detailed information about deep retinal layers and choroid. Images can be evaluated separately or a composite photo image is acquired [18].

5. Multimodal imaging with digital wide-field systems

A great advantage offered by many of the present WFI and UWFI systems is the possibility of simultaneous acquisition of fundus fluorescein angiography (FA), indocyanine angiography (ICGA), red-free photography, fundus photography, fundus autofluorescence (FAF), including blue-light fundus autofluorescence (BAF), infrared autofluorescence (IRAF) or green-light fundus autofluorescence (GAF). The main features of commercially available WFI systems are summarized in Table 2.

	Platforms/devices	Type of lens system	Principle	Field of view	Available application
WFI	Heidelberg Spectralis	Non-contact	SD-OCT with CSLO	55°(105°with HRA2)	FFA, ICGA, FAF(BAF and IRAF)
		Contact	SD-OCT with CSLO using Staurenghi Lens	150°	FFA,ICGA, FAF(BAF and IRAF)

Platforms/devices		Type of lens system	Principle	Field of view	Available application
RetCam 3		Contact	Optical light source to obtain high resolution	130°	FFA, ICGA
UWFI	Optos	Non-contact	CSLO-based	200	FFA, FAF (GAF, IRAF), ICGA

Table 2.
The main features of commercially available WFI systems.

6. Wide-field fundus autofluorescence (FAF) imaging

Autofluorescence is based on the excitation of fluorophores within the retina. The main fluorophore is lipofuscin, found in the retinal pigment epithelial cells [19]. For some diseases, autofluorescence provides valuable information in the differential diagnosis. An ultra-wide-field scanning laser ophthalmoscope with FAF capability was recently introduced. The importance of peripheral retinal evaluation was highlighted in reports showing distinct peripheral FAF changes in diseases that were previously assumed to be isolated to macula [20]. Wide-field FAF imaging

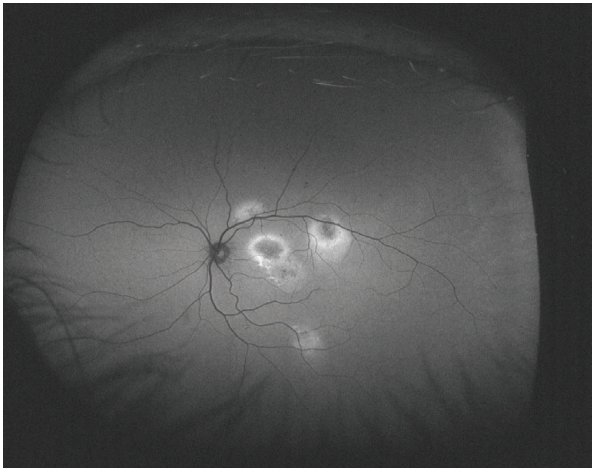


Figure 1.
Typical FAF appearance of multifocal central serous chorioretinopathy. Hyperfluorescent areas are indicative of chronic subretinal fluid and secondary RPE changes.

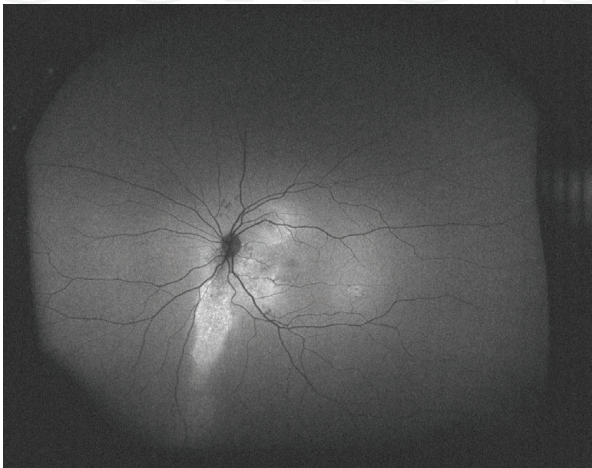


Figure 2.
FAF shows a hyper-autofluorescent gravitational tract in chronic central serous chorioretinopathy.

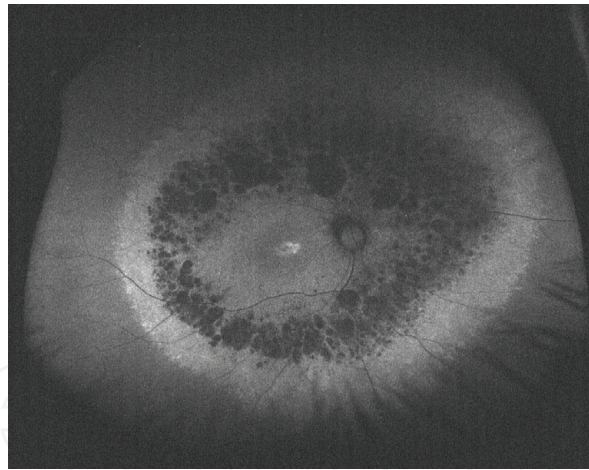


Figure 3.
FAF image of a patient with retinitis pigmentosa showing annular hypo and hyper autofluorescent areas.

provides valuable information in pathologies such as AMD, posterior uveitis, and choroidal melanoma [21]. Wide-field imaging also provides valuable clinical data in central serous chorioretinopathy [22] (**Figures 1–3**).

7. Applications of wide-field imaging in clinical practice

7.1 Healthy eyes

In order to evaluate the pathological angiography findings in various diseases, first of all, it is necessary to evaluate the normal retinal findings in wide-field angiography. [23, 24] Perfused vascular border distance decreases after 60 years of age in all quadrants [24]. Normal peripheral retinas infrequently show granular background fluorescence [23]. **Figure 4** shows wide-field images of healthy eyes.

7.2 Diabetic retinopathy

Vascular abnormalities in diabetic retinopathy, particularly non-perfusion, occur in the peripheral retina; therefore, evaluation of the retinal periphery is of vital importance [25]. With the advent of wide-field imaging systems in recent years, it is possible to evaluate peripheral retina which cannot be visualized by conventional imaging systems in diabetic patients. Peripheral avascular areas, neovascularization, and vascular leakages are evaluated. UWFA was found superior to simulated seven-standard field images in a previous study not only in terms of the visualized total retinal area (3.2 times) but also in terms of the total area of retinal non-perfusion (3.9 times), neovascularization (1.9 times), and panretinal photocoagulation (3.8 times) [26]. Moreover, this study has demonstrated that the seven-standard field image technique has failed to identify positive findings that were present in UWFA in 10% of the patients [26]. Detecting peripheral retinal ischemia is essential as studies have shown that peripheral ischemia may precede diabetic macular edema [27, 28]. In patients with retinal ischemia, macular edema was 3.75 times more than those without ischemia [28]. Patients with diabetic retinopathy with large ischemic areas had more treatment-resistant macular edema [27]. It is stated that ultra-wide-field imaging may provide some additional data in the diagnosis because it contains a larger area [29–32]. **Figure 5** shows UWFA image of a diabetic patient with marked peripheral ischemia.

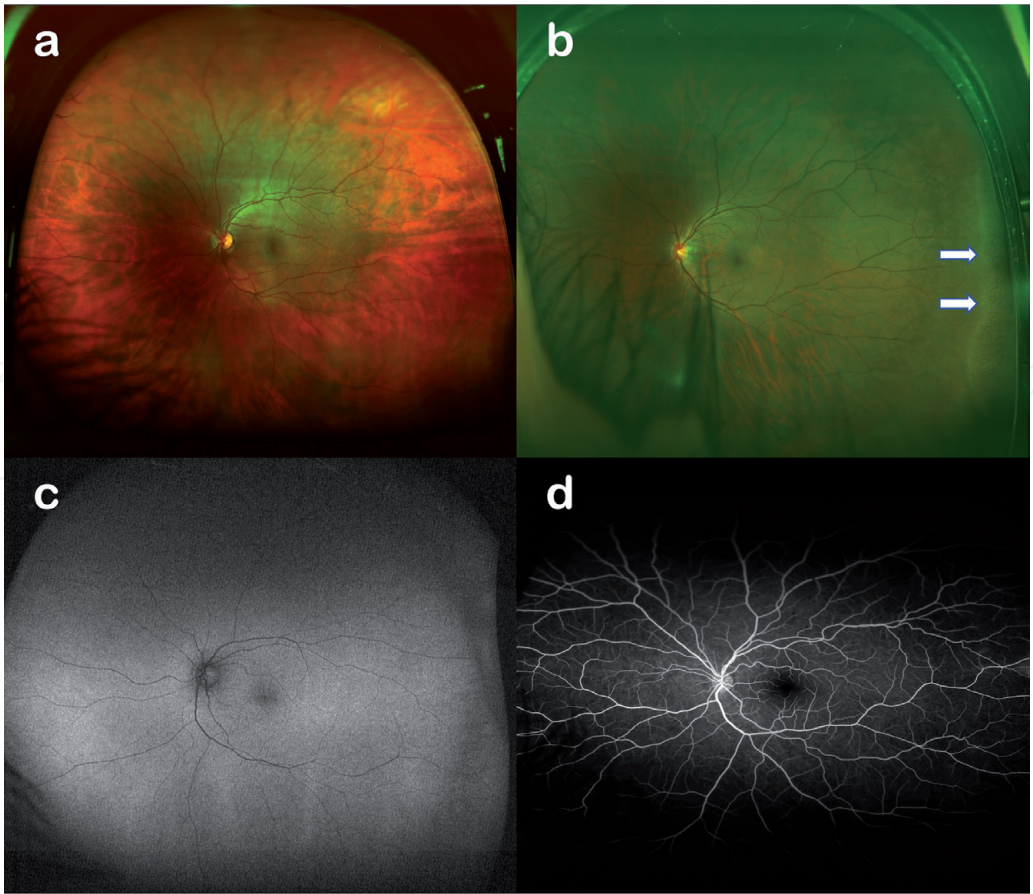


Figure 4. Various wide-field images in different adults with healthy eyes. Composite color photo (a), pars plana view at temporal gaze (white arrows) (b), normal FAF image (c), and normal FA image (d).

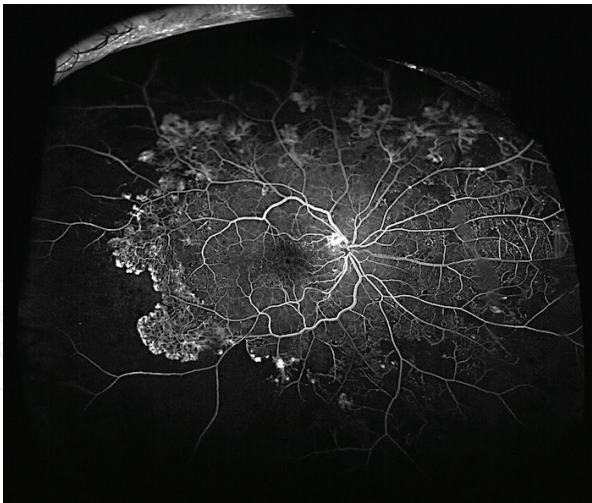


Figure 5. UWFA image of a patient with diabetic retinopathy showing marked peripheral ischemia, patches of neovascularization at disc and elsewhere.

7.3 Retinal vascular occlusions

7.3.1 Branch retinal vein occlusions

Branch retinal vein occlusion (BRVO) is a significant cause of vision loss and is the second most common retinal vascular disease after diabetic retinopathy. BRVO can be categorized as ischemic or non-ischemic [33]. Wide-field FA can be used to

identify vascular abnormalities, peripheral capillary non-perfusion, and neovascularization [34, 35]. Capillary non-perfusion on wide-field angiography heralds the development of macular edema in patients with BRVO [36]. Increased production of VEGF has been proposed to cause macular edema by increasing capillary permeability [36]. **Figure 6** shows UWFA image of a patient with BRVO.

7.3.2 Central retinal vein occlusions

Central retinal vein occlusion (CRVO) is a relatively less frequent cause of vision loss than BRVO. CRVO is classified into ischemic and non-ischemic types depending on the extent of retinal ischemia. As the detection of the extent of retinal ischemia is crucial in prognostication, peripheral retinal imaging is of significant value. Conventional FA systems may be limited in peripheral retinal assessment compared to UWFA. As such, considering that ischemic CRVO is, by definition, the presence of non-perfusion greater than 10 disc diameters, UWFA may be more efficient than conventional FA in differentiating ischemic from non-ischemic CRVOs [37]. Furthermore, wide-field FA allows detection of a greater area of overall non-perfusion enabling earlier and targeted laser photocoagulation [37–39]. In view of these considerations, UWFA is anticipated to improve the management of CRVO. **Figure 7** shows a wide-field fundus photography and UWFA of a patient with CRVO in the acute phase.

7.4 Choroidal lesions including tumors

Wide-field imaging systems ease the evaluation and follow-up of peripheral temporal lesions [40]. SLO images can be distinguished as malignant or benign lesions. Typically, malignant lesions appear dark with a red laser, but appear bright with a green laser [41]. Wide-field fundus imaging may allow documentation of growth of a choroidal tumor and associated serous retinal detachment [42]. **Figures 8 and 9** show two different choroidal tumors imaged by ultra-wide-field imaging system.

7.5 Retinal detachment

Wide-field imaging may be used to supplement fundus examination for characterizing and documenting retinal detachments [7, 43]. Use of wide-field systems in the diagnosis and evaluation of retinal detachments is, however, controversial. The gold

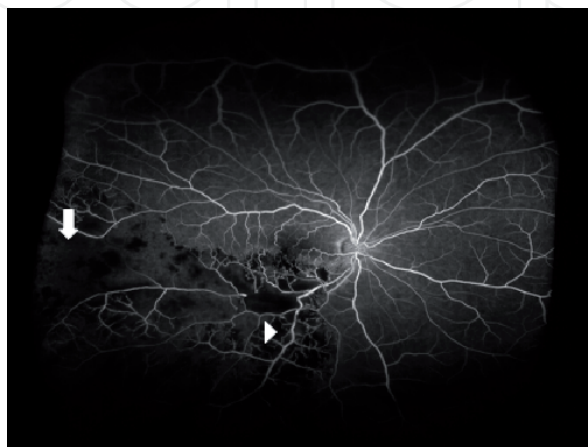

Figure 6.
UWFA image of the inferior temporal region in a patient with BRVO showing a delineated area of peripheral ischemia (arrow) and areas of blocked fluorescence due to hemorrhage (arrow head).

standard in diagnosing retinal detachment remains a dilated binocular indirect examination with scleral depression. **Figure 10** shows a patient with retinal detachment.

7.6 Age-related macular degeneration (AMD)

Detection of peripheral autofluorescence is a potential area of research and its significance is currently being investigated in different studies [44, 45]. In a previous study, peripheral FAF abnormalities were found to be 68.9% and several distinct FAF patterns were identified: granular (46.2%), spotted (34.0%), and nummular (18.1%). An abnormal FAF pattern was observed more frequently in neovascular compared to non-neovascular AMD or normal eyes, but the clinical

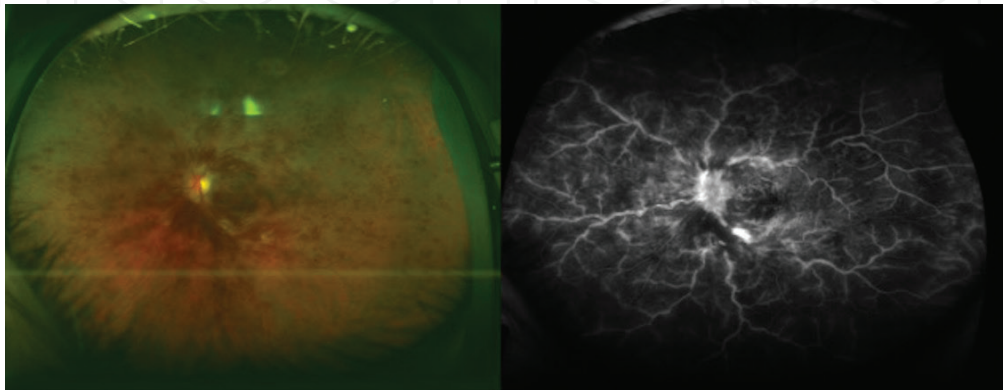


Figure 7. Wide-field fundus photograph and UWFA image of the left eye of a patient with CRVO illustrating widespread retinal hemorrhage and disc staining. Peripheral ischemia in this patient may have been missed by conventional FA due to limited field of view.

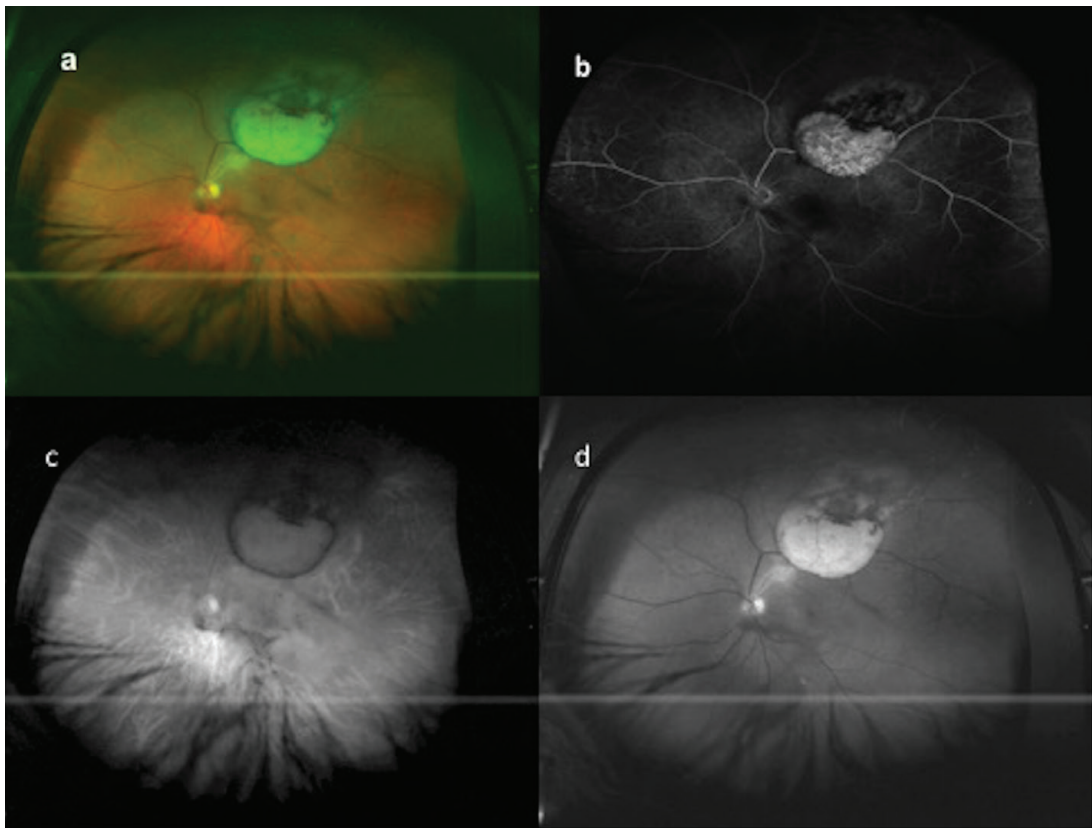


Figure 8. A case of choroidal malignant melanoma, composite photograph (a), UWFA (b), red laser (c), and green laser/red-free (d) images.

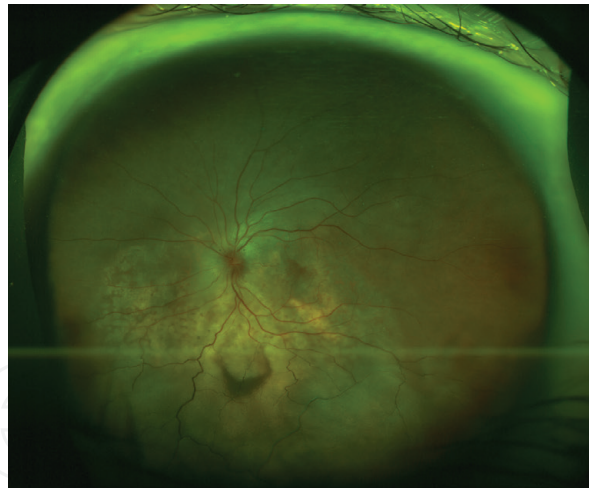


Figure 9.
 Wide-field fundus photograph of a choroidal metastatic tumor with exudative retinal detachment in a patient with lung cancer.

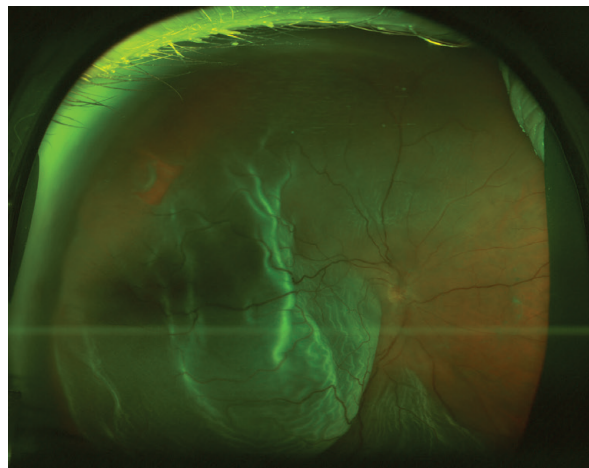


Figure 10.
 Macula-off retinal detachment with a horse-shoe tear at 10 o'clock.

significance of these findings is, at present, uncertain [45]. **Figure 11** shows various peripheral FAF abnormalities in different AMD patients.

7.7 Pediatric retinal diseases

Wide-field imaging of retinopathy of prematurity (ROP) is usually performed using RetCam technology. Optos test is performed more often in older children to document the late sequelae of ROP. Even if it seems difficult, Optos imaging of newborns with ROP can also be performed using the “flying baby” position [46]. Wide-field imaging for telemedicine-based screening of ROP has recently gained popularity [47]. RetCam can be used immediately after laser treatment to identify untreated areas in ROP cases [48]. The RetCam technology is also useful in the diagnosis and follow-up of retinoblastoma. UWF imaging with Optos has been shown to be useful in the diagnosis of Coats’ disease. Wide-field imaging is critical for the detection of areas of non-perfusion and telangiectasias, in addition image-guided targeted panretinal photocoagulation to these areas [49, 50]. Familial exudative vitreoretinopathy (FEVR) is a condition of abnormal vascularization of the retinal periphery. UWFA has also been employed to conceptualize an updated version of FEVR classification [51]. **Figures 12–15** show images of pediatric patients with different retinal diseases.

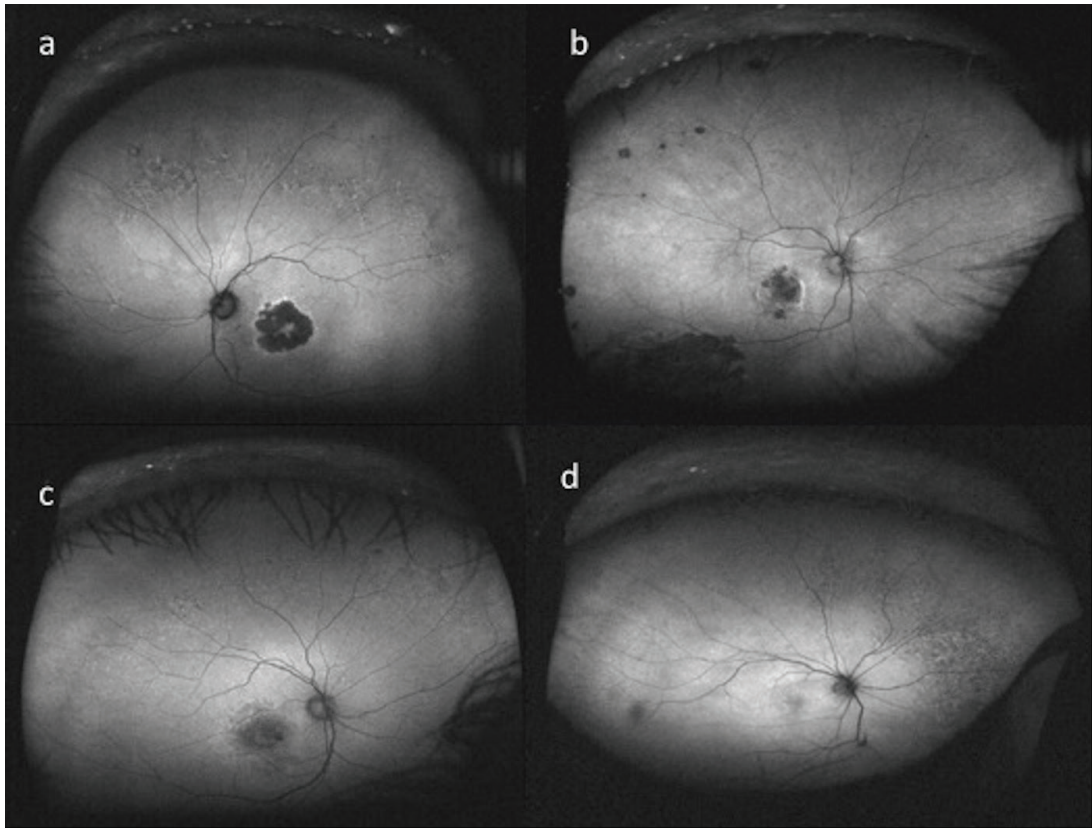


Figure 11. Various peripheral FAF abnormalities in different AMD patients. Hypo-autofluorescent lesions with hyper-autofluorescent borders (a), nummular hypo-autofluorescent lesions (b), hyper-autofluorescent lesions (c), and hypo-autofluorescent lesions (d) at peripheral retina.

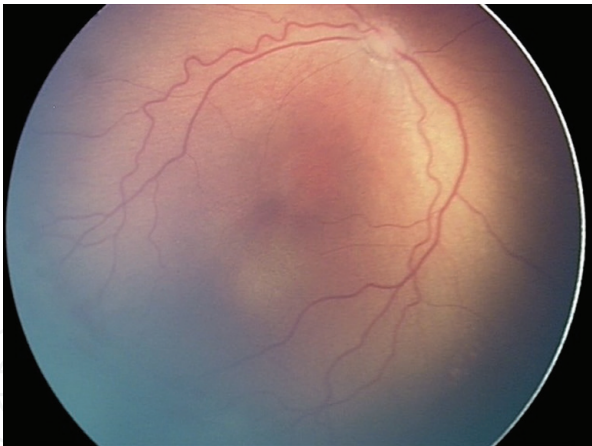


Figure 12. Color fundus photograph reveals zone II, stage 2 retinopathy of prematurity with plus disease (from RetCam).

7.8 Uveitis

UWFA is useful in evaluating disease severity, progression, and treatment response in intermediate or posterior uveitis [52]. The UWFA showed a view of capillary dropout and leakage in the peripheral retina. This was first demonstrated in two case series of patients with retinal vasculitis imaged with UWFA [53, 54]. In a study about Behçet retinal vasculitis, it was found that UWFA detected active vasculitis not otherwise detectable in 84.8% of eyes [55]. Multimodal UWF imaging will likely assume a more prominent role in the diagnosis and follow-up of patients with retinal vasculitis and posterior uveitis [7]. **Figures 16–18** show images of different uveitis patients in wide-field imaging.

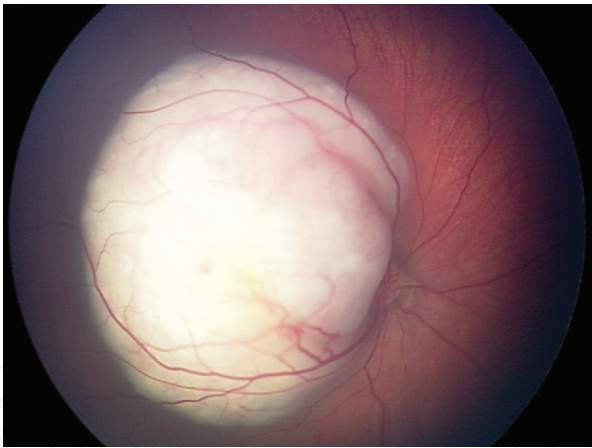


Figure 13.
A RetCam image of a retinoblastoma case showing a large retinal mass encompassing the retinal arcuates.

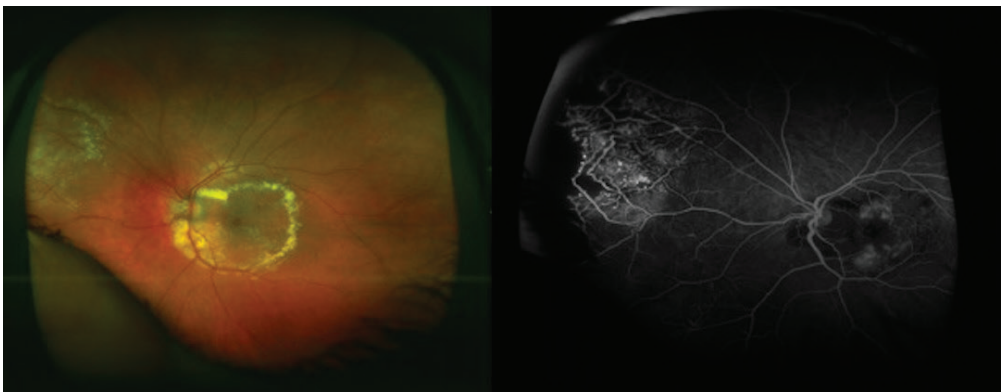


Figure 14.
Wide-field fundus photograph (left panel) of a patient with Coats' disease showing macular circinate exudates, telangiectatic vessels in the upper nasal retina. UWFA image (right panel) of the same patient showing telangiectatic vessels and peripheral non-perfusion.

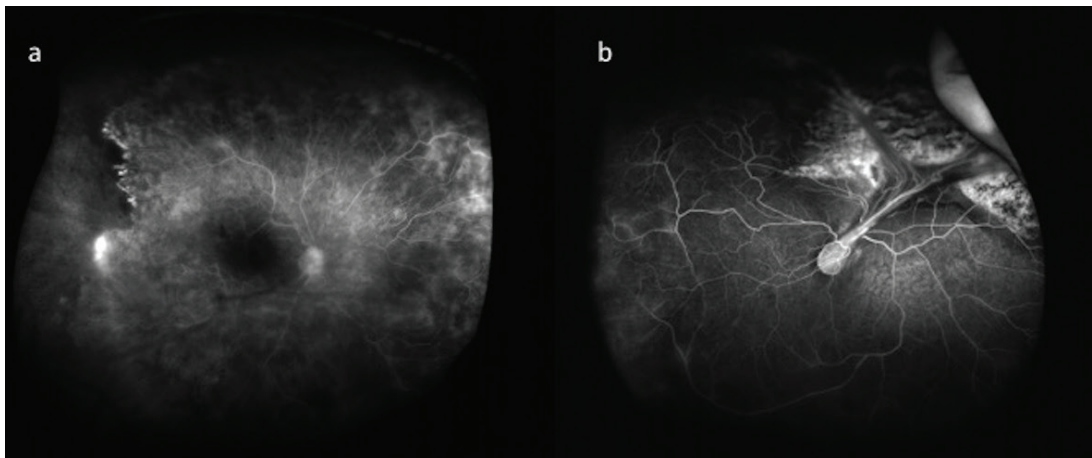


Figure 15.
UWFA image of the right (a) and left eye (b) of a patient with FEVR. Marked peripheral retinal non-perfusion and NVE (a) and severe macular dragging due to falciform retinal fold (b) is noted.

7.9 Miscellaneous diseases

UWFA shows peripheral perfusion abnormalities not previously recognized in myopic eyes. Retinal vasculature in the peripheral retina is significantly altered in eyes with axial myopia. This may be associated to a mechanical stretching [56].

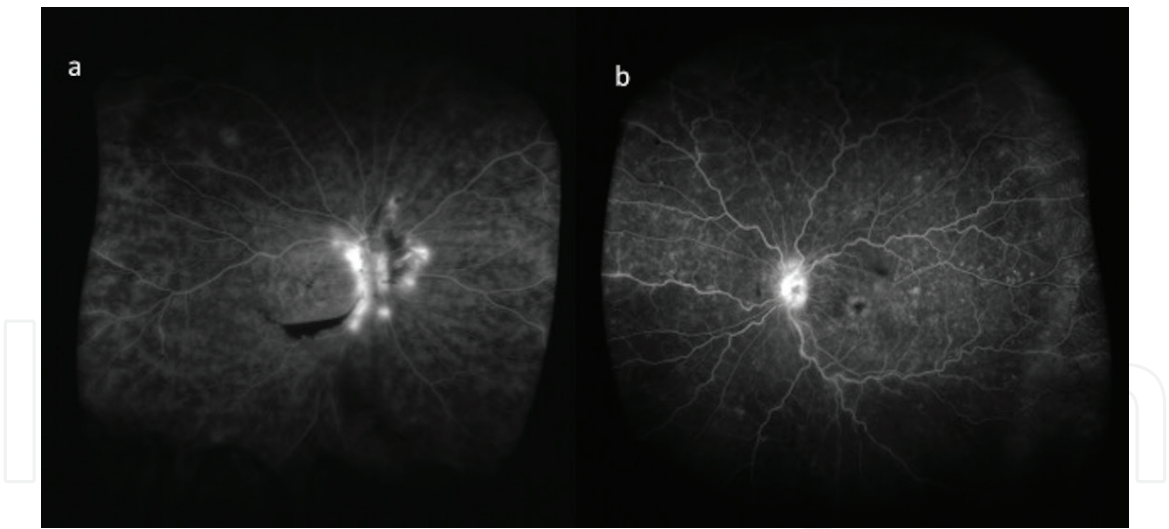


Figure 16.
Diffuse vasculitic leakage and neovascularization at disc (NVD) in a case with Behçet's disease (a) and diffuse vasculitic leakage and macular edema in a patient with idiopathic retinal vasculitis (b).

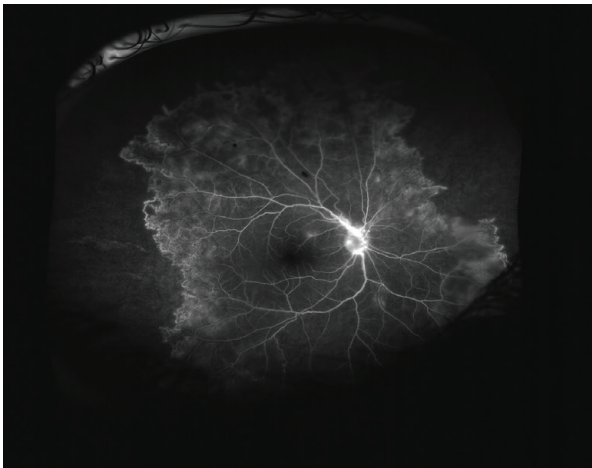

Figure 17.
Wide-field fundus photograph and UWFA image of the left eye of a patient with Eales disease. Peripheral ischemia in the nasal and temporal quadrants accompanied by collateral formation and NVD.

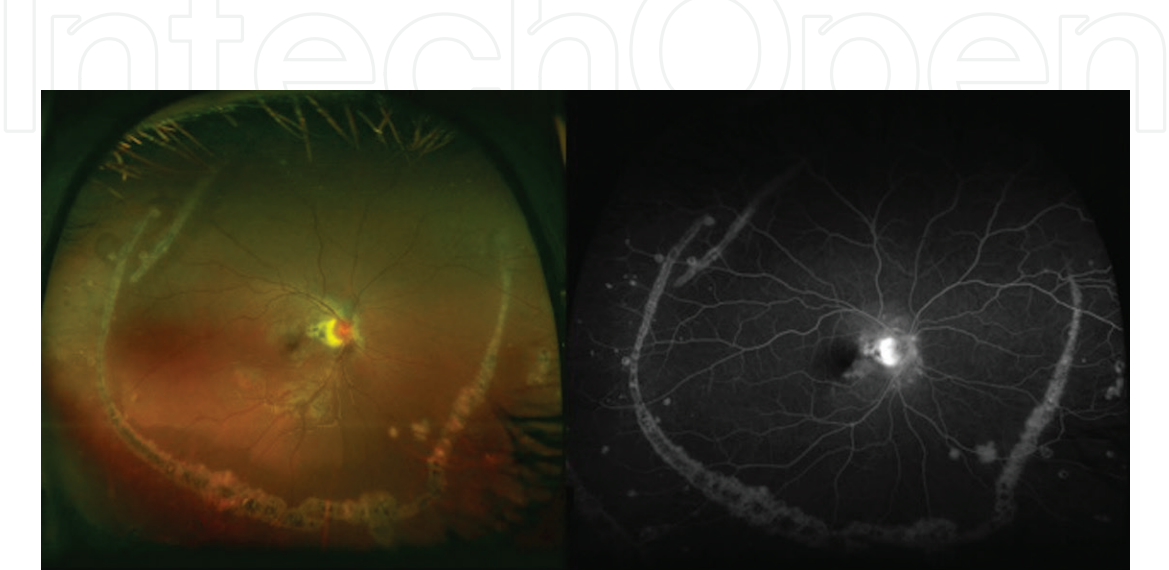


Figure 18.
Wide-field fundus photograph and UWFA images of the right eye showing mid-peripheral linear lesions (Schlaegel lines) and secondary peripapillary CNV. This patient was diagnosed with multifocal choroiditis.

UWFI has shown a significant association between Alzheimer's disease and peripheral hard drusen formation [57].

8. Limitations of wide-field imaging systems

The eyeball is a three-dimensional structure. Since a two-dimensional image is obtained with a wide-field system, there are peripheral aberrations in the image. Because of the ellipsoid mirror used, lesions in the retinal periphery appear larger, with a slight distortion [58]. As this distortion and enlargement are variable in different directions, capturing should be done at the same direction as possible [24]. The Optomap system displays an area of 200° in the horizontal plane, while the vertical plane displays an area of 170° [58]. Evaluation of the retinal periphery, especially in the lower quadrant due to eyelashes, is difficult [1, 59]. **Figure 19** shows an image artifact caused by eyelashes.

Limitations of the Optos include laser artifacts, abnormal colors, and lack of stereopsis [9]. Also, resolution of the macula area is lower than that of standard fundus cameras [1]. Wide-angle retinal imaging with the use of a contact lens, such as the Staurenghi lens, expanded the view to 150° but is technically more challenging and requires high patient cooperation [12]. HRA is an alternative to Optos system in peripheral retinal imaging and each has its own advantages and disadvantages. A recent study has demonstrated that UWFA with the Optos system is able to capture a significantly wider total retinal area when compared to the Heidelberg noncontact system particularly in the nasal and temporal quadrants [60]. Although it was not found statistically significant, Heidelberg system was able to obtain a wider area in the superior and inferior quadrants. In contrast, Optos showed more peripheral distortion and greater variability in image quality, largely due to eyelash artifacts [60].

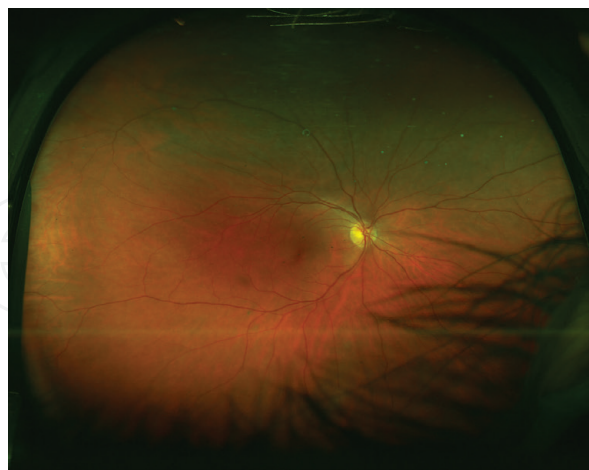

Figure 19.
Limited view in the lower quadrant due to eyelash artifacts.

9. Future directions

The future goal in retinal imaging is to capture a high-resolution image of the whole retina with the finest details. Devices that allow ultra-wide-field retinal imaging may be miniaturized, thus enhancing portability. These systems may also be integrated with smartphones, therefore facilitating telemedicine applications.

A novel smartphone-based wide-field retinal camera capable of capturing high-quality fundus images was previously described [61]. Nonphysician operators may also be trained to acquire retinal images for remote evaluation [62].

Different diagnostic tools embedded in one device will offer more cost- and time-efficient systems. A multimodal device combining conventional wide-field fundus photography, OCT, FA, FAF, ICGA, adaptive optics, and OCT angiography would be a step forward in retinal diagnostic testing. Incorporating a treatment utility such as laser photocoagulation into a multimodal diagnostic tool would be revolutionary in retina clinical practice.

10. Conclusion

The use of wide-field imaging systems for clinical applications and researches is increasing. In the future, the role of these imaging systems in the diagnosis, follow-up, and treatment of retinal diseases will continue to be demonstrated in comparative studies.

Acknowledgements

The authors would like to thank Dr. Eray Atalay for his help in final proof reading of the manuscript.

Conflict of interest

The authors declare that they do not have any financial conflict of interest related to the study.

Notes/thanks/other declarations

All images used in the section are from our archives of Optos and Retcam device.

Author details

Mustafa Değer Bilgeç¹, Nazmiye Erol¹ and Seyhan Topbaş^{2*}

1 Ophthalmology Department, Eskisehir Osmangazi University Medical School, Eskisehir, Turkey

2 Private Umit Hospital Ophthalmology Department, Eskisehir, Turkey

*Address all correspondence to: stopbas@ogu.edu.tr

IntechOpen

© 2019 The Author(s). Licensee IntechOpen. This chapter is distributed under the terms of the Creative Commons Attribution License (<http://creativecommons.org/licenses/by/3.0>), which permits unrestricted use, distribution, and reproduction in any medium, provided the original work is properly cited. 

References

- [1] Witmer MT, Kiss S. Wide-field imaging of the retina. *Survey of Ophthalmology*. 2013;**58**(2):143-154. DOI: 10.1016/j.survophthal.2012.07.003
- [2] Sim DA, Keane PA, Rajendram R, Karampelas M, Selvam S, Powner MB, et al. Patterns of peripheral retinal and central macula ischemia in diabetic retinopathy as evaluated by ultra-widefield fluorescein angiography. *American Journal of Ophthalmology*. 2014;**158**(1):e141, 144-153. DOI: 10.1016/j.ajo.2014.03.009
- [3] Diabetic Retinopathy Study. Report Number 6. Design, methods, and baseline results. Report Number 7. A modification of the Airlie House classification of diabetic retinopathy. Prepared by the Diabetic Retinopathy. *Investigative Ophthalmology & Visual Science*. 1981;**21**(1 Pt 2):1-226
- [4] Manivannan A, Plskova J, Farrow A, McKay S, Sharp PF, Forrester JV. Ultra-wide-field fluorescein angiography of the ocular fundus. *American Journal of Ophthalmology*. 2005;**140**(3):525-527. DOI: 10.1016/j.ajo.2005.02.055
- [5] Friberg TR, Gupta A, Yu J, Huang L, Suner I, Puliafito CA, et al. Ultrawide angle fluorescein angiographic imaging: A comparison to conventional digital acquisition systems. *Ophthalmic Surgery, Lasers & Imaging*. 2008;**39**(4):304-311
- [6] Patel M, Kiss S. Ultra-wide-field fluorescein angiography in retinal disease. *Current Opinion in Ophthalmology*. 2014;**25**(3):213-220. DOI: 10.1097/ICU.0000000000000042
- [7] Nagiel A, Lalane RA, Sadda SR, Schwartz SD. Ultra-widefield fundus imaging: A review of clinical applications and future trends. *Retina*. 2016;**36**(4):660-678. DOI: 10.1097/IAE.0000000000000937
- [8] Mark HH. On the evolution of binocular ophthalmoscopy. *Archives of Ophthalmology*. 2007;**125**(6):830-833. DOI: 10.1001/archophth.125.6.830
- [9] Leung EH, Rosen R. Fundus imaging in wide-field: A brief historical journey. In: Kozak I, Arévalo JF, editors. *Atlas of Wide-Field Retinal Angiography and Imaging*. 1st ed. Switzerland: Springer International Publishing; 2016. pp. 1-25. DOI: 10.1007/978-3-319-17864-6
- [10] Pomerantzeff O. Wide-angle noncontact and small-angle contact cameras. *Investigative Ophthalmology & Visual Science*. 1980;**19**(8):973-979
- [11] Shields CL, Materin M, Shields JA. Panoramic imaging of the ocular fundus. *Archives of Ophthalmology*. 2003;**121**(11):1603-1607. DOI: 10.1001/archophth.121.11.1603
- [12] Staurengi G, Viola F, Mainster MA, Graham RD, Harrington PG. Scanning laser ophthalmoscopy and angiography with a wide-field contact lens system. *Archives of Ophthalmology*. 2005;**123**(2):244-252. DOI: 10.1001/archophth.123.2.244
- [13] Pomerantzeff O. Equator-plus camera. *Investigative Ophthalmology*. 1975;**14**(5):401-406
- [14] Reeves GM, Kumar N, Beare NA, Pearce IA. Use of Staurengi lens angiography in the management of posterior uveitis. *Acta Ophthalmologica*. 2013;**91**(1):48-51. DOI: 10.1111/j.1755-3768.2011.02200.x
- [15] Dhaliwal C, Wright E, Graham C, McIntosh N, Fleck BW. Wide-field digital retinal imaging versus binocular indirect ophthalmoscopy for retinopathy of prematurity screening: A two-observer prospective, randomised comparison. *The British Journal of*

Ophthalmology. 2009;**93**(3):355-359.
DOI: 10.1136/bjo.2008.148908

[16] Klufas MA, Yannuzzi NA, Pang CE, Srinivas S, Sadda SR, Freund KB, et al. Feasibility and clinical utility of ultra-widefield indocyanine green angiography. *Retina*. 2015;**35**(3):508-520. DOI: 10.1097/IAE.0000000000000318

[17] Yannuzzi LA, Ober MD, Slakter JS, Spaide RF, Fisher YL, Flower RW, et al. Ophthalmic fundus imaging: Today and beyond. *American Journal of Ophthalmology*. 2004;**137**(3):511-524. DOI: 10.1016/j.ajo.2003.12.035

[18] Erol N. Wide angle imaging: Technique, indications and assessment (analysis). *Turkiye Klinikleri Journal of Ophthalmology*. 2015;**8**(2):30-37

[19] Delori FC, Dorey CK, Staurengi G, Arend O, Goger DG, Weiter JJ. In vivo fluorescence of the ocular fundus exhibits retinal pigment epithelium lipofuscin characteristics. *Investigative Ophthalmology & Visual Science*. 1995;**36**(3):718-729

[20] Heussen FM, Tan CS, Sadda SR. Prevalence of peripheral abnormalities on ultra-widefield greenlight (532 nm) autofluorescence imaging at a tertiary care center. *Investigative Ophthalmology & Visual Science*. 2012;**53**(10):6526-6531. DOI: 10.1167/iovs.12-9909

[21] Heussen FM, Puliafito CA, Sadda SR. Wide-field autofluorescence. In: Kozak I, Arévalo JF, editors. *Atlas of Wide-Field Retinal Angiography and Imaging*. 1st ed. Switzerland: Springer International Publishing; 2016. pp. 49-57. DOI: 10.1007/978-3-319-17864-6

[22] Pang CE, Shah VP, Sarraf D, Freund KB. Ultra-widefield imaging with autofluorescence and indocyanine green angiography in central serous

chorioretinopathy. *American Journal of Ophthalmology*. 2014;**158**(2):362-371. e362. DOI: 10.1016/j.ajo.2014.04.021

[23] Lu J, Mai G, Luo Y, Li M, Cao D, Wang X, et al. Appearance of far peripheral retina in normal eyes by ultra-widefield fluorescein angiography. *American Journal of Ophthalmology*. 2017;**173**:84-90. DOI: 10.1016/j.ajo.2016.09.024

[24] Singer M, Sagong M, van Hemert J, Kuehlewein L, Bell D, Sadda SR. Ultra-widefield imaging of the peripheral retinal vasculature in normal subjects. *Ophthalmology*. 2016;**123**(5):1053-1059. DOI: 10.1016/j.ophtha.2016.01.022

[25] Shimizu K, Kobayashi Y, Muraoka K. Midperipheral fundus involvement in diabetic retinopathy. *Ophthalmology*. 1981;**88**(7):601-612

[26] Wessel MM, Aaker GD, Parlitsis G, Cho M, D'Amico DJ, Kiss S. Ultra-wide-field angiography improves the detection and classification of diabetic retinopathy. *Retina*. 2012;**32**(4):785-791. DOI: 10.1097/IAE.0b013e3182278b64

[27] Patel RD, Messner LV, Teitelbaum B, Michel KA, Hariprasad SM. Characterization of ischemic index using ultra-widefield fluorescein angiography in patients with focal and diffuse recalcitrant diabetic macular edema. *American Journal of Ophthalmology*. 2013;**155**(6):1038-1044 e 1032. DOI: 10.1016/j.ajo.2013.01.007

[28] Wessel MM, Nair N, Aaker GD, Ehrlich JR, D'Amico DJ, Kiss S. Peripheral retinal ischaemia, as evaluated by ultra-widefield fluorescein angiography, is associated with diabetic macular oedema. *The British Journal of Ophthalmology*. 2012;**96**(5):694-698. DOI: 10.1136/bjophthalmol-2011-300774

[29] Kernt M, Hadi I, Pinter F, Seidensticker F, Hirneiss C, Haritoglou C,

- et al. Assessment of diabetic retinopathy using nonmydriatic ultra-widefield scanning laser ophthalmoscopy (Optomap) compared with ETDRS 7-field stereo photography. *Diabetes Care*. 2012;**35**(12):2459-2463. DOI: 10.2337/dc12-0346
- [30] Silva PS, Cavallerano JD, Sun JK, Noble J, Aiello LM, Aiello LP. Nonmydriatic ultrawide field retinal imaging compared with dilated standard 7-field 35-mm photography and retinal specialist examination for evaluation of diabetic retinopathy. *American Journal of Ophthalmology*. 2012;**154**(3):549-559. e542. DOI: 10.1016/j.ajo.2012.03.019
- [31] Rasmussen ML, Broe R, Frydkjaer-Olsen U, Olsen BS, Mortensen HB, Peto T, et al. Comparison between early treatment diabetic retinopathy study 7-field retinal photos and non-mydratic, mydratic and mydratic steered widefield scanning laser ophthalmoscopy for assessment of diabetic retinopathy. *Journal of Diabetes and its Complications*. 2015;**29**(1):99-104. DOI: 10.1016/j.jdiacomp.2014.08.009
- [32] Silva PS, Cavallerano JD, Sun JK, Soliman AZ, Aiello LM, Aiello LP. Peripheral lesions identified by mydratic ultrawide field imaging: Distribution and potential impact on diabetic retinopathy severity. *Ophthalmology*. 2013;**120**(12):2587-2595. DOI: 10.1016/j.ophtha.2013.05.004
- [33] Rogers S, McIntosh RL, Cheung N, Lim L, Wang JJ, Mitchell P, et al. The prevalence of retinal vein occlusion: Pooled data from population studies from the United States, Europe, Asia, and Australia. *Ophthalmology*. 2010;**117**(2):313-319, e311. DOI: 10.1016/j.ophtha.2009.07.017
- [34] Tsui I, Bajwa A, Franco-Cardenas V, Pan CK, Kim HY, Schwartz SD. Peripheral fluorescein angiographic findings in fellow eyes of patients with branch retinal vein occlusion. *International Journal of Inflammation*. 2013;**2013**. DOI: 10.1155/2013/464127
- [35] Prasad PS, Oliver SC, Coffee RE, Hubschman JP, Schwartz SD. Ultra wide-field angiographic characteristics of branch retinal and hemicentral retinal vein occlusion. *Ophthalmology*. 2010;**117**(4):780-784. DOI: 10.1016/j.ophtha.2009.09.019
- [36] Noma H, Minamoto A, Funatsu H, Tsukamoto H, Nakano K, Yamashita H, et al. Intravitreal levels of vascular endothelial growth factor and interleukin-6 are correlated with macular edema in branch retinal vein occlusion. *Graefes Archive for Clinical and Experimental Ophthalmology*. 2006;**244**(3):309-315. DOI: 10.1007/s00417-004-1087-4
- [37] Tsui I, Prasad PS. Wide-field retinal imaging of central retinal vein occlusions. In: Kozak I, Arévalo JF, editors. *Atlas of Wide-Field Retinal Angiography and Imaging*. 1st ed. Switzerland: Springer International Publishing; 2016. pp. 83-91. DOI: 10.1007/978-3-319-17864-6
- [38] Spaide RF. Peripheral areas of nonperfusion in treated central retinal vein occlusion as imaged by wide-field fluorescein angiography. *Retina*. 2011;**31**(5):829-837. DOI: 10.1097/IAE.0b013e31820c841e
- [39] Tsui I, Kaines A, Havunjian MA, Hubschman S, Heilweil G, Prasad PS, et al. Ischemic index and neovascularization in central retinal vein occlusion. *Retina*. 2011;**31**(1):105-110. DOI: 10.1097/IAE.0b013e3181e36c6d
- [40] Jain A, Shah SP, Tsui I, McCannel TA. The value of Optos Panoramic 200MA imaging for the monitoring of large suspicious choroidal lesions. *Seminars in Ophthalmology*.

2009;**24**(1):43-44. DOI:
10.1080/08820530802520384

[41] Kernt M, Schaller UC, Stumpf C, Ulbig MW, Kampik A, Neubauer AS. Choroidal pigmented lesions imaged by ultra-wide-field scanning laser ophthalmoscopy with two laser wavelengths (Optomap). *Clinical Ophthalmology*. 2010;**4**:829-836

[42] Coffee RE, Jain A, McCannel TA. Ultra wide-field imaging of choroidal metastasis secondary to primary breast cancer. *Seminars in Ophthalmology*. 2009;**24**(1):34-36. DOI: 10.1080/08820530802520194

[43] Kornberg DL, Klufas MA, Yannuzzi NA, Orlin A, D'Amico DJ, Kiss S. Clinical utility of ultra-widefield imaging with the optos optomap compared with indirect ophthalmoscopy in the setting of non-traumatic rhegmatogenous retinal detachment. *Seminars in Ophthalmology*. 2016;**31**(5):505-512. DOI: 10.3109/08820538.2014.981551

[44] Reznicek L, Wasfy T, Stumpf C, Kampik A, Ulbig M, Neubauer AS, et al. Peripheral fundus autofluorescence is increased in age-related macular degeneration. *Investigative Ophthalmology & Visual Science*. 2012;**53**(4):2193-2198. DOI: 10.1167/iops.11-8483

[45] Tan CS, Heussen F, Sadda SR. Peripheral autofluorescence and clinical findings in neovascular and non-neovascular age-related macular degeneration. *Ophthalmology*. 2013;**120**(6):1271-1277. DOI: 10.1016/j.ophtha.2012.12.002

[46] Patel CK, Fung TH, Muqit MM, Mordant DJ, Brett J, Smith L, et al. Non-contact ultra-widefield imaging of retinopathy of prematurity using the Optos dual wavelength scanning laser ophthalmoscope. *Eye (London,*

England). 2013;**27**(5):589-596. DOI: 10.1038/eye.2013.45

[47] Scott KE, Kim DY, Wang L, Kane SA, Coki O, Starren J, et al. Telemedical diagnosis of retinopathy of prematurity intraphysician agreement between ophthalmoscopic examination and image-based interpretation. *Ophthalmology*. 2008;**115**(7):1222-1228e1223. DOI: 10.1016/j.ophtha.2007.09.006

[48] Kang KB, Orlin A, Lee TC, Chiang MF, Chan RV. The use of digital imaging in the identification of skip areas after laser treatment for retinopathy of prematurity and its implications for education and patient care. *Retina*. 2013;**33**(10):2162-2169. DOI: 10.1097/IAE.0b013e31828e6969

[49] Tsui I, Franco-Cardenas V, Hubschman JP, Schwartz SD. Pediatric retinal conditions imaged by ultra wide field fluorescein angiography. *Ophthalmic Surgery, Lasers and Imaging Retina*. 2013;**44**(1):59-67. DOI: 10.3928/23258160-20121221-14

[50] Kang KB, Wessel MM, Tong J, D'Amico DJ, Chan RV. Ultra-widefield imaging for the management of pediatric retinal diseases. *Journal of Pediatric Ophthalmology and Strabismus*. 2013;**50**(5):282-288. DOI: 10.3928/01913913-20130528-04

[51] Kashani AH, Brown KT, Chang E, Drenser KA, Capone A, Trese MT. Diversity of retinal vascular anomalies in patients with familial exudative vitreoretinopathy. *Ophthalmology*. 2014;**121**(11):2220-2227. DOI: 10.1016/j.ophtha.2014.05.029

[52] Campbell JP, Leder HA, Sepah YJ, Gan T, Dunn JP, Hatef E, et al. Wide-field retinal imaging in the management of noninfectious posterior uveitis. *American Journal of Ophthalmology*. 2012;**154**(5):908-911, e902. DOI: 10.1016/j.ajo.2012.05.019

- [53] Tsui I, Kaines A, Schwartz S. Patterns of periphlebitis in intermediate uveitis using ultra wide field fluorescein angiography. *Seminars in Ophthalmology*. 2009;24(1):29-33. DOI: 10.1080/08820530802520186
- [54] Kaines A, Tsui I, Sarraf D, Schwartz S. The use of ultra wide field fluorescein angiography in evaluation and management of uveitis. *Seminars in Ophthalmology*. 2009;24(1):19-24. DOI: 10.1080/08820530802520095
- [55] Mesquida M, Llorenc V, Fontenla JR, Navarro MJ, Adan A. Use of ultra-wide-field retinal imaging in the management of active Behcet retinal vasculitis. *Retina*. 2014;34(10):2121-2127. DOI: 10.1097/IAE.0000000000000197
- [56] Kaneko Y, Moriyama M, Hirahara S, Ogura Y, Ohno-Matsui K. Areas of nonperfusion in peripheral retina of eyes with pathologic myopia detected by ultra-widfield fluorescein angiography. *Investigative Ophthalmology & Visual Science*. 2014;55(3):1432-1439. DOI: 10.1167/iovs.13-13706
- [57] Csincsik L, Mac Gillivray TJ, Flynn E, Pellegrini E, Papanastasiou G, Barzegar-Befroei N, et al. Peripheral retinal imaging biomarkers for Alzheimer's disease: A pilot study. *Ophthalmic Research*. 2018;59(4):182-192. DOI: 10.1159/000487053
- [58] Oishi A, Hidaka J, Yoshimura N. Quantification of the image obtained with a wide-field scanning ophthalmoscope. *Investigative Ophthalmology & Visual Science*. 2014;55(4):2424-2431. DOI: 10.1167/iovs.13-13738
- [59] Mackenzie PJ, Russell M, Ma PE, Isbister CM, Maberley DA. Sensitivity and specificity of the optos optomap for detecting peripheral retinal lesions. *Retina*. 2007;27(8):1119-1124. DOI: 10.1097/IAE.0b013e3180592b5c
- [60] Witmer MT, Parlitsis G, Patel S, Kiss S. Comparison of ultra-widfield fluorescein angiography with the Heidelberg Spectralis((R)) noncontact ultra-widfield module versus the Optos((R)) Optomap((R)). *Clinical Ophthalmology*. 2013;7:389-394. DOI: 10.2147/OPTH.S41731
- [61] Maamari RN, Keenan JD, Fletcher DA, Margolis TP. A mobile phone-based retinal camera for portable wide field imaging. *The British Journal of Ophthalmology*. 2014;98(4):438-441. DOI: 10.1136/bjophthalmol-2013-303797
- [62] Fijalkowski N, Zheng LL, Henderson MT, Wang SK, Wallenstein MB, Leng T, et al. Stanford University Network for Diagnosis of Retinopathy of Prematurity (SUNDRP): Five years of screening with telemedicine. *Ophthalmic Surgery, Lasers and Imaging Retina*. 2014;45(2):106-113. DOI: 10.3928/23258160-20140122-01