

We are IntechOpen, the world's leading publisher of Open Access books Built by scientists, for scientists

6,900

Open access books available

185,000

International authors and editors

200M

Downloads

Our authors are among the

154

Countries delivered to

TOP 1%

most cited scientists

12.2%

Contributors from top 500 universities



WEB OF SCIENCE™

Selection of our books indexed in the Book Citation Index
in Web of Science™ Core Collection (BKCI)

Interested in publishing with us?
Contact book.department@intechopen.com

Numbers displayed above are based on latest data collected.
For more information visit www.intechopen.com



Alar Rim Grafts

*Pedro S. Arquero, Wenceslao M. Calonge, Daniel P. Espinoza
and Diana Oesch*

Abstract

Alar rim grafts date back to the 1950s for the correction of alar base in cleft lip nose. Cartilage struts under the anterior half of the *alae* of a pinched nose tip were popularised and the cartilage of the auricular concha became the donor site of choice for nasal procedures. Recently, some surgeons pointed to its potential role in aesthetic cases and added some technical refinements. These grafts are used for open and closed rhinoplasties. They usually consist of a rod of septal or auricular cartilage that we lay as reinforcement inside a pocket along the alar margin. Indications include the following: congenital or traumatic asymmetry, dynamic alar collapse, alar flare, primary retraction or notching, secondary (surgical or traumatic) retraction and malposition of the lateral cartilages (upwards or downwards). Harvesting and implanting techniques as well as the possible drawbacks are discussed.

Keywords: graft, alar, nose, cartilage, rhinoplasty

1. Introduction

In spite of deep inspiration, nasal tip maintains its general shape through different mechanisms. Major mechanisms include *medialis* and *lateralis* cartilages, the fibrous union between both *crus medialis* to the caudal septum and the ligaments that bind the caudal aspect of the superior lateral cartilages to the cephalic aspect of the inferior lateral cartilages. Secondary mechanisms encompass the cartilaginous septal dorsum, interdomal ligaments, the membranous septum, the nasal spine, the adherence between skin soft tissues and alar cartilages as well as the lateral alar walls (**Figure 1**).

Normal alar contour is defined by well-defined alar margins and extension from the tip lobe to the alar lobe. The inferior lateral cartilages act as a dynamic spring that can resist small traumatism, providing some elasticity to the nasal tip to prevent a collapse of the nasal *alae* during inspiration.

Positioning of the alar cartilages is a fundamental element when planning a rhinoplasty. An overenthusiastic resection may cause their weakness and inability to perform their sustaining role.

An inadequate positioning of the alar cartilages entails an instable Anderson tripod with alar pinching. This may be a consequence of the resection of ligaments and the septal angle in order to achieve a reduction in nasal tip projection in open rhinoplasty procedures.

Less frequently, inborn asymmetries of the alar cartilages produce unbalance and rotation of the nasal tip. Moreover, some patients may suffer from a cephalad

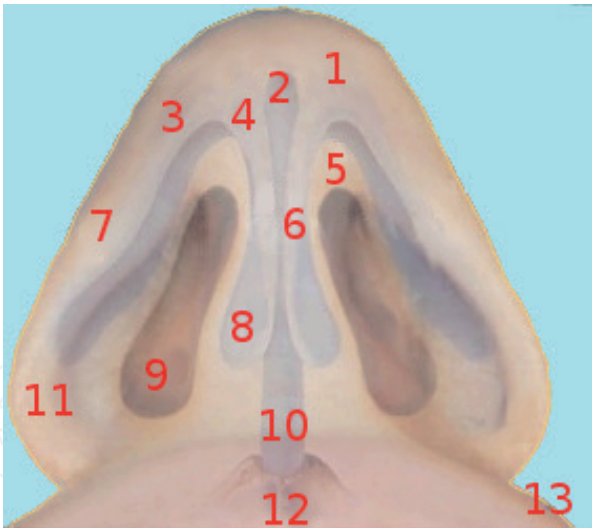


Figure 1.
A representation of the main cartilages from a basal perspective: 1. domus; 2. septal angle; 3. crus lateralis; 4. crus intermedia; 5. soft triangle; 6. crus medialis; 7. rima alaris; 8. 'feet' of the crura medialis; 9. nostrils; 10. caudal septum; 11. lobe of the nasal ala; 12. anterior nasal spine; and 13. nasolabial ridge.

rotation of the alar cartilages; they may orientate their main axis toward the inner cantus without giving adequate support to the external valve.

2. Historical notes

Alar and perialar rim grafts are rods or little splints made of cartilage. They are placed under the caudal margin of alar cartilages. They may be applied for primary and secondary rhinoplasty. Alar rim grafts were heralded as early as the 1950s by Fomon [1, 2] and Denecke [3] for the correction of alar base in cleft lip nose. Composite paranasal grafts on the nasal mucosa (instead of *under*) were an

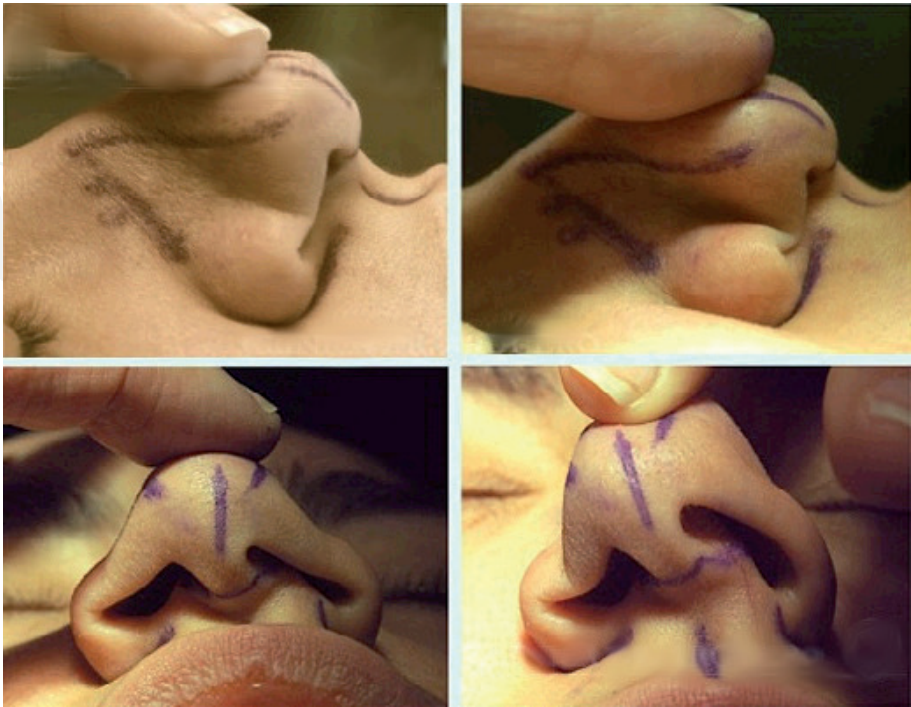


Figure 2.
Testing of the general elasticity and passive collapse of the nasal tip and alae.

Congenital asymmetry
Dynamic alar collapse
Alar flare (without functional impairment)
Primary retraction or notching
Secondary (surgical or traumatic) retraction as in pinched tip
Malposition of the lateral cartilages (upwards/downwards, bulbous tip, square tip)
Congenital microrrhinia (all nasal dimensions affected as seen in foetal alcoholic syndrome)

Table 1.
Main indications for alar rim grafts.

interesting, easier variation proposed by Farrior [4]. However, these techniques had a moderate predicament for the treatment of stenoses of the vestibule [5, 6]. In a parallel evolution, cartilage struts under the anterior half of the *alae* of a pinched nose tip were popularised, while the cartilage of the auricular concha became the donor site of choice for nasal procedures [7].

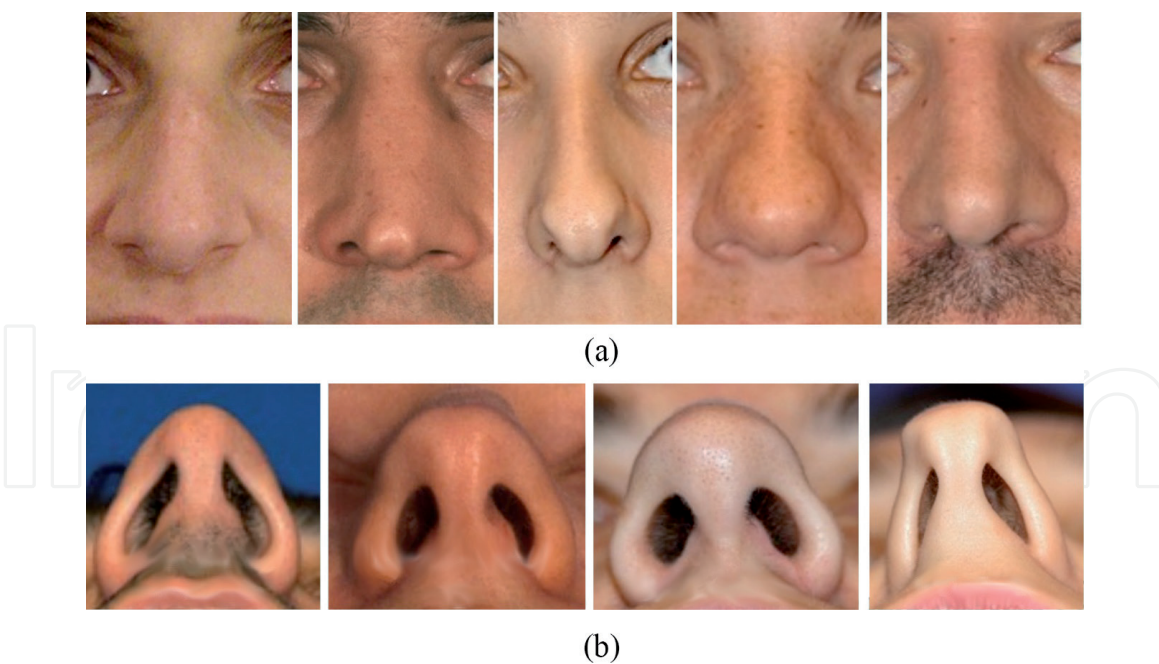
With greater emphasis focused on correcting the collapse of the internal valve, this approach by alar rim grafts was a sleeper. It was not until recent times when some surgeons [8–10] pointed to its potential role in aesthetic cases and added some technical refinements (**Figure 2**).

Alar rim grafts may be used for treatment and prevention of disorders of the nasal tip outline. They have been advised for the treatment of alar deformities. These deformities may stem not only from malposition or congenital hypoplasia of inferior lateral cartilages but also from a loss of continuity or a weakening of *crus lateralis* as a result of previous surgeries [11]. In rare cases, scar tissue may cause local *synechiae* that easily resolve with local section [12] (**Table 1**).

3. Pre-operative assessment

The position and dimension of the nasal *alae* must be assessed from frontal, lateral and basal points of view. As a rule of thumb, the distance between each inner cantus of the eyelids is roughly equivalent to the width of nasal base in frontal view. An ideal nasal base is schematised as an equilateral triangle. However, there is considerable interethnic variability. In shallow, general speaking, patients with East Asian and African ancestry may present a wider base [13]. The alar contour displays an oval nostril, and the alar fringe follows a smooth curvature with an inferior concavity. According to the distances between columella-nose axis and alar rim-nose axis, we may consider four different alterations of the alar position [14, 15] (**Figure 3A and B**):

- alar retraction—an elevation of the inferior concavity of the arch;
- hanging alar rim;
- retracted columella; and
- hanging columella—the inner mucosal lining of the medial aspect of each narine is conspicuous.

**Figure 3.**

(A) Anatomical variations and primary alterations of alar contour include (from left to right) pinched lobes, undulating alar cartilages, visible margins, bulbous tip and parallel orientation of both alar cartilages. (B) Some features that may involve alar rim grafts as a treatment include (from left to right) lack of sustentation of alar rim, high positioned soft triangle, bulbous tip and square tip.

Functional primary disturbances may be the main motivation for a rhinoplasty (though they are also seen as an undesired side effect of a previous operation). These disturbances may cause difficulties in breathing, altered olfactory function, bleeding and frequent infection. Pre-operative rhinoscopy in order to exclude upper functional conditions (septal deviation, hypertrophic cornets, collapse of the upper internal valve and polyps) must be always carried out. A hanging tip is assessed by pinching the skin of the nasal dorsum. The collapse of the upper internal valve is sometimes evident after mild finger traction on the maxillary ascending apophysis. A cotton tip moisturised in adrenaline produces vasoconstriction and reduction in the size of hypertrophied cornets. A collapse of the lower valve may be corrected by gently opening the tweezers inside the air passage.

4. Surgical technique

Inspection of the nasal external valve constitutes an unavoidable step toward the end of any rhinoplasty procedure. Whenever we have performed a reduction of the projection of the nasal tip, we shall get an alar excess. Scar lines or excessive resection may entail a narrowing of the air passage. We use these grafts for open and closed rhinoplasties. The graft consists of a rod of septal or auricular cartilage (**Figure 4A, B and 5**) that we lay as reinforcement inside a pocket along the alar margin. We perform an incision (less than 5 mm) on the hairy area of alar *vestibulum* (scarcely two-or-three millimetres away from the narine marge) by means of a number 11 blade. We use blunt scissors to create a double pocket backwards to the alar lobe and frontwards to the soft triangle (**Figure 6**). Some authors propose infiltration with 1% lidocaine with epinephrine in the skin caudal to the marginal incision [12]. In the so-created tunnels, we lay our rod of cartilage (from 1 × 6 mm up to 2 × 12 mm), from incision to back in the posterior tunnel and from incision to front in the anterior tunnel. We perform a single stitch in reabsorbable polydioxanone (PDS[®] 5/0). We must crush the anterior shaft with the tissue forceps in order

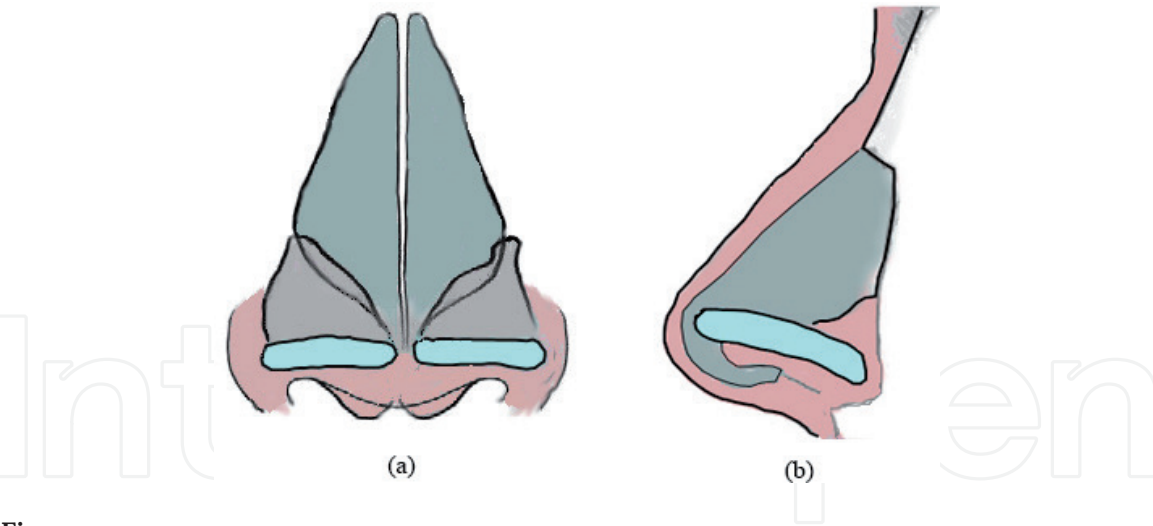


Figure 4.
(A) A sketch of the positioned alar rim graft in a frontal view. (B) The positioned alar rim graft in a lateral view.

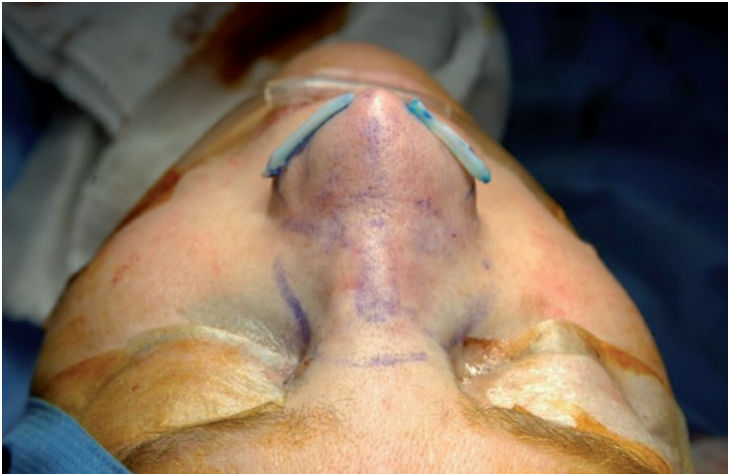


Figure 5.
Intraoperative appreciation of the required length of grafts.

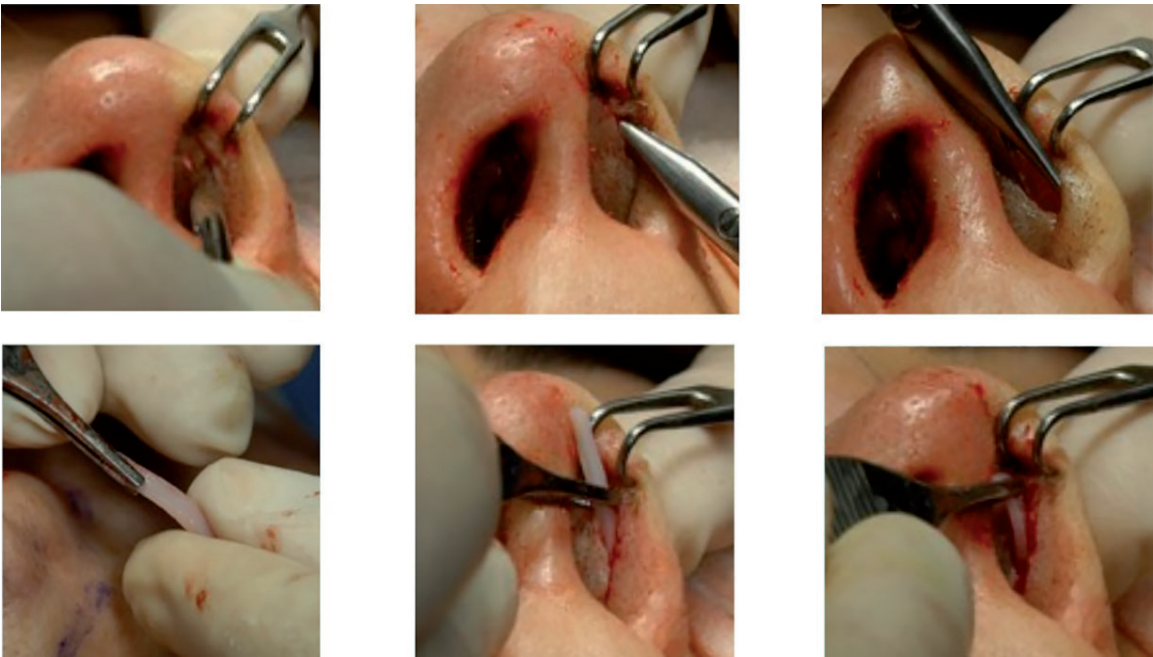


Figure 6.
Incision, blunt dissection and insertion of an alar rim graft.

to prevent it from exteriorizing through the skin. In any case, the graft should never extend anterior to the nasal tip [16, 17]. It must never widen the tip or be palpable [18]. We usually perform this step at the end of the procedure. We can check the final texture of the nasal tip and *alae* by pressing with fingertips or tissue forceps. Alar rim grafts allow us to caudally displace the alar rim margin up to 2 mm but this small gain reveals itself crucial in many cases. Whenever the alar rim graft is an isolated procedure, a safe, less traumatic way to incise the skin maybe achieved by using an ophthalmic slit blade [19].

5. Variations

When performing an open rhinoplasty, we use the same pre-rimal incision. Thus, we can check the symmetry of graft positioning. When performing a closed rhinoplasty, we place the grafts through a marginal incision (1 mm from the alar rim) and we extend the pocket frontwards to the soft triangle and backwards to the caudal end of the ala. We first lay the graft inside the posterior pocket and by careful sliding, we position its crushed edge inside the anterior pocket.

An alternative method involves conchal cartilage extension grafts fixed to the caudal margins of the lateral crura as described by Jang et al. [20]. This hybrid method focuses on correcting anterior contraction of the alar rim as seen in East Asian patients with nostril exposure. Alar vestibular skin is dissected at the end of an open approach for augmentation rhinoplasty. Conchal cartilage grafts are fashioned in a semilunar shape (13 mm × 6 mm) and sutured to the caudal margins of each *crus lateralis*.

Articulated alar rim grafts [21, 22] stand as an interesting concept. In this widespread variation, the anterior margin of each alar rim graft is sutured to the tip complex instead of just being freely sited in a pocket. Emphasis is mainly made to stabilise the nasal tip.

A peculiar variation [23] elevates a 2–3 mm flap from the caudal portion of the *crus lateralis*, pulls it caudally and extends it with a cartilage graft. This extension of the alar rim flap is placed along the alar rim for support.

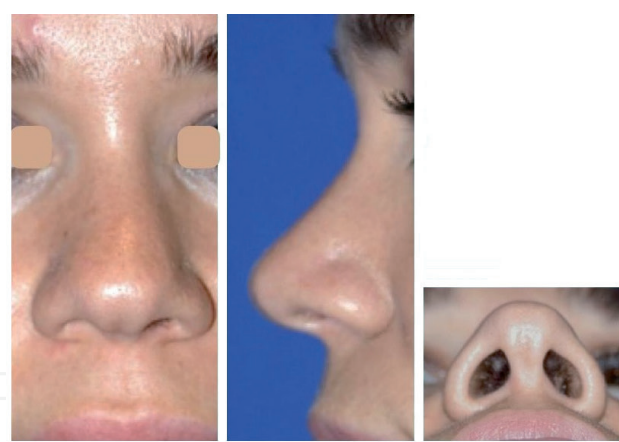
Selected cases of external nasal valve collapse as an isolated condition have been treated by a microinvasive technique that creates the pocket from the cutaneous, facial aspect of the posterior margin of the ala [24].

Needless to say, versatile surgeons should bear in mind alternative donor sites as part of their armamentarium [25]. A posterior incision is the less conspicuous choice when taking conchal grafts. Adequate semicompressive dressings and anaesthetic infiltration of the margins of the skin (for instance with bupivacaine or ropivacaine) would minimise haematoma and post-operative pain in this donor area.

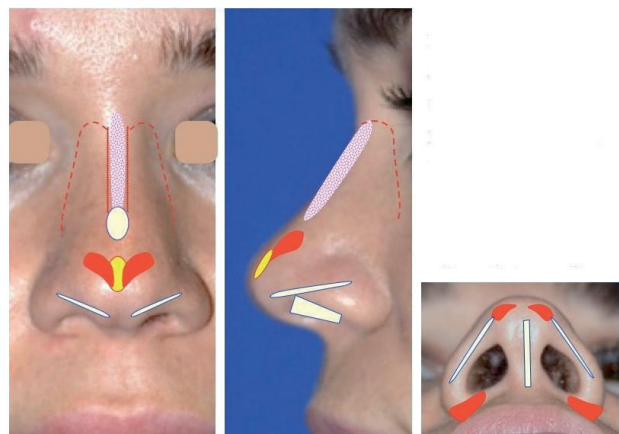
6. Complications

As with any surgical procedures, patients should be informed about potential problems as transient inflammation, haemorrhage, haematoma, seroma, adhesions, conspicuous scarring, keloids and pigmentation alterations. The same goes for undesirable infectious conditions as chondritis, osteitis, myositis and abscess. More specific conditions are paraesthesia, loss of temperature sensation and partial resorption of the cartilaginous graft. Jarring right-left asymmetry of the grafts may entail pyramid deviation.

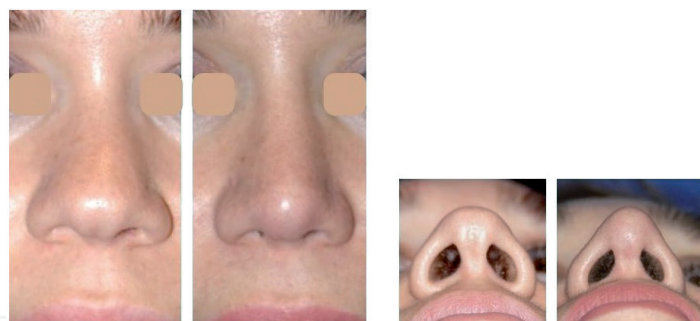Local necrosis and extrusion of the graft are very rarely seen. They may be the result of local traumatism or inadequate dressing as well as previous ischaemic features as seen in chain smoking (**Figures 7–10**).



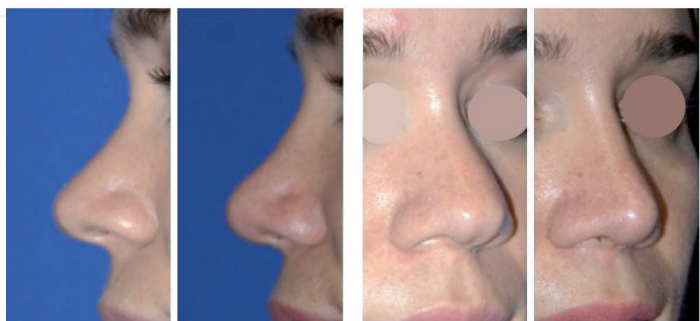(a)



(b)



(c)



(d)

Figure 7.
(A) Broad, bilobed nasal tip in a 27-year-old female patient. Slight deviation of dorsum and retracted columella. (B) Surgical planning for the patient in **Figure 5A**. This patient underwent lipectomy (yellow), cephalic resection of alar cartilages (red), caudal extension graft (from septum), submucous section of triangle area, medial and lateral fracture (spiked line), septal cartilage graft over tip region, septal cartilage graft inside alar rim. (C) and (D) Post-operative result of patient in (A).

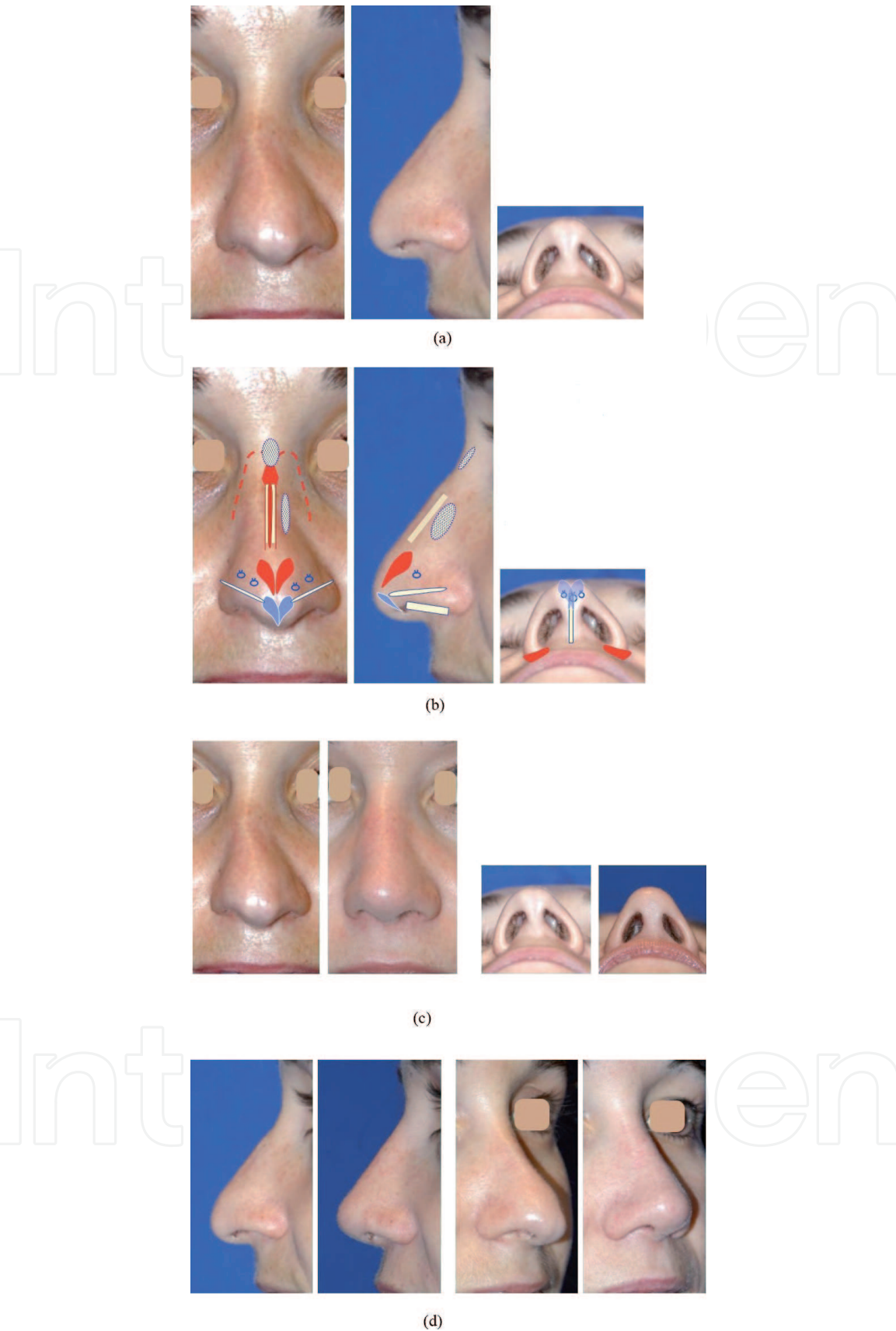


Figure 8.
(A) A 32-year-old female patient suffering for traumatic deviation. Hanging tip, acute nasolabial angle, broad tip and unbalance between lobe and alae. (B) Surgical planning for the patient in **Figure 6A**. A trans-columellar incision was extended along pre-rimal areas. The procedure included a partial septoplasty (red), tension-discharging incisions on the left side, dorsal expansion grafts, a columellar stick graft, cephalic resection of alar cartilages, several interdomal, intradomal and intraalar stitches, as well as septal cartilage graft to the left cartilaginous wall, a suspension-rotation suture of the crus medialis, predomal grafts (light blue), a medial and lateral fracture (interrupted line), a batten graft to the radix, pre-rimal grafts and a resection with rotation of the skin and mucosa of the alae. (C) and (D) Comparison between pre-operative and post-operative result of patient in (A).

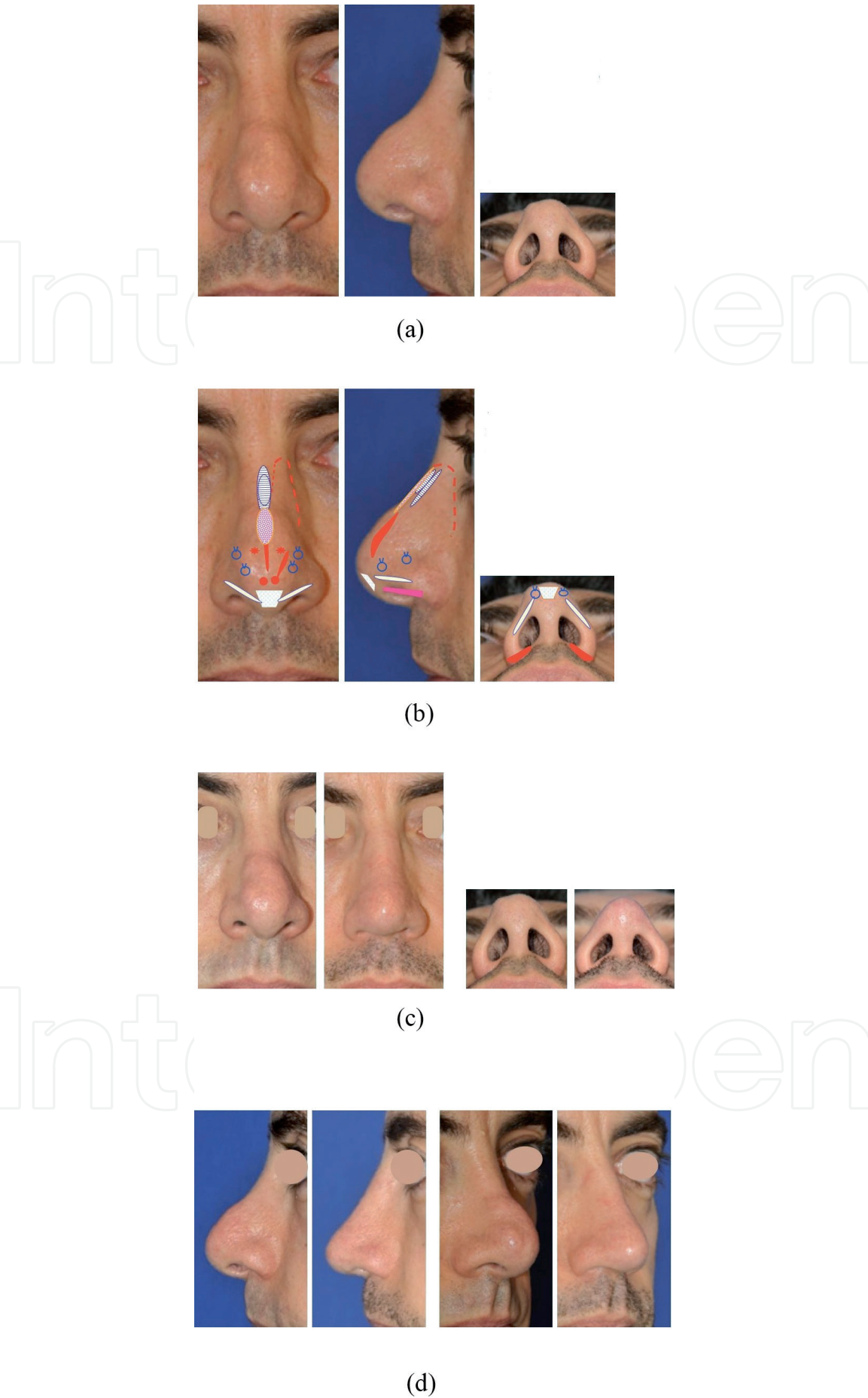


Figure 9.
(A) A 35-year-old male patient with supratip deformation after secondary rhinoplasty. He showed a thick skin, a saddle (broad and flat) dorsum as well as an asymmetric, pinched tip, other features include an osseous dehiscence on the left side and malpositioned, undulating alae. (B) Surgical planning for patient in (A). (C) and (D) Comparison between pre-operative and post-operative result of patient in (A).

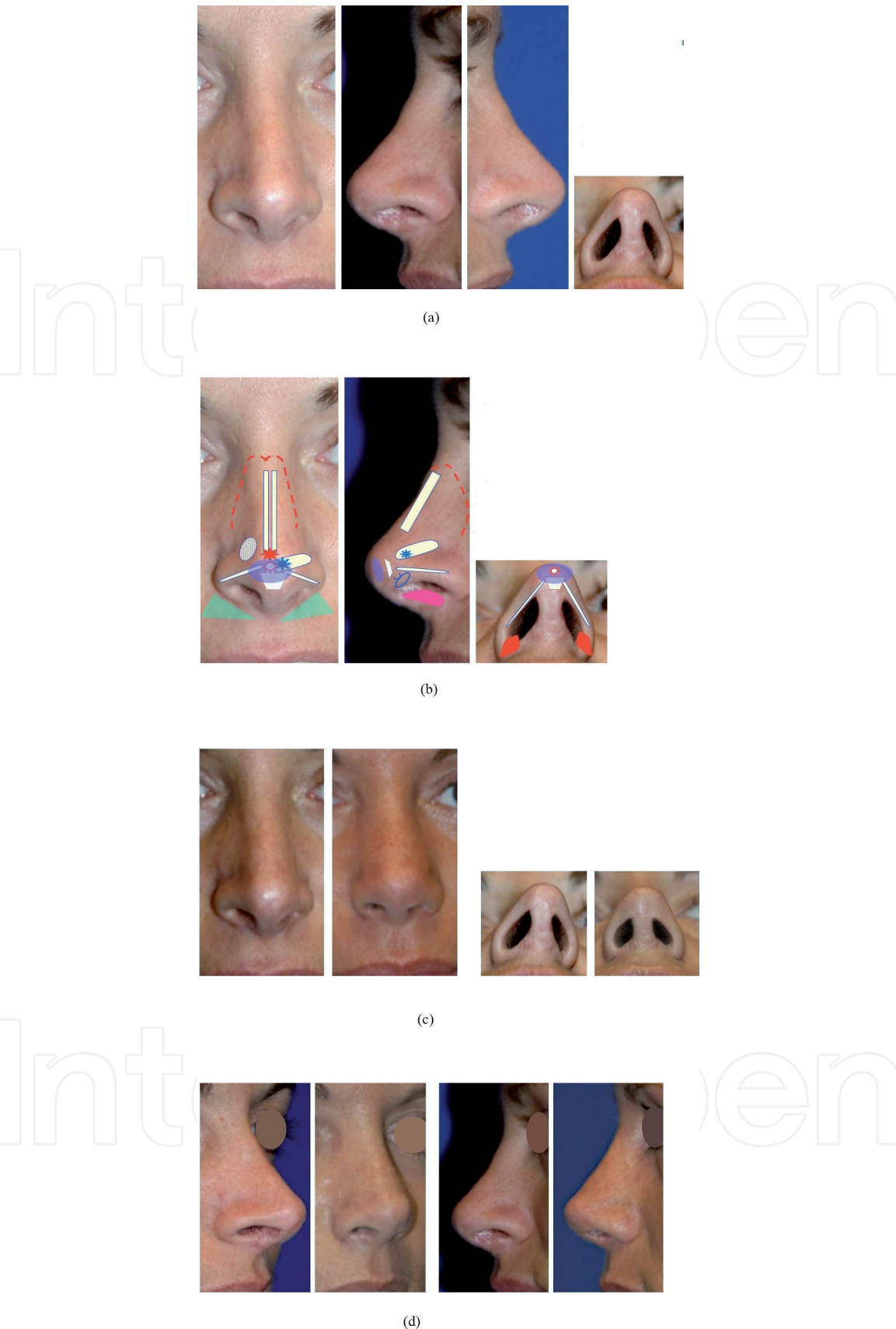


Figure 10.
(A) Secondary rhinoplasty in a 29-year-old female patient that showed deviation, irregularities of her dorsum, upper valve collapse, pinched tip, light alar retraction, hanging columella and maxillary hypotrophy. (B) Surgical planning for the patient in Figure 8A included an osteocartilaginous septoplasty with removal of previous graft and fibrotic tissue (red star). The procedure involved reconstruction of the left alar cartilage (blue star), expansor grafts for dorsum, batten alar graft on the right lateral wall, a left alar graft, a predomal graft, a fixation suture between crus medialis and caudal septum, pre-rimal grafts, a lateral fracture (spiked line), partial resection of the mucosa of the membranous septum, an expansion mesh of polypropylene on the maxilla and partial resection of the skin and mucosa of the alae. (C) and (D) Comparison between pre-operative and post-operative result of patient in (A).

7. Conclusion

These grafts are useful to prevent an alar retraction and post-operative shifts on those patients that show primary alterations of alar outline. They provide support and steadiness for the alar rim by creating a structure that counteracts the forces of scar contraction [26–29]. Whenever we use them we shall prevent descent (or rotation) of caudal margin of alar cartilages and a trilobulate, pinched nose. At the same time, we enhance a correct functioning of the external valve and prevent its collapse.

These grafts are also very useful for the treatment of pinched, nasal tips with a very long *crus intermedium*, i.e. lack of sustentation of skin in the soft triangle. We may use them as a complement for domal sutures and alar grafts in order to compensate the modifications that these procedures induce on the sustaining tip structures; they favour projection and balance of the nasal tip while preserving the function of external valve. They allow us to provide triangularity to the nasal base, by re-establishing the Anderson tripod, as well as to preserve the pyramidal shape of nasal tip. This will help to achieve a natural allure of the nasal tip contour.

Author details

Pedro S. Arquero^{1†}, Wenceslao M. Calonge^{2*†}, Daniel P. Espinoza³ and Diana Oesch²

1 Clinica Arquero, Madrid, Spain

2 Clinique de Genolier, Genolier, Switzerland

3 Centre Feel Well, Geneva, Switzerland

*Address all correspondence to: wcalonge@yahoo.es

† These authors equally contributed to the work.

IntechOpen

© 2019 The Author(s). Licensee IntechOpen. This chapter is distributed under the terms of the Creative Commons Attribution License (<http://creativecommons.org/licenses/by/3.0>), which permits unrestricted use, distribution, and reproduction in any medium, provided the original work is properly cited. 

References

- [1] Fomon S, Bell JW, Berger EL, Goldman IB, Neivert H, Schattner A. Management of deformities of lower cartilaginous vault. *A.M.A. Archives of Otolaryngology*. 1951;**54**(5):467-472
- [2] Fomon S, Bell JW, Lubart J, Schattner A, Syracuse VR. Rhinoplastic problems in the lower cartilaginous vault. *Archives of Otolaryngology*. 1964;**79**:512-521
- [3] Denecke HJ, Meyer R. Plastische Operationen an Kopf und Hals. In: *Korrigierende und Rekonstruktive Nasenplastik*. Berlin: Springer; 1964
- [4] Farrior RT. The problem of the unilateral cleft lip nose. A composite operation for revision of the secondary deformity. *Laryngoscope*. 1962;**72**:289-352
- [5] Janeke JB, Wright WK. Studies on the support of the nasal tip. *Archives of Otolaryngology*. 1971;**93**(5):458-464
- [6] Vecchione TR. Reconstruction of the ala and nostril sill using proximal composite grafts. *Annals of Plastic Surgery*. 1980;**5**(2):148-150
- [7] Orticoechea M. A new method for total reconstruction of the nose: The ears as donor areas. *Clinics in Plastic Surgery*. 1981;**8**(3):481-505
- [8] Troell RJ, Powell N, Riley RW, Li KK. Evaluation of a new procedure for nasal alar rim and valve collapse: Nasal alar rim reconstruction. *Otolaryngology and Head and Neck Surgery*. 2000;**122**(2):204-211
- [9] Rohrich RJ, Raniere J Jr, Ha RY. The alar contour graft: Correction and prevention of alar rim deformities in rhinoplasty. *Plastic and Reconstructive Surgery*. 2002;**109**(7):2495-2505
- [10] Toriumi DM, Checcone MA. New concepts in nasal tip contouring. *Facial Plastic Surgery Clinics of North America*. 2009;**17**(1):55-90
- [11] Daniel RK, Palhazi P, Gerbault O, Kosins AM. Rhinoplasty: The lateral crura-alar ring. *Aesthetic Surgery Journal*. 2014;**34**(4):526-537
- [12] Alexander AJ, Shah AR, Constantinides MS. Alar retraction: Etiology, treatment, and prevention. *JAMA Facial Plastic Surgery*. 2013;**15**(4):268-274
- [13] Tas S, Colakoglu S, Lee BT. Nasal base retraction: A treatment algorithm. *Aesthetic Surgery Journal*. 2017;**37**(6):640-653
- [14] Ellenbogen R, Bazell G. Nostrilplasty: Raising, lowering, widening, and symmetry correction of the alar rim. *Aesthetic Surgery Journal*. 2002;**22**(3):227-237
- [15] Unger JG, Roostaeian J, Small KH, Pezeshk RA, Lee MR, Harris R, et al. Alar contour grafts in rhinoplasty: A safe and reproducible way to refine alar contour aesthetics. *Plastic and Reconstructive Surgery*. 2016;**137**(1):52-61
- [16] Gruber RP, Fox P, Peled A, Belek KA. Grafting the alar rim: Application as anatomical graft. *Plastic and Reconstructive Surgery*. 2014;**134**(6):880e-887e
- [17] Toriumi DM, Josen J, Weinberger M, Tardy ME Jr. Use of alar batten grafts for correction of nasal valve collapse. *Archives of Otolaryngology—Head & Neck Surgery*. 1997;**123**:802-808
- [18] Guyuron B, Bigdeli Y, Sajjadian A. Dynamics of the alar rim graft. *Plastic and Reconstructive Surgery*. 2015;**135**(4):981-986
- [19] Li YK, Greensmith A. Facilitated alar rim graft placement with an

ophthalmic slit blade. Plastic and Reconstructive Surgery. Global Open. 2018;**6**(4):e1721

[20] Jang YJ, Kim SM, Lew DH, Song SY. Simple correction of alar retraction by conchal cartilage extension grafts. Archives of Plastic Surgery. 2016;**43**(6):564-569 [Epub Nov 18, 2016]

[21] Goodrich JL, Wong BJ. Optimizing the soft tissue triangle, alar margin furrow, and alar ridge aesthetics: Analysis and use of the articulate alar rim graft. Facial Plastic Surgery. 2016;**32**(6):646-655

[22] Ballin AC, Kim H, Chance E, Davis RE. The articulated alar rim graft: Reengineering the conventional alar rim graft for improved contour and support. Facial Plastic Surgery. 2016;**32**(4):384-397

[23] Kemaloglu CA, Altıparmak M. The alar rim flap: A novel technique to manage malpositioned lateral crura. Aesthetic Surgery Journal. 2015;**35**(8):920-926

[24] Deroee AF, Younes AA, Friedman O. External nasal valve collapse repair: The limited alar-facial stab approach. The Laryngoscope. 2011;**121**(3):474-479

[25] Field LM. Nasal alar rim reconstruction utilizing the crus of the helix, with several alternatives for donor site closure. The Journal of Dermatologic Surgery and Oncology. 1986;**12**(3):253-258

[26] Losquadro WD, Bared A, Toriumi DM. Correction of the retracted alar base. Facial Plastic Surgery. 2012;**28**(2):218-224

[27] Boahene KD, Hilger PA. Alar rim grafting in rhinoplasty: Indications, technique, and outcomes. Archives of Facial Plastic Surgery. 2009;**11**(5):285-289

[28] Kalan A, Kenyon GS, Seemungal TA. Treatment of external nasal valve (alar

rim) collapse with an alar strut. The Journal of Laryngology and Otology. 2001;**115**(10):788-791

[29] Cárdenas-Camarena L, Guerrero MT. Use of cartilaginous autografts in nasal surgery: 8 years of experience. Plastic and Reconstructive Surgery. 1999;**103**(3):1003-1014