

We are IntechOpen, the world's leading publisher of Open Access books Built by scientists, for scientists

6,900

Open access books available

186,000

International authors and editors

200M

Downloads

Our authors are among the

154

Countries delivered to

TOP 1%

most cited scientists

12.2%

Contributors from top 500 universities



WEB OF SCIENCE™

Selection of our books indexed in the Book Citation Index
in Web of Science™ Core Collection (BKCI)

Interested in publishing with us?
Contact book.department@intechopen.com

Numbers displayed above are based on latest data collected.
For more information visit www.intechopen.com



Introductory Chapter: General Remarks Regarding Limb Amputations

Masaki Fujioka

1. Introduction

Developments of microsurgical techniques allows reimplantation in patients with severed hands, legs, and fingers (**Figures 1 and 2**). And flap transfer techniques have also allowed reconstruction of bone and soft tissue defects in the extremities following malignant neoplasm resection and severe open fractures (**Figures 3 and 4**) [1].

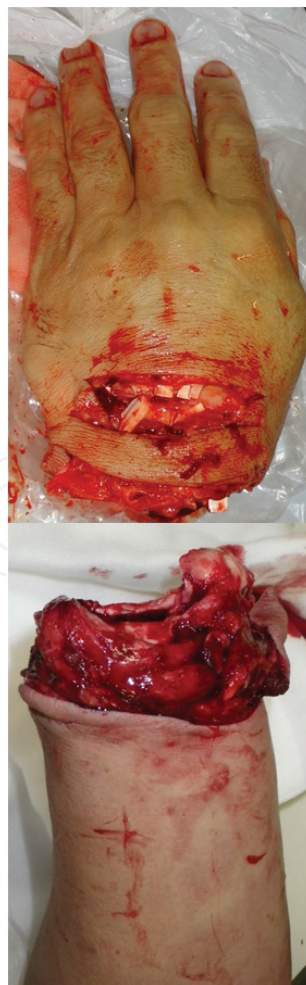


Figure 1.
The photograph shows a severed hand following an accident.

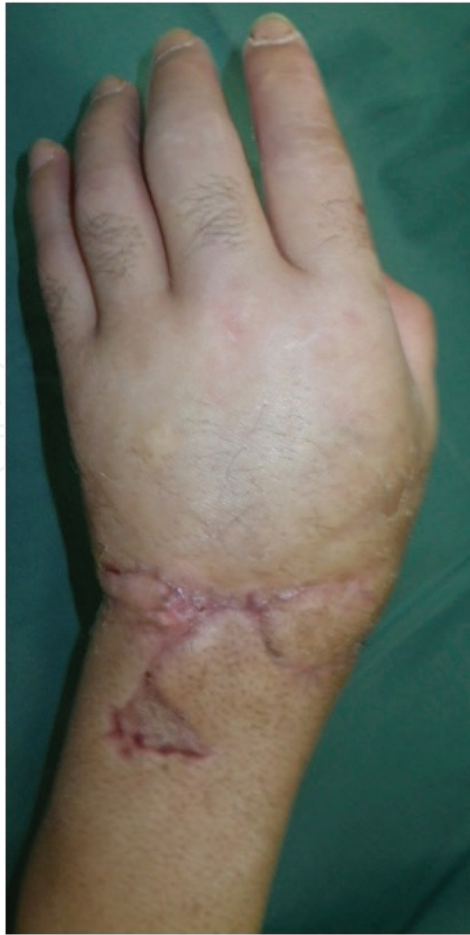

Figure 2.
The photograph shows re-plantation of the severed hand.

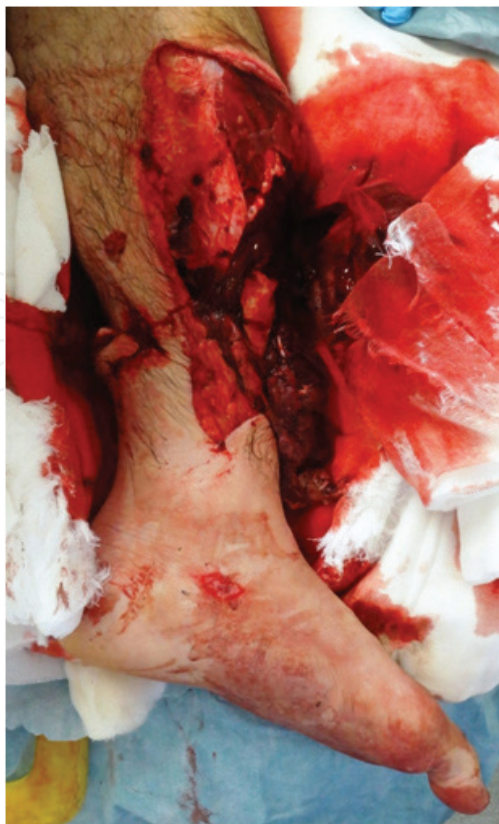

Figure 3.
The photograph shows a Gustilo-Anderson IIIC bone-exposing fracture of the left fibula and tibia with severe abrasion of the skin and muscles.

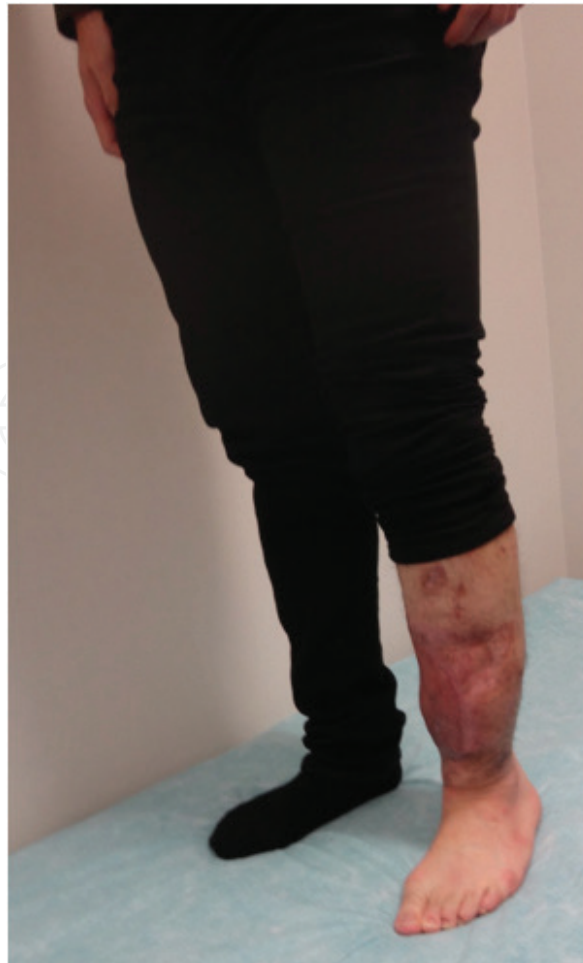

Figure 4.
The patient could walk 1-year after surgery.

As result, previously non-salvageable limbs have been salvaged. However, there are many patients who require limb amputation. Circumstances of limb amputation may vary, including war wound, infections and animal bites, and traffic accidents and various diseases [2, 3].

In this chapter, I describe general remarks regarding limb amputations, which may help to better understand the following chapters.

2. Types and incidence of amputation.

Although the term “amputation” is usually used for the removal of a limb, the removal of other prominent parts of the body, such as the ear, nose, breast, and penis, is also called amputation [4, 5]. However, the population of limb amputees is largest, and an estimated 1.6 million persons were living with the loss of a limb in the USA in the year 2005 [6]. Males are more likely to require limb amputation (a male to female ratio of 1.6–3.9:1), because males are more outgoing and are more prone to trauma, and peripheral artery disease [7]. Lower limb amputation is six–seven times more frequent than upper limbs one [8].

3. Causes

Before 2004, trauma accounted for most amputations in the majority of hospitals, followed by malignancies [9]. Although trauma is still the most predominant indication

for amputation in developing countries, peripheral arterial disease with or without diabetes mellitus is now the most common cause of amputation in the developed countries [2, 3].

3.1 Peripheral arterial disease

Limb loss is most often due to peripheral arterial disease (54–82%); the estimated increase in the rate of dysvascular amputations was 27%. On the other hand, rates of trauma- and cancer-related amputations both declined by approximately half [10]. Peripheral arterial disease affects the distal vessels and results in occlusion, which is one of the major causes of ulcer development and a risk factor for amputation (**Figure 5**).

These patients often require challenging distal revascularization surgery or angioplasty to avoid limb amputation. Revascularization is the only way to prevent major amputation of an ischemic foot, and the ulcer healing rate after revascularization ranges from 46 to 91% [11].

3.2 Diabetes mellitus

Patients with diabetes are likely to develop infections, because of the alteration of immune defense mechanisms due to the hyperglycemic environment [12]. Furthermore, more than 50% of patients by diabetes mellitus are complicated with peripheral arterial disease [2].

Once a diabetic foot develops infection, it progresses rapidly and requires the removal of all necrotic tissue (**Figure 6**).

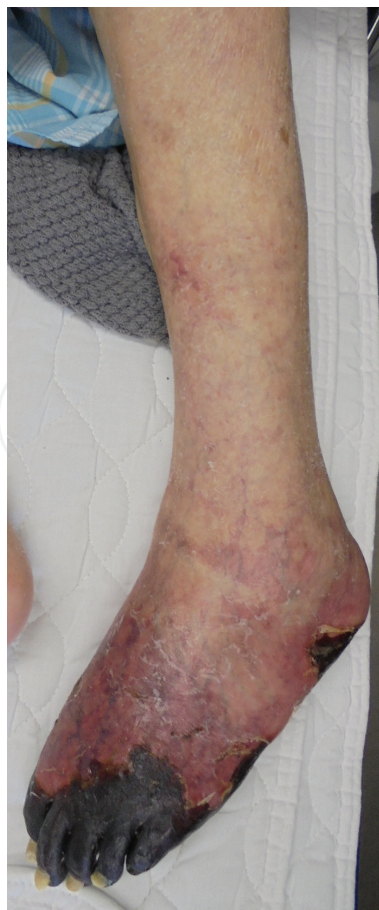

Figure 5.
The photograph shows an ischemic foot due to peripheral arterial disease of the left leg, which required below-knee amputation.

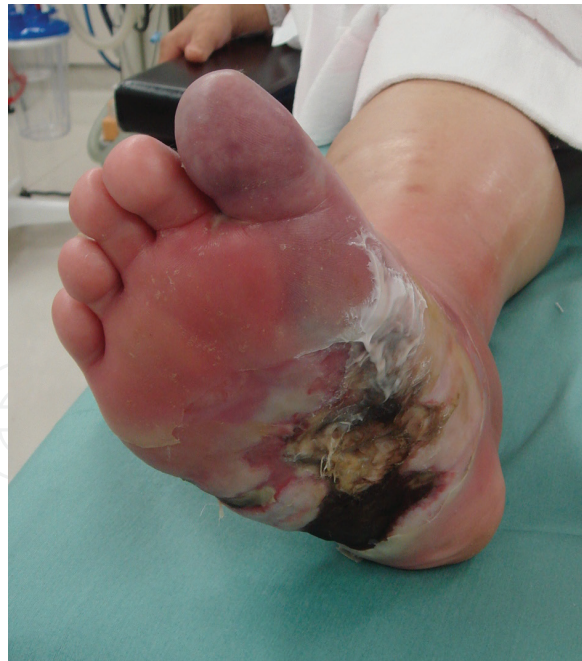

Figure 6.
The photograph shows diabetic gangrene on the right sole, which required transverse tarsal (Chopart) amputations.

These patients are common in developing countries, and extremity amputations associated with diabetes mellitus accounted for most indications (57.0%) in northeast Nigeria [13]. Thus, diabetes prevention, detection, and management should be prioritized in any attempt to reduce the current incidence of amputation [3]

3.3 Infection

Necrotizing fasciitis and myositis are life-threatening infections with associated mortality rates of 10–20% [14]. Especially, *Vibrio vulnificus* and group A streptococci often cause aggressive and fatal gangrene and necrotizing

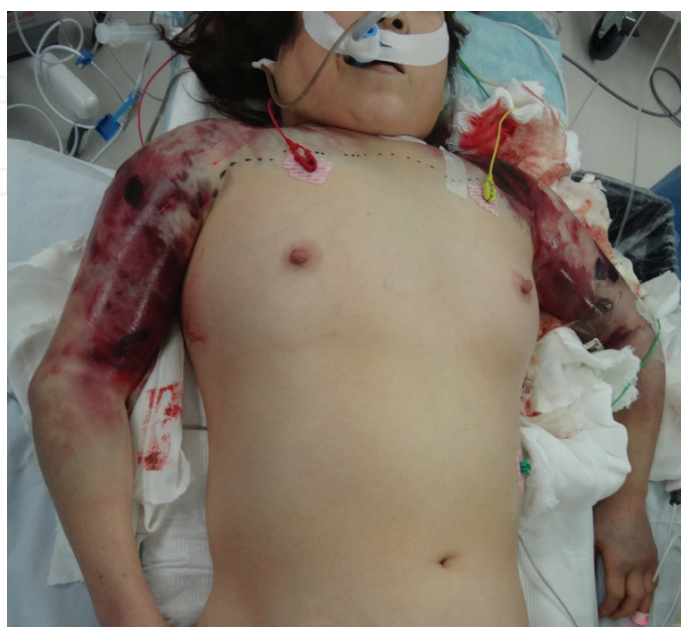

Figure 7.
The photographs show a patient with group A streptococci infection of the bilateral upper lower limbs, which led to streptococcal toxic shock syndrome.

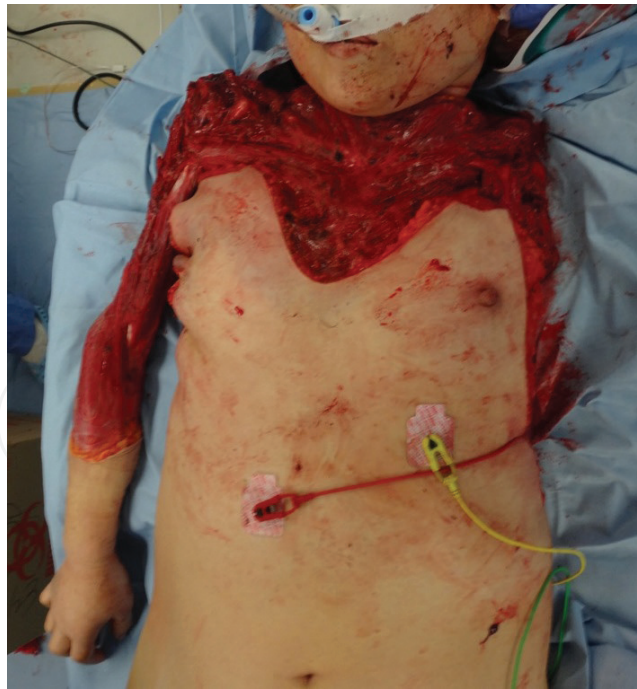

Figure 8.
Intraoperative photographs show immediate amputation of the left arm and the complete removal of the infected skin of the right arm and chest.

myofasciitis, and a reported 23% of patients die of vibrio, and 20–34% die of group A *streptococci* infection [15]. Regarding surgical intervention, early and appropriate debridement to reduce infection is recommended to achieve infection control. Thus, surgical debridement including limb amputation should be considered in the early stage.

Patients with group A *streptococci* infection can develop streptococcal toxic shock syndrome (STSS). When STSS is complicated by myositis, multiple limb amputations should be considered, and the reported mortality rate is 80–100% [16] (**Figures 7 and 8**).

3.4 Trauma

Treatment of patients with severe injury with vasculopathy of the extremities, such as trauma-related amputation and Gustilo-Anderson type IIIC fracture, is challenging, because it often requires the resurfacing of tissue defects as well as preservation of functional blood flow to distal areas [1]. Previously, patients with these severe limb injuries underwent amputation. Now, most severed limbs can be replanted, and vascular and soft tissue defects can be reconstructed, owing to the development of microsurgical techniques [17]. Therefore, indications for limb amputation due to injuries are now limited.

3.5 Neoplasm

Malignant bone and soft tissue tumors are rare conditions, but a delay in diagnosis or the misinterpretation of data can have limb- and life-threatening consequences. Although a tissue defect following oncologic resection can be reconstructed using a flap transfer technique, hand and leg salvage cannot always be achieved, because radical surgery sometimes requires the removal of important organs such as the bone, arteries, and nerves [17] (**Figure 9**).

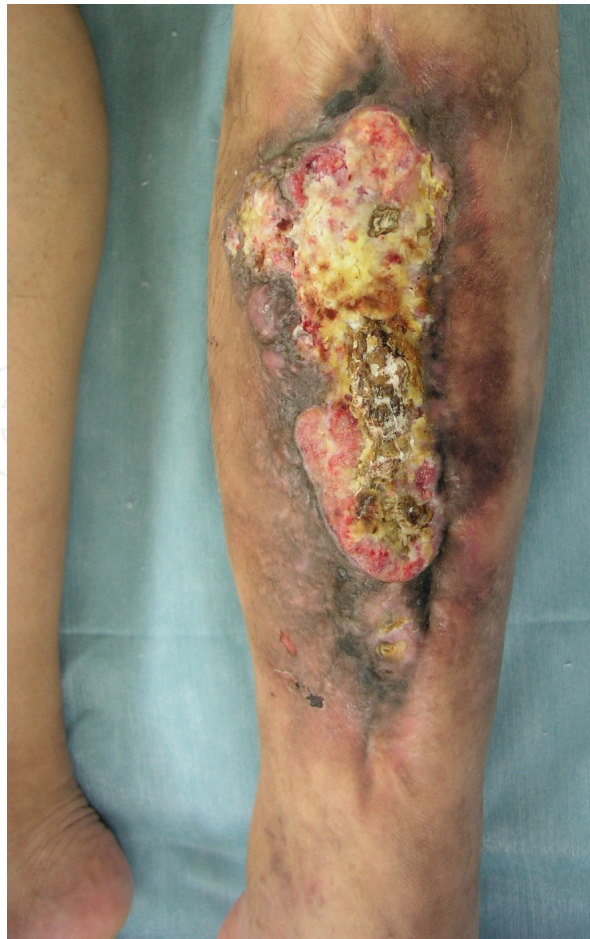

Figure 9.
The photograph shows squamous cell carcinoma on the left leg invading the tibia, which required above-knee amputation.

Conflict of interest statement

There are no conflicts of interest, including financial, consultant, institutional, and other relationships that might lead to a perceived bias.

Financial disclosure and products

There were no external sources of funding in the form of grants supporting the work presented in this manuscript.

Ethical considerations

The procedures followed were in accordance with the ethical standards of our institutional committee on human experimentation and with the Helsinki Declaration of 1975, as revised in 1983.

Patients in our manuscript were additionally informed about the patient's ethical rights by the author and agreed that the patient's illustrative material, including face, could be used for the aim of the medical study and also agreed to the photos being published in a medical journal.

This manuscript has not previously been presented at any meeting. This article is original and has not previously been published.

IntechOpen

IntechOpen


Author details

Masaki Fujioka

Department of Plastic and Reconstructive Surgery, Clinical Research Center,
National Hospital Organization Nagasaki Medical Center, Nagasaki, Japan

*Address all correspondence to: inazmahayato7@gmail.com

IntechOpen

© 2019 The Author(s). Licensee IntechOpen. This chapter is distributed under the terms of the Creative Commons Attribution License (<http://creativecommons.org/licenses/by/3.0>), which permits unrestricted use, distribution, and reproduction in any medium, provided the original work is properly cited. 

References

- [1] Fujioka M. Application of free flow-through anterolateral thigh flap for the reconstruction of an extremity soft tissue defect requiring vascularization. In: *Flap Surgery*. Rijeka: InTech; 2018. pp. 51-76 (Chapter 4)
- [2] Yaghi K, Yaghi Y, McDonald AA, Yadegarfar G, Cecil E, Seidl J, et al. Diabetes or war? Incidence of and indications for limb amputation in Lebanon, 2007. *Eastern Mediterranean Health Journal*. 2012;**18**(12):1178-1186
- [3] Sargen MR, Hoffstad O, Margolis DJ. Geographic variation in Medicare spending and mortality for diabetic patients with foot ulcers and amputations. *Journal of Diabetes and its Complications*. 2013;**27**(2):128-133
- [4] Ellis H. Amputation of the breast. *Journal of Perioperative Practice*. 2015;**25**(1-2):27-28
- [5] Falcone M, Garaffa G, Raheem A, Christopher NA, Ralph DJ. Total phallic reconstruction using the radial artery based forearm free flap after traumatic penile amputation. *The Journal of Sexual Medicine*. 2016;**13**(7):1119-1124
- [6] Ziegler-Graham K, MacKenzie EJ, Ephraim PL, Travison TG, Brookmeyer R. Estimating the prevalence of limb loss in the United States: 2005 to 2050. *Archives of Physical Medicine and Rehabilitation*. 2008;**89**(3):422-429
- [7] Roumia M, Aronow HD, Soukas P, Gosch K, Smolderen KG, Spertus JA, et al. Sex differences in disease-specific health status measures in patients with symptomatic peripheral artery disease: Data from the PORTRAIT study. *Vascular Medicine*. 2017;**22**(2):103-109
- [8] Farrokhi S, Perez K, Eskridge S, Clouser M. Major deployment-related amputations of lower and upper limbs, active and reserve components, U.S. Armed Forces, 2001-2017. *MSMR*. 2018;**25**(7):10-16
- [9] Settakorn J, Rangdaeng S, Arpornchayanon O, Lekawanvijit S, Bhoopat L, Attia J. Why were limbs amputated? An evaluation of 216 surgical specimens from Chiang Mai University Hospital, Thailand. *Archives of Orthopaedic and Trauma Surgery*. 2005;**125**(10):701-705
- [10] Dillingham TR, Pezzin LE, MacKenzie EJ. Limb amputation and limb deficiency: Epidemiology and recent trends in the United States. *Southern Medical Journal*. 2002;**95**(8):875-883
- [11] Vouillarmet J, Bourron O, Gaudric J, Lermusiaux P, Millon A, Hartemann A. Lower-extremity arterial revascularization: Is there any evidence for diabetic foot ulcer-healing? *Diabetes & Metabolism*. 2016;**42**(1):4-15
- [12] Mustăţea P, Bugă C, Doran H, Mihalache O, Bobîrcă FT, Georgescu DE, et al. Soft tissue infections in diabetic patients. *Chirurgia (Bucur)*. 2018;**113**(5):651-667
- [13] Dabkana TM, Nyaku FT, Bwala ST. Current indications for extremity amputations in Maiduguri, north-East Nigeria: A 6-year retrospective review. *Annals of African Medicine*. 2018;**17**(1):22-25
- [14] Fujioka M, Nishimura G, Miyazato O, et al. Necrotizing fasciitis and myositis that originated from gastrointestinal bacterial infection: Two fatal cases. *Scandinavian Journal of Plastic and Reconstructive Surgery and Hand Surgery*. 2003;**37**:239-242
- [15] Kaul R, McGeer A, Low DE, Green K, Schwartz B. Population-based surveillance for group A streptococcal necrotizing fasciitis: Clinical features,

prognostic indicators, and microbiologic analysis of seventy-seven cases. Ontario Group A Streptococcal Study. American Journal of Medicine. 1997;**103**(1):18-24

[16] Saijo H, Fujioka M, Hayashida K, Murakami C. A fatal case of streptococcal toxic shock syndrome by group A *streptococcus* despite of undergoing immediate three extremities amputation. Japanese Journal of Plastic & Reconstructive Surgery. 2013;**56**:667-672

[17] Saint-Cyr M, Langstein HN. Reconstruction of the hand and upper extremity after tumor resection. Journal of Surgical Oncology. 2006;**94**:490-503