

We are IntechOpen, the world's leading publisher of Open Access books Built by scientists, for scientists

6,900

Open access books available

185,000

International authors and editors

200M

Downloads

Our authors are among the

154

Countries delivered to

TOP 1%

most cited scientists

12.2%

Contributors from top 500 universities



WEB OF SCIENCE™

Selection of our books indexed in the Book Citation Index
in Web of Science™ Core Collection (BKCI)

Interested in publishing with us?
Contact book.department@intechopen.com

Numbers displayed above are based on latest data collected.
For more information visit www.intechopen.com



Low Flow Low Gradient Severe Aortic Stenosis: Diagnosis and Treatment

Faez Mohamad Ali, Vindhya Wilson and Rajesh Nair

Abstract

Approximately 40% of patients with aortic stenosis (AS) show discordant Doppler-echocardiographic parameters with aortic valve area (AVA) $<1 \text{ cm}^2$ and/or index iAVA $<0.6 \text{ cm}^2/\text{m}^2$ (consistent with severe AS) and the mean gradient (MG) $<40 \text{ mmHg}$, consistent with mild/moderate AS. Accurate diagnosis of true severe low flow low gradient AS versus pseudo-severe aortic stenosis is important for prognosis and optimal timing for intervention. Doppler echocardiography using intravenous low dose dobutamine challenge is widely used for differentiating pseudo-severe from true severe aortic stenosis. However, relying on echocardiography alone may have limitations in accurate diagnosis. Reliable diagnosis using echocardiography is dependent on multiple factors like the angle of interrogation of the aortic jet, the assumption that the LVOT area is circular in cross section, optimal echo windows, the presence of underlying subclinical coronary artery disease prior to dobutamine challenge etc. In this chapter, we describe non-invasive and invasive strategies to assess the aortic valve using dobutamine stress. Direct measurement of gradients across the aortic valve while estimating the change in cardiac output and aortic valve area with increments of dobutamine infusion dose is complementary, safe and useful when conventional echocardiography techniques are inconclusive. Finally, the chapter describes effective strategies of treatment for low gradient severe aortic stenosis, including the role for diagnostic balloon valvuloplasty, in the era of transcatheter valve replacement (TAVR).

Keywords: balloon aortic valvuloplasty, dobutamine stress test, low flow low gradient severe aortic stenosis, pseudo-severe aortic stenosis, trans-catheter aortic valve replacement

1. Introduction

Degenerative calcific aortic stenosis (AS) is the commonest primary valvular heart disease responsible for approximately 85,000 valve replacement procedures and 15,000 deaths per year in North America [1].

The diagnosis and staging of AS is primarily based on symptoms and Doppler echocardiography. AS is considered severe when the patient has a mean transvalvular gradient $>40 \text{ mmHg}$, a peak aortic jet velocity $>4 \text{ m/s}$, an aortic valve area (AVA) $<1.0 \text{ cm}^2$, indexed aortic valve area (iAVA) $<0.6 \text{ cm}^2/\text{m}^2$ and a dimensionless velocity index <0.25 [2–4].

However, in up to 40% of patients with AS, there is discordance between aortic valve area ($<1\text{ cm}^2$ suggesting severe AS) and transvalvular gradients ($<40\text{ mmHg}$ suggesting non-severe AS) on Doppler echocardiography [5–7]. These patients are referred to as having “low gradient” severe AS. Most of these patients have a “low flow state” across the aortic valve, which is defined as an indexed stroke volume $<35\text{ ml/m}^2$. Many of these patients may be quite advanced in the natural history of severe AS. Despite challenges in establishing accurate diagnosis, “low gradient” severe AS patients tend to have poorer outcomes compared to patients with “high gradient” severe AS. This chapter describes the etiology, classification, diagnosis and management options of low flow low gradient (LFLG) severe AS.

2. Classification of aortic stenosis

All major guidelines have classified aortic stenosis based on hemodynamic parameters, symptoms and the left ventricular (LV) systolic function (Figure 1). According to the American College of Cardiology/American Heart Association, severe aortic stenosis is classified into asymptomatic severe AS (stage C) and symptomatic severe AS (stage D). Asymptomatic severe AS depending on LV function is further sub classified into stage C1—with normal LV function and stage C2—with reduced LV function (left ventricular ejection fraction (LVEF) $<50\%$). Symptomatic severe AS is sub classified into three stages depending on blood flow across the aortic valve and hemodynamic characteristics (Figure 2). Normal flow ($>35\text{ ml/m}^2$), high gradient ($>40\text{ mmHg}$), severe AS (AVA $<1\text{ cm}^2$ /iAVA $<0.6\text{ cm/m}^2$) is the most easily recognized entity with little diagnostic confusion (stage D1).

Low flow low gradient (LFLG) severe aortic stenosis (stages D2 and D3) represents an advanced stage in the hemodynamic spectrum of severe AS with poor prognosis and higher surgical morbidity and mortality than normal flow high gradient severe AS [8–12].

Although not incorporated into guidelines some authors recognize another variant called normal flow low gradient severe AS. This is a relatively poorly defined entity with unclear pathophysiology. Apart from measurement errors, one proposed explanation is that these patients have reduced arterial compliance (stiff arteries), which leads to a faster arterial wave reflection from the periphery. The

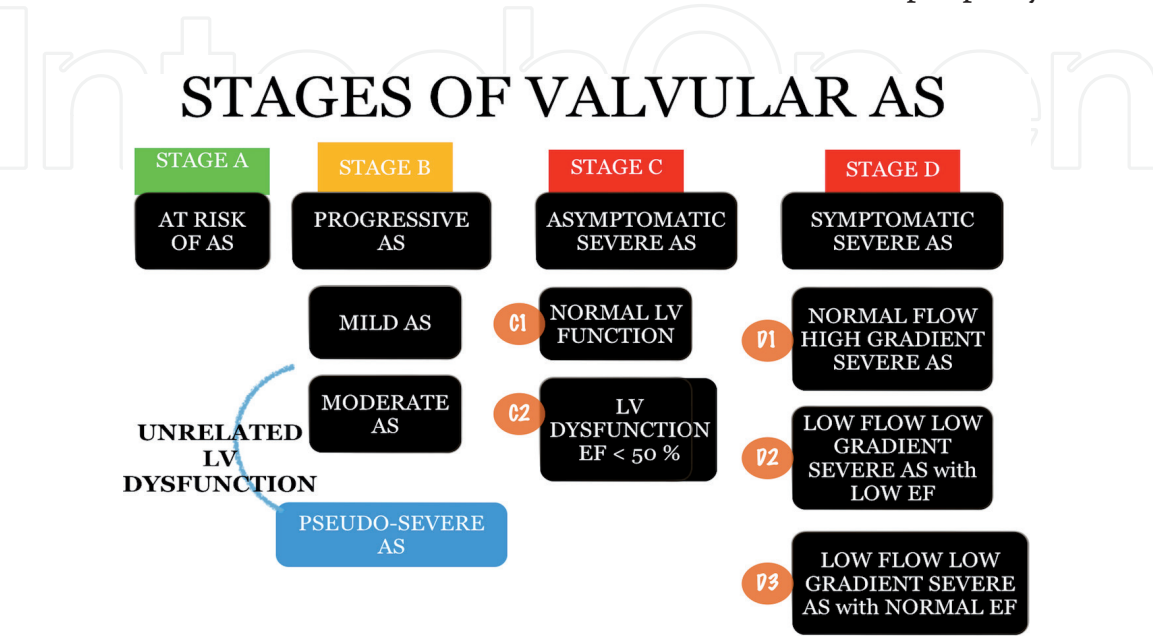


Figure 1. Stage of aortic stenosis—adapted and modified from Nishimura et al. [2].

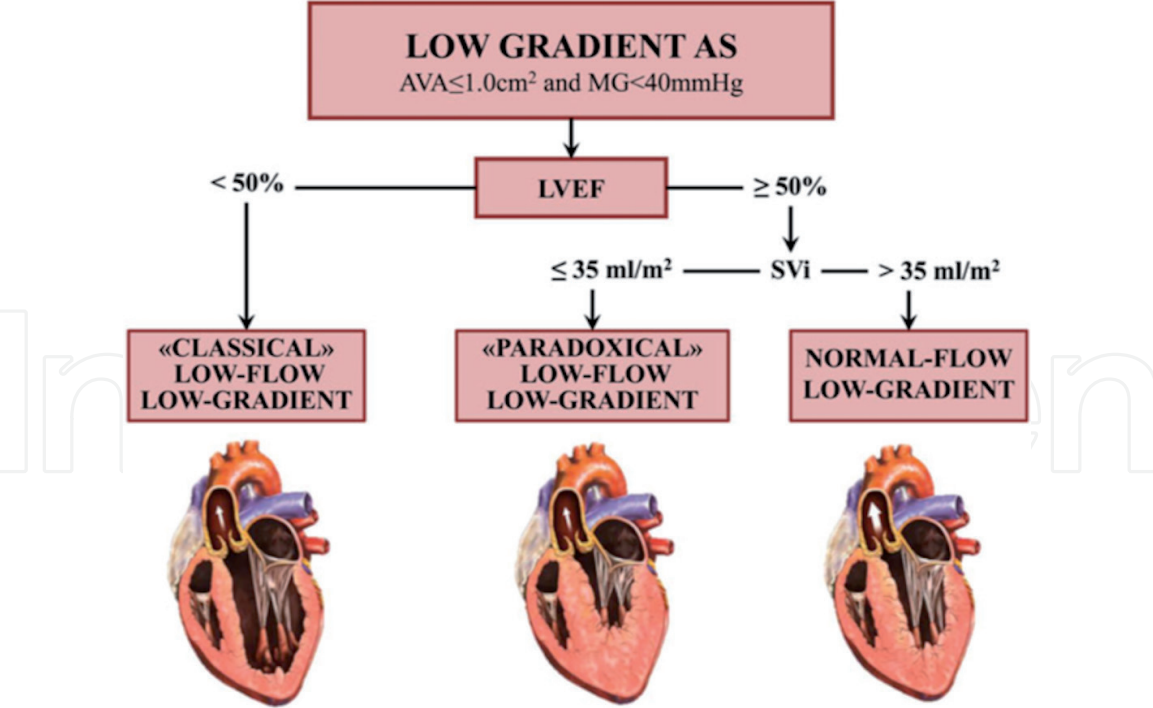


Figure 2.
Subtypes of low-gradient aortic stenosis. AS, aortic stenosis; AVA, aortic valve area; LVEF, left ventricular ejection fraction; MG, mean transvalvular gradient; SVi, stroke volume index. Reproduced with permission from Clavel et al. [32].

early reflection of the arterial wave at the end of systole may dampen the transvalvular gradients, independent of transvalvular flow. This phenomenon may, in part, explain the small AVA and low gradient discordance observed in patients with normal flow, low gradient severe AS.

2.1 Low flow low gradient severe AS with reduced ejection fraction (stage D2)

This entity is found in about 5–10% of patients with severe AS. It is more prevalent in men, and is very often associated with coronary artery disease [13]. LFLG severe AS is defined as indexed stroke volume <35 ml/m², LVEF <50%, AVA <1.0 cm²/iAVA <0.6 cm²/m² and mean aortic valve gradient <40 mmHg [2]. As severe AS progresses over several years, the left ventricle responds to the increase in afterload by concentric left ventricular hypertrophy. This compensatory mechanism helps the left ventricle pump against an increase in afterload as well as offset the increase in wall tension. The compensatory mechanism is reflected in the natural history of aortic stenosis where patients with severe AS who are truly asymptomatic have a relatively long symptom free period. However onset of symptoms indicates a significant turning point in the natural history with poor prognosis when left untreated (**Figure 3**). The average life expectancy for patients with severe AS is 2 years for those with shortness of breath, 3 years for patients with syncope, and 5 years for those with angina [16].

Patients who start out as normal flow high gradient severe AS eventually transform into LFLG severe AS with reduced LVEF through a number mechanisms (**Figure 4**). The long standing persistent left ventricular hypertrophy leads to oxygen supply demand mismatch, reduced capillary density, chronic subendocardial ischemia and interstitial fibrosis. Another important reason for LV dysfunction is coexistent coronary artery disease seen in a majority of these patients—49–76% [8, 9, 12].

Eventually the left ventricle fails to keep up with the high pressure gradients and decompensates due to the afterload mismatch. The LV dilates, stroke volumes drops

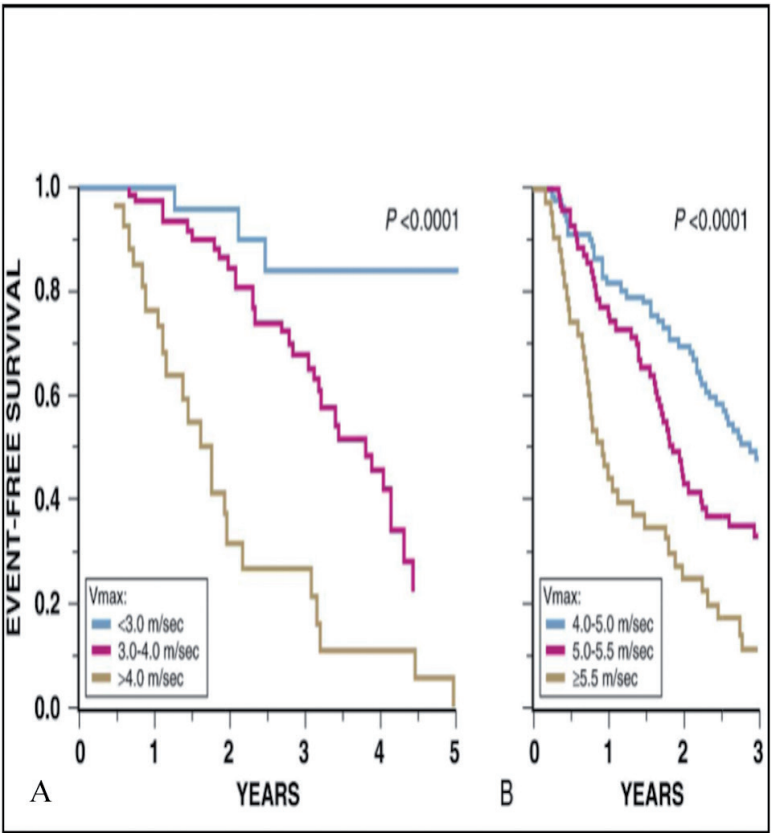


Figure 3. (A) Natural history as reflected by event-free survival in asymptomatic patients with AS. Initial aortic jet velocity (Vmax) stratifies patients according to the likelihood that symptoms requiring valve replacement will develop over time [14]. (B) Outcomes with very severe AS. Kaplan-Meier event-free survival rate for patients with a peak aortic jet velocity of 4.0 m/s or greater [15]. In both A and B, most “events” consisted of the onset of symptoms warranting aortic valve replacement.

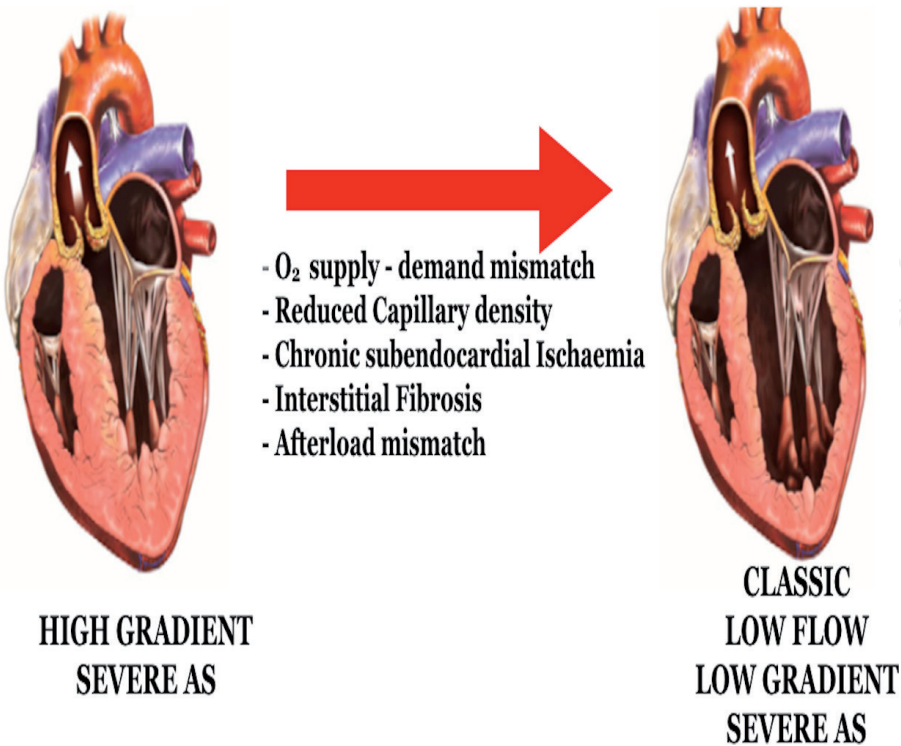


Figure 4. Factors leading to transformation of high gradient severe aortic stenosis to low flow low gradient severe aortic stenosis with reduced ejection fraction.

and LVEF falls. As the flow across the stenosed aortic valve declines, the ability of the valve to open (which is flow dependent) reduces and hence the calculated aortic valve area is low. The pressure gradients across the valve are measured by modified Bernoulli's equation ($P = 4V^2$, P , transaortic valve pressure gradient; V , maximum velocity of the aortic jet). Since flow velocities decline along with the stroke volume, the measured pressure gradients also drop exponentially. This leads to LFLG severe AS, with overall poor prognosis and a consensus class IIa recommendation for aortic valve replacement (AVR).

2.2 Low flow low gradient severe AS with preserved left ventricular ejection fraction (stage D3)

As opposed to patients with “classic” LFLG AS with reduced LVEF, those with “paradoxical” LFLG AS have preserved LVEF. This entity is defined as an LVEF >50%, the presence of a low flow (stroke volume index <35 ml/m²), an AVA <1.0 cm², an iAVA <0.6 cm²/m², and a mean aortic valve gradient <40 mmHg [2, 5, 17]. LFLG pattern is seen in 5–15% of patients with severe AS and is more prevalent in women and elderly patients. These patients have excessive LV hypertrophy in response to the hemodynamic stress. As a result they have small LV cavities and hence a low stroke volumes despite the preserved LVEF. Other factors (**Figure 5**) that contribute to low forward flow across the aortic valve include mitral regurgitation/stenosis, tricuspid regurgitation/stenosis, atrial fibrillation and infiltrative cardiomyopathies like amyloidosis. Paradoxical LFLG AS shares clinical, pathological and hemodynamic similarities with heart failure with preserved ejection fraction. Both conditions are characterized by significant concentric left ventricular hypertrophy

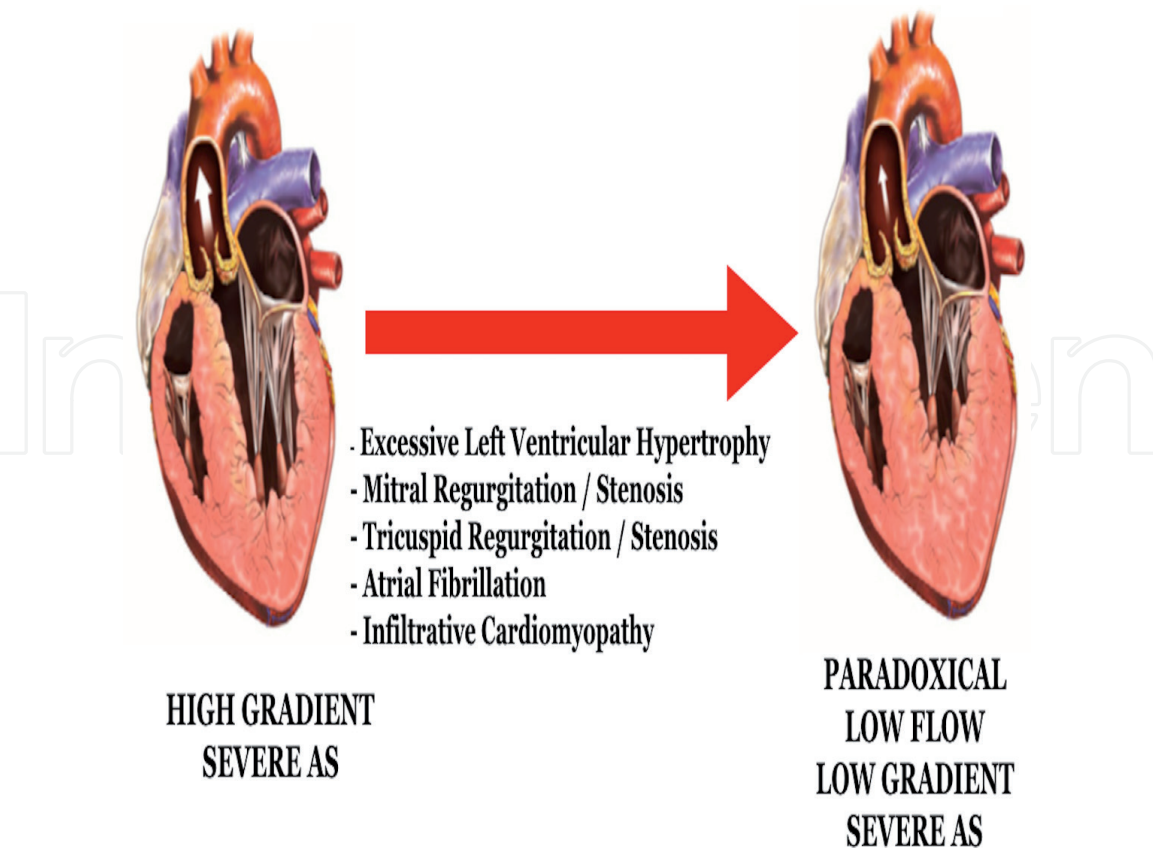


Figure 5.
Factors leading to transformation of high gradient severe aortic stenosis to paradoxical low flow low gradient severe aortic stenosis.

leading to small cavity size and restrictive physiology. In addition there is marked reduction in intrinsic LV systolic function that may not be apparent by routinely used echocardiographic indices. Global longitudinal strain is a more sensitive parameter that helps unmask the apparently normal LVEF in these patients. It is reduced to a larger extent due to fibrosis along the subendocardial layer. These findings suggest that paradoxical LFLG AS is a more advanced stage in the hemodynamic spectrum of severe AS [5, 18, 19] and classified in guidelines as stage D3.

2.3 Moderate aortic stenosis with left ventricular dysfunction—“pseudo-severe” aortic stenosis

One of the main challenges in the diagnosis of LFLG severe AS is distinguishing it from pseudo-severe AS, i.e., moderate AS with underlying LV dysfunction, unrelated to aortic stenosis. In this case, the primary culprit is LV dysfunction; typically due to associated cardiomyopathy (ischemic or idiopathic) or myocarditis. The myopathic ventricle fails to generate adequate blood flow to open the aortic valve sufficiently, hence overestimating severity of AS on echocardiography. At the same time, the gradients across the aortic valve are low related to lower transvalvular flow. This produces a hemodynamic picture similar to LFLG severe AS. Studies have shown that in patients with pseudo-severe AS, the 5-year survival with medical therapy is better than in true severe AS and comparable with that of propensity matched patients with heart failure with reduced ejection fraction and no evidence of valve disease (Figure 6) [20].

Paradoxically, moderate aortic stenosis for a normal ventricle may be functionally more significant for the myopathic ventricle. Some studies have suggested that moderate AS may have a detrimental effect on outcomes in patients with coexistent LV dysfunction. This concept raises the hypothesis that aortic valve replacement (AVR) may be beneficial in such patients [21, 22]. Trans-catheter Aortic Valve

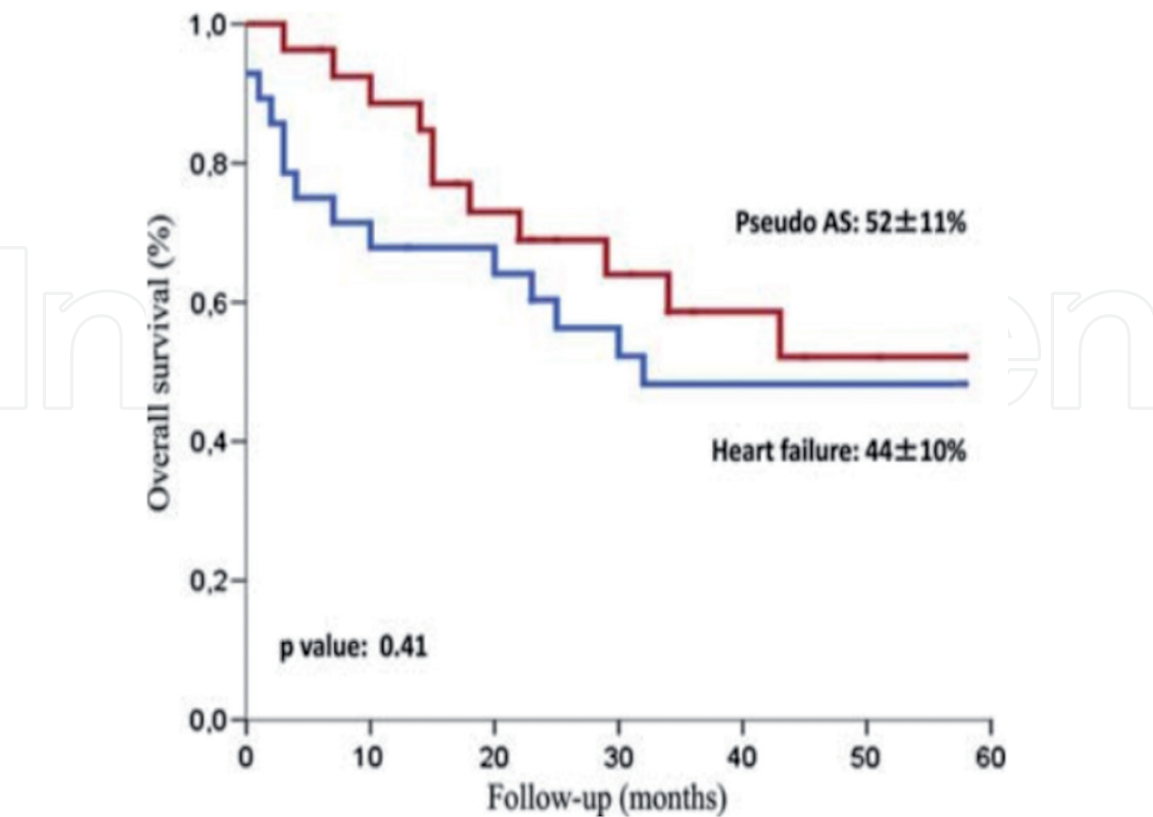


Figure 6. Kaplan-Meier survival estimates under conservative treatment among 28 patients with pseudo-severe aortic stenosis and 28 propensity-matched patients with systolic heart failure. Reproduced with permission from Fougères et al. [20].

Replacement to UNload the Left ventricle in patients with ADvanced heart failure (TAVR UNLOAD) trial is designed to test the above hypothesis. Patients with heart failure with reduced ejection fraction and moderate AS confirmed by resting and/or dobutamine stress echocardiography are randomized to optimized heart failure therapy alone versus optimized heart failure therapy plus transcatheter AVR.

3. Diagnosis of low flow low gradient severe aortic stenosis

Transthoracic echocardiogram is the gold standard to detect the “low flow state” across the aortic valve. Accurate Doppler echocardiographic measurements of stroke volume, AVA, and gradient are important to minimize underestimation of severe AS or an overestimation of moderate AS.

3.1 Echocardiographic caveats in estimating AS severity

Typically Doppler echocardiographic assessment is operator dependent. Optimal alignment of the continuous wave Doppler beam with the direction of the aortic flow jet is crucial to accurately quantify aortic valve gradient, aortic valve area and thereby severity of AS. The apical window detects peak velocity in 40% of cases whereas the right parasternal window picks up peak velocity in 50% of cases [23]. A multiwindow approach is recommended which includes apical, right parasternal, suprasternal and right supraclavicular windows.

The most common technical pitfall that may lead to an erroneous diagnosis of low-flow state and overestimation of AS severity is underestimation of the left ventricular outflow tract (LVOT) diameter. The effective AVA is determined by the continuity equation method (**Figure 7**), which is based on the principle that the flow across the left ventricular outflow tract should be equal to the flow across the aortic valve. Since the LVOT diameter is squared in the equation, an underestimation of the LVOT diameter may lead to underestimation of valve area and thus the false conclusion that the patient has LFLG severe AS when, in fact, the patient has normal flow and/or moderate AS.

The 2009 European Association of Echocardiography/American Society of Echocardiography guidelines suggest measuring the diameter and velocity 5–10 mm below the aortic annulus. However, recent studies suggest measuring the LVOT diameter inner-edge-to-inner-edge from the base of the right coronary cusp anteriorly to the commissure posteriorly [24, 25]. From a practical standpoint, an easy way to measure the LVOT diameter is to assess the pulse wave Doppler signal from the distal to proximal LVOT in the apical view. The LVOT velocity time integral is then measured just below the point where aliasing is seen, when the flow signals are smooth with sharp borders. The LVOT diameter is ideally measured at this point in the parasternal long axis view (**Figure 8**).

3.1.1 Dobutamine stress echocardiography

Once technical errors in measurement are ruled out, it is essential to distinguish LFLG true severe AS from pseudo-severe AS. deFilippi et al. [26] were the first to demonstrate that low dose (up to 20 µg/kg/min) dobutamine stress echocardiography (DSE) may be used in these patients to distinguish true versus pseudo-severe stenosis. The use of DSE for this purpose has received a class IIa (level of evidence: B) recommendation in the American College of Cardiology/American Heart Association-European Society of Cardiology (ACC/AHA-ESC/EACTS) guidelines [1–3], and a similar protocol has also been used for invasive assessment in cardiac catheterization laboratory by Nishimura et al. [27].

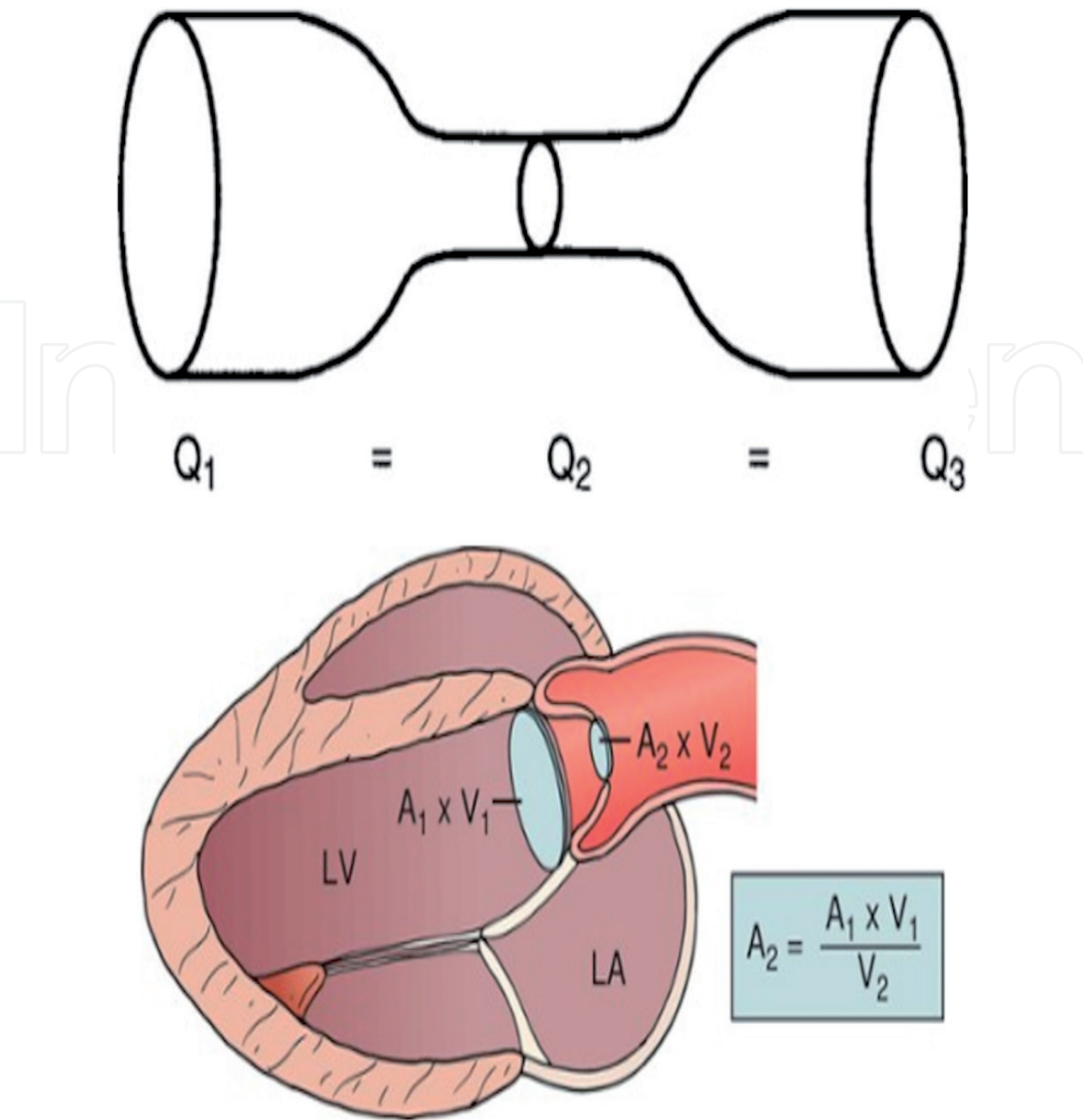


Figure 7.
Continuity equation, formula to calculate aortic valve area. The LVOT is assumed to be cross sectional in area.

Dobutamine recruits myocardial contractility in normal and hibernating myocardium, thus enhancing stroke volume and transvalvular flow. This is referred to as “stroke volume reserve.” Patients with more than 20% rise in stroke volume at peak dobutamine levels are referred to as having stroke volume reserve. When the flow across the valve increases, depending on the underlying condition, one of two possibilities occurs. If the patient has true severe AS, the valve being intrinsically restricted cannot open up further. In this case the transaortic gradients will increase with little or no change in aortic valve area. On the other hand in patients with pseudo-severe AS, aortic valve area increases significantly ($>0.6 \text{ cm}^2/\text{m}^2$) with little or no change in trans-aortic gradients (**Figure 9**).

Though not incorporated into guidelines, in our experience, DSE can also be used in patients with LFLG severe AS with preserved LVEF. Dobutamine is able to recruit the subendocardial longitudinally oriented myocardial fibers and further increase transvalvular flow. Studies have estimated that about 30–40% of patients with LFLG severe AS may not have adequate stroke volume reserve ($<20\%$ rise in stroke volume with peak dobutamine stress) [9, 21, 26–28]. They have higher operative mortality (22–33%) than those with flow reserve (5–8%) [9]. However the presence or absence of flow reserve cannot be used to predict recovery of LV function after valve replacement

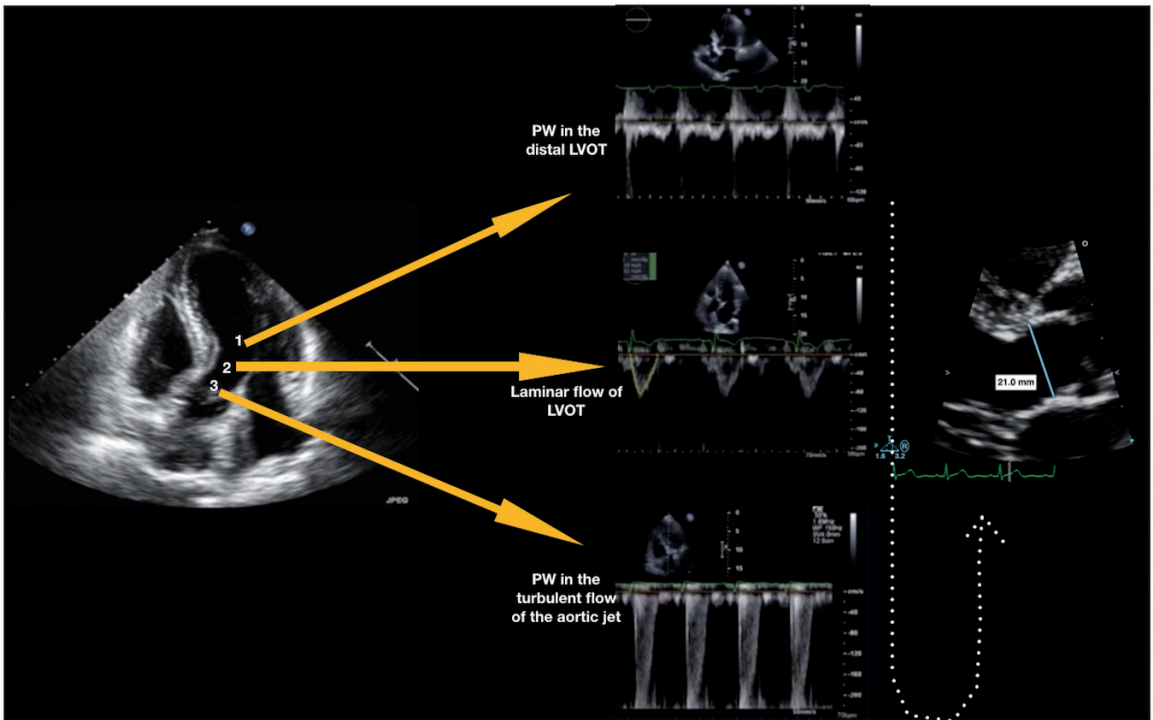


Figure 8.
The pulse wave Doppler is walked from the distal to proximal LVOT. At point 3, aliasing is noted suggesting that the Doppler signal is within the turbulent aortic jet. The pulse wave Doppler is moved just distal to point 3 (at point 2) where laminar LVOT velocities are seen. The LVOT VTI is measured at this point and the LVOT diameter at this corresponding point in the parasternal long axis view.

DSE with Positive LV Flow Reserve	EOA	GRADIENT		
TRUE SEVERE AS	Little or no change in area	> 40mmHg	Truly Severe Valve	
PSEUDO SEVERE AS	EOA > 1cm ² or iAVA > 0.6	< 40mmHg	Pseudo Severe Valve	

Figure 9.
In the presence of stroke volume reserve, if the valve area remains more or less constant with increase in gradient >40 mmHg, it is suggestive of true severe AS. On the other hand, if the valve area increases with no significant change in gradients, it is suggestive of pseudo severe AS.

and cannot be used to determine long term prognosis. The French Multicenter Study of LFLG AS reported that, in patients with no LV flow reserve who survived surgical aortic valve replacement (SAVR) had similar improvement in post-operative LVEF and late survival rate compared to patients with preserved LV flow reserve [29] (**Figure 10**). These findings suggest that DSE is useful to distinguish true severe from pseudo-severe AS and estimate operative risk. However, DES does not predict recovery of

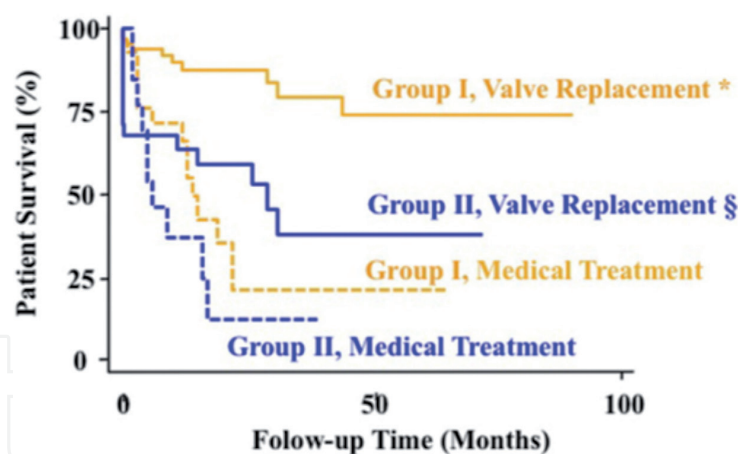


Figure 10.

Patients with no LV flow (contractile) reserve (Group II) defined as 20% increase in stroke volume during DSE have markedly reduced survival compared with those with LV flow reserve (Group I), regardless of the type of treatment. Aortic valve replacement is associated with dramatic improvement in survival in patients with LV flow reserve and a trend for better survival in those with no flow reserve. * $p < 0.001$ versus medical; § $p = 0.07$ versus medical. Adapted with permission from Monin et al. [9].

LV function, improvement in symptom status, and late survival after SAVR [9, 13, 30]. Though the absence of flow reserve portends higher perioperative mortality, DSE should only be used as a diagnostic modality. The absence of LV flow reserve should not exclude patients for AVR [9, 12].

3.1.2 Projected effective orifice area

DSE results may be inconclusive in 30–40% due to inadequate stroke volume reserve [9, 13]. In this patient subset, the investigators of the TOPAS (Truly or Pseudo-Severe Aortic Stenosis) study proposed to calculate the projected effective orifice area (EOA) that would have occurred at a standardized flow rate of 250 ml/s (EOAProj) [21, 31] (**Figure 11**). This parameter, standardized for flow, has been shown to better predict the actual hemodynamic severity of the valve stenosis and the clinical outcome of patients with classical or paradoxical LFLG AS, as compared with standard stress echocardiography parameters [8, 21, 33]. A projected AVA $< 1.0 \text{ cm}^2$ confirms the presence of true severe AS (**Figure 11**). Some patients may not have an adequate increase in stroke volume but nevertheless will have an increase in transvalvular flow rate due to shortening of ejection time. The phase III of the TOPAS study is currently underway and is expected to be completed by 2022.

3.1.3 CT calcium score of the aortic valve

About 15–20% of patients may have inconclusive results from DSE and may not have adequate transvalvular flow rate to calculate projected effective orifice area. DSE can be used in patients with paradoxical LFLG AS; however, some patients with very small LV cavities can develop dynamic LVOT obstruction and hypotension. For such patients, an alternative method to assess aortic stenosis severity is proposed.

Multi detector computerized tomography (MDCT) scan without contrast can accurately quantify calcium distribution along the AV leaflets. Calcium burden along the AV leaflets has been shown to correlate with severity of aortic stenosis [34]. It is an anatomical test independent of hemodynamics, blood flow and does not require administration of contrast or any stress agents. For the quantitation of calcification, a non-contrast MDCT scan during trained end-inspiration breath-hold is performed. Radiation exposure for such an examination is $< 3 \text{ mSV}$. The amount of calcification in the region of the aortic valve is quantitated using the

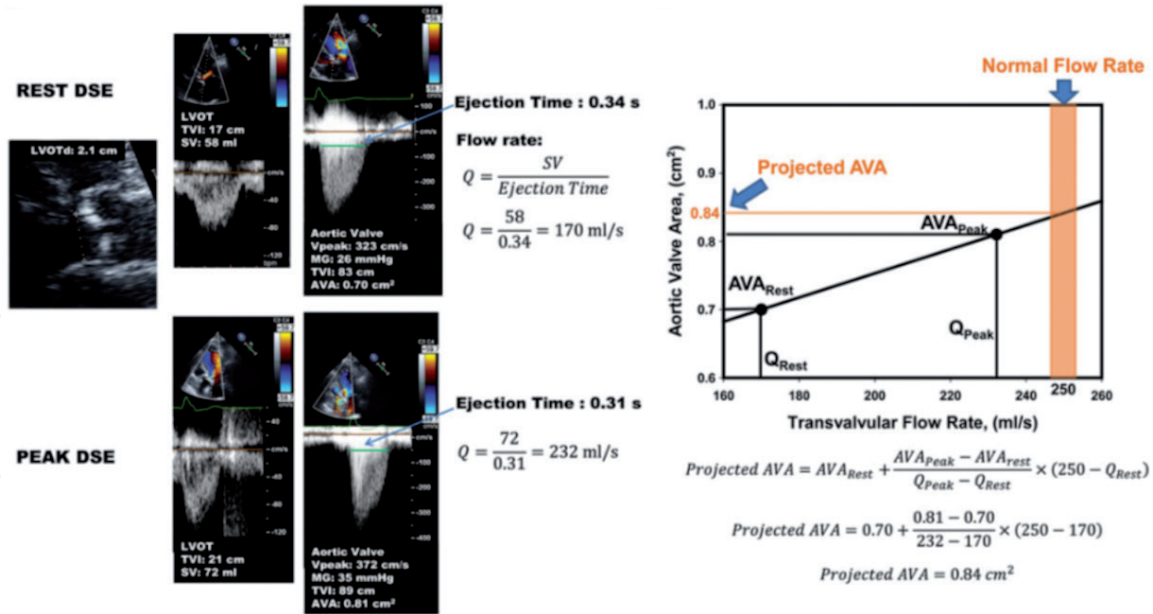


Figure 11. DSE in a patient with low flow low gradient state across the aortic valve. Even with dobutamine the valve area is 0.81 cm^2 and the mean gradient is still $<40 \text{ mmHg}$. Due to inconclusive results, the projected effective orifice area is calculated at a normalized flow rate of 250 ml/s which is 0.84 cm^2 suggesting the presence of true severe AS. Adapted with permission from Clavel et al. [32].

modified Agatston method, in which calcification is defined as four adjacent pixels with a density >130 Hounsfield Units [35]. The aortic valve calcium score measured by MDCT strongly correlates with hemodynamic severity, the progression rate, and the clinical outcomes of AS patients [34, 36, 37]. Women tend to develop less calcification for the same degree of severity of stenosis. Cut off values for valve calcification to differentiate severe versus non-severe AS in men is $>2000 \text{ AU}$ and in women $>1200 \text{ AU}$ [34, 38]. The same approach should be applied when using cutoff point for aortic valve calcium density (i.e., calcium score indexed to LVOT area): $>500 \text{ AU/cm}^2$ in men versus $>300 \text{ AU/cm}^2$ in women [34–38] (**Figure 12**).

It is important to note that MDCT grossly underestimates valve fibrosis and hence significantly underestimates severe AS in younger patients [39]. Hence this technique may be used in older patients where the degenerative aortic valve pathology is driven by valve calcification.

3.1.4 Invasive assessment of aortic stenosis in the catheterization laboratory

3.1.4.1 Pitfalls of echocardiography in diagnosis of AS

The advent of echocardiography revolutionized the field of cardiology providing hemodynamic data that could only be previously obtained by invasive cardiac catheterization. However echocardiographic derivations are based on some basic assumptions, which might not be reliable for all patient anatomy. Furthermore, there are limitations on subjective assessment by personnel with varying experience. Doppler measurements are dependent on the angle of insinuation of the sound waves against the jet of blood flow across the aortic valve (**Figure 13**). Depending on the restriction along the leaflet coaptation edges, the jet of blood through the stenosed AV, can be eccentric. This makes it almost impossible to align the continuous wave Doppler perpendicular to the jet. The peak velocity is inversely proportional to the cosine of the angle of insinuation. Even a 1° off axis tilt may reduce the peak velocity by 0.04 m/s representing an error of 1%, considering a cut off value of 4 m/s for severe aortic stenosis. When the estimated velocity is squared to calculate pressure gradient across the aortic valve, any error is exponentially increased.

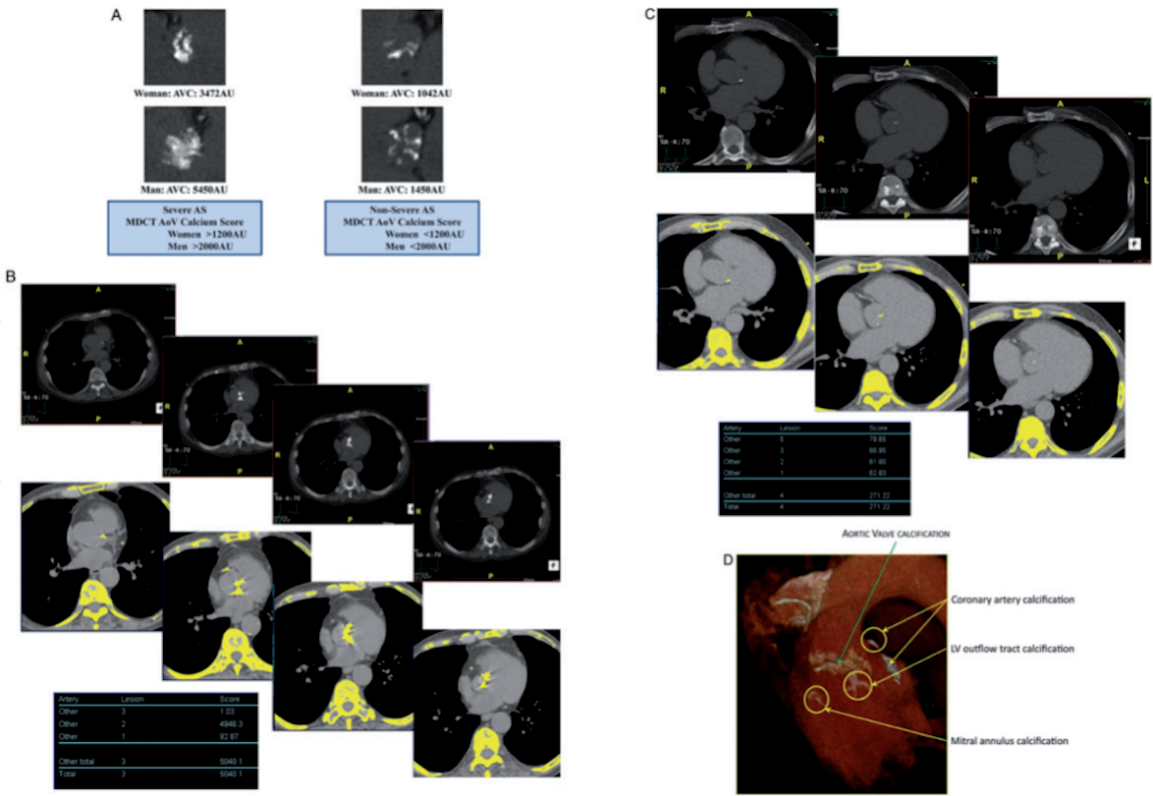


Figure 12. Quantitation of aortic valve calcium by multi-detector computed tomography for the assessment of stenosis severity in low-gradient aortic stenosis. (A) Multi-detector computed tomography can be used to quantitate aortic valve calcification by the modified Agatston method. With this method, calcification is defined as four adjacent pixels with density 0.130 Hounsfield units. Different cut-point values of valve calcium score should be used in women (0.1200 AU) versus men (0.2000 AU) to differentiate true-severe versus pseudo-severe stenosis in low-flow, low-gradient aortic stenosis. (B) Serial multi-detector computed tomography slices at the level of the aortic valve showing a severely calcified valve with a calcium score of 5040 AU consistent with true-severe aortic stenosis. Calcified areas are displayed in yellow in the bottom images. (C) Mild calcification (score 271 AU) consistent with pseudo-severe aortic stenosis. (D) Pitfalls in the assessment of aortic valve calcification by multi-detector computed tomography. For the calculation of calcium score, it is important to only include aortic valve calcification and exclude calcification of aorta, coronary arteries, LVOT, and mitral annulus. Adapted with permission from Clavel et al. [32].

Another common limitation of echocardiography is the assumption that LVOT is circular in cross section, when in fact it is circular in only 1–2% of cases (**Figure 14**). The LVOT is a three-dimensional (3D) dynamic structure that is often elliptical, with the antero-posterior dimension representing the smaller minor axis diameter, as compared with the generally larger diameter in the sagittal plane. Hence, 2D echocardiography may underestimate the LVOT area compared with 3D imaging modalities such as 3D echocardiography, MDCT, or cardiac magnetic resonance [40–43]. To overcome the potential underestimation of the LVOT diameter and stroke volume and AVA by 2D echocardiography, the use of a hybrid approach has been suggested, where the LVOT area is measured by MDCT or 3D echocardiography and the LVOT and aortic flow velocities are measured by Doppler echocardiography [43, 44]. However, it is also important to note, the AVA value generally used to define severe AS $<1.0\text{ cm}^2$, has been established and validated by outcome studies, where AVA was measured by standard 2D Doppler-echocardiography [2, 4]. A recent study demonstrated that the hybrid approach systematically overestimates the LVOT area and thus AVA. The best discriminative hybrid AVA to predict mortality in patients with AS under medical treatment was larger (1.2 cm^2) versus the Doppler-echocardiographic AVA (1.0 cm^2) [43].

Finally, it becomes difficult to obtain LVOT velocity time integral when there is associated subaortic fixed or dynamic obstruction contributing to transvalvular gradients.

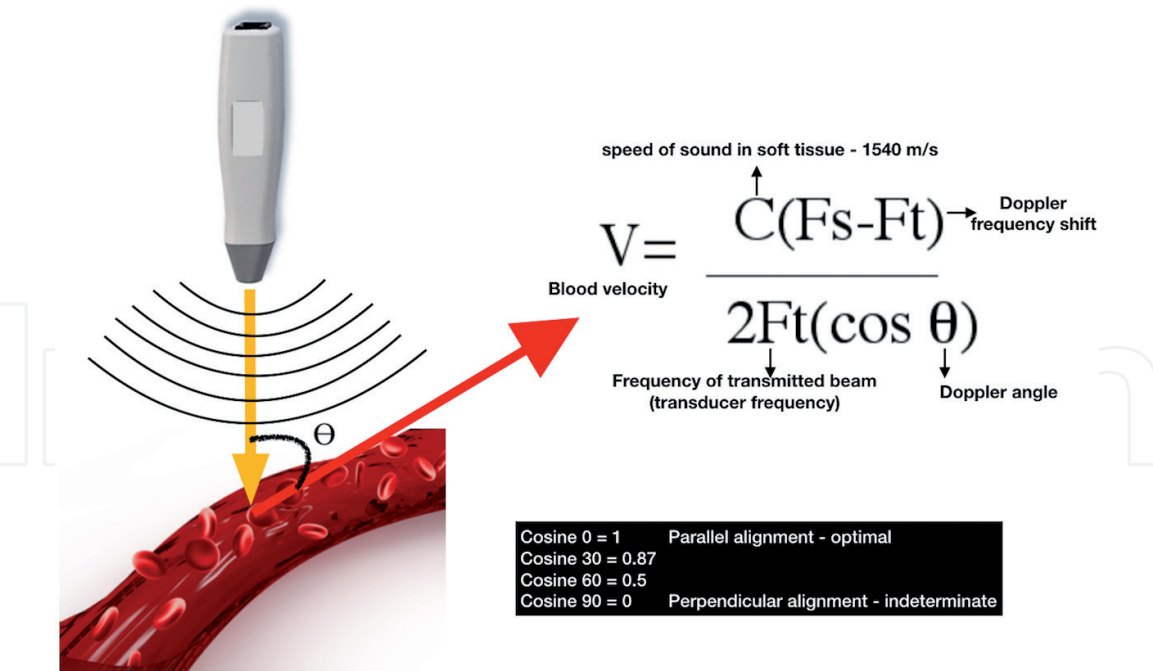


Figure 13.
Doppler measurements are angle dependent. For optimal values the angle of insinuation should be parallel/ antiparallel (0 or 180°) to the flow of blood. As the Doppler angle increases, the measured velocities decrease, thus underestimating velocities.

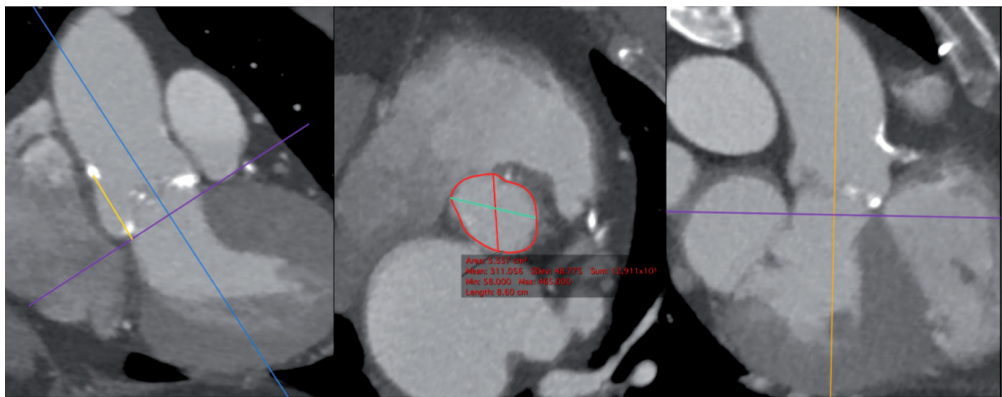


Figure 14.
CT showing elliptical shape of the LVOT.

3.1.4.2 Invasive assessment of severe AS

Currently invasive measurement is recommended only when non-invasive tests are inconclusive, the patient has poor echo windows or when there is significant discrepancy between the patient’s clinical symptoms and echocardiographic data. **Figure 15** shows the steps of invasive assessment of aortic stenosis in the catheterization lab. Ideally simultaneous pressure gradients are measured by obtaining dual arterial access. Single arterial puncture may also be used for diagnosis by inserting a 7F long sheath reaching the ascending aorta from where pressure can be transduced from the side port of the long sheath. The pressure from the left ventricle should be transduced through a 5F pigtail catheter inserted into the left ventricle through the long sheath. The cardiac output is measured either by thermodilution using a Swan Ganz catheter or by Fick’s principle. Dobutamine stress can be achieved using incremental doses, infused through a venous sheath. Cardiac output, mean gradient across the aortic valve, aortic valve area and iAVA is calculated after at least 2 minutes of incremental dobutamine infusion [27].

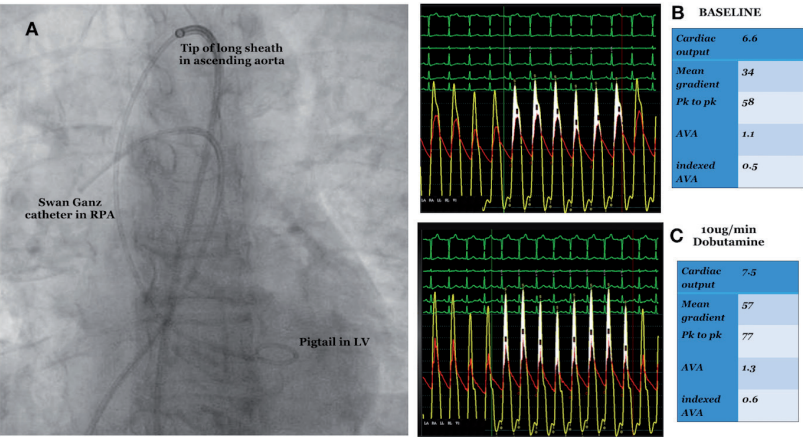


Figure 15. Invasive assessment of low flow gradient AS in the Cathlab. Panel A shows the initial setup of the catheters. A 7F long sheath is positioned with its tip in the ascending aorta from where aortic pressures are transduced. A 5F pigtail is positioned in the LV through the long sheath to measure LV pressures. A Swan Ganz catheter is positioned in the pulmonary artery to measure cardiac output at each stage. Panel B—at baseline the patient is shown to have an indexed valve area of 0.5 cm², with a mean gradient of 34 mmHg across the aortic valve. Panel C—with 10 µg/min of dobutamine, the trans-aortic gradients increase from 34 to 57 mmHg with no significant change in indexed valve area suggesting the presence of true severe AS.

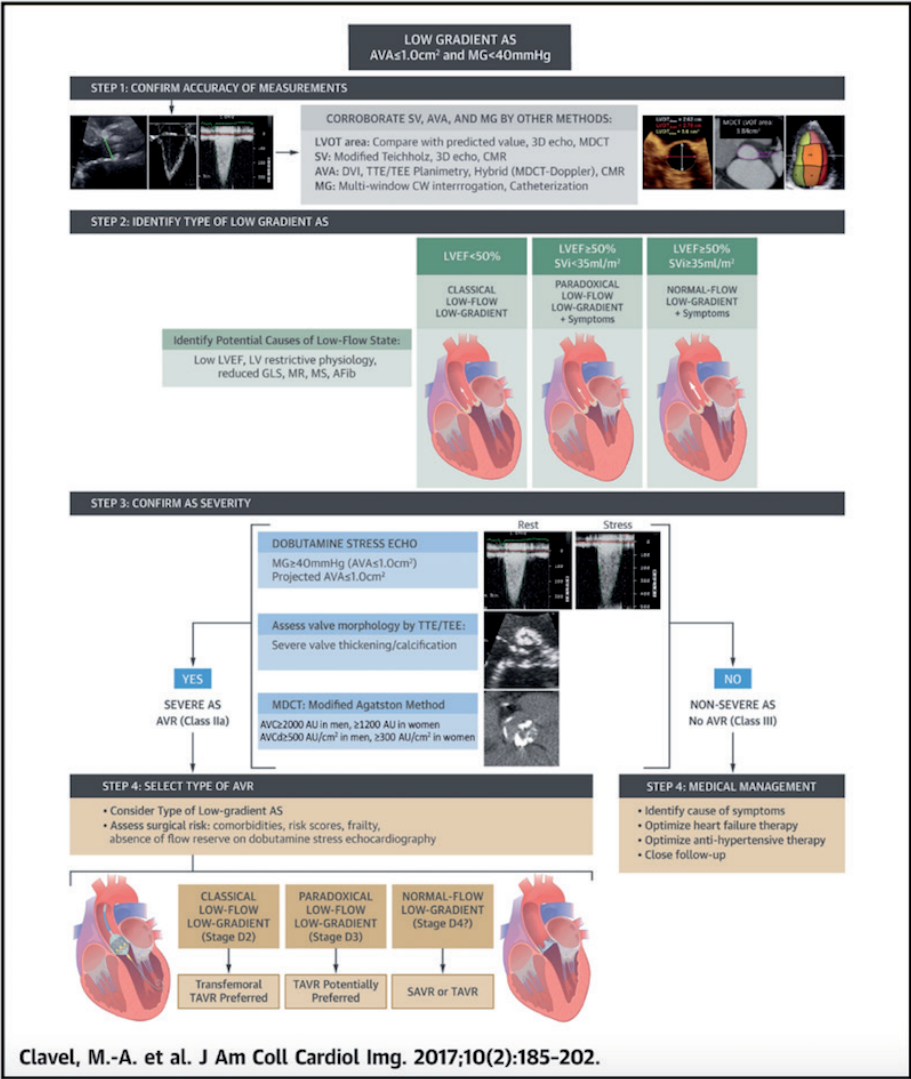


Figure 16. Four-step algorithm for the diagnostic and therapeutic management of low-gradient AS. AVC ¼ aortic valve calcification; AVCd ¼ aortic valve calcification density; AVR ¼ aortic valve replacement; CMR ¼ cardiac magnetic resonance; MDCT ¼ multi-detector computed tomography; RCT ¼ randomized controlled trial; TEE ¼ transesophageal echocardiography; TTE ¼ transthoracic echocardiography. Reproduced with permission from Clavel et al. [1].

Invasive assessment is not limited by the factors that confound echocardiographic measurement mentioned above. In the presence of serial obstruction, an end hole catheter can be positioned above and below the point of interest and pressure gradients can be reassessed. In this scenario, it is possible to determine the site that contributes maximally to gradients—either the valve or the obstruction further down in the LVOT, thus facilitating accurate diagnosis.

Another advantage of invasive assessment is that the operators often perform coronary angiography prior to potentially inducing dobutamine stress. When there is no flow limiting coronary artery disease, higher doses of dobutamine (up to 40 µg/kg body weight) can be used to obtain a conclusive result. When there is associated significant coronary artery disease, high dose dobutamine (>30 µg/kg body weight) can result in a “biphasic response,” further reducing blood flow across the aortic valve, thus confounding results. This is one of the main reasons why a low dose dobutamine is recommended when doing a DSE. In the cardiac catheterization laboratory however, any significant coronary artery disease can be treated percutaneously before escalating to higher doses of dobutamine to diagnose LFLG severe AS.

The disadvantage of invasive assessment is the potential complications of cardiac catheterization, especially when crossing the heavily calcified aortic valve; in particular stroke. In the presence of a small aortic root, the phenomenon of “pressure recovery” may confound gradients by increasing aortic pressure and under estimating transvalvular pressure gradients.

The diagnosis of LFLG severe aortic stenosis requires a systematic approach with a series of tests. **Figure 16** summarizes an algorithm for assessment of low flow low gradient aortic stenosis.

4. Prognosis and management

The importance of establishing the diagnosis of LFLG severe AS is reflected in its differing prognosis to high gradient severe AS. Not only are the outcomes with conservative management worse in LFLG AS, studies have also suggested poorer outcomes following intervention.

4.1 “Classical” low flow low gradient severe AS with reduced left ventricular ejection fraction: (stage D2)

Among the subgroups of severe AS, classical LFLG AS has the worst clinical outcome. With medical management the 2-year survival is approximately 40–60%. Thirty-day mortality of SAVR is high depending on the presence or absence of flow reserve (8–33%) [8, 9, 12, 13, 29]. However, if patients survive SAVR, there is a prognostic benefit compared to medical therapy. There is limited head to head randomized data comparing SAVR and TAVR in patients with LFLG severe AS. There are few studies that suggest that TAVR leads to better and faster LV function recovery compared to SAVR [45, 46]. It is well known that TAVR, especially with supra-annular valves leads to less patient prosthesis mismatch, which is an independent predictor of worse outcomes [46], especially in patients with reduced LV ejection fraction. In patients with no flow reserve who represent the highest risk subgroup, TAVR may have a definite survival benefit over SAVR. Though the PARTNER I trial conclusively proved the superiority of TAVR to medical management and similar outcomes to SAVR [47], patients with no LV flow reserve as well as those with very low LVEF were excluded. More randomized studies are needed to confirm the superiority of TAVR over SAVR in patients with classical LFLG severe AS (stage D2).

The heart team plays the central role in selecting the most appropriate modality of treatment, i.e., TAVR versus SAVR versus medical management (**Figure 17**).

A comprehensive risk stratification algorithm that takes into consideration risk scores (STS), frailty indices, major organ compromise and procedure specific impediments is used by the heart team to risk stratify the patient. Ideally the risk stratification process may also take into consideration specific factors that are not mentioned in the guidelines. These include preoperative NHYA class >III, low trans-aortic gradient (<20 mmHg), absence of flow reserve and reduced global longitudinal strain. A reduced global longitudinal strain, by itself suggests high risk, independent of risk scores (STS/Euroscore) [8, 9, 12].

Palliative balloon aortic valvuloplasty and medical management should be considered in patients with an expected life expectancy <1 year (**Figure 17**). In patients with classical LFLG severe AS with prohibitive and high surgical risk TAVR is recommended. In patients with intermediate surgical risk, SAVR or TAVR may be considered depending heart team evaluation; depending on other factors such as frailty, major organ compromise and procedure specific impediments (hostile chest in case of SAVR or vascular access route for TAVR).

4.2 Paradoxical low flow low gradient severe AS with preserved ejection fraction (stage D3)

Patients with paradoxical LFLG AS fare better than patients with classical LFLG AS [5, 18, 48]. The PARTNER I cohort B is the only randomized trial that reports better survival after TAVR compared to medical management [47], all other studies

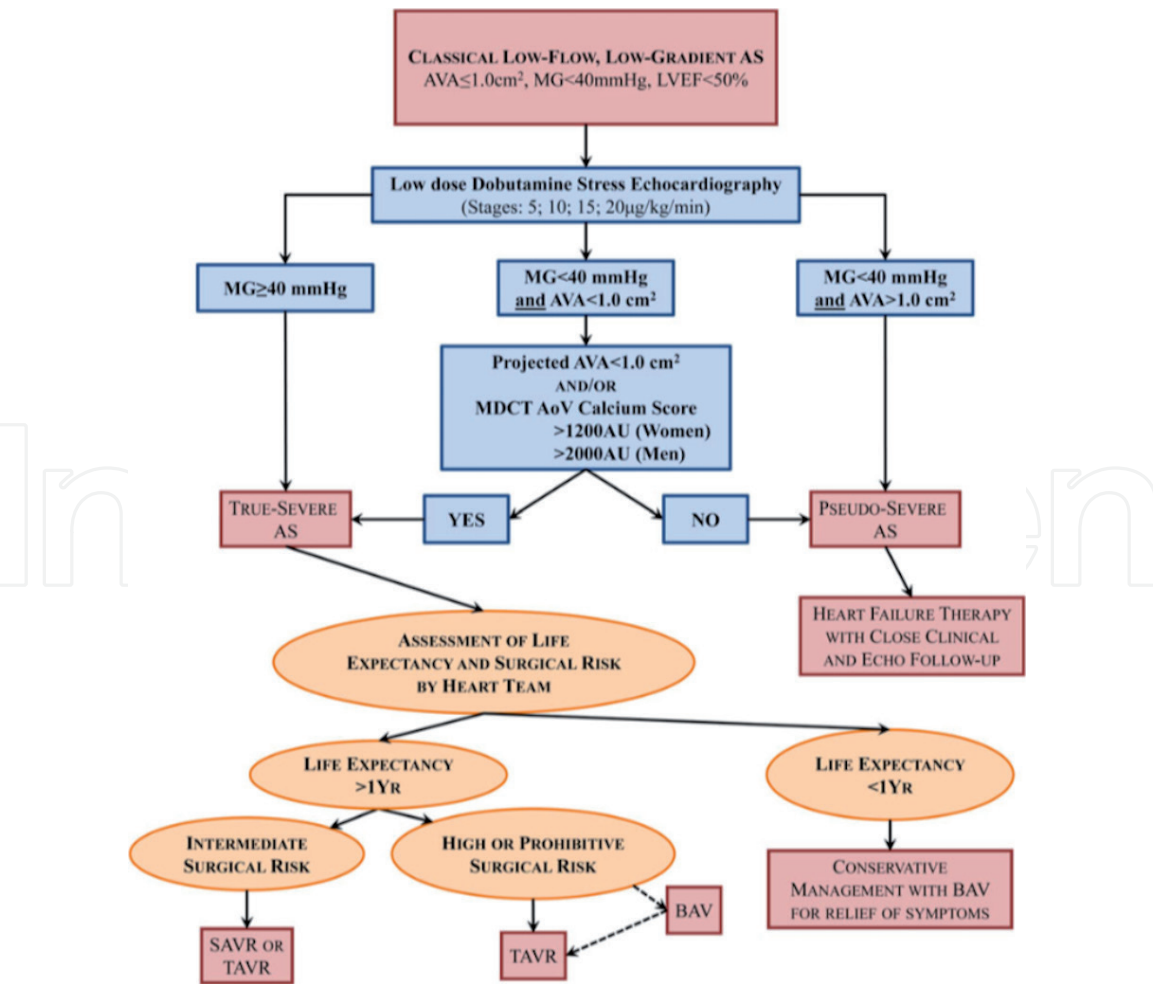


Figure 17. Algorithm for the management of classical (reduced left ventricular ejection fraction) low-flow, low-gradient aortic stenosis. AoV, aortic valve; BAV, balloon aortic valvuloplasty; MDCT, multi-detector computed tomography; SAVR, surgical aortic valve replacement; TAVR, transcatheter aortic valve replacement. Reproduced with permission from Clavel et al. [32].

being observational. AVR reduces mortality by 57% in patients with paradoxical LFLG AS [49].

LVEF is a relatively poor and misleading parameter in assessing LV function especially in paradoxical LFLG AS. Higher degree of myocardial fibrosis documented either by cardiac magnetic resonance imaging or global longitudinal strain are independent risk factors for mortality in patients with paradoxical LFLG AS [50, 51].

The role of plasma brain natriuretic peptide (BNP) in risk stratification of patients with paradoxical LFLG AS is unclear [30]. Owing to significant LV concentric remodeling and small LV cavities, the LV wall stress may even be normal, thus the extent of myocardial stretch and release of BNP may not accurately reflect the severity of impairment of myocardial structure/function in these patients.

A systematic heart team approach is recommended to optimize outcomes (Figure 18). Aortic valve replacement should be considered in symptomatic patients with paradoxical LFLG and true severe AS. TAVR may be superior to SAVR in patients with paradoxical LFLG AS [47]. Certain factors intrinsic to patients with paradoxical LFLG AS pose higher surgical risks compared to patients with high gradient AS. These include higher prevalence in female sex, older age, systemic hypertension, atrial fibrillation, restrictive LV physiology and smaller aortic annulus that predisposes to patient prosthesis mismatch [52–54]. TAVR was associated

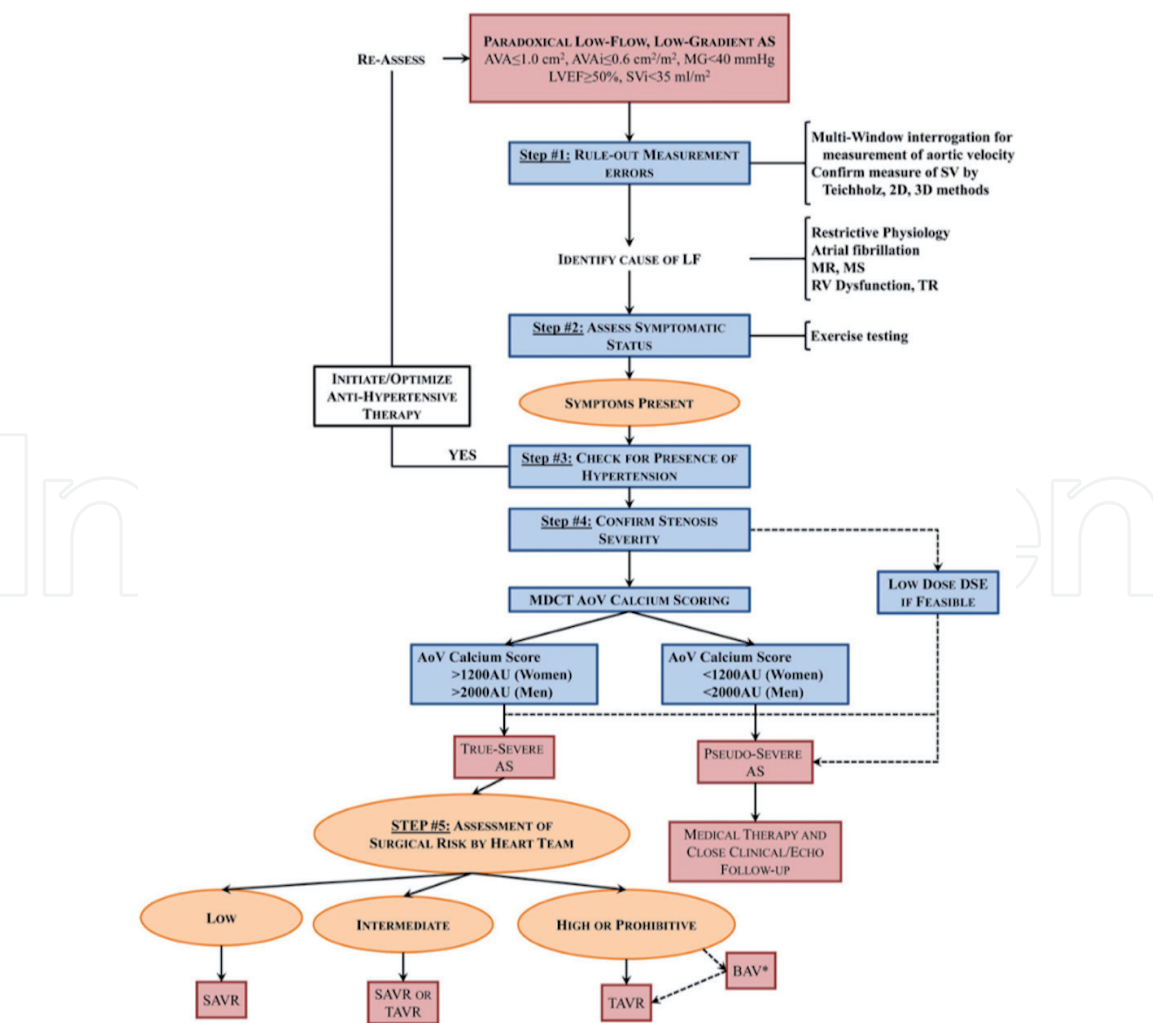


Figure 18. Algorithm for the management of paradoxical (preserved left ventricular ejection fraction) low-flow, low-gradient aortic stenosis. AVA_i , indexed aortic valve area; MR, mitral regurgitation; MS, mitral stenosis; TR, tricuspid regurgitation. Reproduced with permission from Clavel et al. [32].

with better 1-year survival compared with SAVR in patients with paradoxical LFLG AS in the PARTNER-I Cohort A trial. Further studies are needed to confirm the potential superiority of TAVR versus SAVR in this subset of patients.

5. Role of diagnostic balloon aortic valvuloplasty

In 1986, Cribier et al. [55] first described balloon aortic valvuloplasty (BAV) as a treatment strategy for patients with symptomatic severe AS presenting in cardiogenic shock, or who were deemed too high risk for conventional SAVR. Due to procedural complications, high incidence of restenosis within 6 months, lack of sustained clinical and hemodynamic benefit, BAV was not routinely performed. Furthermore, mortality rates within a year of BAV was similar to others with severe AS who were managed conservatively [56].

Table 1 lists the current status of BAV according to major guidelines. BAV has a class IIb recommendation for use as a bridge therapy to TAVR or SAVR in hemodynamically unstable patients at high risk for surgery. In the European guidelines (2017) BAV is recommended as a palliative measure in patients not suitable for TAVR or SAVR and in patients with symptomatic severe AS who require urgent noncardiac surgery. The American Heart Association (AHA)/American College of Cardiology (ACC) guidelines (2014) are similar to the European guidelines except they do not recommend the use of BAV as a palliative procedure nor its use in patients undergoing urgent non-cardiac surgery. However it does acknowledge that some patients report an improvement in their symptoms post BAV. The role of BAV as bridge to decision in high-risk patients has been supported by a number of studies [57]. The rationale behind such a strategy is listed below.

- i. BAV helps to choose the best therapeutic option for each patient; avoiding expensive or high risk intervention for patients who may not have prognostic benefit from definitive treatment of AS.
- ii. BAV may be utilized to palliate symptoms and reduce operative risk while awaiting TAVR or SAVR.
- iii. BAV may be used as a diagnostic procedure especially in patients with concomitant severe pulmonary disease. The improvement in symptom status post BAV can attribute dyspnea to severe AS rather than lung disease alone.
- iv. DSE is used to assess contractile reserve in patients with severe AS. It helps in diagnosis and predicting perioperative mortality but cannot predict LV function recovery. In this subgroup of patients, LV function can be reassessed after 4–8 weeks after “diagnostic” BAV. Recovery of LV function post BAV is a good indicator of contractile reserve and predicts sustained LV function improvement post SAVR/TAVR [58].
- v. It has been demonstrated that nearly 50% of patients with severe AS and coexistent mitral regurgitation (MR) showed a reduction in the magnitude of MR after BAV [59]. A similar reduction is also seen with pulmonary artery systolic pressure [60]. BAV therefore negates the need for multiple valve intervention and reduces the overall the risk of SAVR.
- vi. BAV may be used as a palliative procedure in patients with serious comorbidities, frailty, cognitive alteration, severe lung disease or life expectancy less than a year.

Indication for BAV in severe symptomatic aortic stenosis	ESC (2017)	ACC/AHA (2014)
As bridge therapy for all patients undergoing TAVI or AVR	✗	✓
As bridge therapy for haemodynamically unstable patients undergoing TAVI or AVR	✓	✓
For patients requiring urgent non-cardiac surgery	✓	✗
Palliative BAV for symptom benefit	✓	✗

Table 1.
Summary of ESC and ACC/AHA guidelines for the role of BAV in managing symptomatic severe AS.

6. Conclusion

Clinicians should be mindful that patients with symptomatic severe AS may well have low flow and thereby low gradient. Occasionally symptoms may represent severity of underlying heart failure rather than the severity of AS. Established minimally invasive trans-catheter therapies, although has improved associated morbidities of SAVR for intermediate and high-risk patients, it is important that treatment is directed to those who will benefit the most. Accurate diagnosis of severe AS is important as treatment modalities and its timing can offer prognostic benefits in the immediate and long term.

Conflict of interest

Faez Mohamad Ali and Vindhya Wilson—no conflict of interest.
Rajesh Nair—proctor for Medtronic.

Author details

Faez Mohamad Ali¹, Vindhya Wilson² and Rajesh Nair^{1*}

1 Waikato Hospital, Hamilton, New Zealand

2 Nelson Hospital, New Zealand

*Address all correspondence to: drnrnair@gmail.com

IntechOpen

© 2019 The Author(s). Licensee IntechOpen. This chapter is distributed under the terms of the Creative Commons Attribution License (<http://creativecommons.org/licenses/by/3.0>), which permits unrestricted use, distribution, and reproduction in any medium, provided the original work is properly cited. 

References

- [1] Clavel MA, Burwash IG, Pibarot P. Cardiac imaging for assessing low-gradient severe aortic stenosis. *JACC: Cardiovascular Imaging*. 2017;**10**(2):185-202
- [2] Nishimura RA, Otto CM, Bonow RO, Carabello BA, Erwin JP 3rd, Guyton RA, et al. 2014 AHA/ACC guideline for the management of patients with valvular heart disease: A report of the American College of Cardiology/American Heart Association Task Force on Practice Guidelines. *Journal of the American College of Cardiology*. 2014;**63**(22):e57-e185
- [3] Baumgartner H, Hung J, Bermejo J, Chambers JB, Evangelista A, Griffin BP, et al. Echocardiographic assessment of valve stenosis: EAE/ASE recommendations for clinical practice. *Journal of the American Society of Echocardiography*. 2009;**22**(1):1-23
- [4] Vahanian A, Alfieri O, Andreotti F, Antunes MJ, Barón-Esquivias G, Baumgartner H, et al. Guidelines on the management of valvular heart disease (version 2012). Joint Task Force on the Management of Valvular Heart Disease of the European Society of Cardiology (ESC); European Association for Cardio Thoracic Surgery (EACTS). *European Heart Journal*. 2012;**33**(19):2451-2496
- [5] Hachicha Z, Dumesnil JG, Bogaty P, Pibarot P. Paradoxical low flow, low gradient severe aortic stenosis despite preserved ejection fraction is associated with higher afterload and reduced survival. *Circulation*. 2007;**115**(22):2856-2864
- [6] Berthelot-Richer M, Pibarot P, Capoulade R, Dumesnil JG, Dahou A, Thebault C, et al. Discordant grading of aortic stenosis severity: Echocardiographic predictors of survival benefit associated with aortic valve replacement. *JACC: Cardiovascular Imaging*. 2016;**9**(7):797-805
- [7] Minners J, Allgeier M, Gohlke-Baerwolf C, Kienzle RP, Neumann FJ, Jander N. Inconsistent grading of aortic valve stenosis by current guidelines: Haemodynamic studies in patients with apparently normal left ventricular function. *Heart*. 2010;**96**(18):1463-1468
- [8] Connolly HM, Oh JK, Schaff HV, Roger VL, Osborn SL, Hodge DO, et al. Severe aortic stenosis with low transvalvular gradient and severe left ventricular dysfunction. Result of aortic valve replacement in 52 patients. *Circulation*. 2000;**101**(16):1940-1946
- [9] Monin JL, Quéré JP, Monchi M, Petit H, Baleynaud S, Chauvel C, et al. Low-gradient aortic stenosis: Operative risk stratification and predictors for long term outcome: A multicenter study using dobutamine stress hemodynamics. *Circulation*. 2003;**108**(3):319-324
- [10] Brogan WC 3rd, Grayburn PA, Lange RA, Hillis LD. Prognosis after valve replacement in patients with severe aortic stenosis and a low transvalvular pressure gradient. *Journal of the American College of Cardiology*. 1993;**21**(7):1657-1660
- [11] Levy F, Laurent M, Monin JL, Maillet JM, Pasquet A, Le Tourneau T, et al. Aortic valve replacement for low-flow/low-gradient aortic stenosis: Operative risk stratification and long term outcome: A European multicenter study. *Journal of the American College of Cardiology*. 2008;**51**(15):1466-1472
- [12] Tribouilloy C, Lévy F, Rusinaru D, Guéret P, Petit-Eisenmann H, Baleynaud S, et al. Outcome after aortic valve replacement for low-flow/low-gradient aortic stenosis without contractile reserve on dobutamine

stress echocardiography. *Journal of the American College of Cardiology*. 2009;**53**(20):1865-1873

[13] Clavel MA, Fuchs C, Burwash IG, Mundigler G, Dumesnil JG, Baumgartner H, et al. Predictors of outcomes in low-flow, low-gradient aortic stenosis: Results of the multicenter TOPAS study. *Circulation*. 2008;**118**(14 Suppl):S234-S242

[14] Otto CM, Burwash IG, Legget ME, Munt BI, Fujioka M, Healy NL, et al. Prospective study of asymptomatic valvular aortic stenosis. Clinical, echocardiographic, and exercise predictors of outcome. *Circulation*. 1997;**95**(9):2262-2270

[15] Rosenhek R, Zilberszac R, Schemper M, Czerny M, Mundigler G, Graf S, et al. Natural history of very severe aortic stenosis. *Circulation*. 2010;**121**(1):151-156

[16] Ross J Jr, Braunwald E. Aortic stenosis. *Circulation*. 1968;**38** (1 Suppl):61-67

[17] Dumesnil JG, Pibarot P, Carabello B. Paradoxical low flow and/or low gradient severe aortic stenosis despite preserved left ventricular ejection fraction: Implications for diagnosis and treatment. *European Heart Journal*. 2010;**31**(3):281-289

[18] Lancellotti P, Magne J, Donal E, Davin L, O'Connor K, Rosca M, et al. Clinical outcome in asymptomatic severe aortic stenosis. Insights from the new proposed aortic stenosis grading classification. *Journal of the American College of Cardiology*. 2012;**59**(3):235-243

[19] Baumgartner H, Hung J, Bermejo J, Chambers JB, Evangelista A, Griffin BP, et al. EAE/ASE. Echocardiographic assessment of valve stenosis: EAE/ASE recommendations for clinical practice. *European Journal of Echocardiography*. 2009;**10**(1):1-25

[20] Fougères E, Tribouilloy C, Monchi M, Petit-Eisenmann H, Baleynaud S, Pasquet A, et al. Outcomes of pseudo-severe aortic stenosis under conservative treatment. *European Heart Journal*. 2012;**33**(19):2426-2433

[21] Clavel MA, Burwash IG, Mundigler G, Dumesnil JG, Baumgartner H, Bergler-Klein J, et al. Validation of conventional and simplified methods to calculate projected valve area at normal flow rate in patients with low flow, low gradient aortic stenosis: The multicenter TOPAS (True or Pseudo-Severe Aortic Stenosis) study. *Journal of the American Society of Echocardiography*. 2010;**23**(4):380-386

[22] Samad Z, Vora AN, Dunning A, Schulte PJ, Shaw LK, Al-Enezi F, et al. Aortic valve surgery and survival in patients with moderate or severe aortic stenosis and left ventricular dysfunction. *European Heart Journal*. 2016;**37**(28):2276-2286

[23] Thaden JJ, Nkomo VT, Lee KJ, Oh JK. Doppler imaging in aortic stenosis: The importance of the nonapical imaging windows to determine severity in a contemporary cohort. *Journal of the American Society of Echocardiography*. 2015;**28**(7):780-785

[24] Skjaerpe T, Hegrenaes L, Hatle L. Noninvasive estimation of valve area in patients with aortic stenosis by Doppler ultrasound and two dimensional echocardiography. *Circulation*. 1985;**72**(4):810-818

[25] LaBounty TM, Miyasaka R, Chetcuti S, Grossman PM, Deeb GM, Patel HJ, et al. Annulus instead of LVOT diameter improves agreement between echocardiography effective orifice area and invasive aortic valve area. *JACC: Cardiovascular Imaging*. 2014;**7**(10):1065-1066

[26] deFilippi CR, Willett DL, Brickner ME, Appleton CP, Yancy

CW, Eichhorn EJ, et al. Usefulness of dobutamine echocardiography in distinguishing severe from nonsevere valvular aortic stenosis in patients with depressed left ventricular function and low transvalvular gradients. *The American Journal of Cardiology*. 1995;**75**(2):191-194

[27] Nishimura RA, Grantham JA, Connolly HM, Schaff HV, Higano ST, Holmes DR Jr. Low-output, low-gradient aortic stenosis in patients with depressed left ventricular systolic function: The clinical utility of the dobutamine challenge in the catheterization laboratory. *Circulation*. 2002;**106**(7):809-813

[28] Picano E, Pibarot P, Lancellotti P, Monin JL, Bonow RO. The emerging role of exercise testing and stress echocardiography in valvular heart disease. *Journal of the American College of Cardiology*. 2009;**54**(24):2251-2260

[29] Quere JP, Monin JL, Levy F, Petit H, Baleynaud S, Chauvel C, et al. Influence of preoperative left ventricular contractile reserve on postoperative ejection fraction in low-gradient aortic stenosis. *Circulation*. 2006;**113**(14):1738-1744

[30] Bergler-Klein J, Mundigler G, Pibarot P, Burwash IG, Dumesnil JG, Blais C, et al. B-type natriuretic peptide in low-flow, low-gradient aortic stenosis: Relationship to hemodynamics and clinical outcome. *Circulation*. 2007;**115**(22):2848-2855

[31] Blais C, Burwash IG, Mundigler G, Dumesnil JG, Loho N, Rader F, et al. Projected valve area at normal flow rate improves the assessment of stenosis severity in patients with low flow, low-gradient aortic stenosis: The multicenter TOPAS (Truly or Pseudo-Severe Aortic Stenosis) study. *Circulation*. 2006;**113**(5):711-721

[32] Clavel M-A, Magne J, Pibarot P. Low-gradient aortic

stenosis. *European Heart Journal*. 2016;**37**(34):2645-2657

[33] Burwash IG, Lortie M, Pibarot P, de Kemp RA, Graf S, Mundigler G, et al. Myocardial blood flow in patients with low flow, low gradient aortic stenosis: Differences between true and pseudo-severe aortic stenosis. Results from the multicenter TOPAS (Truly or Pseudo-Severe Aortic Stenosis) study. *Heart*. 2008;**94**(12):1627-1633

[34] Clavel MA, Messika-Zeitoun D, Pibarot P, Aggarwal SR, Malouf J, Araoz PA, et al. The complex nature of discordant severe calcified aortic valve disease grading: New insights from combined Doppler echocardiographic and computed tomographic study. *Journal of the American College of Cardiology*. 2013;**62**(24):2329-2338

[35] Agatston AS, Janowitz WR, Hildner FJ, Zusmer NR, Viamonte M Jr, Detrano R. Quantification of coronary artery calcium using ultrafast computed tomography. *Journal of the American College of Cardiology*. 1990;**15**(4):827-832

[36] Cueff C, Serfaty JM, Cimadevilla C, Laissy JP, Himbert D, Tubach F, et al. Measurement of aortic valve calcification using multislice computed tomography: Correlation with haemodynamic severity of aortic stenosis and clinical implication for patients with low ejection fraction. *Heart*. 2011;**97**(9):721-726

[37] Clavel MA, Pibarot P, Messika-Zeitoun D, Capoulade R, Malouf J, Aggarwal S, et al. Impact of aortic valve calcification, as measured by MDCT, on survival in patients with aortic stenosis: Results of an international registry study. *Journal of the American College of Cardiology*. 2014;**64**(12):1202-1213

[38] Aggarwal SR, Clavel MA, Messika-Zeitoun D, Cueff C, Malouf J, Araoz PA, et al. Sex differences in aortic valve

calcification measured by multidetector computed tomography in aortic stenosis. *Circulation. Cardiovascular Imaging*. 2013;**6**(1):40-47

[39] Shen M, Tastet L, Capoulade R, Larose É, Bédard É, Arsenault M, et al. Effect of age and aortic valve anatomy on calcification and haemodynamic severity of aortic stenosis. *Heart*. 2017;**103**(1):32-39

[40] Jilaihawi H, Doctor N, Kashif M, Chakravarty T, Rafique A, Makar M, et al. Aortic annular sizing for transcatheter aortic valve replacement using cross sectional 2-dimensional transesophageal echocardiography. *Journal of the American College of Cardiology*. 2013;**61**(9):908-916

[41] Chin CW, Khaw HJ, Luo E, Tan S, White AC, Newby DE, et al. Echocardiography underestimates stroke volume and aortic valve area: Implications for patients with small area low-gradient aortic stenosis. *The Canadian Journal of Cardiology*. 2014;**30**(9):1064-1072

[42] Khalique OK, Kodali SK, Paradis JM, Nazif TM, Williams MR, Einstein AJ, et al. Aortic annular sizing using a novel 3-dimensional echocardiographic method: Use and comparison with cardiac computed tomography. *Circulation. Cardiovascular Imaging*. 2014;**7**(1):155-163

[43] Clavel MA, Malouf J, Messika-Zeitoun D, Araoz PA, Michelena HI, Enriquez-Sarano M. Aortic valve area calculation in aortic stenosis by CT and Doppler echocardiography. *JACC: Cardiovascular Imaging*. 2015;**8**(3):248-257

[44] Kamperidis V, van Rosendaal PJ, Katsanos S, van der Kley F, Regeer M, Al Amri I, et al. Low gradient severe aortic stenosis with preserved ejection fraction: Reclassification of severity by fusion of Doppler and computed

tomographic data. *European Heart Journal*. 2015;**36**(31):2087-2096

[45] Clavel MA, Webb JG, Rodés-Cabau J, Masson JB, Dumont E, De Larocheillère R, et al. Comparison between transcatheter and surgical prosthetic valve implantation in patients with severe aortic stenosis and reduced left ventricular ejection fraction. *Circulation*. 2010;**122**(19):1928-1936

[46] Ben-Dor I, Maluenda G, Iyasu GD, Laynez-Carnicero A, Hauville C, Torguson R, et al. Comparison of outcome of higher versus lower transvalvular gradients in patients with severe aortic stenosis and low (<40%) left ventricular ejection fraction. *The American Journal of Cardiology*. 2012;**109**(7):1031-1037

[47] Herrmann HC, Pibarot P, Hueter I, Gertz ZM, Stewart WJ, Kapadia S, et al. Predictors of mortality and outcomes of therapy in low-flow severe aortic stenosis: A Placement of Aortic Transcatheter Valves (PARTNER) trial analysis. *Circulation*. 2013;**127**(23):2316-2326

[48] Eleid MF, Sorajja P, Michelena HI, Malouf JF, Scott CG, Pellikka PA. Flow-gradient patterns in severe aortic stenosis with preserved ejection fraction: Clinical characteristics and predictors of survival. *Circulation*. 2013;**128**(16):1781-1789

[49] Dayan V, Vignolo G, Magne J, Clavel MA, Mohty D, Pibarot P. Outcome and impact of aortic valve replacement in patients with preserved LV ejection fraction and low gradient aortic stenosis: A meta-analysis. *Journal of the American College of Cardiology*. 2015;**66**(23):2594-2603

[50] Herrmann S, Störk S, Niemann M, Lange V, Strotmann JM, Frantz S, et al. Low-gradient aortic valve stenosis: Myocardial fibrosis and its influence on function and outcome. *Journal of*

the American College of Cardiology. 2011;**58**(4):402-412

[51] Le Ven F, Freeman M, Webb J, Clavel MA, Wheeler M, Dumont É, et al. Impact of low flow on the outcome of high risk patients undergoing transcatheter aortic valve replacement. *Journal of the American College of Cardiology*. 2013;**62**(9):782-788

[52] Mohty D, Magne J, Deltreuil M, Aboyans V, Echahidi N, Cassat C, et al. Outcome and impact of surgery in paradoxical low-flow, low-gradient severe aortic stenosis and preserved left ventricular ejection fraction: A cardiac catheterization study. *Circulation*. 2013;**128**(11 Suppl 1):S235-S242

[53] Clavel MA, Berthelot-Richer M, Le Ven F, Capoulade R, Dahou A, Dumesnil JG, et al. Impact of classic and paradoxical low flow on survival after aortic valve replacement for severe aortic stenosis. *Journal of the American College of Cardiology*. 2015;**65**(7):645-653

[54] Mohty D, Boulogne C, Magne J, Pibarot P, Echahidi N, Cornu E, et al. Prevalence and long term outcome of aortic prosthesis-patient mismatch in patients with paradoxical low-flow severe aortic stenosis. *Circulation*. 2014;**130**(11 Suppl 1):S25-S31

[55] Cribier A, Savin T, Saoudi N, et al. Percutaneous transluminal aortic valvuloplasty using a balloon catheter. A new therapeutic option in aortic stenosis in the elderly. *Arch Mal Coeur Vaiss*. 1986;**79**:1678-1686

[56] Ben-Dor I, Pichard AD, Satler LF, Goldstein SA, Syed AI, Gaglia MA Jr, et al. Complications and outcome of balloon aortic valvuloplasty in high-risk or inoperable patients. *JACC. Cardiovascular Interventions*. 2010;**3**(11):1150-1156

[57] Saia F, Moretti C, Dall'Ara G, Ciuca C, Taglieri N, Berardini A, et al. Balloon aortic valvuloplasty as a bridge-to-decision in high risk patients with aortic stenosis: A new paradigm for the heart team decision making. *Journal of Geriatric Cardiology*. 2016;**13**(6):475-482

[58] Berland J, Cribier A, Savin T, Lefebvre E, Koning R, Letac B. Percutaneous balloon valvuloplasty in patients with severe aortic stenosis and low ejection fraction. Immediate results and 1-year follow-up. *Circulation*. 1989;**79**(6):1189-1196

[59] Maluenda G, Ben-Dor I, Laynez-Carnicero A, Barbash IM, Sardi G, Gaglia MA Jr, et al. Changes in mitral regurgitation after balloon aortic valvuloplasty. *The American Journal of Cardiology*. 2011;**108**(12):1777-1782

[60] Ben-Dor I, Goldstein SA, Pichard AD, Satler LF, Maluenda G, Li Y, et al. Clinical profile, prognostic implication, and response to treatment of pulmonary hypertension in patients with severe aortic stenosis. *The American Journal of Cardiology*. 2011;**107**(7):1046-1051