

# We are IntechOpen, the world's leading publisher of Open Access books Built by scientists, for scientists

6,900

Open access books available

185,000

International authors and editors

200M

Downloads

Our authors are among the

154

Countries delivered to

TOP 1%

most cited scientists

12.2%

Contributors from top 500 universities



WEB OF SCIENCE™

Selection of our books indexed in the Book Citation Index  
in Web of Science™ Core Collection (BKCI)

Interested in publishing with us?  
Contact [book.department@intechopen.com](mailto:book.department@intechopen.com)

Numbers displayed above are based on latest data collected.  
For more information visit [www.intechopen.com](http://www.intechopen.com)



# The Proprioception in the Muscles Supplied by the Facial Nerve

*Juan L. Cobo, Antonio Solé-Magdalena, Sonsoles Junquera, Teresa Cobo, José Antonio Vega and Juan Cobo*

## Abstract

Proprioception is a quality of somatosensibility that informs the central nervous system about the static and dynamics of muscles and joints. In muscles, the proprioceptive originates in the specialized sensory-organ-denominated muscle spindles. Nevertheless, facial muscles lack muscle spindles, but the facial proprioception plays key roles in the regulation and coordination of facial musculature and diverse reflexes. At the basis of these functional characteristics are the multiple communications between the facial and the trigeminal nerves, and neuroanatomical studies have demonstrated that facial proprioceptive impulses are conveyed via branches of the trigeminal nerve to the central nervous system. Substituting muscle spindles facial muscles contain other kinds of proprioceptors of variable morphology that display immunoreactivity for some putative mechanoproteins known to participate in proprioception (acid-sensing ion channel 2, transient receptor potential vanilloid 4, and Piezo2).

**Keywords:** facial muscles, facial nerve, trigemino-facial communications, proprioception, innervation, mechanoproteins

## 1. Introduction

The facial and trigeminal nerves are cranial nerves (CN) responsible for the motor and sensory innervation of the cranioccephalic muscles and skin of the face, respectively. All the classic texts of Human Anatomy describe with detail the origin, branching patterns and anatomical variants of both trigeminal (CNV) and facial (CNVII) nerves, and it can be think that little new can be say of these nerves. Nevertheless, nothing so far from the reality since complexes communications exists between them. In fact, almost all the terminal branches of CNVII receive numerous communications from branches of CNV whose fibers accompany those of CNVII until muscles form sensorimotor units. Therefore, CNVII, at least at the terminal level, is mixed and no purely motor. Although studies in humans do not exist, the data collected from animal models indicate that the nerve fiber interchange is always from CNV to CNVII and not on the contrary [1].

The skeletal muscles contain an intrinsic mechanosensory system, the proprioceptive system, which provides information to the central nervous system about static and dynamic conditions of joints and muscles [2, 3]. The proprioceptive inputs originate in specialized sensory organs (proprioceptors) present in muscles (muscle spindles [4, 5]), tendons (Golgi's tendon organs [6]), and joint capsules

(Ruffini-like sensory corpuscles, Pacinian corpuscles, and free nerve endings [7]). Furthermore, it has been proposed that some kinds of cutaneous mechanoreceptors can also work as proprioceptors, but their physiological properties suggest they are not the alternative to muscle spindles [8–11].

Proprioception is a part of mechanosensation that involves all skeletal muscles, including the cranioccephalic ones. But while muscles innervated by CNV contain typical proprioceptors [12, 13], i.e., muscle spindles, in those innervated by CNVII, they are absent (see [14]). However, facial proprioception, emanated from the facial muscles, plays key roles in facial expression and coordination of facial movement, regulation of the masticatory force in conjunction with jaw muscles, oromotor behaviors, and nonverbal facial communication, as well as in orofacial reflexes related to speech, swallowing, coughing, vomiting, or breathing [14]. Moreover, proprioceptive acuity of the orofacial muscles has been found to be more accurate than the jaw [15].

Some decades ago, Baumel [16] suggested that proprioceptive impulses from facial muscles are conveyed to the central nervous system via different branches of CNV throughout multiple communications with the branches of CNVII, and actually it is accepted that the proprioception of the cranioccephalic muscles depends on CNV [14, 17].

All together, the above data suggest complex anatomical and functional intercommunication between CNV and CNVII which are of capital importance to understand the clinic of these nerves.

Here we have reviewed the literature of the connections between CNV and CNVII as well as the actual knowledge about facial proprioception. Moreover we added our experience in those fields with results from anatomical dissections and analyzed the proprioceptors present in facial muscles.

## **2. An overview of CNV and CNVII**

CNV and CNVII are both mixed cranial nerves that carry motor and sensory fibers responsible for both the sensory and motor innervation of the face, respectively. Moreover, CNVII and some branches of CNV contain preganglionic and postganglionic parasympathetic nerve fibers [18, 19].

### **2.1 Trigeminal nerve: CNV**

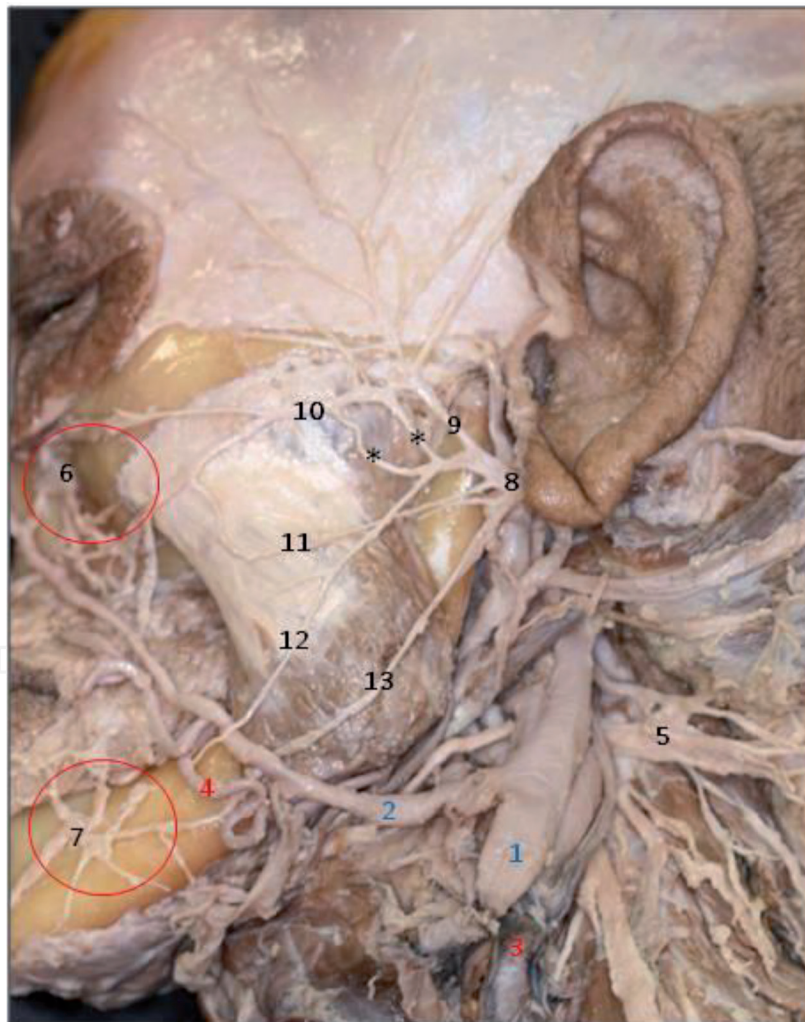
CNV is responsible for the sensory innervation of the face, both skin and mucosae, and the motor innervation of the cranioccephalic muscles originated from the first pharyngeal arch. It apparently originates by two roots at the midlateral surface of pons that reach the Gasser's ganglion where it divides into three branches denominated ophthalmic (sensory CNV1), maxillary (sensory CNV2), and mandibular (mixed CNV3). The soma of the trigeminal somatosensory neurons is localized in the trigeminal ganglion (Gasser's ganglion), whereas the proprioceptive ones, i.e., those innervating craniofacial muscles, are localized in the nucleus mesencephalicus nervi trigemini [18, 19].

### **2.2 Facial nerve—CNVII**

CNVII is responsible for the innervation and control of the movements of all the craniofacial muscles, with exceptions of jaw muscles. Moreover, it innervates some muscles in the neck and middle ear. The sensory territory of CNVII includes the anterior two-thirds of the tongue, a part of the outer ear skin, and the so-called Ramsey-Hunt's zone. CNVII originates at the pontocerebellar angle by two roots: the largest root motor

and the smaller root sensitive (the so-called intermediate Wrisberg's nerve; *N. intermedius*). Both roots enter the temporal bone, continue through the facial canal and fuse, and finally emerge at the foramen stylomastoideum. Within the parotid gland, CNVII bifurcates into two primary trunks: larger temporo-facial and a smaller cervicofacial trunk. The two primary trunks form the parotid plexus and thus form connections along six distinctive anastomotic types in 44% of the cases [20]. Thereafter, from the parotid plexus originates five major branches (with wide variations): temporal (*r. temporales*), the zygomatic (*r. zygomatici*), the buccal (*r. buccales*), mandibular (*R. marginalis mandibularis*), and the cervical (*r. cervicales*) [18, 19, 21–23].

Nevertheless, the peripheral branching and intercommunication of the facial branches were highly variable [24]. In our experience on 10 hemi heads we observed a different pattern of facial nerve branching between subjects and between right and left sides from the same subject. According to the Davis et al. classification [25] of the facial nerve based on the patterns of facial nerve branching, we observed that type II (6/10) predominates, followed by type IV (3/10) and type V (1/10). But independently of the type communicating branches between the different the main terminal branches of CNVII were found (**Figure 1**; [26]).



**Figure 1.** Cadaveric dissection of the left facial nerve in the hemi-head of a male, 66 years old. The facial nerve branched within the parotid gland (removed) into five branches largely connected between them at the initial segments. 1, external jugular vein; 2, facial vein; 3, external carotid artery; 4, facial artery; 5, CN XI; 6, infraorbital branch of CNV2; 7, mental nerve CNV3; 8, CN VII; 9, temporal branches of CNVII; 10, zygomatic branch of CNVII; 11, buccal branches of CNVII; 12, mandibular branches of CNVII; 13, cervical branches of CNVII; \*, connections between primary facial trunks. This image was obtained from our own dissections and was carried out at the area of anatomy and human embryology, Department of Morphology and Cell Biology, University of Oviedo, Spain. Similar image from the same dissection was published previously by Cobo et al. [42].



In addition to the main primary branches mentioned above, in some cases an aberrant branch arose from the main trunk before bifurcation and numerous anatomical variants. Moreover connections between the facial nerve branches have been described [27, 28].

The somatosensory and gustative peripheral neurons of CNVII are localized in the ganglion geniculatum, and their central branch terminates in the nucleus tractus solitarius of the brainstem. The motor axons originate from neurons located in nucleus nervi facialis. CNVII innervates the derivatives of the second branchial arch of the embryos, including facial muscles.

### **3. Communications between CNV and CNVII**

CNVII exhibits a highly variable and complicated branching pattern and forms communications with several other cranial nerves, especially with branches of all three divisions of CNV [20, 29–42].

The revision about trigemino-facial communications carried out by Hwang et al. [33] shows in cadaveric studies the highest frequency of communication of CNVII is with CNV2 ( $95.0\% \pm 8.0\%$ ), followed by CNV3 ( $76.7\% \pm 38.5\%$ ) and CNV1 ( $33.8\% \pm 19.5\%$ ). However using nerve impregnation methods, the communications reach 100% for CNV2 and CNV3 and 85.7% for CNV1 [39]. Interestingly, communication between the infraorbital nerve and the different branches of CNVII is regularly found just below the infraorbital foramen, forming the infraorbital plexus [30, 36, 42]. Another regular connection is between the mental nerve of CNV3 and the mandibular branch of the facial nerve [42]. On the other hand, CNVII can receive proprioceptive information from the cervical nerves which are frequently communicated ( $65.2 \pm 43.5\%$ ; [33]), as well as with the auriculotemporal nerve [34, 43].

Interestingly, although independent of CNV, the connection between the great auricular nerve (composed of branches of spinal nerves C2 and C3) and CNVII trunk has been regularly observed (100%) [44], which probably serves the platysma colli. Functionally, these communications consistently innervated some of the muscles of upper facial expression and presumably are also responsible of their proprioception. Anastomoses in the neck between the sensory transverse cervical nerve (C2 and C3) and the cervical branch of the facial nerve are common, but communications with more superior branches of the facial nerve are rare [45].

### **4. Sensory innervation of the facial muscles**

All the craniofacial muscles except the jaw ones are innervated by CNVII. To understand the proprioceptive innervation of the facial muscles, it is necessary to know as they are innervated by CNVII branches and as terminal segments of the facial nerves contain sensory fibers coming from CNV that provide these muscles with proprioceptive fibers, although individual differences may exist. The innervation of the facial muscles is summarized in **Figure 2** [46].

The facial muscles are devoid of proprioceptors, and therefore facial movements lack a conventional proprioceptive feedback system, which may be only in part vicariate by cutaneous afferents [10, 47]. Therefore, a putative facial proprioceptive system, if present, must be represented by other structures not identified yet.

#### **4.1 Proprioceptors in facial muscles**

In the middle of the last century, Kadanoff [48] investigated the innervation of the human facial muscles using silver impregnation techniques and observed

Trigeminal nerve branches	Facial nerve branches	Muscles
auriculotemporal great auricular	<b>Facial trunks:</b> temporo--facial Cervico-facial	
zygomatictemporal supraorbital auriculotemporal	<b>Temporal branch</b>	frontalis procerus depressor supercilii corrugator supercilii orbicularis oculi
supraorbital supratrochlear buccinators buccal zygomaticofacial auriculotemporal	<b>Zygomatic branch</b>	orbicularis oculi zygomaticus major zygomaticus minor levator labii superioris aequi nasi levator anguli oris
infraorbital infraorbital buccal mental buccinator zygomaticofacial auriculotemporal	<b>Buccal branch</b>	orbicularis oculi zygomaticus major zygomaticus minor levator labii superioris aequi nasi levator anguli oris buccinators risorius
buccinator mental	<b>Mandibular branch</b>	orbicularis oris depressor anguli oris depressor labii inferioris mentalis
	<b>Cervical branch</b>	platysma

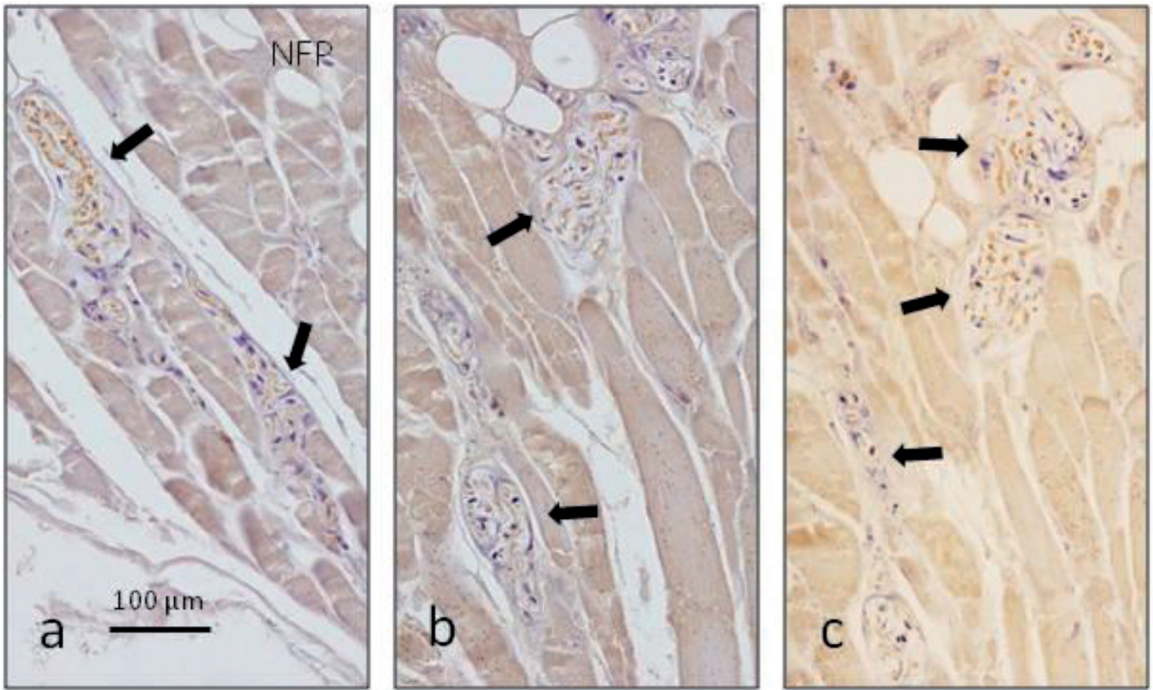
**Figure 2.**  
*Schematic presentation of the communications between CNV branches and the main divisions of CNVII to provide sensory innervation to the facial muscles. Data are based on the literature cited in the manuscript.*

numerous and varied morphotypes of sensory nerve endings in the facial muscles, especially in the perioral ones. Nevertheless, as far as we know, no typical muscle spindles have been found in the human facial muscles [49–53]. More recently, Cobo et al. [54] have not found any morphological or immunohistochemical evidence for the presence of muscle spindles in two facial muscles, while they were regularly present in the masseter muscle. Conversely, one muscle spindle was found in the muscle orbicularis oculi in one pediatric specimen [55], and abundant muscle spindles have been found in the platysma colli [56].

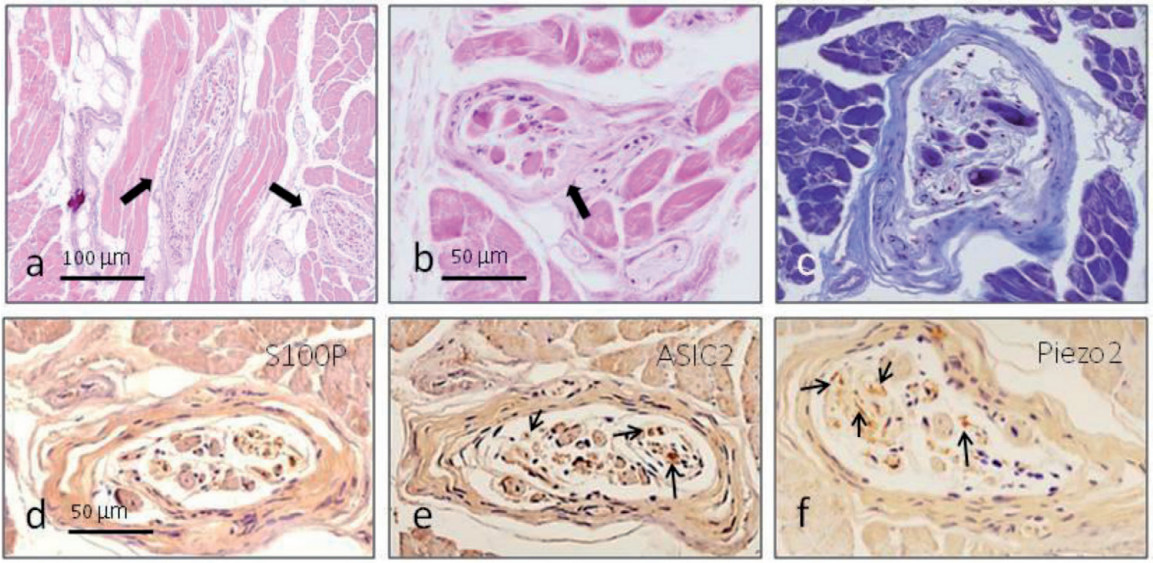
Recently we have conducted a research focused to identify proprioceptors, other than muscle spindles, in human facial muscles [26, 54]. The identification of putative sensory receptors in the facial muscles was based on the following criteria: independence of the nerve trajectory, be placed in close relation to muscle fibers, display a morphologically differentiated aspect, and display immunoreactivity for any putative mechanoprotein (**Figure 3**).

In no case were typical muscle spindles found, whereas in the masseter muscle (used as a control) typical muscle spindles were found (**Figure 4**). In agreement with the above premises, we identified capsulated and non-capsulated corpuscle-like structures of variable size and shape containing numerous axon profiles complexly arranged, which resembled elongated or round Ruffini-like corpuscles (**Figure 5**).





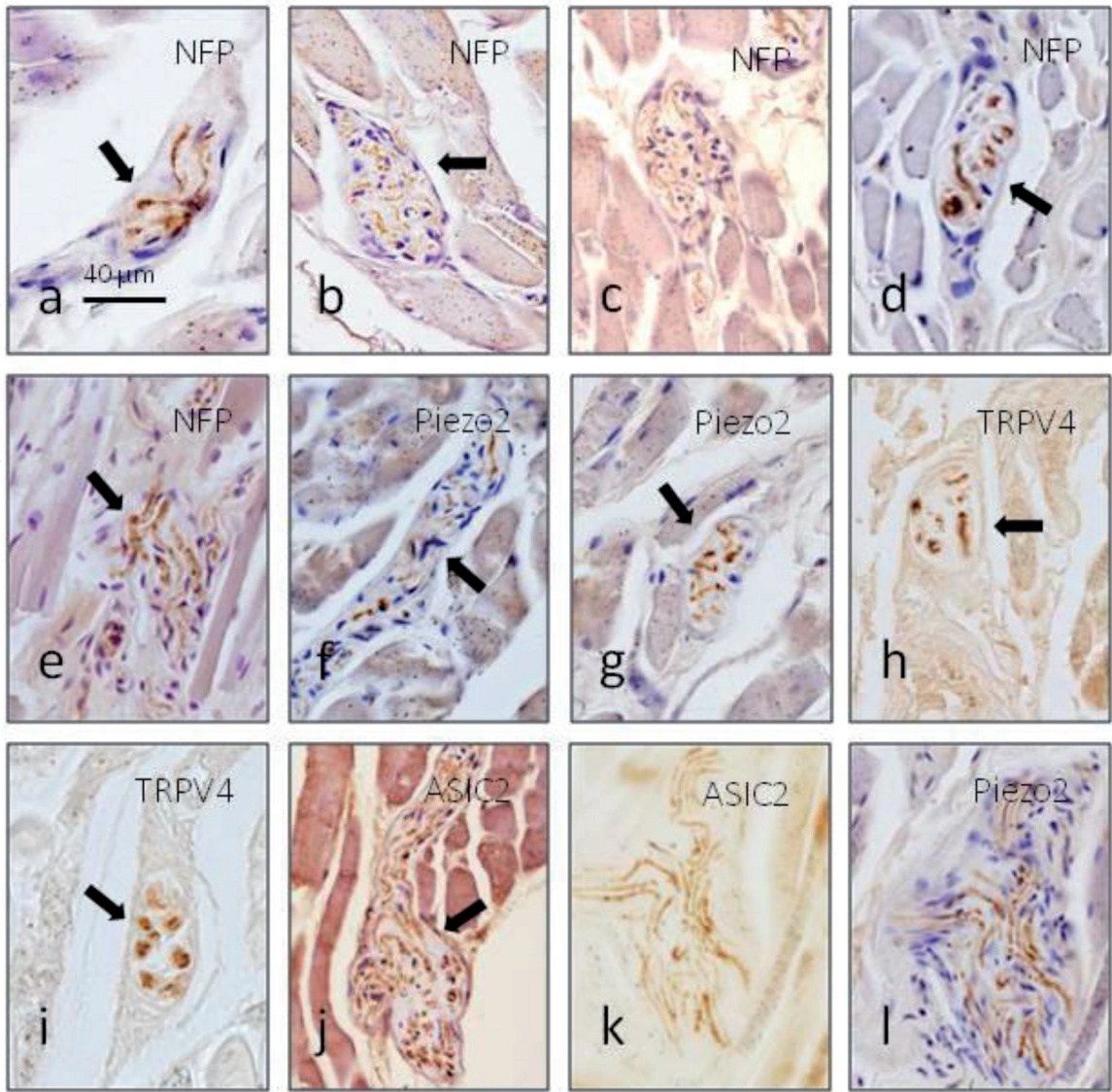
**Figure 3.** Sensory nerve formations in the facial muscles (arrows) displaying immunoreactivity for the axonal marker neurofilament protein (NFP). a, buccal muscle; b, zygomaticus major muscle; c, orbicularis oris muscle.



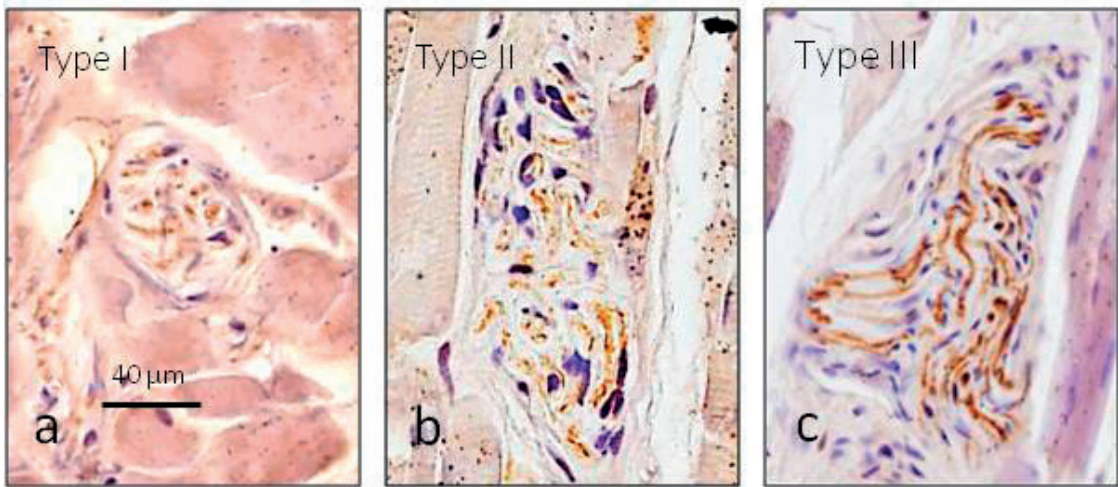
**Figure 4.** Longitudinal (a) and cross (b,c) sections of two typical muscle spindles in the human masseter muscle (arrows) containing a variable number of intrafusal muscle fibers. Nerve fibers supplying them display immunoreactivity for Schwann cells markers like S100 protein (d) and the putative mechanoproteins ASIC2 (e, arrows) and Piezo2 (f, arrows).

Given the morphologic heterogeneity of the corpuscle-like structures that fulfill the preestablished criteria we attempt to classify them into three types: type I, encapsulated by a thin capsule and the glial cells variably arranged and showing different morphologies (**Figure 6a**); type II, partially capsulated (the capsule being continuous with the perimysium), with variable morphology, and in most of the cases the direction of the long axis was parallel to the one of muscular fibers (**Figure 6b**); and type III, non-capsulated and both the axon and Schwann-like cells are variably arranged (**Figure 6c**).





**Figure 5.**  
*Different morphotypes of corpuscle-like structures (arrows) identified immunohistochemically using axonal markers (a–e) and putative mechanoproteins (f–l). In serial sections (k and l), apparent co-localization of two mechanoproteins in the axon is observed.*



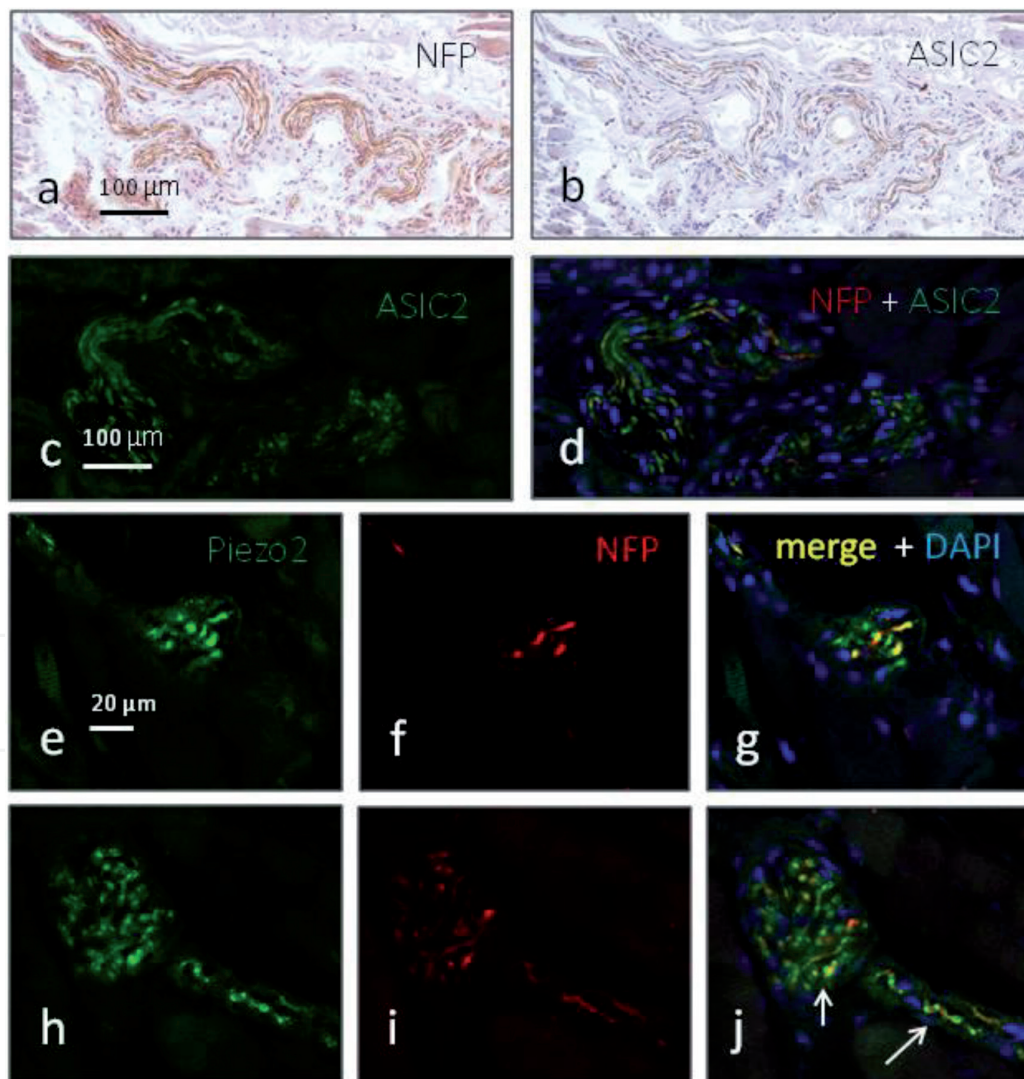
**Figure 6.**  
*Types of sensory structures identified in the facial muscles as observed using immunohistochemistry for neurofilament proteins.*



Muscle	Type I	Type II	Type III	Fibers*
M. corrugator supercilii + M. depressor supercilii	1	3	7	Yes
<i>M. orbicularis oculi</i> pars palpebralis pars orbitalis	3	11	9	Yes
M. orbicularis oris pars marginalis pars labialis	5	19	12	Yes
M. zygomaticus major	1	4	4	Yes
M. zygomaticus minor	1	2	0	Yes
M. buccinator	19	28	10	Yes
M. depressor labii inferioris + mentalis	0	8	2	

\*Isolated nerve fibers displaying immunoreactivity for any of the mechanoproteins investigated.

**Table 1.**  
*Relative density of proprioceptors in human facial muscles. Counts were made on 10 sections separated de 200  $\mu\text{m}$  between them.*



**Figure 7.** Serial sections processed for the detection of neurofilament protein (NFP) and ASIC2 showing that a subpopulation of the axons in nerves supplying the facial nerves contains mechanoproteins (a,b). Nerves and capsulated corpuscle-like structures (types I and II) immunostained with anti-ASIC2 (c) or anti-Piez2 (e,h) antibodies conjugated with Alexa fluor 488 (green fluorescence) and with anti-NFP antibody conjugated with CyTM3 (red fluorescence). The localization of the putative mechanoproteins ASIC2 and Piez2 in the large axons was evident while it was not so clear in the thick axons.

On the other hand, the relative density of proprioceptors in the facial muscles varied from one to another (**Table 1**), the greater density being observed in the buccinator and orbicularis oris muscles, and the type II of proprioceptors being the predominating morphotype.

All sensory modalities involve different ion channels, and at the basis of mechanosensibility are mechanically gated membrane ion channels [5, 57]. At present acid-sensing ion channel 2 (ASIC2), transient receptor potential vanilloid 4 (TRPV4), and Piezo2 have been detected in muscle spindles and are strong candidates to initiate the mechanotransduction in proprioceptors [57–61]. In the studies, we have carried out [54] regularly found is immunoreactivity for ASIC2, TRPV4, and Piezo2 in the axon of types I, II, and III facial sensory corpuscles, thus confirming that these structures may serve as proprioceptors (**Figure 5f-l**). In serial sections (**Figure 7a and b**) with our use of double immunofluorescence and laser confocal microscopy (**Figure 7c-j**), it was observed that a subpopulation of nerve fibers displays immunoreactivity for the putative mechanoproteins and that these proteins are localized in the axon of the sensory structures within the facial muscles, thus confirming their proprioceptive function.

## 5. Concluding remarks

The facial muscles are richly innervated by sensory fibers that form at the periphery of different types of sensory structures of variable complexity which express putative mechanoproteins and therefore can be regarded as proprioceptors. Conversely facial muscles lack typical muscles spindles. Presumably, the sensory fibers forming the facial muscle proprioceptors originate in CNV. Because of the high variability in the pattern of branching and distribution of CNVII as well as of their communications with other CNs especially CNV, a correct knowledge of the anatomy of those nerves to preserve it when performing surgical or medical procedures in the face is necessary since a disruption of these connections might alter facial muscle proprioception. These communications have clinical significance for recovery of damaged facial expression muscles, treatment of hemifacial spasm, and surgical procedures for facial reconstruction and neck dissection.

IntechOpen

IntechOpen

### **Author details**

Juan L. Cobo<sup>1,2</sup>, Antonio Solé-Magdalena<sup>1,3</sup>, Sonsoles Junquera<sup>4</sup>, Teresa Cobo<sup>5,6</sup>, José Antonio Vega<sup>1,7\*</sup> and Juan Cobo<sup>5,6</sup>

1 Departamento de Morfología y Biología Celular, Grupo SINPOS, Universidad de Oviedo, Spain

2 Servicio de Cirugía Máxilo-Facial, Hospital Universitario Central de Asturias, Oviedo, Spain

3 Servicio de Hematología, Hospital Universitario Central de Asturias, Oviedo, Spain

4 Servicio de Radiología, Hospital Universitario, Santiago de Compostela, Spain

5 Departamento de Cirugía y Especialidades Médico-Quirúrgicas, Universiada de Oviedo, Spain

6 Instituto Asturiano de Odontología, Oviedo, Spain

7 Facultad de Ciencias de la Salud, Universid Autónoma de Chile, Temunco, Chile

\*Address all correspondence to: javega@uniovi.es

### **IntechOpen**

© 2019 The Author(s). Licensee IntechOpen. This chapter is distributed under the terms of the Creative Commons Attribution License (<http://creativecommons.org/licenses/by/3.0>), which permits unrestricted use, distribution, and reproduction in any medium, provided the original work is properly cited. 



## References

- [1] Bowden RE, Mahran ZY. Experimental and histological studies of the extrapetrous portion of the facial nerve and its communications with the trigeminal nerve in the rabbit. *Journal of Anatomy*. 1960;**94**:375-386
- [2] Dijkerman HC, de Haan EH. Somatosensory processes subserving perception and action. *The Behavioral and Brain Sciences*. 2007;**30**:189-201
- [3] Butler AA, Héroux ME, Gandevia SC. Body ownership and a new proprioceptive role for muscle spindles. *Acta Physiologica (Oxford, England)*. 2016;**220**:19-27
- [4] Banks RW. The innervation of the muscle spindle: A personal history. *Journal of Anatomy*. 2015;**227**:115-135
- [5] Bewick GS, Banks RW. Mechanotransduction in the muscle spindle. *Pflügers Archiv*. 2015;**467**:175-190
- [6] Ackermann PW, Salo P, Hart DA. Tendon innervation. *Advances in Experimental Medicine and Biology*. 2016;**920**:35-51
- [7] Heppelmann B. Anatomy and histology of joint innervation. *Journal of the Peripheral Nervous System*. 1997;**2**:5-16
- [8] Collins DF, Refshauge KM, Todd G, Gandevia SC. Cutaneous receptors contribute to kinesthesia at the index finger, elbow, and knee. *Journal of Neurophysiology*. 2005;**94**:1699-1706
- [9] Macefield VG. Physiological characteristics of low-threshold mechanoreceptors in joints, muscle and skin in human subjects. *Clinical and Experimental Pharmacology & Physiology*. 2005;**32**:135-144
- [10] Andreatta RD, Barlow SM. Somatosensory gating is dependent on the rate of force recruitment in the human orofacial system. *Journal of Speech, Language, and Hearing Research*. 2009;**52**:1566-1578
- [11] Proske U, Gandevia SC. The proprioceptive senses: Their roles in signaling body shape, body position and movement, and muscle force. *Physiological Reviews*. 2012;**92**:1651-1697
- [12] Osterlund C, Liu JX, Thornell LE, Eriksson PO. Muscle spindle composition and distribution in human young masseter and biceps brachii muscles reveal early growth and maturation. *Anatomical Records (Hoboken)*. 2011;**294**:683-693
- [13] Saverino D, De Santanna A, Simone R, Cervioni S, Cattrysse E, Testa M. Observational study on the occurrence of muscle spindles in human digastric and mylohyoideus muscles. *BioMed Research International*. 2014;**2014**:294263
- [14] Cattaneo L, Pavesi G. The facial motor system. *Neuroscience and Biobehavioral Reviews*. 2014;**38**:135-159
- [15] Frayne E, Coulson S, Adams R, Croxson G, Waddington G. Proprioceptive ability at the lips and jaw measured using the same psychophysical discrimination task. *Experimental Brain Research*. 2016;**234**:1679-1687
- [16] Baumel J. Trigeminal-facial nerve communications. *Archives of Otolaryngology*. 1974;**99**:34-44
- [17] Lazarov NE. Neurobiology of orofacial proprioception. *Brain Research Reviews*. 2007;**56**:362-383

- [18] Monhouase S. Cranial Nerves. Functional Anatomy. Cambridge: Cambridge University Press; 2005
- [19] Wilson-Pawels L, Stewart T, Akesson EJ, Spacey SD. Cranial Nerves. Third Edition. Function and Dysfunction. 3er ed. People's Medical Publishing House of China; 2010
- [20] Bendella H, Spacca B, Rink S, Stoffels HJ, Nakamura M, Scaal M, et al. Anastomotic patterns of the facial parotid plexus (PP): A human cadaver study. *Annals of Anatomy*. 2017;**213**:52-61
- [21] Monkhouse WS. The anatomy of the facial nerve. *Ear, Nose, & Throat Journal*. 1990;**69**:677-683, 686-7
- [22] Moore KL, Dalley AF. Clinically Oriented Anatomy. 4th ed. Baltimore: Lippincott Williams & Wilkins; 1999. pp. 859-861
- [23] Vacher C, Cyna-Gorse F. Motor nerves of the face. Surgical and radiologic anatomy of facial paralysis and their surgical repair. *Annales de Chirurgie Plastique et Esthétique*. 2015;**60**:363-369
- [24] De Bonnez G, Vergez S, Chaput B, Vairel B, Serrano E, Chantalat E, et al. Variability in facial-muscle innervation: A comparative study based on electrostimulation and anatomical dissection. *Clinical Anatomy*. 2018. DOI: 10.1002/ca.23081
- [25] Davis RA, Anson BJ, Budinger JM, Kurth IE. 1956 surgical anatomy of the facial nerve and parotid gland based upon a study of 350 cervicofacial halves. *Surgery, Gynecology & Obstetrics*. 1956;**102**:385-412
- [26] Cobo JL. Neuroanatomía de la cara. Anatomía topográfica, quirúrgica, radiológica y microscópica de la inervación de la cara. Oviedo: Universidad de Oviedo; 2016
- [27] Ekinici N. A study on the branching pattern of the facial nerve of children. *Kaibogaku Zasshi*. 1999;**74**:447-450
- [28] Gataa IS, Faris BJ. Patterns and surgical significance of facial nerve branching within the parotid gland in 43 cases. *Oral and Maxillofacial Surgery*. 2016;**20**:161-165
- [29] Shimada K, Moriyama H, Ikeda M, Tomita H, Shigihara S, Gasser RF. Peripheral communication of the facial nerve at the angle of the mouth. *European Archives of Oto-Rhino-Laryngology*. 1994:110-112
- [30] Hwang K, Han JY, Battuvshin D, Kim DJ, Chung IH. Communication of infraorbital nerve and facial nerve: Anatomic and histologic study. *The Journal of Craniofacial Surgery*. 2004;**15**:88-91
- [31] Hwang K, Hwang JH, Cho HJ, Kim DJ, Chung IH. Horizontal branch of the supraorbital nerve and temporal branch of the facial nerve. *The Journal of Craniofacial Surgery*. 2005;**16**:647-649
- [32] Hwang K, Jin S, Park JH, Kim DJ, Chung IH. Relation of mental nerve with mandibular branch of the facial nerve. *The Journal of Craniofacial Surgery*. 2007;**18**:165-168
- [33] Hwang K, Yang SC, Song JS. Communications between the trigeminal nerve and the facial nerve in the face: A systematic review. *The Journal of Craniofacial Surgery*. 2015;**26**:1643-1646
- [34] Kwak HH, Park HD, Youn KH, Hu KS, Koh KS, Han SH, et al. Branching patterns of the facial nerve and its communication with the auriculotemporal nerve. *Surgical and Radiologic Anatomy*. 2004;**(6)**:494-500
- [35] Tohma A, Mine K, Tamatsu Y, Shimada K. Communication between the buccal nerve (V) and facial nerve

(VII) in the human face. *Annals of Anatomy*. 2004;**186**:173-178

[36] Hu KS, Kwak J, Koh KS, Abe S, Fontaine C, Kim HJ. Topographic distribution area of the infraorbital nerve. *Surgical and Radiologic Anatomy*. 2007;**29**:383-388

[37] Diamond M, Wartmann CT, Tubbs RS, Shoja MM, Cohen-Gadol AA, Loukas M. Peripheral facial nerve communications and their clinical implications. *Clinical Anatomy*. 2011;**24**:10-18

[38] Odobescu A, Williams HB, Gilardino MS. Description of a communication between the facial and zygomaticotemporal nerves. *Journal of Plastic, Reconstructive & Aesthetic Surgery*. 2012;**65**:1188-1192

[39] Yang HM, Won SY, Kim HJ, Hu KS. Sihler staining study of anastomosis between the facial and trigeminal nerves in the ocular area and its clinical implications. *Muscle & Nerve*. 2013;**48**:545-550

[40] Shoja MM, Oyesiku NM, Griessenauer CJ, Radcliff V, Loukas M, Chern JJ, et al. Anastomoses between lower cranial and upper cervical nerves: A comprehensive review with potential significance during skull base and neck operations, part I: Trigeminal, facial, and vestibulocochlear nerves. *Clinical Anatomy*. 2014;**27**:118-130

[41] Tansatit T, Phanchart P, Chinnawong D, Apinuntrum P, Phetudom T, Sahraoui YM. A cadaveric study of the communication patterns between the Buccal trunks of the facial nerve and the Infraorbital nerve in the Midface. *The Journal of Craniofacial Surgery*. 2016;**27**:214-218

[42] Cobo JL, Solé-Magdalena A, Menendez I, De Vicente JC, Vega JA. Connections between the facial and trigeminal nerves: Anatomical basis for

facial muscle proprioception. *JPRAS Open*. 2017;**12**:9-18

[43] Namking M, Boonruangsri P, Woraputtaporn W, G€uldner FH. Communication between the facial and auriculotemporal nerves. *Journal of Anatomy*. 1994;**185**:421-426

[44] Yang HM, Kim HJ, Hu KS. Anatomic and histological study of great auricular nerve and its clinical implication. *Journal of Plastic, Reconstructive & Aesthetic Surgery*. 2015;**68**:230-236

[45] Brennan PA, Elhamshary AS, Alam P, Anand R, Ammar M. Anastomosis between the transverse cervical nerve and marginal mandibular nerve: How often does it occur? *The British Journal of Oral & Maxillofacial Surgery*. 2017;**55**:293-295

[46] Marur T, Tuna Y, Demirci S. Facial anatomy. *Clinics in Dermatology*. 2014;**32**:14-23

[47] Connor NP, Abbs JH. Orofacial proprioception: Analyses of cutaneous mechanoreceptor population properties using artificial neural networks. *Journal of Communication Disorders*. 1998;**31**:535-542; 553

[48] Kadanoff D. Die sensiblen Nervendigungen in der mimischen Muskulatur des Menschen. *Zeitschrift für Mikroskopisch-Anatomische Forschung*. 1956;**62**:1-15

[49] Stål P, Eriksson PO, Eriksson A, Thornell LE. Enzyme-histochemical differences in fibre-type between the human major and minor zygomatic and the first dorsal interosseus muscles. *Archives of Oral Biology*. 1987;**32**:833-841

[50] Stål P, Eriksson PO, Eriksson A, Thornell LE. Enzyme-histochemical and morphological characteristics of muscle fibre types in the human buccinator and orbicularis oris. *Archives of Oral Biology*. 1990;**35**:449-458



- [51] Kamen G, De Luca CJ. Firing rate interactions among human orbicularis oris motor units. *The International Journal of Neuroscience*. 1992;**64**:167-175
- [52] Happak W, Burggasser G, Liu J, Gruber H, Freilinger G. Anatomy and histology of the mimic muscles and the supplying facial nerve. *European Archives of Oto-Rhino-Laryngology*. 1994;**1994**:S85-S86
- [53] Goodmurphy CW, Ovalle WK. Morphological study of two human facial muscles: Orbicularis oculi and corrugator supercilii. *Clin Ant*. 1999;**12**:1-11
- [54] Cobo JL, Abbate F, de Vicente JC, Cobo J, Vega JA. Searching for proprioceptors in human facial muscles. *Neuroscience Letters*. 2017;**640**:1-5
- [55] Nelson CC, Blaivas M. Orbicularis oculi muscle in children. Histologic and histochemical characteristics. *Investigative Ophthalmology & Visual Science*. 1991;**32**:646-654
- [56] May A, Bramke S, Funk RHW, May CA. The human platysma contains numerous muscle spindles. *Journal of Anatomy*. 2018;**232**:146-151
- [57] Kröger S. Proprioception 2.0: Novel functions for muscle spindles. *Current Opinion in Neurology*. 2018;**31**:592-598
- [58] Simon A, Shenton F, Hunter I, Banks RW, Bewick GS. Amiloride-sensitive channels are a major contributor to mechanotransduction in mammalian muscle spindles. *The Journal of Physiology*. 2010;**588**:171-185
- [59] Chen CC, Wong CW. Neurosensory mechanotransduction through acid-sensing ion channels. *Journal of Cellular and Molecular Medicine*. 2013;**17**:337-349
- [60] Gautam M, Benson CJ. Acid-sensing ion channels (ASICs) in mouse skeletal muscle afferents are heteromers composed of ASIC1a, ASIC2, and ASIC3 subunits. *The FASEB Journal*. 2013;**27**:793-802
- [61] Woo SH, Lukacs V, de Nooij JC, Zaytseva D, Criddle CR, Francisco A, et al. Patapoutian. Piezo2 is the principal mechanotransduction channel for proprioception. *Nature Neuroscience*. 2015;**18**:1756-1762