

# We are IntechOpen, the world's leading publisher of Open Access books Built by scientists, for scientists

6,900

Open access books available

185,000

International authors and editors

200M

Downloads

Our authors are among the

154

Countries delivered to

TOP 1%

most cited scientists

12.2%

Contributors from top 500 universities



WEB OF SCIENCE™

Selection of our books indexed in the Book Citation Index  
in Web of Science™ Core Collection (BKCI)

Interested in publishing with us?  
Contact [book.department@intechopen.com](mailto:book.department@intechopen.com)

Numbers displayed above are based on latest data collected.  
For more information visit [www.intechopen.com](http://www.intechopen.com)



# Leadless Pacemakers

*Peter Magnusson, Joseph V. Pergolizzi Jr and Jo Ann LeQuang*

## Abstract

Leadless or transcatheter pacemakers have recently been introduced to market with important benefits and some limitations. Implanted entirely within the right ventricle, these devices eliminate the need for transvenous pacing leads and pacemaker pockets and thus reduce the risk of infections and lead-related problems. Currently, they offer only VVI/R pacing and they cannot provide atrial sensing, antitachycardia pacing, or AV synchrony. They offer a number of features (such as rate response) and electrogram storage, albeit more limited than in a transvenous system. Real-world clinical data are needed to better comment on projected battery life, which manufacturers suggest will be at least equivalent to transvenous devices. Extracting an implanted leadless pacemaker remains a challenge, although proprietary snare and removal systems are available. However, a leadless pacemaker at end of service may be programmed to OOO and left in place; a revised device may be implanted adjacent. These innovative new devices may have important uses in special populations. Initial data on implant success and adverse events are favorable. Currently, there are two leadless pacemakers available: the Micra™ device by Medtronic and the Nanostim™ device by Abbott (formerly St. Jude Medical).

**Keywords:** LEADLESS clinical study, leadless pacemaker, Micra™ pacemaker, Nanostim™ pacemaker, transcatheter pacemaker

## 1. Introduction

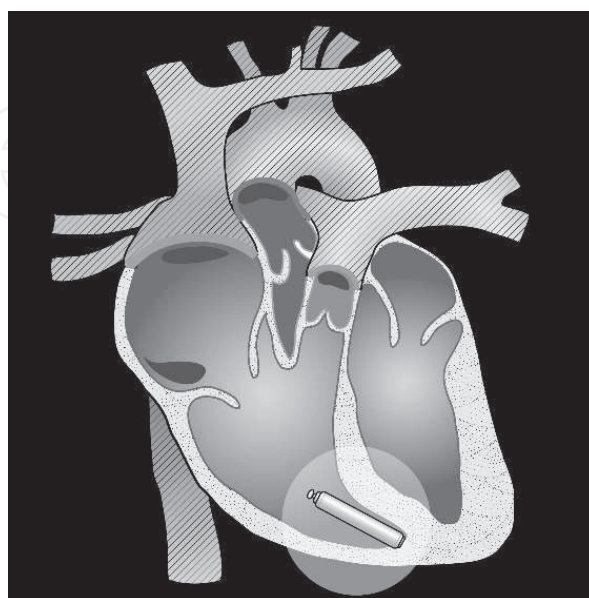
The most vulnerable portion of the implantable cardiac pacemaker system is the transvenous lead(s), which can dislodge, fracture, experience insulation breach, and may lead to a host of adverse events including perforation, venous occlusion, tricuspid regurgitation, oversensing (with inappropriate device function), and infection. The innovation of a leadless pacemaker offers pacing support through a catheter-delivered device that is situated entirely within the right ventricle. A leadless pacemaker eliminates the need for both a pacemaker pocket and transvenous access. Its main limitations are lack of atrial pacing and sensing capabilities and the inability to provide antitachycardia pacing. For patients who require solely single-chamber ventricular pacing (VVI/R), the leadless pacemaker offers an important new option. Growing experience with these leadless devices shows great promise and expanding applications, even though real-world clinical experience is limited. The Spanish Pacemaker Registry reported about 1.6% leadless pacemakers out of all 12,697 reported devices by 2016 [1]. Despite this slow uptake, leadless pacing systems may be an important “disrupting technology” in cardiac rhythm management.

## 2. Device description

There are currently two commercially available leadless pacemakers, which are designed to reside entirely within the right ventricle, affixed to the ventricular septum either mid-way or near the apex (see **Figure 1**). These devices are manufactured by two of the leading pacemaker companies in the world: Medtronic makes the Micra™ leadless pacemaker and Abbott (formerly St. Jude Medical) the Nanostim™ leadless pacemaker. The devices are cylindrical, attach directly to right ventricular septum, and have pacing and sensing electrodes that adhere to the myocardium with a retrieval loop on the other end of the device to facilitate extraction.

Leadless pacemakers are capable of pacing in the VVI mode with the programmable option of rate response (VVIR). The Medtronic device contains a lithium-silver-vanadium-oxide/carbon monofluoride battery (120 mAh), while the Abbott device utilizes a lithium carbon monofluoride battery with 248 mAh [2]. Both devices weigh about 2 g; the Abbott device (Nanostim™) is longer and thinner (42 mm in length and 5.99 mm diameter), while the Medtronic device (Micra™) is shorter and thicker (25.9 and, 6.7 mm) [2]. The Abbott device is secured via an active-fixation type helix mechanism, while the Medtronic device relies on passive fixation with nitinol tines [3]. Battery longevity in leadless pacemakers is estimated to be about 12–14 years. The Abbott (Nanostim™) leadless pacemaker was the subject of a global alert in late 2016 because of premature battery depletion that could result in loss of output and telemetry. The battery is a proprietary lithium-carbon monofluoride cell. Of 1423 Nanostim™ implantations around the world, 34 batteries failed (about 2%), but without any associated patient injury [4].

Leadless pacemakers at present cannot offer dual-chamber pacing modes or anti-tachycardia pacing; thus, they are only appropriate for patients who require VVI/VVIR or VOO/VOOR pacing. Electrogram storage is possible but there is limited device memory compared to transvenous pacemaker systems [5].



**Figure 1.**

*The leadless pacemaker is implanted via a catheter into the right ventricle and affixed near the apex or midway on the right-ventricular septum where the operator attains acceptable electrical measurements (capture threshold, R-wave amplitude, and pacing impedance). The integral pacing and sensing electrodes in the device eliminate the need for transvenous pacing leads (illustration by Todd Cooper).*

### 3. Implantation techniques

Leadless pacemakers are typically implanted via right or left femoral venous access into the septal wall of the right ventricle, although a right internal jugular vein approach has been described in the literature [6]. Right femoral access is preferred as the femoral iliac system nothing is less sharply angled on this side at the point where it joins the inferior vena cava [7]. The outer delivery sheath needed to deliver the pacemaker may have a diameter of 27 French (9 mm), which can be accommodated at implant by using a step-up sequence of dilators. Ultrasound with or without micropuncture has been recommended to avoid accidental arterial puncture or suboptimal sites of femoral puncture. As delivery sheaths may be large caliber, a poorly positioned puncture may make hemostasis challenging at the point when the sheath is withdrawn [7]. The proprietary delivery catheter is deflectable and advances with the device via the superior or inferior vena cava into the right atrium, over the tricuspid valve, and then into the right ventricle. The delivery catheter releases the device, which is affixed by active- or passive-fixation mechanisms to the endocardium [7]. Fluoroscopy may be used to confirm appropriate position. On radiography, the implanted devices look like a small cylinder (about the size and shape of a triple-A battery) [8]. Appropriate position is confirmed with acceptable electrical measurements generally defined as capture threshold  $\leq 1.0$  V at 0.24–0.4 ms, R-wave  $> 6$  mV, and impedance  $> 500$   $\Omega$ . The introducer sheath is then detached and removed and hemostasis achieved by a closure device, sutures, or manual pressure [7].

Unlike pacing thresholds with transvenous systems, which tend to gradually rise weeks after implant, the capture threshold for a leadless device may be expected to decrease somewhat about 30 min after implant and then stabilize. In two cases reports, threshold values in for a leadless pacemaker (Nanostim™) decreased markedly during the perioperative period. In one case, the pacing threshold was  $> 6.5$  V, the initial R-wave was  $> 12.0$  mV, and impedance was 1830  $\Omega$ . Rather than reposition the system, it was decided to wait for 30 min, at which time the pacing threshold was 2.25 V at 0.4 ms and impedance dropped to 1520  $\Omega$ . The same report described another case in which the pacing threshold was  $> 6.5$  V and impedance was 1330  $\Omega$ , but after allowing 25 min to elapse, the capture threshold decreased to 2.0 V at 0.4 ms and impedance was measured the next day at 800  $\Omega$  [9]. In fact, thresholds continued to improve in both cases the day after implant. It has been speculated that acute injury caused by the extension of the active-fixation helix being screwed into the myocardium might cause an increase in threshold that attenuates rapidly [9]. Thus, it may not always be necessary to reposition the device during implant in order to obtain adequate thresholds; instead, it requires a perioperative waiting period.

As with other implanted devices, operator experience may help reduce adverse events at implant. In an analysis of all patients implanted with a leadless pacemaker (Nanostim™) in the LEADLESS and LEADLESS II clinical trials ( $n = 1439$ ), 6.4% of patients experienced a serious adverse device effect (SADE) in the first 30 days after implant, but SADE rates dropped significantly from 7.4 to 4.5% ( $p = 0.038$ ), once the operator had more than 10 implants. Over time, the need for device repositioning likewise decreased with operator experience, from the first quartile (26.8%) to the fourth quartile (14.8%),  $p < 0.001$  [10]. This suggests that there is a learning curve for leadless pacemaker implantation, not unlike that for other implantable devices, such as cardiac resynchronization therapy systems and subcutaneous implantable cardioverter defibrillators. The most frequently reported adverse events were cardiac perforation (24 events, 1.7% of patients) followed by device dislodgement (20 events, 1.4%) and tamponade (18 events, 1.3%) [10].



The leadless pacemaker is shipped already programmed to VVI pacing. It is sometimes helpful to switch the device to VOO during implant, for example, to better manage a pacemaker-dependent patient or if electromagnetic devices used during implant could potentially interfere with the pacemaker. A conventional transvenous pacemaker can be set to VOO mode perioperatively with simple magnet application, but this is not possible with some leadless pacemakers. Instead, the manufacturer or other expert team should be consulted in the event that the leadless pacemaker must be implanted in VOO mode [11].

Implant success rates are high with leadless devices. In the LEADLESS study (Nanostim™), the pacemaker could be implanted successfully in 95.8% of patients with a procedural time of  $28.6 \pm 17.8$  min and fluoroscopy time of  $13.9 \pm 9.1$  min [3]. In a study at a Polish single center, 10 patients were successfully implanted with a leadless pacemaker (Micra™), which was implanted with a mean implant duration of 82 min and mean fluoroscopy time of 3.5 min [12]. In a case series of five leadless pacemaker (Micra™) patients, the average duration of implantation procedure was  $47 \pm 11$  min, which appeared to shorten over the series from a peak of 65 (second case) to 38 min for the last case [13]. In this case series, the mean capture threshold was  $0.53 \pm 0.27$  V at 0.24 ms and mean R-wave was  $13 \pm 5.8$  mV with no cases of acute dislodgement [13]. A study of 92 patients with leadless pacemakers (Micra™) at a Swiss single center found median capture thresholds at implant were 0.38 V at 0.24 ms (range 0.13–2.88 V at 0.24 ms), which remained stable throughout 1 year of follow-up [14]. In a case series of five leadless pacemaker patients (Micra™), all of the devices were successfully implanted [13]. A study of leadless pacing (Micra™) in Japan enrolled 38 patients at four sites and reported an implant success rate of 100% and the rate of freedom from major complications at 1 year was 96%. At 6 months, 98.3% had low, stable capture thresholds [15].

## 4. Safety and efficacy

### 4.1 Micra™ clinical studies

A prospective multicenter uncontrolled study enrolled 725 patients with an indication for single-chamber pacing to be implanted with a leadless pacemaker (Micra™). The primary endpoint was the percentage of patients with low, stable electrical capture thresholds at 6 months, defined as  $\leq 2.0$  V at 0.24 ms that increased  $\leq 1.5$  V from implant. The device could be successfully implanted in 719/725 patients (99.2%), and 96.0% met the primary endpoint at 6 months. At 6 months, the mean capture threshold was 0.54 V at 0.24 ms with an R-wave of 15.3 mV and 627  $\Omega$  impedance. The majority of patients (91%) had a pacing output of  $<1.5$  V at 0.24 ms at 6 months, which implies that battery longevity should exceed 12 years [16]. A total of 28 major complications were reported in 25/725 patients, but no devices dislodged. Those complications included cardiac injuries ( $n = 11$ ), complications at the puncture site in the groin ( $n = 5$ ), thromboembolism ( $n = 2$ ), pacing problems ( $n = 2$ ), and other complications ( $n = 8$ ). In total, three patients required device revision (two had elevated capture thresholds and one had pacemaker syndrome) and devices were deactivated (OOO mode) and abandoned; a transvenous pacing system was implanted. One patient had the device explanted because of transient loss of capture and a new leadless pacemaker was implanted [16].

A worldwide postapproval registry of the Micra™ device reported 99.1% rate of successful implantations in 1817 patients with a one-year major complication rate of 2.7% (95% confidence interval [CI], 2.0–3.7%), 63% lower than the rate of

major complications for transvenous pacemaker patients (hazard ratio 0.37, 95% CI, 0.27–0.52,  $p < 0.001$ ). In this study, there were three instances of device infection, none of which required device extraction [17].

A single-center registry of 66 patients undergoing leadless pacemaker implantation (Micra™) reported that the indications in this population were third-degree atrioventricular block, sinus node dysfunction, or permanent atrial fibrillation with bradycardia (30.3, 21.2, and 45.5%, respectively). Implant success was achieved in 65/66 patients, and electrical measurements were stable over the follow-up period of  $10.4 \pm 6.1$  months. At the last follow-up, the mean capture threshold was  $0.57 \pm 0.32$  V, the mean R-wave was measured at  $10.62 \pm 4.36$  mV, and the mean impedance was  $580 \pm 103 \Omega$ . In this study, one patient experienced a major adverse event (loss of device function) and there were three minor adverse events [18].

A single-arm observational study based on a postapproval registry of Micra™ leadless pacemakers reported a 99.6% success rate in device implants (792/795 patients) at 96 centers in 20 countries. At 30 days after implantation, 13 major complications were reported in 12 patients (1.51% complication rate, 95% CI, 0.78–2.62%) [19]. In a Swiss retrospective observational study of 92 Micra™ patients, the serious adverse event rate was 6.5% ( $n = 6$ ), resulting in extended hospitalization for five patients and one death; three other adverse events occurred over the one-year follow-up (3.3% of patients,  $n = 3$ ), resulting in revision to a conventional transvenous pacemaker in two patients and extraction of the pacemaker in the third because of ventricular tachycardia [14].

Physician acceptance of leadless pacing appears to be high. A study of leadless pacing (Micra™) in Japan enrolled 38 patients, and most of the implanting physicians said the leadless pacemaker was “extremely easy” or “easy” to implant (91.6%) and deploy (94.4%) [15].

#### **4.2 Nanostim™ clinical trials: LEADLESS, LEADLESS II**

The prospective, single-arm, multicenter LEADLESS observational study ( $n = 470$ ) evaluated the freedom from serious adverse device events at 6 months as the primary endpoint. The study had to be interrupted owing to the occurrence of cardiac perforation events that required changes in the protocol and training. In the 300 patients enrolled after the study interruption, freedom from serious adverse device events was 94.6% (95% CI, 91.0–97.2%), although 18 serious adverse device events were observed in 6.6% of patients ( $n = 16$ ), the most frequent of which were perforation (1.3%), vascular complications (1.3%), and dislodgement of the device (0.3%). When all 470 patients were included (before and after the interruption), 6.6% of all patients experienced a serious adverse device-related event [20].

The LEADLESS clinical trial retrospectively evaluated safety and efficacy of the Nanostim™ leadless pacemaker over a minimum of 3 years of follow-up. A total of 33 patients (mean age  $77 \pm 8$  years) were enrolled, of whom 31 received a leadless pacemaker [21]. Two patients could not be implanted (one procedure was aborted and the other was revised to an ICD.) At 3 years, 74% (23/31) of patients were alive and no deaths were attributable to the leadless pacemaker. Most patients (89.9%) reported freedom from serious adverse events (95% CI, 79.5–100%), and 9% experienced device-related complications, of whom two had procedure-related serious adverse events. One suffered perforation leading to tamponade and the other had inadvertent implantation of the leadless pacemaker into the left ventricle by way of a patent foramen ovale, which was successfully retrieved and a new device implanted into the right ventricle. A third complication was reported after 37 months attributed to battery malfunction and necessitating device revision, which involved the successful removal of the leadless pacemaker and replacement

with a new one. Up to 35 months, the electrical parameters of the leadless pacemakers were appropriate [21]. A retrospective assessment of 31 of the 33 patients from the LEADLESS study was conducted to evaluate the complication rates, device performance, and rate response features at 1 year. No pacemaker-related adverse events occurred from 3 months postimplant to 12 months. At 12 months, the mean pacing threshold was  $0.43 \pm 0.30$  V at 0.4 ms, the mean R-wave was  $10.3 \pm 2.2$  mV, and 61% had rate response features activated, of whom adequate results were achieved by all [22].

The LEADLESS II study is a premarket, nonrandomized, prospective, multicenter study of 526 patients with a leadless pacemaker (Nanostim™) who were followed for safety and efficacy for 6 months [3]. Inclusion criterion was a single-chamber ventricular pacing indication (which included patients with persistent or permanent atrial fibrillation). The primary efficacy outcome was achievement of a therapeutic capture threshold (defined as  $\leq 2.0$  V at 0.4 ms) and appropriate sensing ( $\geq 5.0$  mV R-wave or an R-wave that exceeded the R-wave value at implant). By an intention-to-treat analysis, 90.0% of patients in the primary cohort achieved this at implant. At 12 months, the mean capture threshold was  $0.58 \pm 0.31$  V at 0.4 ms and the mean R-wave was  $9.2 \pm 2.9$  mV. At 12 months, the mean percentage of ventricular pacing was  $51.6 \pm 39.1\%$ . The primary safety outcome was freedom from device-related adverse events in the first 6 months after implant, which was achieved by 93.3% of patients. Over 6 months, a total of 22 serious adverse events related to the device occurred in 20 patients (6.7%) in the primary cohort. In the total cohort, the rate of serious adverse events related to the device was 6.5%. Devices migrated from the heart into the pulmonary artery or right femoral vein in four and two patients, respectively, and all devices were successfully retrieved percutaneously [3]. The majority of patients did not require revision to reposition the pacemaker (70.2%), but 4.4% of patients required two or more attempts to reposition the device. The mean duration of hospital stay was  $1.1 \pm 1.7$  days (range 0–33) [3]. Over the course of the study, 28 patients died (5.3%) but no deaths were related to the device.

The LEADLESS II patient cohort ( $n = 718$ ) was compared retrospectively to 1436 transvenous pacemaker patients (historical data) with the results that leadless pacemaker patients had fewer complications (hazard ratio 0.44, 95% CI, 0.23–0.60,  $p < 0.001$ ) broken down as short-term complications (5.8 vs. 9.4%,  $p = 0.01$ ) and mid-term complications (0.56 vs. 4.9%,  $p < 0.001$ ). Specifically, leadless pacemaker patients had more pericardial effusions (1.53 vs. 0.35%,  $p = 0.005$ ), but similar rates of vascular events (1.11 vs. 0.42%,  $p = 0.085$ ), dislodgements (0.97 vs. 1.39%,  $p = 0.54$ ), and generator complications (0.70 vs. 0.28%,  $p = 0.17$ ). Leadless pacemaker patients had no cases of thoracic trauma compared to 3.27% of transvenous patients [23].

In October 2016, an advisory was issued for the Nanostim™ device regarding premature battery depletion [24]. A prospective, observational, single-center study was conducted in Germany with patients implanted early (up until April 2014) or late (starting December 2015 and thereafter). The cohort included 14 consecutive patients ( $77 \pm 9$  years, 57% male) with a mean follow-up of  $29.5 \pm 11.5$  months (range 11.9–44.6 months). Most were “early” patients ( $n = 9$ , 64%) implanted before the implantation suspension and five were implanted “late” (36%). From data obtained at the last follow-up, 57% had permanent atrial fibrillation with complete heart block, 21% were considered pacemaker dependent, and 36% had a mean regular escape rhythm of  $37 \pm 2$  beats per minute (bpm). Almost half of the patients had signs of battery malfunction (43%,  $n = 6$ ), all of whom had “early” implants. Using the Kaplan-Meier method, the mean time calculated from implant to device failure was 39.0 months (standard error 1.85 months, 95% CI, 35.4–42.7 months). Device parameters fell within the normal range for all patients (100%) at the last follow-up before battery malfunction was detected. Devices



were explanted and analysis showed reduced electrolytes in the lithium carbon monofluoride battery, which caused high internal battery resistance, reducing the available current for device function. While a report from 2016 showed Nanostim™ battery malfunction occurred at a global rate of 2.4%, the rate at this particular institution was much higher, possibly owing to the fact that the observation period was longer [24].

### 4.3 Meta-analyses and comparative studies

In a meta-analysis of lead and device dislodgement (n = 18 studies, 17,321 patients) involving conventional transvenous pacemakers and leadless pacemakers (both Micra™ and Nanostim™), the weighted mean incidence of lead dislodgement in transvenous devices was 1.71%. Atrial leads had a higher dislodgement rate than ventricular leads (odds ratio 3.56, 95% CI, 1.96–6.70). The dislodgement rate for leadless devices was reported in three studies (n = 2116) and was 0, 0.13, and 1.0%, respectively, showing an overall lower dislodgement rate than conventional systems [25].

In a propensity score-matched study, 440 pacemaker patients were matched based on whether they had a leadless system (n = 220) or a transvenous system (n = 220). The complication rate at 800 days of follow-up was significantly lower in the leadless pacemaker group (0.9 vs. 4.7%, 95% CI, p = 0.02) [26].

### 4.4 Other safety issues

Ventricular arrhythmias after the implantation of a leadless pacemaker should be considered as potential side effect secondary to leadless pacemaker implantation. A case report in the literature describes a patient who experienced short episodes of polymorphic ventricular tachycardia (VT) in the perioperative period and high ventricular rates with short-long-short runs of polymorphic VT induced by premature ventricular contractions. The system was extracted successfully, revised with a new device of the same type successfully implanted at a different position in the right ventricle, and the VT resolved. The pro-arrhythmic effect of the leadless pacemaker remains to be elucidated, but it may involve the irritation of the right-ventricular myocardium at the site of implantation [27].

## 5. Leadless pacemaker features

### 5.1 Rate response

Both commercially available systems offer rate response. The Micra™ device utilizes a programmable accelerometer that works on three axes. Rate response is set up based on three activity vectors. The accelerometer can be programmed following a five-minute exercise test, which should be conducted before hospital discharge and then at an in-clinic visit later. While Vector 1 can be programmed as the nominal setting, an early study in 51 patients (278 tests, 818 vector measurements) found the manual selection of a vector produced better results than opting for the default Vector 1 setting. In initial testing, Vector 1 was found to be adequate in 74.5% of patients but in in-clinic testing, Vector 1 was adequate for 64.7%, while Vector 3 was adequate in 68.6% (and Vector 2 was adequate in 51.0%) [28]. The Nanostim™ device utilizes blood temperature for its rate response [2].

In the LEADLESS clinical trial (n = 31), rate response was turned on in 61% of patients at 12 months, 42% at 24 months, and 39% at 36 months [21].



## 5.2 Capture management

The Micra™ leadless pacemaker offers a capture management system, while the Nanostim™ does not.

## 5.3 Magnet mode

Application of a magnet over the implant site of a conventional transvenous pacemaker will cause it to behave in highly specific ways (for example, asynchronous fixed-rate pacing) in response in a function known as magnet mode. The Micra™ device does not offer magnet mode, but the Nanostim™ will pace at 100 bpm for eight beats and then go to asynchronous pacing at 90 bpm (or 65 bpm if the device is at the elective replacement indicator) [5].

## 5.4 Magnetic resonance imaging compatibility

The MIMICRY study (Monocenter Investigation Micra™ MRI Study) examined magnetic resonance imaging (MRI) compatibility in 15 leadless pacemaker patients undergoing either a 1.5 Tesla (T) or 3.0 T cardiac MRI scan; one patient was excluded from the study because severe claustrophobia precluded an MRI. Device parameters remained stable during the MRI and over the one and three-month observation points nothing showed MRI scans were safe and feasible [29]. In an *ex vivo* study using porcine hearts, leadless pacemakers were implanted in the heart (100% success rate) and then MRI conducted to assess artifacts. In most of the MRI sequences, the right ventricle and septal area near the device showed some degree of artifact, which might compromise utility, but the rest of the myocardium was free of artifacts. The leadless-pacemaker-created artifact had the shape of a shamrock and was brighter in the 3 T scans than the 1.5 T images [30].

## 5.5 Compatibility with external electrical cardioversion

A case report describes an 85-year-old woman with bradycardia and atrial fibrillation who received a leadless pacemaker (Micra™) and underwent external electrical cardioversion with three shocks at 100, 200, and 360 J. The three cardioversion shocks had no observable effect on the implanted leadless pacemaker [31].

## 6. Device retrieval

To date, there is limited experience with normal, expected end-of-life device revision. Revision may be accomplished by retrieving the old device and implanting a new one, or by simply inactivating the exhausted device and adding a new device nearby. In theory at least, device retrieval seems preferable, in that it limits the amount of hardware in the body and might reduce long-term complications or device-device interference [32]. Successful acute and chronic device retrievals have been reported in the literature. A study on human cadaver hearts has demonstrated that it is feasible to simply implant a new leadless pacemaker without removing the old one [33]. Successful device extraction in a porcine model was reported using a single-loop retrieval snare and a superior vena cava approach [34].

In a study of Micra™ pacemaker revisions, 989 implants were analyzed and compared to 2667 control patients with a transvenous ventricular single-chamber pacemaker. The actuarial rate for device revision at 24 months following implant was 1.4% for leadless pacemakers (11 revisions in 10 patients) compared to 5.3%

in the transvenous pacemaker group (123 revisions in 117 patients), that is, 75% lower for leadless pacemakers (95% CI, 53–87%,  $p < 0.001$ ). The main reasons for extracting a leadless device were a need for a different device therapy, pacemaker syndrome, and prosthetic valve endocarditis. No leadless pacemaker was extracted because of device dislodgement or device-related infection. In seven cases, the device was deactivated and abandoned; in three cases, the device was extracted percutaneously; and in one case, the device was removed during aortic valve surgery. Overall, 64% of deactivated leadless pacemakers were left *in situ* [35].

In a retrospective study of 40 successful retrievals of leadless pacemakers (Micra™), 73% ( $n = 29$ ) consented to supplying procedural details to a research study by Afzal and colleagues. This largest retrieval study to date differentiated between “immediate retrievals” ( $n = 11$ ) in which the original device was retrieved perioperatively and “delayed retrieval” ( $n = 18$ ) in which the retrieval involved a new procedure at a later date. The median duration between implant and retrieval in the delayed retrieval group was 46 days (range 1–95 days). The most commonly reported reasons for leadless pacemaker retrieval were elevated pacing threshold upon tether removal (immediate retrieval) and elevated threshold, endovascular infection, or need to switch to transvenous system (delayed retrieval) [36]. The mean duration for a retrieval procedure was  $63.11 \pm 56$  min with a mean fluoroscopy exposure of  $16.7 \pm 9.8$  min. Retrieval was accomplished using a snaring system deployed via a delivery catheter or steerable sheath. No serious complications were reported [36].

In the LEADLESS II trial, the implantable device was retrieved successfully and without complications in seven patients at  $160 \pm 180$  days (median 100 days, 1–413 range). Of these patients, three were implanted with a new leadless pacemaker, two were implanted with a conventional transvenous pacing system, and two patients were implanted with a cardiac resynchronization therapy (CRT) device for heart failure. In a study composed of leadless pacemaker patients who required leadless pacemaker removal from three other multicenter studies, 5/5 patients who required acute extraction (within 6 weeks of implant) and 10/11 of patients who required chronic extraction ( $\geq 6$  weeks after implant) experienced successful device retrieval with no procedure-related adverse events [37].

Acute explantation of the leadless device was reported in the literature when the device migrated into the pulmonary artery a few days after implantation in a 34-year-old patient with infective endocarditis. A single-loop snare guided by a steerable sheath was used to retrieve the migrated device, and a second leadless pacemaker was successfully implanted with no further complications [38]. A case report describes a 62-year-old pacemaker patient who had a leadless pacemaker implanted (to replace an infected transvenous system) and then revised with a second leadless pacemaker because of failure to capture at maximum output settings. The procedure was conducted by implanting the new leadless pacemaker into the patient, assuring its proper function, and then extracting the original underperforming leadless device using a triple-loop snare system [39]. A single-center case series reported extraction of leadless pacemakers (Nanostim™) in three cases with 100% success rate and fluoroscopic exposure times of 12, 16, and 19 min. Each extraction was preceded by a transesophageal 3D echocardiogram to assess the device’s mobility with the heart and possible endothelialization. Retrieval was carried out using the proprietary catheter system from the manufacturer [40].

A novel extraction technique using a cryoballoon steerable sheath together with a snare was reported for the successful retrieval of a leadless pacemaker (Micra™), which was securely positioned in the patient but had an unusual subacute rise in pacing threshold [41]. The pacemaker was first implanted at the right-ventricular apex, but pacing thresholds were too high there (1.63 V at 0.24 ms), so the device was repositioned to a site on the right-ventricular septum with acceptable thresholds

(0.75 V at 0.24 ms). The threshold increased unexpectedly over the next 30 min to 2.2 V at 0.24 ms with no radiographic proof of dislodgement. Using a 15 French steerable cryoballoon sheath in an introducer to the right atrium, the sheath could be navigated over the tricuspid valve and into the right ventricle. A 7 French 20 mm snare was then introduced into the steerable sheath. The retrieval loop on the leadless pacemaker was successfully snared and could be extracted along with the introducer and sheath. No blood clot or visible defect was found on the extracted device. A second leadless pacemaker was implanted at the mid-septum of the right ventricle with good electrical measurements (capture threshold 0.5 V at 0.24 ms), which remained stable over 30 minutes. At 1 month, the patient has a capture threshold of 0.62 V at 0.24 ms, an R-wave of 8.6 mV, and impedance of 600  $\Omega$  [41].

Of 1423 leadless Nanostim™ pacemakers implanted around the world, there were 34 reported cases of premature battery depletion with a 90.4% successful retrieval rate even though these were chronic implants (battery depletion occurred at  $2.9 \pm 0.4$  years). Of the seven patients in whom retrieval was not possible, most cases were caused by an inaccessible or otherwise nonfunctional retrieval loop on the device [4].

## 7. Quality of life

In a study of health-related quality of life using the Short-Form 36 (SF-36) questionnaire at baseline, 3 months, and 12 months in 720 Micra™ patients, all domains improved significantly at 3 and 12 months compared to baseline values and 96% were “satisfied” or “very satisfied” with the aesthetic appearance of the system, 91% with their recovery, and 74% with their current activity level [42]. Leadless pacemakers were associated with fewer restrictions on activity than leadless pacemakers in a survey of 720 patients [42].

In a study of leadless pacemaker (Micra™) patients, some national differences emerged. In this study, 35 Japanese patients were reviewed compared to 658 similar patients outside of Japan. Fewer Japanese-only patients compared to outside-Japan patients were “very satisfied” or “satisfied” with their recovery (74.3 vs. 91.8%,  $p = 0.002$ ), but those who reported themselves “very satisfied” or “satisfied” with the device’s cosmetic appearance were similar (91.4 Japanese vs. 96.2% outside Japan). All implants in the Japanese patients were successful [15].

## 8. Guidelines

Leadless pacemakers are indicated for patients with symptomatic bradycardia requiring single-chamber ventricular bradycardia pacing support; persistent atrial tachyarrhythmias in such patients are not a contraindication for leadless pacing. In fact, many patients who receive a leadless pacemaker have persistent or permanent atrial fibrillation with slow ventricular response.

The role of leadless pacemakers following removal of an infected conventional transvenous pacing system is debated. Since a leadless device requires no pocket formation and has no transvenous leads, it would appear to be suitable for a revision system for appropriate patients. In a study of patients who required device replacement after a conventional pacemaker system was infected ( $n = 17$ ), patients were implanted with a Nanostim™ ( $n = 11$ ) or Micra™ ( $n = 6$ ) device [43]. In six patients, the leadless pacemaker was implanted within a week or less while in 11 patients, the leadless pacemakers was implanted after at least 1 week. In all patients, there was no infection over the course of a mean follow-up of  $16 \pm 12$  months. This patient population included seven patients with a history of recurrent device infections

(mean follow-up of  $20 \pm 14$  months). This study suggests that a leadless pacemaker may be a viable revision pacing system for selected patients who experienced device infection with a conventional pacemaker [43].

The French Working Group on Cardiac Pacing and Electrophysiology of the French Society of Cardiology has issued specific guidelines on leadless pacing [44]. Currently, the indication for leadless pacing is a patient indicated for VVIR pacing and the patient's life, as well as device service life must be taken into account as device retrieval may not always be possible. They consider that leadless devices should be implanted only in centers that also perform cardiac surgery, because of the higher incidence of tamponade, vascular complications, perforations caused by large-diameter sheaths, or other complications associated with leadless pacemakers [44].

It has been recommended that anesthesiologists familiarize themselves with all implantable device technologies, including leadless pacemakers [5]. A challenge to these devices is that interrogation software may not be readily available and that implantation should be coordinated with device manufacturer representatives or cardiologists, for example, if the device should be programmed to an asynchronous pacing mode during implant [5].

## **9. Special populations**

In 64% of patients enrolled in one of the pivotal trials for leadless pacemakers (Micra™), the pacing indication was managing persistent or permanent atrial fibrillation with slow ventricular response [16]. In that pivotal trial, only 6% of patients had a clear-cut medical reason that limited or contraindicated them from a transvenous system. However, there are many emerging groups who may derive benefits from leadless pacemakers.

### **9.1 Limited or occluded venous access**

Leadless pacemakers may be an important alternative to conventional devices in patients with thromboses, venous obstruction, tortuous or abnormal venous anatomy, superior vena cava syndrome, or other conditions may be contraindicated for a conventional transvenous pacemaker. A case report describes a patient with third-degree atrioventricular (AV) block who experienced an occlusive thrombosis of the superior vena cava and had her conventional VDD transvenous pacemaker replaced with a leadless device [45]. Limited venous access as an anatomical challenge may be overcome with a leadless pacemaker as in a case study of a bradycardic hemodialysis patient who suffered from skin erosion in the chest area due to radiation treatments for esophageal carcinoma. The leadless pacemaker was implanted successfully, but the patient developed ventricular tachyarrhythmias, necessitating the implantation of a subcutaneous implantable cardioverter-defibrillator. At 1 month, both devices were performing adequately with no device-device interactions [46].

A 72-year-old man with a thrombosed venous stent, renal failure, and myelodysplastic syndrome presented with second-degree AV block. A leadless pacemaker was preferred (Micra™) because of limited venous access and a high risk of infection due to his immunocompromised condition [47].

### **9.2 Pacemaker-dependent patients transitioned to leadless pacing**

When it is necessary to extract transvenous leads in a pacemaker-dependent patient, a common approach is to utilize a temporary pacemaker with active-fixation lead as a bridge to a contralateral pacemaker implantation. A case report



describes the use of a leadless pacemaker in a pacemaker-dependent patient with dextrocardia who required lead extraction following endocarditis. The implantation procedure was uneventful and the leadless pacemaker performed well with stable measurements taken 1 year postimplant [48].

### **9.3 Transplanted hearts**

The literature reports on successful implantation of a leadless pacemaker in a transplanted heart [49].

### **9.4 Patients with prosthetic valves**

The permanent position of a transvenous lead over the tricuspid valve may cause damage to the valve. In patients with a prosthetic tricuspid valve, locating a transvenous lead over the tricuspid valve must be considered carefully. The literature reports a case in which a 67-year-old woman with three valve replacements (an aortic mechanical valve, a mitral mechanical valve, and a tricuspid prosthesis) underwent successful implantation of a leadless pacemaker (Micra™) for high-degree AV block with permanent atrial fibrillation. She had previously had an epicardial pacemaker, which experienced lead dysfunction and transient loss of capture [50].

In a study of 23 leadless pacemaker patients (both Micra™ and Nanostim™), devices were implanted in the septal-apical area or the mid-septal region of the right ventricle. No observed changes in heart structure or heart function, such as changes to the tricuspid valve, were found. One patient in this study developed increased tricuspid valve regurgitation but without abnormal leaflet motion or any changes in annulus size, suggesting it was caused by changes in right ventricular pressure [51].

### **9.5 Tandem subcutaneous ICD with leadless pacemaker**

It is not difficult to imagine the possibilities of combining a subcutaneous ICD (S-ICD) with a leadless pacemaker to allow for bradycardia pacing support and rescue defibrillation in a patient without the need for any transvenous leads. In an experimental study (n = 40, animal models were ovine, porcine, and canine), the dual devices were successfully implanted in 39/40 and 23 animals were followed for 90 days. Appropriate pacing was observed in 100% of animals by the leadless pacemaker, and the ICD could communicate unidirectionally with the pacemaker in 99% of cases. When triggered, the leadless pacemaker could deliver antitachycardia pacing (10 beats at 81% of the coupling interval) in 100% of attempts, while the S-ICD was able to maintain appropriate sensing [52]. While this is a preliminary animal study, it demonstrates the potential of utilizing these two leadless systems in tandem. For an S-ICD and a leadless pacemaker to work effectively together, they require the ability to communicate with each other, which, in turn, depends on the device orientation within the subject. In a canine study (n = 23), it was found that communication could occur in 100% of the implanted dogs although the median angle of the leadless pacemaker was 29°, and the median distance of the S-ICD to the leadless pacemaker was 0.8 cm. While these are not optimal values, communication was effective. A retrospective study of 72 leadless pacemaker patients found the median angle of the leadless pacemaker was 56 degrees; in a retrospective analysis of 100 S-ICD patients, the median distance between the coil and the position of the leadless pacemaker was 4.6 cm [53]. Thus, it appears that communication between devices is possible and that humans offer a better theoretical positioning opportunity for such communication than dogs.

Dual device implantation was performed in an 81-year-old man who received an S-ICD in 2012 after explant of three transvenous ICDs due to infection [54]. At the time of S-ICD implant, the patient had no indication for bradycardia pacing, but that changed in 2015 when he developed sinus bradycardia with a daytime heart rate of about 20 bpm. Both subclavian veins were occluded, and it was decided to implant a leadless pacemaker (Micra™). The device was successfully implanted with satisfactory electrical measurements (capture threshold was 0.38 V at 0.24 ms capture threshold, the R-wave was 10.4 mV, and impedance was 640  $\Omega$ ). When programmed to high outputs, the leadless pacemaker did not appear to interact with the S-ICD, even at its most sensitive settings. The patient was doing well with improved function at 4 months. At 6 months, the patient had a VT that was appropriately sensed and converted at first shock. The threshold of the leadless pacemaker following the shock remained stable [54].

## 9.6 Dialysis patients

For patients with chronic renal disease, a leadless pacemaker may allow preservation for central veins, necessary for permanent dialysis vascular access [55]. In patients with end-stage renal disease and the need for an implantable pacemaker, it is best to avoid transvenous leads if possible. Since kidney disease can progress rapidly, patients with a high risk for renal failure (for example, glomerular filtration rate  $< 20$  mL/min/1.73 m<sup>2</sup>); it may be helpful to consider these patients for leadless pacemakers or S-ICD systems rather than transvenous devices when possible [56].

## 9.7 Patients with indwelling inferior vena cava filters

Leadless pacemakers are contraindicated in patients with an indwelling inferior vena cava (IVC) filter, but as IVC filters become more common, the role of leadless pacemakers in this population will be explored. In some cases, an IVC filter might block passage of a catheter entering the femoral vein and routing toward the heart, but there are cases reported in the literature in which the catheter with the leadless pacemaker has been able to navigate around the indwelling IVC device. However, large studies of leadless pacemakers exclude IVC filter patients, so there is not much data on how a leadless pacemaker might be deployed in this population. A few cases in the literature suggest it is feasible, at least in selected cases, to implant a leadless pacemaker in the presence of an IVC filter.

A case report in the literature describes the successful implant of a Micra™ device via a collateral branch of the right common femoral vein through a previously implanted IVC filter in a 68-year-old man with a history of pulmonary embolism and recent development of AV block [57].

## 9.8 Left atrial appendage occluders

There is a report in the literature of a dual implant of a left-atrial-appendage occluder (Watchman™, Boston Scientific, Natick, Massachusetts, USA) and a leadless pacemaker (Micra™) in a single procedure. The patient was a 73-year-old woman with persistent atrial fibrillation. Both devices were implanted via right femoral access with no complications and good results at 1 month postimplant [58].

## 9.9 Small patients

The idea that this miniaturized pacemaker might be appropriate in smaller patients has been explored in a few case studies. The literature reports a

successful implantation of a leadless device (Micra™) in an 11-year-old patient with recurrent syncope episodes and prolonged sinus pauses [59]. A 71-year-old man with achondroplastic dwarfism had a transvenous pacemaker for decades for third-degree AV block; in 2010, a pocket infection with endocarditis of the tricuspid valve necessitated the extraction of the conventional pacemaker and placement of an epicardial dual-chamber pacemaker with tunneling of leads. The patient was pacemaker dependent with permanent atrial fibrillation and developed an untreatable pocket infection. He was implanted with a leadless pacemaker (Micra™) via standard implantation technique, which was complicated by the fact that the delivery catheter was much longer than the patient's inferior limb. The device was successfully implanted and showed good electrical results. The epicardial device was then removed via a mini-thoracotomy [60]. A leadless pacemaker (Micra™) could be successfully implanted in a small-frame geriatric patient with third-degree AV block and a history of pacemaker implantations and infections [61].

### **9.10 Vasovagal syncope**

A leadless pacemaker was successfully implanted in a 17-year-old male patient with cardioinhibitory syncope. The patient had vasovagal syncope with episodes of bradycardia and drops in arterial blood pressure. An implantable loop recorder documented a pause of 9 s, whereupon he was implanted with the leadless pacemaker [62]. Cardioinhibitory syncope may be a temporary condition.

### **9.11 AV nodal ablation with permanent pacing**

For rate control in patients with symptomatic atrial fibrillation (AF), atrio-ventricular (AV) nodal ablation with subsequent pacemaker implantation (the so-called “ablate and pace” procedure) is an established course of treatment. In a multicenter observational study of 127 such patients, 60 received a leadless pacemaker and 67 a conventional transvenous pacemaker. The primary efficacy endpoint of this study was acceptable sensing thresholds (R wave  $\geq 5.0$  mV and pacing threshold  $\leq 2.0$  V at 0.4 ms). Nearly all patients (95% in leadless and 97% in conventional groups) met the primary endpoint. Five early and one late minor adverse events occurred in the leadless pacemaker group and three early adverse events occurred in the conventional pacemaker group (not statistically significantly different). Thus, it appears that leadless pacemakers may be a viable option for “ablate and pace” patients [63]. In another study in a similar population, 21 patients with permanent atrial fibrillation underwent implantation of a leadless pacemaker (Micra™) followed by AV junctional ablation; these patients were followed over 12 months with no major device-related complications. Two patients in this study died over the course of the 12 month follow-up of noncardiac causes [64]. Short- and long-term outcomes of patients undergoing a simultaneous leadless pacemaker implantation were reported from an observational study of 137 patients (mean age  $77.9 \pm 10.5$  years) in which 19.7% ( $n = 37$ ) underwent simultaneous AV nodal ablation. The complication rate was 5.5% in patients who just had leadless pacemaker insertion and 11% in those who underwent both ablation and pacemaker implant. There were no cases of device dislodgement in either group. Over the mean follow-up of  $123 \pm 48$  days, 3.6% patients ( $n = 3$ ) died, but all deaths were unrelated to cardiovascular causes. There were no significant differences between groups in terms of pacing and sensing threshold values [65].

## 9.12 Concurrent valve replacement and pacemaker implantation

The literature reports on a 66-year-old female with rheumatic heart disease, permanent atrial fibrillation with slow ventricular response, and renal failure. She was admitted for mitral valve replacement and tricuspid valve repair, at which time a *de novo* pacemaker would be implanted to help manage transient AV block. It was decided to implant a leadless pacemaker (Micra™), but the sequence of these three procedures (valve replacement, valve repair, and pacemaker implantation) was not clear. The device was anchored at an adjacent septal site with measurements of 1.25 V at 0.24 ms capture threshold, R-wave of 7 mV, and impedance of 600  $\Omega$ . After this satisfactory implantation was achieved, a tricuspid ring annuloplasty was carried out successfully, and the proper position of the leadless pacemaker was confirmed using intraoperative transesophageal echocardiography [66].

The literature reports a case in which a 91-year-old man underwent a successful transcatheter aortic valve implantation (TAVI) but experienced the not uncommon side effect of conduction disturbances. As the patient was frail and elderly, it was decided to implant a leadless pacemaker to help manage the arrhythmias rather than a transvenous system. The procedure was successful and the patient was discharged without complications [67].

## 9.13 Congenital heart disorders

Patients with congenital heart disorders are at an elevated risk for arrhythmias and anatomical anomalies, which may complicate venous access and device implantation. In fact, congenital heart disease patients have a rate for pacemaker-related complications that approaches 40% compared to about 5% in the general population [68]. A case study in the literature reports on a 47-year-old female pacemaker-dependent patient with congenital heart disease who had experienced complications with a transvenous pacemaker (lead malfunction followed by occlusion of the superior vena cava and innominate veins). The transvenous lead was abandoned, and the patient was revised to an epicardial system. She presented with dizzy spells, and it was found her epicardial system was nearing end of service and had elevated thresholds. As there was no viable vascular access, it was decided to revise her pacemaker to a leadless system (Micra™). The leadless pacemaker was implanted via left femoral venous access and a steerable catheter to the right ventricular apical septal region where it was successfully positioned with good electrical values (1.0 V at 0.4 ms with an R-wave of 8 mV) [69].

## 10. Costs

At present, leadless pacemakers cost significantly more than a conventional transvenous device without the expense of two transvenous leads. The question of cost effectiveness in medical devices is always complicated, but it must be taken into account that even with a higher upfront cost, leadless pacemakers have substantially longer expected longevity (up to twice as long as a conventional transvenous pacemaker) and fewer complications [13]. In an online survey conducted by the European Heart Rhythm Association (EHRA) of 52 centers who participate in the EHRA Research Network, most of the 52 centers who reported said they implanted leadless pacemakers (86%) but at a small volume (82% said they implanted fewer than 30 such devices in the past 12 months). The main reasons for the low volume were device costs (91%) and lack of reimbursement for these systems (55%) [50].



## **11. Future challenges**

Currently, leadless pacing is limited to right-ventricular pacing only. The vast majority of pacemaker patients depend on AV synchronization and may even benefit from additional cardiac resynchronization for heart failure. One way to solve the AV-sequential issue is to employ VDD mode that would allow for atrial sensing; a subcutaneous ECG integrated into the circuit would be an option.

Systems that are able to communicate between devices are being developed, i.e., integration of a leadless pacemaker with an S-ICD. Ideally, this combination would offer reliable sensing/pacing in the right ventricle including antitachycardia pacing in order to terminate VT without shock therapy. Moreover, combining intracardiac signals from the leadless pacemaker with the subcutaneous ECG from the S-ICD may improve the system's ability to discriminate arrhythmias.

Another concern is handling of the device at the end of its service life. Likely, the devices will be encapsulated and could be programmed off (OOO mode), and up to three devices can reasonably be accommodated within the right ventricle [33]. However, many pacemaker patients are old with a shorter life expectancy than projected batter longevity and will only need one device.

Extraction will be necessary in the event of an infection, and the development of safe catheter-based tools would be helpful even in the situation of complete device encapsulation. More data are needed about safety of leadless pacemakers with regard to infection, device migration, and RV failure in long-term follow-up.

A leadless ultrasound-based technology used by the WiCS™ system (Wireless Cardiac Stimulation, EBR Systems) has been developed for endocardial pacing of the left ventricle [70]. The ultrasound energy is transmitted from a subcutaneous transmitter to an endocardial receiver unit in the endocardium. This device is fixed by three self-expanding nitinol tines on the device. Thus, this cardiac resynchronization therapy (CRT) system comprises three parts: the left-ventricular endocardial unit (using ultrasound for conversion of electrical energy), the subcutaneous pulse generator, and a conventional pacing device. The subcutaneously implanted pulse generator consists of a battery connected by a cable to a transmitter. The system detects right-ventricular stimulation provided by the concomitant pacemaker, CRT device, or ICD.

## **12. Conclusion**

The technology of leadless pacing is a disruptive innovation with the potential to usher in a new era of cardiac pacing and solve problems related to the transvenous leads and pocket. The first-generation leadless pacemakers are limited to single-chamber pacing, typically VVIR pacing, but further innovations may expand that. Battery longevity is supposed to be excellent, but real-world clinical data are needed from long-term use to confirm this. The extraction of a leadless pacemaker remains a challenge. Future directions include integration of leadless pacing with S-ICDs, dual-chamber devices, and a leadless version of CRT pacing.

## **Acknowledgements**

Todd Cooper of Coyote Studios in Los Angeles, California, provided the original illustration. The authors acknowledge editorial assistance provided by John Bisney who proofed the final manuscript. Trademarks and registered trademarks in this chapter are the property of their respective owners.

## Conflict of interest

The authors have no relevant conflicts to disclose.

IntechOpen

## Author details

Peter Magnusson<sup>1,2</sup>, Joseph V. Pergolizzi Jr<sup>3</sup> and Jo Ann LeQuang<sup>3\*</sup>

1 Cardiology Research Unit, Department of Medicine, Karolinska Institute, Stockholm, Sweden

2 Centre for Research and Development, Uppsala University/Region Gävleborg, Gävle, Sweden

3 NEMA Research, Inc., Naples, Florida, USA

\*Address all correspondence to: [joann@leqmedical.com](mailto:joann@leqmedical.com)

## IntechOpen

© 2019 The Author(s). Licensee IntechOpen. This chapter is distributed under the terms of the Creative Commons Attribution License (<http://creativecommons.org/licenses/by/3.0>), which permits unrestricted use, distribution, and reproduction in any medium, provided the original work is properly cited. 

## References

- [1] Cano Perez O, Pombo Jimenez M, Fidalgo Andres ML, Lorente Carreno D, Coma Samartin R. Spanish Pacemaker Registry. 14th Official Report of the Spanish Society of Cardiology Working Group on Cardiac Pacing (2016). *Revista Espanola de Cardiologia* (English ed). 2017;**70**(12):1083-1097
- [2] Kancharla K, Deshmukh AJ, Friedman PA. Leadless pacemakers—Implant, explant and long-term safety and efficacy data. *Journal of Atrial Fibrillation*. 2017;**10**(2):1581
- [3] Reddy VY, Exner DV, Cantillon DJ, Doshi R, Bunch TJ, Tomassoni GF, et al. Percutaneous implantation of an entirely intracardiac leadless pacemaker. *The New England Journal of Medicine*. 2015;**373**(12):1125-1135
- [4] Lakkireddy D, Knops R, Atwater B, Neuzil P, Ip J, Gonzalez E, et al. A worldwide experience of the management of battery failures and chronic device retrieval of the Nanostim leadless pacemaker. *Heart Rhythm: The Official Journal of the Heart Rhythm Society*. 2017;**14**(12):1756-1763
- [5] Cronin B, Essandoh MK. Update on cardiovascular implantable electronic devices for anesthesiologists. *Journal of Cardiothoracic and Vascular Anesthesia*. 2018;**32**(4):1871-1884
- [6] Kolek MJ, Crossley GH, Ellis CR. Implantation of a MICRA leadless pacemaker via right internal jugular vein. *JACC Clinical Electrophysiology*. 2018;**4**(3):420-421
- [7] Lloyd MS, El-Chami MF, Nilsson KR Jr, Cantillon DJ. Transcatheter/leadless pacing. *Heart Rhythm: The Official Journal of the Heart Rhythm Society*. 2018;**15**(4):624-628
- [8] Conyers JM, Rajiah P, Ahn R, Abbara S, Saboo SS. Imaging features of leadless cardiovascular devices. *Diagnostic and Interventional Radiology* (Ankara, Turkey). 2018;**24**(4):203-208
- [9] Kawata H, Patel PM, Banker R. Nanostim leadless pacemaker system: A longer waiting period after active fixation may reduce unnecessary repositioning. *HeartRhythm Case Reports*. 2018;**4**(2):63-65
- [10] Tjong FVY, Beurskens NEG, Neuzil P, Defaye P, Delnoy PP, Ip J, et al. The learning curve associated with the implantation of the Nanostim leadless pacemaker. *Journal of Interventional Cardiac Electrophysiology: An International Journal of Arrhythmias and Pacing*. 2018;**53**(2):239-247
- [11] Essandoh M. Perioperative management of the micra leadless pacemaker. *Journal of Cardiothoracic and Vascular Anesthesia*. 2017;**31**(6):e97-ee8
- [12] Grabowski M, Michalak M, Gawalko M, Gajda S, Cacko A, Januszkiewicz L, et al. Implantation of the Micra transcatheter pacing system: Single Polish center experience with the real costs of hospitalization analysis. *Cardiology Journal*. 2018
- [13] Shen EN, Ishihara CH, Uehara DR. Leadless pacemaker: Report of the first experience in Hawai'i. *Hawai'i Journal of Medicine & Public Health: A Journal of Asia Pacific Medicine & Public Health*. 2018;**77**(4):79-82
- [14] Valiton V, Graf D, Pruvot E, Carroz P, Fromer M, Bisch L, et al. Leadless pacing using the transcatheter pacing system (Micra TPS) in the real world: Initial Swiss experience from the Romandie region. *Europace*. 2018
- [15] Soejima K, Asano T, Ishikawa T, Kusano K, Sato T, Okamura H, et al. Performance of leadless pacemaker in

japanese patients vs. rest of the world—Results from a global clinical trial. *Circulation Journal: Official Journal of the Japanese Circulation Society*. 2017;**81**(11):1589-1595

[16] Reynolds D, Duray GZ, Omar R, Soejima K, Neuzil P, Zhang S, et al. A leadless intracardiac transcatheter pacing system. *The New England Journal of Medicine*. 2016;**374**(6):533-541

[17] El-Chami MF, Al-Samadi F, Clementy N, Garweg C, Martinez-Sande JL, Piccini JP, et al. Updated performance of the Micra transcatheter pacemaker in the real-world setting: A comparison to the investigational study and a transvenous historical control. *Heart Rhythm: The Official Journal of the Heart Rhythm Society*. 2018

[18] Garweg C, Ector J, Voros G, Greyling A, Vandenberk B, Foulon S, et al. Monocentric experience of leadless pacing with focus on challenging cases for conventional pacemaker. *Acta Cardiologica*. 2018;**73**(5):459-468

[19] Roberts PR, Clementy N, Al Samadi F, Garweg C, Martinez-Sande JL, Iacopino S, et al. A leadless pacemaker in the real-world setting: The Micra Transcatheter Pacing System Post-Approval Registry. *Heart Rhythm: The Official Journal of the Heart Rhythm Society*. 2017;**14**(9):1375-1379

[20] Sperzel J, Defaye P, Delnoy PP, Garcia Guerrero JJ, Knops RE, Tondo C, et al. Primary safety results from the LEADLESS Observational Study. *Europace*. 2018

[21] Tjong FVY, Knops RE, Neuzil P, Petru J, Sediva L, Wilde AAM, et al. Midterm safety and performance of a leadless cardiac pacemaker: 3-year follow-up to the LEADLESS Trial (Nanostim Safety and Performance Trial for a Leadless Cardiac Pacemaker System). *Circulation*. 2018;**137**(6):633-635

[22] Knops RE, Tjong FV, Neuzil P, Sperzel J, Miller MA, Petru J, et al. Chronic performance of a leadless cardiac pacemaker: 1-year follow-up of the LEADLESS trial. *Journal of the American College of Cardiology*. 2015;**65**(15):1497-1504

[23] Cantillon DJ, Dukkupati SR, Ip JH, Exner DV, Niazi IK, Banker RS, et al. Comparative study of acute and mid-term complications with leadless and transvenous cardiac pacemakers. *Heart Rhythm: The Official Journal of the Heart Rhythm Society*. 2018;**15**(7):1023-1030

[24] Richter S, Doring M, Ebert M, Bode K, Mussigbrodt A, Sommer P, et al. Battery malfunction of a leadless cardiac pacemaker: Worrisome single-center experience. *Circulation*. 2018;**137**(22):2408-2410

[25] Wang Y, Hou W, Zhou C, Yin Y, Lu S, Liu G, et al. Meta-analysis of the incidence of lead dislodgement with conventional and leadless pacemaker systems. *Pacing and Clinical Electrophysiology: PACE*. 2018

[26] Tjong FVY, Knops RE, Udo EO, Brouwer TF, Dukkupati SR, Koruth JS, et al. Leadless pacemaker versus transvenous single-chamber pacemaker therapy: A propensity score-matched analysis. *Heart Rhythm: The Official Journal of the Heart Rhythm Society*. 2018;**15**(9):1387-1393

[27] Amin AK, Billakanty SR, Chopra N, Fu EY, Nichols AJ, Kleman JM, et al. Premature ventricular contraction-induced polymorphic ventricular tachycardia after leadless pacemaker implantation: A unique adverse effect of leadless pacing. *Heart Rhythm Case Reports*. 2018;**4**(5):180-183

[28] Bari Z, Vamos M, Bogyi P, Reynolds D, Sheldon T, Fagan DH, et al. Physical activity detection in patients with intracardiac leadless pacemaker. *Journal*



of Cardiovascular Electrophysiology. 2018

[29] Blessberger H, Kiblboeck D, Reiter C, Lambert T, Kellermair J, Schmit P, et al. Monocenter Investigation Micra(R) MRI study (MIMICRY): Feasibility study of the magnetic resonance imaging compatibility of a leadless pacemaker system. *Europace*. 2018

[30] Edlinger C, Granitz M, Paar V, Jung C, Pfeil A, Eder S, et al. Visualization and appearance of artifacts of leadless pacemaker systems in cardiac MRI : An experimental ex vivo study. *Wiener Klinische Wochenschrift*. 2018;**130**(13-14):427-435

[31] Filipovic K, Bellmann B, Luker J, Steven D, Sultan A. External electrical cardioversion of persistent atrial fibrillation in a patient with a Micra Transcatheter Pacing System. *Indian Pacing and Electrophysiology Journal*. 2018;**18**(1):44-46

[32] Beurskens NE, Tjong FV, Knops RE. End-of-life management of leadless cardiac pacemaker therapy. *Arrhythmia & Electrophysiology Review*. 2017;**6**(3):129-133

[33] Omdahl P, Eggen MD, Bonner MD, Iaizzo PA, Wika K. Right ventricular anatomy can accommodate multiple micra transcatheter pacemakers. *Pacing and Clinical Electrophysiology: PACE*. 2016;**39**(4):393-397

[34] Vatterott PJ, Eggen MD, Mattson AR, Omdahl PK, Hilpisch KE, Iaizzo PA. Retrieval of a chronically implanted leadless pacemaker within an isolated heart using direct visualization. *HeartRhythm Case Reports*. 2018;**4**(5):167-169

[35] Grubman E, Ritter P, Ellis CR, Giocondo M, Augustini R, Neuzil P, et al. To retrieve, or not to retrieve: System revisions with the Micra

transcatheter pacemaker. *Heart Rhythm: The Official Journal of the Heart Rhythm Society*. 2017;**14**(12):1801-1806

[36] Afzal MR, Daoud EG, Cunnane R, Mulpuru SK, Koay A, Hussain A, et al. Techniques for successful early retrieval of the Micra transcatheter pacing system: A worldwide experience. *Heart Rhythm: The Official Journal of the Heart Rhythm Society*. 2018;**15**(6):841-846

[37] Reddy VY, Miller MA, Knops RE, Neuzil P, Defaye P, Jung W, et al. Retrieval of the leadless cardiac pacemaker: A multicenter experience. *Circulation. Arrhythmia and Electrophysiology*. 2016;**9**(12):pii:e004626

[38] Taborsky M, Skala T, Kocher M, Fedorco M. Extraction of a dislocated leadless pacemaker in a patient with infective endocarditis and repeated endocardial and epicardial pacing system infections. *Biomedical Papers of the Medical Faculty of the University Palacky, Olomouc, Czechoslovakia*. 2018

[39] M RA, Dar T, Houmsse M, Augustini R, Daoud EG, Hummel J. Successful denovo implantation and explanation of an old malfunctioning micratm leadless pacemaker. *Journal of Atrial Fibrillation*. 2017;**10**(4):1723

[40] Gonzalez Villegas E, Al Razzo O, Silvestre Garcia J, Mesa Garcia J. Leadless pacemaker extraction from a single-center perspective. *Pacing and Clinical Electrophysiology: PACE*. 2018;**41**(2):101-105

[41] Chan NY, Yuen HC, Mok NS. Successful percutaneous retrieval of a leadless pacemaker due to an acute rise in pacing threshold. *Indian Pacing and Electrophysiology Journal*. 2017;**17**(6):186-188

[42] Tjong FVY, Beurskens NEG, de Groot JR, Waweru C, Liu S, Ritter P,

et al. Health-related quality of life impact of a transcatheter pacing system. *Journal of Cardiovascular Electrophysiology*. 2018

[43] Beurskens NEG, Tjong FVY, Dasselaar KJ, Kuijt WJ, Wilde AAM, Knops RE. Leadless pacemaker implantation after explantation of infected conventional pacemaker systems: A viable solution? *Heart Rhythm: The Official Journal of the Heart Rhythm Society*. 2018

[44] Defaye P, Klug D, Anselme F, Gras D, Hermida JS, Piot O, et al. Recommendations for the implantation of leadless pacemakers from the French Working Group on Cardiac Pacing and Electrophysiology of the French Society of Cardiology. *Archives of Cardiovascular Diseases*. 2018;**111**(1):53-58

[45] Dell'Era G, Porcellini S, Boggio E, Prenna E, Gravellone M, Varalda M, et al. Transcatheter leadless pacemaker implantation in a patient with failing transvenous pacemaker and total occlusion of superior vena cava. *Journal of Cardiovascular Medicine (Hagerstown, Md)*. 2018;**19**(9):511-512

[46] Enomoto Y, Hashimoto H, Ishii R, Torii S, Nakamura K, Noro M, et al. Leadless pacemaker and subcutaneous implantable cardioverter defibrillator combination in a hemodialysis patient. *Circulation Journal: Official Journal of the Japanese Circulation Society*. 2018

[47] Sideris S, Archontakis S, Vaina S, Stroumpouli E, Koumallos N, Gatzoulis K, et al. Leadless pacing systems: A valuable alternative for patients with severe access problems. *Hellenic Journal of Cardiology: HJC = Hellenike kardiologike epitheorese*. 2018;**59**(1):36-39

[48] De Regibus V, Pardeo A, Artale P, Petretta A, Filannino P, Iacopino S. Leadless pacemaker implantation

after transcatheter lead extraction in complex anatomy patient. *Clinical Case Reports*. 2018;**6**(6):1106-1108

[49] Martinez-Sande JL, Garcia-Seara J, Gonzalez-Melchor L, Rodriguez-Manero M, Gomez-Otero I, Gonzalez-Juanatey JR. Leadless pacemaker implantation in a transplanted heart. *Revista Espanola de Cardiologia (English ed)*. 2018

[50] Boveda S, Lenarczyk R, Haugaa KH, Iliodromitis K, Finlay M, Lane D, et al. Use of leadless pacemakers in Europe: Results of the European Heart Rhythm Association survey. *Europace*. 2018;**20**(3):555-559

[51] Salaun E, Tovmassian L, Simonnet B, Giorgi R, Franceschi F, Koutbi-Franceschi L, et al. Right ventricular and tricuspid valve function in patients chronically implanted with leadless pacemakers. *Europace*. 2018;**20**(5):823-828

[52] Tjong FVY, Brouwer TF, Koop B, Soltis B, Shuros A, Schmidt B, et al. Acute and 3-month performance of a communicating leadless antitachycardia pacemaker and subcutaneous implantable defibrillator. *JACC Clinical Electrophysiology*. 2017;**3**(13):1487-1498

[53] Quast ABE, Tjong FVY, Koop BE, Wilde AAM, Knops RE, Burke MC. Device orientation of a leadless pacemaker and subcutaneous implantable cardioverter-defibrillator in canine and human subjects and the effect on intrabody communication. *Europace*. 2018

[54] Ahmed FZ, Cunningham C, Motwani M, Zaidi AM. Totally leadless dual-device implantation for combined spontaneous ventricular tachycardia defibrillation and pacemaker function: A first report. *The Canadian Journal of Cardiology*. 2017;**33**(8):1066.e5-1066.e7

[55] Maradey JA, Jao GT, Vachharajani TJ. Leadless pacemaker placement

in a patient with chronic kidney disease: A strategy to preserve central veins. Hemodialysis International International Symposium on Home Hemodialysis. 2018

[56] Kusztal M, Nowak K. Cardiac implantable electronic device and vascular access: Strategies to overcome problems. The Journal of Vascular Access. 2018;1129729818762981

[57] Flores E, Patel M, Orme G, Su W. Successful implantation of a Micra leadless pacemaker via collateral femoral vein and inferior vena cava filter. Clinical Case Reports. 2018;6(3):502-505

[58] Johar S, Luqman N. Implant of a left atrial appendage occluder device (Watchman) and leadless pacing system (Micra) through the same venous access in a single sitting. BMJ Case Reports. 2018;2018

[59] Tejman-Yarden S, Nof E, Beinart R, Ovadia N, Goldshmit Y, Buber J, et al. Leadless pacemaker implantation in a pediatric patient with prolonged sinus pauses. Pediatric Cardiology. 2018;39(4):844-847

[60] Morani G, Bolzan B, Borio G, Tomasi L, Ribichini FL. Leadless pacemaker implantation in achondroplastic dwarfism and recurrent cardiac implantable electronic device infections: A case report. Europace. 2018;20(7):1160

[61] Tse G, Liu T, Li G, Tak Wong W, Chin Pang Chan G, Chan YS, et al. Implantation of the Micra leadless pacemaker in a patient with a low body mass index of 16. Oxford Medical Case Reports. 2017;2017(9):omx051

[62] De Regibus V, Moran D, Chierchia GB, Brugada P, de Asmundis C. Leadless pacing in a young patient with cardioinhibitory vasovagal syncope. Indian Pacing and Electrophysiology Journal. 2018;18(3):120-122

[63] Yarlagaadda B, Turagam MK, Dar T, Janagam P, Veerapaneni V, Atkins D, et al. Safety and feasibility of leadless pacemaker in patients undergoing atrioventricular node ablation for atrial fibrillation. Heart Rhythm: The Official Journal of the Heart Rhythm Society. 2018;15(7):994-1000

[64] Okabe T, El-Chami MF, Lloyd MS, Buck B, Gornick CC, Moore JC, et al. Leadless pacemaker implantation and concurrent atrioventricular junction ablation in patients with atrial fibrillation. Pacing and Clinical Electrophysiology: PACE. 2018;41(5):504-510

[65] Martinez-Sande JL, Rodriguez-Manero M, Garcia-Seara J, Lago M, Gonzalez-Melchor L, Kreidieh B, et al. Acute and long-term outcomes of simultaneous atrioventricular node ablation and leadless pacemaker implantation. Pacing and Clinical Electrophysiology: PACE. 2018

[66] Marai I, Diab S, Ben-Avi R, Kachel E. Intraoperative implantation of micra leadless pacemaker during valve surgery. The Annals of Thoracic Surgery. 2018;105(5):e211-e2e2

[67] Shikama T, Miura M, Shirai S, Hayashi M, Morita J, Nagashima M, et al. Leadless pacemaker implantation following transcatheter aortic valve implantation using SAPIEN 3. Korean Circulation Journal. 2018;48(6):534-535

[68] McLeod CJ, Attenhofer Jost CH, Warnes CA, Hodge D 2nd, Hyberger L, Connolly HM, et al. Epicardial versus endocardial permanent pacing in adults with congenital heart disease. Journal of Interventional Cardiac Electrophysiology: An International Journal of Arrhythmias and Pacing. 2010;28(3):235-243

[69] Sanhoury M, Fassini G, Tundo F, Moltrasio M, Ribatti V, Lumia G, et al. Rescue leadless pacemaker implantation

in a pacemaker-dependent patient with congenital heart disease and no alternative routes for pacing. *Journal of Atrial Fibrillation*. 2017;**9**(5):1542

[70] Sperzel J, Burri H, Gras D, Tjong FV, Knops RE, Hindricks G, et al. State of the art of leadless pacing. *Europace*. 2015;**17**(10):1508-1513

IntechOpen

IntechOpen