

We are IntechOpen, the world's leading publisher of Open Access books Built by scientists, for scientists

6,900

Open access books available

185,000

International authors and editors

200M

Downloads

Our authors are among the

154

Countries delivered to

TOP 1%

most cited scientists

12.2%

Contributors from top 500 universities



WEB OF SCIENCE™

Selection of our books indexed in the Book Citation Index
in Web of Science™ Core Collection (BKCI)

Interested in publishing with us?
Contact book.department@intechopen.com

Numbers displayed above are based on latest data collected.
For more information visit www.intechopen.com



Rhinosinusitis: How Common Are Anatomical Variations Responsible?

Shrikant Phatak and Richa Agrawal

Abstract

The term rhinosinusitis is defined as inflammation of nose and paranasal sinuses characterised by nasal blockage, nasal discharge, post-nasal drip, facial pain, pressure and reduction/loss of smell with corresponding endoscopic appearance and CT scan changes. The combined term is more apt than individual rhinitis or sinusitis as it is unusual for having sinus inflammation alone in the absence of nasal inflammation. The disease occurs due to obstruction in the key area, i.e., the osteomeatal complex (OMC). This chapter discusses anatomical variations responsible for the blockage of OMC leading to rhinosinusitis. Nasal endoscopic findings and radiological features depicting these variations are discussed in detail.

Keywords: rhinosinusitis, anatomical variations, osteomeatal complex, nasal endoscopy, imaging

1. Introduction

The approach of an otolaryngologist towards the management of sinusitis has changed significantly after the development of endoscopes and imaging techniques. Both these modalities help in thorough understanding of surgical anatomy and prominent anatomical variations of nose and paranasal sinuses (PNS).

Diagnostic nasal endoscopy (DNE) and imaging are complimentary to each other as small polyps in the areas of sinus ostia can often be missed in a CT scan. CT scan is still the mainstay of diagnosis for inflammatory sinonasal pathology because this displays the anatomy in a perspective that is useful to the surgeon [1]. The coronal plane, in particular, is considered as a map for assessing the anatomy that varies significantly even between both sides in the same individual. CT scan gives complete information about normal anatomy, anatomical variations, the extent of disease, and relation of sinuses to adjoining vital structures such as orbit and intracranial areas. Hence, the surgeon should master the normal surgical as well as radiological anatomy and probable anatomical variations for successful surgical outcomes.

2. Surgical anatomy

Nasal cavity is divided into right and left halves by the nasal septum. The right and left nasal cavities are often considered as mirror image; however, this

may not be the case [2]. In the lateral nasal wall there lie openings of maxillary, frontal, ethmoid, and sphenoid sinuses. The lateral nasal wall is convoluted and has got three turbinates: superior, middle, and inferior turbinate. Sometimes there can also be a supreme turbinate. Beneath each turbinate lies the corresponding meatus, namely superior meatus, middle meatus, and inferior meatus, respectively. Superior meatus is confined to the posterior third of lateral wall, the middle meatus about two thirds of the length, and inferior meatus extends along the whole length of the lateral wall. Superior meatus has opening of posterior ethmoids, while the sphenoid opens in the sphenoethmoidal recess. Middle meatus harbours the opening of frontal, maxillary, and anterior ethmoidal sinuses. The nasolacrimal duct opens in the inferior meatus.

The superior and middle turbinate are the part of ethmoid bone, while inferior turbinate is a separate bone. Middle turbinate is the most important landmark for the sinus surgery, and therefore, its attachments are important. The anterior portion lies in the sagittal plane and inserts into the lateral border of cribriform plate of ethmoidal bone. The central portion rotates in the coronal plane and is attached to the lamina papyracea. This part is known as basal or ground lamella of middle turbinate. The ground lamella separates anterior ethmoidal cells from the posterior ethmoidal cells. The posterior portion of the middle turbinate runs in the horizontal plane and is attached to the perpendicular plate of palatine bone.

2.1 Paranasal sinuses

The sinuses are arranged in pairs in relation to each nasal cavity, comprising two groups: anterior and posterior. The maxillary, frontal, and anterior ethmoids form the anterior group and these drain into the middle meatus. The posterior ethmoids and sphenoid form the posterior group which drain into superior meatus and sphenoethmoidal recess, respectively. The maxillary sinus exists at birth as small but definitive cavity adjacent to the middle meatus and it gradually enlarges with the eruption of primary dentition, and by the age of 7th year, it reaches the level of nasal floor. It attains the maximum dimension by the age of 21 years, when its floor lies 4–5 mm below the floor of nose [3]. The natural ostium is located in the superior aspect of the medial wall of the sinus and drains into hiatus semilunaris. Frontal sinus is rudimentary at birth and it reaches the level of orbital roof at the age of 9 years and its development is completed by 20 years. There is minimal development of sphenoid sinus until 3 years of age after this sphenoid sinus begins to pneumatise the sphenoid bone. There is a great variation in the extent of pneumatisation of the sphenoid sinus. It may be present as a small pit in a predominantly nonpneumatized sphenoid bone—Conchal Type. It may extend up to the anterior wall of sella turcica—Presellar type. It may pneumatise the entire sphenoid body below and behind the sella turcica so that the pituitary forms distinct bulge in its posterosuperior wall—Sellar Type [4]. Ethmoidal sinuses are the most complex of the sinuses and they are present at birth and attain adult size by the age of 12 years.

2.2 Osteomeatal complex

The term OMC is used to refer collectively the maxillary sinus ostium, ethmoid infundibulum, hiatus semilunaris, middle meatus, frontal recess, ethmoidal bulla, and uncinate process. It describes the final drainage pathway of the anterior group of sinuses.

2.3 Mucociliary clearance

Secretions of nose and sinuses form a sheet called mucous blanket. Mucous blanket consists of a superficial mucus layer, floating on the top of cilia which constantly beat like a conveyor belt towards the nasopharynx; the inspired bacterial viruses and dust particles are entrapped on the mucous blanket and carried to the nasopharynx to be swallowed. Hampering of the mucociliary mechanism leads to the stasis of secretions and subsequent sinusitis [5].

2.4 Anatomical variations

Variation in anatomy is a rule than an exception. Nature has customised different anatomies for every individual. Therefore, one must be aware of these possible variations before any surgical interventions. The major consequences of these anatomical variations are narrowing of the infundibulum.

Air in the nose and PNS act as natural contrast, so CT scan in bone and soft tissue windows is sufficient to diagnose anatomical variations and pathology in most of the cases of chronic rhinosinusitis (CRS). Here, a brief account of radiological images of anatomical variations and corresponding nasal endoscopic findings is discussed.

- DNS

It is the commonest anatomical variation. Deviation of posterior nasal septum causes CRS by creating pressure and air flow changes within the maxillary sinuses [6] (**Figures 1 and 2**). Septal spur causes turbulence in airflow leading to polyp formation.

- Concha bullosa

It is pneumatisation of middle turbinate involving its inferior bullous portion, and it may be bilateral [7, 8]. Large concha causes significant obstruction of nose. Such patients present with sinogenic headaches or chronic sinusitis. Sometimes there can be pneumatisation of lamina of middle turbinate known as lamellar concha.

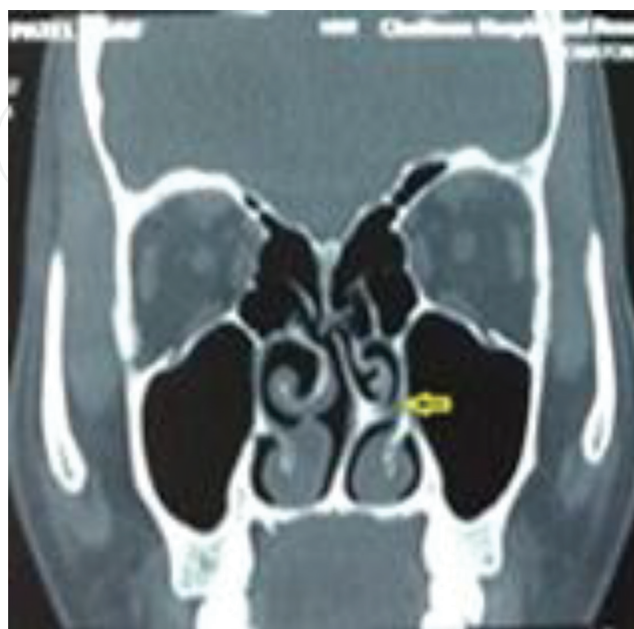

Figure 1.
CT showing sharp spur impinging middle turbinate.

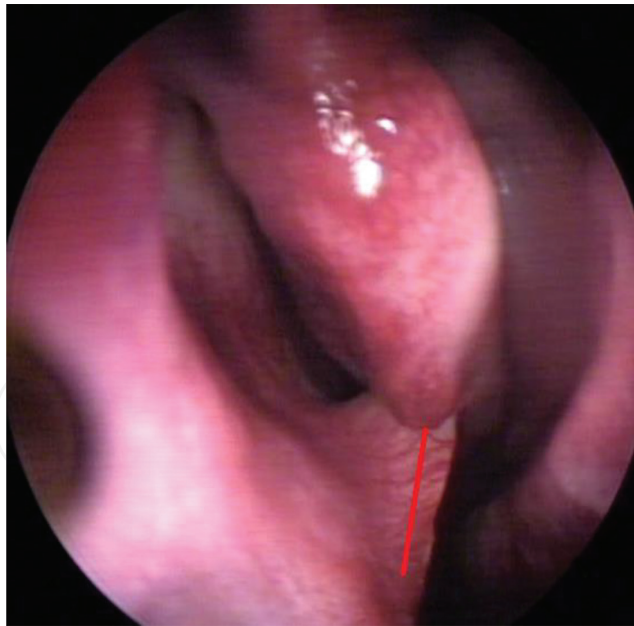

Figure 2.
Endoscopic picture showing spur impacting middle turbinate in left nasal cavity.

A paradoxical bent of middle turbinate is defined as turbinate having convexity towards the lateral nasal wall. This leads to narrowing of infundibulum [9–11] (**Figures 3 and 4**).

- Pneumatisation of superior turbinate- (**Figure 5**)
- Uncinate process

Can be medially bent uncinate process (**Figures 6 and 7**) or pneumatised uncinate process (**Figures 8 and 9**). Sometimes the uncinate can protrude anterior-inferior to middle turbinate, giving the impression of two middle turbinates [12].

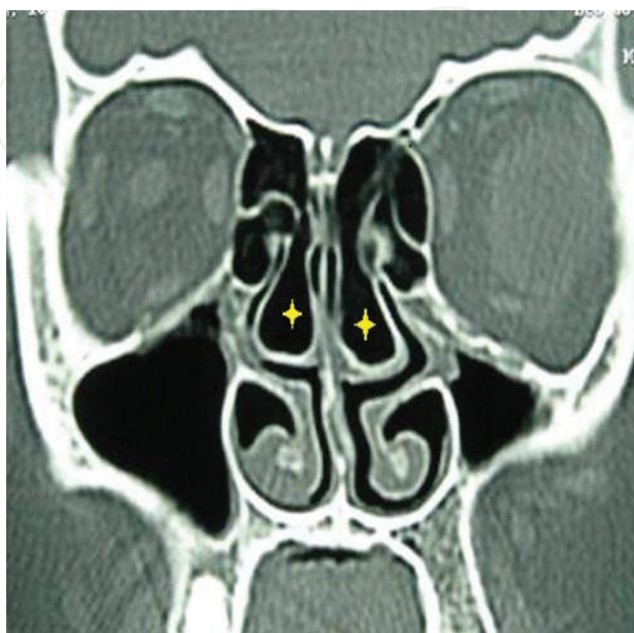


Figure 3.
CT PNS showing bilateral concha bullosa.

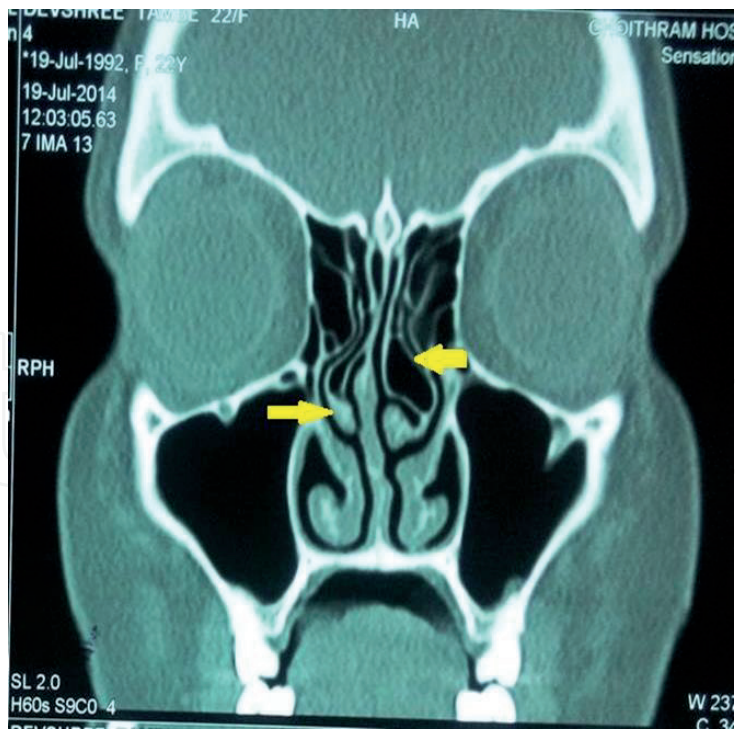


Figure 4.
CT PNS showing bilateral paradoxical middle turbinate with right lamellar concha.

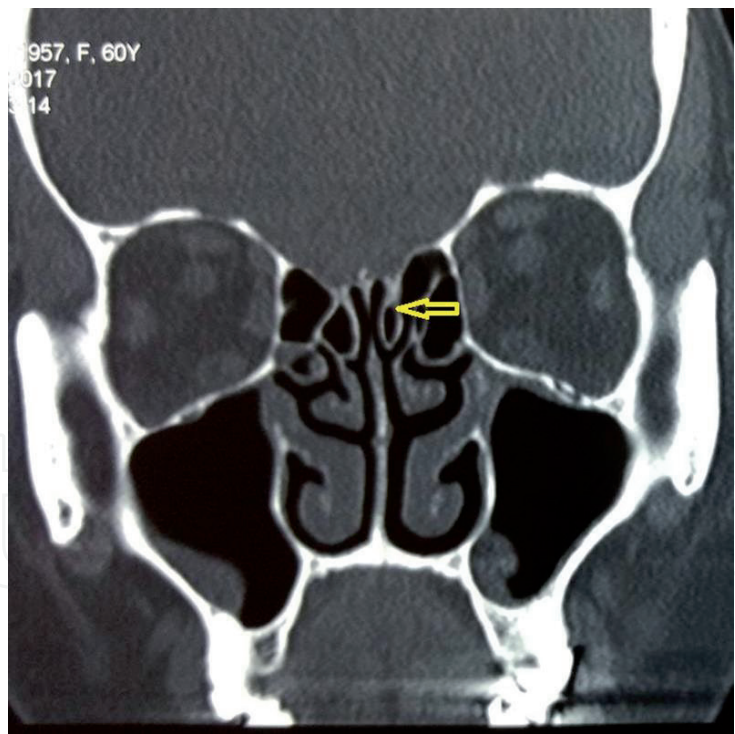


Figure 5.
CT PNS coronal cuts showing pneumatisation of superior turbinate.

- Big agar

Agar cells are usually pneumatised from the frontal recess. Extensively pneumatised agger nasi cells will narrow the frontal sinus drainage pathway leading to frontal sinusitis [13]. Agger nasi cells are closely related to lacrimal sac and are separated from the latter by thin lacrimal bone. This bone may also be naturally dehiscant leading to spread of infection and subsequent dacryocystitis (**Figures 10 and 11**).

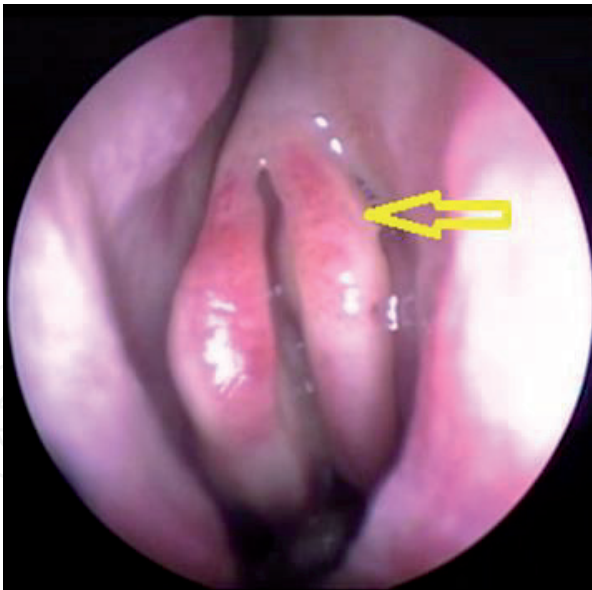


Figure 6.
DNE showing medially bent uncinat process.

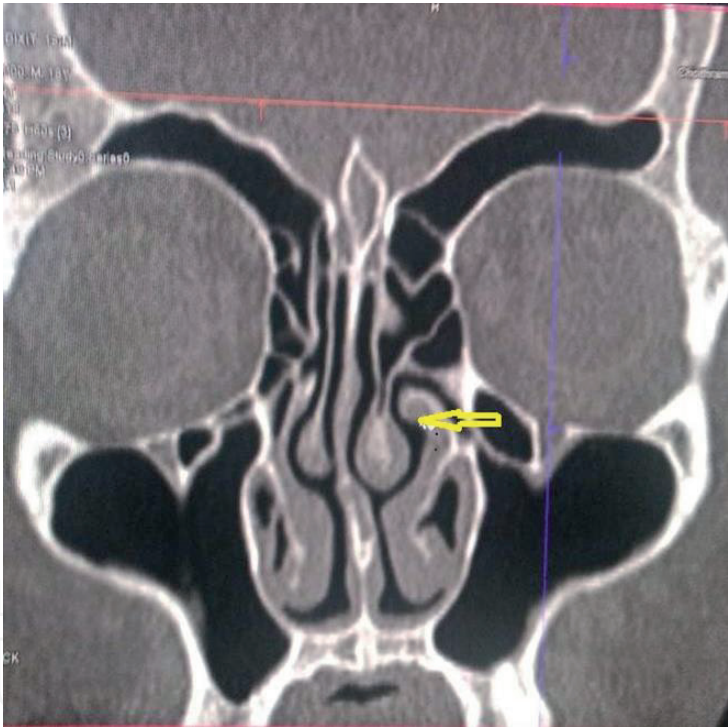


Figure 7.
CT showing thick and medially bent uncinat process.

- Haller cell

The presence of infraorbital ethmoidal cells can obstruct the drainage pathway of the maxillary sinus and also increase the risk of orbital injury during ethmoidectomy (**Figure 12**).

- Onodi cell

It is insinuation of posterior ethmoid air cell between optic nerve and sphenoid sinus. It is associated with increased risk of injury with optic nerve or carotid artery during functional endoscopic sinus surgery (FESS) [14] (**Figure 13**).

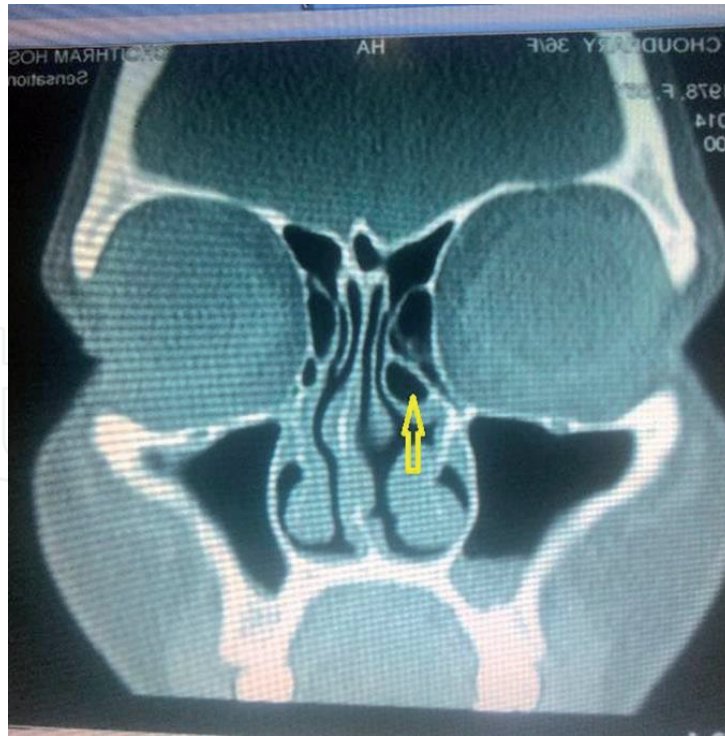


Figure 8.
CT showing pneumatised uncinete process on left side.

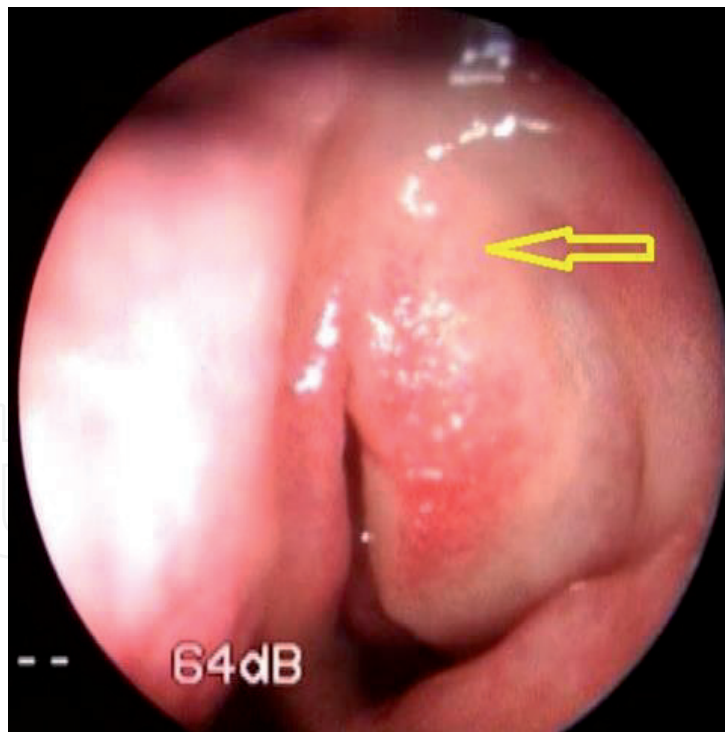


Figure 9.
Endoscopy showing pneumatised uncinete process.

- Accessory ostia

Maxillary sinus drains through the natural ostia and the presence of accessory ostia does not play a role in its physiologic drainage. Rather, it leads to mucous recirculation and CRS [15] (**Figures 14 and 15**).

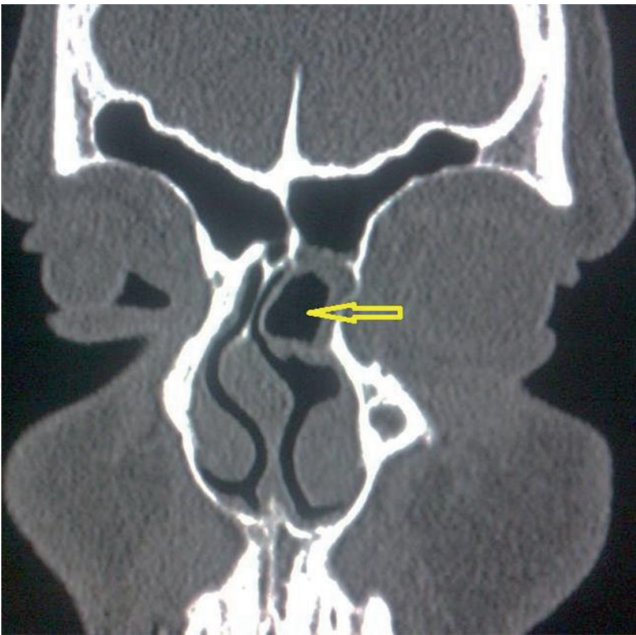


Figure 10.
CT PNS showing big agar on left side. Note that frontal sinuses are still clear.

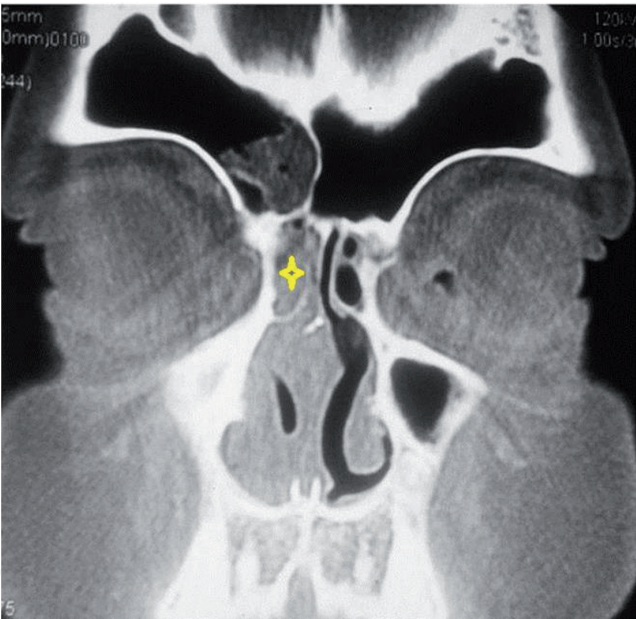


Figure 11.
CT PNS showing infected agar on right side with haziness in right frontal sinus.

- Hypoplasia/agenesis of maxillary sinus

According to Bolger and Parsons, maxillary sinus hypoplasia can be classified into three types:

Type I—There is mild decrease in maxillary sinus volume with normal uncinate and normal ethmoid infundibulum.

Type II—There is mild-to-moderate reduction in volume of maxillary sinus combined with CT evidence of an absent or hypoplastic uncinate process and an absent or poorly defined ethmoid infundibulum due to uncinate process being fused with the inferomedial wall of the orbit.

Type III—Maxillary sinus is primarily absent. Ethmoid infundibulum and uncinate process are absent [16].

In our case, there was type III maxillary sinus hypoplasia (**Figures 16 and 17**).

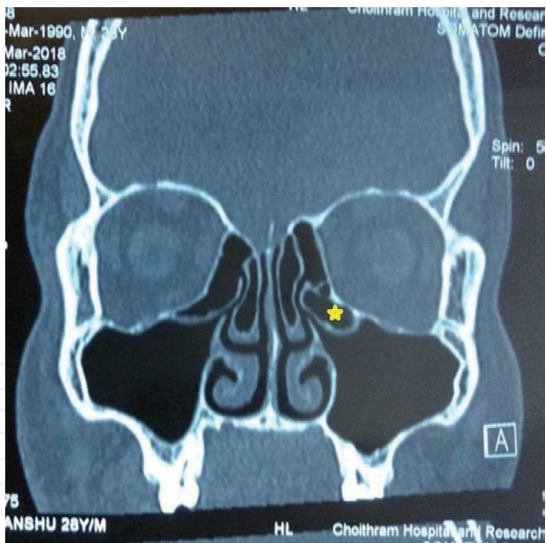


Figure 12.
CT PNS showing Haller cell on left side with narrowing of infundibulum. Sinuses are still clear.

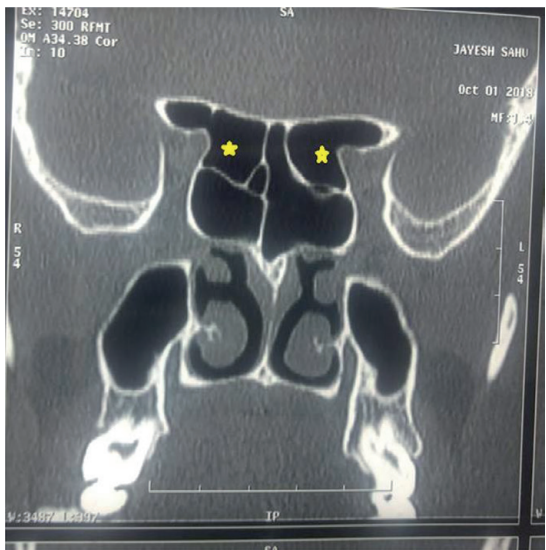


Figure 13.
Coronal section of PNS showing bilateral Onodi cell.

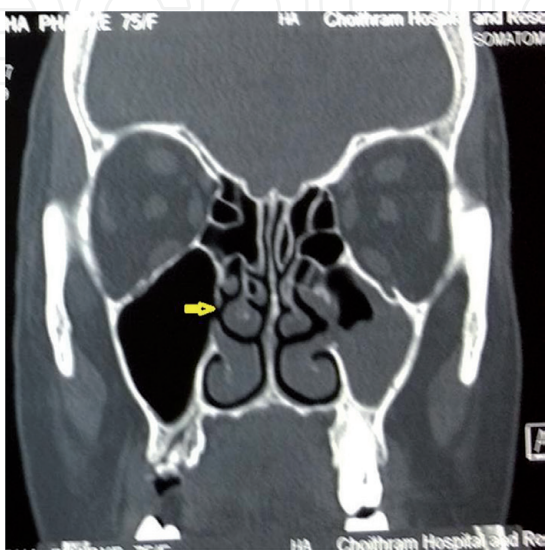


Figure 14.
CT PNS showing accessory ostia on right with clear maxillary. On the contrary, opposite sinus is hazy.

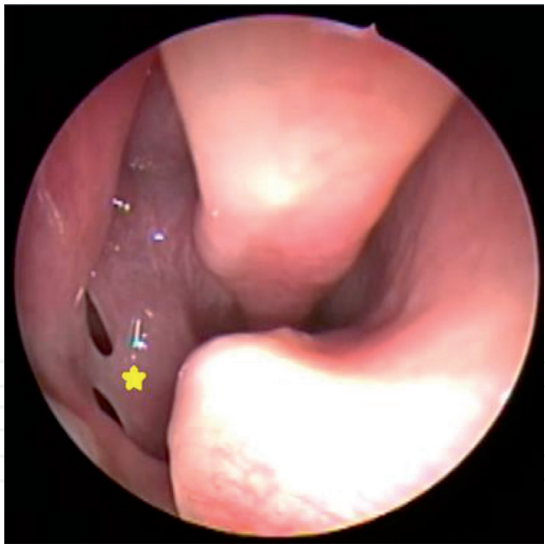


Figure 15.
Endoscopy showing two accessory ostia.

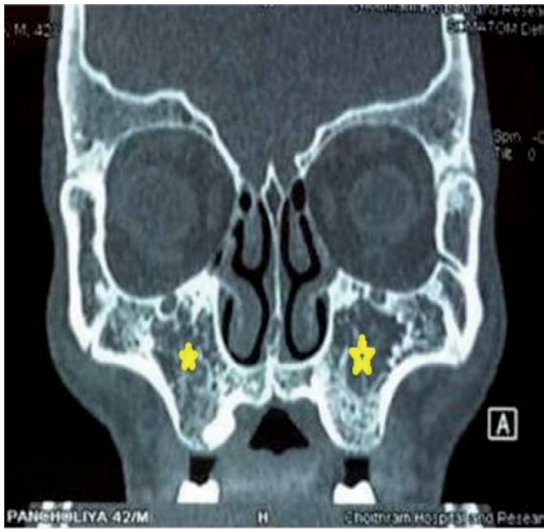


Figure 16.
CT showing hypoplasia of bilateral maxillary sinus.

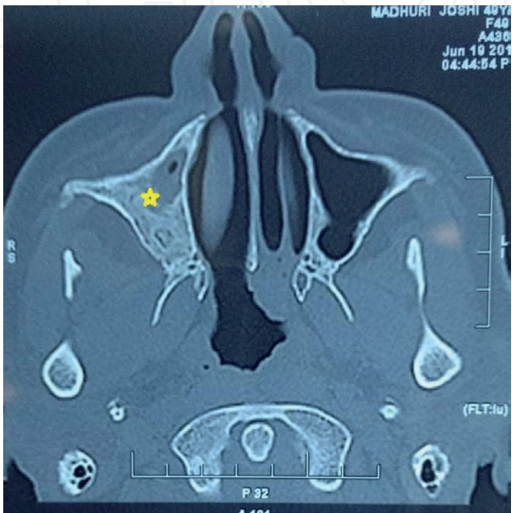


Figure 17.
CT (axial section) agenesis of right maxillary sinus.

- Pneumatisation of septum (**Figure 18**)

The septum may be pneumatised as a result of extension of an aerated crista galli or anterior extension of the sphenoid sinus.

- Persistent adenoids

Adenoids are present at birth and usually regress by 12–14 years of age. With advent of CT PNS, it is now clear that adenoids may persist even after adolescence. In our case, adenoids persisted till 56 years of age; this patient too had presented with CRS (**Figures 19 and 20**).

There is evidence that the adenoid provides a reservoir of bacteria that may be a pathogenic factor in the development of CRS. Biofilms overlying the adenoid pad may prevent antibiotic therapy from clearing the infection. Adenoidectomy surgically removes this reservoir for chronic infection [17].

- KEROS classification (**Figures 21–24**)

Depending upon the depth of olfactory fossa Keros classification is as follows:

KEROS type I—Depth of olfactory fossa is 1–3 mm.

KEROS type II—Depth of olfactory fossa is 4–7 mm.

KEROS type III—Depth of olfactory fossa is 8–14 mm.

Type I is the safest while type III has high chances of skull base injury during ethmoidectomy.

Asymmetry of ethmoid roof on both sides of the same patient is not uncommon. Hence, the surgeon should read CT thoroughly before any surgical intervention.

- Low anterior ethmoidal artery

Anterior ethmoidal artery is an important landmark in sinus surgery. The anterior ethmoidal artery is seen as a classical breaking of the medial orbital wall. The artery may lie close to the skull base or may cross low within anterior ethmoid in which case the orbitocranial canal with its bony mesentery is clearly seen [4] (**Figure 25**). If the anterior ethmoidal notch is abutting the lateral lamella or the fovea ethmoidalis, the artery is considered protected during functional

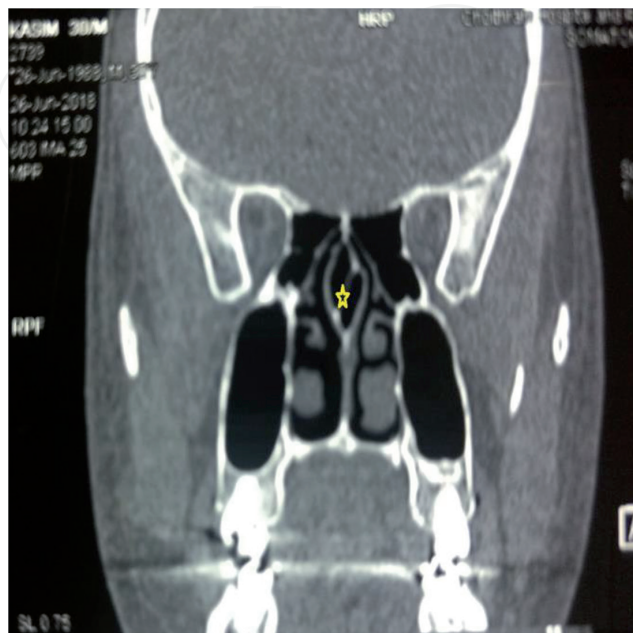


Figure 18.
CT showing septal pneumatisation.

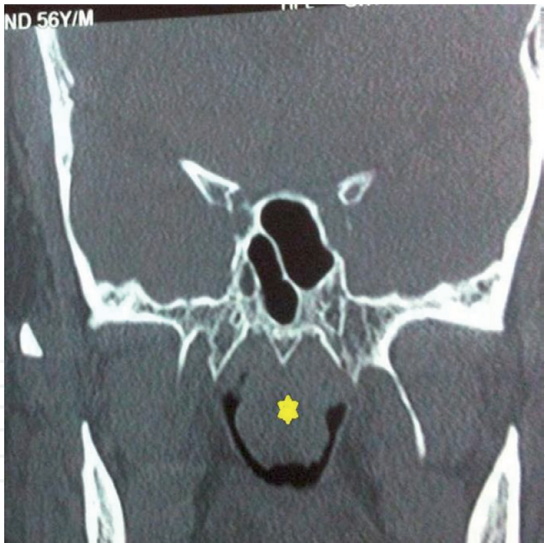

Figure 19.
CT showing persistent adenoids in a 56-year-old patient.

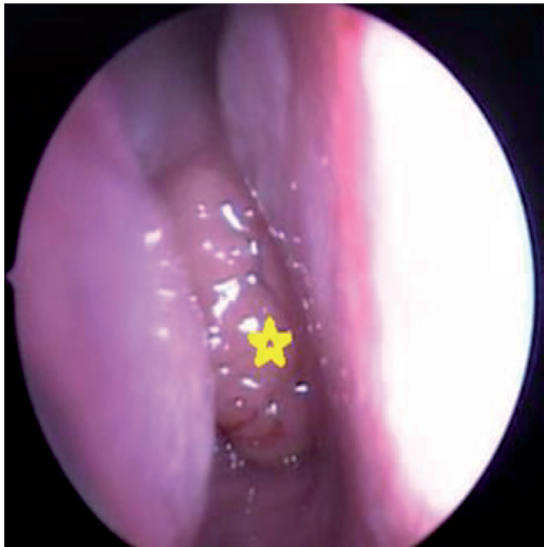

Figure 20.
Endoscopic showing persistent adenoids.

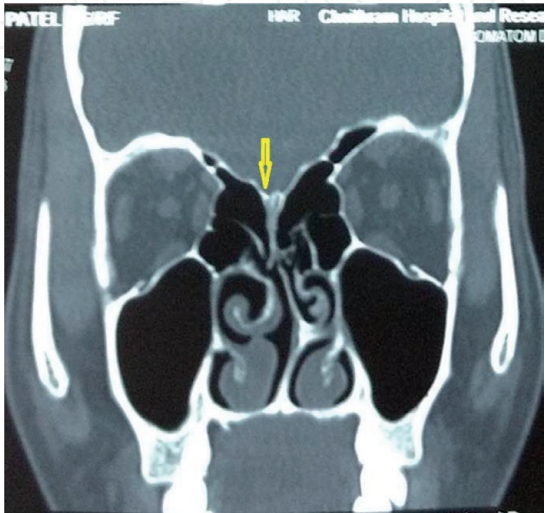


Figure 21.
CT showing KEROS type I.

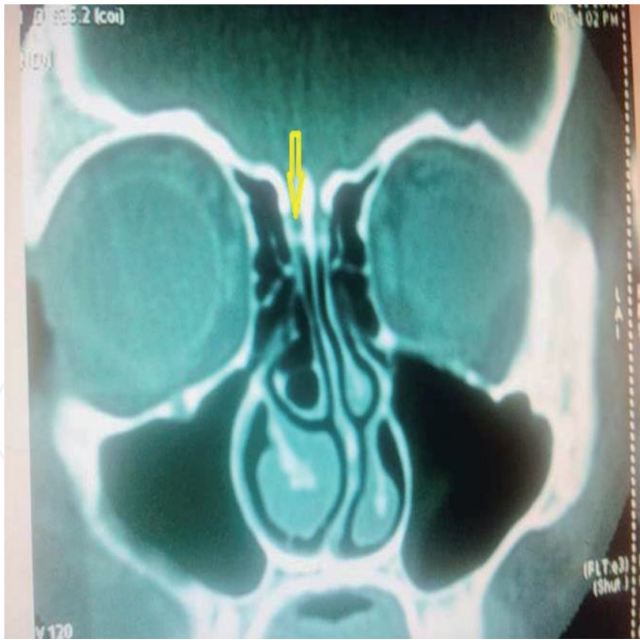


Figure 22.
CT showing Keros type II.

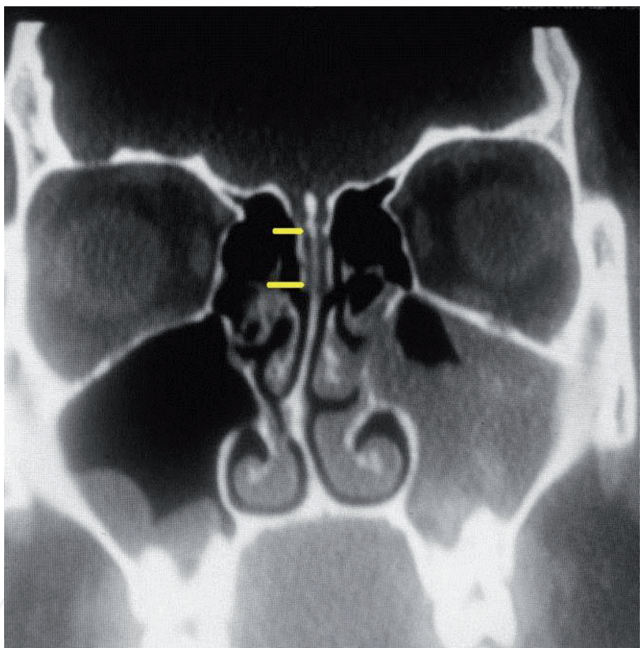


Figure 23.
CT showing Keros type III.

endoscopic sinus surgery as it is at the level of the skull base. If a supraorbital cell is seen above the anterior ethmoidal notch, or if the artery is located below the skull base, it is considered at risk [18, 19].

- Dehiscent lamina papyracea (**Figure 26**)

Natural dehiscence in lamina papyracea will result in prolapse of orbital contents into the nasal cavity. The defects allow easy damage to the orbit during FESS and also increase the risk of orbital contents being drawn into the microdebrider.

The incidence of anatomical variations responsible for CRS in decreasing order of their frequency is as follows:

Deviated nasal septum—the commonest anatomical variation with 69% incidence.

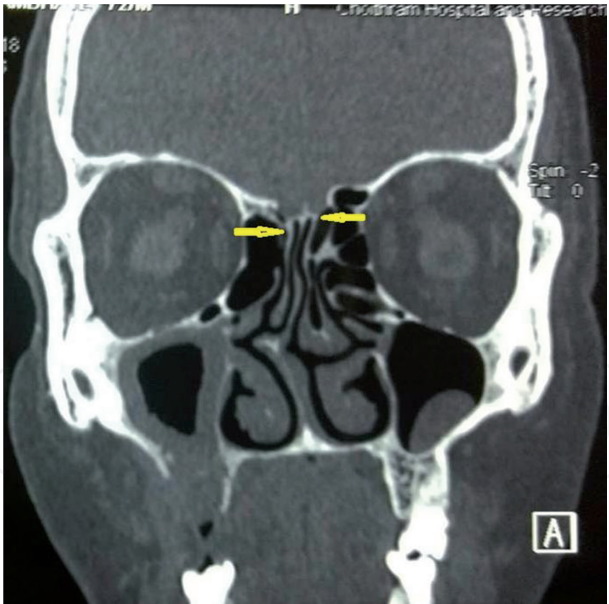


Figure 24.
CT showing asymmetrical ethmoidal roof.

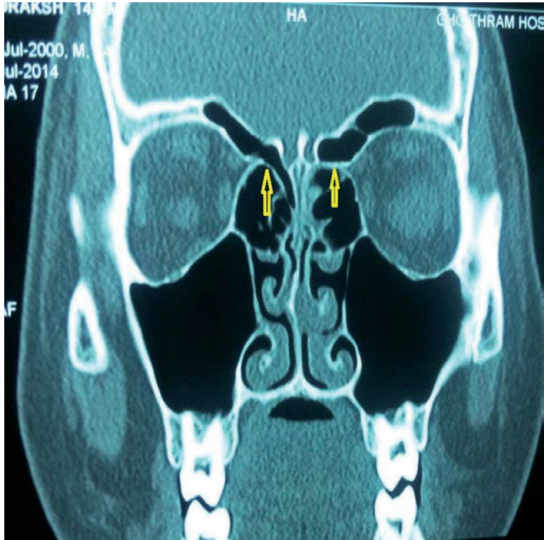


Figure 25.
CT showing low bilateral low anterior ethmoidal artery.

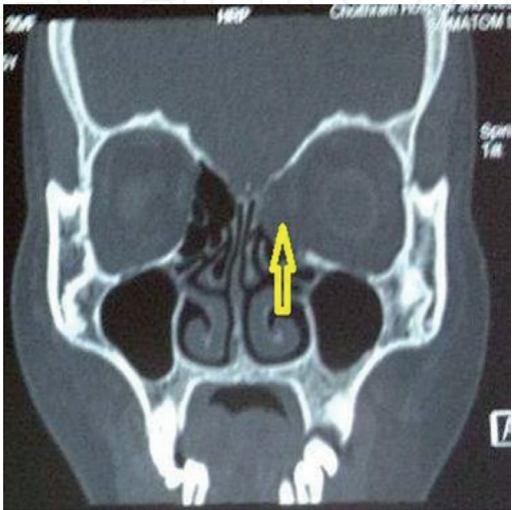


Figure 26.
CT PNS (coronal view) showing dehiscence lamina with fat prolapse on left side.

Concha—24%.
Unilateral concha was seen in 13%, while bilateral concha was seen in 11% cases.
Big agar—12%.
Pneumatised or medially bent uncinata—8%.
Accessory ostia—6%.
Septal pneumatization—5%.
Onodi cell—4%.
Haller cell—3%.
Hypoplasia of maxillary sinus with dehiscent lamina was seen in less than 2% of cases.

3. Conclusion

The presence of anatomical variations in nose and sinuses is frequently seen on imaging in patients with CRS. It is observed that the presence of more than one variation increases the probability of sinus infections. However, it is not the rule as there can be clear sinuses even with multiple anatomical variations.

Acknowledgements

Dr. Sunil Chandiwal. Director Medical Services. Choithram Hospital & Research Centre. Indore, India. Source of funding: None.

Conflict of interest

None.

Appendices and nomenclature


OMC	osteomeatal complex
PNS	paranasal sinuses
DNE	diagnostic nasal endoscopy
CRS	chronic rhinosinusitis
FESS	functional endoscopic sinus surgery

Author details

Shrikant Phatak* and Richa Agrawal
Department of ENT, Choithram Hospital and Research Centre, Indore, India

*Address all correspondence to: phatakshrikant2@gmail.com

IntechOpen

© 2019 The Author(s). Licensee IntechOpen. This chapter is distributed under the terms of the Creative Commons Attribution License (<http://creativecommons.org/licenses/by/3.0>), which permits unrestricted use, distribution, and reproduction in any medium, provided the original work is properly cited. 

References

- [1] Shankar L, Evans K. An Atlas of Imaging of the Paranasal Sinuses. 2nd ed. Lippincott Williams & Wilkins; 2009. p. 28
- [2] Kirtane MV, de Souza CE. Rhinology and Endoscopic Skull Base Surgery. Thieme; 2013. p. 8
- [3] Mclay K, Maran AGD, Dale BAB, Cowan DL, Kerr AIG. Logan Turner's. Diseases of the Nose, Throat and Ear. 9th ed. John Wright & Sons; 1982. pp. 9-11
- [4] Bradoo R. Anatomical Principal of Endoscopic Sinus Surgery: A Step by Step Approach. 1st ed. Jaypee Brothers Medical Publishers; 2016. p.78
- [5] Dhingra PL, Dhingra S. Disease of Ear, Nose and Throat & Head and Neck Surgery. 6th ed. Elsevier; 2014. pp. 140-141
- [6] Hasan OA, Hassan MA, Fawzy EK, Maarouf AM. Anatomical variations of nasal structures in chronic rhinosinusitis as detected by computed tomography scan. The Egyptian Journal of Hospital Medicine. 2017;**68**(3):1390-1394
- [7] Kantarci M, Karasen RM, Alper F, et al. Remarkable anatomic variations in paranasal sinus region and their clinical importance. European Journal of Radiology. 2004;**50**:296-302
- [8] Beale TJ, Madani G, Morley SJ. Imaging of the paranasal sinuses and nasal cavity: Normal anatomy and clinically relevant anatomical variants. Seminars in Ultrasound, CT, and MR. 2009;**30**:2-16
- [9] Azila A, Irfan M, Rohaizan Y, et al. The prevalence of anatomical variations in osteomeatal unit in patients with chronic rhinosinusitis. The Medical Journal of Malaysia. 2011;**66**:191-194
- [10] Fadda GL, Rosso S, Aversa S, et al. Multiparametric statistical correlations between paranasal sinus anatomic variations and chronic rhinosinusitis. Acta Otorhinolaryngologica Italica. 2012;**32**:244-251
- [11] Nouraei SA, Elisay AR, Dimarco A, et al. Variations in paranasal sinus anatomy: Implications for the pathophysiology of chronic rhinosinusitis and safety of endoscopic sinus surgery. Journal of Otolaryngology—Head & Neck Surgery. 2009;**38**:32-37
- [12] Polavaram R, Devaiah AK, Sakai O, Shapshay SM. Anatomic variants and pearls-functional endoscopic sinus surgery. Otolaryngologic Clinics of North America. 2004;**37**:221-242
- [13] Brunner E, Jacobs JB, Shpizner BA, Lebowitz RA, Holliday RA. Role of agar nasi cell in chronic frontal sinusitis. The Annals of Otology, Rhinology, and Laryngology. 1996;**105**(5):694-700
- [14] Tomovic S, Esmaeili A, Chan NJ, et al. High-resolution computed tomography analysis of the prevalence of Onodi cells. Laryngoscope. 2012;**122**:1470-1473
- [15] Yanagisawa E, Yanagisawa K. Endoscopic view of recirculation phenomenon of the maxillary sinus. Ear, Nose, & Throat Journal. 1997;**76**:196-198
- [16] Bolger WE, Butzin CA, Parsons DS. Paranasal sinus bony anatomic variation and mucosal abnormalities: CT analysis for endoscopic sinus surgery. Laryngoscope. 1991;**101**:56-64
- [17] Arthur WW, Shapiro NL, Bhattacharya N. Chronic rhinosinusitis in children: What are treatment options? Immunology and Allergy Clinics of North America. 2009;**29**(4):705-717
- [18] Kirtane MV. Endoscopic Endonasal Surgery: Sinuses and Beyond. 1st ed. Jaypee Brothers Medical Publishers. 2015. p. 9
- [19] Simmen D, Raghavan U, Briner HR, et al. The surgeon's view of the anterior ethmoid artery. Clinical Otolaryngology. 2006;**31**(3):187-191