

# We are IntechOpen, the world's leading publisher of Open Access books Built by scientists, for scientists

6,900

Open access books available

186,000

International authors and editors

200M

Downloads

Our authors are among the

154

Countries delivered to

TOP 1%

most cited scientists

12.2%

Contributors from top 500 universities



WEB OF SCIENCE™

Selection of our books indexed in the Book Citation Index  
in Web of Science™ Core Collection (BKCI)

Interested in publishing with us?  
Contact [book.department@intechopen.com](mailto:book.department@intechopen.com)

Numbers displayed above are based on latest data collected.  
For more information visit [www.intechopen.com](http://www.intechopen.com)



# Preoperative Assessment of Functioning Benign Adrenocortical Tumors: A Clinical Surgical Approach

*Bruno Costa do Prado, Alana Rocha Puppim,  
Jose Tadeu Carvalho Martins, Fabiana Lima Marques,  
Robson Dettman Jarske  
and Octavio Meneghelli Galvão Gonçalves*

## Abstract

In assisting a patient with adrenocortical tumors, the main concern is to establish whether the lesion consists of a malignant neoplasm and if there is any hormonal functioning, which are two instances that generally demand surgery. In distinguishing benign from malignant lesions, two aspects are particularly important: the size of the lesion and the image findings. In order to establish whether a lesion is hormonally functioning, it is necessary to carry out thorough clinical and endocrine assessments. The extension of such assessments is still controversial. This present chapter revises fundamental aspects of the propaedeutic of such tumors. Most guidelines agree that lesions smaller than 1 cm need not be investigated. The diagnostic and therapeutic approach of adrenocortical tumors imposes a difficult and challenging dilemma in terms of its approach, as it may be a benign finding or it may imply a high level of morbidity and mortality due to its hormonal activity or a possible malignant histology.

**Keywords:** adrenocortical tumors, adenoma, adrenal, Cushing's syndrome, aldosteronoma

## 1. Introduction

Adrenal gland tumors are common entities in clinical practice. They are divided as functioning (which produces hormones) and the nonfunctioning ones (also known as silent). In terms of their biological behavior, they may be divided in benign or malignant tumors. The term “incidentaloma” refers to adrenal masses that are found in image exams aiming at investigating disturbances unrelated to the adrenal glands [1–3].

Most adrenocortical tumors are benign, unilateral, nonfunctioning adenomas with less than 4 cm in diameter that are found during abdominal image studies [3]. The functioning adrenal tumors are generally the benign adenoma type, which

cause, for instance, the Cushing's syndrome, primary aldosteronism, or, not so commonly, virilization [1, 2].

This present chapter discusses the preoperative assessment of patients suffering from this condition. It mainly focuses on:

1. Whether there is hormonal production by the tumor and the controlling techniques
2. The malignancy risk and the staging for propaedeutic planning purposes

## **2. Epidemiology**

The frequency of adrenocortical tumor diagnosis has increased nowadays due to larger availability of image examination techniques, which makes it a relatively common clinical problem currently. Some studies claim a detection rate of 4% in all abdominal computer tomography [4]. Studies in series of autopsies identified that adrenal masses count less than 1% in individuals younger than 30 years of age and that the rate increases to 7% in those who were 70 or older [1, 2].

Adrenocortical tumors are more common in white, obese, diabetic, and hypertensive individuals. These data might be biased, as elderly, white individuals constitute the groups that most frequently undergo image examinations. It is known that such tumors are rather uncommon in individuals under 50 years of age and are especially uncommon in children [2]. They are more common on the right side [2, 3].

In terms of hormonal production, even though most tumors are nonfunctioning, in up to 15% of cases, there might be a slightly increased production of certain hormones, being cortisol the most common one, which may cause Cushing's syndrome [1].

Around 10–15% of all tumors found are bilateral [2]. Bilateral functioning adrenocortical masses may be congenital adrenal hyperplasia due to a 21-hydroxylase deficiency, adrenal macronodular hyperplasia, or primary hyperaldosteronism [2].

The most common causes of bilateral nonfunctioning adrenal masses are metastases, infections (mycosis, tuberculosis), lymphomas, bleedings, amyloidosis, and, rather rarely, carcinoma and myelolipomas [1].

In a decreasing order of occurrence, the adrenocortical tumor categories are:

1. Nonfunctioning adenomas (43–75%)
2. Cortisol-producing adenomas (including subclinical Cushing's syndrome) (10–15%)
3. Myelolipomas (6–8%)
4. Adrenal carcinomas (4–11%)
5. Metastatic lesions (3–10%)
6. Aldosteronomas (2–6%)
7. Cyst (5%)
8. Tuberculosis and lymphomas (3–8%)

### 3. Natural history

Natural history of adrenocortical tumors is still not completely known [1]. Some studies suggest that most incidentalomas remain within stable size for many years [2]. Long-term follow-up studies suggest that from 5 to 20% of cases involving tumors larger than 1 cm, there is an increase in adrenal mass after an average period of 4 years, regardless of the state of adrenal hormonal production [1]. The typical increase rate of an adrenocortical carcinoma exceeds 2 cm per year, with a survival expectation lower than 50% within 5 years [1, 2].

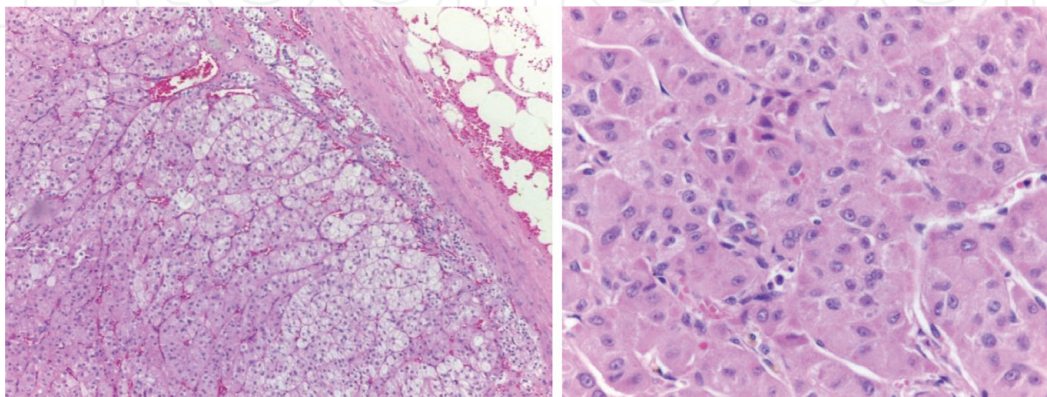
Occasionally, tumor reduction might be observed (3–4% of cases). Appearance of mass at the contralateral gland might also be noticed. Nonetheless, the risk of malignancy development is low ( $<1/1000$ ) [1].

There is a risk that a nonfunctioning adenoma starts to produce some hormone during follow-up, especially if the mass is larger than 3 cm and mainly in the case of cortisol production. Prospective studies show a 0.3% risk of a subclinical Cushing's syndrome development and a 0.2% chance of it turning into a pheochromocytoma. After a 3- to 4-year follow-up, such risk reaches a plateau that is to say the possibility that it would turn into a functioning one is low. Therefore, repetition of screening for functioning is only prescribed during the first 5 years of follow-up [2].

For the reasons explained here, rather small nodules (smaller than 1 cm) with a benign tomographic aspect need not be further investigated by image, as the benignity chance is high, whereas the risk of growth is low [2].

### 4. Pathological findings

Adrenal adenomas are generally encapsulated, have variable volume and weight, and in most cases have a diameter of 2–4 cm. In nonfunctioning tumors, clear cells of the fasciculate zone, filled with lipids (cholesterol), predominate microscopically, which gives the yellowish coloration. Functioning tumors are usually of varied colors, reddish-brown, with yellowish areas or striae, showing in microscopy the predominance of compact cells, associated with clear cell nests (**Figure 1**). Cortisol-producing adenomas are accompanied by hypotrophy of the adrenal cortex of the affected gland and the contralateral adrenal gland due to adrenocorticotrophic hormone (ACTH) (suppression in contrast to aldosterone-producing adenomas in which this aspect is not observed) [3].



**Figure 1.**

Microscopy of an adrenal cortex adenoma showing one or more cell types (A) separated from each other by fibrous septa containing blood vessels (H&E 100 $\times$ ). High increase showing cells in the zona glomerulosa, fasciculate zone, and reticular zone forming nests and strands (H&E 400 $\times$ ).



Adrenal carcinomas are usually larger than 4 cm and occasionally weigh more than 1 kg. Microscopically, the picture is varied: in some cases, the tumor is very similar to the adenoma, but in some cases, the tumor appears anaplastically, being composed of cells with large pleomorphism, bizarre nuclei, and atypical mitoses. Vascular or capsular invasion is a predictive sign of malignant behavior, being a sign of local extension [3, 4].

Differentiation with adenomas can be difficult and is based on macroscopic (tumor weight, hemorrhage, and capsule integrity) and microscopic aspects using the modified Weiss scoring system. The five criteria used in the updated Weiss system include >6 mitoses/50 high potency fields,  $\leq 25\%$  clear tumor cells in the cytoplasm, abnormal mitoses, necrosis, and capsular invasion. Each criterion is scored 0 when absent or 2 for the first two criteria and 1 for the last three when present. The adrenal carcinoma can be diagnosed by the presence of a total score  $\geq 3$  [5].

Tumors are functioning in approximately 60% of all cases, but the presence of symptoms of hormonal hypersecretion is present in only 40%, possibly by the secretion of large quantities of biologically inactive hormones [5, 6].

In general, adrenal carcinomas rarely produce and secrete a single steroid hormone and are usually associated with overproduction and hypersecretion of multiple hormones and precursors. Most cases produce different types of steroid hormones [7–9]. Thus, hypersecretion of a single adrenocortical steroid usually indicates the benign nature of adrenocortical neoplasia. The most frequently seen combination is hypersecretion of cortisol and androgens [10].

## 5. Hormone assessment

There are basically three types of production by adrenocortical tumors:

1. Cortisol (corresponding to between 5 and 20% of cases)
2. Aldosterone (corresponding to 1% of cases)
3. Androgen (extremely rare)

### 5.1 Cortisol-producing tumors

Such tumors generally produce minute quantities of cortisol, which, most of times, do not suffice to increase the excretion of free cortisol in urine. They are, nonetheless, able to cause suppression of the hypothalamic-pituitary axis. Ordinarily, there are no Cushing-related manifestations in those patients. For that reason, this condition has been known as subclinical Cushing's syndrome or subclinical hypercortisolism [11]. There might be the classic Cushing's syndrome in long-evolving cases.

A suppression test with 1 mg of dexamethasone should be carried out at night for tracking Cushing's syndrome. The patient orally takes 1 mg of dexamethasone at 11:00 pm the night prior to sample collection of plasmatic cortisol, which is to be carried out at 8:00 am the following morning. Values that determine abnormal response of cortisol in this test varied in several studies from 1.8 to 5.0 mcg/dL, yet most guidelines lead to the following interpretation:

Levels of plasmatic cortisol  $< 1.8$  mcg/dL virtually exclude autonomous production of cortisol, with sensitivity  $> 95\%$  and specificity from 70 to 80%.

Cortisol levels between 1.8 and 5 mcg/dL have been considered to be undetermined.

Values >5 mcg/dL would indicate a highly probable diagnosis of Cushing's syndrome (specificity > 95%) [1].

An abnormal suppression of 1 mg of dexamethasone during the night is consistent with a positive tracking, and it should be confirmed by a 24-hour free urinary cortisol, which should then be followed by an investigation of the serum dosage of cortisol after a high dose (8 mg) of dexamethasone during the night and the serum dosage ACTH [3, 4]. This latter investigation aims at determining the origin of the Cushing's syndrome, as to refute a hypopituitary cause. This condition is typically presented with unsuppressed levels (ACTH dependent). For diagnosis of subclinical Cushing's syndrome, many experts propose confirmation under the following criteria:

Values > 5 mcg/dL in plasmatic cortisol at the 1 mg dexamethasone test without any other stigma

**OR**

At least two from the following results:

Levels of plasmatic ACTH < 10 pg/ml with an increased 24-hour free urinary cortisol and values > 3 mcg/dL of plasmatic cortisol at the 1 mg dexamethasone test [1]. **Figure 2** shows an algorithm of investigation of Cushing's syndrome.

Dehydroepiandrosterone sulfate is an adrenal androgen that is produced under stimulus of ACTH. Thus, an undetectable concentration of dehydroepiandrosterone sulfate in serum suggests a chronical suppression of ACTH levels [12].

Percentage of patients suffering from subclinical Cushing's syndrome that would evolve to the classic Cushing's syndrome is uncertain. It is estimated to be <1%, though [1].

Even though patients suffering from subclinical Cushing's syndrome do not present the classic stigmata related to hypercortisolism, they present, as suggested in some studies, in comparison with the population in general, higher occurrences of:

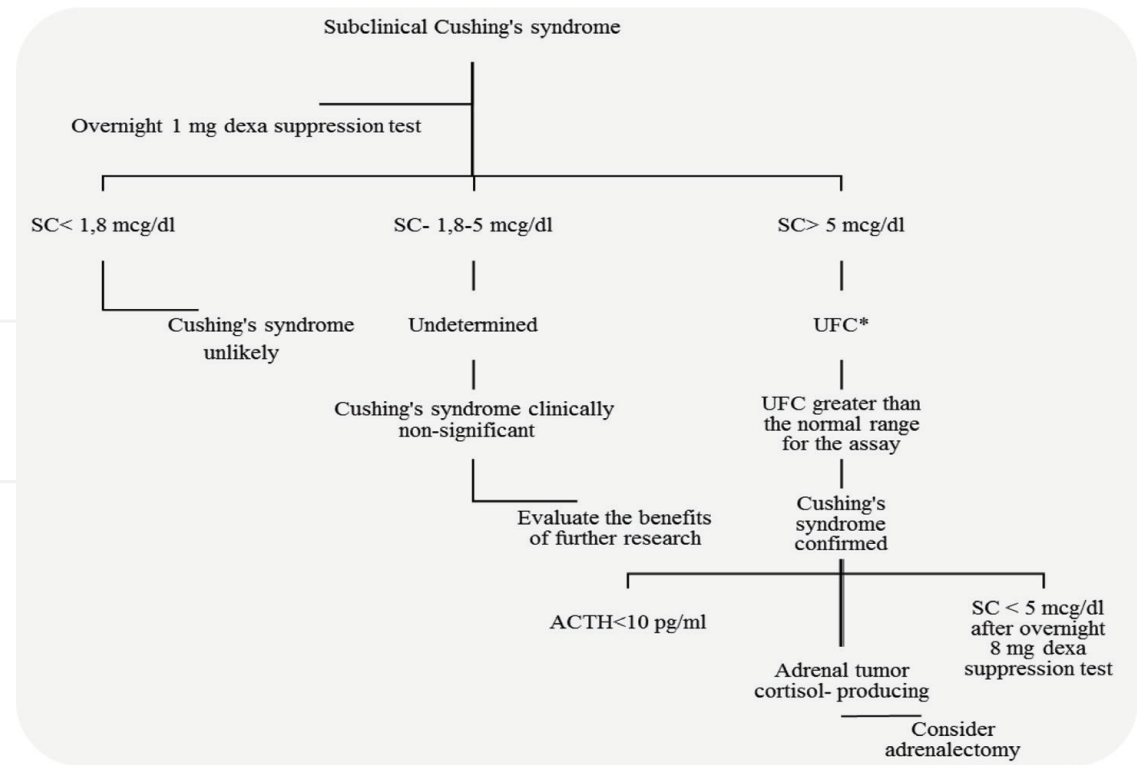
- Hypertension (40–90%)
- Type 2 diabetes mellitus or glucose intolerance (20–75%)
- Osteopenia/osteoporosis (40–50%)
- Hyperlipidemia (50%)
- Obesity (35–50%)

An increase in the carotid intima-media thickness has been recently reported, as well as alteration of coagulation parameters, decrease in the quality of life, and occurrences of mortality due to cardiovascular disease [1].

For those reasons, there is still no consensus about the approach to subclinical Cushing's syndrome. It may be treated clinically or through surgery [2].

Generally, in cases with many occurrences of comorbidity that might be attributed to hypercortisolism, such as systemic arterial hypertension, diabetes mellitus, dyslipidemia, osteoporosis, and central obesity, especially the ones that are difficult to control, a ponderation of the risk/benefit of surgical treatment by adrenalectomy of the affected adrenal should be carried out, as proposed for the treatment of classic Cushing's syndrome [2].

It is important to mention that up to 75% of patients might develop acute adrenal insufficiency (sometimes deadly) at the post-surgery phase of adrenalectomy in case they are not treated with glucocorticoid due to atrophy of the contralateral gland. This should be an additional functional endocrine characterization for the propaedeutic planning [1]. In case the adrenalectomy is carried out, there should be



**Figure 2.**  
An algorithm for investigation of Cushing's syndrome in adrenal incidentalomas. Dexamethasone; SC, serum cortisol; UFC, urine-free cortisol; ACTH, adrenocorticotropic hormone. \*At least two measurements.

a perioperative coverage of glucocorticoid due to the risk of adrenal insufficiency, hemodynamic crisis, and death [12].

Weight loss, improvement of hypertension, glycemic control, and normalization of bone renewal markers are frequently found in the post unilateral adrenalectomy scenario of patients with subclinical or classic Cushing's syndrome [12].

5.2 Aldosterone-producing tumors

Also known as aldosteronomas, they are rare (less than 1% of cases), and their characteristic manifestation is systemic arterial hypertension associated with hypokalemia. Yet primary normocalcemic hyperaldosteronism is common (20–50% of cases) [1, 12]. For that reason, as most patients suffering from primary aldosteronism do not suffer from hypocalcemia, all patients suffering from hypertension and adrenal incidentaloma should be assessed through measurements of their aldosterone plasmatic concentration and plasma renin activity [12].

Initial endocrine investigation in such cases consists of dosing the levels of plasma aldosterone and plasma renin activity. In case the ratio between them is <27, the existence of hyperaldosteronism is virtually excluded. Other authors use further landmarks (between 20 and 30) to establish diagnosis as abnormal. Values >40–50 are almost hyperaldosteronism pathognomonic [1].

It is important to mention that if the laboratory can only assess the renin direct dosage (other than the plasma renin activity), the renin value must be divided by 12, so that the actual value of plasma renin activity is established, which will eventually be the one used for the ratio calculation. If the ratio is lower than 20, it can refute diagnosis. In case it is between 20 and 30, it indicates a likely diagnosis. Then, if it exceeds 30, with aldosterone dosage higher than 15 ng/dl, positive tracing should be considered and investigation should continue through tests for confirmation [2]. In patients with spontaneous hypokalemia, plasma renin below detection

levels plus plasma aldosterone >20 ng/dL, it is suggested that there is no need for further confirmatory testing (**Figure 3**) [4].

The aldosterone and plasma renin activity relationship should never be used for patients under spironolactone, and in case doubtful results appear, other medications (a beta blocker, central alpha-adrenergic agonist, anti-inflammatory) that might cause a false increase of that relationship should ideally be suspended, as well as those drugs that cause a false reduction of the inhibitors of angiotensin-converting enzyme, aldosterone receptor blocker, thiazide, and dihydropyridine inhibitors of the calcium channel [2].

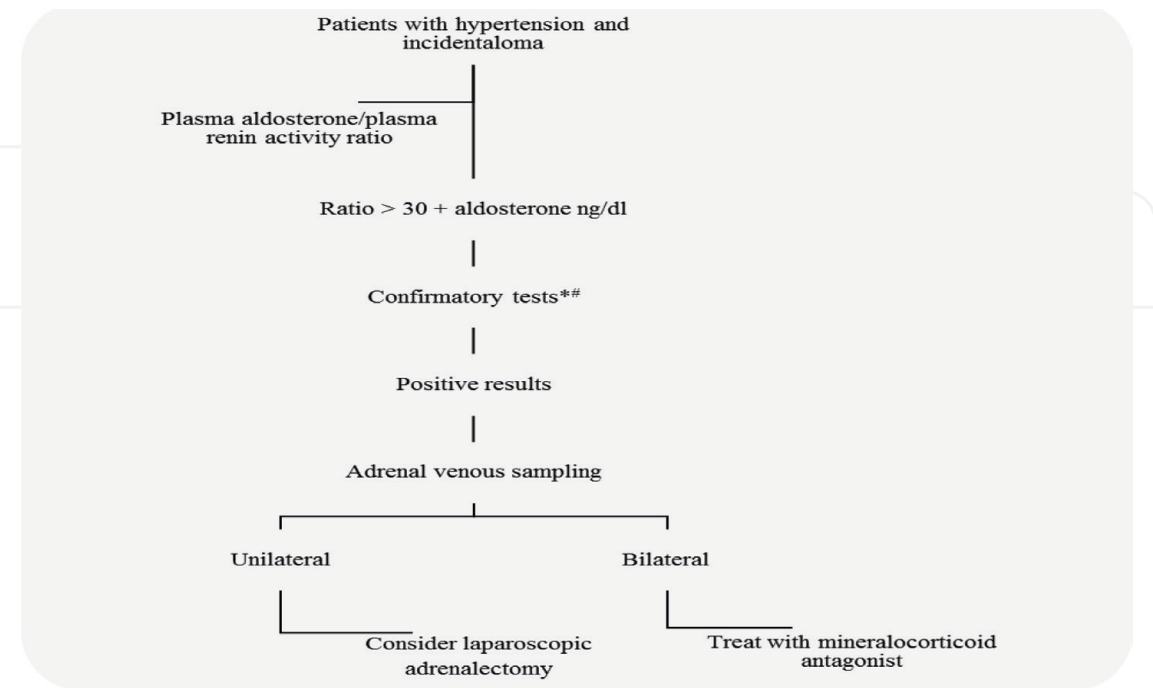
Patients older than 40 years of age suffering from confirmed hyperaldosteronism, even with evidence of adrenal images compatible with such diagnosis, should be submitted to adrenal catheterization for assessment of whether that increased aldosterone production is really due to incidentaloma or to adrenal hyperplasia, whereas the occurrence of nonfunctioning incidentalomas in the population older than 40 is no longer negligible (around 4%).

In such cases, adrenalectomy would not solve hormonal hyperproduction, which should be kept under control with the use of medication, aldosterone antagonists, such as spironolactone [2].

### 5.3 Androgen- and estrogen-producing tumors

In cases of congenital adrenal hyperplasia due to a 21-hydroxylase deficiency, it is rather common to find adrenal masses, either uni- or bilateral ones, presumably due to excessive chronic stimulation of adrenals by ACTH [1].

Sex-hormone-producing adrenal adenomas are very rare. Androgen-producing carcinomas are also uncommon. Nevertheless, patients generally manifest some virilization, which makes it unlikely for such tumors to be related to adrenal incidentalomas. Thus, the routine testosterone and estradiol dosage are not recommended for patients with adrenocortical incidentalomas who present trace of



**Figure 3.** Algorithm for investigation of hyperaldosteronism in adrenal incidentalomas. \*Most commonly used confirmatory tests: oral sodium loading test and intravenous saline infusion test. #In patients with spontaneous hypokalemia, plasma renin below detection levels plus plasma aldosterone > 20 ng/dl, it is suggested that there is no need for further confirmatory testing.



virilization [1]. For individuals that present such virilization or high concentrations of androgens, adrenalectomy may be indicated for controlling of hormones.

Estrogen-producing tumors are rare and they are generally malignant. In men, it may manifest through feminization with gynecomastia, decrease in libido, atrophy of testicles, whereas in women, it could manifest through breast sensitivity and bleedings [12]. In such cases, adrenalectomy may also be indicated.

## **6. Adrenal image**

As previously mentioned, most adrenocortical tumors are benign, nonfunctioning adenomas that were incidentally found in abdominal image examinations such as computed tomography and abdomen magnetic resonance imaging.

Adrenal incidentalomas rarely have a malign cause in patients with no known record of cancer. It is estimated that only 2–5% of incidentalomas are formed by adrenal adenocarcinomas, and around 0.7–2.5% of cases are caused by metastasis from tumors elsewhere toward the adrenal [13, 14].

Size and some other radiology characteristics of the computed tomography and magnetic resonance imaging might help differentiating an adrenal benign lesion from a malign one, with consequent perioperative implications. Adrenal tumors with surgical indication are generally approached through laparoscopy. On the other hand, in cases when an adrenal adenocarcinoma is suspected, open surgery is preferable, especially for larger lesions (>10 cm), or for those that might expand to other organs [15].

There is a direct relationship between the size of the adrenal tumor and the potential for malignancy. Average size of an adrenal adenocarcinoma at diagnosis is 10–11 cm, whereas most benign adrenal tumors present a diameter smaller than 5 cm [16].

Besides their larger size, malign adrenal tumors, in most cases, show on image exams as heterogeneous lesions, with irregular margins, suggestive calcifications, and a peripheral enhancement by intravenous contrast due to the core of the necrosis. Expansion toward other organs and lymph node involvement confirm malignancy.

Adrenal adenomas feature a profuse presence of lipids in their constitution. It is, therefore, very useful to assess the lipid contents by means of density calculation for differentiating adrenal tumors [15].

### **6.1 Computed tomography**

The computed tomography is a very important exam in assessing adrenal tumors. At the phase with no contrast, a density calculus is used by means of the Hounsfield units (UH). Lesions with a <10 UH density have a high probability of being benign, whereas most adrenal adenocarcinomas present a >30 UH, which indicates low lipid content. Thus, tumors with density >10 UH demand further assessment.

Precision of diagnosis may be enhanced by the use of late stages of computed tomography with contrast and the “washout” calculation, which represents the fraction of contrast that is eliminated 10 min after administration. The finding of an average absolute “washout” of 50% after 10 min of contrast used in studies evidenced a 100% sensitivity and specificity for detection of adenomas in relation to adenocarcinomas, pheochromocytoma, and extra-adrenal metastases [17, 18].

All patients likely to be suffering from an adrenal adenocarcinoma should undergo a computed tomography of the thorax prior to surgery as any findings related to metastasis may alter the approach of treatment.

## 6.2 Magnetic resonance imaging

Despite the fact that the computed tomography is the most important exam in assessing adrenal nodules, in some situations it is imperative to resort to a magnetic resonance imaging.

Analysis of conventional images weighted at T1 and T2 is the most frequently used technique. Adrenal adenocarcinomas present an isointense sign in relation to the T1 liver and enhanced intensity of sign at weighted sequences at T2 (**Figure 4**). Typically, they present as large lesions (>5.0 cm) at the moment of the diagnosis and may include necrosis, bleeding, and, frequently, calcification [19].

After administration of gadolinium, a slight increase of sign is noticed, as well as a swift washout of contrast, whereas malign lesions present a fast and striking increase of sign followed by a rather slow washout pattern [20].

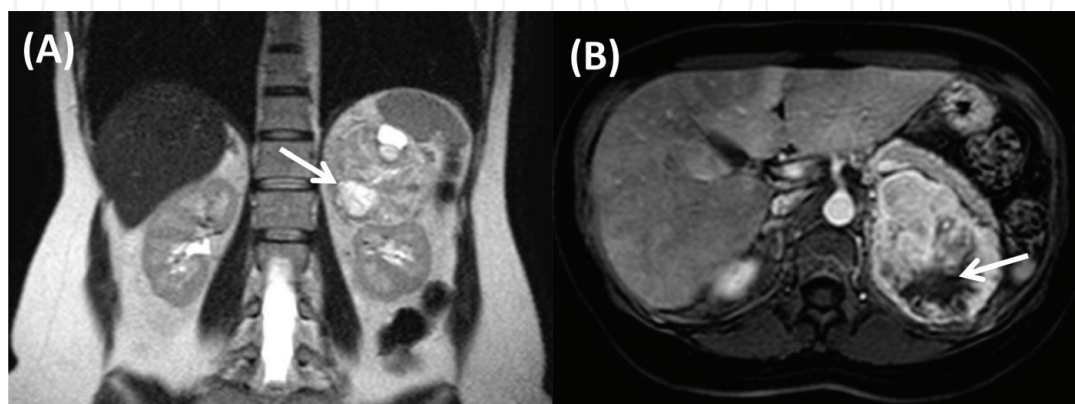
Chemical shift imaging is a detection technique for the presence of lipids. Benign lesions show as relatively shiny at the in-phase images, and they present a dimmed sign at the out-of-phase ones. The majority of adenomas are slightly hypointense or isointense to the liver on T1-weighted images and slightly hyperintense or isointense on T2-weighted images. The utilization of chemical shift techniques (in-phase or out-of-phase GRE) allows the characterization of adenomas containing microscopic fat and water protons in a same voxel (**Figure 5**). On out-of-phase images, the protons signal is null and results in signal loss as compared with in-phase images [21–24].

A magnetic resonance imaging may be superior to a computed tomography in the assessment of the vascular invasion, especially in terms of the inferior vena cava [25, 26].

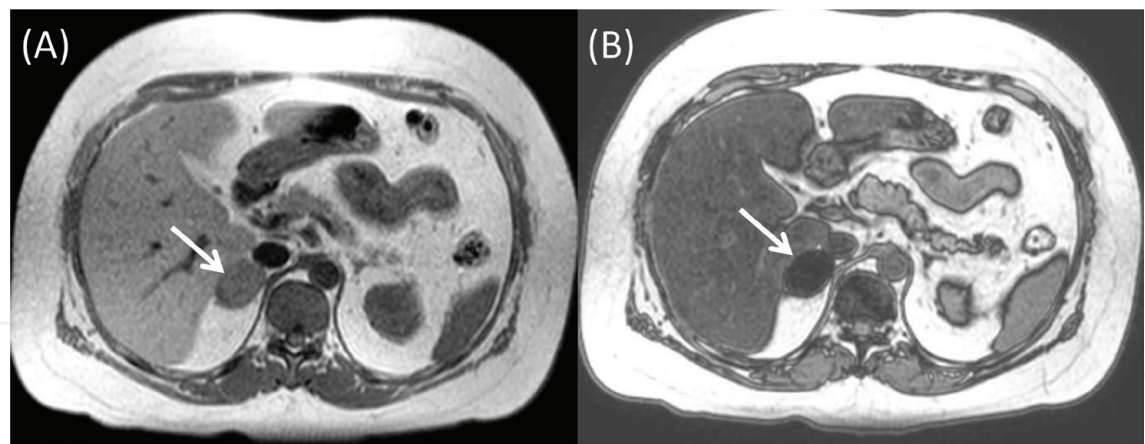
## 6.3 Other resources of diagnosis per image

In patients whose characterization of lesion malignancy could not be carried out by a tomography or resonance, additional information could be obtained through fluorine-18 fluorodeoxyglucose positron emission tomography. Malignant lesions present a high collection rate of the radiotracer.

Metomidate binds itself specifically to Cyp11b cortical adrenal enzymes. It is used as a radiotracer at C-MTO PET, as it is capable of differentiating lesions originated at the adrenal cortical from the metastatic ones toward the adrenal [27].



**Figure 4.** Adrenal cortical carcinoma. Magnetic resonance imaging coronal T2-weighted FSE (A) and contrast-enhanced axial T1-weighted GRE (B) sequences demonstrate a large expansive lesion involving the right adrenal gland. The lesion shows heterogeneous pattern of impregnation by the contrast agent and areas of necrosis (hypersignal on T2-weighted sequences) (arrows).



**Figure 5.** Magnetic resonance imaging axial T1-weighted phase GRE (A) and axial out-of-phase sequences (B) demonstrate right adrenal lesions signal loss (arrows), allowing the diagnosis of microscopic lipid-rich adenoma.

7. Conclusion

Patients diagnosed with adrenal lesions should undergo a thorough assessment of functioning in light of the possibility of malignancy.

Functioning adrenal tumors or those likely to be malignant should lead to surgical treatment.

Special care should be taken in preparation prior to adrenalectomy of patients that might suffer from functioning tumors or pheochromocytoma.

Conflict of interest

None of the authors have any conflict of interest.

Abbreviations

ACTH	adrenocorticotrophic hormone
UH	Hounsfield units
H&E	hematoxylin and eosin
SC	serum cortisol
UFC	urine-free cortisol
FSE	fast spin echo
GRE	gradient echo

IntechOpen

## Author details

Bruno Costa do Prado<sup>1\*</sup>, Alana Rocha Puppim<sup>2</sup>, Jose Tadeu Carvalho Martins<sup>2</sup>,  
Fabiana Lima Marques<sup>2</sup>, Robson Dettman Jarske<sup>1</sup>  
and Octavio Meneghelli Galvão Gonçalves<sup>3</sup>

1 Department of Urology, Universidade Federal do Espírito Santo [Espírito Santo Federal University], Vitória (ES), Brazil

2 Department of Clinical Medicine, Universidade de Vila Velha [Vila Velha University], Vila Velha (ES), Brazil

3 Department of Radiology, Universidade Federal do Espírito Santo [Espírito Santo Federal University], Vitória (ES), Brazil

\*Address all correspondence to: [brunocostadoprado@gmail.com](mailto:brunocostadoprado@gmail.com)

## IntechOpen

© 2019 The Author(s). Licensee IntechOpen. This chapter is distributed under the terms of the Creative Commons Attribution License (<http://creativecommons.org/licenses/by/3.0>), which permits unrestricted use, distribution, and reproduction in any medium, provided the original work is properly cited. 



## References

- [1] Vilar L. Manuseio dos Incidentalomas Adrenais. In: Vilar L, editor. *Endocrinologia Clínica*. 6th ed. Rio de Janeiro: Guanabara Koogan; 2016. pp. 621-649
- [2] Sales P, Santomauro A, Cunha Silva M, Pires P, Alvarenga T, Pereira Marcon L. Incidentaloma Adrenal. In: Sales P, Halpern A, Cercato C, ed. *O essencial em Endocrinologia*. 1st ed. Rio de Janeiro: Roca; 2016. p. 121 - 135
- [3] Pittella JEH, Coutinho LMB, Hilbig A. Sistema endócrino. In: Brasileiro Filho G, editor. *Bogliolo patologia*. 8th ed. Rio de Janeiro: Grupo Gen - Guanabara Koogan; 2011. p. 1149
- [4] Carroll TB, Aron DC, Findling JW, Tyrrell B. Glucocorticoids and adrenal androgens. In: Gardner DG, Shoback D, editors. *Greenspan's Basic and Clinical Endocrinology*. 10th ed. New York: McGraw-Hill; 2018. p. 328
- [5] Aubert S, Wacrenier A, Leroy X, Devos P, Carnaille B, Proye C, et al. Weiss system revisited: A clinicopathologic and immunohistochemical study of 49 adrenocortical tumors. *American Journal of Surgical Pathology*. 2002;**26**(12):1612-1619
- [6] Hough AJ, Hollifield JW, Page DL, Hartmann WH. Prognostic factors in adrenal cortical tumors. A mathematical analysis of clinical and morphologic data. *American Journal of Clinical Pathology*. 1979;**72**(3):390-399
- [7] Ng L, Libertino JM. Adrenocortical carcinoma: Diagnosis, evaluation and treatment. *Journal of Urology*. 2003;**169**(1):5-11
- [8] Wooten MD, King DK. Adrenal cortical carcinoma. Epidemiology and treatment with mitotane and a review of the literature. *Cancer*. 1993;**72**(11):3145-3155
- [9] Icard P, Chapuis Y, Andreassian B, Bernard A, Proye C. Adrenocortical carcinoma in surgically treated patients: A retrospective study on 156 cases by the French Association of Endocrine Surgery. *Surgery*. 1992;**112**(6):972-979 discussion 9-80
- [10] Nakamura Y, Yamazaki Y, Felizola SJ, Ise K, Morimoto R, Satoh F, et al. Adrenocortical carcinoma: Review of the pathologic features, production of adrenal steroids, and molecular pathogenesis. *Endocrinology and Metabolism Clinics of North America*. 2015;**44**(2):399-410
- [11] Carroll TB, Aron DC, Findling JW. Massa suprarrenal incidental. In: Gardner DG, Shoback D, editors. *Endocrinologia Básica e Clínica de Greenspan*. 10th ed. San Francisco: McGraw-Hill Education; 2017. pp. 324-325
- [12] Stewart PM, Newell-Price JDC. The adrenal cortex. In: Melmed S, Polonsky KS, Reed Larsen P, Kronenberg HM, editors. *Williams Textbook of Endocrinology*. 13th ed. Philadelphia: Elsevier; 2016. pp. 490-555
- [13] Young WF Jr. Clinical practice. The incidentally discovered adrenal mass. *New England Journal of Medicine*. 2007;**356**:601
- [14] Terzolo M, Stigliano A, Chiodini I, et al. AME position statement on adrenal incidentaloma. *European Journal of Endocrinology*. 2011;**164**:851
- [15] Zini L et al. Contemporary management of adrenocortical carcinoma. *European Urology*; **60**(5):1055-1065
- [16] Grumbach MM, Biller BM, Braunstein GD, et al. Management of the clinically inapparent adrenal mass ("incidentaloma"). *Annals of Internal Medicine*. 2003;**138**:424-429

- [17] Szolar DH, Korobkin M, Reittner P, et al. Adrenocortical carcinomas and adrenal pheochromocytomas: Mass and enhancement loss evaluation at delayed contrast-enhanced CT. *Radiology*. 2005;**234**:479
- [18] Peña CS, Boland GW, Hahn PF, et al. Characterization of indeterminate (lipid-poor) adrenal masses: Use of washout characteristics at contrast-enhanced CT. *Radiology*. 2000;**217**:798
- [19] Fishman EK, Deutch BM, Hartman DS, et al. Primary adrenocortical carcinoma: CT evaluation with clinical correlation. *American Journal of Roentgenology*. 1987;**148**:531-535
- [20] Allolio B, Fassnacht M. Clinical review: Adrenocortical carcinoma—Clinical update. *Journal of Clinical Endocrinology and Metabolism*. 2006;**91**:2027-2037
- [21] Israel GM, Krinsky GA. MR imaging of the kidneys and adrenal glands. *Radiologic Clinics of North America*. 2003;**41**:145-159
- [22] Mitchell DG, Crovello M, Matteucci T, et al. Benign adrenocortical masses: Diagnosis with chemical shift MR imaging. *Radiology*. 1992;**185**:345-351
- [23] Krestin GP. Genitourinary MR: Kidneys and adrenal glands. *European Radiology*. 1999;**9**:1705-1714
- [24] Namimoto T, Yamashita Y, Mitsuzaki K, et al. Adrenal masses: Quantification of fat content with double-echo chemical shift in-phase and opposed-phase FLASH MR images for differentiation of adrenal adenomas. *Radiology*. 2001;**218**:642-646
- [25] Hricak H, Amparo E, Fisher MR, Crooks L, Higgins CB. Abdominal venous system: Assessment using MR. *Radiology*. 1985;**156**:415-422
- [26] Soler R, Rodríguez E, López MF, Marini M. MR imaging in inferior vena cava thrombosis. *European Journal of Radiology*. 1995;**19**:101-107
- [27] Hennings J, Hellman P, Ahlström H, Sundin A. Computed tomography, magnetic resonance imaging and <sup>11</sup>C-metomidate positron emission tomography for evaluation of adrenal incidentalomas. *European Journal of Radiology*. 2009;**69**:314