

We are IntechOpen, the world's leading publisher of Open Access books Built by scientists, for scientists

6,900

Open access books available

186,000

International authors and editors

200M

Downloads

Our authors are among the

154

Countries delivered to

TOP 1%

most cited scientists

12.2%

Contributors from top 500 universities



WEB OF SCIENCE™

Selection of our books indexed in the Book Citation Index
in Web of Science™ Core Collection (BKCI)

Interested in publishing with us?
Contact book.department@intechopen.com

Numbers displayed above are based on latest data collected.
For more information visit www.intechopen.com



OCT Findings in Myopic Traction Maculopathy

*Ramesh Venkatesh, Bharathi Bavaharan
and Naresh Kumar Yadav*

Abstract

The prevalence of myopia is constantly on a rise. Patients with high myopia and pathological myopia can lose vision due to a number of degenerative changes occurring at the macula. With recent advances in imaging techniques such as spectral domain optical coherence tomography (OCT) and swept-source OCT, our understanding of macular pathology in myopia has improved significantly. New conditions such as myopic traction maculopathy have been identified and defined. Treatment approaches are now being planned on the basis of the pathoanatomy of myopic traction maculopathy on OCT. In this chapter, we discuss the role of OCT imaging in myopic traction maculopathy.

Keywords: myopia, traction maculopathy, posterior staphyloma

1. Introduction

Myopic traction maculopathy was first described by Panozza and associates in 2004 as a group of pathological features seen in eyes with high myopia generated by traction [1]. In recent times, MTM is also termed as myopic foveoschisis. One of the important reasons for reduced vision in these myopic eyes is traction-related retinal disorders. Eyes with myopic traction maculopathy demonstrate features of vitreomacular traction, retinal thickening, macular retinal schisis-like thickening, lamellar macular hole (MH), and foveal retinal detachment (FRD) [2]. Many of these retinal pathologies are not detectable on clinical examination and are only found on advanced imaging with optical coherence tomography. Because of the clinical subtlety of some of these disorders, decreased visual acuity may be attributed to other causes, whereas macular traction may remain undiagnosed [3–8]. The natural course of myopic macular traction disorders is not clear. Some studies have shown progression to more serious complications like full-thickness MH and FRD while a few studies have shown spontaneous resolution of foveal detachment and macular retinoschisis after development of spontaneous posterior vitreous detachment (PVD) [6, 9–13]. Optical coherence tomography (OCT) is a useful, non-invasive and indispensable tool in the diagnosis, pathogenesis, staging, prognosis, treatment and follow-up of MTM. In this article, we describe the role of OCT imaging in MTM.

2. Pathogenesis

Before the advent of OCT, the anatomic features of MTM were not described and the pathogenesis was poorly understood. Both TD-OCT and SD-OCT studies have provided an invaluable contribution to the characterization and understanding of the underlying pathologic mechanism involved in MTM. There are four major traction mechanisms identified in MTM: (1) Peri foveal vitreomacular traction (2) Cortical vitreous remnants after (PVD) development (3) Epiretinal membrane formation (4) Intrinsic non-compliance of the internal limiting membrane (ILM) and inner retina to conform to the shape of the posterior staphyloma [14, 15]. The first three mechanisms constitute the extrinsic forces (outside the retina) responsible for MTM while the stiff ILM and inner retinal layers constitute the intrinsic force (within the retina) responsible for MTM formation. The ILM itself can cause traction in eyes with posterior staphyloma.

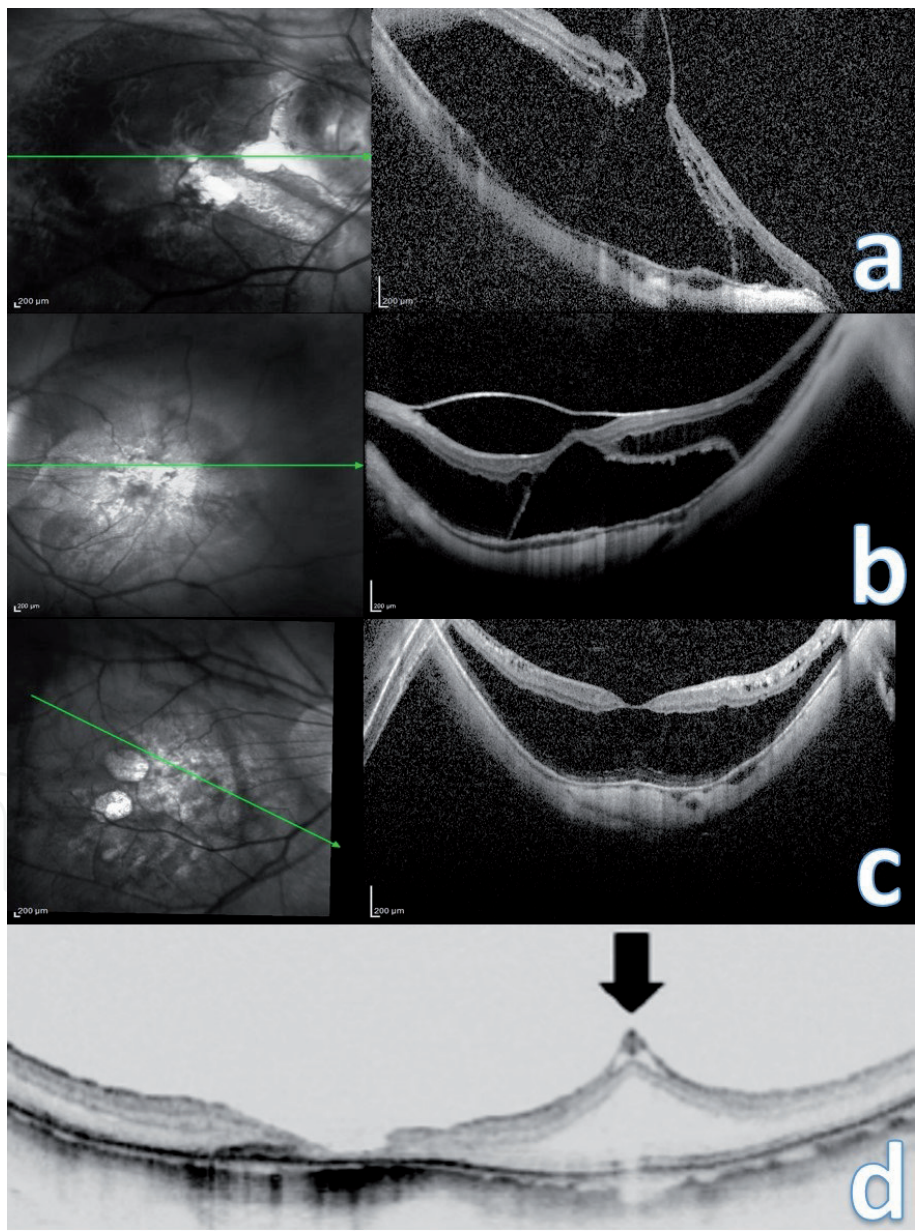


Figure 1. Mechanisms causing MTM. (a) MTM caused by vitreomacular traction with presence of foveal retinal detachment (FRD). (b) Epiretinal membrane causing schisis-like retinal thickening with associated FRD. (c) MTM with no apparent preretinal membranes. (d) Tenting of the inner retina at the retinal arteriole (black arrow) with complete resolution of the retinal thickening following vitrectomy in MTM.

It appears that in eyes without identifiable preretinal tractional elements, ILM peeling resolves the retinal thickening. There are two possible explanations: One is that the ILM is highly elastic and tough, rendering it taut like a drum. In eyes with posterior staphyloma, the ILM is like the surface of a drum and is relatively resistant to permanent deformation and stretching. The second, more probable, explanation is that microscopic cellular and collagen proliferation develops on the ILM surface after PVD causing the ILM to be less distensible and making it more rigid. This prevents the ILM to conform to the contour of the posterior staphyloma and causes a schisis-like retinal thickening [16]. Understanding the pathogenetic mechanism responsible for MTM formation helps in deciding the surgical approach in these eyes (**Figure 1**).

3. Diagnosis

Myopic tractional maculopathy is virtually seen in eyes with posterior staphyloma. In a study using SD-OCT, Henaine-Berra et al. [17] identified MTM in 17 of 116 eyes of pathological myopia, thus reporting a prevalence of approximately 15%. Some of these retinal changes are difficult to appreciate in eyes with high myopia due to the presence of the pathological degenerative changes at the posterior pole. Decreased visual acuity in these eyes is usually attributed to causes other than macular traction. OCT is often used in identifying the different retinal pathologies like vitreomacular traction, retinal thickening, macular retinoschisis, lamellar MH, and FRD. Progression of the myopic tractional detachment to develop a full-thickness MH and macular retinal detachment can also be identified with use of OCT.

4. Staging and classification

On the basis of OCT, Shimada et al. [4] have classified MTM into five stages from S0 to S4. This staging is based on the location of retinoschisis and its extent of macular involvement (**Table 1**).

Shimada et al. [4] further defined the progression as an increase of the extent or height of retinoschisis (more than 100 μ m) or the development of an inner lamellar MH, FRD, or full-thickness MH. During a mean follow-up of 36.2 months, they reported progression in 11.6% (24/207) eyes, which included 0.9% who progressed to full-thickness MH and 3.4% who progressed to FRD. The eyes with extensive macular retinoschisis (S4) showed progression significantly more (42.9%) than eyes having less extensive macular retinoschisis areas (6.7%). Six (21.4%) of 28 eyes with S4 MTM progressed to foveal detachment (**Figures 2 and 3**).

Stage	Location and involvement
0	No retinoschisis
1	Extrafoveal
2	Foveal
3	Both foveal and extrafoveal but not the entire macula
4	Entire macula

Table 1.
Staging of myopic tractional maculopathy depending on the extent of involvement.

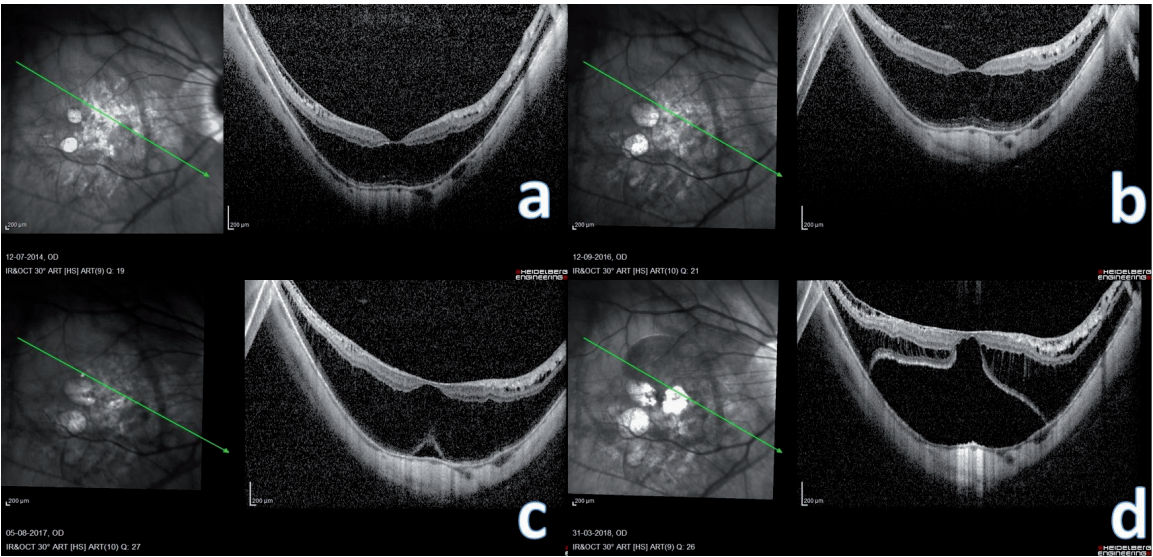


Figure 2.
(a–d) Progression of MTM leading to FRD over a period of 5 years.

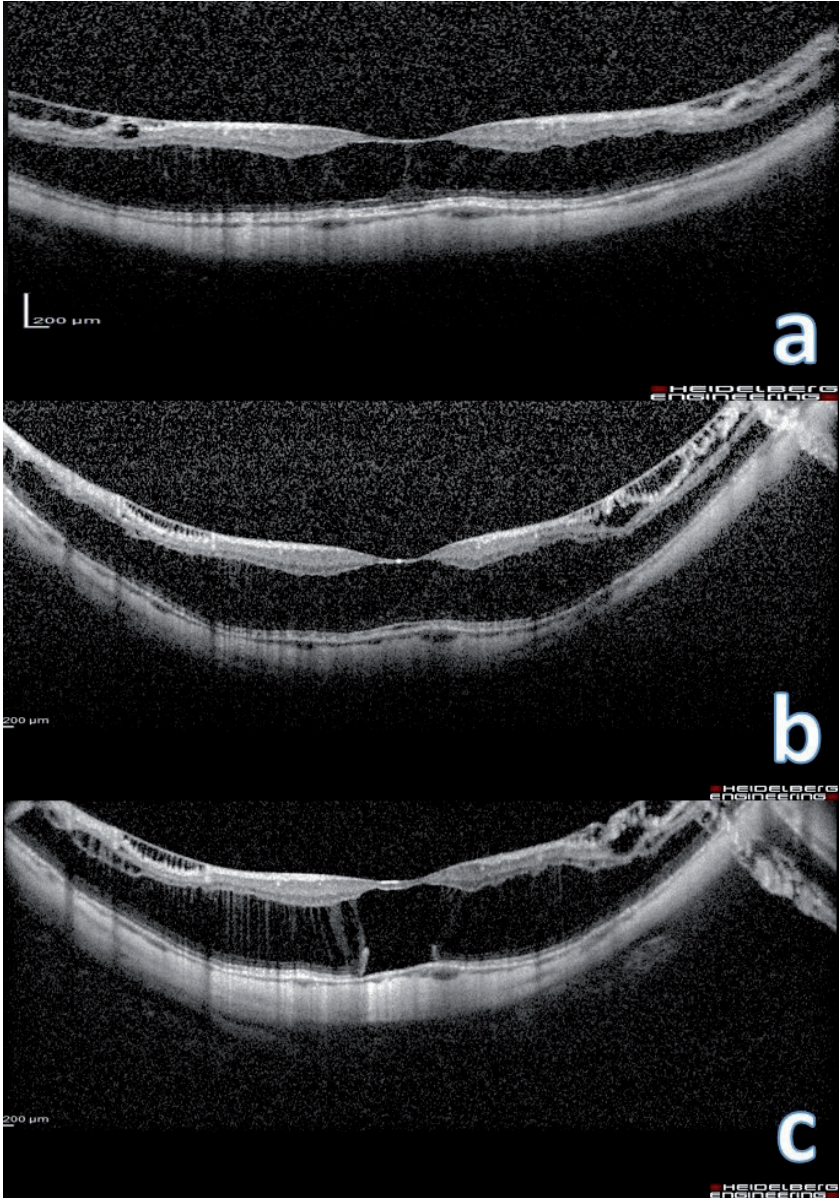


Figure 3.
(a–c) Progression of MTM in the fellow eye of a patient who had undergone vitrectomy for MTM with foveal detachment in the other eye.

5. Treatment

The goal of treatment in MTM is to relieve the tractional forces responsible for the formation of MTM [18]. This can be achieved primarily with the help of internal procedure with vitrectomy and external procedure with macular buckle. Pharmacologic vitreolysis can be considered a useful treatment option if vitreomacular traction from the perifoveal PVD or traction associated with a remnant cortical vitreous layer after PVD is responsible for the MTM formation.

The indications of surgery in MTM are:

1. Recent onset reduction in visual acuity secondary to development of full-thickness MH or FRD.
2. Progression in the extent of the schisis-like thickening documented by OCT.
3. Vision <20/50.

Most surgeons while dealing with myopic traction maculopathy have two approaches:

1. Minimalist approach—This involves identifying and resolving only the major traction mechanism visible on OCT. In this approach, only vitrectomy with PVD induction is carried out. ILM peeling is not done in these cases. This avoids complications of ILM peeling in select eyes, but it is unlikely to be successful in each and every case.
2. Comprehensive approach—In this approach, all the preretinal tractional elements are removed along with ILM peeling in every case. This approach has the highest single-operation success rate and ensures complete removal of all cellular and vitreous components that might cause current or future traction [14].

Taniuchi et al. [19] evaluated the effect of vitrectomy with and without ILM peeling in 71 eyes of 64 patients with myopic traction maculopathy. They studied the effects on visual acuity and post-operative complications. The results indicated that vitrectomy with ILM peeling can lead to improvement in vision in patients with macular retinoschisis or foveal detachment. Recurrences of tractional macular detachment were also more frequent in eyes without ILM peeling.

5.1 Surgical techniques

Basically, vitrectomy with removal of the posterior cortical vitreous is what is minimally required in relieving the tractional forces responsible for MTM formation. The role of additional procedures like peeling of internal limiting membrane and use of gas tamponade in MTM is debatable. In eyes with MTM secondary to vitreomacular traction from the perifoveal PVD and traction associated with a remnant cortical vitreous layer after PVD, vitrectomy alone with removal of posterior cortical vitreous is sufficient in relieving the traction and achieves a normal retinal anatomy. In eyes with MTM secondary to epiretinal membrane formation, additional removal of epiretinal membrane is required. MTM caused by intrinsic stiffening of the ILM requires peeling of ILM with or without the placement of macular buckle [20, 21]. Few studies have shown that sparing a small island of ILM over the fovea in eyes with MTM can prevent the development of post-operative MHs which are usually difficult to fix [22, 23] (**Table 2**).

MTM	Surgery procedure
(1) Due to vitreomacular traction from the perifoveal PVD	Vitrectomy with posterior cortical vitreous removal
(2) Due to traction associated with a remnant cortical vitreous layer after PVD	Vitrectomy with posterior cortical vitreous removal
(3) Due to epiretinal membrane formation	Vitrectomy with posterior cortical vitreous removal with ERM removal
(4) Due to intrinsic stiffening of the ILM	(a) Vitrectomy with posterior cortical vitreous removal with ILM peeling (b) Macular buckle alone (c) combined vitrectomy and macular buckle
(5) With associated full-thickness MH or FRD	(a) Vitrectomy with posterior cortical vitreous removal with ILM peeling with gas tamponade (b) Macular buckle alone (c) Combined vitrectomy and macular buckle

Abbreviations: MTM—myopic traction maculopathy; PVD—posterior vitreous detachment; ERM—epiretinal membrane; ILM—Internal limiting membrane; MH—Macular hole; FRD—Foveal retinal detachment.

Table 2.
Surgical decision-making in myopic traction maculopathy based on pathoanatomy seen on optical coherence tomography.

Common difficulties encountered during vitrectomy in these high myopic eyes are: (1) inability of the smaller gauge instruments to reach the retinal tissue at the macula due to longer axial length; (2) In eyes with posterior staphyloma, the vitreous is strongly adherent to the edge of the staphyloma resulting in retinal breaks during PVD induction; (3) Staining of ILM with various dyes is usually inadequate and patchy making ILM peeling difficult in these scenarios; (4) Glaucoma is associated with high myopia resulting in an already compromised optic nerve head which can get worsened following vitrectomy; (5) Scleral thinning associated with high myopia

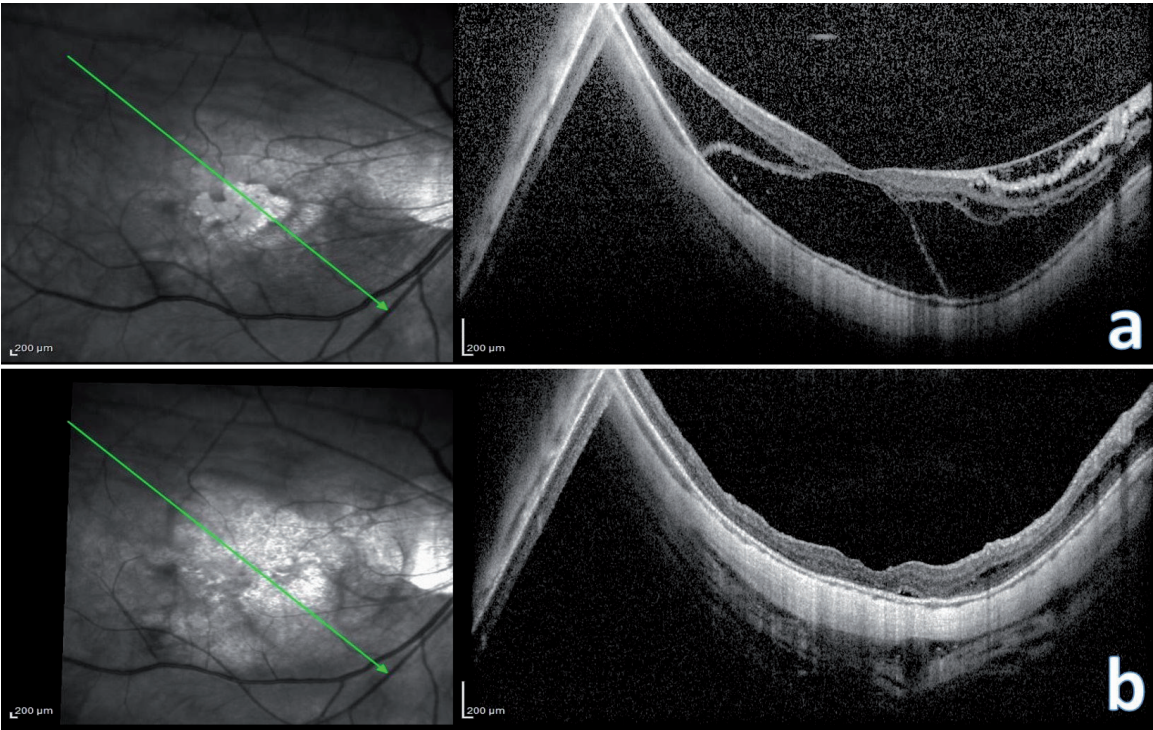


Figure 4.
(a–b) Pre and post-operative images of a patient with myopic foveoschisis with FRD. At 6 months post-op, there is complete resolution of the retinal thickening and subretinal fluid.

can lead to catastrophic complications like expulsive hemorrhage. Thus, macular buckle has emerged as a useful and effective treatment option in the management of MTM. However, due to the longer learning curve of this technique and unpredictable outcomes following this procedure, vitrectomy still remains the most preferred treatment modality amongst most vitreoretinal surgeons in the management of MTM.

6. Monitoring

Following surgery for MTM, resolution of retinal thickening and/or foveal detachment is monitored using OCT. Complete resolution of retinal thickness or subretinal fluid is achieved in 6–9 months after surgery [24] (**Figure 4**). Patients with high myopia and unilateral MTM require regular OCT monitoring of the fellow eye to assess progression to myopic pre-MTM [25].

7. Conclusion


One of the important causes for disturbed vision secondary to high myopia is MTM. It may be difficult to appreciate MTM on clinical examination with biomicroscopy. With the advent of OCT, the diagnosis of MTM and a posterior staphyloma can be made easily. Newer generation OCT imaging modalities have helped in the understanding the mechanism of myopic foveoschisis formation and help in deciding the treatment plan by the retinal surgeon. Early detection and referral to a retinal specialist for evaluation and treatment when appropriate may prevent further vision loss secondary to MH formation and/or retinal detachment.

Author details

Ramesh Venkatesh*, Bharathi Bavaharan and Naresh Kumar Yadav
Narayana Nethralaya, Bengaluru, India

*Address all correspondence to: vramesh80@yahoo.com

IntechOpen

© 2019 The Author(s). Licensee IntechOpen. This chapter is distributed under the terms of the Creative Commons Attribution License (<http://creativecommons.org/licenses/by/3.0>), which permits unrestricted use, distribution, and reproduction in any medium, provided the original work is properly cited. 

References

- [1] Panozzo G, Mercanti A. Optical coherence tomography findings in myopic traction maculopathy. *Archives of Ophthalmology*. 2004;**122**(10):1455-1460
- [2] Kanski JJ. *Clinical Ophthalmology: A Systematic Approach*. 6th ed. Oxford: Butterworth-Heinemann Elsevier Ltd.; 2007. p. 931
- [3] Smiddy WE, Kim SS, Lujan BJ, et al. Myopic traction maculopathy: Spectral domain optical coherence tomographic imaging and a hypothesized mechanism. *Ophthalmic Surgery, Lasers and Imaging*. 2009;**40**:169-173
- [4] Shimada N, Ohno-Matsui K, Baba T, et al. Natural course of macular retinoschisis in highly myopic eyes without MH or retinal detachment. *American Journal of Ophthalmology*. 2006;**142**:497-500
- [5] Takano M, Kishi S. Foveal retinoschisis and retinal detachment in severely myopic eyes with posterior staphyloma. *American Journal of Ophthalmology*. 1999;**128**:472-476
- [6] Benhamou N, Massin P, Haouchine B, et al. Macular retinoschisis in highly myopic eyes. *American Journal of Ophthalmology*. 2002;**133**:794-800
- [7] Ikuno Y, Tano Y. Early MHs with retinoschisis in highly myopic eyes. *American Journal of Ophthalmology*. 2003;**136**:741-744
- [8] Baba T, Ohno-Matsui K, Futagami S, et al. Prevalence and characteristics of FRD without MH in high myopia. *American Journal of Ophthalmology*. 2003;**135**:338-342
- [9] Shimada N, Ohno-Matsui K, Yshida T, et al. Progression from macular retinoschisis to retinal detachment in highly myopic eyes is associated with outer lamellar hole formation. *The British Journal of Ophthalmology*. 2008;**92**(6):762-764
- [10] Sun CB, Liu Z, Xue AQ, Yao K. Natural evolution from macular retinoschisis to full-thickness MH in highly myopic eyes. *Eye (London, England)*. 2010;**24**(12):1787-1791
- [11] Gaucher D, Haouchine B, Tadayoni R, et al. Long-term follow-up of high myopic foveoschisis: Natural course and surgical outcome. *American Journal of Ophthalmology*. 2007;**143**(3):455-462
- [12] Ripandelli G, Rossi T, Scarinci F, et al. Macular vitreoretinal interface abnormalities in highly myopic eyes with posterior staphyloma: 5-year follow-up. *Retina*. 2012;**32**(8):1531-1538
- [13] Polito A, Lanzetta P, Del Borrello M, Bandello F. Spontaneous resolution of a shallow detachment of the macula in a highly myopic eye. *American Journal of Ophthalmology*. 2003;**135**(4):546-547
- [14] Johnson MW. Myopic traction maculopathy: Pathogenic mechanisms and surgical treatment. *Retina*. 2012;**32**(Suppl 2):S205-S210
- [15] VanderBeek BL, Johnson MW. The diversity of traction mechanisms in myopic traction maculopathy. *American Journal of Ophthalmology*. 2012;**153**(1):93-102
- [16] Yokota R, Hirakata A, Hayashi N, Hirota K, Rii T, Itoh Y, et al. Ultrastructural analyses of internal limiting membrane excised from highly myopic eyes with myopic traction maculopathy. *Japanese Journal of Ophthalmology*. 2018;**62**(1):84-91
- [17] Henaine-Berra A, Zand-Hadas IM, Fromow-Guerra J, García-Aguirre G. Prevalence of macular anatomic abnormalities

in high myopia. *Ophthalmic Surgery, Lasers and Imaging Retina*. 2013;**44**(2):140-144

[18] Hattori K, Kataoka K, Takeuchi J, Ito Y, Terasaki H. Predictive factors of surgical outcomes in vitrectomy for myopic traction maculopathy. *Retina*. 2018;**38**(Suppl 1):S23-S30

[19] Taniuchi S, Hirakata A, Itoh Y, Hirota K, Inoue M. Vitrectomy with or without internal limiting membrane peeling for each stage of myopic traction maculopathy. *Retina*. 2013;**33**(10):2018-2025

[20] Alkabes M, Mateo C. Macular buckle technique in myopic traction maculopathy: A 16-year review of the literature and a comparison with vitreous surgery. *Graefes Archive for Clinical and Experimental Ophthalmology*. 2018;**256**(5):863-877

[21] Susvar P, Sood G. Current concepts of macular buckle in myopic traction maculopathy. *Indian Journal of Ophthalmology*. 2018;**66**(12):1772-1784

[22] Ho TC, Chen MS, Huang JS, et al. Foveola nonpeeling technique in internal limiting membrane peeling of myopic foveoschisis surgery. *Retina*. 2012;**32**:631-634

[23] Shimada N, Sugamoto Y, Ogawa M, Takase H, Ohno-Matsui K. Fovea-sparing internal limiting membrane peeling for myopic traction maculopathy. *American Journal of Ophthalmology*. 2012;**154**(4):693-701

[24] Kumar A, Ravani R, Mehta A, Simakurthy S, Dhull C. Outcomes of microscope-integrated intraoperative optical coherence tomography-guided center-sparing internal limiting membrane peeling for myopic traction maculopathy: A novel technique. *International Ophthalmology*. 2018;**38**(4):1689-1696

[25] Xia HJ, Wang WJ, Chen F, Wu Y, Cai ZY, Chen W, et al. Long-term follow-up of the fellow eye in patients undergoing surgery on one eye for treating myopic traction maculopathy. *Journal of Ophthalmology*. 2016;**2016**:2989086