

We are IntechOpen, the world's leading publisher of Open Access books Built by scientists, for scientists

6,900

Open access books available

186,000

International authors and editors

200M

Downloads

Our authors are among the

154

Countries delivered to

TOP 1%

most cited scientists

12.2%

Contributors from top 500 universities



WEB OF SCIENCE™

Selection of our books indexed in the Book Citation Index
in Web of Science™ Core Collection (BKCI)

Interested in publishing with us?
Contact book.department@intechopen.com

Numbers displayed above are based on latest data collected.
For more information visit www.intechopen.com



Introductory Chapter: Some Important Aspects of Root Canal Treatment

Ana Luiza de Carvalho Felippini

1. Introduction

Root canal treatment is one type of endodontic treatment. To understand endodontic treatment, it is important to know about the anatomy of the tooth. The lack of knowledge regarding morphological and anatomical variations of the root canal system can result in failure to identify all root canals and lead to inadequate instrumentation and consequent failure of the endodontic treatment.

The external and internal morphological features of roots are variable and complex, and several classifications have been proposed to define the various types of canal configurations that occur commonly. Improvements in nondestructive digital image systems, such as cone-beam and micro-computed tomography, as well as the use of magnification in clinical practice, have increased the number of reports on complex root canal anatomy [2, 12].

Inside the tooth, under the white enamel and the hard layer of the dentin, there is a soft tissue called the pulp. The pulp contains blood vessels, nerves, and connective tissue and creates the surrounding hard tissues of the tooth during development (**Figure 1**).

The endodontist removes the inflamed or infected pulp, carefully cleans and shapes the inside of the root canal, and then fills and seals the space. The endodontically treated tooth will receive a crown or other restoration to protect and restore it to full function [21].

A canal is considered well obturated when a radiopaque mass is visualized on the radiographs, being homogeneous and continuous, without voids, adapted to the lateral walls, terminating near the radiographic apex, namely 0.5–1 mm [16].

The principal stages of endodontic treatment are as follows (**Figure 2**):

1. The endodontist examines and takes a radiograph of the tooth using X-rays and then administers local anesthetic. After the tooth is numb, the endodontist places a small protective sheet called a “dental dam” over the area to isolate the tooth and keep it clean and free of saliva during the procedure.
2. The endodontist makes an opening in the crown of the tooth. Very small instruments are used to clean the pulp and the root canals.
3. After the space is cleaned and shaped, the endodontist fills the root canals with a biocompatible material, usually a rubberlike material called gutta-percha. The gutta-percha is placed with an adhesive cement to ensure complete sealing of the root canals. In most cases, a temporary filling is placed to close the opening. The temporary filling will be removed by the dentist before the tooth is restored [3].

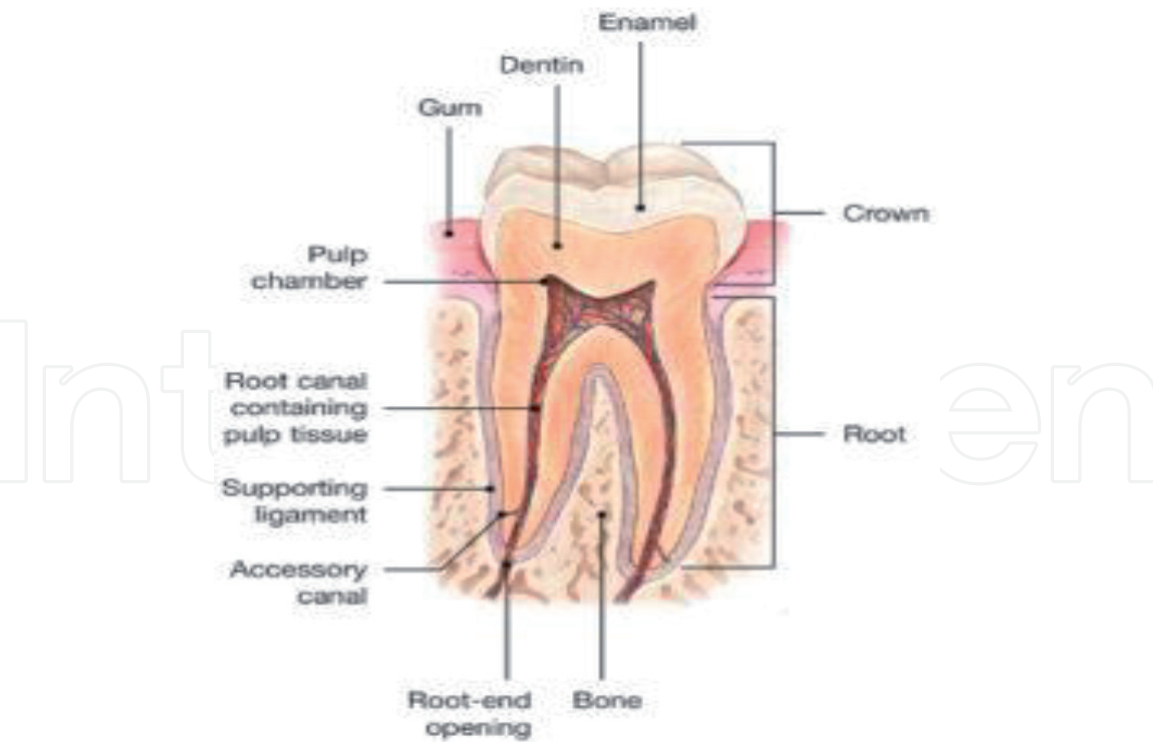


Figure 1.
Anatomy of the tooth.

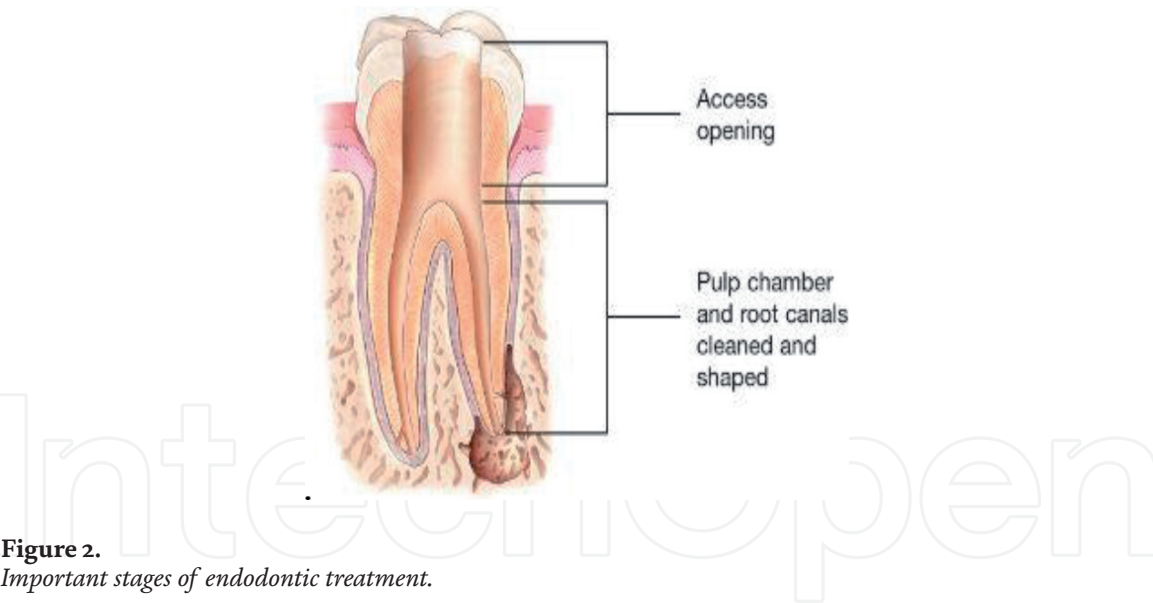


Figure 2.
Important stages of endodontic treatment.

4. In the end of the treatment, the tooth will need a crown or other types of restoration to protect and restore it to full function.

The main purpose of endodontics is the total elimination or significant reduction of bacteria and their products by combining root canal system instrumentation with chemical cleaning and filling with an inert material in order to maintain or to restore the health of periradicular tissues. Endodontic treatment aims to eliminate inflamed pulpal tissue, to clean and to obturate the canals. The sealing material must be inert, biocompatible, and stable to fill the spaces left by the pulp tissues. During the chemical-mechanical preparation, endodontic instruments promote the mechanical removal of microorganisms. The mechanical instruments remove

products, and tissues aided by a chemical substance that, in addition to maximizing the removal of debris through the mechanical action of the flow and reflux, can also exert a significant chemical effect, as long as it has an antimicrobial action.

The mechanical action of instrumentation and irrigation is able to reduce the amount of microorganisms and degenerate tissue within the root canal system. However, the use of irrigating solutions (auxiliary chemical) with antibacterial activity significantly increases the efficacy of the preparation in terms of infection control.

Remaining for a longer time inside the root canal, an intracanal medicament with antibacterial action has a greater chance of reaching areas not affected by instrumentation. Thus, by exerting its antibacterial action, it can contribute to the reduction of the endodontic microbiota.

Root canals are usually sealed using a solid material (usually gutta-percha). Although gutta-percha presents antibacterial activity, attributed to the zinc oxide component of the cones, such activity is discrete and unlikely to have any value inside the root canal system [13].

In fact, disinfected channels should be filled to eliminate void space that would have the potential to be infected or reinfected. Chemomechanical preparation of the root canal includes both mechanical instrumentation and antibacterial irrigation, and this is principally directed toward the elimination of microorganisms from the root canal system [15]. A variety of instruments and techniques have been developed and described for this critical stage of root canal treatment. Since their introduction in 1988, nickel-titanium rotary instruments have become a mainstay in clinical endodontics because of their exceptional ability to shape root canals with potentially fewer procedural complications. The safe clinical use of nickel-titanium instruments requires an understanding of the alloys as their mechanical properties and their correlation to canal anatomy [24].

Photodynamic therapy is a treatment modality that was initiated in 1900. Recently, several papers advocated its use for root canal treatment. The concept of photodynamic inactivation requires microbial exposure to either exogenous or endogenous photosensitizer molecules, followed by visible light energy, typically wavelengths in the red-infrared region. This causes the excitation of the photosensitizers, resulting in the production of some reactive oxygen species that react with intracellular components and consequently produce cell inactivation and death. This therapy is suggested as effective to antimicrobial intracanal, being a clinical treatment for periapical lesions [14].

2. Irrigation of radicular canal

Microorganisms play an important role in the etiology and maintenance of pulp and periapical infections. It is now known that more than 300 species of bacteria inhabit the oral cavity; however, the number of bacterial species present in the root canals ranges from 1 to 12, with a predominance of strict anaerobes. The use of irrigating solutions during biomechanical preparation is important for the cleaning and elimination of microorganisms present inside the root canal system [18, 20, 25].

In the process of root canal preparation, irrigation of the root canal is an essential element. There are five main benefits to using these irrigation solutions during root canal cleaning:

- Wetting of the walls of the canal
- Elimination of microorganisms

- Dissolution of organic matter
- Removal and softening of the teeth
- Cleaning of areas inaccessible by mechanical instruments

The ideal irrigating solution should exhibit potent antimicrobial action, have the ability to dissolve organic material, be lubricating, have low surface tension, and have no cytotoxic effects on periradicular tissues. Sodium hypochlorite is a halogenated compound used as an irrigating solution. It is an effective antimicrobial agent and solvent of organic matter and has low surface tension, and its effectiveness becomes larger when its concentration increases; however, the higher the concentration, the higher the possibility of toxic effect on the periapical tissues. Chlorhexidine is also a halogenated compound and has broad-spectrum antimicrobial properties, substance and low toxicity but does not have the property to dissolve organic matter. Although sodium hypochlorite is considered the best irrigating solution, it cannot dissolve inorganic particles and prevent smear layer formation during root canal instrumentation [6]. Demineralizing agents are recommended as adjuvants in the endodontic treatment of the root canal system. It is very important that the professional has the knowledge of the chemical properties of irrigating solutions to select and use them in the best possible way and in each particular case [10].

3. Endodontic obturation

Root canal obturation signals the complementary and expressive action of endodontic triad such as coronary opening, cleaning conformation of the radicular canal, and endodontic sealing. This underscores the concept of the elimination of gaps within the channels. Technically, the objectives of obturation consist in sealing root canal system with an inert and antiseptic material offering protection to the periapical tissues [1]. The radicular canal system has a very complex internal anatomy which should be considered with special attention during the treatment, since many studies reveal that there is a wide variety of accessory lateral channels, isthmuses, particularly in the third medium and apical root.

The success of nonsurgical endodontic treatment is based on the complete elimination of all debris from the root canal system, sealing the root canal system with a suitable material. The action of the endodontic instruments, however, occurs only in the main channel not covering all the root canal system. The use of a chemical substance during the action of the instrumentation is very important, facilitating the instrumentation and the entry into the largest number of accessory channels.

According to some authors, about 60% of endodontic failures should be due to the improper sealing of radicular system [4, 5]. The obturation of the root canal promotes the apical repair process. The mechanical procedures of this step should provide biocompatibility for periapical tissues especially in the selection of sealing material. The purpose of endodontic filling is to seal all entry and exit of possible infiltrations into the root canals. It should promote hermetic apical sealing, and all the stages of endodontic treatment cannot cause damage for the periapical tissues [8].

4. Endodontic surgery

The success of endodontic treatment is related to several factors such as correct therapeutic indication, careful execution of the preparation technique,

three-dimensional filling, and aseptic chain maintenance and preservation. Thus, the failure of conventional endodontic treatment usually stems from factors related to the technique, pre-existing pathology, and/or systemic factors. In many cases are observed that, even though the root canals are perfectly obturated, a persistent infection occurs. Such failures are probably related to resistant bacteria or to organic aspects of the patient. The main indicators of failure of conventional endodontic treatment are the presence of persistent apical lesion and painful post-symptomatic symptomatology. When the first intervention does not achieve the expected result, conventional endodontic retreatment should be the first option to correct any failures (such as microbial persistence in the root canal system as a consequence of inadequate aseptic control, insufficient access, and cleaning or inadequate sealing). If the infection persists, the surgical procedure may be indicated [23]. Parendodontic surgery is a therapeutic resource in the treatment of persistent conditions that affect the periapical tissues, being, for example, indicated for the resolution of cases not solved by conventional endodontic treatments. The technique used may vary according to the anatomical characteristics and local etiological factors. There are several modalities of parendodontic surgeries: urgency, exploratory and restorative, corrective, and apical. Periapical curettage is a very important procedure, since it provides the removal of infected, contaminated, and necrotic pathological tissues. The histopathological analysis of the biological material removed by curettage is fundamental for the definition of a correct diagnosis for the disease. Such procedure can promote drainage of secretions and pain relief, besides contemplating anatomical alterations, iatrogenic problems, traumatism, endo-periodontal defects, and failures in the previous treatment. It also promotes the possibility of circumventing issues such as the need to provide material for biopsies. Modern endodontic surgery techniques incorporate ultrasonic tips and biocompatible root-end filling materials that are associated with the use of high-power magnification and illumination from an operative microscope [7, 9]. Modern techniques allow for easier identification of root apices, smaller osteotomies, and shallower resection angles that preserve cortical bone and root length [17]. Improved identification of anatomic structures allows dentists to better clean and seal the root surface, thus improving surgical therapy. This type of endodontic microsurgery has demonstrated a high success rate compared with traditional techniques [11, 22, 23].

5. Conclusion

The lack of knowledge regarding morphological and anatomical variations of the root canal system can result in inadequate instrumentation and consequent failure of the endodontic treatment. The treatment of root canal is so important, together with irrigation to eliminate the microorganisms in the interior of the canals. The obturation is another very important stage in the endodontic treatment, sealing all spaces that could exist in the radicular system. All new options of rotary instruments can improve the results of instrumentation and have to be known by the professionals.

IntechOpen

IntechOpen

Author details

Ana Luiza de Carvalho Felippini
Faculty of Dentistry of Ribeirão Preto, University of São Paulo, São Paulo, Brazil

*Address all correspondence to: analuizafelippini@gmail.com

IntechOpen

© 2019 The Author(s). Licensee IntechOpen. This chapter is distributed under the terms of the Creative Commons Attribution License (<http://creativecommons.org/licenses/by/3.0>), which permits unrestricted use, distribution, and reproduction in any medium, provided the original work is properly cited. 

References

- [1] Abarca AM, Bustos A, Navia M. A comparison of apical sealing and extrusion between thermafil and lateral condensation techniques. *Journal of Endodontics*. 2001;27(11):670-672
- [2] Ahmed HMA, Versiani MA, De-Deus G, Dummer PMH. A new system for classifying root and root canal morphology. *International Endodontic Journal*. 2017;50(8):761-770
- [3] Anna-Júnior, Tanomaru-Filho M, Hungaro Duarte MA, Santos Nunes Reis JM, Guerreiro Tanomaru JM. Temperature changes in gutta-percha and resilon cones induced by thermomechanical compaction technique. *Journal of Endodontics*. 2009;35(6):879-882
- [4] Bueno AP et al. Estudio comparativo de filtración apical entre la técnica de compactación lateral en frío y técnica de obturación com System B. *Revista Odontológica Mexicana*. 2005;9(2):65-72
- [5] Ferreira MM, Sanches F, Rodrigues B, Gonçalves D, Dias JPM. Estudo Comparativo da Infiltração Apical de Canais Radiculares Obturados por Duas Técnicas Diferentes. *Revista Portuguesa de Estomatologia, Medicina Dentária e Cirurgia Maxilofacial*. 2006;47:133-138
- [6] Jeansonne M, White R. A comparison of 2,0% chlorhexidine gluconate and 5,25% sodium hypochlorite as antimicrobial endodontic irrigants. *Journal of Endodontia*. 1994;20(6):276-278
- [7] Jorge ECG, Tanomaru-Filho M, Guerreiro-Tanomaru JM, Reis JM, Spin-Neto R, Gonçalves M. Periapical repair following endodontic surgery: Two- and three-dimensional imaging evaluation methods. *Brazilian Dental Journal*. 2015;16(1):69-74
- [8] Karabucak B et al. The comparison of Gutta-Percha and Resilon penetration into lateral canals with different thermoplastic delivery systems. *Journal of Endodontia*. 2008;34(7):847-849
- [9] Levenson D. Higher powered magnification improved endodontic surgery outcomes. *Evidence-Based Dentistry*. 2012;13(4):109
- [10] Lui JN, Kuab HG, Chen NN. Effect of EDTA with and without surfactants or ultrasonics on removal of smear layer. *Journal of Endodontia*. 2007;33(4):472-475
- [11] Machado R, Vansan LP, da Cruz Ade M, da Sila EJ. Surgical endodontic reintervention using a modern technique: 2 case report. *General Dentistry*. 2014;62(5):40-43
- [12] Marceliano-Alves MF, de Lima CO, Augusto CM, Almeida Barbosa AF, Vieira Bruno AM, Rosa AM, et al. The internal root canal morphology single-rooted mandibular canines revealed by microcomputed tomography. *Journal of Conservative Dentistry*. 2018;21(6):588-591
- [13] Moorer WR, Genet JM. Antibacterial activity of gutta-percha cones attributed to the zinc oxide component. *Oral Surgery, Oral Medicine, and Oral Pathology*. 1982;53(5):508-517
- [14] Plotino G, Grande NM, Mercade M. Photodynamic therapy in endodontics. *International Endodontic Journal*. 2018;12:1-15
- [15] Sassone M, Fidel R, Vieira M, Hirata Júnior R. The influence of organic load on the antimicrobial activity of different concentrations of NaOCl and chlorhexidine in vitro. *International Endodontic Journal*. 2003;36(12):848-852

- [16] Schilder H, Filling Root DDS. Canals in three dimensions. *Journal of Endodontics*. 2006;**32**(4):281-290
- [17] Setzer FC, Kohli MR, Shah SB, Karabucak B, Kim S. Outcome of endodontic surgery: A meta-analysis of the literature—Part 2: Comparison of endodontic microsurgical techniques with and without the use of higher magnification. *Journal of Endodontia*. 2012;**38**(1):1-10
- [18] Siqueira Júnior JF, Machado AG, Silveira RM, Lopes HP, Uzeda M de. Evaluation of the effectiveness of sodium hypochlorite used with three irrigation methods in the elimination of *Enterococcus faecalis* from the root canal, in vitro. *International Endodontic Journal*. 1997;**30**(4):279-282
- [19] Siqueira JF, Rôças IN. Clinical implications and microbiology of bacterial persistence after treatment procedures. *Journal of Endodontia*. 2008;**34**(11):1291-1301
- [20] Sundqvist G. Ecology of the root canal flora. *Journal of Endodontia*. 1992;**18**(9):427-430
- [21] Trope M. Flare-up rate of single-visit endodontics. *International Endodontic Journal*. 1991;**24**(1):24-26
- [22] Tsesis I, Faivishevsky V, Kfir A, Rosen E. Outcome of surgical endodontic treatment performed by a modern technique: A meta-analysis of literature. *Journal of Endodontia*. 2009;**35**(11):1505-1511
- [23] Tsesis I, Rosen E, Taschieri S, Telishevsky Strauss Y, Ceresoli V, Del Fabbro M. Outcome of surgical endodontic treatment performed by a modern technique: A meta-analysis of literature. *Journal of Endodontia*. 2013;**39**(3):332-339
- [24] Young GR, Parashos P, Messer HH. The principles of techniques for cleaning root canals. *Australian Dental Journal*. 2007;**52**(1 Suppl):S52-S63
- [25] Zehnder M. Root canal irrigants. *Journal of Endodontia*. 2006;**32**(5):389-398