

We are IntechOpen, the world's leading publisher of Open Access books Built by scientists, for scientists

6,900

Open access books available

186,000

International authors and editors

200M

Downloads

Our authors are among the

154

Countries delivered to

TOP 1%

most cited scientists

12.2%

Contributors from top 500 universities



WEB OF SCIENCE™

Selection of our books indexed in the Book Citation Index
in Web of Science™ Core Collection (BKCI)

Interested in publishing with us?
Contact book.department@intechopen.com

Numbers displayed above are based on latest data collected.
For more information visit www.intechopen.com



Robotic Sacrocolpopexy and Sacrocervicopexy for the Correction of Pelvic Organ Prolapse

James C Brien¹, Michael D Fabrizio¹ and James C Lukban²

¹*Department of Urology, Eastern Virginia Medical School, Norfolk, Virginia,*

²*Division of Urogynecology, Eastern Virginia Medical School, Norfolk, Virginia, USA*

1. Introduction

The lifetime risk for undergoing a single operation for prolapse (or incontinence) is 11%, with the National Center for Health Statistics reporting 400,000 procedures for these conditions performed annually.[1] Swift et al. described the epidemiologic distribution of pelvic organ prolapse (POP) in a sample of 1004 women presenting for an annual gynecologic exam, evaluated with a validated staging system (Pelvic Organ Prolapse Quantification System or POP-Q).[2,3] Despite a relatively young mean age of 42.7 years, clinically significant (Stage II or greater) vaginal wall descensus was identified in 37% of subjects. In a larger study as part of the Women's Health Initiative, those between the ages of 50 and 79 were screened for POP through a non-validated system.[4] Of 16,616 subjects with no previous hysterectomy, 41.1% had some form of prolapse, while 38% of 10,727 hysterectomized women exhibited POP. The true incidence of POP is likely higher, as many women may not report their condition due to embarrassment, or they may feel that such changes are a normal part of aging.

2. Anatomy of the pelvic floor

The pelvic floor is comprised of layers of connective tissue and muscle that provide support to the pelvic viscera. The urethra, vagina and rectum are attached to the pelvic sidewalls by the endopelvic fascia, which in turn is supported by the pelvic floor musculature (PFM).[5] The PFM consists of the levator ani (pubococcygeus and iliococcygeus) and coccygeus muscles, providing tonic support to the endopelvic fascia and viscera through a preponderance of type I (slow twitch) fibers.[6] Thus, a robust PFM is essential in maintaining the position of the viscera within the pelvis.

3. Etiology of pelvic organ prolapse

Pelvic organ prolapse represents an attenuation or disruption of the connective tissue comprising the pubocervical endopelvic "fascia" anteriorly or rectovaginal endopelvic "fascia" posteriorly, manifesting as anterior or posterior vaginal wall prolapse, respectively. Additionally, a weak or torn cardinal - uterosacral ligament complex may lead to vaginal

Source: Robot Surgery, Book edited by: Seung Hyuk Baik,
ISBN 978-953-7619-77-0, pp. 172, January 2010, INTECH, Croatia, downloaded from SCIYO.COM

apex (cuff post hysterectomy or cervix) descent. Predominant risk factors for POP include age and parity, with partial denervation of the PFM proven to be the result of parturition, senescence, or some combination.[7,8] As the PFM becomes weak, support to the endopelvic fascia and viscera is lost, placing the connective tissue at risk for attenuation and/or discrete breaks with resultant POP. When encountered in a younger subject, POP may reasonably be the sequela of acute obstetric trauma, or the result of a genetic alteration in the proportion of fascial collagen subtypes.[9]

4. Considerations prior to surgical correction of pelvic organ prolapse

The goal of POP repair is to restore pelvic anatomy, and facilitate normal visceral and sexual function. To this end, the surgeon must consider, first and foremost, the integrity of the vaginal apex. The Surgery for Pelvic Organ Prolapse Committee of the 3rd International Consultation on Incontinence noted, "...the apex is the keystone of pelvic organ support". [10] Additionally, they concluded that anterior and posterior repairs are doomed to fail unless the apex is adequately supported. While multiple approaches exist to address vaginal apical prolapse, choosing the optimal repair is critical to a successful outcome.

In the following text, we will discuss several methods for the repair of apical descensus, examine the surgical evolution from vaginal and abdominal surgery to laparoscopic and robotic approaches, and describe our technique of robot assisted laparoscopic sacrocolpopexy and sacrocervicopexy.

5. Transvaginal surgery for apical prolapse

Uterosacral ligament suspension is an intraperitoneal technique in which the remnants of the uterosacral ligaments are brought together with permanent suture, and subsequently attached to the vaginal apices bilaterally employing delayed absorbable stitch. Recurrent apical prolapse following this procedure has been reported between 1% and 18%, with the anterior segment found to be the most common site of persistent prolapse.[11,12] Overall, reported patient satisfaction is high, with a re-operation rate of 5.5% in one series.[13] Although bowel injury and bleeding complications are relatively infrequent, ureteral injury or kinking has been reported to be as high as 11%, emphasizing the importance of interrogating the ureters endoscopically after suspension.[12,13]

Sacrospinous ligament fixation involves an extraperitoneal rectovaginal dissection with support of the vaginal apex through attachment to the sacrospinous ligament either unilaterally or bilaterally. Exposing the ischial spine and ligament may, at times, be a challenge, with the attendant risk of neurovascular trauma. The surgeon must avoid the hypogastric plexus, the inferior gluteal and internal pudendal vessels, and the pudendal and sciatic nerves. Outcomes are variable, with recurrence ranging from 3-30%. [14-16] Additional potential complications include gluteal pain and rectal injury.

Iliococcygeus fascial suspension is also an extraperitoneal technique performed through a posterior vaginal incision. Dissection is carried out laterally and cephalad until the iliococcygeus musculature is identified, at which point an absorbable suture is placed through the fascia and ipsilateral vaginal apex bilaterally. While Shull and colleagues reported recurrence as low as 5% with low complication rates compared to other transvaginal approaches, the potential for hemorrhagic morbidity exists, with one author reporting an average estimated blood loss (EBL) of 358 mL.[17,18]

6. Transvaginal mesh repairs

The introduction of a variety of mesh products has been implemented for the repair of stress urinary incontinence as well as POP. Although a thorough review of this modality is beyond the scope of this chapter, a brief account of contemporary outcomes will be discussed.

Several synthetic graft materials have been used historically including expanded PTFE and polyester, with polypropylene being the dominant synthetic used in contemporary kits due to its macroporous nature, allowing for tissue in-growth and minimal inflammatory response.[19,20] Commercial kits, designed to allow for minimally invasive mesh insertion, include Elevate (American Medical Systems, Minnetonka, MN, USA) and Gynecare Prolift System (Ethicon Women's Health and Urology, Somerville, NJ, USA), along with several other products and approaches for mesh support of the vaginal apex.

In a review of clinical trials and observational studies addressing apical prolapse repair, Diwadkar and colleagues included 3,425 patients from 24 studies employing vaginal mesh kits, reporting a low rate of reoperation for recurrent POP (1.3 % at 17 months), with an overall complication rate (14.5 %) similar to traditional vaginal (15.3 %) and abdominal (17.1%) approaches.[21] However, the majority of complications associated with mesh kits required surgical intervention under general anesthesia (8.5 %), due in part to mesh erosion (vaginal exposure of synthetic material). In a retrospective review comparing outcomes following Prolift mesh repair, uterosacral ligament suspension and abdominal sacrocolpopexy, no difference in operative success (% with Stage 0 or I at follow-up) was observed between the three groups; however, mean change in apical support was significantly better after abdominal sacrocolpopexy compared to transvaginal mesh repair and uterosacral ligament suspension.[22]

7. Abdominal surgery for apical prolapse

High uterosacral ligament suspension, similar to its vaginal counterpart, involves suspension of the vaginal apex to plicated ureterosacral ligaments. After entrance into the abdomen, the cul-de-sac is obliterated to address any co-existing enterocele. Subsequently, the apex of the vagina is exposed and reapproximated to the plicated uterosacral ligaments.

Abdominal sacral colpopexy (ASC) involves securing the apex of the vagina to the sacral promontory with intervening mesh. After a laparotomy incision is made and hysterectomy performed (if uterus present), the vagina is elevated with an end-to-end anastomosis (EEA) sizer followed by dissection of the vesicovaginal and rectovaginal spaces. The anterior and posterior leafs of a Y-shaped polypropylene mesh are sutured to the anterior and posterior vaginal walls, respectively. After opening the peritoneum over the sacral promontory, multiple nonabsorbable sutures are placed through the anterior longitudinal ligament, and secured to the single tail of the "Y". Lastly, the peritoneum over the sacrum and vaginal apex is closed.

Several studies document durable success following ASC, with recurrent prolapse ranging from 1 - 7% at long term follow up.[23,24] A recent Cochrane Review of the Surgical Management of Pelvic Organ Prolapse concluded that ASC was superior to sacrospinous fixation, exhibiting a lower rate of recurrent prolapse and less postoperative dyspareunia. [25] Abdominal sacrocolpopexy, however, was associated with longer operative time, longer recovery time and higher costs. Complications are infrequent, and include injury to bowel and bladder, with the potential for significant hemorrhage from presacral vessels. While

mesh erosion has historically been higher with ASC employing small pore multifilament material, rates of apical exposure of graft have been 5% or less with the use of polypropylene.[26]

Given the durability of ASC, such an approach is considered by many to represent the “gold standard” in the treatment of apical prolapse. In considering the attendant risks of open abdominal procedures and the availability of burgeoning technology, practitioners have made the logical progression to a less invasive approach using minimally invasive instrumentation in the performance of sacrocolpopexy.

8. Laparoscopic sacrocolpopexy (LSC)

The concept and surgical technique of LSC is similar to that of its open counterpart. With the introduction of laparoscopy to vaginal reconstruction, many studies have been published evaluating the efficacy and safety of LSC as compared to ASC. Overall, LSC appears to be durable, with a low rate of recurrence (0-4%),[28-30] exhibiting favorable quality of life outcomes[28] and high patient satisfaction (96%).[30] Complications are overall infrequent, and include erosions (0-9%), dyspareunia (1%), spondylitis (<1%), partial small bowel obstruction (0-4%) and a low conversion to open rate of 2.2%.[28-31] Reported operative times have ranged from 97 min to 219 minutes depending on surgeon experience.[29-30] In two retrospective comparative trials, LSC was associated with lower EBL, shorter hospital stay and increased time in the operating room (OR) as compared to ASC.[27,29] From this data, we may conclude LSC to be non-inferior to its open counterpart with a low incidence of adverse events.

9. Robot assisted laparoscopic sacral colpopexy and cervicopexy (RALSC)

The da Vinci surgical system (Intuitive Surgical, Sunnyvale, CA, USA) has augmented traditional laparoscopy adding three-dimensional vision, wristed instrumentation with seven degrees of freedom (versus 3 degrees with laparoscopy) and improved surgical ergonomics. Specific to sacrocolpopexy, the addition of the 4th arm adds facilitation of sigmoid colon reflection.

Robot assist laparoscopic sacrocolpopexy (RALSC) has been found to have similar outcomes to its pure laparoscopic predecessor. Efficacy appears durable with one non-comparative study of 30 patients reporting 6% recurrence at 24 months,[32] and surgical failure in two additional studies ranging from 0 - 4.7% at shorter follow up.[33,34] Such data are comparable to the 7% rate of recurrence reported in a large series of open sacralcolpopexy by Snyder and Krantz.[24] Daneshgardi and colleagues evaluated preoperative and postoperative POP-Q values in patients undergoing RALSC, reporting not only an overall improvement in global POP-Q scores, but statistically significant improvement of anterior, posterior and apical POP-Q scores separately.

Mesh erosion rates are comparable to an open incidence of 7% reported by Kohli and colleagues.[37] Length of hospital stay in 4 series ranges from 1 - 2.4 days[32,33,35,38] with operative times ranging 186 - 328 minutes.[32,34-36,38] One series reported a 25% decrease in procedure time after the initial 10 cases, suggesting a steep, but short learning curve.[36] Complications of RALSC are comparable to LSC. Ureteral injury, enterotomy and cystotomy are infrequent (0 - 1.2%) as is post op small bowel obstruction (4.7%).[32,34,36] While no randomized-controlled trials comparing RALSC to LSC have been published to our

knowledge, a retrospective comparison of RALSC with ASC by Geller et al. found the former to be associated with slightly better postoperative POP-Q "C" (apex) improvement, less EBL and shorter hospital stay. While RALSC was observed to have longer operative times, there was no significant difference with respect to intraoperative or postoperative complications between the two groups.[38]

10. Description of RALSC

The patient is given appropriate antibiotic prophylaxis in the preoperative area and sequential pneumatic compression devices are applied for deep venous thrombosis prophylaxis. After intubation, the patient is placed in low - lithotomy position and straps are placed across the shoulders and chest in a criss - cross pattern to secure the patient on the table. The arms are padded and tucked. See Figure 1 for operating room configuration.

After prepping and draping of the abdomen, perineum and vagina, a foley catheter is placed. A Veress needle may be inserted through the umbilicus (or just cephalad) to facilitate insufflation of the abdomen, or the initial trocar may be introduced under direct vision employing a clear blunt-tipped device with lens inside prior to introduction of gas. In patients suspected of having significant midline abdominal adhesions, one may enter the abdomen with a 5 mm laparoscope loaded into a 5 mm clear blunt-tipped trocar at Palmer's point (3 cm below the left costal margin in the mid-clavicular line) to visualize subsequent midline trocar placement.[39]

The initial 12 mm camera port is inserted no less than 15 cm and no greater than 22 cm from the pubic symphysis in the midline. Prior to placement of lateral trocars, the patient is placed in a steep Trendelenburg tilt. With full insufflation (not to exceed 15 mm Hg), measurements are made on the anterior abdomen to ensure appropriate placement of subsequent trocars, and avoid collision of the robotic arms (Fig. 2). Two lateral 8 mm ports are then placed 10 cm inferolateral to the camera port in the direction of the ipsilateral anterior superior iliac spine (ports 1 and 2). A 3rd 8 mm port is placed 8 - 10 cm superolateral to port 2 (port 3) and a 12 mm assistant port is placed 8 cm lateral to port 1. The robot is docked and ports secured (Fig. 3).

The sigmoid is reflected with the fourth arm employing a non-fenestrated grasper in the open position, facilitating visualization of the sacrum. If the sigmoid shows significant redundancy, additional retraction may be provided by the introduction of a 0 - polypropylene suture on a straight needle passed percutaneously through the left lower abdomen to tether the sigmoid. Several passes are made through the appendices epiploicae and the needle re-passed to exit the abdomen at a point 1 cm lateral to its site of entry. The sigmoid is placed on gentle traction to complete exposure. The peritoneum over the promontory is then incised, with dissection carried out distally to the pelvis in between the right ureter and rectosigmoid. The pre-sacral fat is cleared and the anterior longitudinal ligament exposed (Fig. 4). This area should be well inspected for presacral vessels, the inadvertent injury to which may lead to troublesome bleeding. Should this occur we prefer the use of bipolar cautery or Ligasure® (Covidien, Norwalk, CT, USA) to control hemorrhage.

Using an EEA placed transvaginally, the apex is identified and peritoneum over the cuff incised, allowing for dissection of the vesicovaginal and rectovaginal spaces (Fig. 5). A

polypropylene Y- shaped mesh is then passed through the assistant port. The mesh is tailored to ensure coverage of the anterior vaginal wall to a point just above the trigone, and the posterior wall to the level of the perineal body. The anterior limb is secured to the anterior vagina with 6 interrupted sutures of expanded PTFE or braided polyester suture (Fig. 6). Similarly, the posterior limb of the mesh is sutured to the posterior vagina, employing 8 sutures of the same (Fig. 7). Care is taken not to pass the stitch through full thickness vagina.

Next, the single arm of the Y- mesh is brought to the sacral promontory. Excess mesh is trimmed to the appropriate length (Fig. 8). Once the appropriate tension is set the, the mesh may be held with fixed tension with the fourth arm and sutured to the promontory with 2 to 4 interrupted sutures of expanded PTFE or braided polyester (Fig. 9).

Finally, the peritoneum is closed over the mesh to avoid bowel adhesions, potential erosion or small bowel obstruction (Fig. 10). This is accomplished with a running absorbable suture with a Lapra-Ty® (Ethicon Endo-Surgery, Albuquerque, NM, USA) fixed to the end (we prefer 2-0 piloglecaprone 25 stitch due to its relatively short persistence and ability to slide). The abdomen is inspected for bleeding or any unrecognized visceral injury. The vagina is inspected to confirm the apex is well supported.

The camera and robotic ports are subsequently decoupled from robotic arms and all ports removed under direct endoscopic visualization. We close both 12 mm ports with an interrupted suture of 0 polyglactin suture using the Carter-Thomason CloseSure System (Inlet Medical, Eden Prairie, MN, USA).

Patients are evaluated for ureteral patency postoperatively with cystoscopy following the intravenous administration of indigo carmine. An anti-incontinence procedure may also be performed at this time if stress urinary incontinence has been diagnosed preoperatively on urodynamic testing with prolapse reduction.

11. Innovations in robotic surgical techniques for apex suspension

Traditional docking of the robot patient cart often restricts access to the patient's perineum, a potential problem in those patients requiring concomitant vaginal and intracorporeal approaches. In this situation, side docking should be considered. Proper docking requires the patient cart to be aligned with the ipsilateral anterior superior iliac spine and midline camera port. Additionally, this technique may require lateral displacement of the 3rd robotic port, with the 4th port placed in the horizontal plane slightly above the camera site, bisecting the camera and 3rd ports (Fig. 11). We have recently adopted this technique for cases requiring simultaneous perineal and intraabdominal access, including robotic assisted laparoscopic creation of an ileal neovagina, finding overall good range of motion and relative ease of set up.

12. Conclusion

While level 1 evidence favors outcomes of abdominal sacrocolpopexy over sacrospinous ligament repairs, this comes with the attendant morbidity of a traditional open abdominal procedure. Robot assisted laparoscopic sacrocolpopexy offers the ability to support the apex in a fashion similar to the open approach with equal efficacy. This technique offers the advantages of a minimally invasive option using a modality the traditional open surgeon can adopt with a demonstrated steep but short learning curve.

13. References

- [1] Olsen AL, Smith VJ, Bergsrom JO et al. Epidemiology of surgically managed pelvic organ prolapse and urinary incontinence. *Obstet Gynecol* 1997; 89:501
- [2] Swift S, Woodman R, O'Boyle A et al. Pelvic Organ Support Study (POSST): the distribution, clinical definition, and epidemiologic condition of pelvic organ support defects. *Am J Obstet Gynecol* 2005; 192:795
- [3] Bump RC, Mattiasson A, Bo K et al. The standardization of terminology of female pelvic organ prolapse and pelvic floor dysfunction. *Am J Obstet Gynecol* 1996; 175:10
- [4] Hendrix SL, Clark A, Nygaard I et al. Pelvic organ prolapse in the Women's Health Initiative: gravity and gravidity. *Am J Obstet Gynecol* 2002; 186:1160
- [5] Delancey JOL. Surgical anatomy of the female pelvis, In: Rock JA, Thompson JD, eds. *TeLinde's Operative Gynecology*, ed 8. Philadelphia: Lippincott-Raven; 1997:63-93
- [6] Gosling JA, Dixon JS, Critchley HOD et al. A comparative study of the human external sphincter and periurethral levator ani muscles. *Br J Urol* 1981;53:35-41
- [7] Allen RE, Hosker GL, Smith ARB et al. Pelvic floor damage and childbirth: a neurophysiological study. *Br J Obstet Gynaecol* 1990;97: 770-779
- [8] Smith ARB, Hosker GL, Warrell DW. The role of partial denervation of the pelvic floor in the etiology of genitourinary prolapse and stress incontinence of urine. A neurophysiological study. *Br J Obstet Gynaecol* 1989;96:24-28
- [9] Chen HY, Chung YW, Lin WY et al. Collagen type 3 alpha 1 polymorphism and risk of pelvic organ prolapse. *Int J Gynecol Obstet* 2008;103:55-58
- [10] Brubaker L, Bump R, Fynes M et al. Surgery for Pelvic Organ Prolapse, In: Abrams P, Cardozo L, Khoury S et al. editors. *Incontinence, Management. Third International Consultation on Incontinence. Vol. 2*, Monaco: International Continence Society 2005. pp 1371-402, chapter 21
- [11] Shull BL, Bachofen C, Coats KW, et al. A transvaginal approach to repair of apical and other associated sites of pelvic organ prolapse with uterosacral ligaments. *Am J Obstet Gynecol* 2000;183:1365
- [12] Barber MD, Visco AG, Weidner AC et al. Bilateral uterosacral ligament vaginal vault suspension with site-specific endopelvic fascia defect repair for treatment of pelvic organ prolapse. *Am J Obstet Gynecol* 2000;183: 1402
- [13] Karram M, Goldwasser S, Kleeman S et al. High uterosacral vaginal vault suspension with fascial reconstruction for vaginal repair of enterocele and vaginal vault prolapse. *Am J Obstet Gynecol* 2001;185:1339
- [14] Richter K, Albright W. Long-term results following fixation of the vagina on the sacrospinous ligament by the vaginal route. *Am J Obstet Gynecol* 1981; 151: 811
- [15] Nichols DH. Sacrospinous fixation for massive eversion of the vagina. *Am J Obstet Gynecol* 1982; 142:901
- [16] Sze E, Miklos J, Patroll L, et al. Sacrospinous ligament fixation with transvaginal needle suspension for advanced pelvic organ prolapse and stress incontinence. *Obstet Gynecol* 1997; 98: 94
- [17] Shull BL, Capen CV, Riggs MW, et al. Bilateral attachment of the vaginal cuff to iliococcygeus fascia: an effective method of cuff suspension. *Am J Obstet Gynecol*.1993; 168:1669
- [18] Meeks GR, Washburne JF, McGehee RP, et al.. Repair of vaginal vault prolapse by suspension of the vagina to the iliococcygeus (prespinous) fascia. *Am J Obstet Gynecol* 1994; 171:1444-54

- [19] Amid PK. Classification of biomaterials and their complications in abdominal wall hernia surgery. *Hernia* 1997;1: 15
- [20] Cosson M, Debodinance P, Boukerrou M, et al. Mechanical properties of synthetic implants used in the repair of prolapse and urinary incontinence in women: which is the ideal material? *Int Urogynecol J Pelvic Floor Dysfunct.* 2003; 14:169
- [21] Diwadkar GB, Barber MD, Feiner B, et al. Complication and reoperation rates after apical vaginal prolapse surgical repair: a systematic review. *Obstet Gynecol* 2009; 113: 367
- [22] Sanses TVD, Shahryarinejad A, Molden S, et al. Anatomic outcomes of vaginal mesh procedure (Prolift) compared with uterosacral ligament suspension and abdominal sacrocolpopexy for pelvic organ prolapse: a Fellow's Pelvic Research Network study. *Am J Obstet Gynecol* 2009
- [23] Timmons MC, Addison WA, Addison SB, et al. Abdominal sacral colpopexy in 163 women with post hysterectomy vaginal vault prolapse and enterocele. Evolution of operative techniques. *J Reprod Med* 1992; 37: 323
- [24] Snyder TE, Krantz KE. Abdominal-retroperitoneal sacral colpopexy for the correction of vaginal prolapse. *Obstet Gynecol* 1991; 77:944
- [25] Maher C, Baessler K, Glazener CMA et al. Surgical management of pelvic organ prolapse in women (Review). The Cochrane Collaboration. The Cochrane Library 2007, Issue 2
- [26] Cundiff GW, Varner E, Visco AG, Zyczynski HM, Nager CW, Norton PA, Schaffer J, Brown MB, Brubaker L; Pelvic Floor Disorders Network. *Am J Obstet Gynecol* 2008; 199:e1-5.
- [27] Paraiso MFR, Walters MD, Rackley RR et al. Laparoscopic and abdominal sacral colpopexy: A comparative cohort study. *Am J Obstet Gynecol* 2005; 192:1752
- [28] Sarlos D, Brandner S, Kots L et al. Laparoscopic sacrocolpopexy for uterine and post-hysterectomy prolapse: anatomical results, quality of life and perioperative outcome - a prospective study with 101 cases. *Int Urogynecol J Pelvic Floor Dysfunct* 2008; 19:1415
- [29] Hsiao KC, Latchamsetty K, Govier FE et al. Comparison of laparoscopic and abdominal sacrocolpopexy for the treatment of vaginal vault prolapse. *J Endourol* 2007;21:926
- [30] Rozet F, Mandron E, Arroyo C et al. Laparoscopic sacral colpopexy approach for gentio-urinary prolapse: experience with 363 cases. *Eur Urol* 2005;47:230
- [31] Ross JW, Preston M. Laparoscopic sacrocolpopexy for severe vaginal vault prolapse: five-year outcome. *J Minim Invasive Gynecol* 2005;12:221
- [32] Elliott DS, Krambeck AE, Chow GK. Long-term results of robotic assisted laparoscopic sacrocolpopexy for the treatment of high grade vaginal vault prolapse. *J Urol* 2006;176:655
- [33] Di Marco DS, Chow GK, Gettman MT et al. Robotic-assisted laparoscopic sacrocolpopexy for treatment of vaginal vault prolapse. *Urology* 2004;63:373
- [34] Kramer BA, Whelan CM, Powell TM et al. Robotic-assisted laparoscopic sacrocolpopexy as management for pelvic organ prolapse. *J Endourol* 2009;23:655
- [35] Daneshgari F, Kefer JC, Moore C et al. Robotic abdominal sacrocolpopexy/sacrouteropexy repair of advanced female pelvic organ prolapse (POP): utilizing POP-quantification-based staging and outcomes. *BJU Int.* 2007; 100: 875

- [36] Akl MN, Long JB, Giles DL et al. Robotic – assisted sacrocolpopexy: technique and learning curve. *Surg Endosc* 2009 (27)
- [37] Kohli N, Walsh PM, Roat TW et al. Mesh erosion after abdominal sacrocolpopexy. *Obstet Gynecol* 1998;92:999
- [38] Geller EJ, Siddiqui NY, Wu JM et al. Short-term outcomes of robotic sacrocolpopexy compared with abdominal sacrocolpopexy. *Obstet Gynecol* 2008;112:1198
- [39] Chang FH, Lee CL, Soong YK. Use of Palmer's Point for Insertion of the Operative Laparoscope in Patients with Severe Pelvic Adhesions: Experience of Seventeen Cases. *J Am Assoc Gynecol Laparosc* 1994;1:S7

Figures

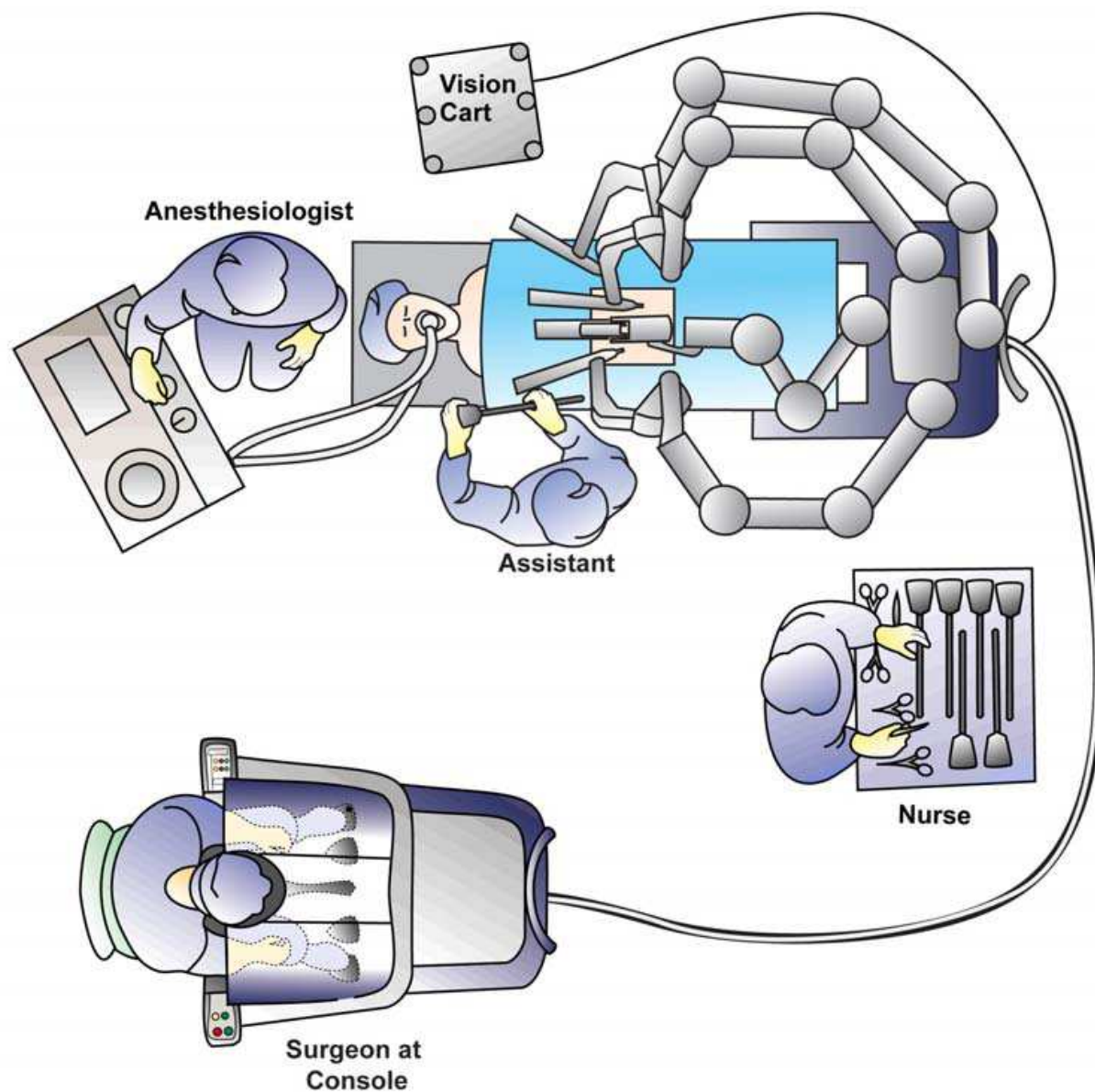


Fig. 1. Operating room configuration

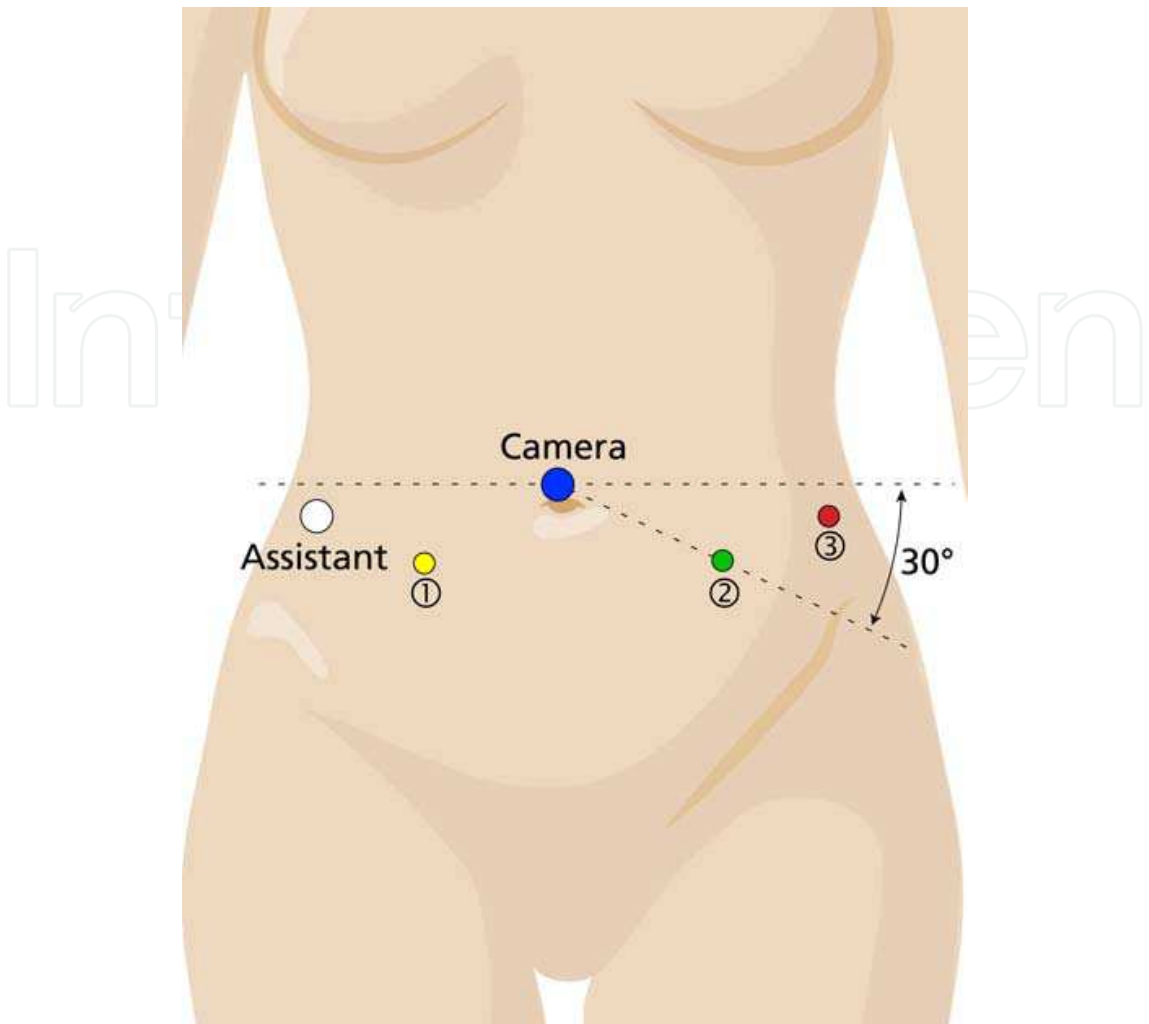


Fig. 2. Port placement for RALSC (4-arm DaVinci)

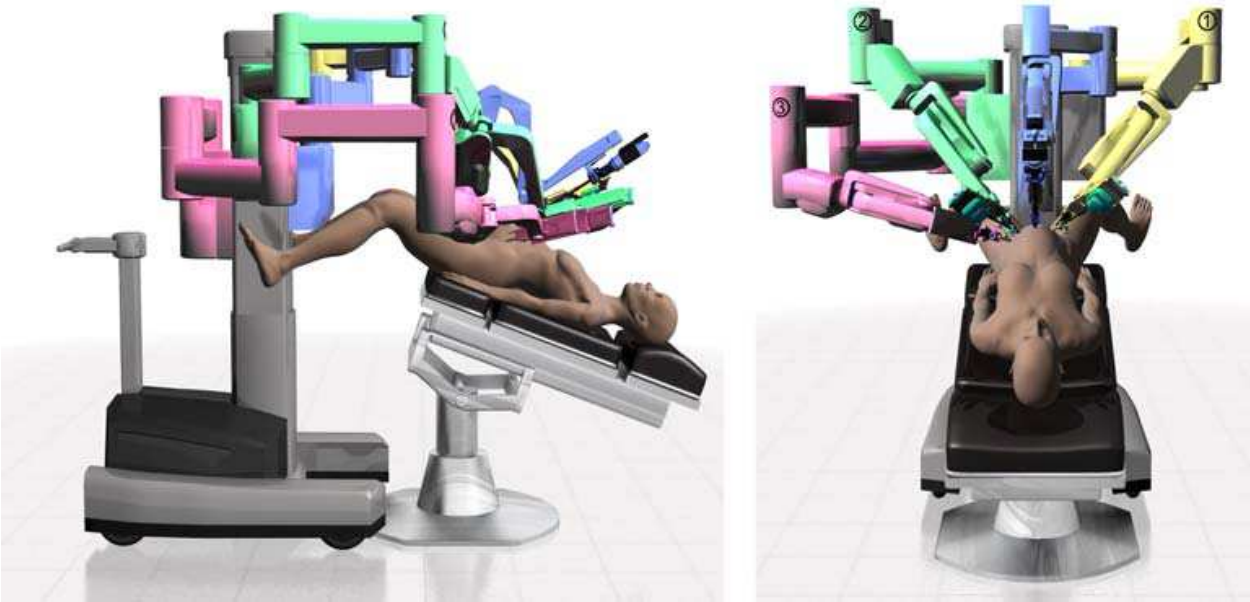


Fig. 3. Patient positioning and patient cart docking of 4-arm DaVinci

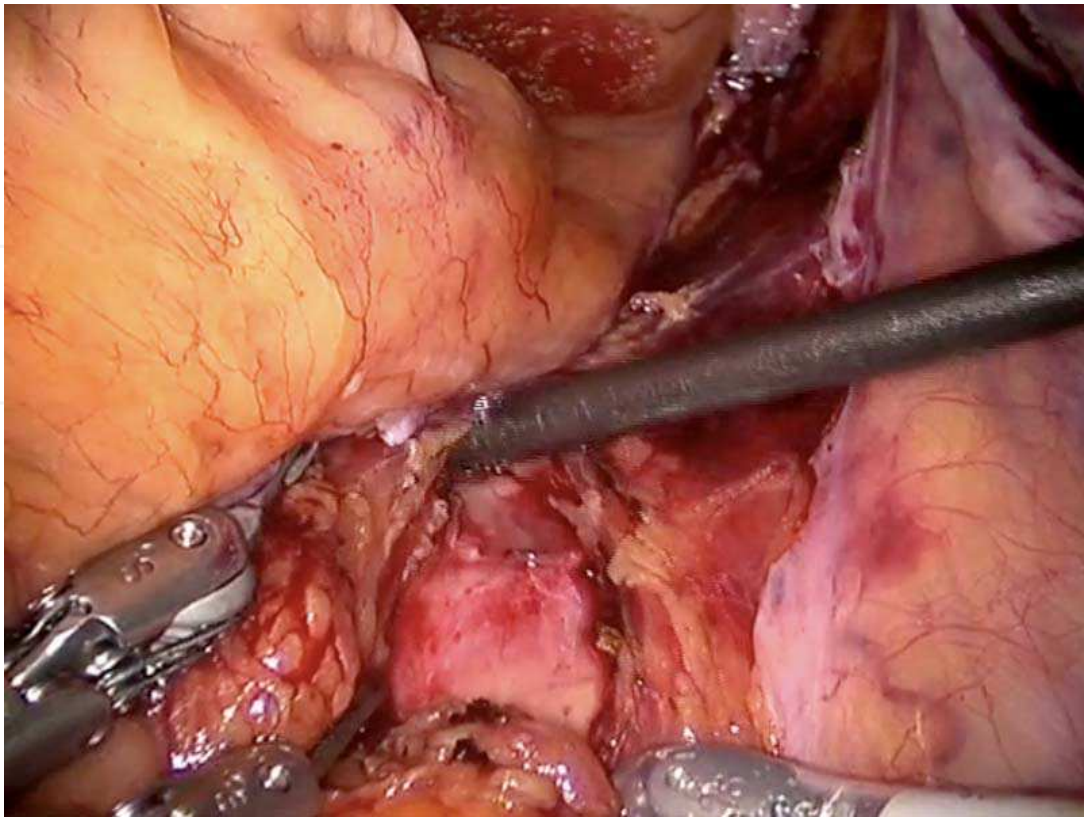


Fig. 4. Exposed anterior longitudinal ligament over sacral promontory

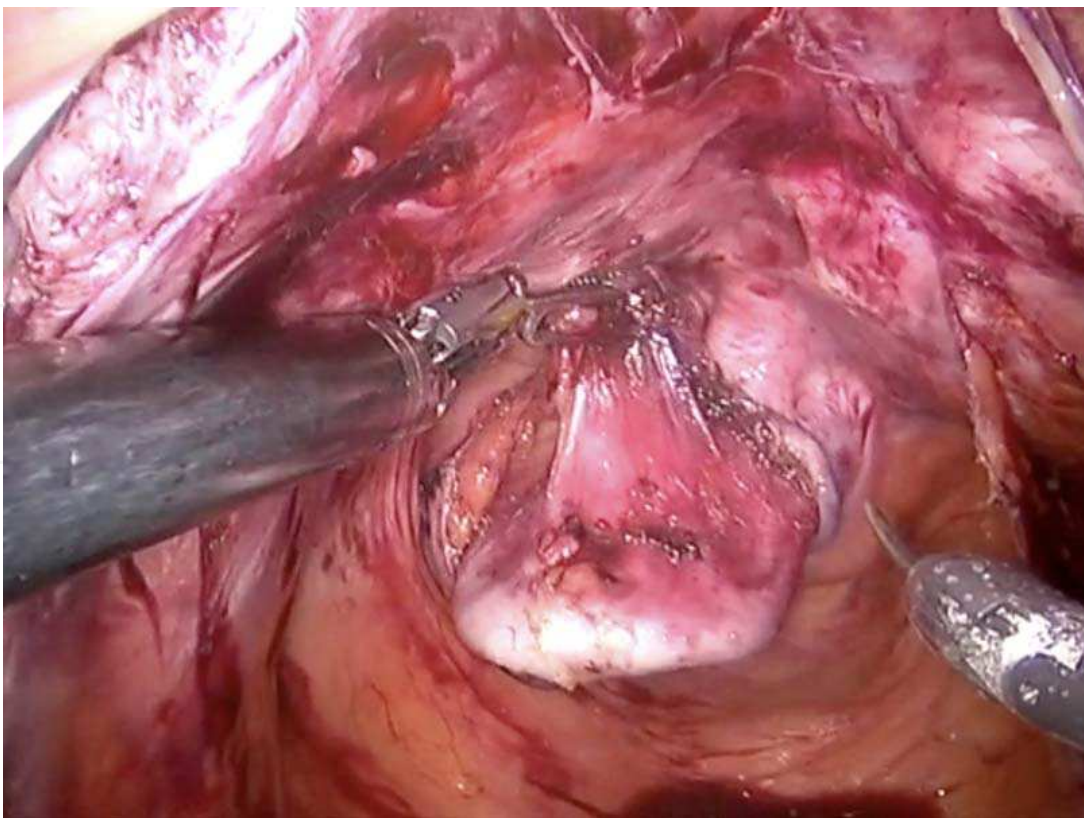


Fig. 5. Dissecting peritoneum from vaginal cuff

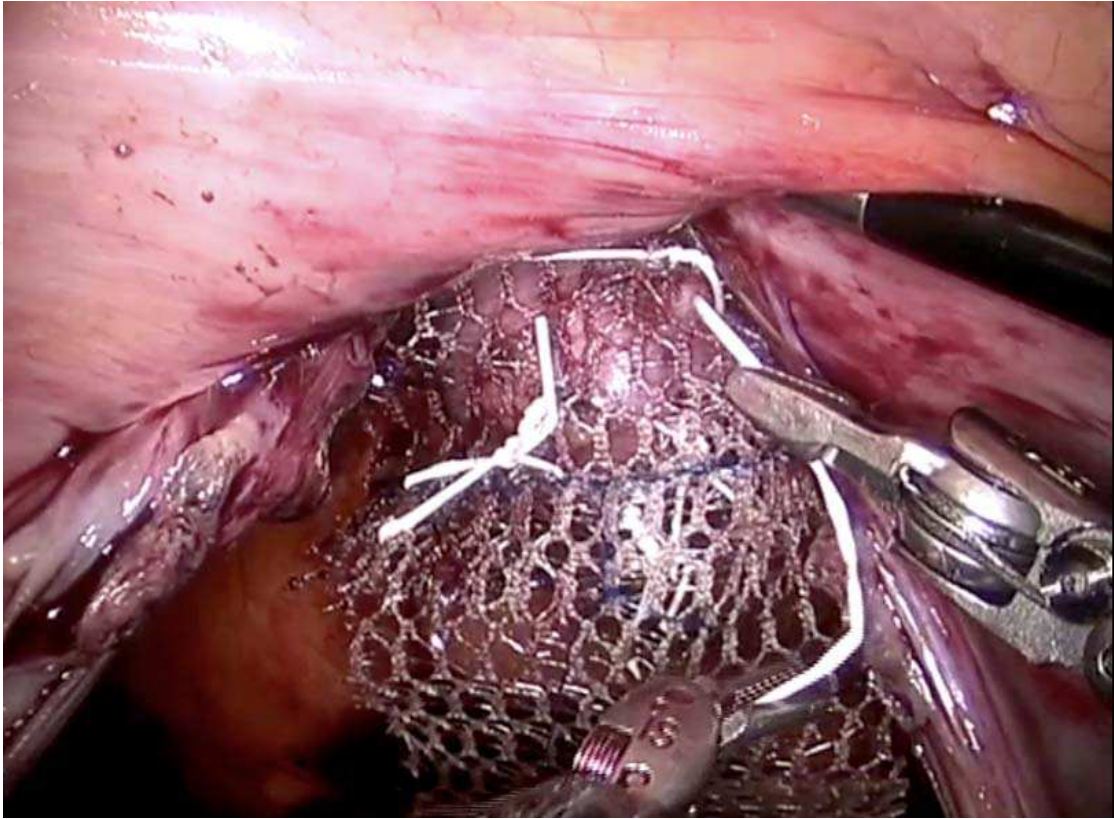


Fig. 6. Securing mesh to anterior vaginal wall

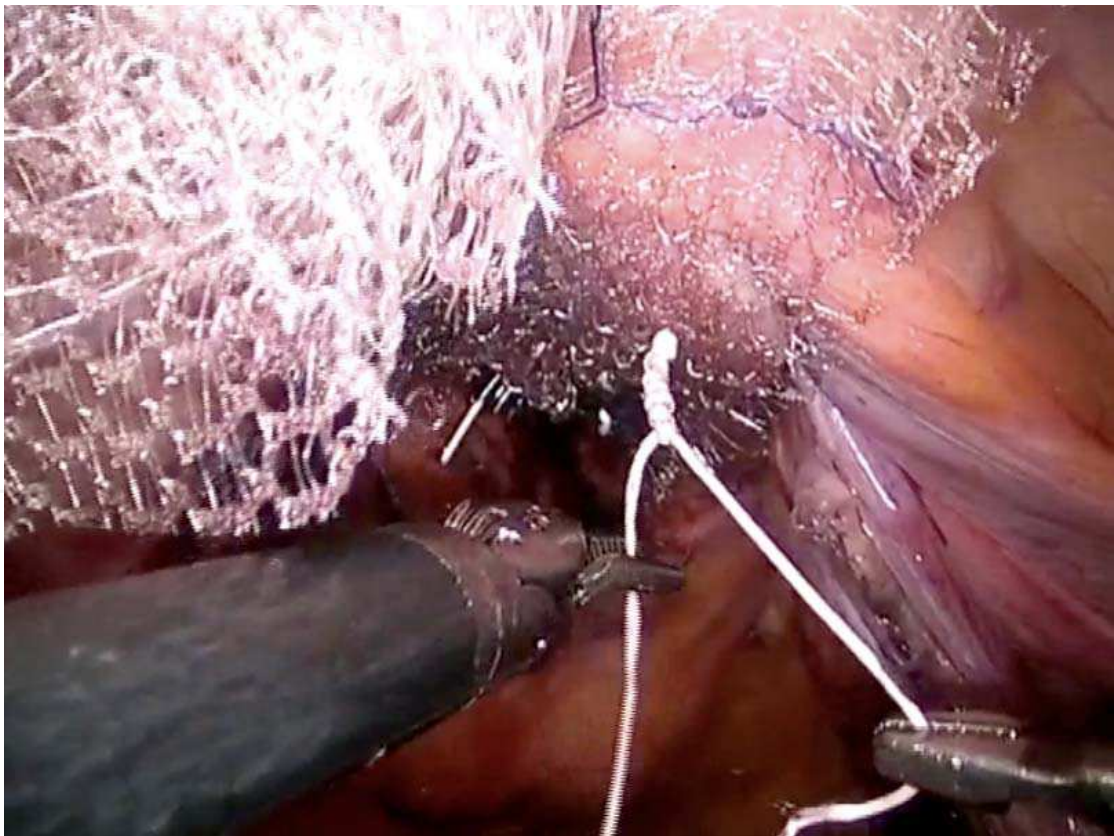


Fig. 7. Securing mesh to posterior vaginal wall

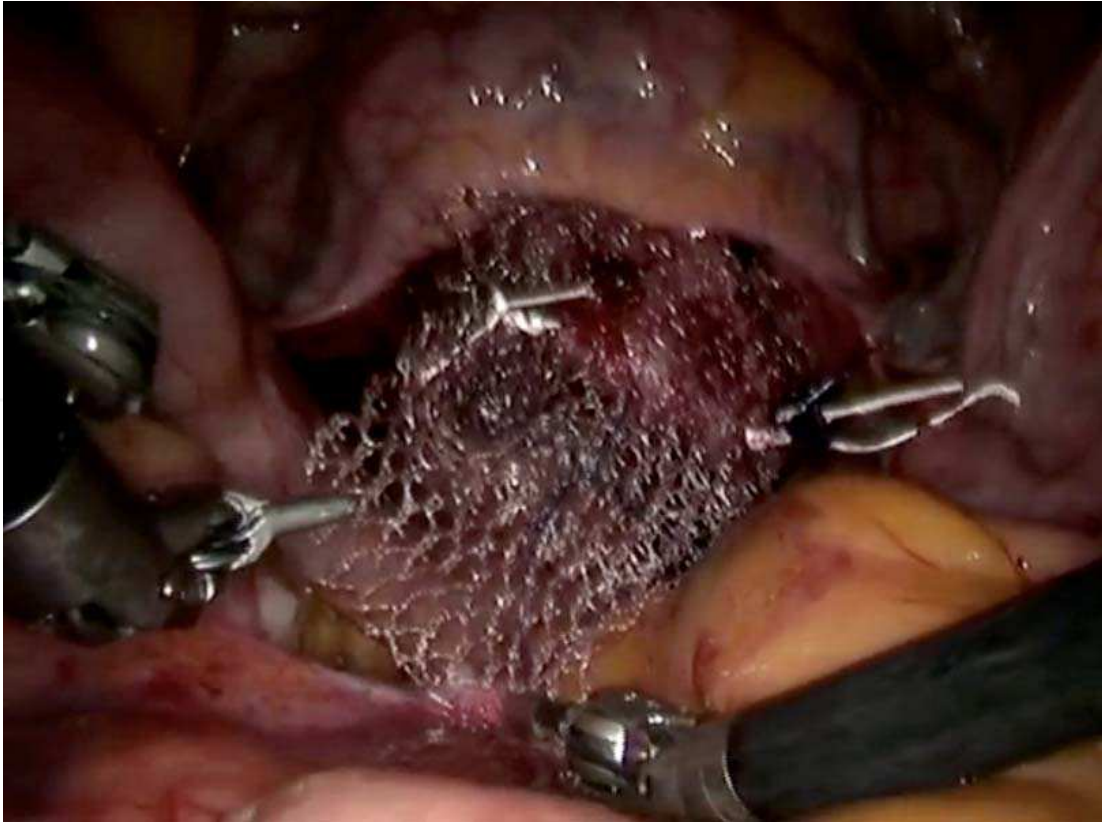


Fig. 8. Mesh trimmed to appropriate size

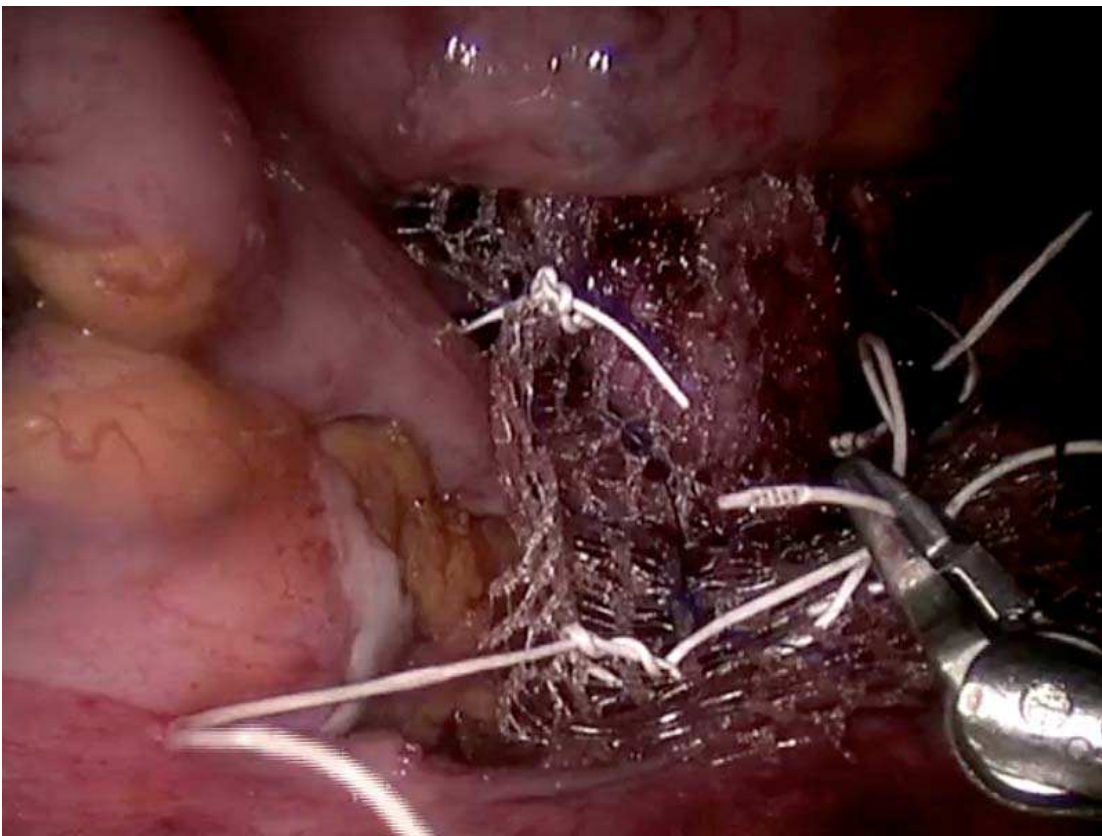


Fig. 9. Securing mesh to sacral promontory

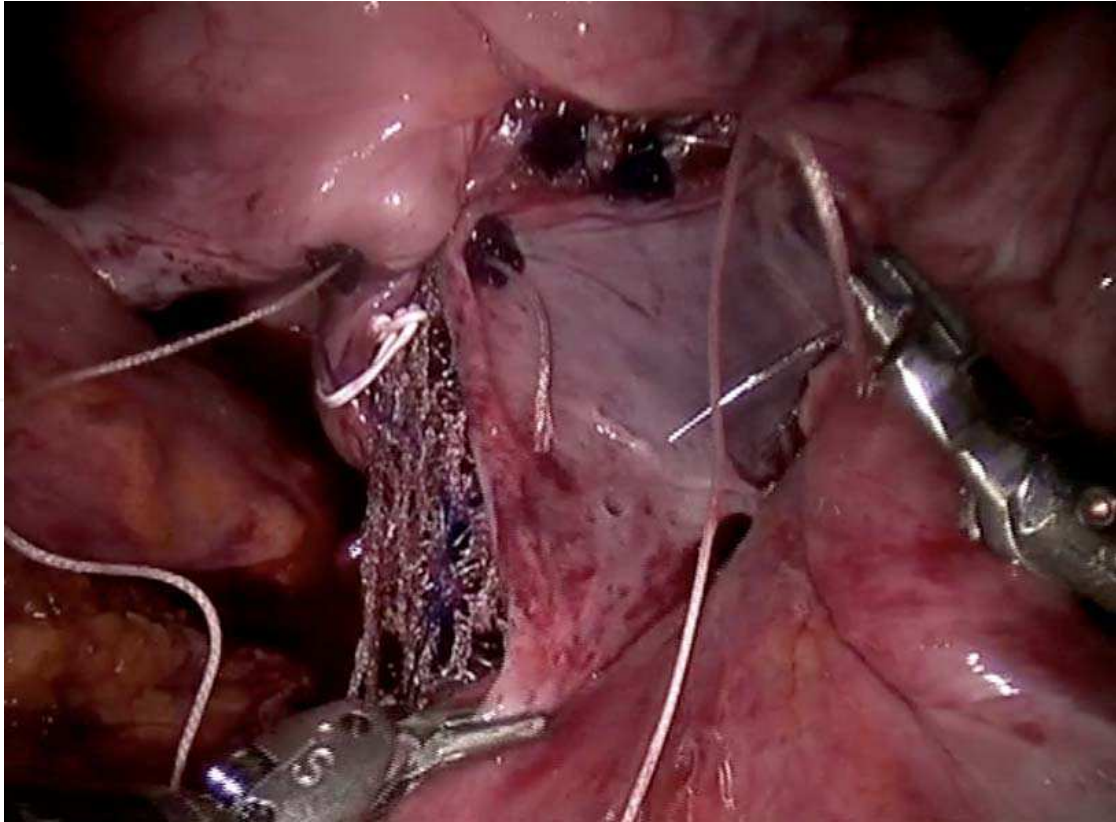


Fig. 10. Closure of peritoneum over mesh




Fig. 11. Alternative side-docking 4-arm DaVinci for pelvic surgery



Robot Surgery

Edited by Seung Hyuk Baik

ISBN 978-953-7619-77-0

Hard cover, 172 pages

Publisher InTech

Published online 01, January, 2010

Published in print edition January, 2010

Robotic surgery is still in the early stages even though robotic assisted surgery is increasing continuously. Thus, exact and careful understanding of robotic surgery is necessary because chaos and confusion exist in the early phase of anything. Especially, the confusion may be increased because the robotic equipment, which is used in surgery, is different from the robotic equipment used in the automobile factory. The robots in the automobile factory just follow a program. However, the robot in surgery has to follow the surgeon's hand motions. I am convinced that this In-Tech Robotic Surgery book will play an essential role in giving some solutions to the chaos and confusion of robotic surgery. The In-Tech Surgery book contains 11 chapters and consists of two main sections. The first section explains general concepts and technological aspects of robotic surgery. The second section explains the details of surgery using a robot for each organ system. I hope that all surgeons who are interested in robotic surgery will find the proper knowledge in this book. Moreover, I hope the book will perform as a basic role to create future prospectives. Unfortunately, this book could not cover all areas of robotic assisted surgery such as robotic assisted gastrectomy and pancreaticoduodenectomy. I expect that future editions will cover many more areas of robotic assisted surgery and it can be facilitated by dedicated readers. Finally, I appreciate all authors who sacrificed their time and effort to write this book. I must thank my wife NaYoung for her support and also acknowledge MiSun Park's efforts in helping to complete the book.

How to reference

In order to correctly reference this scholarly work, feel free to copy and paste the following:

James C Brien, Michael D Fabrizio and James C Lukban (2010). Robotic Sacrocolpopexy and Sacrocervicopexy for the Correction of Pelvic Organ Prolapse, Robot Surgery, Seung Hyuk Baik (Ed.), ISBN: 978-953-7619-77-0, InTech, Available from: <http://www.intechopen.com/books/robot-surgery/robotic-sacrocolpopexy-and-sacrocervicopexy-for-the-correction-of-pelvic-organ-prolapse>

INTECH
open science | open minds

InTech Europe

University Campus STeP Ri
Slavka Krautzeka 83/A
51000 Rijeka, Croatia
Phone: +385 (51) 770 447

InTech China

Unit 405, Office Block, Hotel Equatorial Shanghai
No.65, Yan An Road (West), Shanghai, 200040, China
中国上海市延安西路65号上海国际贵都大饭店办公楼405单元
Phone: +86-21-62489820

www.intechopen.com

Fax: +385 (51) 686 166
www.intechopen.com

Fax: +86-21-62489821

IntechOpen

IntechOpen

© 2010 The Author(s). Licensee IntechOpen. This chapter is distributed under the terms of the [Creative Commons Attribution-NonCommercial-ShareAlike-3.0 License](https://creativecommons.org/licenses/by-nc-sa/3.0/), which permits use, distribution and reproduction for non-commercial purposes, provided the original is properly cited and derivative works building on this content are distributed under the same license.

IntechOpen

IntechOpen