

# We are IntechOpen, the world's leading publisher of Open Access books Built by scientists, for scientists

6,900

Open access books available

185,000

International authors and editors

200M

Downloads

Our authors are among the

154

Countries delivered to

TOP 1%

most cited scientists

12.2%

Contributors from top 500 universities



WEB OF SCIENCE™

Selection of our books indexed in the Book Citation Index  
in Web of Science™ Core Collection (BKCI)

Interested in publishing with us?  
Contact [book.department@intechopen.com](mailto:book.department@intechopen.com)

Numbers displayed above are based on latest data collected.  
For more information visit [www.intechopen.com](http://www.intechopen.com)



# Primary Spontaneous Pneumothorax, a Clinical Challenge

*Fabian Andres Giraldo Vallejo, Rubby Romero, Melissa Mejia and Estefania Quijano*

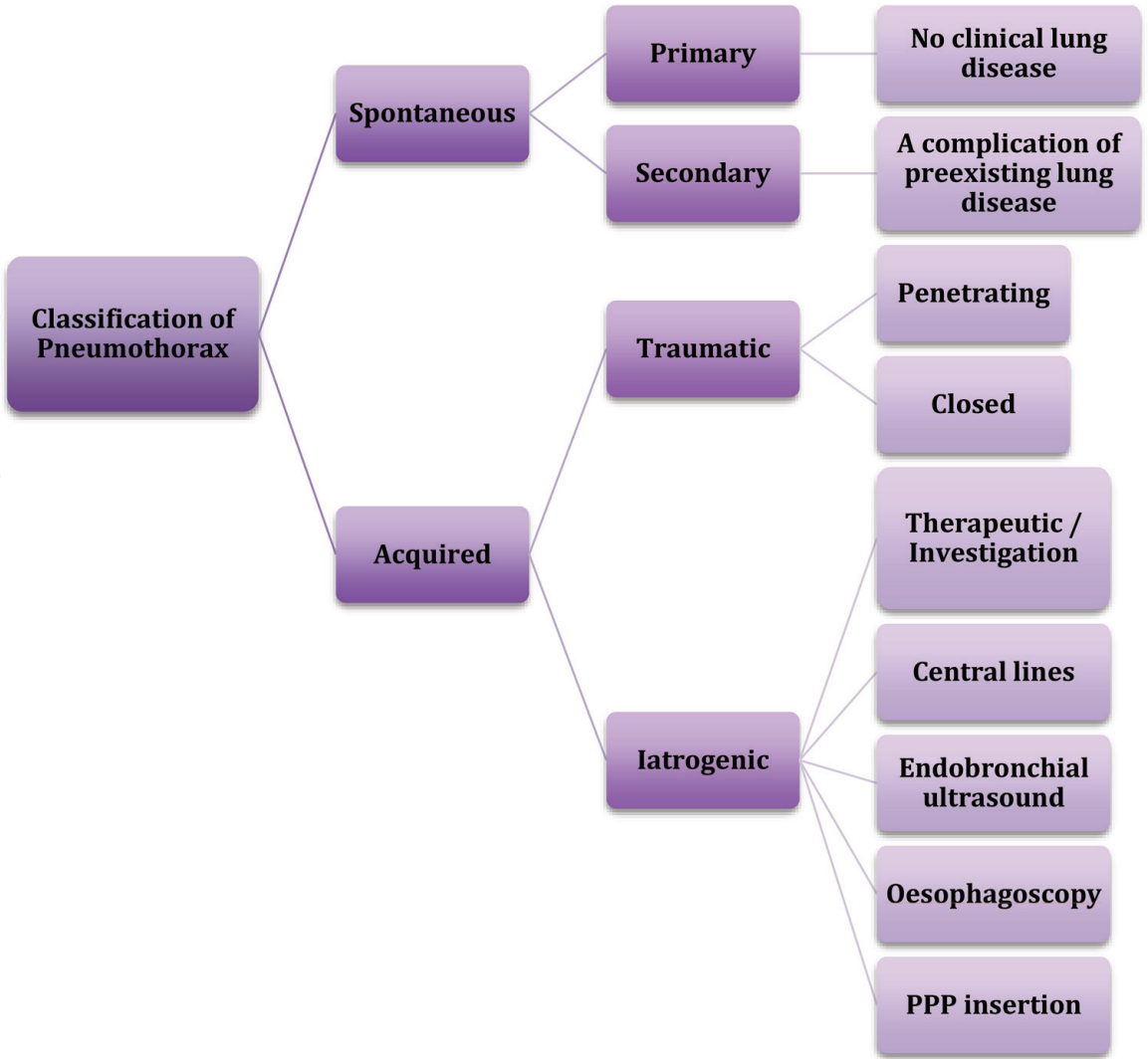
## Abstract

Primary spontaneous pneumothorax (PSP) is a common disease in medical practice that affects young healthy people with a significant recurrence rate. PSP is the presence of air in the pleural space not caused by injury or medical intervention. Some risk factors include male gender, age, and smoking. Classic clinical presentation starts with acute-onset chest pain and shortness of breath. Physical examination can be normal in small pneumothoraces, but in larger pneumothoraces, breath sounds and tactile fremitus are typically decreased or absent, and percussion is hyperresonant. Chest X-ray can help confirm the diagnosis. Evacuation of air from the pleural cavity and prevention of future recurrences are the primary goals of treatment and depend on the patient's presentation. Initial deciding factors to direct the management are first-time or recurrent spontaneous pneumothorax and size of the pneumothorax. Treatment may include conventional chest tube drainage, video-assisted thoracoscopic surgery (VATS), or open surgery.

**Keywords:** pneumothorax, pleural cavity, chest tube drainage, video-assisted thoracoscopic surgery

## 1. Introduction

Pneumothorax is defined as an abnormal collection of air in the pleural cavity, which is a potential space between the two pleurae (visceral and parietal) of the lungs [1]. Itard, a student of Laennec, first coined pneumothorax in 1803, but it was not until 1932 that it was realized that spontaneous pneumothorax was not always caused by tuberculosis. Pneumothorax is classified as spontaneous, traumatic, or iatrogenic (**Figure 1**). Primary spontaneous pneumothorax (PSP) occurs in patients without underlying lung disease or without a precipitating event, and it is a common disease in medical practice with a significant global health problem affecting adolescent and young adults. Notwithstanding the absence of pulmonary disease, many of these patients have asymptomatic subpleural blebs and bullae; they are found in up to 90% of cases at thoracoscopy or thoracotomy and in up to 80% of cases on CT scanning of the thorax [2]. PSP is a benign condition, which resolves spontaneously in the majority of cases [3]. Secondary spontaneous pneumothorax is a complication of a preexisting lung disease and the major causes in descending order are airway disease (chronic obstructive pulmonary disease or cystic fibrosis),



**Figure 1.**  
*Classification of pneumothorax. Adapted from Noppen M. European Respiratory Review. 2010;19:217–219.*

infectious lung disease, interstitial lung disease (sarcoidosis), connective tissue disease (Marfan syndrome or Ehlers-Danlos syndrome), cancer, and thoracic endometriosis. Traumatic pneumothorax is caused by penetrating and non-penetrating (blunt) trauma to the chest. Iatrogenic pneumothorax results from a complication of a diagnostic or therapeutic intervention [4].

The most important risk factor of primary spontaneous pneumothorax is tobacco smoking, and the number of cigarettes smoked per day contributes to the increased risk. Cannabis smoking is associated with bullous disease. Smoking suspension is the only modifiable risk factor for recurrence of PSP. Catamenial pneumothorax is a rare condition associated with the presence of thoracic endometriosis and affects women before or after 72 hours of the start of menstruation. Other risks include male gender and age with peaking between 15 and 34 years. Clinical presentation in patients with spontaneous pneumothorax depends on the size of pneumothorax. PSP may be asymptomatic or may be suspected by typical clinical features. The most common symptoms are abrupt onset of chest pain and breathlessness; the findings on physical exam may include absent breath sounds, reduced ipsilateral chest expansion, and hyperresonant percussion [5]. The presence of hypotension and tachycardia may indicate tension pneumothorax that occurs when the intrapleural pressure exceeded atmospheric pressure, caused mediastinal deviation, and reduced venous return and cardiovascular collapse [6]. The diagnosis is suggested by patient’s history and findings on examination and is confirmed with chest X-ray;

the radiographic sign is the displacement of the pleural line and an absence of lung markings between the edge of the pleura and chest wall. Computed tomography (CT) provides sensitive and specific imaging for the detection of pneumothorax, but it is not recommended routinely except if loculated pneumothorax or lung disease is suspected. The diagnosis may be clearly made on a chest radiograph, and an excess radiation dose should be avoided in this young patient population [7].

The difference between primary, secondary, traumatic, and iatrogenic pneumothorax is important to be defined because of the different management strategies required for their treatment. The goal of treatment is to remove the air from the pleural space and decrease the recurrence. Management options range from observation to aspiration or drainage to thoracic surgical intervention and is guided by presenting symptoms: hemodynamic compromise, size and cause of pneumothorax. As well as it is the first time or recurring pneumothorax. PSP can be treated conservatively; patients with first episode who are asymptomatic and have a small pneumothorax need simple clinical observation, analgesia, and oxygen therapy that increased the rate of reabsorption. The removal of air from the pleural space can be achieved with needle aspiration or chest drain insertion [7, 8]. Simple aspiration and chest tube drainage are the most frequently used methods for the initial treatment of primary spontaneous pneumothorax. Aspiration should be the primary treatment in uncomplicated cases; the insertion of an aspiration catheter is easier and safer than chest tube drainage and is recommended in the guidelines. Chest tube drainage is the most popular and recommended air evacuation technique, but this method does not provide any definitive recurrence prevention [9, 10]. Video-assisted thoracic surgery (VATS) is a minimally invasive procedure, and its advantages include less postoperative pain, better postoperative pulmonary function, shorter length of hospital stay, and less invasive than thoracotomy. Thoracoscopic evaluation of primary pneumothorax shows that this disorder is regularly associated with apical subpleural blebs or bullae. Pleurodesis, either mechanical or chemical, using talc has to be applied to decrease the risk of recurrence of PSP [11, 12]. Open thoracotomy plus pleurectomy are used in the case of recurrent ipsilateral PSP, simultaneous bilateral PSP, an episode of PSP following a previous episode of contralateral PSP, first episode of tension pneumothorax, significant spontaneous hemopneumothorax at first episode, persistent air leak through the chest tube for more than 5–7 days, or failure of the lung to re-expand despite adequate pleural space drainage in the first episode. Open surgery has the lower recurrence rate [13]. The main complication of primary spontaneous pneumothorax is recurrence, which is greater after conservative treatment. Some risk factors for recurrence are younger age, male sex, and low body mass index [14]. A preventive procedure like thoracotomy or thoracoscopy plus pleurodesis may be recommended after the first episode of pneumothorax, with the objective to reduce the rate of recurrence. Some agents have been investigated for pleurodesis, but talc poudrage has presented the best results until now [15].

## 2. Epidemiology

Pneumothorax is defined as the presence of air in the pleural space. For air to enter into the pleural space from the capillary blood would require pleural pressure lower than  $-54$  mmHg ( $< -36$  cm H<sub>2</sub>O), which is difficult to obtain in normal circumstances [16].

If air is present in the pleural space, some of these events may have occurred:

1. Communication between alveola and pleura

2. Communication between the atmosphere (direct or indirect) and the pleural space
3. Presence of gas-producing organisms in the pleural space

PSP has an incidence of 7.4 to 18 cases per 100,000 population each year in males and 1.2 to 6 cases per 100,000 populations each year in females [17, 18]. Risk factors for PSP include tall thin people, male sex, and smoking. The recurrence range is 25–50%, and most recurrences occur in the first year [19]. Female gender, tall male, low body weight, and persistent smoking are associated with a high rate of recurrence [20]. In the largest epidemiologic study of PSP from Bobbio et al. with 42,595 patients, they found that the mean age was significantly greater in women than in men ( $41 \pm 19$  vs.  $37 \pm 19$   $p < 0.0001$ ), rehospitalization was more frequent in women than in men in patients aged  $<50$  years ( $p < 0.0001$ ). In the 50–64 years age group, surgical procedures and rehospitalizations were more frequent in men than in women ( $p = 0.002$  and  $p < 0.0001$ , respectively). The most commonly performed procedures were thoracoscopic resection of blebs (52% of cases) and talc pleurodesis (24% of cases). Surgery was associated with younger age, secondary pneumothorax, and ICU surveillance ( $p < 0.001$ ) [21]. Moderate smoking (22 cigarettes/day) increases the risk of first episode of PSP up to 22 times. PSP usually occurs at rest, so the lack of physical activity should be avoided in the counseling of these patients [17]. Thoracic endometriosis may lead to catamenial pneumothorax and should be considered in women with PSP temporally related to menstruation [22]. Malnutrition in patients with anorexia nervosa may lead to the development of PSP. Birt-Hogg-Dubé syndrome (which predisposes patients to benign skin tumors and renal cancers) is an autosomal dominant condition defined as a rare cause of PSP [23]. Precipitating factors include atmospheric pressure changes and exposure to loud music [24, 25].

An increased frequency of PSP is seen in patients with Marfan syndrome and homocystinuria. Marfan syndrome is a common inherited connective tissue disorder with typical skeletal, ocular, and cardiovascular manifestations. Pulmonary involvement occurs less frequently, with PSP being the most frequently reported. Karpman et al.'s study in 2011 found a prevalence of pneumothorax in patients with Marfan syndrome between 0 and 11%. The increased risk of pneumothorax has been attributed to the presence of apical blebs, bullae, and abnormal connective tissue constituents in the lung parenchyma or increased mechanical stresses in the lung apices due to the tall body habitus. Patients who have Marfanoid features such as long stature, hyperextendable joints, and dislocated lens should be studied by CT scanning to identify blebs and bullae. This may allow risk stratification for pneumothorax in patients with this syndrome and also favors identification of aortic root disease, which leads to aneurysmal dilation, aortic regurgitation, and dissection [26, 27]. A multidisciplinary approach is fundamental in these patients and their family, who must be thoroughly investigated, to confirm the disease and to initiate the treatment, thus decreasing mortality, especially due to cardiovascular causes; also a medical genetics consultation should be provided for genetic counseling [28].

PSP recurrence rates are typically cited as between 16 and 52%, which makes counseling about future risk difficult and creates uncertainty regarding the optimal management. Thoracic Society guidelines advise that pneumothorax recurrence is an indication for surgery (whether second ipsilateral or first contralateral) [29]. Unfortunately, there is no consensus on which treatment offers the best reduction in risk of recurrence [6]. A systematic review demonstrates a 32% PSP recurrence rate, with almost all the risk in the first year. Recurrence rates



did not differ based on the initial intervention for PSP. Female sex was associated with higher risk, suggesting possible sex-specific pathophysiology. Also lower BMI and radiological evidence of dystrophic lungs were associated with higher risk of recurrence (bullae on computed tomography (CT) and pleural thickening on chest radiography), until smoking cessation was associated with a fourfold decrease in risk [30].

### **3. Clinical presentation**

Symptoms in primary spontaneous pneumothorax may be minimal or absent. These clinical symptoms depend on proportion and the size of the pneumothorax. Patients may present an abrupt onset of pleuritic chest pain associated with dyspnea and shortness of breath, and some patients may experience shoulder tip pain [29]. Severe symptoms are not common, and when this happens it suggests a tension pneumothorax. Typical examination findings in primary spontaneous pneumothorax include ipsilateral decreased breath sounds on auscultation, percussion hyperresonance, and thoracic hypoexpansion. The presence of observable breathlessness has influenced subsequent management in previous guidelines [29, 31]. Hemodynamic compromise is unusual in PSP. Arterial blood gas measurements are frequently abnormal in patients with pneumothorax. Arterial oxygen tension is lower according to the extent of the pneumothorax but oxygen saturations are adequate, and pulmonary function tests are poor predictors of the presence or size of a pneumothorax [32].

The clinical features in tension pneumothorax are shortness of breath, dyspnea, tachypnea, respiratory distress, hypoxemia, hypotension, tachycardia and ipsilateral decreased air entry, and percussion hyperresonance. This condition requires an urgent thoracic decompression when the diagnosis is suspected, and the clinicians should be prepared to perform urgent thoracic decompression without chest radiographic confirmation in these patients [31].

### **4. Diagnosis**

#### **4.1 Plain chest X-ray**

The diagnosis of pneumothorax is usually confirmed by imaging techniques such as PA chest radiograph, and the excess radiation dose should be avoided in this young patient population. The diagnostic hallmark is the displacement of the pleural line. The pneumothorax is most frequently seen at the lung apex, but lateral, subpulmonic, and medial collections of air can also be seen [33]. Chest X-ray is the first diagnostic evaluation imaging being used, but small-sized pneumothoraces or loculated pneumothoraces can be missed on chest X-ray. If a pneumothorax is suspected and is unrevealed on chest X-ray, a more specific diagnostic imaging like chest computed tomography (CT) is necessary [34].

#### **4.2 Ultrasonography**

Ultrasound is a sensitive technique in the evaluation of respiratory diseases and was first used to diagnose pneumothorax in humans in 1987. Ultrasound is commonly used in emergency department with trauma patients and show significantly higher and quicker diagnostic accuracy than chest radiographs in these patients [35]. The routine use of ultrasound in PSP is not established.

### 4.3 CT and its indications

CT scanning is recommended for uncertain or complex cases and is useful in the detection of small pneumothoraces and size estimation. Emphysema, bullous lung, and another lung pathology are identified [29]. Chest CT is helpful in understanding the extent of the underlying lung parenchyma distraction. Some patients presented a loculated pneumothorax or pulmonary air cysts [34].

### 4.4 Size of pneumothorax

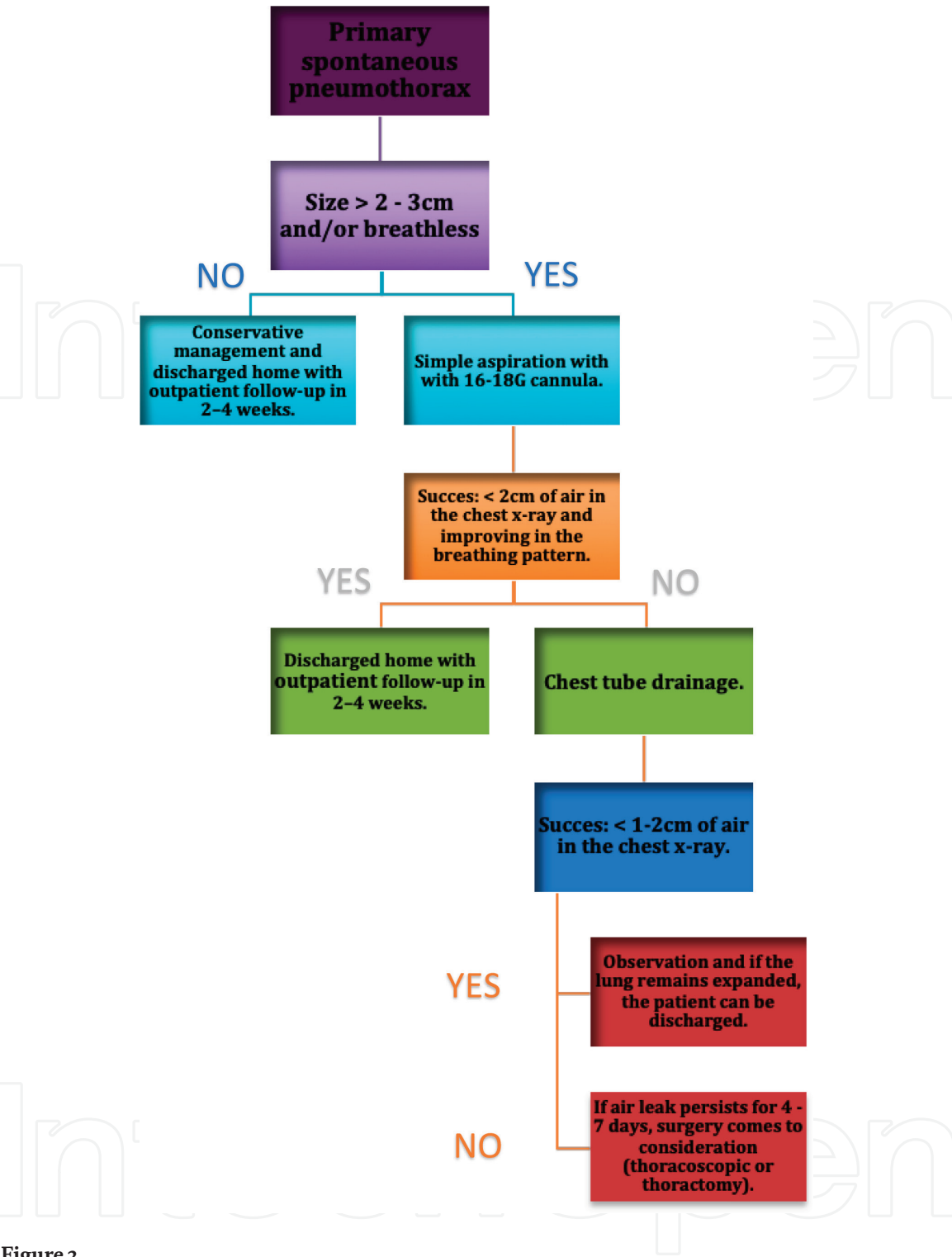
The clinical manifestations and evaluation are more important than the size of pneumothorax and do not correlate with the proportion of the pneumothorax [29]. The size of a pneumothorax is classified into three groups:

- Small is defined as small rim of air around the lung.
- Moderate is defined as collapsed halfway toward the heart border.
- Complete is defined as airless lung, separate from the diaphragm [2].

The difference of a small or large pneumothorax depends on the presence of visible rim  $<2$  cm between the lung margin and the chest wall [29]. PA chest X-ray has been used to quantify the size of the pneumothorax. A commonly used method for estimating pneumothorax size is the light index. This method assumes that the volume of a pneumothorax approximates to the ratio of the cube of the lung diameter to the hemithorax diameter. This volume of pneumothorax can be calculated in percentage [36]. Some guidelines from the USA estimated the volume of a pneumothorax by measuring the distance from the lung apex to the cupola, and some British guidelines estimated the volume by measuring the interpleural distance at level of the hilum [29]. Pneumothorax size calculations are best achieved by CT scanning but are only recommended for difficult cases [36].

## 5. Treatment

Primary spontaneous pneumothorax can be treated conservatively or by intervention that include simple aspiration, chest tube drainage, thoracoscopy, and thoracotomy [37]. A lot of issues must be taken into consideration in the management of spontaneous pneumothorax. Studies have shown numerous approaches offered by different guidelines and associations. According to the American College of Chest Physicians (ACCP), the British Thoracic Society (BTS), and the Spanish Society of Pulmonology and Thoracic Surgery, the initial management of the primary spontaneous pneumothorax is directed to remove air from the pleural space and prevent recurrences [1, 38]. Treatment options for primary spontaneous pneumothorax go from simple observation, aspiration with a catheter, insertion of a chest tube, pleurodesis, thoracoscopy, video-assisted thoracoscopic surgery (which is one of the most studied approaches) to thoracotomy. Selection of the appropriate approach depends on the size of the pneumothorax, the severity of the symptoms, and the presence or absence or persistent air leak (**Figure 2**). An initial step in the management of primary spontaneous pneumothorax is to evaluate the patient hemodynamic stability and risk. When the patient is hemodynamically unstable and/or the pneumothorax is bilateral, chest drain should be performed. If the patient is hemodynamically stable, different approaches can be chosen [38].



**Figure 2.**  
*Management of primary spontaneous pneumothorax [29].*

### 5.1 Conservative management

Clinically stable patients with small pneumothoraces can be treated with conservative management, and they should stay in the emergency room with a control chest radiograph to perceive the resolution of pneumothorax. Conservative management consists of observing the patient, oxygen therapy, and analgesia [39]. In the case of symptomatic and/or large pneumothoraces, it is indicated to remove the air from the pleural space by simple aspiration or chest tube drainage [40]. Patients with a first episode of primary spontaneous pneumothorax that are hemodynamically stable, with few or no symptoms, and have a small pneumothorax (<2–3 centimeters between the lung and the chest wall or <15% of hemithorax) can be



treated by supplemental oxygen, which accelerates the process of reabsorption of air by the pleura. The observation period should be at least 6 hours; after this time, the patient can be discharged if three conditions are met: absence of progression of the pneumothorax confirmed by a control chest radiograph, compliance of the outpatient treatment plans, and ease of access to emergency medical services. In these cases, the follow-up after discharge should be from 2 to 4 weeks [41].

## **5.2 Aspiration**

Patients with a first episode of primary spontaneous pneumothorax episode, which are hemodynamically stable and have a large pneumothorax (more than 2–3 centimeters of air in chest X-ray or more than 15% of the hemithorax) or those who have a progressive pneumothorax, or symptomatic with chest pain, or dyspnea should undergo needle aspiration [29, 42]. Several methods are used to perform simple aspiration, ranging from intravenous catheters in the second intercostal space in the midclavicular line with 16–18G cannula to chest tubes that can be removed once re-expansion of the lung is confirmed [43]. When the procedure is successful (less than 2 centimeters of air in the chest X-ray and improving in the breathing pattern), the patient can be discharged, with follow-up from 2 to 4 weeks. Simple aspiration is successful in 70% of the patients with moderate-sized primary pneumothorax; in patients older than 50 years or aspirations bigger than 2.5 liters, this method is likely to fail [38].

## **5.3 Thoracostomy only**

Primary spontaneous pneumothorax may also be managed with a chest tube that is left in place for 1 or more days or by attaching the catheter to a one-way Heimlich valve or water-seal device and using it as a chest tube. The last method is reserved for patients in whom Heimlich valves fail or those who have coexisting respiratory conditions that reduce the ability to tolerate a recurrent pneumothorax [38]. After treatment, persistent air leaks are not common in primary spontaneous pneumothorax. Seventy five percent of air leaks resolve after 7 days, and 100% resolve after 15 days [38]. When the air leak persists for 4 to 7 days, surgery comes to consideration. In a study from Kim, selection of patients with primary spontaneous pneumothorax and persistent air leaks for immediate surgery must be done according to the presence or absence of bullae, detected by high-resolution chest computed tomographic (HRCT) scanning [44].

## **5.4 Pleurodesis**

The American College of Chest Physicians, British Thoracic Society, and the Belgian Society of Pulmonology recommended surgical pleurodesis via thoracoscopy for air leak that persists more than 4 days or recurrence prevention at second occurrence [45]. Methods of pleurodesis have included mechanical abrasion with gauze or Marlex, instillation of tetracycline, pleural irritation with laser or cautery, and instillation of talc [46]. The addition of pleurodesis agents reduces the rate of recurrence in PSP. Alayouty et al. in a randomized controlled trial studied the efficacy of different pleurodesis agents. They reported that chemical pleurodesis is associated with less recurrence rate than mechanical abrasion ( $P < 0.001$ , evidence level 1b) [47, 48].

## **5.5 Video-assisted thoracoscopic surgery (VATS)**

The thoracoscopic surgery for primary spontaneous pneumothorax has been proposed and studied by a lot of clinicians as the main treatment for recurrent or

persistent spontaneous pneumothorax. Surgical treatment is more invasive and has a lower recurrence rate than the conservative treatment [49–51] but increases patient discomfort, which has restricted the application of open thoracotomy. Video-assisted thoracoscopic surgery (VATS) for primary spontaneous pneumothorax has been proposed as a new surgical technique and has taken over the role of open thoracotomy, due to its minimal invasiveness and low morbidity [52]. This technique has been used not only for prolonged air leak or recurrence but also in patients at the first episode of pneumothorax, when blebs or bullae are identified with CT scan. A study conducted at the Chest Diseases Hospital in Kuwait treated spontaneous pneumothorax in 72 patients using VATS technique. The study included 67 male and 5 female patients from 15 to 40 years with a recurrent episode of pneumothorax. Surgeons performed VATS unilateral technique in all cases, with gauze abrasion and apical pleurectomy to remove subpleural blebs or bullae and excision of the apex of the upper lobe in the absence of any identifiable lesion. They concluded that thoracoscopic surgery could be carried out safely and effectively in the treatment of recurrent or persistent spontaneous pneumothorax, allowing inspection of the entire lung, identification of bullae, and resection of the bullous disease [29]. Another study compared the results of conservative treatment, open thoracotomy, and VATS. The authors studied 281 patients who had primary spontaneous pneumothorax, finding recurrences in 56.4% of the patients with the conservative treatment, 3% for open thoracotomy and 11.7% for VATS with a hospital stay length of 14.5, 22.2, and 8.3 days, respectively. At the end, they concluded VATS was significantly superior to open thoracotomy measuring length of operation, bleeding volume, and length of hospital stay. In terms of morbidity, low invasive and cosmetic issue VATS is superior to open thoracotomy [52]. Conventional three-port VATS has advantage in hospital stay, postoperative pain, and chest drainage time. In 2005, Dr. Gaetano Rocco used simple-port VATS for the first time, a technique that requires a minimum incision of approximately 3 cm and facilitates the postoperative recovery of the patient, compared with three-port VATS [53].

## 5.6 Open thoracotomy

Thoracotomy is an incision into the pleural space of the chest, and it has been the classic surgical treatment of PSP. Surgery is indicated when there is a recurrence of an initial episode of PSP, which produces persistent air leaks, or collapsed lung after placement of pleural drainage [54]. The advantages of this procedure over thoracoscopic techniques are the ability to perform extensive mechanical pleurodesis and the resection of blebs [55]. In order to prevent recurrence of pneumothorax, segments of the lung with bullae or blebs need to be resected. In 1941, Tyson and Grandall described open thoracotomy with pleural abrasion for the treatment of pneumothorax, and then Gaensler introduced parietal pleurectomy and less invasive procedures (like axillary thoracotomy); this became more common during the last years [56].

After the surgical treatment, the next step is to prevent the recurrence of spontaneous pneumothorax, which is estimated from 23 to 50% of all the patients. The highest risk occurs in the first 30 days, and, during this time, patients must avoid activities which involve acute variation of the pressure in the lungs, like flying or diving; these activities increase the risk of recurrent spontaneous pneumothorax. The recommendation for patients with the first episode of spontaneous pneumothorax is to avoid flying or diving. Patients may be able to fly 6 weeks after a definitive surgical intervention and resolution of the pneumothorax and after treatment; patients must perform a control X-ray to confirm the resolution and wait at least 6 weeks before flying. Recurrence of spontaneous pneumothorax is not common

during a flight, but the consequences could be dangerous because there is not medical attention. Passengers may wish to consider alternative forms of transport within 1 year of the initial event [57]. The management of pneumothorax during a flight depends on the patient's clinical condition and the medical supplies on the plane. Supplemental oxygen should be provided, and the descent to the nearest airport considered [58].

## 6. Conclusion

PSP is a common problem encountered by doctors in medical practice. It is a significant global health problem affecting adolescent and young adults mainly. Current guidelines recommend treatment based on the severity of symptoms and the degree of lung collapse according to chest X-ray findings. There is an update needed in the current international guidelines including randomized controlled evidence. The first step in the management is to remove air from pleural space, with subsequent management aimed to prevent recurrence. Observation with supplemental oxygen, aspiration of intrapleural air, tube thoracostomy, and VATS pleurodesis with talc to prevent recurrence are the pillars of treatment. Thoracotomy should be reserved for special cases in which the patient is unable or unwilling to undergo VATS, in situations where VATS has failed or in high-risk cases.

### Author details

Fabian Andres Giraldo Vallejo\*, Rubby Romero, Melissa Mejia  
and Estefania Quijano  
Instituto del Corazon de Bucaramanga, Bucaramanga, Colombia

\*Address all correspondence to: [fabiangiraldomd@gmail.com](mailto:fabiangiraldomd@gmail.com)

### IntechOpen

© 2019 The Author(s). Licensee IntechOpen. This chapter is distributed under the terms of the Creative Commons Attribution License (<http://creativecommons.org/licenses/by/3.0>), which permits unrestricted use, distribution, and reproduction in any medium, provided the original work is properly cited. 

## References

- [1] Wong A, Galiabovitch E, Bhagwat K. Management of primary spontaneous pneumothorax: A review: Management of spontaneous pneumothorax. ANZ Journal of Surgery [Internet]. 2018 Jul 5 [cited 2018 Sep 28]. Available from: <http://doi.wiley.com/10.1111/ans.14713>
- [2] Henry M, Arnold T, Harvey J. BTS Guidelines for the Management of Spontaneous Pneumothorax. Thorax. 2003 May;58(Suppl 2):ii39-52
- [3] Simpson G. Spontaneous pneumothorax: Time for some fresh air. Internal Medicine Journal. 2010 Mar;40(3):231-234
- [4] Sahn SA. Spontaneous pneumothorax. The New England Journal of Medicine. 2000;7
- [5] Bintcliffe O, Maskell N. Spontaneous pneumothorax. BMJ. 2014 May 8;348:g2928-g2928
- [6] Brown SGA, Ball EL, Macdonald SPJ, Wright C, McD Taylor D. Spontaneous pneumothorax; A multicentre retrospective analysis of emergency treatment, complications and outcomes: Spontaneous pneumothorax. Internal Medicine Journal. 2014 May;44(5):450-457
- [7] Tschopp J-M, Bintcliffe O, Astoul P, Canalis E, Driesen P, Janssen J, et al. ERS task force statement: Diagnosis and treatment of primary spontaneous pneumothorax. The European Respiratory Journal. 2015 Aug;46(2):321-335
- [8] Massongo M, Leroy S, Scherpereel A, Vaniet F, Dhalluin X, Chahine B, et al. Outpatient management of primary spontaneous pneumothorax: A prospective study. The European Respiratory Journal. 2014 Feb 1;43(2):582-590
- [9] Chen J-S, Chan W-K, Tsai K-T, Hsu H-H, Lin C-Y, Yuan A, et al. Simple aspiration and drainage and intrapleural minocycline pleurodesis versus simple aspiration and drainage for the initial treatment of primary spontaneous pneumothorax: An open-label, parallel-group, prospective, randomised, controlled trial. The Lancet. 2013 Apr;381(9874):1277-1282
- [10] Noppen M, Alexander P, Driesen P, Slabbynck H, Verstraeten A. Manual aspiration versus chest tube drainage in first episodes of primary spontaneous pneumothorax: A multicenter, prospective, randomized pilot study. American Journal of Respiratory and Critical Care Medicine. 2002 May;165(9):1240-1244
- [11] Sedrakyan A, van der MJ, Lewsey J, Treasure T. Video assisted thoracic surgery for treatment of pneumothorax and lung resections: Systematic review of randomised clinical trials. BMJ. 2004 Oct 30;329(7473):1008
- [12] Margolis M, Gharagozloo F, Tempesta B, Trachiotis GD, Katz NM, Alexander EP. Video-assisted thoracic surgical treatment of initial spontaneous pneumothorax in young patients. The Annals of Thoracic Surgery. 2003 Nov;76(5):1661-1664
- [13] Foroulis CN. Surgery for primary spontaneous pneumothorax. Journal of Thoracic Disease. 2016 Dec;8(12):E1743-E1745
- [14] Chen Y-Y, Huang H-K, Chang H, Lee S-C, Huang T-W. Postoperative predictors of ipsilateral and contralateral recurrence in patients with primary spontaneous pneumothorax. Journal of Thoracic Disease. 2016 Nov;8(11):3217-3224
- [15] Zarogoulidis K, Papaiwannou A, Lazaridis G, Karavergou A, Lampaki S, Baka S, et al. Pneumothorax from



Diagnosis to Treatment, Hands on Course: Part II. *Annals of Translational Medicine*. 2015 Mar;**3**(3):41. DOI: 10.3978/j.issn.2305-5839.2015.02.10

[16] Noppen M, De Keukeleire T. Pneumothorax. *Respiration*. 2008;**76**(2):121-127

[17] Bense L, Eklund G, Wiman L-G. Smoking and the increased risk of contracting spontaneous pneumothorax. *Chest*. 1987 Dec;**92**(6):1009-1012

[18] Iii LJM, Hepper NGG, Offord KP. Incidence of Spontaneous Pneumothorax in Olmsted County, Minnesota: 1950 to 1974. p. 4

[19] Sadikot RT, Greene T, Meadows K, Arnold AG. Recurrence of primary spontaneous pneumothorax. *Thorax*. 1997 Sep 1;**52**(9):805-809

[20] Guo Y, Xie C, Rodriguez RM, Light RW. Factors related to recurrence of spontaneous pneumothorax. *Respirology*. 2005 Jun;**10**(3):378-384

[21] Bobbio A, Dechartres A, Bouam S, Damotte D, Rabbat A, Régnard J-F, et al. Epidemiology of spontaneous pneumothorax: Gender-related differences. *Respiratory Epidemiology*. *Thorax*. 2015 Jul;**70**(7):653-658. DOI: 10.1136/thoraxjnl-2014-206577. Epub 2015 Apr 27

[22] Johnson MM. Catamenial pneumothorax and other thoracic manifestations of endometriosis. *Clinics in Chest Medicine*. 2004 Jun;**25**(2):311-319

[23] Hopkins TG, Maher ER, Reid E, Marciniak SJ. Recurrent pneumothorax. *The Lancet*. 2011 May;**377**(9777):1624

[24] Alifano M, Forti Parri SN, Bonfanti B, Arab WA, Passini A, Boaron M, et al. Atmospheric pressure influences the risk of pneumothorax. *Chest*. 2007 Jun;**131**(6):1877-1882

[25] Noppen M. Music: A new cause of primary spontaneous pneumothorax. *Thorax*. 2004 Aug 1;**59**(8):722-724

[26] Viveiro C, Rocha P, Carvalho C, Zarcos MM. Spontaneous pneumothorax as manifestation of Marfan syndrome. *Case Reports*. 2013 Dec 5;**2013**(Dec 05 1):bcr2013201697

[27] Karpman C, Aughenbaugh GL, Ryu JH. Pneumothorax and bullae in Marfan syndrome. *Respiration*. 2011;**82**(3):219-224

[28] Leite M de FMP, Aoun NBT, Borges MS, Magalhães MEC, Christiani LA. Marfan's syndrome: Early and severe form in siblings. *Arquivos Brasileiros de Cardiologia*. 2003 Jul;**81**(1):89-92

[29] MacDuff A, Arnold A, Harvey J, On behalf of the BTS Pleural Disease Guideline Group. Management of spontaneous pneumothorax: British Thoracic Society pleural disease guideline 2010. *Thorax*. 2010 Aug 1;**65**(Suppl 2):ii18-ii31

[30] Walker SP, Bibby AC, Halford P, Stadon L, White P, Maskell NA. Recurrence rates in primary spontaneous pneumothorax: A systematic review and meta-analysis. *The European Respiratory Journal*. 2018 Sep;**52**(3):1800864

[31] Roberts DJ, Leigh-Smith S, Faris PD, Blackmore C, Ball CG, Robertson HL, et al. Clinical presentation of patients with tension pneumothorax: A systematic review. *Annals of Surgery*. 2015 Jun;**261**(6):1068-1078

[32] Norris RM, Jones JG, Bishop JM. Respiratory gas exchange in patients with spontaneous pneumothorax. *Thorax*. 1968 Jul 1;**23**(4):427-433

[33] Glazer HS, Anderson DJ, Wilson BS, Molina PL, Sagel SS. Pneumothorax: Appearance on lateral chest radiographs. *Radiology*. 1989 Dec 1;**173**(3):707-711



- [34] Terzi E, Zarogoulidis K, Kougioumtzi I, Dryllis G, Pitsiou G, Machairiotis N, et al. Acute respiratory distress syndrome and pneumothorax. *Journal of Thoracic Disease*. 2014;**6**:8
- [35] Zhang M, Liu Z-H, Yang J-X, Gan J-X, Xu S-W, You X-D, et al. Rapid detection of pneumothorax by ultrasonography in patients with multiple trauma. **10**(4):7
- [36] Hoi K, Turchin B, Kelly A-M. How accurate is the Light index for estimating pneumothorax size? *Australasian Radiology*. 2007 Apr;**51**(2):196-198
- [37] Ashby M, Haug G, Mulcahy P, Ogden KJ, Jensen O, Walters JA. Conservative versus interventional management for primary spontaneous pneumothorax in adults. 2014;**17**
- [38] Soulsby T. British Thoracic Society guidelines for the management of spontaneous pneumothorax: Do we comply with them and do they work? *Emergency Medicine Journal*. 1998 Sep 1;**15**(5):317-321
- [39] Baumann MH, Noppen M. Pneumothorax. *Respirology*. 2004 Jun;**9**(2):157-164
- [40] Leyn PD, Lismonde M, Ninane V, Noppen M, Slabbynck H, Meerhaeghe AV, et al. Belgian Society of Pneumology. Guidelines on the management of spontaneous pneumothorax. *Acta Chirurgica Belgica*. 2005 Jan;**105**(3):265-267
- [41] Kelly A-M, Kerr D, Clooney M. Outcomes of emergency department patients treated for primary spontaneous pneumothorax. *Chest*. 2008 Nov;**134**(5):1033-1036
- [42] Ho KK, Ong MEH, Koh MS, Wong E, Raghuram J. A randomized controlled trial comparing minichest tube and needle aspiration in outpatient management of primary spontaneous pneumothorax. *The American Journal of Emergency Medicine*. 2011 Nov;**29**(9):1152-1157
- [43] Miller AC. Guidelines for the Management of Spontaneous Pneumothorax. p. 3
- [44] Kim J, Kim K, Shim YM, Chang WI, Park K-H, Jun T-G, et al. Video-assisted thoracic surgery as a primary therapy for primary spontaneous pneumothorax: Decision making by the guideline of high-resolution computed tomography. *Surgical Endoscopy*. 1998 Nov;**12**(11):1290-1293
- [45] Hallifax RJ, Yousuf A, Jones HE, Corcoran JP, Psallidas I, Rahman NM. Effectiveness of chemical pleurodesis in spontaneous pneumothorax recurrence prevention: A systematic review. *Thorax*. 2017 Dec;**72**(12):1121-1131
- [46] Ayed AK, Al-Din HJ. The results of Thoracoscopic surgery for primary spontaneous pneumothorax. *Chest*. 2000 Jul;**118**(1):235-238
- [47] Jouneau S, Sohier L, Desrues B. Pleurodesis for primary spontaneous pneumothorax. *The Lancet*. 2013 Jul;**382**(9888):203
- [48] Alayouty HD, Hasan TM, Alhadad ZA, Omar Barabba R. Mechanical versus chemical pleurodesis for management of primary spontaneous pneumothorax evaluated with thoracic echography. *Interactive CardioVascular and Thoracic Surgery*. 2011 Nov 1;**13**(5):475-479
- [49] Mouroux J, Elkaïm D, Padovani B, Myx A, Perrin C, Rotomondo C, et al. Video-assisted thoracoscopic treatment of spontaneous pneumothorax: Technique and results of one hundred cases. *The Journal of Thoracic and Cardiovascular Surgery*. 1996 Aug;**112**(2):385-391
- [50] Liu H-P, Lin PJ, Hsieh M-J, Chang J-P, Chang C-H. Thoracoscopic

surgery as a routine procedure for spontaneous pneumothorax. *Chest*. 1995 Feb;**107**(2):559-562

[51] Sawada S, Watanabe Y, Moriyama S. Video-assisted thoracoscopic surgery for primary spontaneous pneumothorax. *Chest*. 2005 Jun;**127**(6):2226-2230

[52] Janssen J, Cardillo G. Primary spontaneous pneumothorax: Towards outpatient treatment and abandoning chest tube drainage. *Respiration*. 2011;**82**(2):201-203

[53] Xu W, Wang Y, Song J, Mo L, Jiang T. One-port video-assisted thoracic surgery versus three-port video-assisted thoracic surgery for primary spontaneous pneumothorax: A meta-analysis. *Surgical Endoscopy*. 2017 Jan;**31**(1):17-24

[54] Freixinet JL, Canalís E, Juliá G, Rodríguez P, Santana N, de Castro FR. Axillary thoracotomy versus videothoracoscopy for the treatment of primary spontaneous pneumothorax. *The Annals of Thoracic Surgery*. 2004 Aug;**78**(2):417-420

[55] Murray KD, Matheny RG, Howanitz EP, Myerowitz PD. A limited axillary thoracotomy as primary treatment for recurrent spontaneous pneumothorax. *Chest*. 1993 Jan;**103**(1):137-142

[56] Lazopoulos A, Barbetakis N, Lazaridis G, Baka S, Mpoukovinas I, Karavasilis V, et al. Open thoracotomy for pneumothorax. *Journal of Thoracic Disease*. 2015;**7**:6

[57] Managing passengers with respiratory disease planning air travel: British Thoracic Society recommendations. *Thorax*. 1 Apr 2002;**57**(4):289-304

[58] Hu X, Cowl CT, Baqir M, Ryu JH. Air travel and pneumothorax. *Chest*. 2014 Apr;**145**(4):688-694