

We are IntechOpen, the world's leading publisher of Open Access books Built by scientists, for scientists

6,900

Open access books available

185,000

International authors and editors

200M

Downloads

Our authors are among the

154

Countries delivered to

TOP 1%

most cited scientists

12.2%

Contributors from top 500 universities



WEB OF SCIENCE™

Selection of our books indexed in the Book Citation Index
in Web of Science™ Core Collection (BKCI)

Interested in publishing with us?
Contact book.department@intechopen.com

Numbers displayed above are based on latest data collected.
For more information visit www.intechopen.com



The Role of Vitamin A-Storing Cells (Stellate Cells) in Inflammation and Tumorigenesis

Isao Okayasu, Mutsunori Fujiwara and Tsutomu Yoshida

Abstract

Characteristic localization and distribution of vitamin A-storing cells (stellate cells) were demonstrated as hepatic stellate cells in the hepatic lobule and as subepithelial myofibroblasts in the colonic crypt. The stem cell-stem cell niche is maintained by stellate cells in the periportal area and crypt base. Periportal vitamin A-rich stellate cells decrease in patients with chronic hepatitis C who are habitual smokers. Mice fed a vitamin A-supplemented diet show reduced severity of dextran sulfate sodium (DSS)-induced colitis and development of subsequent colonic neoplasia in a model of the ulcerative colitis-dysplasia-carcinoma sequence, compared with mice fed a vitamin A-deficient diet. Decreased colonic subepithelial myofibroblasts and IgA/IgG-positive cells, and increased CD11c-positive dendritic cells in the colonic mucosa, in the vitamin A-deficient state suggest dysfunction of the stem cell niche at the colonic crypt base and colonic immunity. Accordingly, vitamin A deficiency may worsen inflammation and subsequent tumor development, indicating the possibility that vitamin A supplementation might be effective against chronic inflammation and cancer development.

Keywords: vitamin A-storing cells, stellate cells, subepithelial myofibroblasts, stem cell niche, chronic hepatitis, DSS colitis, ulcerative colitis, colonic tumorigenesis

1. Introduction

In mammals, vitamin A is mostly stored in the liver, particularly in perisinusoidal stellate cells. It is also detectable in the lung, kidney, and intestine. Storage of total retinol is increased considerably in the lungs, kidneys, and intestines of rats fed a vitamin A-rich diet [1]. Vitamin A-rich lipids can be identified in the cells using electron microscopy [2]. Vitamin A-storing cells (stellate cells) correspond to subepithelial myofibroblasts in the lung and intestine [3]. Stellate cells are necessary for the differentiation of epithelial cells, known as the stem cell niche [4–7].

It is thought that deficiency of vitamin A worsens inflammation and accelerates tumorigenesis, possibly due to local immunity and stem cell niche dysfunction [3, 8–11]. Data presented and discussed in this chapter show (1) the distribution, localization, and function of stellate cells in the liver and intestine, and (2) the role of stellate cells in inflammation and tumorigenesis.

2. Characteristic distribution, localization, and function of stellate cells

2.1 Hepatic stellate cells

Vitamin A is mostly ($\approx 80\%$) stored in hepatic stellate cells, which are located in the perisinusoidal (Disse) space [1, 2]. Lipid droplets containing vitamin A can be assessed by electron microscopy. Vitamin A-rich (containing ≥ 10 vitamin A lipid droplets) (**Figure 1A**) and vitamin A-poor stellate cells (< 10 vitamin A lipid droplets) can be identified by counting the numbers of lipid droplets in the cytoplasm. In humans and experimental animals, vitamin A-rich stellate cells change to vitamin A-poor stellate cells or myofibroblasts, which induce fibrosis by collagen formation in chronic hepatitis or cirrhosis (**Figure 1B**).

Portal fibrosis is induced by collagen produced mainly by stellate cells but not by hepatocytes. Collagen-producing stellate cells change into myofibroblast-like cells, which show a decrease in the number of vitamin A granules in the cytoplasm, and produce collagen around the cytoplasm. Lastly, vitamin A granules disappear completely from the cytoplasm, and stellate cells change their phenotype to that of myofibroblasts and fibrocytes, which are immunohistochemically positive for anti- α SM-actin antibody [12–14].

The periportal area is a microenvironment with a high concentration of vitamin A due to an abundance of vitamin A-rich stellate cells, and the complex of retinol-retinol binding protein is paracrine-transferred from hepatic parenchymal cells to stellate cells, leading to direct secretion of the complex from stellate cells into the plasma [15–17]. Since hepatic stem cells are localized around the periportal area, namely the canal of Hering, the differentiation and maturation of these cells may be impaired due to vitamin A depletion in this area [18–20]. Hepatic stellate cells require vitamin A-rich lipids to maintain their niche function. Accordingly, the hepatic stem cell-stem cell niche relation is maintained in the periportal area [21, 22] (**Figure 2A**).

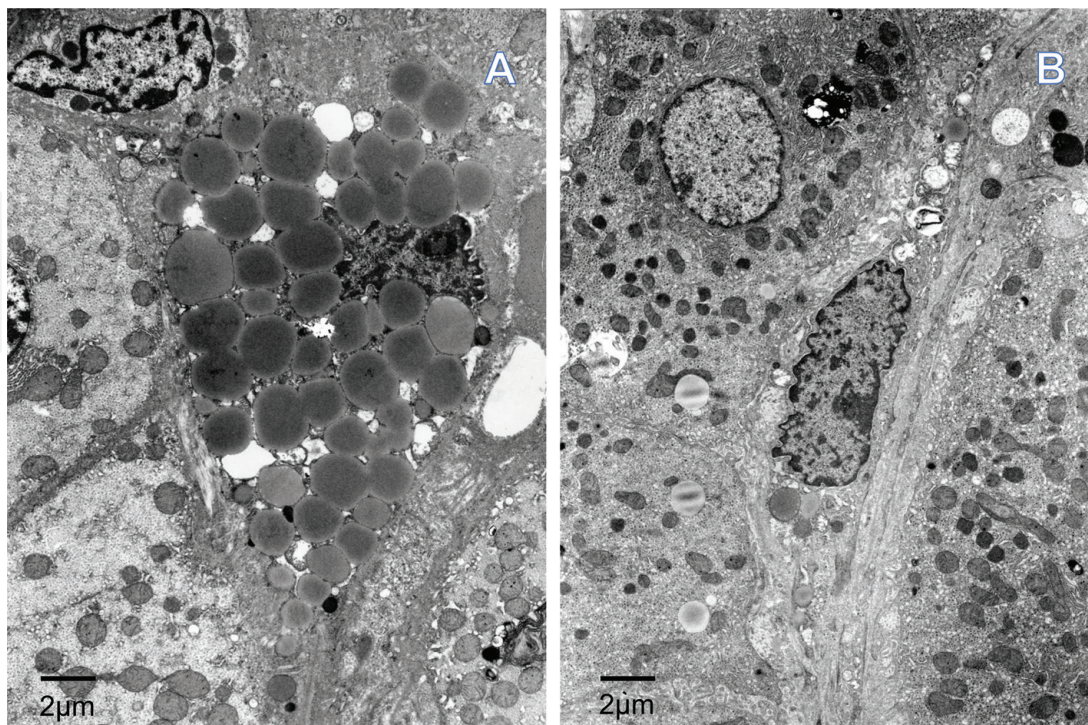


Figure 1. (A) A periportal vitamin A-rich stellate cell containing many lipid droplets and exerting pressure on the nucleus (human liver). (B) A periportal vitamin A-poor stellate cell containing a few lipid droplets (arrow) and well-developed endoplasmic reticulum (human liver).

2.2 Subepithelial myofibroblasts as colonic stellate cells

In the colonic mucosa, subepithelial myofibroblasts correspond to hepatic stellate cells, although they are usually vitamin A-poor in the cytoplasm, suggesting a different endotype from hepatic stellate cells (**Figure 3**). Subepithelial myofibroblasts are localized more at the crypt base than at other regions (**Figure 2B**) [3]. Subepithelial myofibroblasts express α SM-actin, NCAM, cytoglobin, and HSP47, indicating multi-potential roles [3, 11, 23] (**Figure 4**). Because stem cells are localized at the crypt base, subepithelial myofibroblasts around the crypt base are considered a stem cell niche, which has been shown by experimental and histopathological studies [3, 5, 23–25]. Accordingly, mucosal stem cells require subepithelial myofibroblasts for their differentiation. Critical gene expression patterns were shown from the colon basal crypts to the colon tops, including bone morphologic protein (BMP) antagonists, gremlin 1 (*GREM1*), *GREM2*, *CHRD1*, and active Wnt signaling using human colon microarray analysis [5]. Along the colon crypt axis, Wnt signaling and Notch signaling expression were activated at the crypt base, while BMP signaling was activated at the top. Wnt signaling and Notch signaling by subepithelial myofibroblasts of the crypt base and smooth muscle cells of the muscularis mucosa regulate epithelial cell positioning and proliferation, and BMP induces epithelial differentiation. Further, isolated human colonic crypt epithelial cells expressing musashi-1, β 1-integrin, BerEP4, and CD133 have been shown to adhere to colonic myofibroblasts in cell incubation experiments, indicating an intimate interaction with each [26, 27].

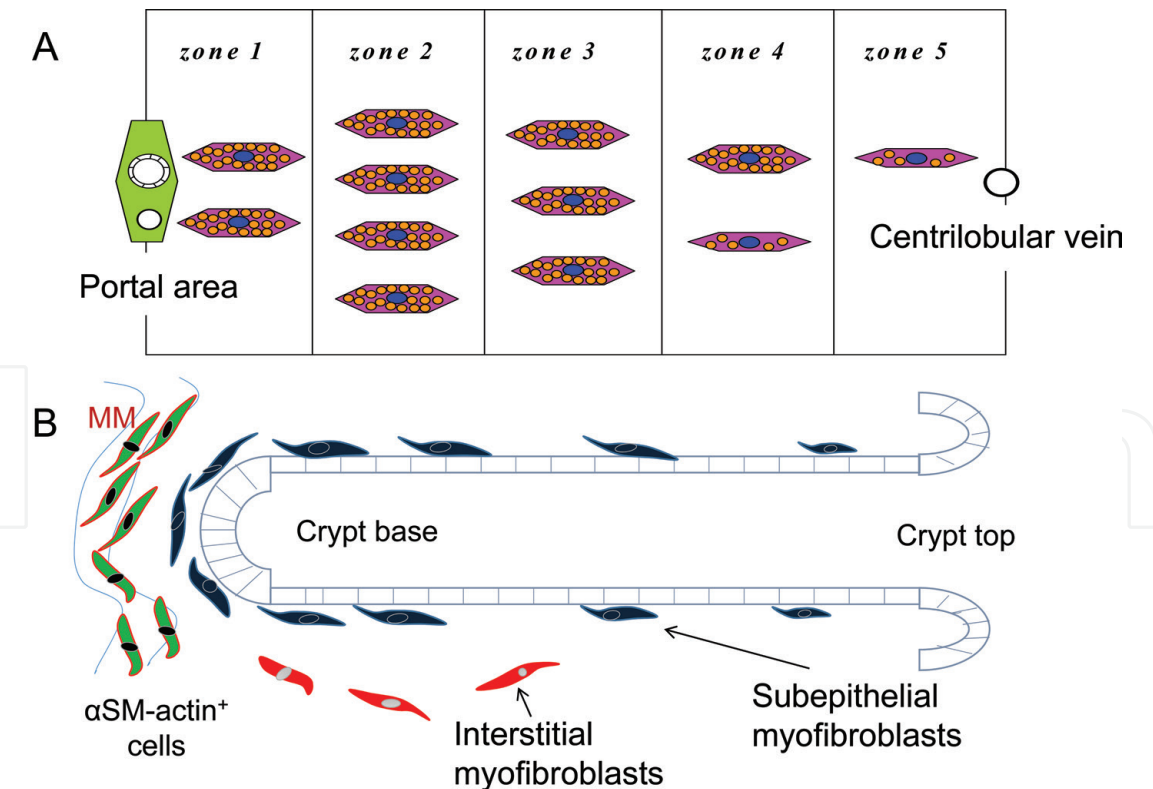


Figure 2.
(A) Characteristic distribution of periportal vitamin A-rich stellate cells in the liver. Hepatic stem cells located in zone 2, where vitamin A-rich stellate cells are collected, form a stem cell niche. Periportal hepatic cells differentiate and mature toward zone 5, close to the centrilobular vein [22]. (B) Localization and distribution of subepithelial myofibroblasts in the colonic mucosa. Many subepithelial myofibroblasts can be seen around the crypt base forming a stem cell niche, where colonic stem cells are located. Epithelial cells at the crypt base differentiate and mature toward the crypt top [3, 11]. The characteristic localization and maintenance of stem cell-stem cell niche are similar to those of the hepatic lobule. MM: Muscularis mucosa.

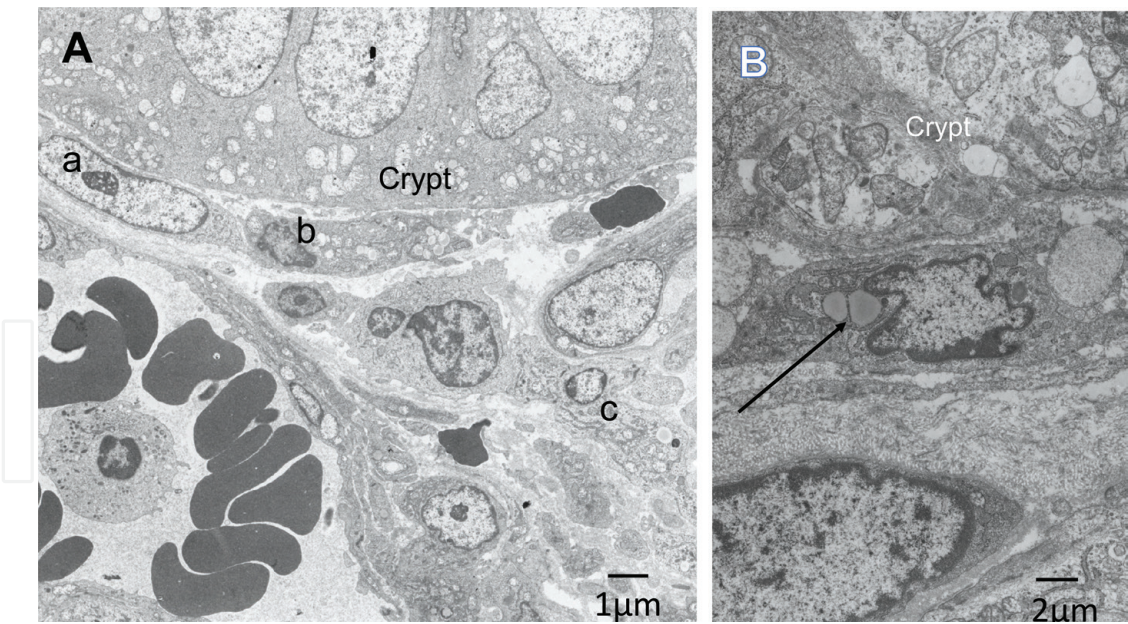


Figure 3. (A) Localization of subepithelial myofibroblasts in human colonic mucosa. Many subepithelial myofibroblasts, vitamin A-absent (a) or vitamin A-poor (b), are located around the crypt base. An interstitial myofibroblast is also seen (c). (B) A vitamin A-poor (arrow) subepithelial myofibroblast adjacent to the crypt.

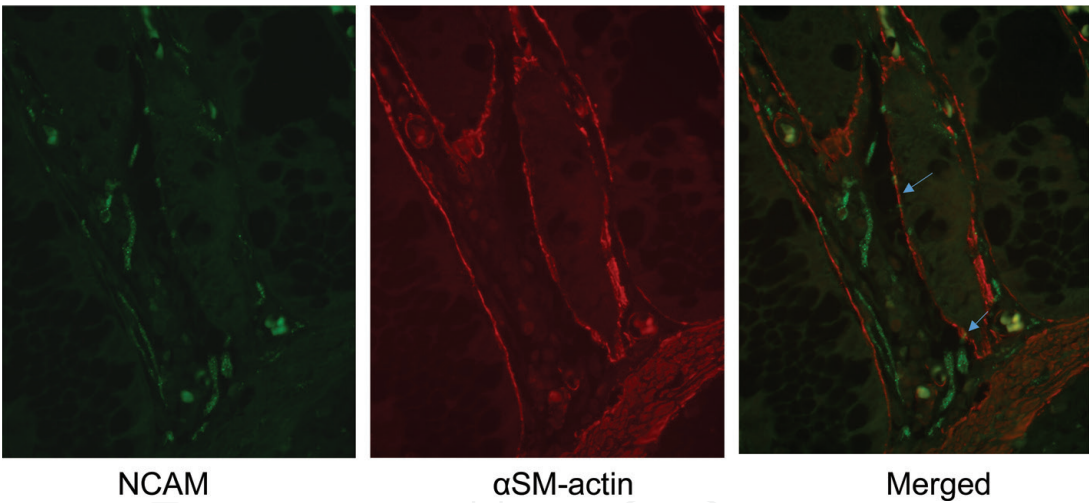


Figure 4. Expression of α SM-actin and NCAM by subepithelial myofibroblasts in human colonic mucosa. Double immunofluorescence staining shows expression of both α SM-actin (red arrows) and NCAM (green arrows).

Thus, the localization and relation of the stem cell-stem cell niche is the same in the liver and intestine.

3. Vitamin A and stellate cells in inflammation and tumorigenesis

3.1 Decrease of vitamin A-rich stellate cells in chronic hepatitis C

With respect to liver disease, the number of periportal vitamin A-rich stellate cells is decreased in chronic hepatitis C patients, which is associated with aggravation of hepatitis, as indicated by elevated serum alanine aminotransferase (ALT) levels [28] (**Figure 5A**). This tendency was demonstrated in both vitamin A-rich and vitamin A-poor stellate cells. Additionally, the number of periportal vitamin A-rich stellate cells or of both vitamin A-rich and vitamin A-poor stellate cells combined is

significantly decreased during the progression of chronic hepatitis C (from chronic persistent hepatitis, CPH or chronic active hepatitis, CAH2A to CAH2B) [29] (**Figure 5B**). Since vitamin A-absent stellate cells, that is, fibrotic myofibroblasts, were not counted in these studies, the change of vitamin A-storing stellate cells to myofibroblasts in chronic hepatitis was not assessed. Hepatic stellate cells in the normal human liver express both cellular retinol-binding protein-1 (CRBP-1) and α SM-actin, while myofibroblasts express only α SM-actin in fibrotic or cirrhotic liver, suggesting a change of stellate cells to myofibroblasts due to chronic inflammation [30]. This fact indicates that the decrease of vitamin A-rich and vitamin A-poor stellate cells correlates with the severity and progression of chronic hepatitis C is in line with the chronic hepatitis-liver cirrhosis-hepatocellular carcinoma (HCC) sequence proposed epidemiologically and clinically [31–33].

Furthermore, chronic hepatitis C patients who are habitual smokers show decreased numbers of vitamin A-rich stellate cells or vitamin A-rich and vitamin A-poor stellate cells combined, compared with those who are non-smokers [29] (**Figure 5C**). The smoking prevalence in the CAH2B group was 54.1%, which was

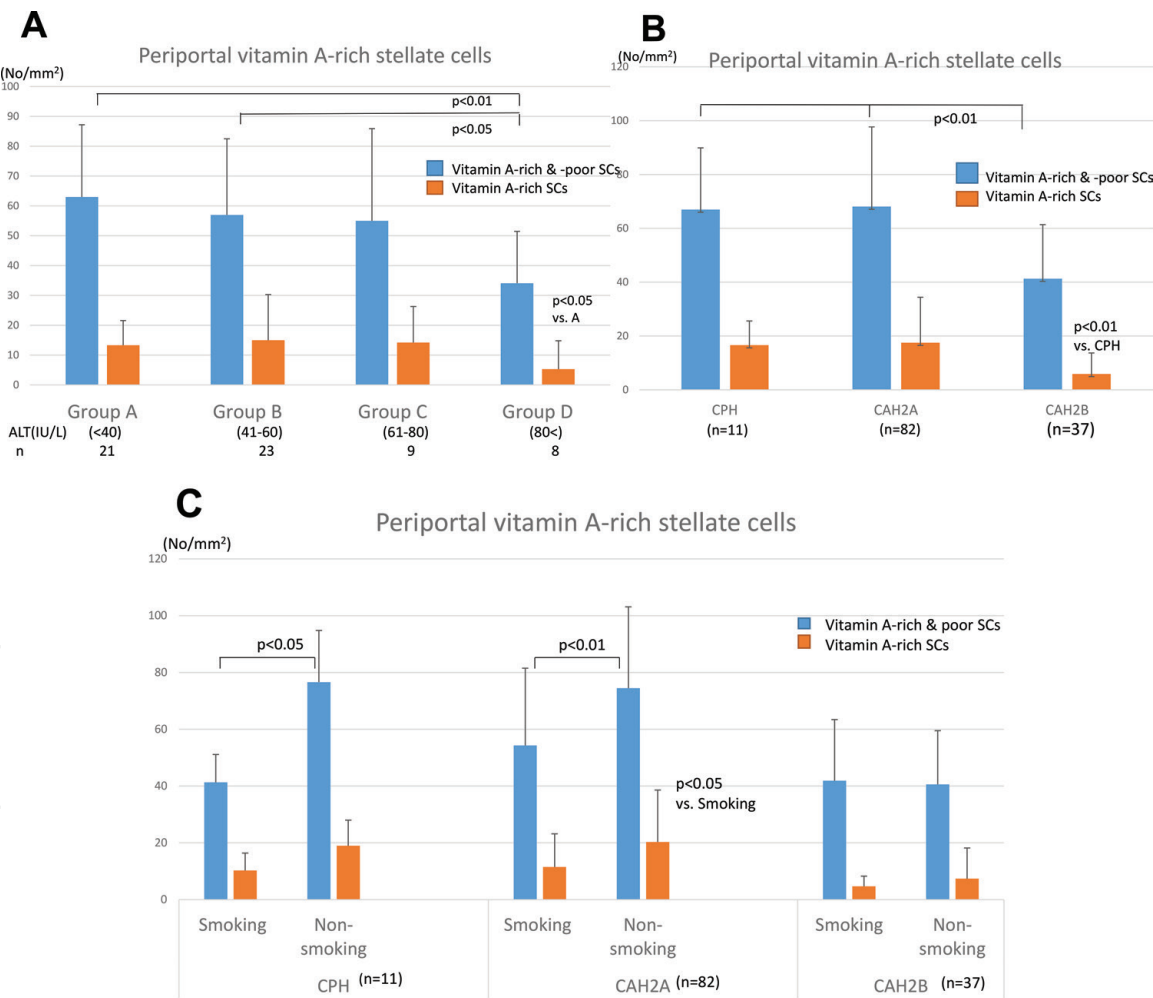


Figure 5. Relationship between the number of periportal vitamin A-rich stellate cells (SCs) and chronic hepatitis C. (A) Chronic hepatitis C monitored by serum ALT level. Both vitamin A-rich (≥ 10 lipid droplets in a cytoplasm) and vitamin A-poor (< 10 lipid droplets) or vitamin A-rich stellate cells in the periportal area are significantly decreased in Group D (ALT > 80 IU/L), compared with the groups with lower ALT level [28]. (B) Chronic hepatitis C. Both vitamin A-rich and vitamin A-poor stellate cells or vitamin A-rich stellate cells in the periportal area are significantly decreased in the CAH2B group compared with the CPH and CAH2A groups [29]. (C) Habitual smoking and the number of periportal vitamin A-rich stellate cells in patients with chronic hepatitis C. Smokers with chronic hepatitis C show low numbers of both vitamin A-rich and vitamin A-poor cells or vitamin A-rich stellate cells in the periportal area compared with non-smoking patients with chronic hepatitis C [29].

approximately 1.8 times that of the CPH and CAH2A groups in this study. Habitual smoking is encountered in 59.4% of patients with HCC, according to a report by the Liver Cancer Study Group of Japan [34]. This fact suggests that habitual smoking in CPH and CAH2A may cause the clinicopathological progression of chronic hepatitis C, in line with the results of other studies reporting that smoking is a risk factor for HCC development [35, 36]. It is possible that the decrease in the number of periportal vitamin A-rich stellate cells causes a decrease in local vitamin A content and a reduction in the anti-inflammatory effect of vitamin A. It has not yet been established whether the decrease of vitamin A-rich stellate cells results from harmful chemicals such as specific nitrosamines or benzopyrenes associated with smoking [37, 38]. The effects of the chemicals remain to be examined in stellate cell cultures to determine whether or not they result in hypoplasia of vitamin A-rich stellate cells.

In summary, habitual smoking can be a risk factor for acceleration of chronic hepatitis C, possibly due to a decrease or hypoplasia of vitamin A-rich stellate cells, resulting in the development of HCC.

3.2 Inhibition of dextran sulfate sodium (DSS) colitis by vitamin A supplementation

As a model of ulcerative colitis, DSS colitis was induced in mice fed a vitamin A deficient-diet or a vitamin A-supplemented diet [39, 40]. Subepithelial myofibroblasts in the colonic mucosa showed significant presence of cytoplasmic vitamin A lipid in the vitamin A-supplemented mice, in addition to the presence of vitamin A-rich hepatic stellate cells (**Figure 6**). Further, α smooth muscle (SM)-actin-positive subepithelial myofibroblasts increased in vitamin A-supplemented mice compared with vitamin A-deficient mice (**Figures 7, 8A**). In addition, CD11c-positive macrophages in the colonic mucosa decreased in vitamin A-supplemented mice compared with vitamin A-deficient mice (**Figure 8B**). IgA-positive cells and the ratio of IgA-positive/IgG-positive cells increased in vitamin A-supplemented mice compared with vitamin A-deficient mice (**Figure 8C**). Experimental DSS colitis, as a murine model of ulcerative colitis, showed significantly higher severity of colitis and colonic ulcer, and shorter colon length in vitamin A-deficient mice compared with vitamin A-supplemented mice (**Figure 9**). In addition, recovery after DSS colitis was delayed in vitamin A-deficient mice compared with vitamin A-supplemented mice. The severity was greater in vitamin A-deficient mice than in vitamin A-supplemented mice with repeated bouts of DSS colitis.

Dietary vitamin A is required as a precursor of retinol in tissues. Tissue retinol plays an important role in immunity and cell differentiation. In immunity, excess Th1 and insufficient Th2 function occur in vitamin A deficiency, resulting in helper T cell imbalance. Further, $\alpha\beta\gamma$ -positive memory/activated T cell generation is reduced in vitamin A-deficiency [41]. Supported by retinoic acid, a vitamin A metabolite, $\gamma\delta$ T cells produce IL-22, leading to improvement of DSS-induced colitis [42]. CD11c-positive dendritic cells in the colonic mucosa of vitamin A-deficient mice are increased, in line with results shown in a study of vitamin A-deficient rats [9]. The increase of CD11c-positive dendritic cells may represent a compensatory response to vitamin A deficiency, which induces maturation of dendritic cells [43, 44], since vitamin A deficiency causes dendritic cell dysfunction in the activation of T lymphocytes. Gut-homing IgA-secreting B cells are generated by intestinal dendritic cells in the sufficient vitamin A state [41]. Accordingly, a decrease in IgA⁺ cells or the ratio of IgA⁺ cells/IgG⁺ in the colonic mucosa is thought to be indicative of disorganized mucosal immunity in vitamin A deficiency [41, 45, 46]. Additionally,

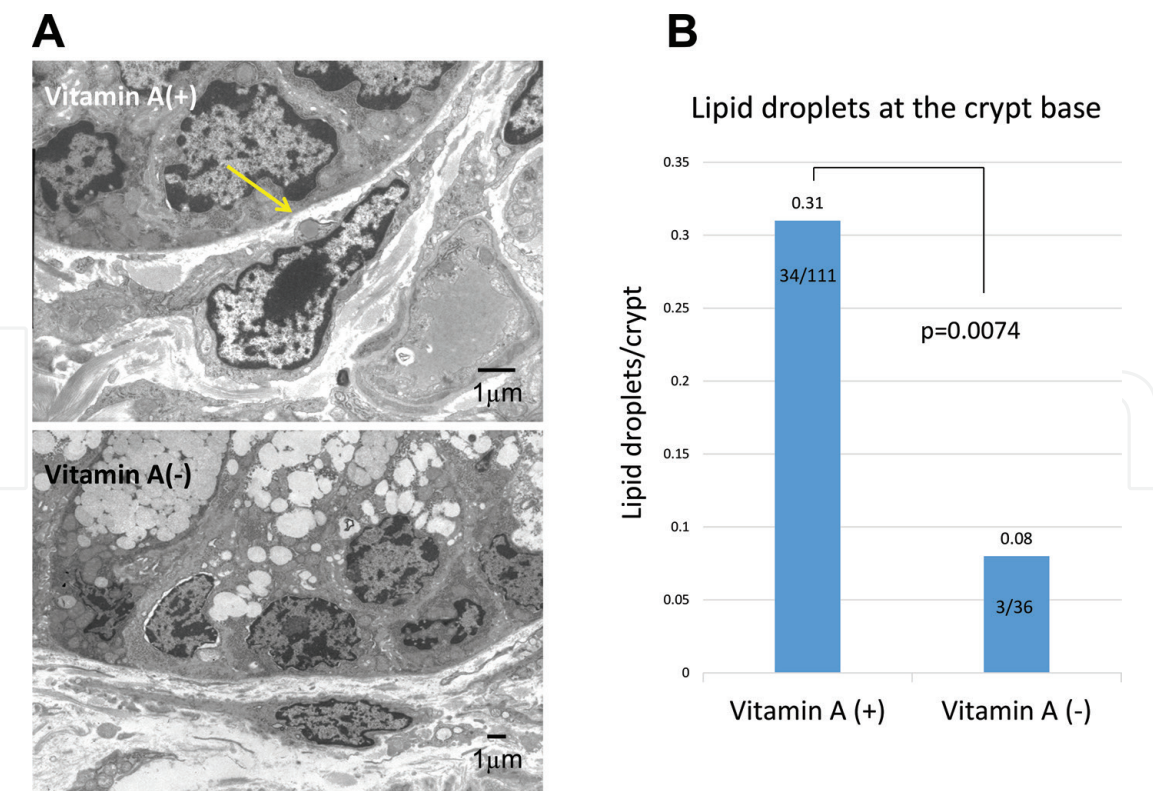


Figure 6. Subepithelial myofibroblasts of colonic mucosa in mice fed a vitamin A-deficient or vitamin A-supplemented diet. (A) A subepithelial myofibroblast from a vitamin A-supplemented mouse contains a few lipid droplets (arrow, upper panel). Conversely, a fibroblast-like subepithelial myofibroblast from a vitamin A-deficient mouse has no lipid droplets (lower panel). (B) Lipid droplets at the crypt base of vitamin A-supplemented mice were significantly more than in vitamin A-deficient mice [40].

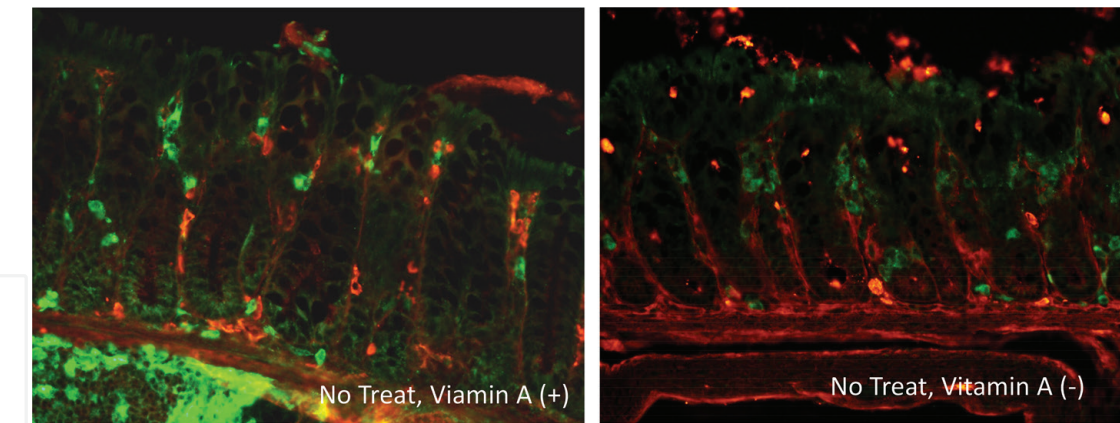


Figure 7. Localization and distribution of CD11c-positive dendritic cells (green) and α SM-actin (red) in the colonic mucosa of vitamin A-deficient (B, vitamin A (-)) and vitamin A-supplemented mice (A, vitamin A (+)) [40].

intestinal epithelial expression of retinaldehyde dehydrogenase 1 (RALDH1) differs among mouse strains. BALB/c mice, which have high RALDH1, show an increased activity for induction of IgA class switching from B cells [42]. The severity of DSS colitis might depend on RALDH1 expression, suggesting the possibility of differences in susceptibility to ulcerative colitis in humans. Further studies should be conducted to clarify this possibility.

Thus, possible dysfunction of mucosal immunity and poor epithelial cell differentiation by malfunction of colonic subepithelial myofibroblasts in vitamin A-deficient mice are presumed to accelerate DSS colitis.

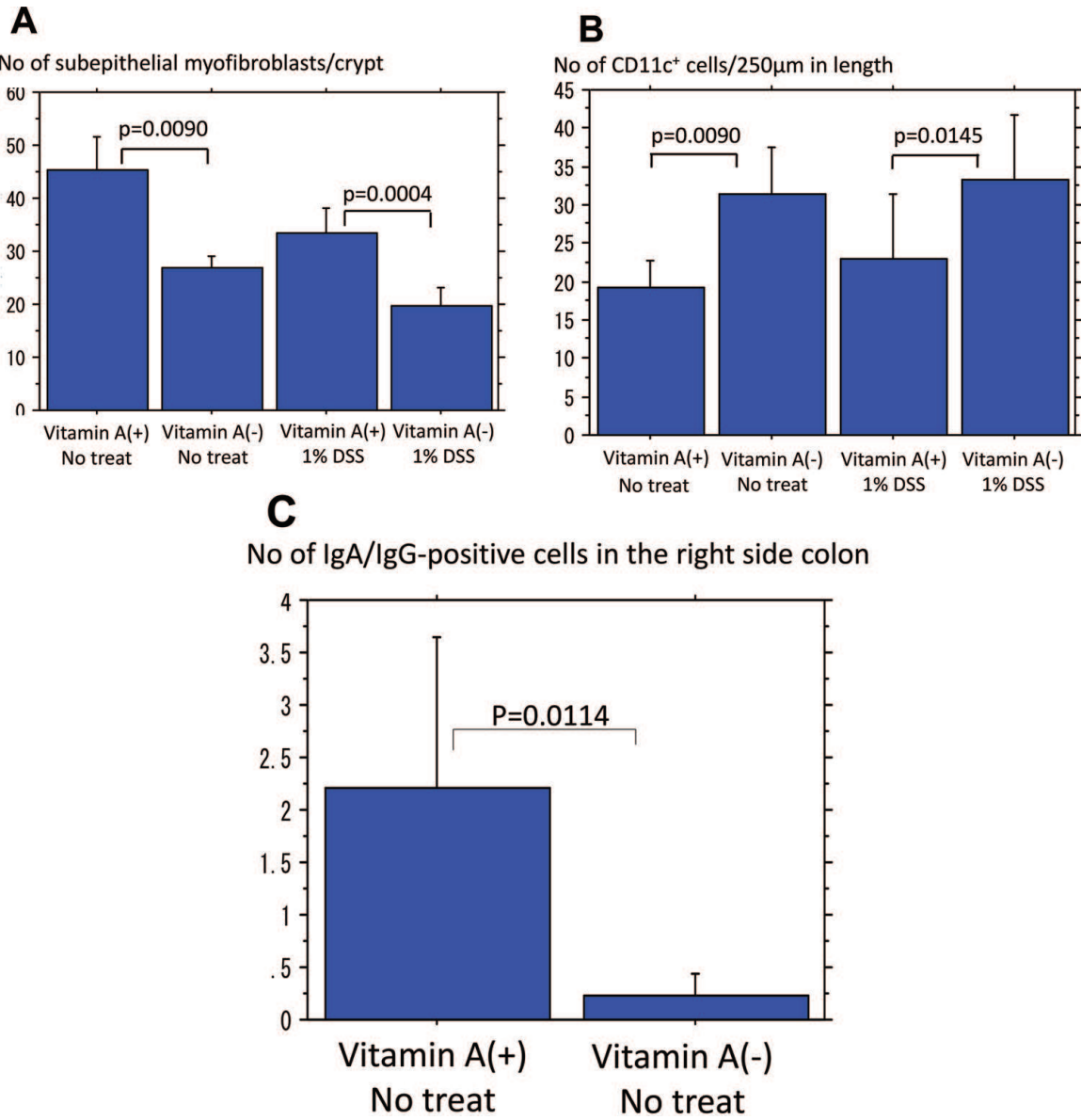


Figure 8. (A, B) Decreased α SM-actin-positive subepithelial myofibroblasts (a) and increased CD11c-positive dendritic cells (B) are shown in vitamin A-deficient mice (vitamin A (-)) compared with vitamin A-supplemented mice (vitamin A (+)), both in the non-treated and DSS colitis-induced groups [40]. (C) Comparison of IgA/IgG-positive cells in the right side colonic mucosa between vitamin A-deficient and vitamin A-supplemented mice. IgA/IgG-positive cells increased in vitamin A-supplemented mice (vitamin A (+)), compared with vitamin A-deficient mice (vitamin A (-)) [40].

3.3 Inhibition of development of colonic tumors by vitamin A supplementation in a DSS colitis model of the ulcerative colitis-carcinoma sequence

A combination of azoxymethane (AZM) preinjection followed by induction of DSS colitis is a well-known experimental murine model of the ulcerative colitis-dysplasia-adenocarcinoma sequence [47]. Vitamin A-deficient mice developed more dysplasia and adenocarcinoma than vitamin A-supplemented mice, as well as more severe colitis (**Figures 10, 11**) [40]. These results demonstrate that a vitamin A-supplemented diet inhibited DSS colitis and the subsequent development of dysplasia-carcinoma seen with a vitamin A-deficient diet.

Cytoplasmic vitamin A lipids decreased in subepithelial myofibroblasts at the colonic crypt base of vitamin A-deficient mice compared with vitamin A-supplemented mice. Furthermore, a decrease in α SM-actin-positive subepithelial myofibroblasts was also found, suggesting dysfunction of niche regulation for the protection and differentiation of mucosal stem cells or progenitor cells [3, 23, 25].

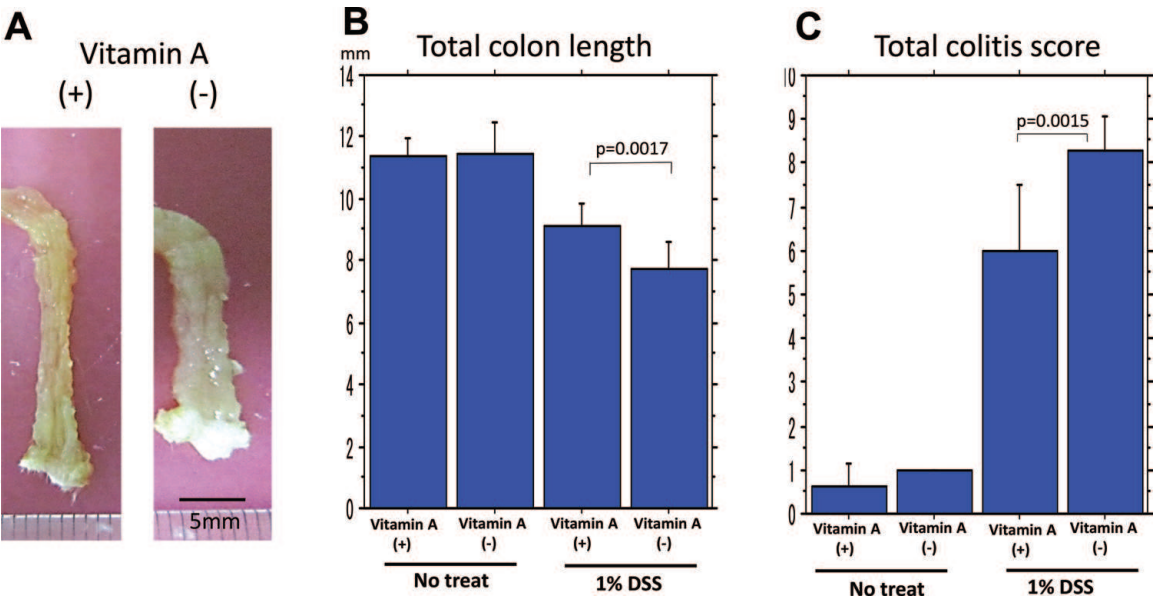


Figure 9. Comparison of DSS colitis between vitamin A-deficient and vitamin A-supplemented mice. Vitamin A-supplemented mice showed improvement of colon length (A, B) and colitis score (C) assessed by erosion, loss of crypts, and inflammatory cell infiltration [40].

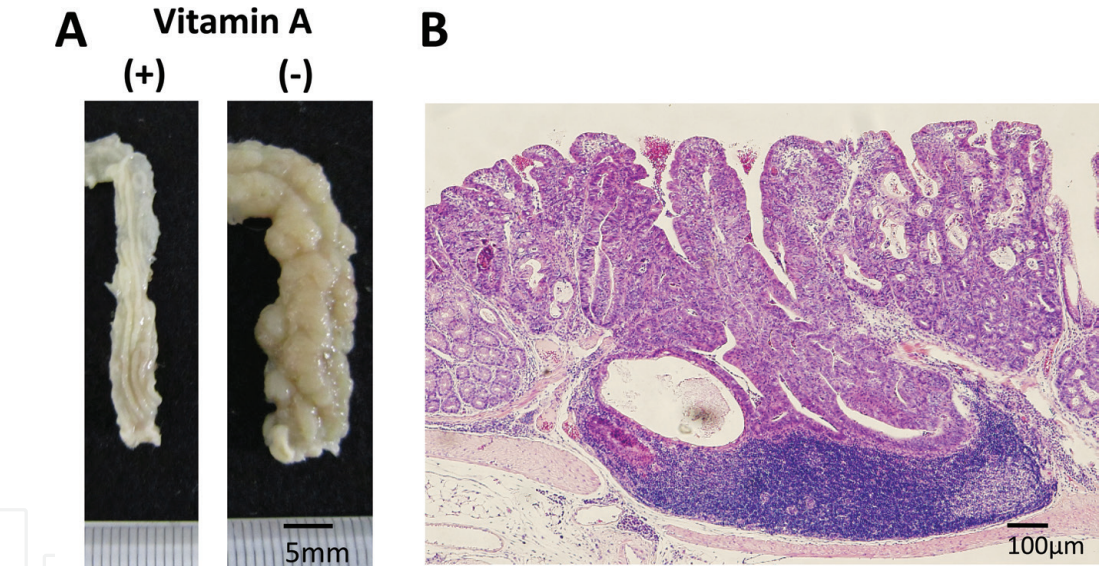


Figure 10. Colon cancer in vitamin A-deficient mouse induced by a combination of azoxymethane (AZM) injection and DSS colitis [40].

These findings might indicate that dysfunction of stem cell niche regulation in subepithelial myofibroblasts causes accelerated DSS colitis, resulting in the development of colorectal neoplasia.

Vitamin A and its metabolites, retinoids, play an important role in cell differentiation [25, 48]. It is well known and clinically accepted that retinoids have chemopreventive effects against cancers, particularly with differentiation therapy for acute promyelocytic leukemia [49]. In addition, there are many clinical and experimental reports that vitamin A deficiency promotes cancer development and progression [50–55]. The CYP26A1 gene, which encodes for the cytochrome P450 enzyme involved in metabolic inactivation of retinoic acid, was highly expressed in cancers of various organs and is related to cancer progression. This may suggest a link between intracellular retinoic acid status and tumorigenesis [56–58]. Furthermore, prolonged recovery from severe DSS colitis and the subsequent development of

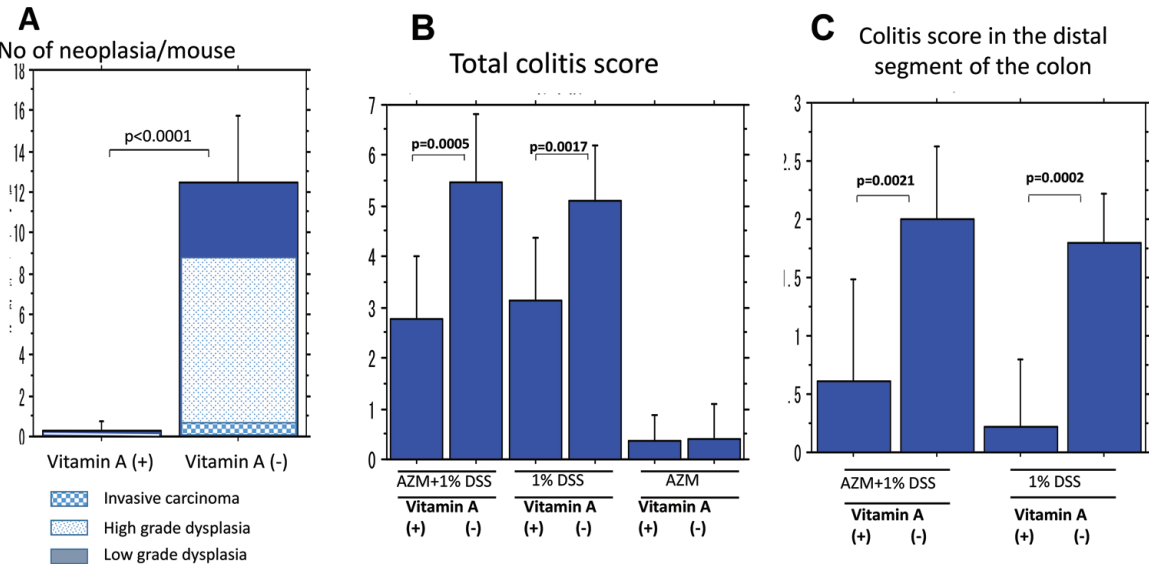


Figure 11.
Comparison of induced colon neoplasia and DSS colitis between vitamin A-deficient and vitamin A-supplemented mice. Vitamin A-supplemented mice showed significant inhibition of neoplasia development (A) and reduction of colon shortness (B) and colitis (C) compared with vitamin A-deficient mice [40].

colonic tumors in vitamin A-deficient mice were significantly improved by vitamin A supplementation, suggesting a cause-effect relationship between local vitamin A status and the development and progression of cancer.

It has been shown that gut microbiota have a possible influence on colitis and the development of colorectal neoplasia. Particularly, correction of microbiota-induced retinoic acid deficiency stimulates protective CD8⁺ T cell-mediated immunity, resulting in inhibition of colitis and its associated colorectal tumorigenesis in mice [59]. Since malnutrition including vitamin A insufficiency accelerates inflammatory bowel disease in children [60, 61], it is thought that the difference in microbiota in response to a vitamin A-deficient versus a vitamin A-supplemented diet may have a substantial effect on colitis and the development of colonic neoplasia [62–64]. Further study is needed to address this possibility.

There are no definite clinical indications for vitamin A administration to protect against inflammation and tumor development, although it has been proposed that dietary vitamin A is closely related to exacerbation and continuity of inflammation, particularly in chronic hepatitis C [65, 66] and inflammatory bowel disease [67, 68]. The results described herein raise the possibility that vitamin A administration inhibits chronic hepatitis and colitis, and the subsequent development of cancer. Further studies are needed to identify the possible mechanisms for inhibition of chronic inflammation and subsequent neoplasia induced by vitamin A supplementation.

4. Conclusions

Vitamin A is stored in stellate cells, mainly in the liver and to a lesser extent in the lung and intestine, and plays important roles in immunity, cell differentiation, and the stem cell niche. In the liver, decreased vitamin A-rich stellate cells, or decreased vitamin A-rich and vitamin A-poor stellate cells combined, relates to the severity of chronic hepatitis C and habitual smoking. In the colon, a vitamin A-supplemented diet inhibits DSS colitis and subsequent colonic tumor development in vitamin A-deficient diet mice, an experimental mouse model of ulcerative colitis. Vitamin A administration could be effective to treat and/or prevent liver

disease and ulcerative colitis, although the clinical effects of vitamin A administration in this context have not been thoroughly characterized to date. Further study is needed to identify the effect of vitamin A administration on chronic inflammation and tumorigenesis.

Author details

Isao Okayasu^{1*}, Mutsunori Fujiwara² and Tsutomu Yoshida³

1 Section of Nutrition, School of Health Care, Kiryu University, Midori, Gunma, Japan

2 Department of Pathology, Nissan Tamagawa Hospital, Tokyo, Japan

3 Department of Pathology, School of Medicine, Kitasato University, Sagamihara, Kanagawa, Japan

*Address all correspondence to: isaokaya@gmail.com

IntechOpen

© 2018 The Author(s). Licensee IntechOpen. This chapter is distributed under the terms of the Creative Commons Attribution License (<http://creativecommons.org/licenses/by/3.0>), which permits unrestricted use, distribution, and reproduction in any medium, provided the original work is properly cited. 

References

- [1] Nagi NE, Holven KB, Roos N, et al. Storage of vitamin A in extrahepatic stellate cells in normal rats. *Journal of Lipid Research*. 1997;**38**:645-658
- [2] Wake K. Perisinusoidal stellate cells (fat-storing cells, interstitial cells, lipocytes), their related structure in and around the liver sinusoids and vitamin A-storing cells in extrahepatic organs. *International Review of Cytology*. 1980;**66**:303-353
- [3] Okayasu I, Yoshida T, Mikami T, et al. Mucosal remodeling in long-standing ulcerative colitis with colorectal neoplasia: Significant alterations of NCAM⁺ or SMA⁺ subepithelial myofibroblasts and interstitial cells. *Pathology International*. 2009;**59**:701-711
- [4] Yen TH, Wright NA. The gastrointestinal tract stem cell niche. *Stem Cell Reviews*. 2006;**2**:203-212
- [5] Kosinski C, Li VS, Chan AS, et al. Gene expression patterns of human colon tops and basal and BMP antagonists as intestinal stem cell niche factors. *Proceedings of the National Academy of Sciences of the United States of America*. 2007;**104**:15418-15423
- [6] Sawitza I, Kordes C, Reister S, et al. The niche of stellate cells within rat liver. *Hepatology*. 2009;**50**:1617-1624
- [7] Kordes C, Sawitza I, Häussinger D. Hepatic and pancreatic stellate cells in focus. Hepatic and pancreatic stellate cells in focus. *Biological Chemistry*. 2009;**390**:1003-1012
- [8] Garcia OP. Effect of vitamin A deficiency on the immune response in obesity. *The Proceedings of the Nutrition Society*. 2012;**71**:290-297
- [9] Dong P, Tao Y, Yang Y, et al. Expression of retinoic acid receptors in intestinal mucosa and the effect of vitamin A on mucosal immunity. *Nutrition*. 2010;**26**:740-745
- [10] Kang SG, Wang C, Matsumoto S, et al. High and low vitamin A therapies induce distinct FoxP3⁺ T-cell subsets and effectively control intestinal inflammation. *Gastroenterology*. 2009;**137**:1391-1402
- [11] Okayasu I. Development of ulcerative colitis and its associate colorectal neoplasia as a model of the organ-specific chronic inflammation-carcinoma sequence. *Pathology International*. 2012;**62**:368-380
- [12] Blomhoff R, Wake K. Perisinusoidal stellate cells of the liver: Important roles in retinol metabolism and fibrosis. *The FASEB Journal*. 1971;**5**:271-277
- [13] Senoo H, Wake K. Suppression of experimental hepatic fibrosis by administration of vitamin A. *Laboratory Investigation*. 1985;**85**:182-192
- [14] Rojkind M, Novikoff PM, Greenwel P, et al. Characterization and functional studies on rat liver fat-storing cell line and freshly isolated hepatocyte coculture system. *The American Journal of Physiology*. 1995;**146**:1508-1520
- [15] Sporn MB, Roberts AB, Goodman DS. *The Retinoids*. New York: Raven Press; 1994. p. 658
- [16] Senoo H, Stang E, Nilsson A, et al. Internalization of retinol-binding protein in parenchymal and stellate cells of rat liver. *Journal of Lipid Research*. 1990;**31**:1229-1239
- [17] Andersen KB, Nilsson A, Blomhoff HK, et al. Direct mobilization of retinol from hepatic perisinusoidal stellate cells

to plasma. *The Journal of Biological Chemistry*. 1992;**267**:1340-1344

[18] Zajicek G, Oren R, Weinreb M Jr. The streaming liver. *Liver*. 1985;**5**:293-300

[19] Sell S. Is there a liver stem cell? *Cancer Research*. 1990;**50**:3811-3815

[20] Sigal SH, Brill S, Fiorino AS, Reid LM. The liver as a stem cell and lineage system. *The American Journal of Physiology*. 1992;**263**:G139-G148

[21] Kordes C, Haussinger D. Hepatic stem cell niches. *The Journal of Clinical Investigation*. 2013;**123**:1874-1880

[22] Besshi K, Fujiwara M, Senoo H, et al. Zonal distribution of stellate cells containing vitamin A lipid droplets in subjects with chronic active hepatitis C. *Cells of the Hepatic Sinusoid*. 2001;**8**:215-216

[23] Okayasu I, Mikami T, Yoshida T, et al. Cytoglobin expression of rectal subepithelial myofibroblasts: Significant alteration of cytoglobin⁺ stromal cells in long-standing ulcerative colitis. *Histology and Histopathology*. 2011;**26**:679-688

[24] Plateroti M, Rubin DC, Duluc I, et al. Subepithelial fibroblast cell lines from different levels of gut axis display regional characteristics. *The American Journal of Physiology*. 1998;**274**:G945-G954

[25] Janesick W, Wu SC, Blumberg B. Retinoic acid signaling and neuronal differentiation. *Cellular and Molecular Life Sciences*. 2015;**72**:1559-1576

[26] Samuel S, Walsh R, Webb J, et al. Characterization of putative stem cells in isolated human colonic crypt epithelial cells and their interactions with myofibroblasts. *American Journal of Physiology. Cell Physiology*. 2009;**296**:C296-C305

[27] Lahar N, Lei NY, Wang J, et al. Intestinal subepithelial myofibroblasts support in vitro and in vivo growth of human small intestinal epithelium. *PLoS One*. 2011;**6**:e26898. DOI: 10.1371/journal.pone.0026898

[28] Fujiwara M, Besshi K, Takemura T, et al. Periportal stellate cells in subjects with chronic hepatitis C with a varied serum alanine aminotransferase level. *Comparative Hepatology*. 2004;**3** (Suppl I):S15, 1-3

[29] Fujiwara M, Besshi K, Takemura T, et al. Smoking influence on periportal vitamin A-rich stellate cells in subjects with hepatitis C. *Cells of the Hepatic Sinusoids*. 1997;**6**:300-301

[30] Guyot C, Lepreux S, Combe C, et al. Hepatic fibrosis and cirrhosis: The (myo) fibroblastic cell subpopulations involved. *The International Journal of Biochemistry & Cell Biology*. 2006;**38**:135-151

[31] Tanaka H, Hiyama T, Tsukuma H, et al. Cumulative risk of hepatocellular carcinoma in hepatitis C virus carriers: Statistical estimation from cross-sectional data. *Japanese Journal of Cancer Research*. 1994;**85**:485-490

[32] Borzio M, Bruno S, Roncalli M, et al. Liver cell dysplasia is a major risk factor for hepatocellular carcinoma in cirrhosis: A prospective study. *Gastroenterology*. 1995;**108**:812-817

[33] Roudot-Thoraval F, Bastie A, Pawlotsky JM, et al. Epidemiological factors affecting the severity of hepatitis C virus-related liver disease: A French survey of 6,664 patients. The study group for the prevalence and the epidemiology of hepatitis C virus. *Hepatology*. 1997;**26**:485-490

[34] The Liver Cancer Study Group of Japan. Survey and follow-up study of primary liver cancer in Japan-report 10

- (1988-89). *Acta Hepatologica Japonica*. 1993;**34**:805-813
- [35] Tsukuma H, Hiyama T, Tanaka S, et al. Risk factor for hepatocellular carcinoma among patients with chronic liver disease. *The New England Journal of Medicine*. 1993;**328**:1707-1801
- [36] Fujita Y, Shibata A, Ogimoto I, et al. The effect of interaction between hepatic C virus and cigarette smoking on the risk of hepatocellular carcinoma. *British Journal of Cancer*. 2006;**94**:737-739
- [37] Li D, Walcott FL, Chang P, et al. Genetic and environmental determinants on tissue response to in vitro carcinogen exposure and risk of breast cancer. *Cancer Research*. 2002;**62**:4566-4570
- [38] Tetyakova N, Matter B, Jones R, et al. Formation of benzopyrene diol epoxide-DNA adducts at specific guanines within K-ras and p53 gene sequences: Stable isotope-labeling mass spectrometry approach. *Biochemistry*. 2002;**41**:9535-9544
- [39] Okayasu I, Hatakeyama S, Yamada M, et al. A novel method in the induction of reliable experimental acute and chronic ulcerative colitis in mice. *Gastroenterology*. 1990;**98**:694-702
- [40] Okayasu I, Hana K, Nemoto N, et al. Vitamin A inhibits development of dextran sulfate sodium-induced colitis and colon cancer in a mouse model. *BioMed Research International*. 2016;**2**:11, 4874809. DOI: 10.1155/2016/4874809
- [41] Iwata M, Hirakiyama A, Eshima Y, et al. Retinoic acid imprints gut-homing specificity on T cells. *Immunity*. 2004;**21**:527-538
- [42] Goverse G, Oliver BJ, Molenaar R, et al. Vitamin A metabolism and mucosal immune function are distinct between BALB/c and C57BL/6 mice. *European Journal of Immunology*. 2015;**45**:89-100
- [43] Yokota A, Takeuchi H, Maeda N, et al. GM-CSF and IL-4 synergistically trigger dendritic cells to acquire retinoic acid-producing capacity. *International Immunology*. 2009;**21**:361-377
- [44] Iwata M. Retinoic acid production by intestinal dendritic cells and its role in T-cell trafficking. *Seminars in Immunology*. 2009;**21**:8-13
- [45] Mora JR, Iwata M, Eksteen B, et al. Generation of gut-homing IgA-secreting B cells by intestinal dendritic cells. *Science*. 2006;**314**:1157-1160
- [46] Bjersing J, Telemo E, Dahlgren U, et al. Loss of ileal IgA⁺ plasma cells and of CD4⁺ lymphocytes in ileal Peyer's patches of vitamin A deficient rats. *Clinical and Experimental Immunology*. 2002;**130**:404-408
- [47] Okayasu I, Ohkusa T, Kajiura K, et al. Promotion of colorectal neoplasia in experimental murine ulcerative colitis. *Gut*. 1996;**39**:87-92
- [48] Batourina E, Gim S, Bello N, et al. Vitamin A controls epithelial/mesenchymal interactions through *Ret* expression. *Nature Genetics*. 2001;**27**:74-78
- [49] Hansen LA, Sigman CC, Andreola F, et al. Retinoids in chemoprevention and differentiation therapy. *Carcinogenesis*. 2000;**21**:1271-1279
- [50] French AL, Kirstein LM, Massad LS, et al. Association of vitamin A deficiency with cervical squamous intraepithelial lesions in human immunodeficiency virus-infected women. *The Journal of Infectious Diseases*. 2000;**182**:1084-1089
- [51] Li K, Gao J, Xiao X, et al. The enhancing role of vitamin A deficiency

on chemically induced nephroblastoma in rats. *Journal of Pediatric Surgery*. 2005;**40**:1951-1956

[52] Bernstein A, Harris B. The relationship of dietary and serum vitamin A to the occurrence of cervical intraepithelial neoplasia in sexually active women. *American Journal of Obstetrics and Gynecology*. 1984;**148**:309-312

[53] Stehr PA, Gloninger MF, Kuller LH, et al. Dietary vitamin A deficiencies and stomach cancer. *American Journal of Epidemiology*. 1985;**121**:65-70

[54] Zou CP, Clifford JL, Xu XC, et al. Modulation by retinoic acid (RA) of squamous cell differentiation, cellular RA-binding proteins, and nuclear RA receptors in human head and neck squamous cell carcinoma cell lines. *Cancer Research*. 1994;**54**:5479-5487

[55] Hansen LA, Brown D, Virador V, et al. A PMLRARA transgene results in a retinoid-deficient phenotype associated with enhanced susceptibility to skin tumorigenesis. *Cancer Research*. 2003;**63**:5257-5265

[56] Osanai M, Sawada N, Lee GH. Oncogenic and cell survival properties of the retinoic acid metabolizing enzyme, CYP26A1. *Oncogene*. 2010;**29**:1135-1144

[57] Osanai M, Lee GH. Enhanced expression of retinoic acid-metabolizing enzyme CYP26A1 in sunlight-damaged human skin. *Medical Molecular Morphology*. 2011;**44**:200-206

[58] Osanai M, Lee GH. Increased expression of the retinoic acid-metabolizing enzyme CYP26A1 during the progression of cervical squamous neoplasia and head and neck cancer. *BMC Research Notes*. 2014;**7**:697. DOI: 10.1186/1756-0500-7-697

[59] Bhattacharya N, Yuan R, Prestwood TR, et al. Normalization of

microbiota-induced protective retinoic acid deficiency stimulates protective CD8⁺ T cell-mediated immunity in colorectal cancer. *Immunity*. 2016;**45**:641-6455

[60] Bousvaros A, Zurakowski D, Duggan C, et al. Vitamins A and E serum levels in children and young adults with inflammatory bowel disease: Effect of disease activity. *Journal of Pediatric Gastroenterology and Nutrition*. 1998;**26**:129-135

[61] Alkhoury RH, Hashmi H, Baker RD, et al. Vitamin and mineral status in patients with inflammatory bowel disease. *Journal of Pediatric Gastroenterology and Nutrition*. 2013;**56**:89-92

[62] Barreto ML, Santos LM, Assis AM, et al. Effect of vitamin A supplementation on diarrhea and acute lower-respiratory-tract infections in young children in Brazil. *Lancet*. 1994;**344**(8917):228-231

[63] Nishida A, Inoue R, Inatomi O, et al. Gut microbiota in the pathogenesis of inflammatory bowel disease. *Clinical Journal of Gastroenterology*. 2018;**11**:1-10

[64] Tilg H, Adolph TE, Gerner RR, Moschen AR. The intestinal microbiota in colorectal cancer. *Cancer Cell*. 2018;**33**:954-964

[65] Santana RC, Machado AA, Martinelli AL, et al. Assessment of indicators of vitamin A status in non-cirrhotic chronic hepatitis C patients. *Brazilian Journal of Medical and Biological Research*. 2016;**49**(1):e4785. DOI: 10.1590/1414-431X20154785

[66] Kataria A, Deaton RJ, Enk E, et al. Retinoid and carotenoid status in serum and liver among patients at high-risky for liver cancer. *BMC Gastroenterology*. 2016;**16**:30. DOI: 10.1186/s12876-016-0432-5

[67] Lan A, Blachier F, Benamouzig R, et al. Mucosal healing in inflammatory bowel diseases: Is there a place for nutritional supplementation? *Inflammatory Bowel Diseases*. 2015;**21**:198-207

[68] Owczarek D, Rodacki T, Domagala-Rodacka R, et al. Diet and nutritional factors in inflammatory bowel diseases. *World Journal of Gastroenterology*. 2016;**22**:895-905