

We are IntechOpen, the world's leading publisher of Open Access books Built by scientists, for scientists

6,900

Open access books available

186,000

International authors and editors

200M

Downloads

Our authors are among the

154

Countries delivered to

TOP 1%

most cited scientists

12.2%

Contributors from top 500 universities



WEB OF SCIENCE™

Selection of our books indexed in the Book Citation Index
in Web of Science™ Core Collection (BKCI)

Interested in publishing with us?
Contact book.department@intechopen.com

Numbers displayed above are based on latest data collected.
For more information visit www.intechopen.com



Malignant Migrating Partial Seizures of Infancy (Coppola-Dulac Syndrome)

Alexey Kholin

Abstract

Malignant migrating partial seizures of infancy (MMPSI) is a rare and usually an unrecognized epileptic syndrome of infancy. The first publication was presented by Coppola and colleagues in 1995, and Dulac in 2005 summarized 24 patients' follow-up in the Saint Vincent de Paul Hospital in Paris. Clinical cases have demonstrated a new epileptic syndrome, different from previously described forms of epileptic encephalopathies of infancy for the whole world of epileptology. Seizure onset before the age of 6 months but commonly start within a few weeks of birth. In the age of 1 to 10 months seizures become very frequent, polymorphic and usually get clustered nature; mental and motor retardation is clear observed. Clinical manifestation of seizures may include head and eyes version, lateralized clonic eyelid twitchings, fixed gaze, tonic tension or clonias of one limb or hemispasms, axial tonic spasms, chewing or sucking movements, episodes of apnea, flushing, hypersalivation, and secondary generalized seizures. MMPSI could be also considered as a special type of infantile status epilepticus. Video-EEG monitoring plays the most important role in the MMPSI diagnosis. Ictal EEG patterns involve different areas of the cerebral cortex of both hemispheres; initial zone of ictal patterns shifts from one region to another. MMPSI is a drug-resistant epilepsy with serious prognosis.

Keywords: malignant migrating partial seizures of infancy, Coppola-Dulac syndrome, status epilepticus in infancy, epileptic encephalopathy

1. Introduction

Malignant migrating partial seizures of infancy (MMPSI) is a rare and usually an unrecognized epileptic syndrome of infancy. The International League Against Epilepsy defines this form of epilepsy as follows: seizure onset in the first 6 months of life, occurrence of almost continuous migrating polymorphous focal seizures, combined with multifocal ictal EEG discharges, and progressive deterioration of psychomotor development [1–3]. Exact criteria of MMPSI are not defined and are being developed. According to the draft of the Classification of the Epilepsies 2001, this syndrome refers to presumably symptomatic neocortical focal epilepsy. In the new Classification of the Epilepsies 2017 (ILAE 2017), MMPSI has not found a separate place, but it is implied that it includes in a group of developmental and epileptic encephalopathy.

This severe form of epilepsy was recently described. The first publication about migrating partial seizures of infancy was presented by Coppola and colleagues in 1995 [1], and then personal observations were done by Gerard et al. [4] and by Okuda et al. [5]. Veneselli et al. summarized previous observations and added three own cases [6]. Coppola et al. in their remarkable report (1995) based on neuropsychiatric department at the René Descartes University (Paris) presented 14 clinical cases of infants of both sexes with previously undescribed epileptic syndrome characterized by virtually continuous multifocal seizures. According to the classical authors description, the first seizures occurred average at the age of 3 months without any significant previous events. During the period from 1 to 10 months, seizures became very frequent. Seizures were focal and had different clinical characteristics; EEG revealed multiple epileptiform discharges arising independently and with migration during subsequent seizures from one cortical region to another. Patients had regression of psychomotor development, tetraparesis and severe muscular hypotonia of axial muscles. Three of 14 patients died: one at the age of 7 months, and other at the age of 7 and 8 years. Seizures were completely ceased only in two patients. In most cases the cause of the disease was not identified; and there were no family cases [1].

In 2005, Dulac summarized 24 patients' follow-up (the largest number of verified cases in the world) in the Saint Vincent de Paul Hospital in Paris. Marsh et al. [25] reported another six cases of MMPSI observed in the Philadelphia Children's Hospital University of Pennsylvania who met the criteria described by Coppola. Presented clinical cases have demonstrated a new epileptic syndrome, different from previously described forms of epileptic encephalopathies of infancy for the whole world epileptology [3].

Synonyms of this epileptic syndrome in the world scientific literature are malignant migrating partial seizures of infancy, migrating partial seizures of infancy, malignant epilepsy of infancy with migrating multifocal seizures, Coppola-Dulac syndrome, and most genetic verified cases, which can be referred to early infantile epileptic encephalopathy type 14 (EIEE14).

2. Etiology

In most MMPSI cases, etiology remains unknown; familial cases are rare. In observation by Dulac, relatives in 3 of 24 patients had febrile convulsions, and 4 patients had family history of epilepsy [3]. Multiple tests for inherited metabolism defects had negative results [7].

2.1 Monogenic mutations with Mendelian type of inheritance

The first genetic sequencing for identification mutations specific for MMPSI was carried out by Coppola et al. [8]. Was performed automatic sequencing of genes of potassium (KCNQ2, KCNQ3) and sodium (SCN1A, SCN2A) ion channels in three children with MMPSI but no mutation have been found. Mutational screening of chloride (CLCN2) ion channel gene revealed a homozygous mutation G2003C (exon 17), leading to a Ser/Thr substitution at the codon 668, in two of the three patients. But the same variation has been found in 38 out of 100 control alleles [8].

At present time a number of monogenic mutations were identified in patients with malignant migrating partial seizures of infancy. In catalog of human genes and genetic disorders – Online Mendelian Inheritance in Man (OMIM), we could find the following positions for MMPSI phenotype (**Table 1**):

Phenotype OMIM classification	Phenotype OMIM number	Gene/ locus	Gene OMIM number	Location	Mutation variants	Inheritance	References
Early infantile epileptic encephalopathy type 3 (EIEE3)	609304	SLC25A22	609302	11p15.5	gly110arg; (.0003)	AR	Poduri et al. [9]
Early infantile epileptic encephalopathy type 6 (EIEE6)	607208	SCN1A	182389	2q24.3	ala1669gly (.0023) arg862gly (.0024)	AD	Freilich et al. [10] Carranza Rojo et al. [11]
Early infantile epileptic encephalopathy type 13 (EIEE13)	614558	SCN8A	600702	12q13.13	phe846ser	AD	Ohba et al. [12]
Early infantile epileptic encephalopathy type 14 (EIEE14)	614959	KCNT1	608167	9q34.3	arg428glm (.0001) ala934thr (.0002) arg474his (.0003) ile760met (.0004) phe932ile (.0009) gly288ser (.0010)	AD	Barcia et al., [13] Vanderver et al. [14] Ishii et al. [15]
Early infantile epileptic encephalopathy type 16 (EIEE16)	615338	TBC1D24	613577	16p13.3	phe229ser (.0005) + cys156ter (.0006)	AR	Millh et al. [18]
Progressive microcephaly with seizures and cerebral and cerebellar atrophy (MSCCA)	615760	QARS	603727	3p21.31	tyr57his (.0003) + arg515trp (.0004)	AR	Zhang et al. [19]

Table 1.
Monogenic mutations as etiological factors of malignant migrating partial seizures of infancy

2.1.1 Early infantile epileptic encephalopathy type 3 (EIEE6; 609304)

Poduri et al. [9] reported about two sibs (brother and sister), born of consanguineous Saudi Arabian parents, with EIEE3 presenting MMPSI phenotype. EEG showed abnormal spikes in various brain regions. Neurological signs included hypotonia and brisk tendon reflexes; psychomotor development was delayed and subsequently arrested. Brain MRI was normal in the boy but showed delayed myelination and diffuse thinning of the corpus callosum in his sister. Two sibs had polymorphic seizures including bilateral and hemiclonic convulsions, flushing of the face, “staring,” and eventually bilateral eyelid blinking. The seizures in both children were refractory to treatment. The boy developed seizure onset at 1 week of age and died at 14 months; the girl presented first seizures at 2 weeks of age and died at 47 months of age. They also had two healthy brothers. The research team

analyzed consanguineous pedigree (parents are cousins) and obtained DNA from affected and unaffected family members, analyzed single nucleotide polymorphism (SNP) 500 K data to identify regions with evidence for linkage, performed whole-exome sequencing, analyzed homozygous variants in regions of linkage to identify a candidate gene, and performed functional studies of the candidate gene SLC25A22. In affected siblings, a homozygous c.328G-C transversion in the SLC25A22 gene was identified, resulting in a gly110-to-arg (G110R; 609302.0003) substitution at a highly conserved residue in the third transmembrane helix [9].

2.1.2 Early infantile epileptic encephalopathy type 6 (EIEE6; 607208)

It is a well-known fact that mutation in SCN1A is a leading etiological factor for severe myoclonic epilepsy of infancy (Dravet syndrome). OMIM genetic classification is early infantile epileptic encephalopathy type 6 (607208) with autosomal dominant inheritance. Nevertheless, Freilich et al. [10] have found a novel mutation in the SCN1A gene in the girl with MMPSI who died at the age of 9 months from recurrent status epilepticus (SE). This girl had a severe phenotype, with onset of seizures at age 10 weeks, progression to refractory recurrent seizures by age 5 months, SE of migrating multifocal seizures confirmed by EEG monitoring, progressive microcephaly, and profound psychomotor delay. By sequencing genomic DNA from blood, the heterozygous missense mutation c.C5006C > A transversion in the SCN1A gene, resulting in an ala1669-to-glu (A1669E; 182389.0023), which further was confirmed in brain DNA, was identified. The resulting amino acid substitution p.A1669E alters an evolutionarily conserved residue in an intracellular linker of domain 4 of the SCN1A sodium channel protein [10].

In a scientific group of Epilepsy Research Centre, Department of Medicine, University of Melbourne, Australia, Carranza Rojo et al. [11] have investigated 15 unrelated children with MMPSI for mutations in genes associated with infantile epileptic encephalopathies (SCN1A, CDKL5, STXBP1, PCDH19, and POLG). One girl with seizure onset at 2 weeks had heterozygous missense mutation de novo 2584C-G transversion in exon 14 of the SCN1A gene, resulting in an arg862-to-gly (R862G; 182389.0024) that affects the sodium channel by substitution in the voltage sensor segment S4 of the second protein domain. She had epilepsy onset of alternative hemiclonic seizures (Dravet-like onset) at the age of 2 weeks with developing status epilepticus of multifocal migrating seizure. Also, the girl had acquired microcephaly, developmental regression, and severe intellectual disability with much more severe phenotype than children with Dravet syndrome. And, another girl who developed MMPSI at the age of 2 months had de novo 11.06 Mb deletion of chromosome 2q24.2q31.1 encompassing more than 40 genes that included SCN1A. Screenings of CDKL5, STXBP1, and PCDH19 and the three common European mutations of POLG were negative [11].

Along with Dravet and MMPSI syndromes, mutation in SCN1A gene has been also associated with generalized epilepsy with febrile seizures plus type 2 (604403), familial febrile seizures type 3A (604403), and familial hemiplegic migraine type 3 (609634). All the diseases have autosomal dominant inheritance.

2.1.3 Early infantile epileptic encephalopathy type 13 (EIEE13; 614558)

Ohba et al. [12] identified in seven unrelated patients with early-onset epileptic encephalopathies seven different de novo heterozygous missense mutations in the SCN8A gene, and one of them had MMPSI. In a 5-year-old bedridden severe delayed and profound intellectual disabled Japanese boy by whole-exome sequencing, de novo previously not described mutation in SCN8A gene c.2537 T > C

(p.Phe846Ser) was detected. He developed apnea seizures from the age of 2 months and further at 4 months demonstrated migrating hemiclonic convulsions increasing up to status epilepticus of multifocal migrating seizures. MRI has shown mild atrophy of the cerebellum and thin corpus callosum. High-dose combined antiepileptic therapy with phenobarbital, phenytoin, and lamotrigine, ketogenic diet, and vagus nerve stimulator (VNS) implantation are temporarily and partially effective [12].

Voltage-dependent sodium channels, such as SCN8A, are responsible for the initial membrane depolarization that occurs during generation of action potentials in most electrically excitable cells. Mutations in KCNT1 aside from E1EE13 also determine benign familial infantile seizures type 5 (OMIM 617080) and cognitive impairment with or without cerebellar ataxia (OMIM 614306) with autosomal dominant inheritance.

2.1.4 Early infantile epileptic encephalopathy type 14 (E1EE14; 614959)

Barcia et al. in 2012 had identified four different de novo heterozygous mutations in the KCNT1 gene (608167.0001–608167.0004) in 6 of 12 unrelated pediatric patients (50%) with clinical manifestation as MMPSI. The gene KCNT1 encodes a sodium-activated potassium channel that is widely expressed at the nervous system. Its activity contributes to the slow hyperpolarization as the neuronal membrane potential that follows repetitive firing. The C-terminal cytoplasmic domain interacts with a protein network, including FMRP (fragile X mental retardation protein), suggesting additional functions [13].

OMIM genetic classification for this type of MMPSI is early infantile epileptic encephalopathy type 14 (614959). At present time, the following allelic variants of KCNT1 gene mutation in patients with MMPSI were identified:

ARG428GLN (608167.0001 KCNT1). It was founded by Barcia et al. [13] in three unrelated patients of French origin and was identified as de novo heterozygous 1283G-A transition in exon 13 of the KCNT1 gene, resulting in an arg428-to-gln substitution at a highly conserved residue in the cytoplasmic C-terminal domain.

ALA934THR (608167.0002 KCNT1). In a child of French origin with MMPSI, Barcia et al. [13] identified a de novo heterozygous 2800G-A transition in exon 24 of the KCNT1 gene, resulting in an ala934-to-thr substitution at a highly conserved residue in the cytoplasmic C-terminal domain. The mutation was shown to cause constitutive activation of the sodium-activated potassium channel, mimicking the effects of phosphorylation of the C-terminal domain by protein kinase C activation.

ARG474HIS (608167.0003 KCNT1). It was identified in a patient of French origin with MMPSI by Barcia et al. [13] as de novo heterozygous 1421G-A transition in exon 15 of the KCNT1 gene, resulting in an arg474-to-his substitution at a highly conserved residue.

ILE760MET (608167.0004 KCNT1). It was also founded by Barcia et al. [13] in a child of Ukrainian origin with early clinical manifestation of MMPSI and was identified as de novo heterozygous 2280C-G transversion in exon 20 of the KCNT1 gene, resulting in an ile760-to-met substitution at a highly conserved residue.

All these mutations were identified by exome sequencing and also were confirmed by Sanger sequencing. Mutations were not found in 200 controls or in several large control databases [13].

PHE932ILE (608167.0009 KCNT1). Vanderver et al. [14] identified in an Australian boy the de novo heterozygous c.2794 T-A transversion in the KCNT1 gene, resulting in a phe932-to-ile substitution at a highly conserved residue in the cytoplasmic C-terminal domain. This mutation was found by whole-exome sequencing, confirmed by Sanger sequencing, and was not present in the 1000

Genomes Project or Exome Sequencing Project databases. Seizure onset was at age of 1 month with refractory myoclonic seizures that progressed to different polymorphic seizure types and status epilepticus. He also had microcephaly and severe developmental stagnation. Brain imaging showed serious delayed myelination, and EEG demonstrated background slowing with multifocal interictal discharges and occasional periods of burst suppression. The patient doesn't have classical MMPSI characteristics and survived (last observation at the age of 10) with a decrease of pharmacoresistant seizures at the age of 7 [14].

GLY288SER (608167.0010 KCNT1). Ishii et al. in two unrelated Japanese girls with MMPSI identified a de novo heterozygous c.862G-A transition in the KCNT1 gene, resulting in a gly288-to-ser substitution at a highly conserved residue in the pore region of the channel [15].

Kawasaki et al. described three infants with malignant migrating partial seizures with KCNT1 mutations accompanied by massive systemic to pulmonary collateral arteries with life-threatening hemoptysis and heart failure [16].

Madaan with colleagues from Child Neurology Division, Department of Pediatrics, All India Institutes of Medical Sciences (New Delhi, India), in 2018 identified a child with MMPSI who had a novel heterozygous missense mutation in exon 10 of the KCNT1 gene (chr9:138650308; c.808C > C/G (p.Q270E)). Neither quinidine nor ketogenic diet could control his seizures, and the child succumbed to his illness at 9 months of age [17].

My personal observation consists of two Russian girls with MMPSI having KCNT1 mutations: one with gly288ser (608167.0010 KCNT1) and the other with previously not described mutations c.1066C > T (arg356trp) in exon 12 (chr9:138656907C > T, rs752514808). So, it seems that KCNT1 is a major disease-associated gene for the MMPSI phenotype.

It is interesting that mutations in KCNT1 also determine another form of epilepsy – nocturnal frontal lobe epilepsy type 5. But the mutation is different from the cases of MMPSI and is marked .0005–.0008 (ARG928CYS, TYR796HIS, ARG398GLN, and MET896ILE).

2.1.5 Early infantile epileptic encephalopathy type 16 (EIEE14; 615338)

Milh et al. [18] identified compound heterozygosity for two mutations in exon 2 of the TBC1D24 gene (686 T-C transition, resulting in a phe229-to-ser, 613577.0005, and 468C-A transversion, resulting in a cys156-to-ter, 613577.0006) in two sisters with malignant migrating partial seizures of infancy. These girls early developed clonic seizures in the second month of life and subsequently demonstrated prolonged, almost continuous migrating seizures of different types with severe neurologic deterioration and lack of psychomotor development [18].

OMIM genetic classification for this type of MMPSI – early infantile epileptic encephalopathy type 16 (615338). The screening of TBC1D24 in an additional set of eight MMPSI patients observed by Milh and colleagues was negative. The TBC1D24 gene encodes a member of the Tre2-Bub2-Cdc16 (TBC) domain-containing RAB-specific GTPase-activating proteins, which coordinates peripheral membrane Rab proteins and other GTPases for the proper transport of intracellular vesicles. Coimmunoprecipitation studies showed that the phe229ser mutation impaired the interaction of TBC1D24 with adenosine diphosphate (ADP)-ribosylation factor 6 (ARF6, 600,464), and overexpression of the mutant protein in primary cortical neurons abolished the ability of TBC1D24 to increase neurite length and arborization, consistent with a loss of function [18].

Mutation in TBC1D24 gene has been also associated to infantile familial myoclonic epilepsy (OMIM 605021, autosomal recessive inheritance), DOORS syndrome (deafness, onychodystrophy, osteodystrophy, mental retardation, and seizures syndrome – OMIM 220500) with autosomal recessive inheritance, and also autosomal recessive deafness type 86 (614617), and autosomal dominant deafness type 65 (616044).

2.1.6 Progressive microcephaly with seizures and cerebral and cerebellar atrophy (MSCCA; 615760)

Zhang et al. [19] in four patients from two unrelated families with progressive microcephaly, intractable seizures, and cerebral and cerebellar atrophy (MSCCA; 615,760) identified compound heterozygous mutations in the QARS gene (603727.0001–603727.0004). The mutations were found by whole-exome sequencing and confirmed by Sanger sequencing. QARS (or GLNRS; 603,727) is a class I aminoacyl-tRNA synthetase. Aminoacyl-tRNA synthetases are enzymes that charge tRNAs with their cognate amino acids. The specificity of this reaction determines the fidelity of mRNA translation. At least one synthetase exists in the cytoplasm for each amino acid. QARS is essential for normal brain development. Studies in patient cells and expression of recombinant variants in *E. coli* showed that all four mutations caused a severe loss of QARS catalytic activity, consistent with a loss-of-function effect. Homozygous loss of QARS in zebrafish caused decreased brain and eye size and extensive cell death in the brain. Two sibs observed by Zhang et al. [19], born of unrelated French parents, had clinical and EEG signs of malignant migrating partial seizures of infancy and compound heterozygous mutations in the QARS gene, a c.169 T-C transition, resulting in a tyr57-to-his (603727.0003) substitution at a highly conserved residue in the N-terminal domain, and a c.1543C-T transition, resulting in an arg515-to-trp (603727.0004) substitution at a highly conserved residue in the catalytic domain. Patient cells showed decreased aminoacylation activity of QARS compared to control. Expression of recombinant arg515trp (.0004) in *E. coli* resulted in no QARS catalytic activity, whereas tyr57his (.0003) decreased QARS activity to less than 10% that of controls. In addition, the arg515trp mutation appeared to cause protein misfolding and aggregation, resulting in decreased expression of the soluble mutant protein [19].

2.1.7 Rhizomelic chondrodysplasia punctata type 2 (RCDP2; 222765)

On personal observation of MMPSI patients, one Russian boy with clinical and electroencephalographic pattern of mixed form (MMPSI and early myoclonic encephalopathy) had rhizomelic chondrodysplasia punctata type 2 (RCDP2; 222,765) from the group of peroxisomal metabolic diseases [20]. Rhizomelic chondrodysplasia punctata type 2 (RCDP2) is caused by homozygous or compound heterozygous mutation in the DHAPAT gene (GNPAT; 602,744), which encodes acyl-CoA: dihydroxyacetonephosphate acyltransferase, on chromosome 1q42. This peroxisomal disorder is characterized by disproportionately short stature primarily affecting the proximal parts of the extremities, a typical facial appearance including a broad nasal bridge, epicanthus, high-arched palate, micrognathia, dysplastic external ears, eye abnormalities-cataract and coloboma, congenital contractures, dwarfism, hypotonia, and severe mental retardation. Biochemically, plasmalogen synthesis and phytanic acid alpha-oxidation are defective.

2.2 Chromosome aberrations

At 2010 group of genetics from the Department of Pediatrics, University of Michigan (Ann Arbor, Michigan, USA), has found de novo 598 kb 16p11.2 microduplication in a boy with refractory MMPSI, who has developed seizures in 4 months and also has spastic quadriplegia, severe global developmental delay, hypotonia, and microcephaly [21].

In 2012 Poduri and colleagues from the Department of Neurology of Children's Hospital Boston (Massachusetts, USA) in a patient, born of consanguineous Palestinian parents, with clinical manifestation as MMPSI, identified a homozygous 486-kb deletion on chromosome 20p12.3 encompassing the promoter region and exons 1, 2, and 3 of the PLCB1 gene. The deletion breakpoints were mapped from 8,094,049–8,094,072 to 8,580,261–8,580,284 (GRCh37). The breakpoints lie within two LINE nuclear elements and likely arose from nonallelic homologous recombination. PLCB1 gene (607,120; locus 20p12.3) is responsible for early infantile epileptic encephalopathy type 12 (EIEE12; 613,722). Phospholipase C-beta (PLCB) catalyzes the generation of inositol 1,4,5-trisphosphate (IP3) and diacylglycerol (DAG) from phosphatidylinositol 4,5-bisphosphate (IP2), a key step in the intracellular transduction of many extracellular signals. The PLCB1 gene encodes a mammalian PLCB isoform that is expressed in cerebral cortex, hippocampus, amygdala, lateral septum, and olfactory bulb [22].

2.3 Other etiological factors

Most cases of MMPSI are considered as unknown etiology (cryptogenic). But also MMPSI had its symptomatic analogs including cases considered as dual pathology [1–3, 20, 23].

In two of three cases for the first time presented by Coppola et al., neuropathologic brain examination showed marked loss of hippocampal neurons in combination with gliosis in the CA1 sector of hippocampal pyramidal layer [1, 23].

Personal observation of 35 cases with MMPSI contains 12 children with symptomatic clinical-electroencephalographic copies of MMPSI (5 boys and 7 girls). Only two infants had cerebral dysgenesis: lissencephaly-pachygyria in one girl and polymicrogyria in another girl. Other ten children had severe perinatal hypoxic-ischemic CNS disturbances (four of them mixed with perinatal infections-cytomegalovirus, ureaplasma, chlamydia, herpes type 1) that caused serious brain damage, tetraparetic spastic form of cerebral palsy, and severe retardation in combination with epileptic encephalopathy. Their clinical and video-EEG signs demonstrated MMPSI picture.

3. Clinical signs

At the present time, at least about 100 cases of MMPSI appear to be described in the world literature. However, the number of publications has been steadily growing in recent years. Obviously, this serious disease is more common than diagnosed due to the low clinicians' awareness. In the structure of patients with onset of status epilepticus before 3 years of age ($n = 267$), a group of children with MMPSI consisted 4.9% ($n = 13$), and in the structure of infant with SE ($n = 147$) – 8.8% [24].

Both sexes are equally susceptible. According to Dulac, 20 children with MMPSI included 9 girls and 11 boys [3]. Disease onset varies in age from 1 week to 7 months of life (average – 3 months) [1, 4]. According to Marsh et al., seizures onset varied from the first days to 3 months (average – 25 days) [25].

In most cases, pattern of the first seizure includes motor component of one limb or half of the body; and 50% of the patients develop secondary generalization. In some cases after seizure onset, their frequency uncontrolled rapidly rises to status epilepticus. However, seizures could have longer duration, but at onset seizures often go unrecognized. Cases with autonomic manifestation (episodes of apnea, short blackouts with cyanosis or redness) are difficult to diagnose [3]. Thus, in observation by Gerard et al. [4], epileptic seizures with diffuse erythema and sweating with subsequent hiccups were reported as gastroesophageal reflux, and only a few weeks later, addition of focal seizures was noted, which made diagnosis obvious [4]. According to observations by Dulac, the initial period of the disease usually lasts from 1 week to 3 months (average – 45 days). During this period, seizures may be quite rare, for example, once a week [3].

In the age of 24 days to 10 months (mean 4.5 months), seizures become very frequent and polymorphic but usually are still focal. Seizures usually get clustered (serial) nature, mental and motor retardation is clear. Clinical manifestation of seizures may include head and eye version, lateralized eyeball twitching, fixed gaze, clonic eyelid twitching, tonic tension or clonic spasms of one limb or hemispasms, axial tonic spasms, chewing or sucking movements, episodes of apnea, flushing, hypersalivation, and secondary generalized seizures. One patient may have multiple different combinations of seizures. Typically, seizure duration is 1–4 minutes, but in some cases, it may persist up to several 1 of minutes, until the status epilepticus development. As far as the disease progresses, secondary generalized seizures became more frequent. Seizures are almost continuous or occur as a series 5–30 times per day, mainly on awakening and when falling asleep. Seizure periods may alternate with clear periods when seizures occur within 2–5 days continuously, and then there are several “light” days (the cyclic course of disease) [1–3, 26].

It should be considered that many seizures are hardly noticeable visually and often remain unrecognized for parents and medical staff. In particular, these are “volatile” paroxysms, as short episodes of apnea, episodes of eyes closing or eyes deviation, episodes of facial flushing, etc. Only video-EEG monitoring can prove the epileptic genesis of paroxysmal phenomena.

The course of the disease and the severity of clinical symptoms often have undulating pattern: a period of severe illness and permanent seizures may continue for several weeks, and then it is replaced by a relatively favorable period of the temporary seizure regression and some improvement in cognitive and motor functions. This phenomenon generates additional difficulties in controlling the quality of care as it is quite difficult to differentiate in which case the decrease in frequency and severity of seizures is a true response to therapy and in which case it is subject to the course of the disease.

Under personal observation of patients with MMPSI, age of seizure onset ranged from the 1st day of postnatal life up to 6 months of life. MMPSI were characterized by marked polymorphism (**Table 2**) and high frequency of epileptic seizures and were in fact a special form of infantile status epilepticus (SE) in the form of migrating multifocal SE. All patients had five or more types of epileptic seizures.

Neurological findings in MMPSI children marked with neurological impairment from birth-severe central tetraparesis, often with muscular hypotonia in the axial and limb muscles [1], microcephaly, strabismus, and athetoid hyperkinesia [25]-are common. Many patients in dynamics are unable to walk and sit without support and in severe cases are also unable to control the vertical head position, drink, and swallow. In all cases, there is mental retardation, usually severe, and visual agnosia [3].

Personal patients with MMPSI (n = 35) in neurological status had a high representation of various disorders: high level of stigmatization was observed in 15

Seizure types	Patients (n)	%
Tonic versive seizures	35	100
Tonic spasms	33	94.3
Ophthalmic-tonic seizures	35	100
Ophthalmic-clonic seizures	11	31.4
Atonic seizures	23	65.7
Dialeptic (pseudoabsences)	19	54.3
Pharyngo-oral seizures	18	51.4
Tongue clonus	7	20
Hemiclonic	19	54.3
Jacksonian march	11	31.4
Automotor	8	22.9
Apnea with cyanosis	14	40
Autonomic with vomiting	5	14.3
Focal myoclonic	18	51.4
Bilateral myoclonic	13	37.1
Fragmentary “erratic” myoclonus	5	14.3
GTCS	14	40
SE of migratory minor motor seizures	35	100
SE of inhibitory seizures	12	34.3
Hemiconvulsive SE	11	31.4
SE of tonic spasms	10	28.6
Myoclonic SE	9	25.7
SE of GTCS	8	22.9

Table 2.
Epileptic seizure types in patients with malignant migrating partial seizures of infancy (n=35)

patients (42.8%), 13 patients (37.1%) had microcephaly, and optic nerve atrophy was observed in 27 patients (77.1%). Disorders of bulbar innervation were observed in all patients, while in nine children (25.7%), these impairments were bulbar syndrome, and in 26 children (74.3%) – pseudobulbar syndrome. All patients with MMPSI had changes in the muscle tone: 10 children (28.6%) had spastic hypertonus, 16 children (45.7%) had diffuse muscle hypotonia, and 9 children had dystonic changes (25.7%). Severe movement disability with tetraparesis was formed in all of the children with MMPSI. Neurological disorders were expressed at birth (n = 16, 45.7%) or developed with the onset of seizures (n = 19, 54.3%) and tended to a steady progression in all the patients. All children with MMPSI had delay of motor and mental development (n = 35, 100%), up to a complete development stop in 26 infants (74.3%).

4. Electroencephalographic findings and neuroimaging

4.1 EEG and video-EEG monitoring

Diffuse slowing of the main background activity is typical that is revealed in the first EEG recordings. At first epileptic cause of these EEG phenomena may remain

undetected, especially if symptoms include only short autonomic paroxysms. Epileptiform disorders in disease onset are rare. However, in 3 of 14 patients in the observation by Gerard et al. [4], originally normal background EEG was observed; later, slowing with variable asymmetry was recorded in all cases. Often, slow-wave accentuation in one of the EEG recordings is more pronounced in one hemisphere, while the later study may reveal dominating slow-wave lateralization from the opposite side. Multiregional spikes without clear activation during sleep are registered in all cases during development of the disease. However, pathognomonic interictal EEG pattern in MMPSI is absent. During the period relatively free of seizures, stage differentiation in the structure of sleep EEG may persist, but sleep spindles are rare and usually asymmetric [3]. When seizures become very frequent, interictal activity is almost absent.

Ictal EEG patterns involve different areas of the cerebral cortex in the course of successive seizures. Ictal pattern is a rhythmic activity of alpha and theta range, occurring in one region with adjacent regions involvement during seizure, followed by a gradual decrease of the frequency characteristics. Caraballo with colleagues, analyzing 17 infants with MMPSI, had distinguished three different EEG patterns: 8 cases with alternating simple focal motor seizures at onset, and the ictal EEG pattern was characterized by recurrence of rhythmic focal spikes or rhythmic sharp theta or alpha activity in the Rolandic region; 5 cases with complex focal seizures and progressive appearance of polymorphic theta-delta in temporo-occipital regions recurring independently; and 4 cases with focal complex seizures with motor manifestations and ictal EEG with flattening or fast activity in frontotemporal region followed by unilateral fast polyspikes in alternating clusters in both hemispheres. Correlations between these three patterns with severity or prognosis were not found [27]. Electro-clinical seizure patterns last from 1 to 4 minutes. Multiple subclinical ictal EEG patterns lasting from 30 seconds to 1 minute are also typical [1]. Observations show an alternative cortical section of both hemispheres' involvement in epileptogenesis, which implies the presence of a diffuse pathological process in the cerebral cortex [3].

When seizures become very frequent, initial zone of ictal pattern shift from one region to another and from one hemisphere to another occurs. As a result, extended, migratory ictal activity, which forms a complex EEG pattern of status epilepticus, develops [1–3].

Video-EEG monitoring plays the most important role in the MMPSI diagnosis, as it is able to detect a correlation between ictal pattern localization of and clinical characteristics of seizure. Thus, ictal pattern in the frontal region produces clinical signs in the form of tonic tension or clonic spasms in the contralateral limb; ipsilateral automatisms or a versive seizure with alternating tonic phenomena and fencing posture are possible. EEG pattern is localized in perirolandic area and manifests with contralateral clonus of the lips, tongue, facial muscles, and hypersalivation. Temporal EEG patterns clinically manifest with broad “frozen” gaze (“staring” phenomenon) and oro-alimentary automatisms. Ictal EEG patterns originating from occipital cortex correlate with lateralized clonic eyes and head twitching. In the case of parietal pattern, nonspecific motor activity is possible; sometimes, a child seems “listening” to his/her inner feelings. The above phenomena are contrary to a prevailing opinion that there is no clear clinical-electroencephalographic correlation of focal ictal patterns in infants and rather suggest the opposite.

As child grows, the amplitude of ictal activity tends to increase with growing involvement of the frontal lobes; many seizures become secondarily generalized. The phenomenon of secondary bilateral synchronization typically occurs after only a few weeks from the onset [1]. However, Gerard et al. [4] in the last observations found a delay of bilateral synchronization and additional foci of epileptiform

activity generation, at least up to 2 months from the onset (possibly as antiepileptic drug effect) [4]. At this stage detection of early drug resistance may result to a wrong decision about surgical treatment. Extended video-EEG monitoring also has a considerable importance in this category of patients, because visualization of seizures originating from the same cortex area does not mean that all seizures originate only from this area [28].

Despite the various topographies, ictal EEG patterns of all episodes are very similar and correspond to rhythmic activity of the alpha or theta range, prone to the spread and involving all large cortex areas [7].

EEG in personal patients (n = 35) was characterized by diffuse slowing of background activity, while in the developed stage, background EEG was almost completely replaced by continuous ictal patterns. In the initial stages of the disease, interictal record revealed regional or multiregional epileptiform discharges with formation of multifocal independent spike foci (MISF) pattern. Most cases of MMPSI (20 patients, 57.1%) initially had MISF with transformation in MMPSI as frequency of epileptic seizures increased and migratory status developed. In seven cases (20%), monofocal epilepsy was initially observed, followed by addition of extra foci, new types of seizures, and increase of multifocal ictal events up to SE. At eight infants (22.9%), the first properly done EEG investigation fixed the multiregional SE pattern with its preservation in dynamic video-EEG studies and negative prognosis for live.

Ictal EEG patterns in the developed stage of MMPSI involved different areas of the cerebral cortex during a series of seizures, which could overlap each other in cases when ictal pattern in one area is not yet over, but the same pattern appeared in other cortical areas. There may be a complex picture, combining postictal changes in one region of the cerebral cortex, initial ictal pattern in another area, and developed ictal pattern in the third. Typical EEG pattern of MMPSI is presented in a series of electroencephalograms (**Figures 1–7**). In general, ictal pattern

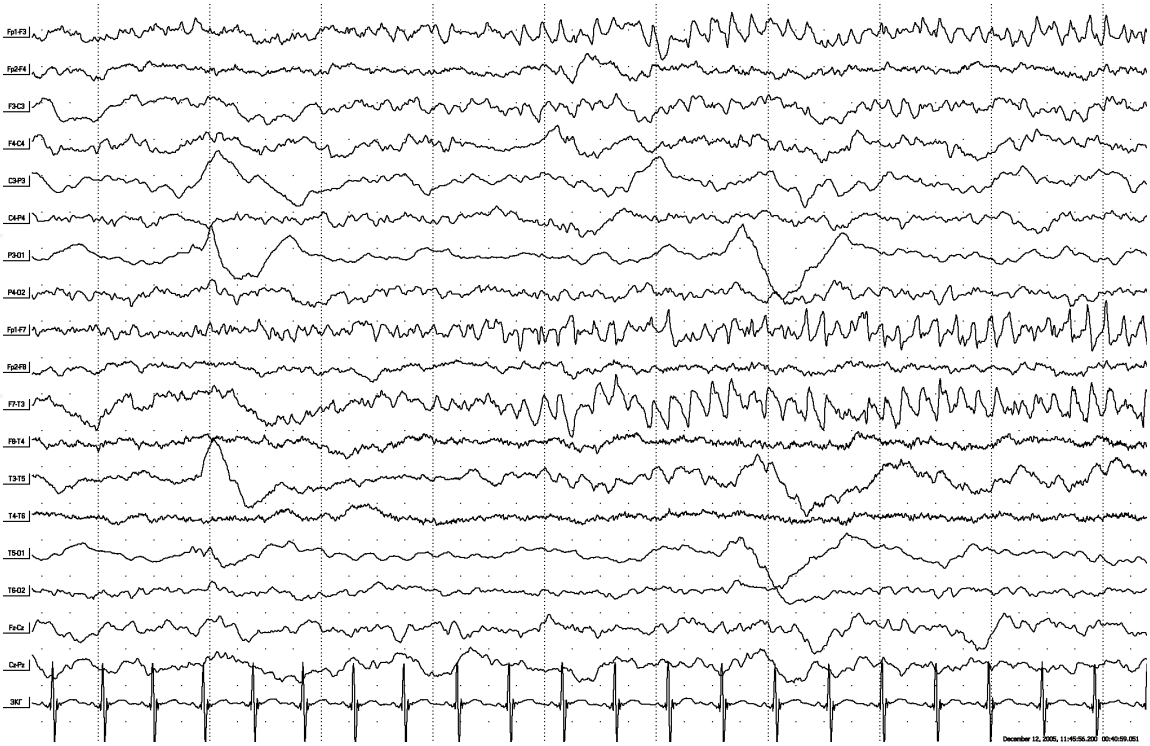


Figure 1. Patient G.E., 1 year old. Diagnosis: Malignant migrating partial seizures of infancy. EEG during status seizures. Emergence of regional ictal EEG pattern in the left frontal region in the form of fast epileptiform activity and transformation to regular activity of theta range with amplitude increase and sharp wave inclusion. In the left parietal, posterior temporal region is seen delta-accentuation after the previous seizure. Manifestation: Right-sided tonic seizure with oro-facial and versive components.

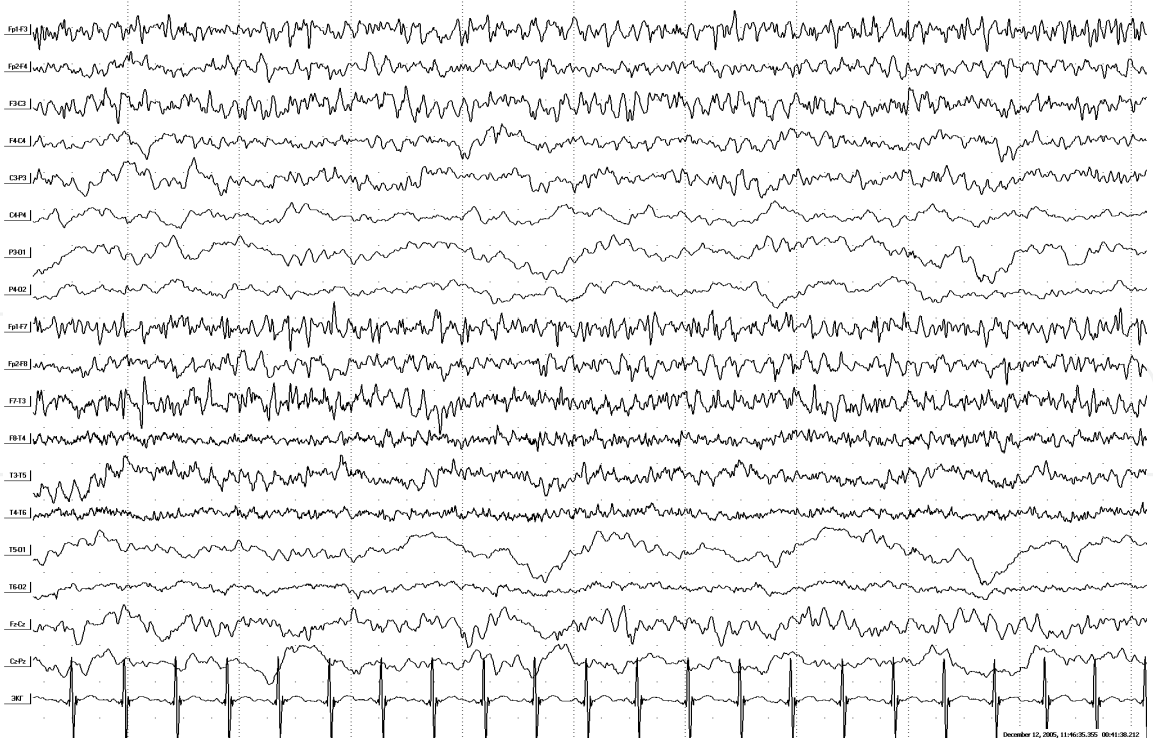


Figure 2.
The same patient. Continuation of ictal EEG. Ictal epileptiform activity involves neighboring regions and same areas of the right hemisphere, but with maintenance of left-sided lateralization. Manifestation: Bilateral tonic seizure.

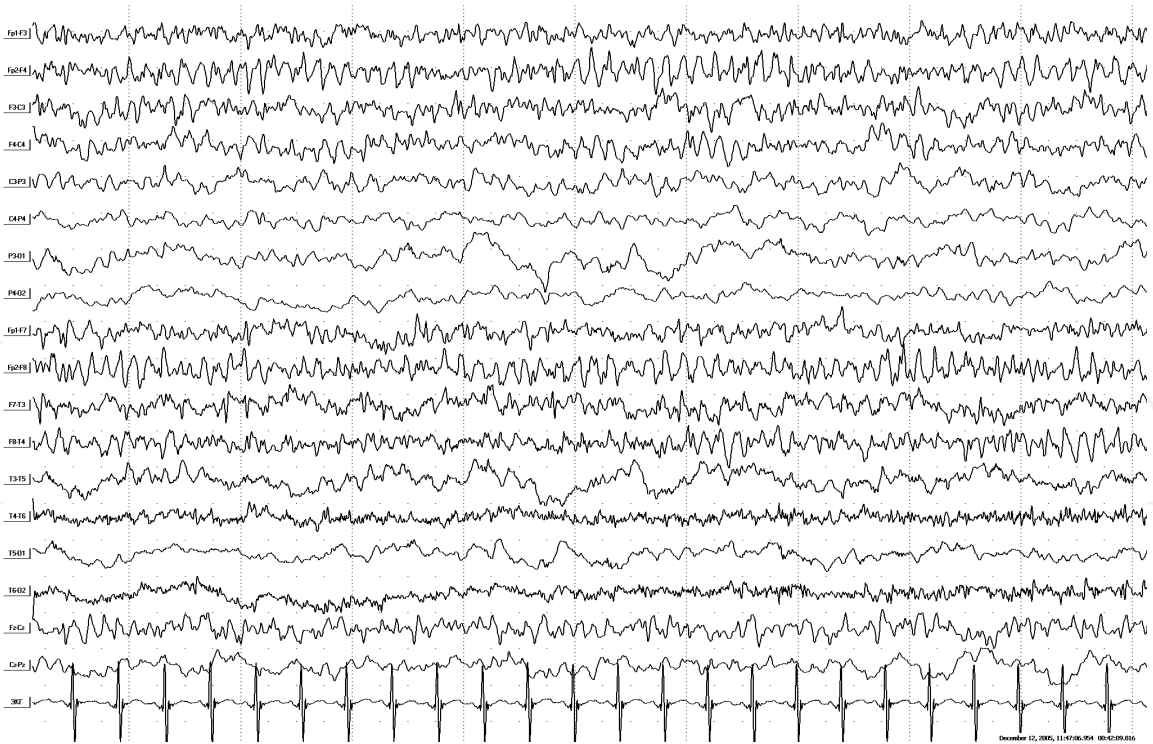


Figure 3.
The same patient. Continuation of ictal EEG. Ictal epileptiform activity in the frontal areas changes to the right-sided lateralization. Manifestation: Transformation to asymmetric tonic seizure with left-sided accentuation.

demonstrates migration of paroxysmal ictal characteristics from one region to another, without formation of stable interregional relations. Probably, only due to ictal pattern migration, patients are able to stay in SE of focal seizures for a long time without development of life-threatening cerebral edema.

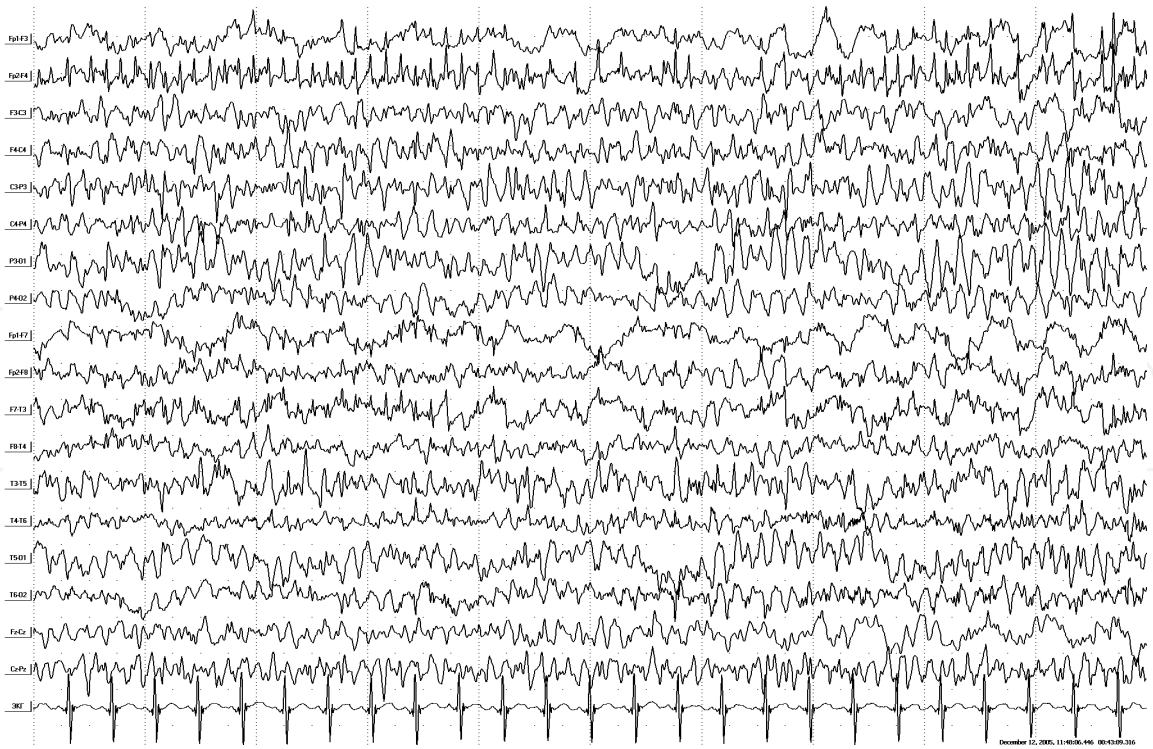


Figure 4.
The same patient. Continuation of ictal EEG. Diffuse spread of ictal epileptiform activity with multiple spikes. On this background, emergence of regional accentuation of ictal pattern in the left parietal-posterior temporal region. Manifestation: Transformation to generalized tonic seizure with clonic component.

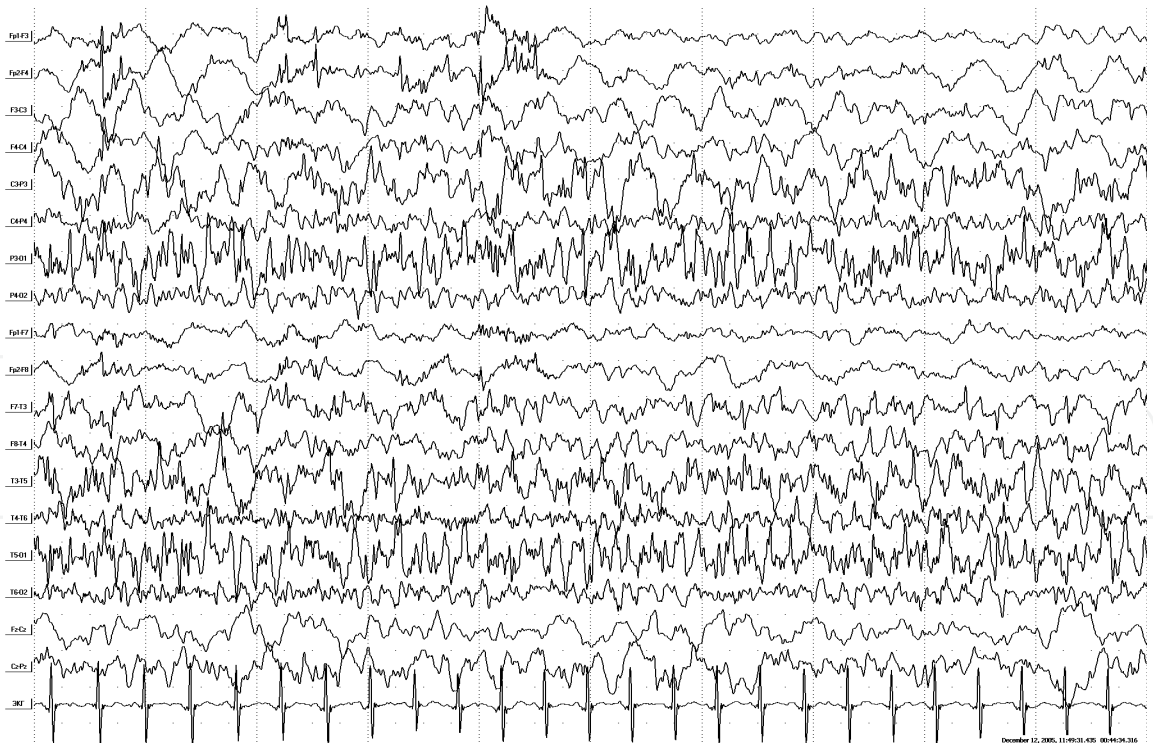


Figure 5.
The same patient. Continuation of ictal EEG. Slowing down of frequency characteristics of the diffuse ictal pattern with transformation to the delta slowing. In the opposite left parietal-posterior temporal region, activation of the regional ictal pattern with regionally accentuated polyspikes and spike-wave complexes is seen. Manifestation: Transformation to asymmetric tonic seizure with right-sided clonic component.

The following variants of ictal patterns have been identified in patients with MMPSI: regional “saw tooth” activity of alpha and theta range; “lafa” runs were obligate ictal patterns and were detected at all patients with MMPSI; frequently

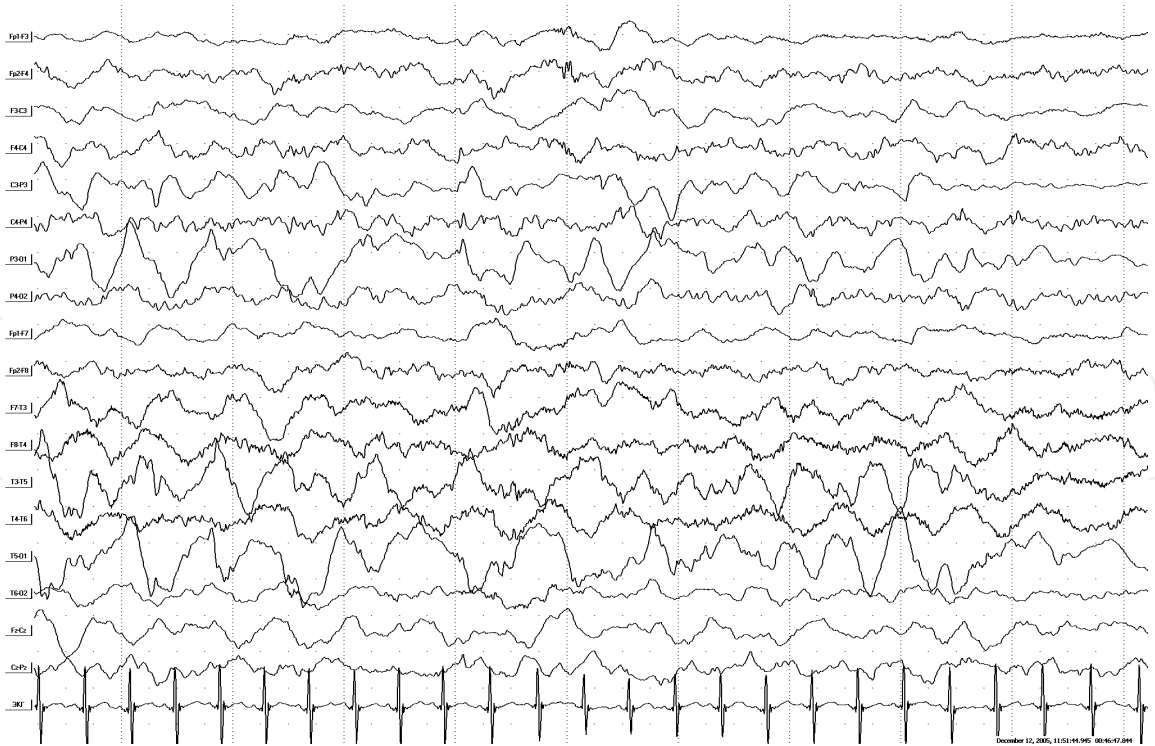


Figure 6.
The same patient. Continuation of ictal EEG. Shift of ictal pattern in the left parietal-posterior temporal region to the delta slowing with slow epileptiform complexes. At the same time in the right hemisphere, emergence of a new ictal pattern in the form of low-amplitude fast activity (lafa). Manifestation: Short-term decrease of clinical ictal severity.

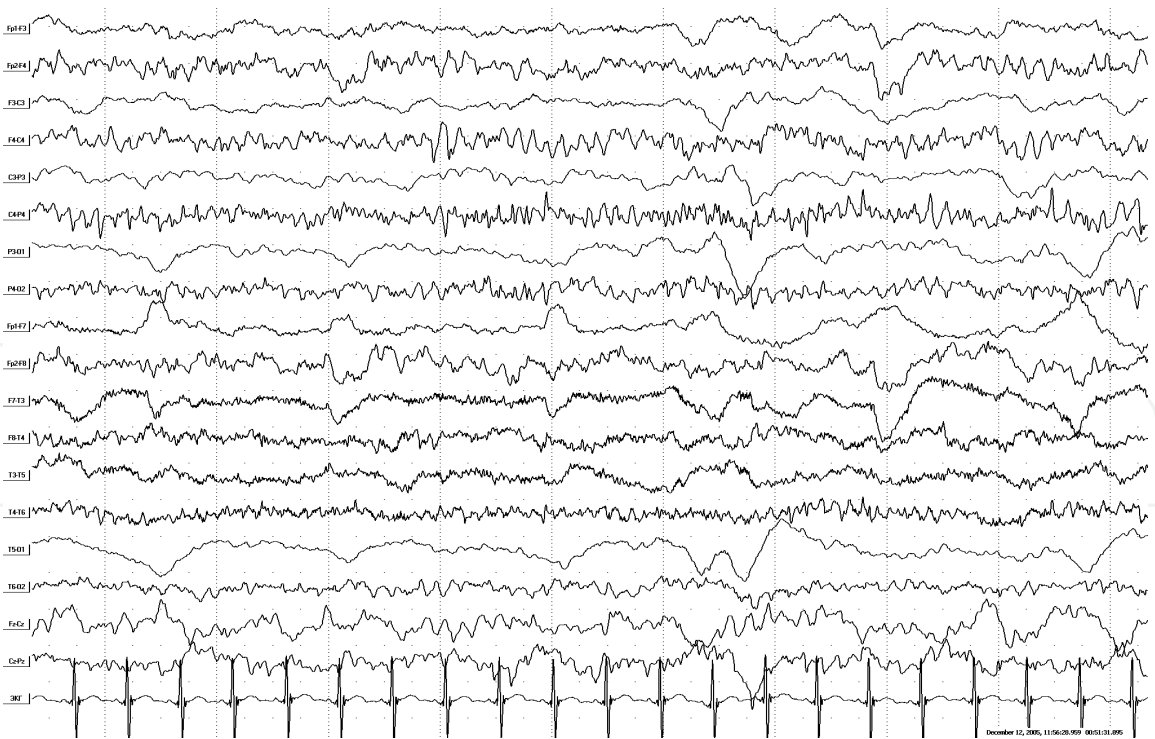


Figure 7.
The same patient. Continuation of ictal EEG. Ictal pattern in the right hemisphere in the form of regular alpha-theta activity with frontal-central accentuation. Postictal changes in the left hemisphere in the form of depression of the bioelectric activity with delta rhythm dominance. Manifestation: Asymmetrical tonic seizure with left-sided accentuation.

runs of fast regular spike-wave complexes were also identified; and runs of slow regular spike-wave complexes (rarely), and diffuse spike- and polyspike-wave discharges.

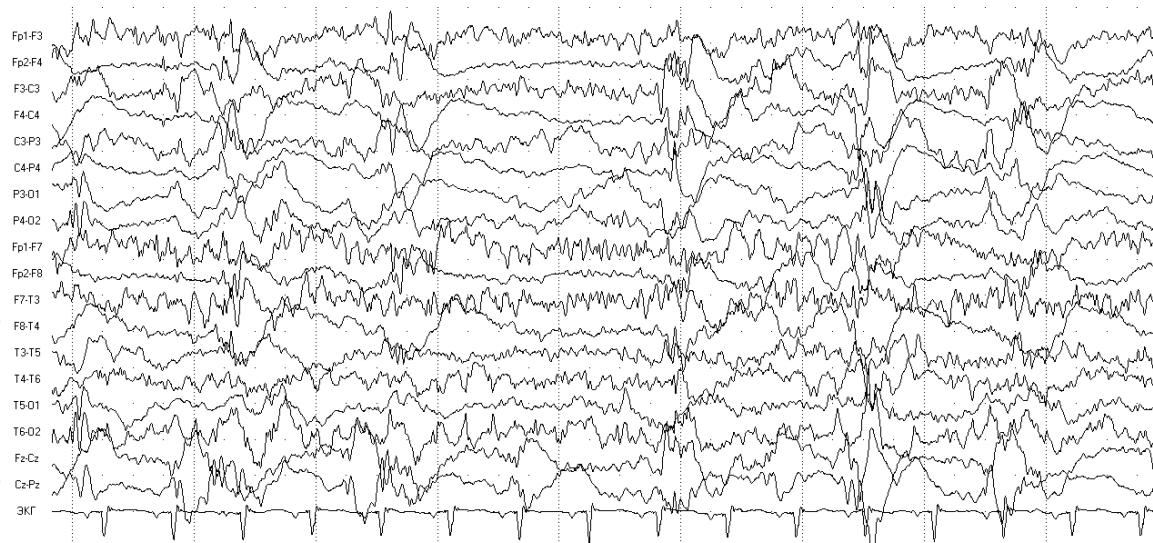


Figure 8. Patient P.S., age 1 year and 1 month old. Ictal EEG. Diagnosis: Mixed form of MMPSI + EME. EEG reveals combination of suppression-burst pattern with polyspike waves and focal ictal patterns in the left frontal and right temporal areas independently.

Along with “classical” EEG pattern of MMPSI, atypical mixed variants were observed in the manner of superposition of continuous migratory multiregional SE pattern to suppression-burst pattern with diffuse polyspike-wave discharges (**Figures 8–10**). Five of these infants (three boys and two girls) had a special mixed form of epilepsy in the form of MMPSI combination with early myoclonic encephalopathy (EME) with the presence of multiple fragmented “erratic” myoclonus along with migrating focal status seizures.

Such mixed form with transformation of EME into MMPSI was also described by specialists from the Department of Pediatrics of the Taipei City Hospital Zhongxing Branch (Taipei, Taiwan) in a female neonate [29].

4.2 Neuroimaging

According to the world literature, CT and MRI changes are absent, and the majority of MMPSI cases are regarded as cryptogenic. Atrophic changes are nonspecific and further are exacerbated by the constant epileptic seizures [1, 25].

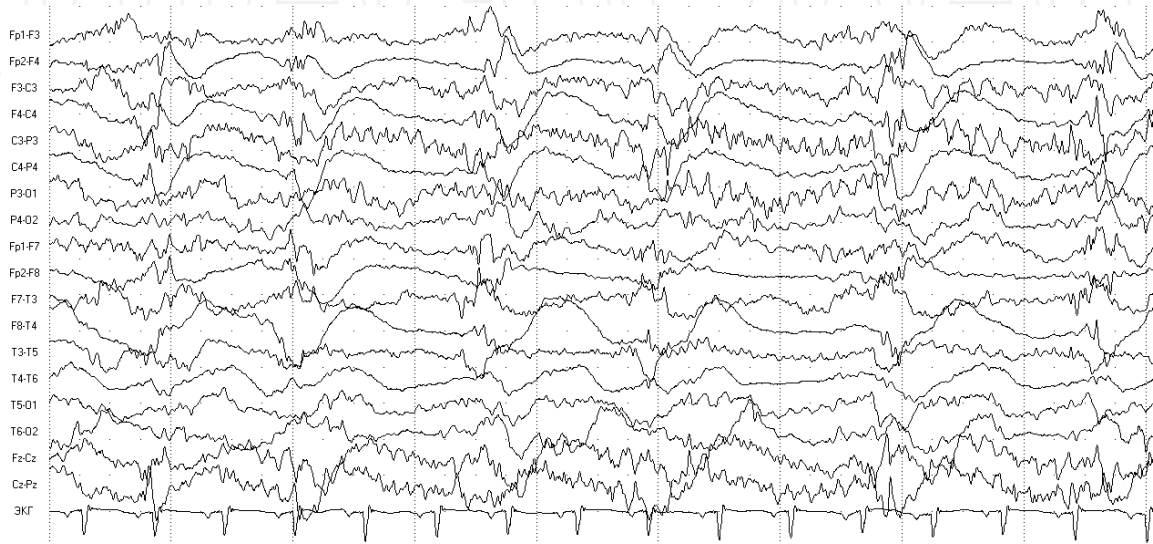


Figure 9. The same patient. Continuation of ictal EEG. EEG reveals combination of suppression-burst pattern and focal ictal patterns in the left centro-parietal area with central sagittal (vertex accent).

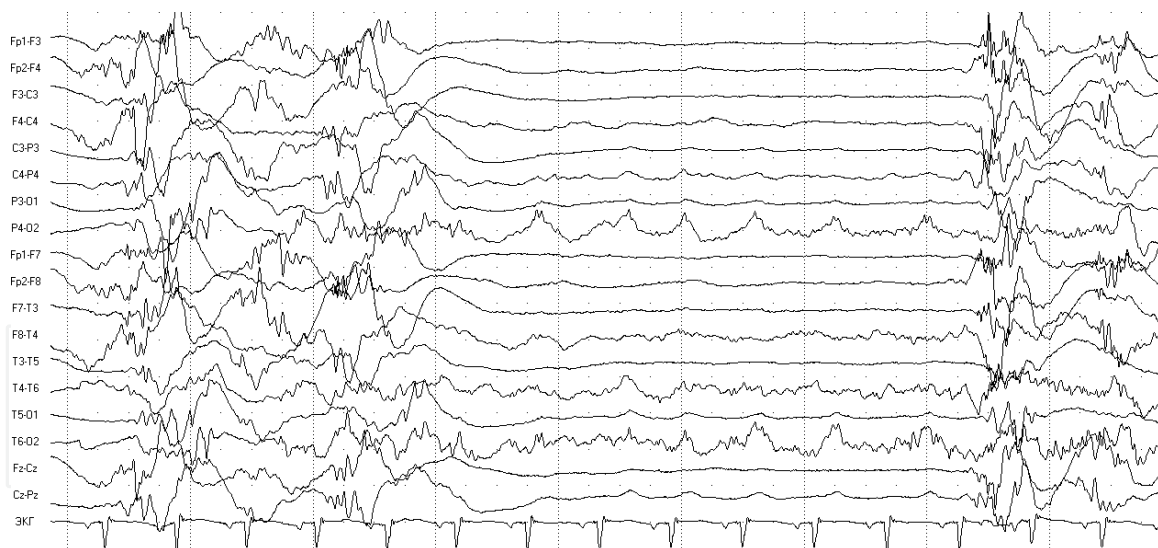


Figure 10.
The same patient. Continuation of ictal EEG. EEG reveals combination of suppression-burst pattern and focal ictal pattern in right occipital-posterior temporal area.

Coppola et al. found left temporal lobe dual pathology in a child with MMRSI, including hippocampal sclerosis and cortical-subcortical blurring [23]. Caraballo et al. reported about mesial temporal lobe sclerosis in 3 of 17 patients [27]. Gross-Tsur et al. presented patients with MMPSI decreased N-acetyl aspartate in the frontal cortex and basal ganglia revealed by MR brain spectroscopy [30].

In cases of cryptogenic MMPSI, minimal or moderate subatrophic changes initially were fixed, sometimes in combination with a moderate delay of myelination, but with progressive cerebral atrophy at 11 children with persistent pharmacoresistant seizures. Dysgenetic brain malformations were found at neuroimaging only in two children with symptomatic analogs of MMPSI in the form of lissencephaly-pachygyria in one girl and polymicrogyria in another girl. Remaining ten patients with symptomatic analogs of MMPSI had a wide range of hypoxic-ischemic CNS lesions in the form of periventricular leukomalacia, parasagittal Chugani necrosis, and diffuse cortical-subcortical atrophy (“walnut” brain).

5. Treatment

MMPSI is a drug-resistant epilepsy form with serious prognosis. Treatment approaches are still developing. Baseline, old, and new antiepileptic drugs in various combinations, as well as corticosteroids, are ineffective [1–3]. However, Dulac observed seizure aggravation during treatment with carbamazepine and vigabatrin in these patients [3]. Perez et al. observed temporary seizure remission in two cases of MMPSI with combination of stiripentol (metabolic drug, inhibitor of several cytochrome P-450 enzymes) and high doses of clonazepam [31]. Hmaimess et al. published about effectiveness of levetiracetam in MMPSI [32]. Okuda et al. [5] reported efficacy of potassium bromide in migrating partial seizures of infancy. A 3-month-old boy and a 4-month-old girl with failure of common antiepileptic drugs reached complete remission of seizures in one case and significant decrease of seizure frequency (95%) in another case due to treatment with potassium bromide 80 mg/kg/day [5]. In all cases of seizure control, gradual improvement in psychomotor development of children was observed that also proves the leading role of epileptiform activity and persistent seizures in the development of epileptic encephalopathy [3].

Chien et al. have stopped erratic myoclonus and suppressive-burst pattern on EEG in a mixed form of EME + MMPSI using dextromethorphan 20 mg/kg [29].

There are different opinions about usefulness of ketogenic diet in MMPSI. So, François et al. proclaimed that seizures in MMPSI are also resistant to ketogenic diet [33]. But specialists from Children's Neuroscience Centre of Royal Children's Hospital (Parkville, Victoria, Australia) published data about efficacy of the ketogenic diet in children with this pharmacoresistant form of epilepsy [34].

Surgical treatment of MMPSI is unreasonable because of diffuse nature of brain damage and lack of clear local structural defect [3]. Theoretically, anterior callosotomy may be offered as a palliative intervention; however, there is no such experience in this form of epilepsy.

A group of scientists from the Pediatric Neurology Department of Azienda Ospedaliera Universitaria (Ancona, Italy) have published about positive experience of vagus nerve stimulation (VNS therapy) in three infants with pharmacoresistant MMPSI [35].

Our cases confirmed that MMPSI are resistant to antiepileptic therapy. Monotherapy had no significant effect in all patients. All patients with MMPSI failed to relieve from epileptic seizures. In 14 MMPSI cases, antiepileptic therapy was completely ineffective (56%), reduction of seizures >50% was observed in seven patients (28%), and only in six patients decrease of seizures was >75% (17.16%). Relatively effective combinations of antiepileptic drugs included valproates with barbiturates (phenobarbital and hexamidine) and benzodiazepines. Clobazam 1 mg/kg was most effective among benzodiazepine groups. In two patients positive effect was observed with combination of levetiracetam, and in one case – with combination of benzodiazepine and topiramate. Phenytoin in two cases caused moderate positive effect with “escape effect.” In one patient, frequency of seizures decreased during treatment with potassium bromide (50 mg/kg) but with side effects in the form of hypersomnia. High doses of vitamin B6 in two cases were moderately positive.

Ethosuximide, rufinamide, carbamazepine, and oxcarbazepine have no substantial positive effect. In one case, carbamazepine in cryptogenic focal frontal epilepsy with temporary positive effect caused subsequent aggravation of seizures with appearance of additional foci with clinical and electroencephalographic transformation into MMPSI.

Hormone therapy caused only a temporary moderate positive effect in eight cases and was completely ineffective at other cases.

For emergent relief of SE of hemiconvulsive and secondary generalized tonic-clonic seizures in 15 cases of MMPSI, benzodiazepines (relanium and midazolam) had only a temporary effect in eight or were completely ineffective in seven cases.

Positive effect in SE in MMPSI was observed with sodium oxybate administration at a dose of 100–150 mg/kg, 400 mg/min. This was done in seven cases of hemiconvulsive (n = 3) and secondary generalized tonic-clonic SE (n = 4) resistant to benzodiazepines with a temporary regression (six cases) or a decrease of clinical-EEG paroxysmal events (one case).

In three patients with MMPSI, intravenous valproates caused significant positive effect in relieving SE, especially in cases of tonic-autonomic seizures with episodes of apnea, with aggravation during treatment with benzodiazepines [36]. The recommended dose was 25 mg/kg intravenous over 5 min with the following maintenance infusion – 2 mg/kg/h.

Sodium thiopental (4 mg/kg for 2 min and then infusion of 0.2 mg/kg per minute) is the last chance to stop drug-resistant SE but caused death in one girl due to central inhibition of cardiac activity.

6. Prognosis

MMPSI is a form of epilepsy with poor prognosis. Within a few months after disease onset, frequency and duration of seizures increase up to the serial seizures and status epilepticus. A number of patients die in the first year of life due to multiple prolonged epileptic seizures, development of respiratory distress syndrome, and decorticate rigidity [30]. Based on the generalized clinical observations, mortality in this syndrome is 28% [3]. The results obtained by Marsh et al. are prognostically more favorable: during the 7-year follow-up, all six patients survived; however, psychomotor retardation with severe muscular hypotonia persisted in three of them, and only one patient reached seizure control for a long time [25].

Mortality at personal observed cases was 25.7% (n = 9); however, the expected mortality is higher due to short follow-up (1 year) in more than half of these patients. The oldest of the survived patients with MMPSI is 9 years old; there is gross delay of psychomotor development with unformed verticalization skills, absence of voice activity, spastic tetraparesis, and multiple focal asymmetric tonic, versive, pharyngo-oral, and dialeptic seizures.

Follow-up of patients with MMPSI allowed distinguishing the following sub-populations:

- “Classical” form in the form of marked SE of migrating multifocal seizures is pharmacoresistant with a poor prognosis for psychomotor development, seizures, and life (19 cases, 54.3%).
- Mixed form (MMPSI + EME) with a combination of electro-clinical MMPSI characteristics but also with the presence of fragmented “erratic” myoclonus and suppression-burst pattern with polyspike-wave discharges on EEG (five cases, 14.3%) with also poor prognosis for mental and motor functions, seizures, and life.
- “Moderate” or “mild” form with a consistent evolution from unifocal form to multifocal form with EEG pattern MISF, and then developed expressed MMPSI electro-clinical characteristics, but with a possible regression and decrease in frequency of seizures during combined antiepileptic therapy (six cases, 17.1%).
- “Subtle” form, in the form of only “subtle” minimal motor seizures, inhibitory seizures, multiple ictal patterns during sleep, and leading to awakening (five cases, 14.3%). This form causes a rough developmental delay in infants, but without video-EEG monitoring, it remains unrecognized [20].

7. Conclusions

MMPSI is an independent epileptic syndrome with special clinical-neurophysiological characteristics, distinct from other forms of epilepsy. Diagnosis can be established if there are different types of focal seizures, involving multiple extended EEG and electro-clinical ictal EEG patterns with involvement of several independent areas in both hemispheres. All the patients need complex investigations including dynamic video-EEG monitoring, neuroimaging, and genetic tests (whole-exome sequencing is more preferable).

MMPSI should also be differentiated from the syndrome described by Ohtahara – “severe epilepsy with multiple independent spike foci” (SE-MISF). In

the literature, this form is also known as Markand-Blume-Ohtahara syndrome [37]. Unlike MMPSI, this form manifests with predominantly pseudogeneralized seizures: bilateral axial tonic spasms, atypical absences, and myoclonic but focal seizures could also be observed. But SE-MISF and MMPSI could have evolutionary changes into each other.

Therefore, malignant migrating partial seizures of infancy is the third type of infantile epileptic encephalopathy, along with early encephalopathies with suppression-burst pattern (Aicardi and Ohtahara syndromes) and West syndrome, when the cerebral cortex is more prone to generate epileptic excitation migrating from one area of the cortex to another, without clear interregional organization. This condition is caused by age-dependent features of infant brain with cortex hyperexcitability at a certain stage of evolution [3, 38].

The definition of this syndrome has not been defined in the international classification of epilepsies and epileptic syndromes. The term “malignant migrating partial seizures of infancy” characterizes this form of epilepsy rather as syndrome, so it is proposed to discuss the following title “malignant epilepsy of infancy with migrating multifocal seizures” that may more fully capture the essence of the disease. Taking into account contributions of scientists that first described this form of epilepsy (Coppola) and gave the most detailed description of the clinical and neurophysiological criteria (Dulac), the following definition is proposed: Coppola-Dulac syndrome [39].

Acknowledgements

I would like to express my special thanks to a veteran of World War II, the world's famous coryphaeus of neurology and epileptology, Academician and Professor Vladimir Alexeevich Karlov; to an expert in epilepsy, President of the scientific council of the French Epilepsy Research Foundation, leading specialist of Children's Hospital Necker, Professor Olivier Dulac; to my German teacher and mentor, Professor Hans Holthausen; to my scientific supervisors and epilepsy experts, Professor Konstantin Yurievich Mukhin and Professor Andrey Sergeevich Petrukhin; to the Head of the Department of Neurology, Neurosurgery and Medical Genetics of Pirogov Russian National Research Medical University, Professor Nikolay Nikolaevich Zavadenko; to the Head of the Department of Psychoneurology N2 of the Russian Children Clinical Hospital, Dr. Elena Stepanovna Il'ina; and to all my colleagues. Also, I would like to extend my special thanks to my big family and especially my wife Elena!

Conflict of interest

No conflict of interest.

IntechOpen

IntechOpen

Author details

Alexey Kholin

Department of Neurology, Neurosurgery and Medical Genetics of Pediatric Faculty,
Pirogov Russian National Research Medical University, Moscow, Russia

*Address all correspondence to: drkholin@mail.ru

IntechOpen

© 2018 The Author(s). Licensee IntechOpen. This chapter is distributed under the terms of the Creative Commons Attribution License (<http://creativecommons.org/licenses/by/3.0>), which permits unrestricted use, distribution, and reproduction in any medium, provided the original work is properly cited. 

References

- [1] Coppola G, Plouin P, Chiron C, Robain O, Dulac O. Migrating partial seizures in infancy: A malignant disorder with developmental arrest. *Epilepsia*. 1995;**36**(10):1017-1024
- [2] Coppola G. Malignant migrating partial seizures in infancy: An epilepsy syndrome of unknown etiology. *Epilepsia*. 2009;**50**(Supp. 5):49-51. DOI: 10.1111/j.1528-1167.2009.02121.x
- [3] Dulac O. Malignant migrating partial seizures in infancy. In: Roger J, Bureau M, Dravet C, Genton P, Tassinari CA, Wolf P, editors. *Epileptic Syndromes in Infancy, Childhood and Adolescence*. 4th ed. John Libbey; 2005. pp. 73-76. ISBN: 2-7420-0575-7
- [4] Gerard F, Kaminska A, Plouin P, Echenne B, Dulac O. Focal seizures versus focal epilepsy in infancy: A challenging distinction. *Epileptic Disorders*. 1999;**1**(2):135-139
- [5] Okuda K, Yasuhara A, Kamei A, Araki A, Kitamura N, Kobayashi Y. Successful control with bromide of two patients with malignant migrating partial seizures in infancy. *Brain & Development*. 2000;**22**(1):56-59
- [6] Veneselli E, Perrone MV, Di Rocco M, Gaggero R, Biancheri R. Malignant migrating partial seizures in infancy. *Epilepsy Research*. 2001;**46**(1):27-32
- [7] Panayiotopoulos CP. *A Clinical Guide to Epileptic Syndromes and their Treatment*. Bladon Medical Publishing. Oxford, 2002. pp. 36-49. ISBN: 1904218237
- [8] Coppola G, Veggiotti P, Del Giudice EM, Bellini G, Longaretti F, Taglialetela M, et al. Mutational scanning of potassium, sodium and chloride ion channels in malignant migrating partial seizures in infancy. *Brain & Development*. 2006;**28**(2):76-79. DOI: 10.1016/j.braindev.2005.05.002
- [9] Poduri A, Heinzen EL, Chitsazzadeh V, Lasorsa FM, Elhosary PC, LaCoursiere CM, et al. SLC25A22 is a novel gene for migrating partial seizures in infancy. *Annals of Neurology*. 2013;**74**(6):873-882. DOI: 10.1002/ana.23998
- [10] Freilich ER, Jones JM, Gaillard WD, Conry JA, Tsuchida TN, Reyes C, et al. Novel SCN1A mutation in a proband with malignant migrating partial seizures of infancy. *Archives of Neurology*. 2011;**68**(5):665-671. DOI: 10.1001/archneurol.2011.98
- [11] Carranza Rojo D, Hamiwka L, McMahon JM, Dibbens LM, Arsov T, Suls A, et al. De novo SCN1A mutations in migrating partial seizures of infancy. *Neurology*. 2011;**77**(4):380-383. DOI: 10.1212/WNL.0b013e318227046d
- [12] Ohba C, Kato M, Takahashi S, Lerman-Sagie T, Lev D, Terashima H, et al. Early onset epileptic encephalopathy caused by de novo SCN8A mutations. *Epilepsia*. 2014;**55**(7):994-1000. DOI: 10.1111/epi.12668
- [13] Barcia G, Fleming MR, Deligniere A, Gazula V-R, Brown MR, Langouet M, et al. De novo gain-of-function KCNT1 channel mutations cause malignant migrating partial seizures of infancy. *Nature Genetics*. 2012;**44**:1255-1259. DOI: 10.1038/ng.2441
- [14] Vanderver A, Simons C, Schmidt JL, Pearl PL, Bloom M, Lavenstein B, et al. Identification of a novel de novo p. Phe932Ile KCNT1 mutation in a patient with leukoencephalopathy and severe epilepsy. *Pediatric Neurology*. 2014;**50**(1):112-114. DOI: 10.1016/j.pediatrneurol.2013.06.024
- [15] Ishii A, Shioda M, Okumura A, Kidokoro H, Sakauchi M, Shimada S,

- et al. A recurrent KCNT1 mutation in two sporadic cases with malignant migrating partial seizures in infancy. *Gene*. 2013;**531**:467-471. DOI: 10.1016/j.gene.2013.08.096
- [16] Kawasaki Y, Kuki I, Ehara E, Murakami Y, Okazaki S, Kawawaki H, et al. Three cases of KCNT1 mutations: Malignant migrating partial seizures in infancy with massive systemic to pulmonary collateral arteries. *The Journal of Pediatrics*. 2017;**191**:270-274. DOI: 10.1016/j.jpeds.2017.08.057
- [17] Madaan P, Jauhari P, Gupta A, Chakrabarty B, Gulati S. A quinidine non responsive novel KCNT1 mutation in an Indian infant with epilepsy of infancy with migrating focal seizures. *Brain & Development*. 2018;**40**(3): 229-232. DOI: 10.1016/j.braindev.2017.09.008
- [18] Milh M, Falace A, Villeneuve N, Vanni N, Cacciagli P, Assereto S, et al. Novel compound heterozygous mutations in TBC1D24 cause familial malignant migrating partial seizures of infancy. *Human Mutation*. 2013;**34**: 869-872. DOI: 10.1002/humu.22318
- [19] Zhang X, Ling J, Barcia G, Jing L, Wu J, Barry BJ, et al. Mutations in QARS, encoding glutaminyl-tRNA synthetase, cause progressive microcephaly, cerebral-cerebellar atrophy, and intractable seizures. *American Journal of Human Genetics*. 2014;**94**(4):547-558. DOI: 10.1016/j.ajhg.2014.03.003
- [20] Kholin AA. The syndrome of malignant migrating partial seizures in infancy or Coppola-Dulac syndrome (19 cases). *Zhurnal Nevrologii i Psikhatrii Imeni S.S. Korsakova*. 2013;**113**(3):21-27
- [21] Bedoyan JK, Kumar RA, Sudi J, Silverstein F, Ackley T, Iyer RK, et al. Duplication 16p11.2 in a child with infantile seizure disorder. *American Journal of Medical Genetics Part A*. 2010;**152A**(6):1567-1574. DOI: 10.1002/ajmg.a.33415
- [22] Poduri A, Chopra SS, Neilan EG, Elhosary PC, Kurian MA, Meyer E, et al. Homozygous PLCB1 deletion associated with malignant migrating partial seizures in infancy. *Epilepsia*. 2012;**53**(8):e146-e150. DOI: 10.1111/j.1528-1167.2012.03538.x
- [23] Coppola G, Operto FF, Auricchio G, D'Amico A, Fortunato D, Pascotto A. Temporal lobe dual pathology in malignant migrating partial seizures in infancy. *Epileptic Disorders*. 2007;**9**(2): 145-148. DOI: 10.1684/epd.2007.0106
- [24] Kholin AA. Status epilepticus in infancy and early childhood. D.M.thesis. Moscow. 2010. 54 p
- [25] Marsh E, Melamed SE, Barron T, Clancy RR. Migrating partial seizures in infancy: Expanding the phenotype of a rare seizure syndrome. *Epilepsia*. 2005;**46**(4):568, 72. DOI: 10.1111/j.0013-9580.2005.34104.x
- [26] Dulac O, Chiron C. Malignant epileptic encephalopathies in children. *Baillière's Clinical Neurology*. 1996;**5**(4): 765-781
- [27] Caraballo RH, Fontana E, Darra F, Cassar L, Negrini F, Fiorini E, et al. Migrating focal seizures in infancy: Analysis of the electroclinical patterns in 17 patients. *Journal of Child Neurology*. 2008;**23**(5):497-506. DOI: 10.1177/0883073807309771
- [28] Kholin AA, Ilina ES, Kolpakchi LM, Fedonuk ID, Mikhailova SV, Semykina LI, et al. Malignant migrating partial seizures in infancy. Clinical observation of 6 cases. *Rus. zh. detsk. nevrol*. 2007;**2**(2):25-38
- [29] Chien YH, Lin MI, Weng WC, Du JC, Lee WT. Dextromethorphan in the treatment of early myoclonic encephalopathy evolving into migrating

- partial seizures in infancy. *Journal of the Formosan Medical Association*. 2012; **111**(5):290-294. DOI: 10.1016/j.jfma.2012.03.007
- [30] Gross-Tsur V, Ben-Zeev B, Shalev RS. Malignant migrating partial seizures in infancy. *Pediatric Neurology*. 2004; **31**(4):287-290. DOI: 10.1016/j.pediatrneurol.2004.05.001
- [31] Perez J, Chiron C, Musial C, Rey E, Blehaut H, d'Athis P, et al. Stiripentol: Efficacy and tolerability in epileptic children. *Epilepsia*. 1999; **40**(11):1618-1612
- [32] Hmaimess G, Kadhim H, Nassogne MC, Bonnier C, van Rijckevorsel K. Levetiracetam in a neonate with malignant migrating partial seizures. *Pediatric Neurology*. 2006; **34**(1):55-59. DOI: 10.1016/j.pediatrneurol.2005.06.011
- [33] François LL, Manel V, Rousselle C, David M. Ketogenic regime as anti-epileptic treatment: Its use in 29 epileptic children. *Archives de Pédiatrie*. 2003; **10**(4):300-306
- [34] Thammongkol S, Vears DF, Bicknell-Royle J, Nation J, Draffin K, Stewart KG, et al. Efficacy of the ketogenic diet: Which epilepsies respond? *Epilepsia*. 2012; **53**(3):e55-e59. DOI: 10.1111/j.1528-1167.2011.03394.x
- [35] Zamponi N, Rychlicki F, Corpaci L, Cesaroni E, Trignani R. Vagus nerve stimulation (VNS) is effective in treating catastrophic 1 epilepsy in very young children. *Neurosurgical Review*. 2008; **31**(3):291, 7. DOI: 10.1007/s10143-008-0134-8
- [36] Kholin AA, Ilina ES, Lemeshko ID, Mukhin KY, Petrukhin AS. Malignant migrating partial seizures of infancy: The experience of treatment of status epilepticus in infancy using intravenous valproate – Convulex (a clinical cases). *Zhurnal Nevrologii i Psikhatrii Imeni S. S. Korsakova*. 2010; **110**(3 Supp. 2):17-24
- [37] Yamatogi Y, Ohtahara S. Severe epilepsy with multiple independent spike foci. *Journal of Clinical Neurophysiology*. 2003; **20**(6):442-448
- [38] Ohtahara S, Yamatogi Y. Epileptic encephalopathies in early infancy with suppression – Burst. *Journal of Clinical Neurophysiology*. 2003; **20**(6):398-407
- [39] Kholin AA. Malignant migrating partial seizures in infancy or Coppola-Dulac syndrome. *Materials of 29th International Epilepsy Congress, Rome*. 2011. p. 716