

# We are IntechOpen, the world's leading publisher of Open Access books Built by scientists, for scientists

6,900

Open access books available

186,000

International authors and editors

200M

Downloads

Our authors are among the

154

Countries delivered to

TOP 1%

most cited scientists

12.2%

Contributors from top 500 universities



WEB OF SCIENCE™

Selection of our books indexed in the Book Citation Index  
in Web of Science™ Core Collection (BKCI)

Interested in publishing with us?  
Contact [book.department@intechopen.com](mailto:book.department@intechopen.com)

Numbers displayed above are based on latest data collected.  
For more information visit [www.intechopen.com](http://www.intechopen.com)



# Management of Flexor Tendon Injuries in Hand

*Tawheed Ahmad, Summaira Jan and Saima Rashid*

## Abstract

Peculiar anatomy of human hand with flexing fingers and opposing thumb give human beings clear edge over other existing living beings. We use hands for carrying out most of our daily activities. But at the same time this makes our hands vulnerable for getting traumatized. Hand injuries which involve underlying tendons make digits dysfunctional, which in turn affects overall precise functioning of hand. In this chapter we will briefly discuss related surgical anatomy of flexor tendons and associated structures, features of flexor tendon injuries at different zonal levels, surgical methods involved and different post-operative protocols used for management of these flexor tendon injuries.

**Keywords:** flexor tendon injuries, flexor digitorum superficialis, hand injuries, flexor digitorum profundus, tenorrhaphy

## 1. Introduction

Philosophically, physiologically and anatomically, the interaction of the brain and the hand give unique identification to *Homo sapiens*. The progress of mankind has been credited for large extent to evolution of mobile and strong upper limb having independently opposing thumb with cognitive power of using it. The precision, balance and its specialization give human hand a central functional as well as communicative role. The aim of surgical treatment for the injured, diseased or dysfunctional hand is to retain its maximal useful length, stable motion and unimpaired mobility of sensate parts.

All functions of hand are executed with the help of digits, and tendons in turn execute the movement of digits.

Flexion of fingers is done by two tendons viz. flexor digitorum superficialis (FDS) and flexor digitorum profundus (FDP). Flexor digitorum superficial splits into radial and ulnar slips prior to insertion on middle phalanx. Flexor digitorum profundus passes between the two slips of flexor digitorum superficialis, through a space called “Camper’s chiasm”. Flexor digitorum profundus is inserted on volar aspect, near the base, of distal phalanx of the respective finger.

The Flexor digitorum superficialis and profundus tendons glide together in a fibro-osseous tunnel. This fibro-osseous tunnel is composed of five annular pulleys ( $A_1$ – $A_5$ ) and three cruciate pulleys ( $C_1$ – $C_3$ ). These pulleys prevent bowstringing and the increase mechanical effectiveness of pull across the joints.

Annular pulleys  $A_2$  and  $A_4$  pulleys are the most critical to finger function and are located in proximal part of proximal phalanx and middle part of middle phalanx, respectively.

Annular pulleys  $A_1$ ,  $A_3$  and  $A_5$  pulleys are located at the metacarpo-phalangeal, proximal interphalangeal and distal interphalangeal joints, respectively. Three cruciate pulleys  $C_1$ ,  $C_2$  and  $C_3$  are located between  $A_2$ – $A_3$ ,  $A_3$ – $A_4$  and  $A_4$ – $A_5$  pulleys, respectively.

Thumb has three pulleys  $A_1$ , oblique and  $A_2$  pulley located over metacarpo-phalangeal joint, proximal phalanx and inter-phalangeal joint respectively. The oblique pulley is the most mechanically important pulley among them.

Flexor tendons of hand are divided into five zones:

Zone I: Extends from finger tip to insertion of flexor digitorum superficialis.

Zone II: This extends from insertion of flexor digitorum superficialis up to distal palmar crease.

Zone III: Extends from distal palmar crease up to flexor retinaculum.

Zone IV: This zone lies under flexor retinaculum.

Zone V: Extends from proximal border of flexor retinaculum to musculo-tendinous junction of flexor muscles.

Flexor tendon within fibro-osseous canal (zone II) receives nutrition from two distinct sources i.e. vascular and synovial. Four digital arches are formed by the anastomosis of branches from the two digital arteries. These arches are located at the base and the neck of proximal and middle phalanx. A vinculum arises from each of these arches ( $V_1$ – $V_4$ ). Vinculae  $V_1$  and  $V_2$  supply the flexor digitorum superficialis, whereas  $V_3$  and  $V_4$  supply flexor digitorum profundus tendon.

The surface of the tendon that is not compressed during flexion is supplied by perfusion with arterial blood, the surface that is compressed i.e. the palmar surface, is supplied by diffusion of synovial fluid. Diffusion is a more significant nutritive pathway than perfusion. The exact proportions of the two have been estimated to be 2:1 in flexor digitorum superficialis, and 5:1 in the flexor digitorum profundus.

Microscopically, tendons are composed of collagen bundles (mainly type I) oriented in regular, spiraling pattern with very few tendon cells (tenocytes), synovial cells and fibroblasts. 'Endotenon' encloses tendon bundles. If the tendon is within a synovial sheath, the outer layer of tendon is called the 'Epitenon' and if the tendon is outside the sheath (extra-synovial), outer loose areolar adventitial layer is called the 'Paratenon', through which blood vessels run longitudinally.

Tendons heal by intrinsic and extrinsic mechanism. Extrinsic mechanism of healing is by fibroblast cells in surrounding tissues and is responsible for adhesion formation, while as intrinsic mechanism of healing is because of tenocytes present within the tendon. Tendon gliding exercises after tendon repair promotes intrinsic mechanism of healing and inhibits the extrinsic mechanism of healing, thus preventing post tendon repair adhesion formation.

Flexor tendon injuries are common but a difficult problem for the patient, hand surgeon and the therapist. The incidence of flexor tendon injuries in industrialized countries is estimated to be 1 in 7000. The impact to patients may include loss of function, stiffness, vocational impairment and associated social and economical hardships.

### **1.1 Pulley system**

The synovial sheath is reinforced by a fibrous pulley system delimiting the digital canal. This system is composed of five annular pulleys and three cruciform pulleys [1–3]. The first, third and fifth annular pulleys arise respectively from the volar plate of the metacarpophalangeal (MCP) joint, proximal interphalangeal (PIP) joint and distal interphalangeal (DIP) joint. The remaining two annular pulleys second and the fourth one arise respectively from the proximal and middle phalanx; these two pulleys are thicker and broader than the rest. Between the

second and third annular pulleys is located the first cruciform pulley; between the third and fourth annular pulleys is present the second cruciform pulley; and the third cruciform pulley is located just proximal to the DIP joint. The cruciform pulleys play a role in the production of synovial fluid. The palmar aponeurosis pulley located at distal part of the transverse fibers of the palmar aponeurosis, just close to the beginning of the membranous synovial sheath, should be considered part of the finger pulley system; on each side of the synovial sheath the vertical fibers anchor it to the deep transverse metacarpal ligament. The digital fibrous pulley system keeps the flexor tendons close to the bone thus allowing complete flexion of the finger. The importance of palmar aponeurosis pulley increases significantly in case of absence of any annular pulley. The palmar aponeurosis having breaking strength of 16.5 kg is superior to the A2 pulley with breaking strength of 14 kg [4]. If A2 and A4 pulleys are absent there is significant loss of finger flexion.

## **1.2 Healing process of tendons**

The two processes are involved in the healing process of tendons: the extrinsic healing mechanism involving the surrounding tissues, and the intrinsic healing mechanism, that involves the tendon itself and its synovial sheath. Vascular and cellular ingrowths from the surrounding tissues enhance the extrinsic healing. The callus formed allows the cicatrization of the tendon but at the same time restricts its mobility, especially in zone II. To prevent formation of these adhesions, agents like steroids, anti-inflammatory drugs, hyaluronic acid and anti-histaminics have been proposed [5, 6]. However, for decreasing the risk of adhesion formation microsurgical techniques and new suture materials along with an atraumatic approach has been very effective. But many factors, such as associated lesions (skin loss, vascular, nerve injury or fracture) and the nature of the trauma (avulsion, crush injuries, blunt injury) play a significant role in increasing chance of adhesion formation. Gelberman and colleagues [7] reported the benefits of gliding function and protected passive mobilization on the tensile strength as compared to complete immobilization of repaired tendons.

Studies have shown that the tendon cells (tenocytes) themselves have a potential of healing. Lundborg et al. [8] showed that a flexor tendon that is isolated and kept in a synovial fluid environment, without any vascular supply, is able to survive and heal without any formation of adhesions. Therefore, its emphasized that during process of tendon repair, as much as possible synovial sheath should be preserved [9–11].

## **2. Surgical techniques for primary flexor tendon repair**

### **2.1 General considerations**

Usually flexor tendon repair is performed in an emergency setup. In cases such as dirty trauma or crush injuries, debridement should be done to convert contaminated wound into a cleaner wound. All the injuries (fracture, skin loss, neurovascular bundles) are repaired simultaneously along with flexor tendon repair. However, if the surgeon does not possess enough expertise to treat such lesions, it's advisable to delay the repair till next appropriate time [12]. All injured flexor tendons should be repaired using proper instruments and under magnification in an operating room thus allowing atraumatic repair of such tendons. Cleaning of wound before tenorrhaphy and in certain circumstances administration of intravenous antibiotics just before, during and 6 hours after surgery is indicated. The tendon repair



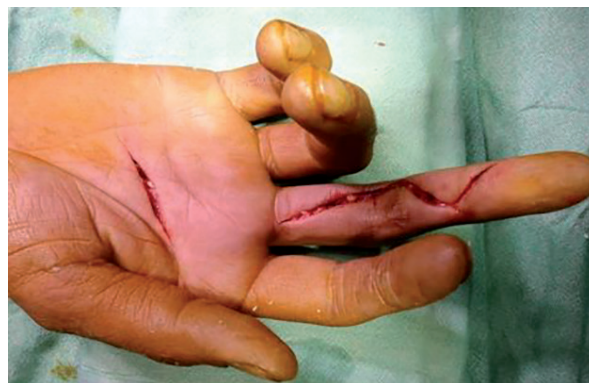is performed under axillary block anesthesia along with a pneumatic tourniquet applied at the level of the arm. The tourniquet is released just before the wound closure in order to perform hemostasis and hence preventing formation of hematoma, infection, potential adhesion and fibrosis.

## 2.2 Incisions for exposure

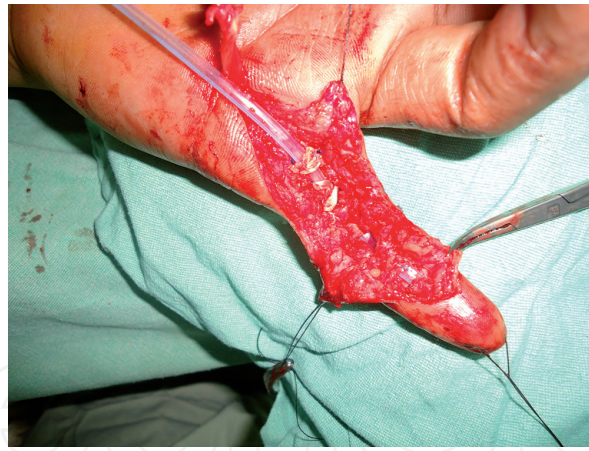
In order to provide better visibility and to allow atraumatic repair of injured tendons, the skin wound should be debrided and enlarged. The position of the finger and the shape of the initial lesion govern the method of extension of wound for exposure; a palmar zigzag approach (Bruner's incision) can be used to extend an oblique skin laceration; a midlateral approach can be used to extend transverse skin laceration. A palmar zigzag incision provides an excellent exposure but at the same time can lead to adhesions as well as scar tissue formation over the repaired tendon. The midlateral approach allows a direct repair of the injured flexor tendon and also preserves vascular transverse branches of neurovascular bundle. Mid-palmar incisions and straight incisions that cross flexor creases should be avoided, as sharp angle in the raised skin flaps can result in tip necrosis. The wound needs to be extended in distal direction if tendon injury has occurred while fingers were in flexion and similarly wound needs to be extended proximally if at time of injury fingers were in extension.

Mid palmar transverse incision becomes sometimes necessary when proximal end of tendon has retracted to palmar level and if flexor tendon massage or flexion of wrist fails to deliver retracted proximal tendon end (**Figure 1**). The silicone tube is passed in retrograde direction into the palm, from superficialis chiasma up to proximal stump. The proximal end of injured tendon is attached to the silicone tube and pulled distally, delivering it back into wound. This procedure helps in avoiding traumatic injury to digital sheath and hence preventing adhesion formation (**Figure 2**) [13].

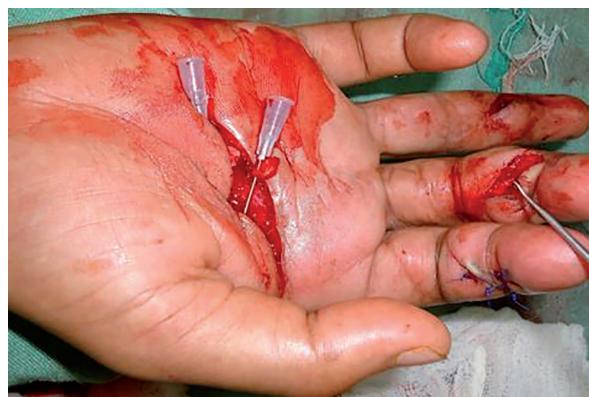With an L-shaped incision (Lister's technique) the digital flexor tendon sheath is opened in between the annular pulleys [9]. to prevent bowstringing Annular pulleys (especially A2 and A4) should be spared and repaired if they are traumatized. The sheath should be closed using a fine suture material after completion of repair of severed flexor tendon. In case of severe damage to the sheath, it may be necessary to excise the portion of the sheath over the repaired tendon site to prevent trigger finger or an impingement. In cases where tendon injury is not a result of sharp cut, the tendon ends need to be refreshed using a sharp blade, this debridement should be minimal to avoid any tension over the tenorrhaphy site. A needle can be used to fix proximal end in place while performing tenorrhaphy, this allows tension free approximation of two injured tendon ends (**Figure 3**).



**Figure 1.**  
*Bruner's incision with palmar incision to expose the tendon stumps.*



**Figure 2.**  
*A silicone tube to bring the proximal tendon stump to the desired level to avoid potential formation of adhesions.*



**Figure 3.**  
*Temporary fixation of the proximal tendon stump with a needle to facilitate repair.*

### 2.3 Suturing technique

Various suturing techniques have been defined. Among these the modified Kessler suture using two sutures [14] and a 'grasping' suture [15, 16] having knots inside the cross-section have been widely accepted. A running fine epitendinous sutures increase the tensile strength and also allows smooth gliding of the repaired tendon within the digital sheath. However, immediate active rehabilitation is not possible after using these suturing techniques. Therefore, number of studies has been carried out to improve the suturing technique as well as the suturing material.

The 'ideal' suturing material should be strong, pliable but non-reactive, and of small caliber. It is advisable to use Nylon 3/0 for the central suture and for the epitendinous running suturing its recommended to use nylon 5/0 or 6/0 [17]. The 'locking' or a 'grasping' suture [18, 19] with four or six strand sutures [20, 21] is considered to be ideal for central core suturing along with running epitendinous locking sutures [22]. This allows an immediate active rehabilitation programme as this suturing technique provides double strength than usual traditional suturing methods. Tsuge's suture [23] is easy method of performing 'locking' sutures, but it leaves a knot outside over the tendon repair site, which in turn can affect smooth gliding of flexor tendons within the synovial sheath or the pulley system. This new suturing method by virtue of strong repair, allows early active motion with minimal risk of gap formation or early tendon rupture. A new material has been reported which is characterized by its high traction resistance: it consists of two intratendinous, stainless steel anchors that are joined by a multifilament stainless steel suture.

This permanent implant is intended to hold the repaired ends of tendon in close approximation until healing is completed. Protected passive tendon mobilization exercises are carried out after completion of tendon repair.

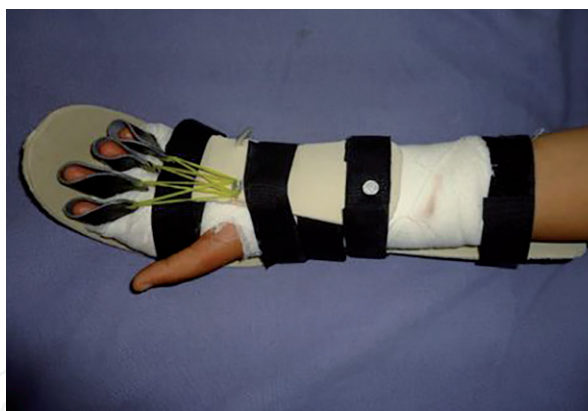## 2.4 Postoperative management

postoperatively, A dorsal plaster splint is applied, from the proximal forearm to the fingertips in 'intrinsic position': the wrist is kept with 20° of palmar flexion, the MP joints in 60° flexion while as PIP and DIP joints are placed in full extension in order to avoid development of any flexion contracture. Two possible options as post-operative protocol are: to immobilize operated hand for 4 weeks or to start early mobilization according to specific exercise protocol. Immobilization is better option in non-cooperative patients and in case of children, in these patients mobilization is started in fifth week, with combination of both active as well as passive motions with dorsal blocking splint in place; seventh week onwards mobilization against resistance is initiated. The complications like tendon rupture or gaping of repair are very low with this protocol, but there are increased chances of adhesion formation, which usually requires tenolysis. Strickland and Glogovac [24] and Lister et al. [25] studied the benefits of early mobilization for tendon healing with better final end results especially in zone II flexor tendon repairs. In these studies using controlled passive mobilization post-operatively excellent results were obtained in 36% patients, 24% patients had poor results and only 4% had tenorrhaphy ruptures; while as no excellent results were obtained in cases of immobilization protocol, poor results were observed in 44% patients and 16% had tenorrhaphy site ruptures. Gelberman et al. [26, 27] also obtained superior results with early mobilization protocol and additional advantages like: improved tendon gliding (due to low rate of soft tissue adherence), enhancement of intrinsic healing mechanism, with enhanced tensile strength thereby decreasing risk of gap formation. The highest risk of tenorrhaphy rupture is between 5th and 10th postoperative day, during this period the hand therapist should be very cautious while doing during active motion exercises.

Kleinert et al. [28] proposed active and passive mobilization with dorsal blocking plaster splint keeping wrist in flexion of 20°, MP joint in flexion of 70° and allowing complete extension of fingers. An elastic traction band is attached to a loop, which is fixed to nail, keeping fingers in flexion but at same time allowing active extension within the range of dorsal blocking splint (**Figure 4**). D first 4 weeks, the patients is asked to perform active extension of the fingers many times for half an hour periods every day at different intervals. For the rest of the day and during the night the rubber band traction is detached in order to prevent development of flexion contracture in interphalangeal joint. At the beginning, the exercises should be guided by the hand therapist keeping patients elbow flexed and pronated in order to relax the flexor muscles. Between the fifth and sixth post-operative weeks, active flexion is begun with dorsal blocking splint in place. This technique is excellent but highly demanding for the therapist, surgeon as well as patient, and a control at every step is necessary to prevent a rupture or a gap at the tendon repair site. A palmar pulley situated at the level of the distal palmar crease significantly improves the range of flexion of the fingers and hence better results have been reported. After repairing the flexor pollicis longus (FPL) in the thumb MP and IP joints are kept in 20° of flexion.

Duran and Hauser [29] proposed controlled passive motion for the post-operative flexor tendon repaired lesions in zone II. The wrist is kept in 20–30° of flexion, the MP joint in 60° of flexion while as PIP and DIP joints are placed in extension.





**Figure 4.**  
*Kleinert's technique for passive flexion and active extension.*

For first 4 weeks controlled passive motion is used, by the hand therapist, twice a day with each session of six to eight motions for each tendon. This method uses 3–5 minute exercise movements at the repair site for preventing any firm adhesion formation. For a week, a rubber band traction is attached to the wrist and active exercises are done for 2 weeks with dorsal blocking splint in place.

Duran's technique was modified by Strickland [15]. He increased the duration and frequency of the passive daily exercises. The PIP and DIP joints are separately mobilized with repeated motions of full passive extension and flexion. An occupational therapist works closely with the operating hand surgeon and guides the controlled passive motion protocol during first 5 weeks. For starting the active flexion exercises after 5th week, the block technique advised by Bunnell [30] can be utilized: the PIP joint is actively flexed while the MP joint is blocked in extension; similarly while the DIP joint is actively flexed, the PIP joint is blocked in extension. Beyond 6 weeks, If the extension of the finger is limited, dynamic splinting may be necessary. Six months is the minimal period before considering any tenolysis and this is the time period that is required to obtain complete motion (especially in children).

Excellent results were reported by Chow et al. [31] in a multicenter study carried out for zone II flexor tendon injuries. They utilized rubber band traction with a palmar pulley at distal palmar crease level thus increasing passive flexion at the MP and PIP joints. This modification increases the differential gliding between superficialis and profundus tendon and in addition increases tendon excursion in the sheath as well. Full passive extension and flexion were performed for the first 4 weeks under the supervision of a hand therapist, in addition to the active extension exercise programme against the rubber band traction. The rubber band traction is removed for the fifth and sixth week and active and passive full flexion and extension exercises are performed. To prevent development of any contracture at the level of interphalangeal joints the supervision of both hand therapist and a hand surgeon is very important.

Many authors have reported their results using early active flexion exercises after performing flexor tendon repair in zone II [32–34]. to perform this rehabilitation programme it's important to Improve the quality as well as resistance of the suture, in order to prevent rupture or a gap of the tendon at the repair site. Indications for using early motion protocol is limited to motivated and intelligent patients having clean cut tendon injury, with a specialized hand therapist working in close collaboration with a hand surgeon.

Magnetic resonance imaging (MRI) is very useful for diagnosing many post-operative complications especially in differentiating gap from adhesion formation, especially in zone II after tenorrhaphy of FDS and FDP tendon injuries.



## 2.5 Zone wise features of primary tendon repair

### 2.5.1 Zone I

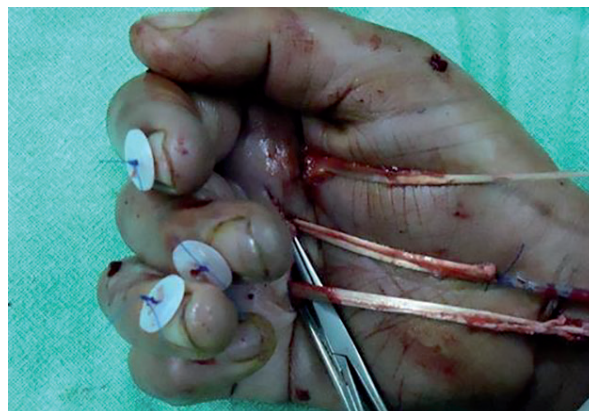
Only the FDP is involved in traumatic lesion of this zone. As the intact vincular system limits the retraction of the tendon hence the severed proximal stump is easy to find. The end to end tenorrhaphy can be done directly if the distal stump is more than 1 cm in length. In case the distal stump is less than 1 cm in length, it is recommended to reinsert the proximal tendon end into the distal phalanx. It is done as double attachment: At the base of the distal phalanx to a subperiosteal flap from the palmar aspect and second attachment is distally at the mid nail plate level after passing through the distal phalanx (**Figure 5**) [35]. A4 pulley should be preserved to prevent bowstringing but the A5 pulley is frequently partially opened.

Avulsion injury of the FDP is relatively a common injury in athletes but often the diagnosis is made late. As any finger can be involved in such injury but the ring finger is most commonly involved. The diagnosis is made in an emergency set up, when an athlete is unable to actively flex the distal phalanx. A lateral radiograph should be carried out routinely, to look for a small bone at the level of the PIP or DIP joint that is actually avulsed from the base of distal phalanx. Three main factors govern the prognosis in such lesion:

1. Remaining nutritional supply to the avulsed tendon and the degree of retraction of the avulsed tendon.
2. Any diagnostic delay.
3. The size of the bony fragment avulsed.

This injury is classified into three types as per Leddy and Parker [36]:

- Type I: complete destruction of the vincular system with FDP retracted into the palm. In an emergency setup, it is advisable to carry out a reinsertion of the severed FDP, but there is significant risk of adherence formation and causing dysfunction of the intact FDS. Alternatively, conservative method of not reinserting severed FDP tendon and excising the FDP tendon with fusion of the DIP joint can be chosen.
- Type II: FDP is retracted to the level of the PIP joint and in this type the vincular system is intact. From all the three this is commonest one. A small bone



**Figure 5.**  
*Reinsertion of the avulsed tendon through the distal phalanx and fixed on the nail plate.*

fragment blocked into the A3 or A2 pulley can be seen in the lateral radiograph. Early reinsertion should be performed or later but within period of 3 months provided vascular supply of the severed tendon is preserved. Satisfactory results can be obtained after repair in this type.

- Type III: in this type a large bony fragment is avulsed from the distal phalanx and caught at the level of A5 or A4 pulley. As the retraction is limited hence vascularization of the severed tendon is spared. There is excellent prognosis once proper repair is done in this type of injury.

Immediately after repair an active rehabilitation programme should be started with dorsal protective splint in place.

Type IIIA lesion as reported by Robins and Dobyns [37]: In this a large bony fragment is fractured from the distal phalanx base and FDP is retracted to the level of PIP joint. Treatment comprises of reduction and an internal fixation of the distal phalanx along with reinsertion of the avulsed FDP tendon. If an avulsion injury is missed in early period, later the treatment will depend upon the degree of motivation of the patient and presence of symptoms (pain, swelling, tenderness and tumefaction) and If the patient has pain or difficulty in movement at the base of the finger it is advisable to excise the FDP tendon. Tenodesis or fusion of the DIP joint can be considered if the distal phalanx is unstable with weak pinch and an excessive dorsal extension.

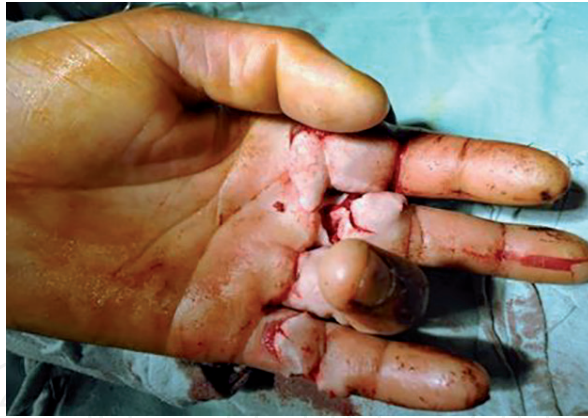Two stage flexor tendon reconstruction of the FDP tendon in zone I is indicated in selective patients; skilled technicians and musicians. It is important to explain the patients the possibility of complications like PIP joint contracture, adhesion formation or worsening of intact FDS tendon functioning.

In the thumb, if the direct repair is not possible, proximal tendon stump can be lengthened by 1–3 cm using tendinous lengthening procedures. A Z-lengthening at the wrist level [38] can give 2–3 cm of advancement and more proximally at the musculo-tendinous junction a fractional lengthening [39] produces an advancement of about 1 cm. The A2 pulley can be partially excised if required without any functional loss but A1 pulley should be preserved.

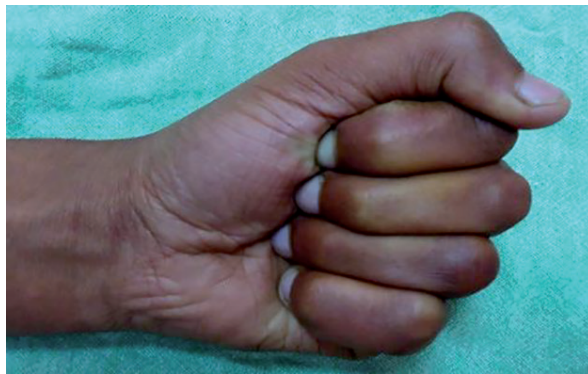### 2.5.2 Zone II

Traumatic lesion in this zone of the finger involves both FDP and FDS tendons, which are most often retracted into the palm (**Figures 6 and 7**). It is recommended to repair both the injured tendons as repairing the FDS tendon preserves the vinculum system which ensures blood supply to the FDP tendon and in addition it maintains a smooth bed for FDP gliding. If only the FDP tendon is repaired and the FDS tendon is excised, it removes the vinculum system at the same time. However, in case both tendons are repaired there are significant chances of developing adhesions between the two tendons especially at the repair site and it may make tenolysis necessary after 6 months of repair.

In the thumb zone II injury causes the FPL trauma, which slips into the palm, and its retrieval gets difficult. In order to locate the proximal stump a small incision is made at the wrist level. This simple approach is adopted to avoid any damage to the carpal tunnel, the thenar eminence and to the cutaneous branch of the median nerve. A similar technique of passing the silicone tube as that used for retrieval of the FDS and the FDP tendons in fingers is used to bring the FPL tendon atraumatically into the initial wound for tenorrhaphy. It is recommended to preserve the A1 or oblique pulley and in case these pulleys are traumatized they need to be reconstructed using the abductor pollicis brevis aponeurosis for prevention of any bowstringing or limitation in thumb motion.



**Figure 6.**  
*Flexor tendon injuries in zone II, Bunnell's "no man's land".*



**Figure 7.**  
*Result in flexion after 6 months of modified Kessler suture and Kleinert's rehabilitation.*

### 2.5.3 Zone III

Injury in this zone is usually associated with damage to the neurovascular bundles, which must be repaired along with the tenorrhaphy of the FDS and the FDP tendons and it is recommended to preserve the transverse palmar fascia (A0 pulley).

### 2.5.4 Zone IV

As this zone is protected anteriorly by the thick transverse carpal ligament hence tendon injuries are rare in this zone. But in case of crush injury in this zone, multiple tendons can get traumatized simultaneously, as they are bunched together in small space of carpal tunnel, in addition median nerve (sensory and motor branches), palmar branch of ulnar nerve can get injured as well. In order to repair all the lesions it is recommended to completely open the carpal tunnel for better access.

### 2.5.5 Zone V

Injury in this zone may involve ulnar artery, radial artery, median nerve, ulnar nerve and multiple tendons. The prognosis after proper repair of the injuries in zone III, IV and V is better and the return of complete motion is expected [40] after 6 months. As compared to zone II tendon adhesions or tenorrhaphy rupture or need of secondary tenolysis are rare in this zone.

## **2.6 Difficult situations in primary tendon repair**

In major trauma where flexor tendon injury is associated with phalanx fracture, skin loss, tendon loss and neurovascular lesions, regular tenorrhaphy without traction is not possible. Two options are available in case the advancement procedures are not sufficient, in zone III, IV or V a bridge graft can be used to restore tendon continuity. A regional or local flap is utilized to cover the repair site and hence decreasing the potential adhesion formation. In zone II, if pulley and the flexor tendon sheath are damaged, it makes placement of transitory silicone tube (Hunters rod) necessary for creation of new digital sheath with smooth gliding potential. This procedure is labeled as “two stage tendon reconstruction”, during the first operation in addition to placement of silicone tube, repair of the neurovascular bundle and skin is done along with reconstruction of the damaged pulleys. A second operation consists of replacement of silicone rod by a tendon graft through limited exposure (Hunter procedure).

The question of whether or not to repair an isolated FDP injury in zone II, it is necessary to assess the level of retraction of proximal stump. If contusion of surrounding soft tissue is limited and the proximal stump is not retracted into the palm, a direct atraumatic repair of the FDP tendon is recommended. But if the proximal stump is retracted into palm with avulsion of vinculum system, there are high chances of local fibrosis and adhesion formation after the FDP repair, therefore in such cases it is preferable to go for DIP tenodesis or fusion rather than to primary repair of the injured FDP tendon.

In case of partial flexor tendon laceration, the surgical technique depends on the total percentage of cross-sectional area of tendon involved: if the laceration involves less than 20% of the total diameter of the tendon, the tendon should be rounded off by local flap resection; to avoid a trigger finger, a partial resection of the pulley could be helpful [41]; if the laceration involves between 20 and 50% of total diameter, a running simple peripheral suture should be sufficient; if the laceration is involving more than 50% of the diameter, a core suture through the injured part of the tendon with fine peripheral running suture is recommended.

## **2.7 Evaluation of results after repairing flexor tendon injuries**

For evaluating the results after tendon repair, many methods have been reported. American Society of Hand Surgery in 1976, proposed a method which measured the active flexion at MP, PIP and DIP joints and decreases in loss of extension for each joint. This value was then compared to the contralateral healthy finger.

Buck-Gramko [42] measured the distance from pulp-palmar, total active motion (TAM) and active extension loss of the finger. This method is lengthy and difficult to reproduce for each patient on every consultation.

Tubiana et al. [43] proposed a method of evaluation which was based on the PIP joint motion. This method evaluated the second phalanx position as compared to the metacarpal position; then the loss of active extension and active flexion of the finger can be precisely measured. This method evaluates the global function of the finger but does not measure the arc of mobility.

Strickland [16] reported a simple method, which counted the total active motion (TAM) of PIP and DIP joints. This method does not take movement across MP joint into consideration; based on the fact that flexion of MP joint is not under the control of only flexor tendons. TAM measured is compared to the contralateral finger to obtain a percentage of motion.



### 3. Conclusions

Many advances have been made in the understanding of tendinous healing mechanism—e.g. rehabilitation programmes, suture technique—but it is important to consider the various other factors related to injury itself that can significantly affect the final outcome, these include: the type of initial injury (clean cut, avulsion or contusion), associated injuries (phalangeal fractures, skin loss or any neurovascular bundle injury) and extent of injury to tendon sheath and pulley system, especially in zone II. However, the maneuvers which help in achieving better end results should essentially be followed, which include: an atraumatic handling of structures preferably under microscope and use of an anatomic suture with high potential of resistance thereby allowing to start immediate active motion and last but not least a well-motivated patient who understands and follows postoperative physiotherapy protocol under the supervision of a hand therapist and an operating surgeon.

### Acknowledgements

We would like to thank all surgeons from department of plastic surgery at Sher-i-Kashmir Institute of Medical Sciences, Soura, Kashmir (India) for providing insight and expertise that greatly assisted in writing this chapter on “Management of Flexor Tendon Injuries in Hand”.

### Conflict of interest

It's to state that there was no conflict of interest in any author for writing this chapter.

### Author details

Tawheed Ahmad<sup>1\*</sup>, Summaira Jan<sup>2</sup> and Saima Rashid<sup>3</sup>


1 Sher-i-Kashmir Institute of Medical Sciences, Soura, Srinagar, Kashmir, India

2 Government Dental College, Srinagar, Kashmir, India

3 Government Medical College, Srinagar, Kashmir, India

\*Address all correspondence to: drtawheedahmad@yahoo.com

### IntechOpen

© 2019 The Author(s). Licensee IntechOpen. This chapter is distributed under the terms of the Creative Commons Attribution License (<http://creativecommons.org/licenses/by/3.0>), which permits unrestricted use, distribution, and reproduction in any medium, provided the original work is properly cited. 

## References

- [1] Doyle JR. Anatomy of the finger flexor tendon sheath and pulley system. *Journal of Hand Surgery*. 1988;**13A**:473-484
- [2] Doyle JR. Anatomy and function of the palmar aponeurosis pulley. *Journal of Hand Surgery*. 1990;**15A**:78-82
- [3] Lin GT, Amadio PC, Cooney WP. Functional anatomy of the human digital flexor pulley system. *Journal of Hand Surgery*. 1989;**14A**:949-956
- [4] Manske PR, Lesker PA. Palmar aponeurosis pulley. *Journal of Hand Surgery*. 1983;**8**:259-263
- [5] Amiel D, Ishizue K, Billings E, et al. Hyaluronan in flexor tendon repair. *Journal of Hand Surgery*. 1989;**14A**:837-843
- [6] Hagberg L. Exogenous hyaluronate as an adjunct in the prevention of adhesions after flexor tendon surgery. A controlled clinical trial. *Journal of Hand Surgery*. 1992;**17A**:132-136
- [7] Gelberman RH, Woo SLY, Amiel D, Horibe SH, Lee D. Influences of flexor sheath continuity and early motion on tendon healing in dogs. *Journal of Hand Surgery*. 1990;**15A**:69-77
- [8] Lundborg G, Hansson HA, Rank F, Rydevick B. Superficial repair of severed flexor tendons in synovial environment: an experimental, ultrastructural study on cellular mechanisms. *Journal of Hand Surgery*. 1980;**5**:451-461
- [9] Lister G. Incision and closure of the flexor sheath during primary tendon repair. *The Hand*. 1983;**15**:123-135
- [10] Saldana MJ, Ho PK, Lichtman DM, Chow JA, Dovel S, Thomes LJ. Flexor tendon repair and rehabilitation in zone II: open sheath technique versus closed sheath technique. *Journal of Hand Surgery*. 1987;**12A**:1110-1114
- [11] Peterson WW, Manske PR, Dunlap J, Horwitz DS, Kahn B. Effects of various methods of restoring flexor sheath integrity on the formation of adhesions after tendon injury. *Journal of Hand Surgery*. 1990;**15A**:48-56
- [12] Schneider LH, Hunter JM, Norris TR, Nadeau PO. Delayed flexor tendon repair in no man's land. *Journal of Hand Surgery*. 1977;**2**:452-455
- [13] Sourmelis SG, McGrouther D. Retrieval of the retracted flexor tendon. *Journal of Hand Surgery*. 1987;**12B**:109-111
- [14] Tajima T. History, current status, and aspects of hand surgery in Japan. *Clinical Orthopaedics*. 1984;**184**:41-49
- [15] Strickland JW. Results of flexor tendon surgery in zone II in flexor tendon surgery. *Hand Clinics*. 1985;**1**:167-169
- [16] Strickland JW. Flexor tendon surgery Part I: Primary flexor tendon repair. *Journal of Hand Surgery*. 1989;**14R**:261-272
- [17] Taras JS, Raphael JS, Marczyk SC, Bauerle WB. Evaluation of suture caliber in flexor tendon repair. *Journal of Hand Surgery*. 2001;**26**:1100-1104
- [18] Barrie KA, Tomak SL, Cholewicki J, Merrell GA, Wolfe SW. Effect of suture locking and suture caliber on fatigue strength of flexor tendon repair. *Journal of Hand Surgery*. 2001;**26A**:340-346
- [19] Wada A, Kubota H, Miyanishi K, et al. The mechanical properties of locking and grasping suture loop configurations in four strand core sutures technique. *Journal of Hand Surgery*. 2001;**25B**:548-551

- [20] Savage R, Risitano G. Flexor tendon repair using a "six strand" method of repair and early active mobilisation. *Journal of Hand Surgery*. 1989;**14B**:396-399
- [21] Dinopoulos H, Boyer MI, Burns ME, Gelberman RH, Silva MJ. The resistance of four and eight strand suture technique to gap formation during tensile testing: an experimental study of repair of canine flexor tendons after 10 days of in vivo healing. *Journal of Hand Surgery*. 2000;**25A**:489-498
- [22] Wade PJF, Wetherell RG, Amis AA. Flexor tendon repair: significant gain in strength from the halsted peripheral suture technique. *Journal of Hand Surgery*. 1989;**14B**:232-235
- [23] Tsuge K, Ikuta Y, Matsui Y. Intratendinous tendon suture in the hand; a new technique. *Journal of Hand Surgery*. 1975;**7**:250-255
- [24] Strickland JW, Glogovac SV. Digital function following flexor tendon repair in zone II: a comparison of immobilization and controlled passive motion techniques. *Journal of Hand Surgery*. 1980;**6**:537-550
- [25] Lister GD, Kleinert HE, Kutz JE, Atasoy E. Primary flexor tendon repair followed by immediate controlled mobilization. *Journal of Hand Surgery*. 1977;**2**:441-452
- [26] Gelberman RH, Siegle DB, Savio LY, et al. Healing of digital flexor tendons: Importance of the interval from injury to repair. *The Journal of Bone and Joint Surgery*. 1991;**73A**:66-75
- [27] Gelberman RH, Steinberg D, Amiel D, Akeson W. Fibroblast chemotaxis after tendon repair. *Journal of Hand Surgery*. 1991;**16A**:688-693
- [28] Kleinert HE, Kutz JE, Ashbell TS, Martinez E. Primary repair of lacerated flexor tendons in "No man's land". *Journal of Bone and Joint Surgery*. 1967;**49A**:577
- [29] Duran RJ, Hauser RG. Controlled passive motions following flexor tendon repair in zones two and three. In: *AAOS Symposium on Tendon Surgery in the Hand*. St Louis: Mosby; 1975. pp. 105-111
- [30] Bunnell S. *Surgery of the Hand*. 3rd ed. Philadelphia: JB Lippincott; 1956
- [31] Chow A, Thomes LJ, Dovel SW, Milnor WH, Jackson JP. Controlled motion rehabilitation after flexor tendon repair and grafting: A multi-centre study. *Journal of Bone and Joint Surgery*. 1988;**70B**:591-595
- [32] Becker H, Orak F, Duponselle E. Early active motion following a bevelled technique of flexor tendon repair: Repair of fifty cases. *Journal of Hand Surgery*. 1979;**4**:454-460
- [33] Small JO, Brennen MD, Colville J. Early active mobilization following flexor tendon repair in zone 2. *Journal of Hand Surgery*. 1989;**14B**:383-389
- [34] Bellemère P, Chaise F, Friol JP, Gaisne E, Le Lardic C. Résultats de la mobilisation active précoce après réparation primaire des tendons fléchisseurs. *La Main*. 1998;**3**:221-233
- [35] Foucher G, Merle M, Ph H. Suture du tendon fléchisseur profond au niveau de la partie distale du "No Man's land". *Revue de Chirurgie Orthopédique*. 1986;**72**:227-229
- [36] Leddy JP, Parker JW. Avulsion of the profundus tendon insertion in athletes. *Journal of Hand Surgery*. 1977;**2**:66
- [37] Robins PR, Dobyns JH. Avulsion of the insertion of the flexor digitorum profundus tendon associated with fracture of the distal phalanx. A brief review. In: *AAOS Symposium on Tendon Injury in the Hand*. St Louis: CV Mosby; 1975. pp. 151-156

[38] Urbaniak J. Repair of flexor pollicis longus. *Hand Clinics*. 1985;1:69-76

[39] Leviet D. Flexor tendon lengthening by tenotomy at the musculotendinous junction. *Annals of Plastic Surgery*. 1986;17:239-246

[40] Rogers GD, Henshall AL, Sach RP, Wallis KA. Simultaneous laceration of the median and ulnar nerves with flexor tendons at the wrist. *Journal of Hand Surgery*. 1990;15A:990-995

[41] Frewin PR, Scheker LR. Triggering secondary to an untreated partially cut flexor tendon. *Journal of Hand Surgery*. 1989;14B:419-421

[42] Buck-Gramko D. A new method for evaluation of results in flexor tendon repair. *Handchirurgie*. 1976;8:65-69

[43] Tubiana R, Gordon S, Grossman J, McMeniman P. Evaluation des résultats après réparation des tendons fléchisseurs des doigts. In: Tubiana R, editor. *Traité de Chirurgie de la Main*. Vol. 3. Paris: Masson; 1986. pp. 281-286