

We are IntechOpen, the world's leading publisher of Open Access books Built by scientists, for scientists

6,900

Open access books available

186,000

International authors and editors

200M

Downloads

Our authors are among the

154

Countries delivered to

TOP 1%

most cited scientists

12.2%

Contributors from top 500 universities



WEB OF SCIENCE™

Selection of our books indexed in the Book Citation Index
in Web of Science™ Core Collection (BKCI)

Interested in publishing with us?
Contact book.department@intechopen.com

Numbers displayed above are based on latest data collected.
For more information visit www.intechopen.com



Stoma Revision on the Flaps in Cases of Abdominal Wall Defect with Digestive Tract Rupture

Masaki Fujioka

Abstract

Several surgical methods are performed for the reconstruction of abdominal wall defects after abdominoperineal resection, involving re-suture and free skin grafting. In the complex surgical cases with large abdominal wall defects, the treatment of intestinal fistula and wound infection is challenging. In many cases, they also have had the problems of the control and reposition of a stoma, which has been already present due to the previous unsuccessful surgical procedures. Especially, the case of larger abdominal wall defects with intestinal fistulation, which drains digestive juice into the wound, requires repairing the abdominal wall while fashioning a stoma. This is because a ruptured digestive tract causes infection and inflammation that results in adhesion of the digestive tract, which limits the mobility of both the abdominal wall and bowel. The only method to solve this complex problem is abdominal wall reconstruction with a large vascularized flap and creation of a new stoma on it to separate the wound from drained digestive juice. We present several cases of a large abdominal wall defect, which was reconstructed successfully. Especially, surgical methods using free and perforator flaps are highlighted. These are optimal methods to reconstruct severe abdominal wall defects that involve complications.

Keywords: stoma, flap, abdominal wall defect, digestive tract rupture, surgical site infection

1. Introduction

Intestinal stomas are surgically created openings of either the small or large bowel into the anterior abdominal wall. They are often necessary to prevent devastating complications or save a patient's life [1]. Permanent stomas are required when altered anatomy prohibits the re-establishment of gastrointestinal continuity or the risks of undergoing another surgery are prohibitive due to the patient's poor condition. A well-made stoma will have the largest impact on the patient's long-term quality of life.

The principles of stoma creation are typically the same: the opening is created in the abdominal wall, a segment of the bowel is delivered through the external and internal oblique and transversus muscles, and the bowel is opened and secured to the skin [1]. Thus, successful stoma creation requires a healthy abdominal wall and a well-vascularized, tension-free segment of bowel [1, 2].

However, patients who have undergone prior abdominal surgery and developed bowel inflammation and adhesion present with problems, if they require emergent ileostomy for infection or fistulization. Especially, when an

abdominal surgical site infection associated with abdominal wall defect develops, fashioning an intestinal stoma is very challenging [3, 4].

In these cases, reconstruction of a wall defect after abdominoperineal resection is very demanding with regard to the functional outcome. Several surgical methods have been performed involving re-suture, free skin grafting, and local flaps, which can be useful when the defect is relatively small [4]. However, larger abdominal wall defects usually require large flaps [5–7]. If the bilateral abdominal skin was not damaged by previous surgical procedures, abdominal defect may be reconstructed using a large pedicled flap. On the other hand, in the case of larger defects with further complications, such as an antecedent formation of a colostomy or iliac conduit, the free flap transfer is required, because local flaps around the wound cannot be harvested due to the damages of the abdominal skin.

The aim of this article is to describe techniques of stoma creation on the flaps in cases of postoperative fascial necrosis with internal bowel fistulae causing continuous peritoneal contamination. Especially, surgical methods for the two major types of the complications: abdominal wall defect with wound infection “with and without previous stoma” using free and perforator flaps are especially highlighted.

2. Case presentations of abdominal wall defect with wound infection with and without the previous stoma

2.1 Case1. Abdominal reconstruction with a free latissimus dorsi musculocutaneous flap for the patient with previous stoma

A 38-year-old female originally had squamous cell carcinoma of the cervix uteri and had undergone radical hysterectomy and oophorectomy followed by postoperative chemotherapy and radiotherapy. After a disease-free period of 13 years, cervical cancer recurred, and she underwent pelvic exenteration including the bladder, rectum, sigmoid colon, and vagina. The end colostomy and ileal conduit were fashioned. However, her postoperative course was complicated by small bowel necrosis, which required another laparotomy to remove it. The mid-abdominal wound developed dehiscence. The pelvic cavity, which extended from the pubic symphysis to the coccyx internally and communicated with the perineal defect measuring 8 × 6 cm, was packed with saline-soaked gauze dressing every day. The remaining bowel and omentum were adherent at the center of the abdominal cavity, possibly due to the previous radiation (**Figures 1–3**). Furthermore, the adhered colon developed necrosis, which drained stools into the pelvic cavity, resulting in chronic peritonitis (**Figures 4 and 5**). Surgery was planned so that the empty pelvic cavity could be filled with a large vascularized muscle to prevent chronic peritonitis and create a new stoma for the ruptured colon to separate the pelvic cavity from drained stools (**Figure 6**). At first, the abdominal full-thickness defect combined with its communication with the pelvic cavity was de-epithelialized and curetted carefully. The patient was then placed in a right lateral decubitus position, and a left combined serratus anterior and latissimus dorsi musculocutaneous flaps with a 25 × 7-cm elliptical skin island, both of which were based on the thoracodorsal vessels, was harvested in the standard manner (**Figure 7**).

Following primary closure of the donor defect, these muscle flaps were inserted into the pelvic cavity. Then, the thoracodorsal artery was connected by end-to-end anastomosis with a branch of the profunda femoris artery, and two thoracodorsal veins were connected by end-to-end anastomosis with the branches of the venae

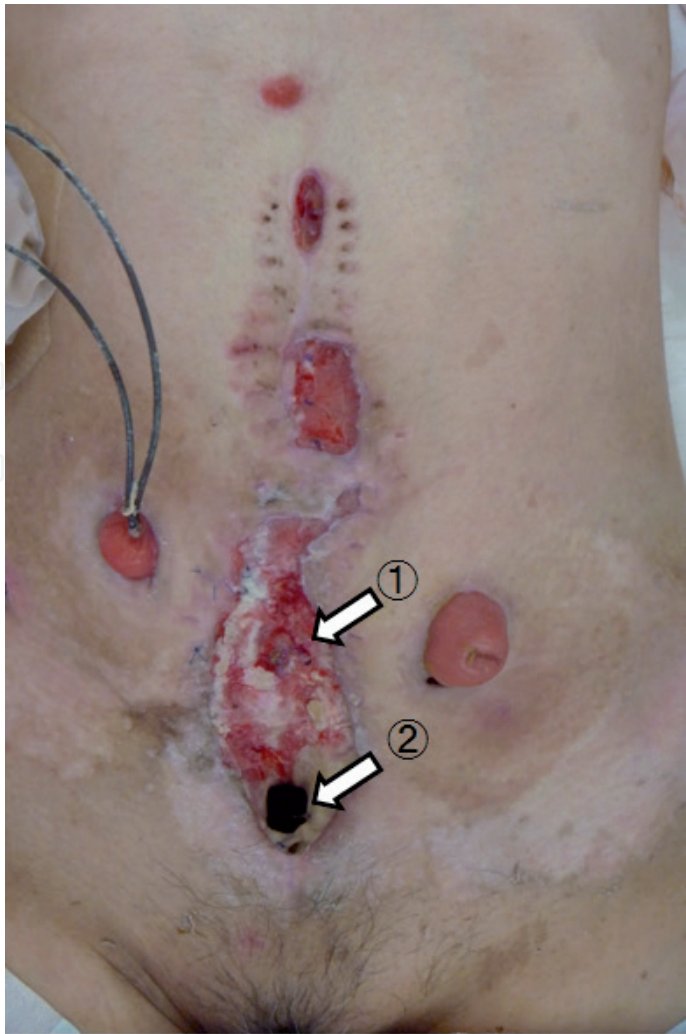


Figure 1.
A view of the abdominal wound, demonstrating the ruptured colon at the center of the abdominal cavity (1), and the fistula penetrating the pelvic cavity (2).

comitantes of this profunda femoris (**Figure 8**). Finally, a skin paddle was applied to cover the abdominal fistula, and a new colon stoma was fashioned through the slit made in the skin flap (**Figures 9 and 10**).

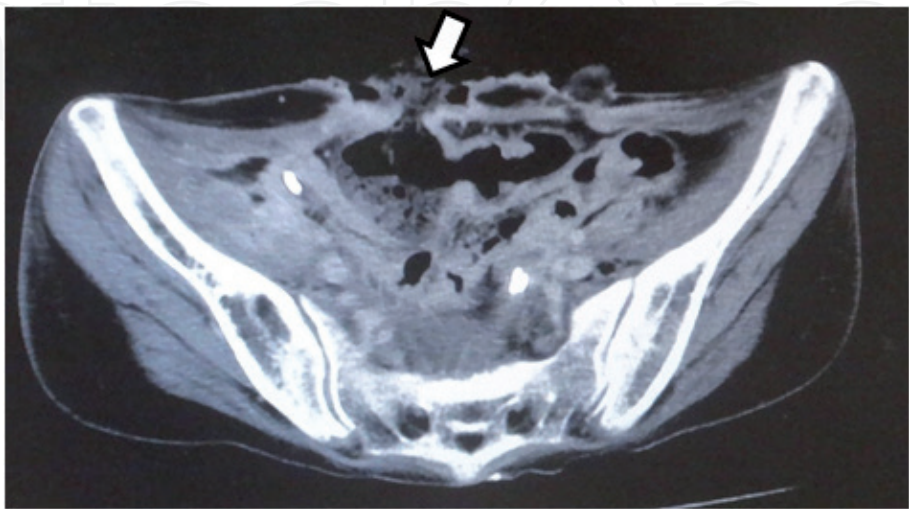


Figure 2.
Computed tomography scan image demonstrating a necrotic colon (arrow).

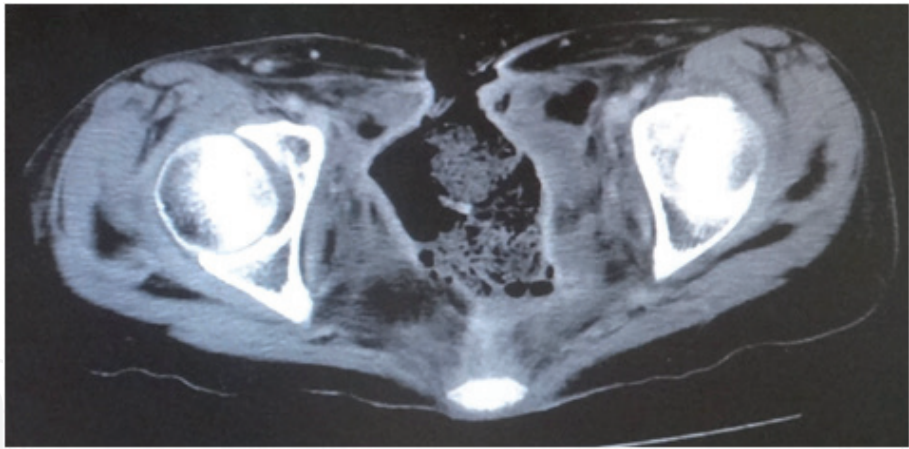


Figure 3.
Computed tomography scan image demonstrating the pelvic cavity, which extended from the pubic symphysis to coccyx internally.

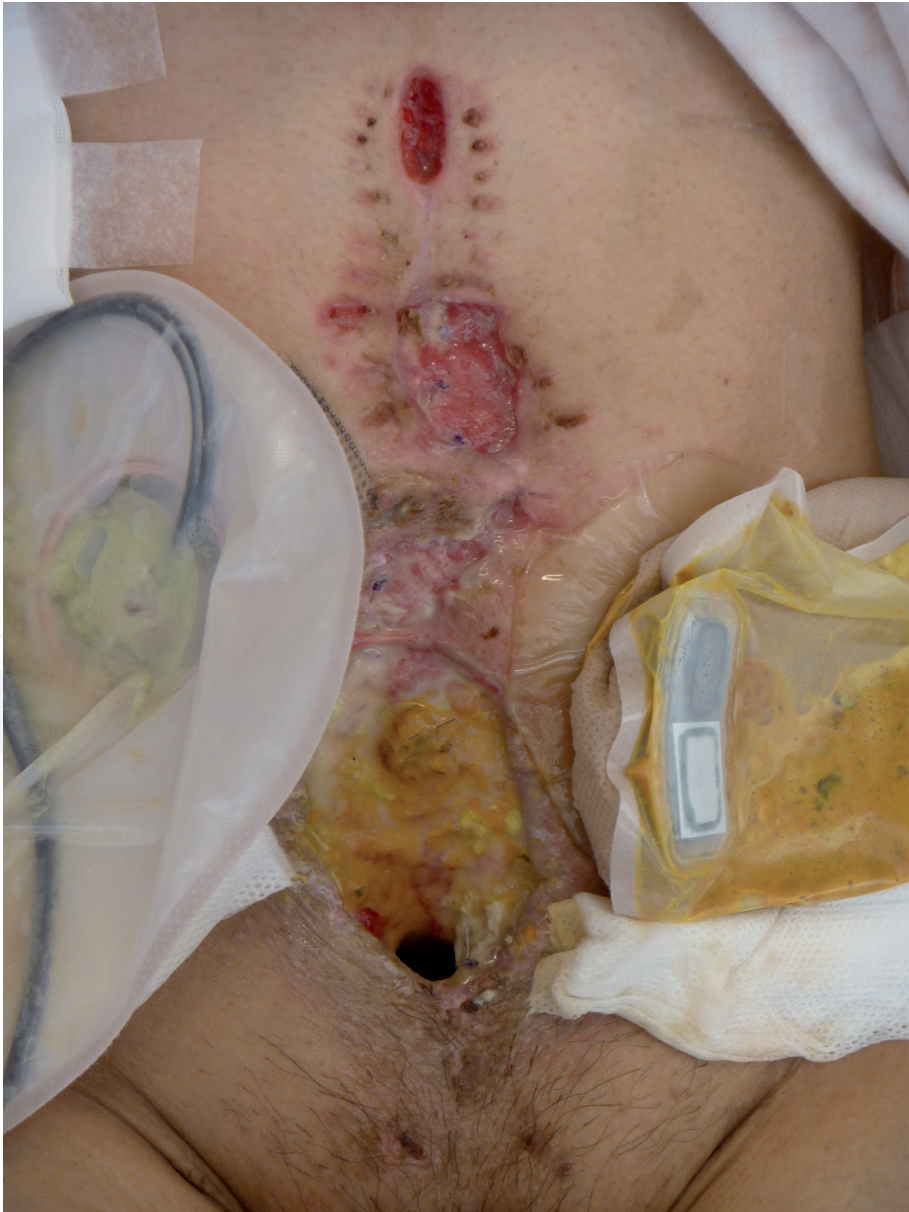

Figure 4.
A view of the abdominal wound, demonstrating that the ruptured colon drained stools into the pelvic cavity, resulting in chronic peritonitis.

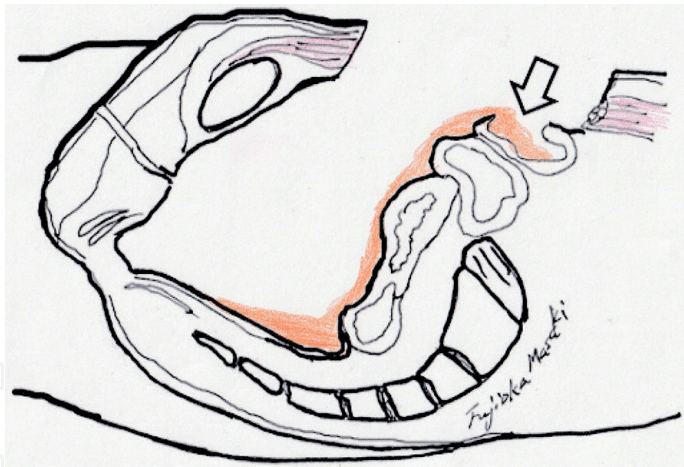


Figure 5.
Illustration of the sagittal section demonstrating the ruptured colon (arrow) and fistula in the pelvic cavity.

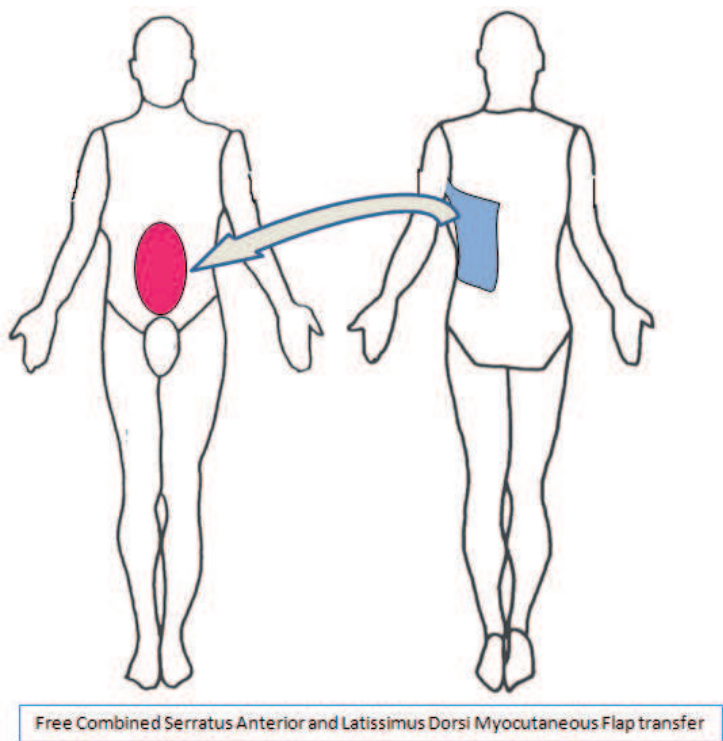


Figure 6.
Schematic illustration of the surgical procedure of free combined serratus anterior and latissimus dorsi musclocutaneous flaps transfer.

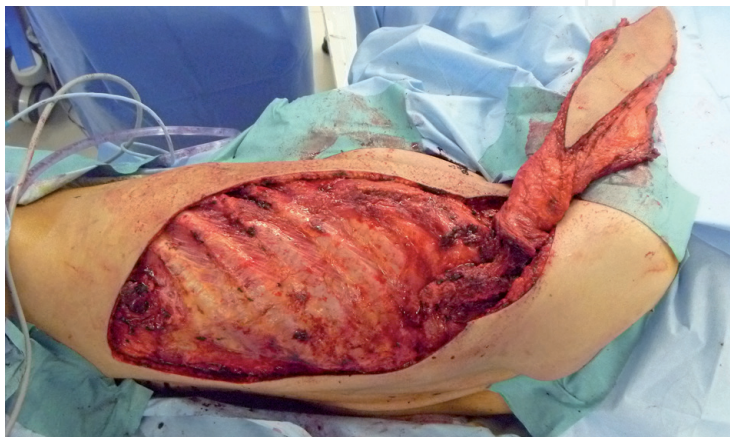

Figure 7.
Intraoperative view showing a left combined serratus anterior and latissimus dorsi musclocutaneous flaps with a skin island.

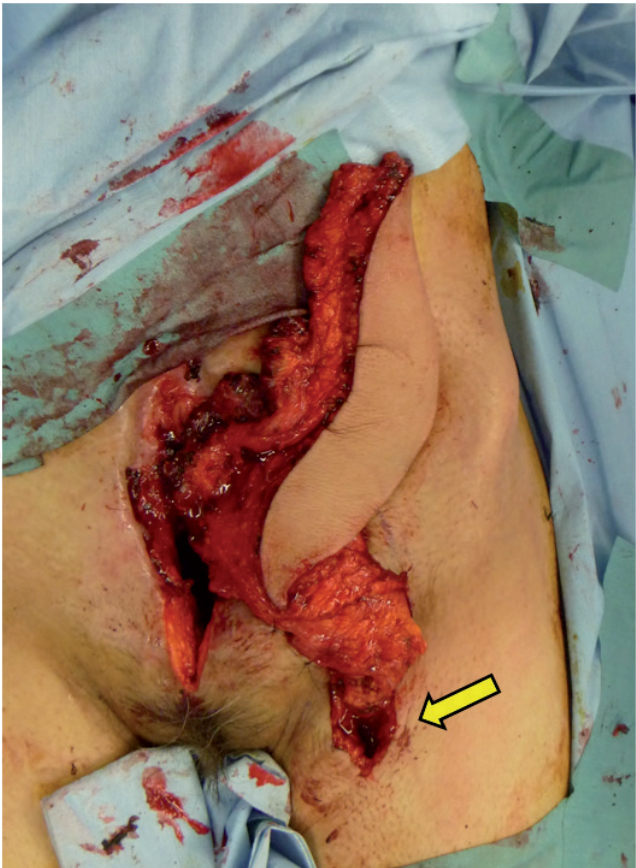

Figure 8.
Intraoperative view showing the muscle flaps inserted into the pelvic cavity and the thoracodorsal vessels connected with a branch of the deep vessels of the thigh (arrow).

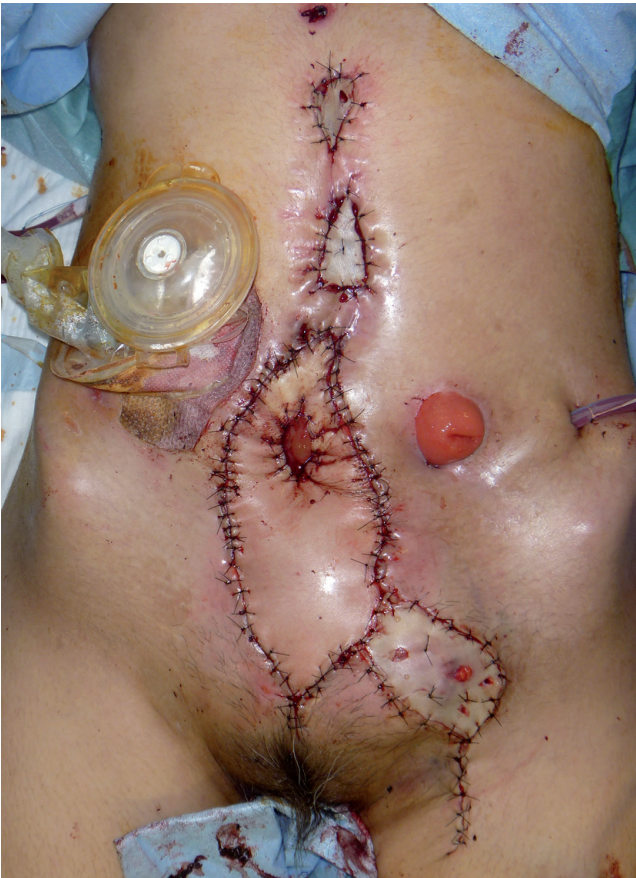

Figure 9.
Intraoperative view showing a skin paddle applied to cover the abdominal fistula and a new colon stoma fashioned through the slit made in the skin flap.

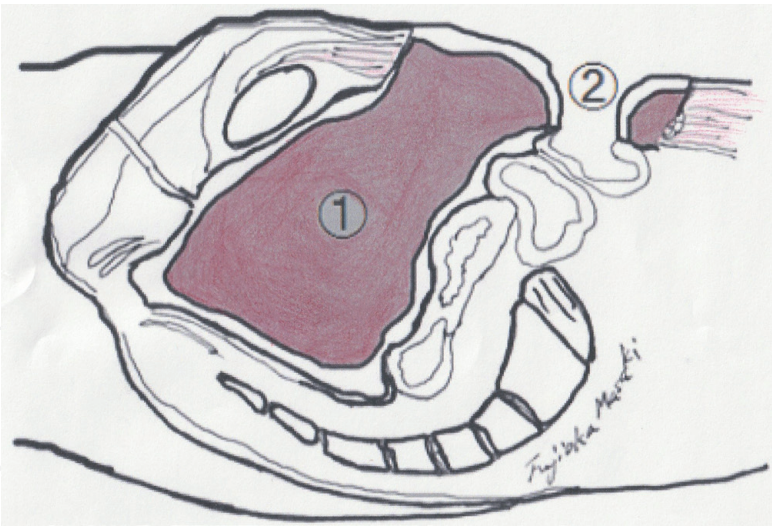


Figure 10.
Illustration of a sagittal section demonstrating the pelvic cavity filled with the muscle (1) and a new colon stoma fashioned in the skin flap (2).

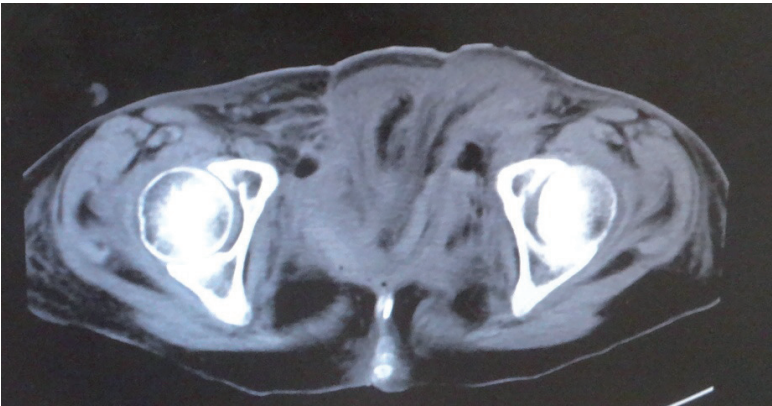


Figure 11.
Computed tomography scan image taken after 2 weeks, showing the pelvic cavity filled with the transported muscle.

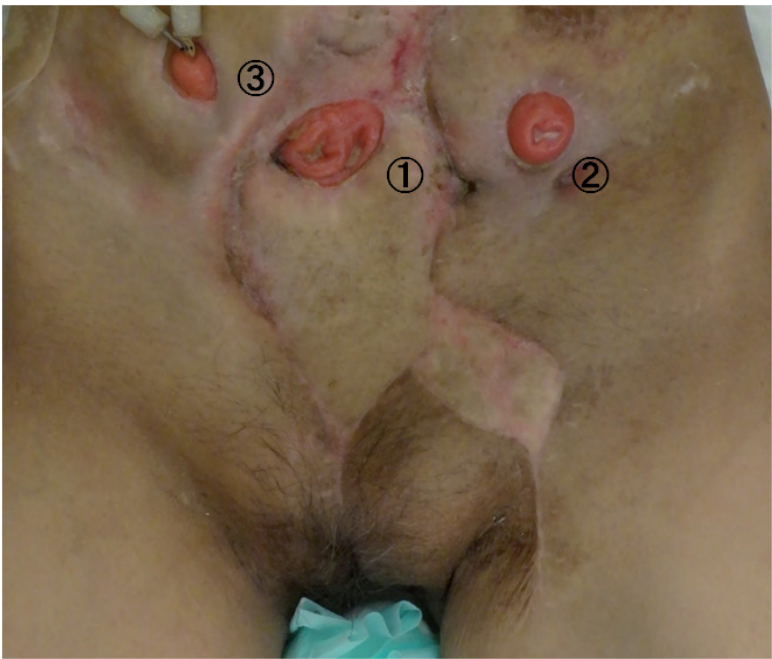

Figure 12.
A view of the abdominal wall 3 months after surgery revealed favorable coverage of the wound and a new colon stoma fashioned on the flap (1). It also showed a conventional stoma (2) and conventional urinary stoma (3).

A CT scan taken after 2 weeks showed that the pelvic cavity had been filled with the transported muscles (**Figure 11**). She underwent excess free skin grafting due to partial necrosis developing at the distal end of the skin flap 3 weeks later. Three months later, the patient could walk in the absence of abdominal hernia formation and relapse of infection (**Figure 12**).

2.2 Case 2. Abdominal reconstruction with pedicled perforator flaps for the patient without previous stoma

A 66-year-old male originally had squamous cell carcinoma of the lower esophagus (Stage III) and had undergone radical resection of the esophageal cancer followed by reconstruction using free jejunum flap transfer. However, his postoperative course was complicated by peritonitis due to a perforation of the duodenum on the next day, which required another emergency laparotomy to cleanse and close the duodenal fistula. The mid-abdominal wound, which extended from the pubic symphysis to the processus xiphoideus, measuring 25 × 6 cm, developed infection and dehiscence 4 days after the primary surgery (**Figure 13**). Thus, the patient underwent debridement, and the wound was packed with saline-soaked gauze dressing every day. Furthermore, the exposed small intestine, which was adherent and fixed at the center of the abdominal wound, developed necrosis and drained digestive juice into the wound, resulting in a contaminated chronic ulcer 10 days after the primary surgery (**Figure 14**).

Reconstruction surgery was performed 20 days after the primary surgery, so that the open wound could be resurfaced with a large vascularized flap to prevent chronic contamination and create a new ileostoma for the ruptured ileum to separate the wound from drained digestive juice. The abdominal full-thickness defect was curetted carefully, and two triangular fasciocutaneous flaps of 25 × 7 cm, both of which were based on the perforator vessels of the lower abdominal artery, were harvested bilaterally (**Figure 15**).

Following primary closure of the donor sites, these perforator flaps were transferred medially to resurface the exposed small intestine. The ruptured ileum was encircled by these two flaps, and the mucosa of the small intestine was sutured to the skin of the flaps; consequently, an ileostoma was fashioned between the skin flaps (**Figure 16**). The remaining upper and lower abdominal wounds were resurfaced using free skin grafting.

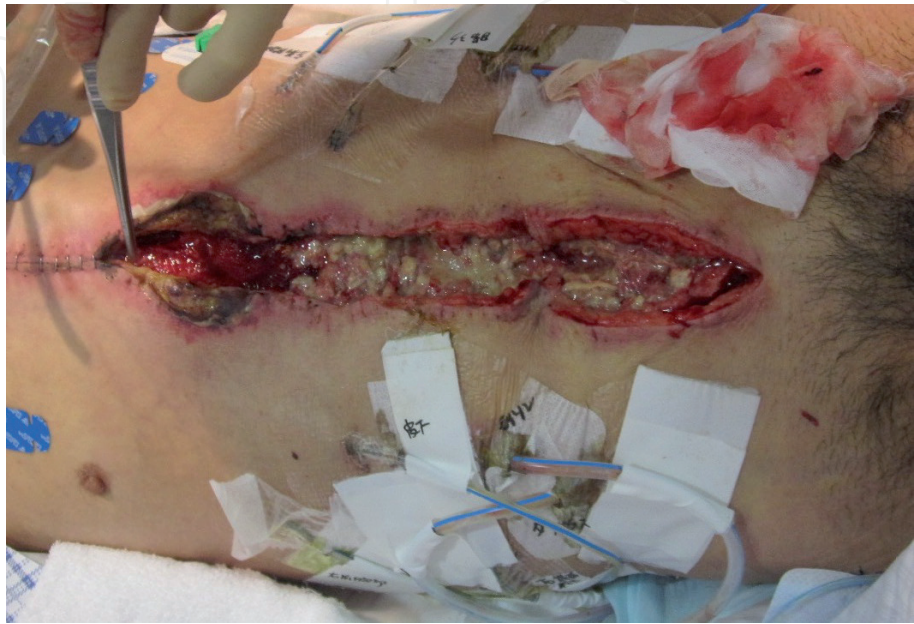

Figure 13.
A view of the abdominal wound, demonstrating infection and dehiscence.

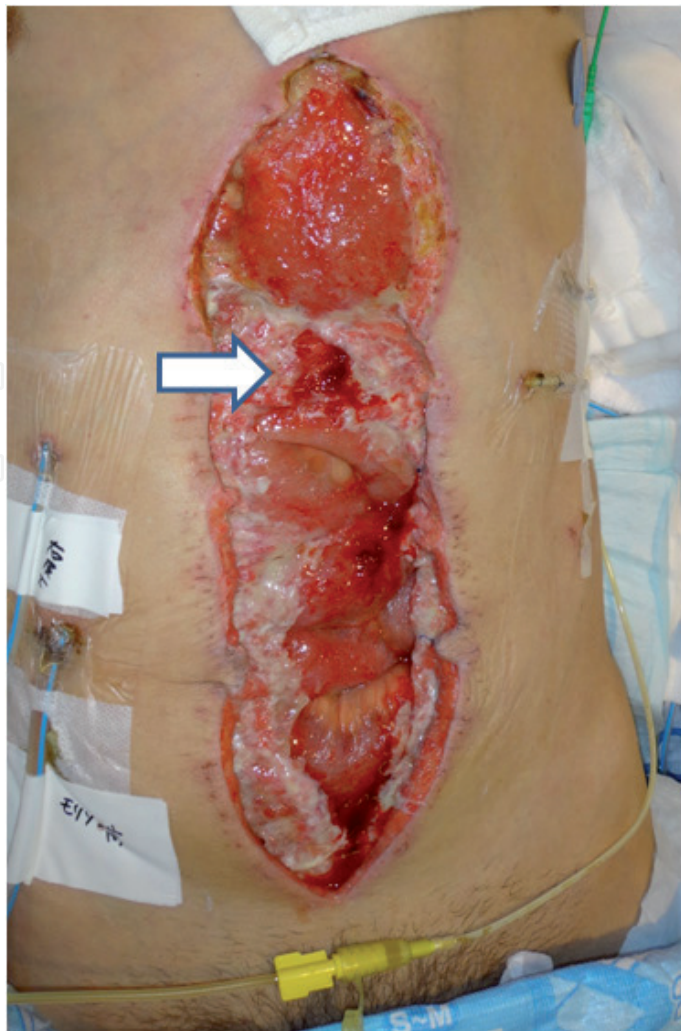

Figure 14.
A view of the abdominal wound after debridement, demonstrating the exposed small intestine, which ruptured and developed a fistula (arrow).

Three months later, all abdominal wounds had resurfaced, and the draining digestive juice could be controlled using a stoma bag. The patient could walk in the absence of abdominal hernia formation and relapse of infection (**Figures 17 and 18**).

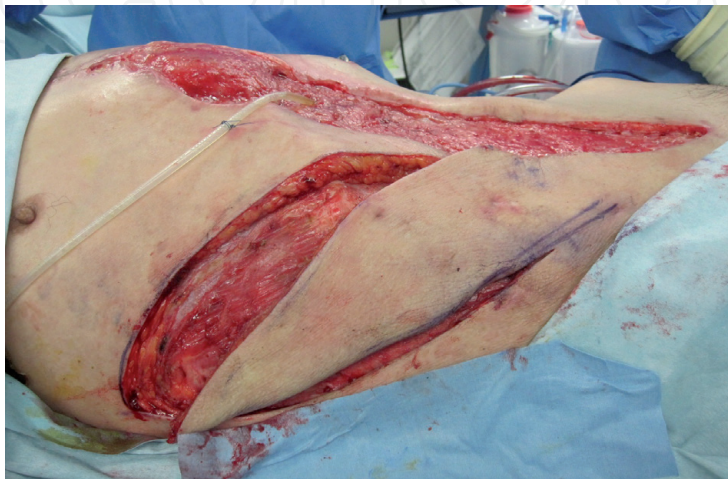


Figure 15.
A view of flap elevation, involving a triangular fasciocutaneous flap, fed by the perforator vessels of the lower abdominal artery.

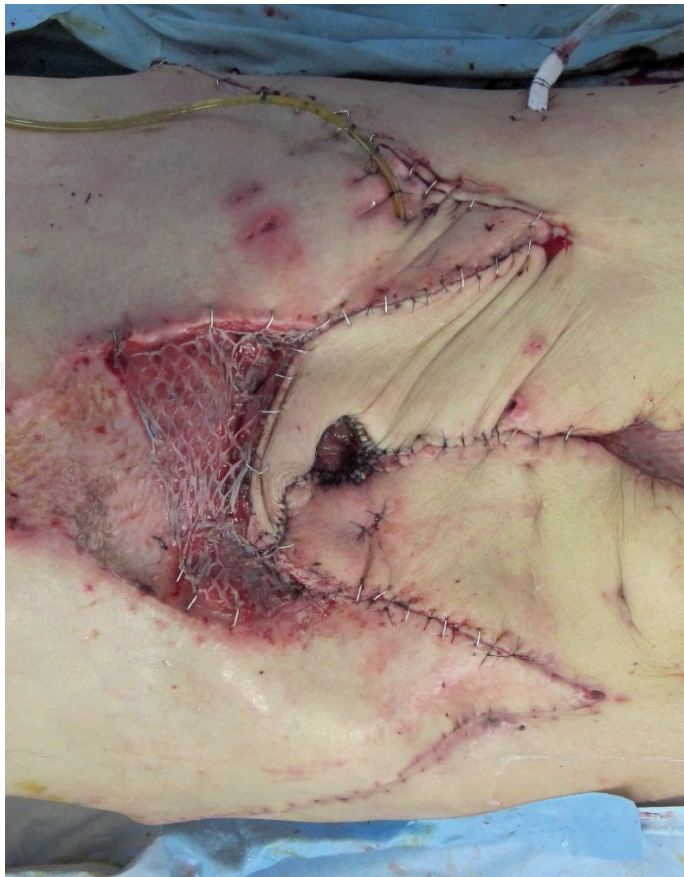

Figure 16.
A view of ileostoma creation; the ruptured ileum was encircled by two flaps.

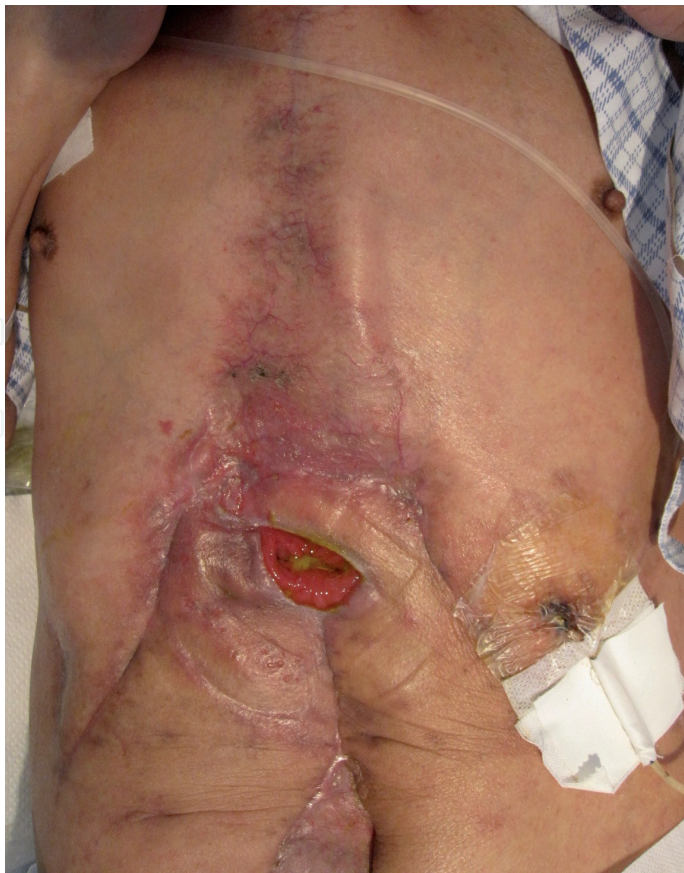

Figure 17.
A view of the abdominal wound 3 months after the surgery, showing that all abdominal wounds had resurfaced.

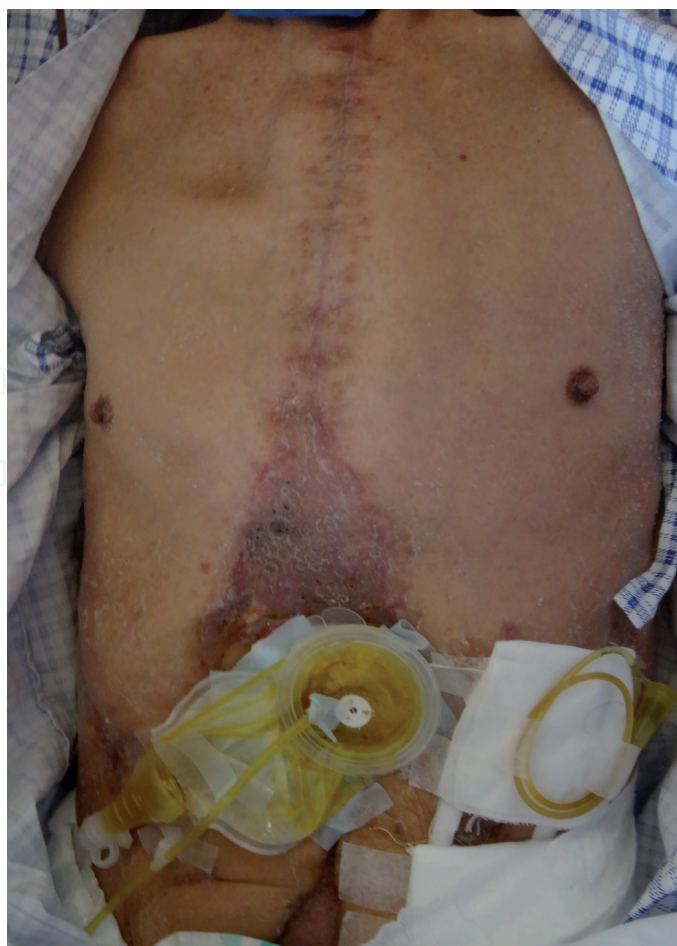

Figure 18.
The draining digestive juice could be controlled using a stoma bag.

3. Discursion

3.1 Management of complex abdominal wall wounds

Management of the patients with infected abdominal wounds associated with bowel fistulae is complicated, and the condition may prove fatal. Kendrick et al. reviewed 21 patients with severe postoperative soft tissue necrosis of the abdominal wall with and without associated intestinal fistulae and reported an overall survival rate of only 71% [8].

Regarding the treatment of an enterocutaneous fistula resulting from invasive bowel infection, en bloc resection of the involved bowel and enterocutaneous fistula tract with a healthy tissue margin while employing direct abdominal wall closure may be an ideal surgical treatment [9]. If the intestinal fistulation cannot be closed directly and end-to-end bowel anastomosis after ruptured intestine removal is not possible, the treatment for these patients becomes complicated, because debridement of contaminated soft tissue, abdominal wall reconstruction, and stoma fashioning are required at the same time [10].

In the procedure of fashioning a stoma, patients who have undergone prior complex abdominal operations present with difficulty due to an edematous and friable bowel and intra-abdominal adhesion, which decrease bowel mobilization. In these cases, the bowel is fixed on the adhesive mass of inflammation, making it difficult to deliver a well-vascularized, tension-free segment of bowel to the normal skin area and secure it through an adequate site of the abdominal wall [3, 11]. Furthermore, the inflammatory and exposed bowel caused by the wound dehiscence tends to develop ischemia and necrosis, which can result in intestinal rupture.

The drained digestive juice and stool from the fistulae spread and worsen the soft tissue infection. Ileostomy effluent, with an alkaline pH and containing active digestive enzymes, is discharged almost continuously and excoriates and digests unprotected skin if left exposed. A colostomy discharges feces, which can cause continuous contamination of wounds [12]. Many of these patients have lost substantial soft tissue to resurface the wound, due to prior enterectomy resulting in reduced compliance of the skin and abdominal wall caused by multiple operations, stomas, abscesses, and enterocutaneous fistulae [13].

The procedure for fashioning an ileostomy or colostomy is well established and straightforward in typical cases. However, problems such as intra-abdominal adhesions, bowel rupture with infection, and abdominal wall defect are difficult to manage [14]. In this context, the key point of managing these complex wounds is to create a stoma on the durable skin and separate the wound from the ileostomy effluent. To achieve this the area around the fistulae should be resurfaced with well-vascularized skin flaps.

3.2 Surgical reconstruction of the abdominal wall

Regarding abdominal wall reconstruction, several surgical methods include primary closure with and without artificial instruments, tissue expanders, component separation, and the use of local, regional, or free flaps [9]. Simultaneous reconstruction of the abdominal wall with prosthetic mesh is associated with a particularly high incidence of recurrent postoperative fistulation. Repair of contaminated abdominal wall defects with non-cross-linked biologic mesh and a component separation technique led to 36 of 80 patients (45%) developing wound infection [15]. Also, artificial mesh disturbs intestinal penetration through the abdominal wall [16]. Adaptations of artificial fascia are not adequate to resurface these contaminated wounds, because these non-vascularized substances are foreign bodies, which can aggravate infection [17–19]. Tissue expanders are used with the aim of expanding the skin around the wound [20]. They can provide the skin that can be used to cover large defects. However, this technique also requires the use of a foreign body in patients, which is a risk of infection, and there are space limitations caused by enterocutaneous fistulae, scar tissue, and stomas [2].

If the abdominal wall defect has a moderate size, but direct wound closure is impossible, abdominal repair with the component separation method, which is one of rectus abdominis muscle advancement flaps, is an alternative technique. This method can be accomplished without the need for artificial mesh, so it is also recommended from an infection control perspective (**Figure 19**) [21]. Separation of the muscle components of the abdominal wall allows mobilization of the rectus abdominal muscle, which enables each unit of the muscle to be sutured directly, and the stoma can be created through the reconstructed muscle. The external oblique muscle is bluntly dissected from the underlying internal oblique muscle, which should result in approximately 5 cm of advancement in the upper third of the abdomen, 10 cm in the mid-abdomen, and 3 cm in the lower third of the abdomen (**Figures 20–22**). This method is easy to perform without requiring the transposition of remote myocutaneous flaps or free tissue transfers [22, 23].

If wide and contaminated abdominal wounds cannot be closed directly, even with the component separation technique, pedicled or free flap transfer is required to resurface the wound [24, 25]. Kayano et al. compared 8 free anterolateral thigh (ALT) flaps and 12 pedicled ALT flaps for abdominal wall reconstruction to investigate their associated complications and clinical and demographic data and concluded that complication rates do not differ between free and pedicled ALT flaps. They suggested that the choice of flap depends on the size and location of the defect and the length of the vascular pedicle [26].

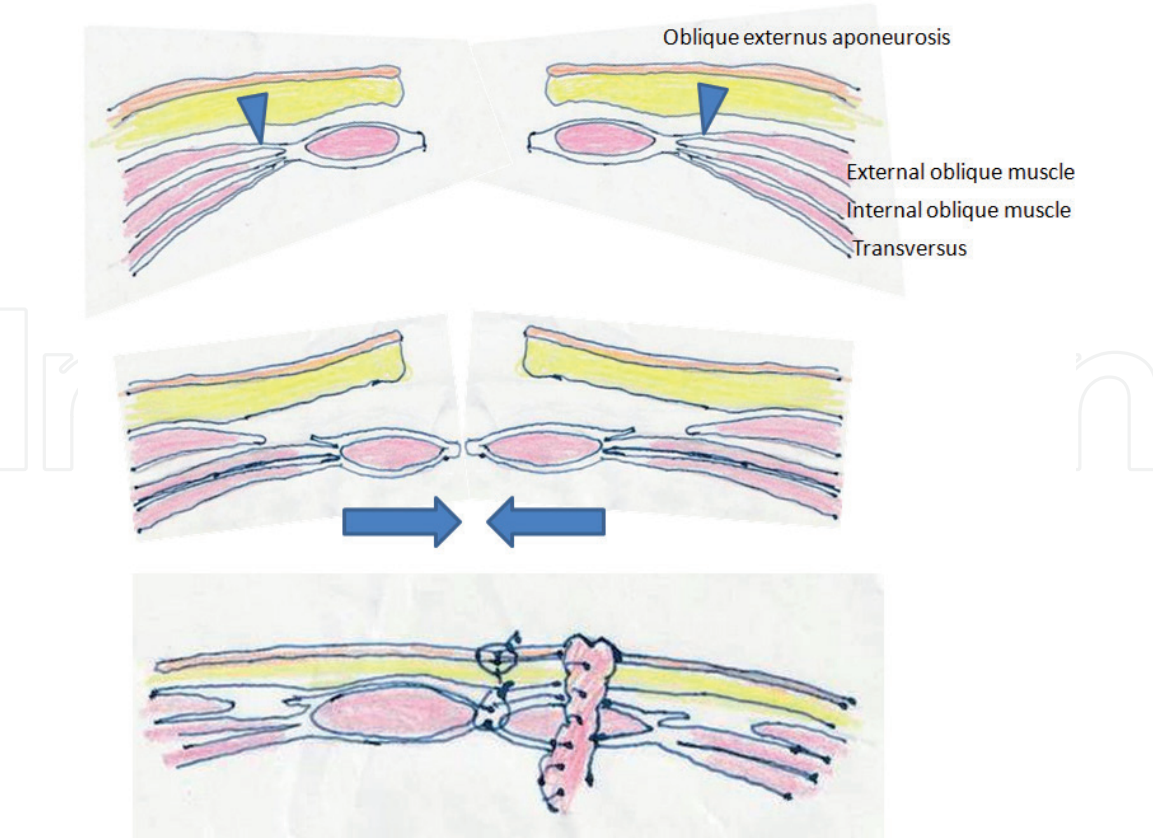


Figure 19.
Schematic illustration of abdominal wall repair with the component separation technique to enable primary fascial closure.

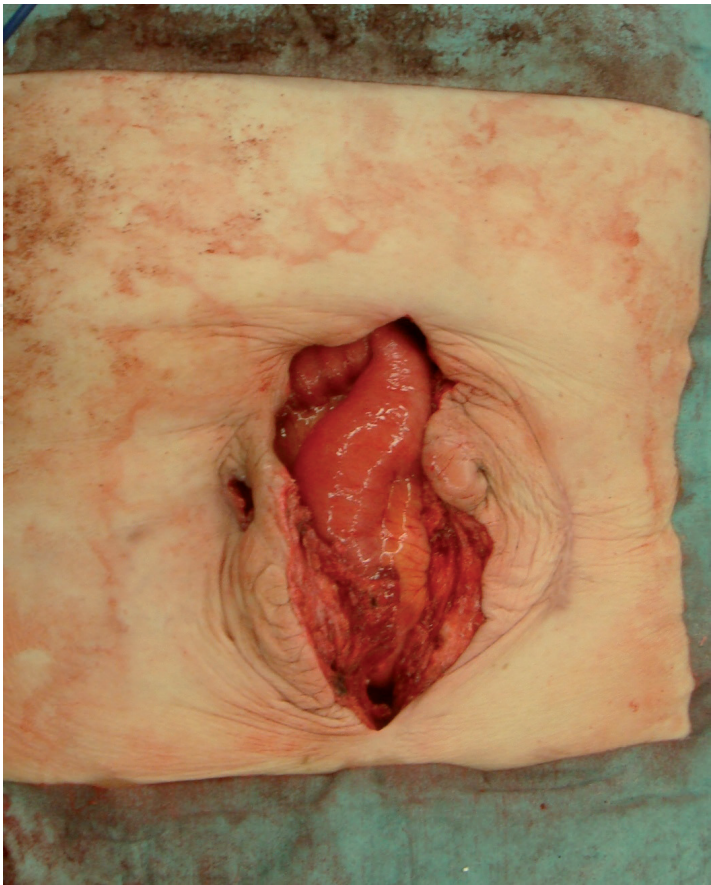


Figure 20.
Abdominal wall defect with a 7-cm width developed after debridement of contaminated skin and muscle.

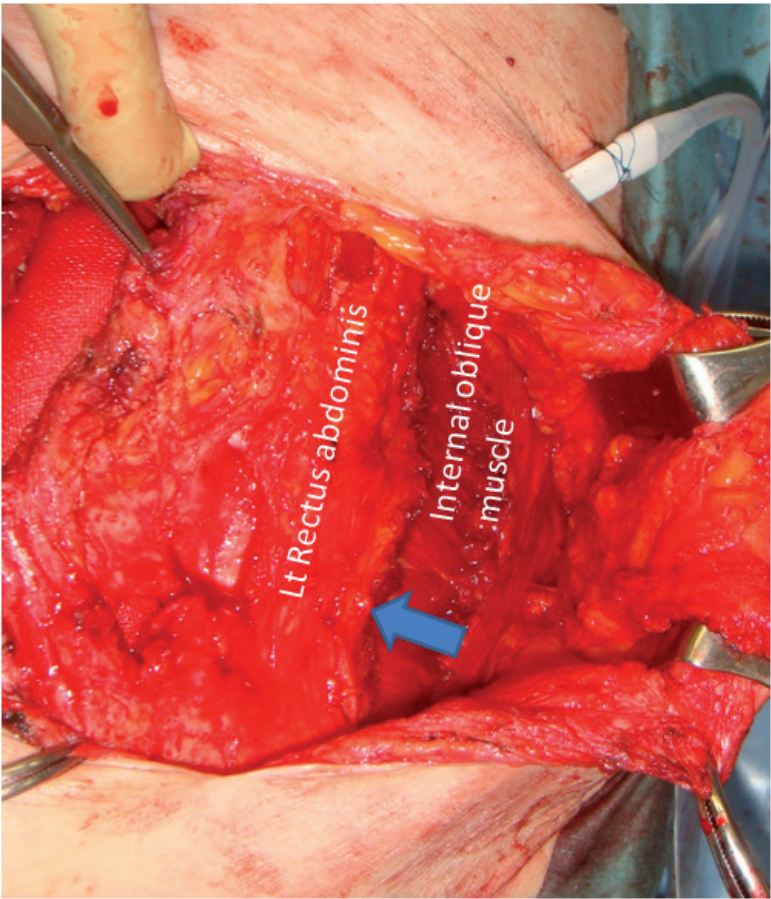


Figure 21.
The external oblique muscle was dissected from the underlying internal oblique muscle, which allowed rectus abdominal muscle advancement 4 cm median-ward (arrow).

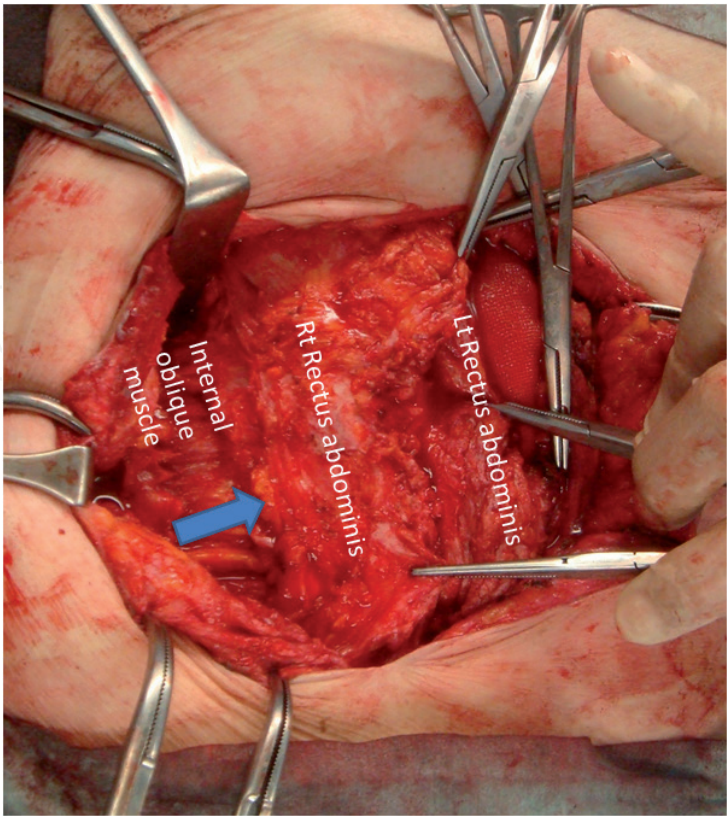


Figure 22.
Bilateral separation of the muscle components of the abdominal wall allows mobilization of the rectus abdominal muscle, enabling each unit of the muscle to be sutured directly.

Several case series revealed that a large flap is usually required for repair in the presence of larger defects with further complications, such as the formation of intestinal fistulae, and wound infection [5–7]. Reconstruction of a lower abdominal defect (below the umbilicus) can be achieved using pedicled ATL and tensor fascia lata fasciocutaneous (TFL) flaps. A retrospective study that analyzed 27 patients with abdominal wall defects concluded that both pedicled ATL and TFL fasciocutaneous flaps may be good options for the reconstruction of lower abdominal wall defects. A pedicled TFL fasciocutaneous flap has usually been utilized for lower abdominal defects (**Figures 23–26**) [27]. A pedicled ALT flap may be a better option for the reconstruction of a lower abdominal wall defect, and it is also available for whole abdominal wall defect restoration (**Figures 27–29**). This flap has the following advantages: it can be harvested as a musculocutaneous flap with the vastus lateralis muscle to fill a tissue defect, and the lack of a need for position change enables flap harvest [28, 29]. Regrettably, several case series showed that these useful flaps, which are harvested from the thigh, cannot reach the upper umbilical area, and the distal third of the TFL flap is at risk of necrosis unless a delaying procedure is used [5–7].

Consequently, free flap transfer has been traditionally chosen as the only suitable method to resurface a large upper abdominal defect [30]. A free musculocutaneous flap is supplied by large blood vessels that may promote the healing process in contaminated tissue [31]. This is because massive vascularized muscle transfer can be undertaken through the removal of contaminated tissue, and muscle flaps for dead-space obliteration and neovascularization are obligatory for successful management of such infected wounds [32, 33]. However, when performing free flap transfer around the contaminated area, identifying an acceptable recipient vessel is not always easy. Chronic inflammation in recipient vessels caused by infection and fibrosis may be one of the factors leading to thrombosis of an anastomosed vessel [34]. So, it is important to select a flap with a long pedicle, as a suitable recipient vessel may be distant from the wound. Abdominal muscle defects require synthetic materials or flaps for restoration to prevent hernias. The insertion of synthetic materials has been reserved for large defects of the abdominal wall, but they have demonstrated increased complication rates, especially in contaminated wounds [5, 27]. Therefore, a myocutaneous free flap is also desirable. The close continuity of the remaining rectus abdominis muscle after debridement and thick and bulky muscle in the transferred flap will prevent hernia formation [6].

Microsurgical free flap transfer may be one of the best options to repair soft tissue defects of the abdominal wall, as it can prevent a hernia and relapse of infection and supply a well-vascularized muscle and large durable skin paddle, which enable stoma fashioning on it [30].

Recently, anatomical understanding of the perforator and angiosomes has increased, allowing regional flaps to cover skin defects, providing an alternative to free flaps [35–37]. Perforator flaps are defined as flaps consisting of the skin and/or subcutaneous fat, with a blood supply from isolated perforating vessels of a stem artery [38]. This new concept highlights again that local flaps are a good option for covering a difficult area around a contaminated wound. An ideal flap is thought to be a good vascularized skin paddle with the same thickness and width as the wound and a single-stage operation [39]. The development of perforator flaps has increased the number of potential donor sites because a flap can be supplied by any musculocutaneous perforator, and donor-site morbidity can be reduced.

Perforator and fasciocutaneous rotation flaps avoid the sacrificing of the underlying muscle and are commonly used due to their advantages. Sameem M et al.

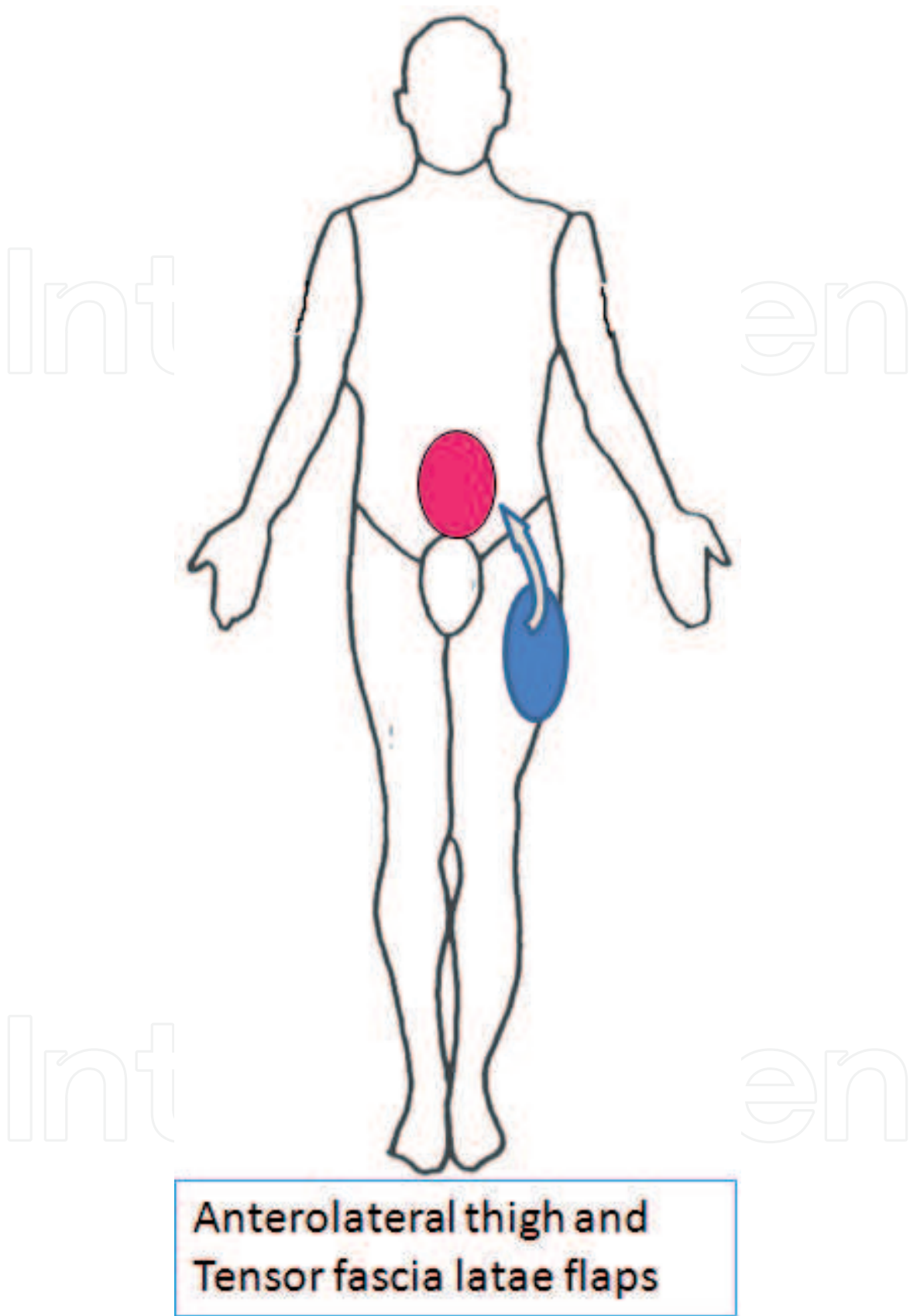


Figure 23.
Schematic illustration of lower abdominal wall repair using anterolateral thigh and tensor fascia lata flaps.

reviewed complications of musculocutaneous, fasciocutaneous, and perforator flaps for the treatment of pressure ulcers and revealed that there was no significant difference with regard to complication rates among these flaps [40]. However, comparing perforator and fasciocutaneous rotation flaps, application of the perforator

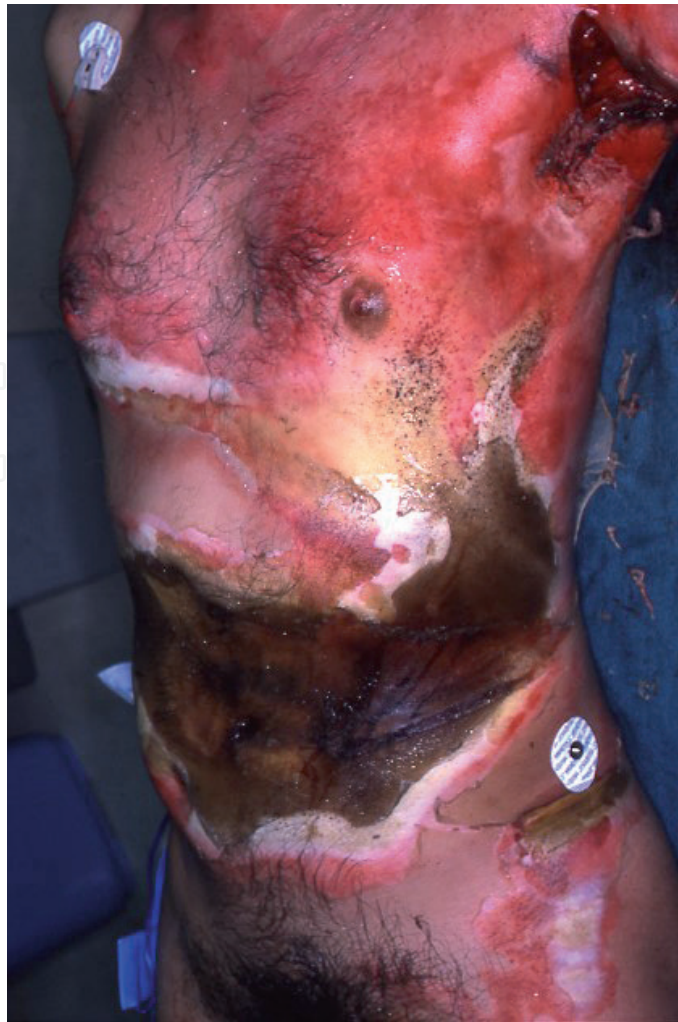

Figure 24.
A man sustained severe full-thickness abdominal burns due to contact with a large iron bowl (about 200°C) for 15 min, which was used for boiling sweet beans.

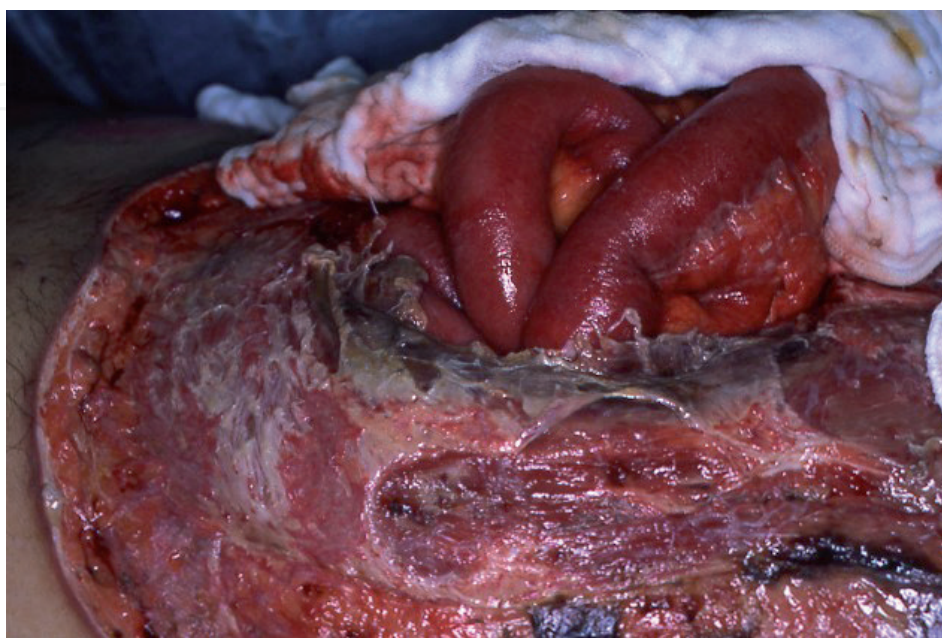


Figure 25.
The abdominal wall ruptured and the intestines were exposed due to the abdominal skin and muscle necrosis.

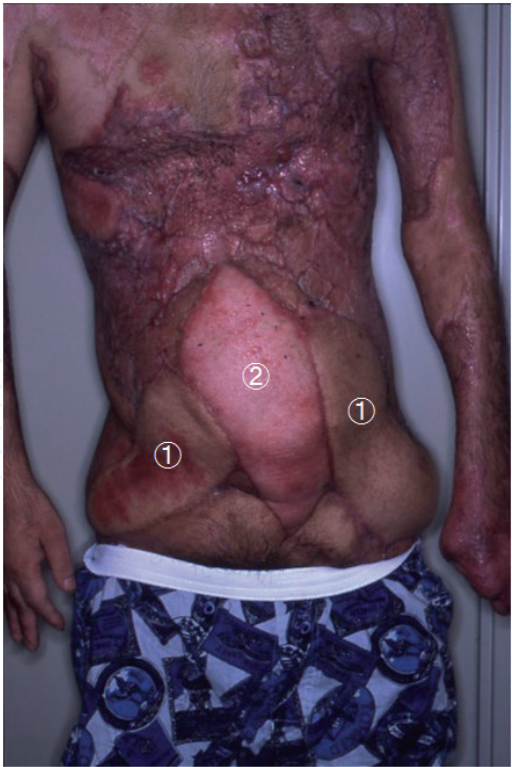

Figure 26.
View of the abdominal wall 9 months after reconstruction, using two pedicled TFL fasciocutaneous (1) and a free latissimus dorsi musculocutaneous (2) flaps.

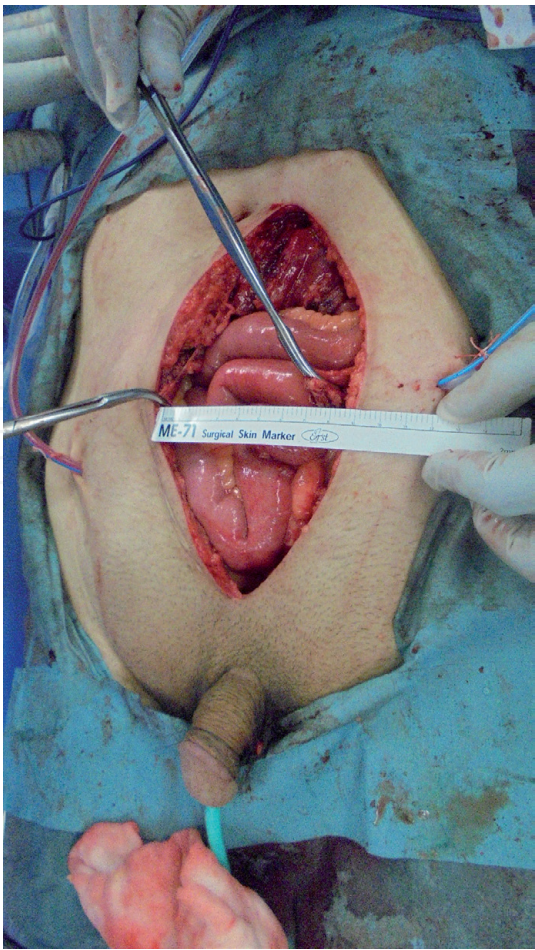


Figure 27.
Rectus abdominal muscle defect with a 9-cm width developed after debridement of contaminated muscle.

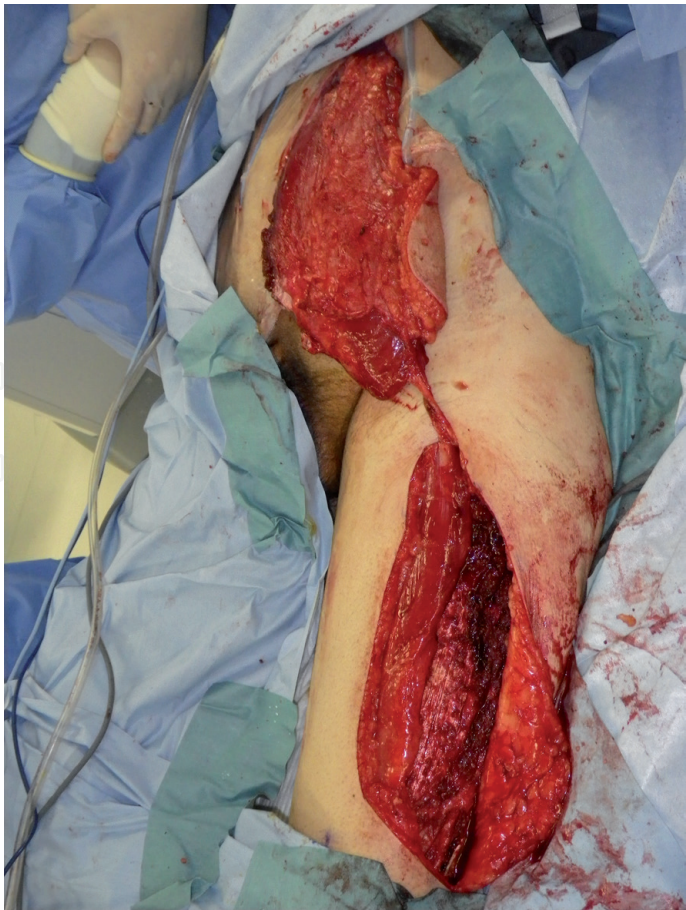

Figure 28.
A pedicled vastus lateralis-anterolateral thigh flap was elevated from the left thigh and transferred to the abdominal wall defect.

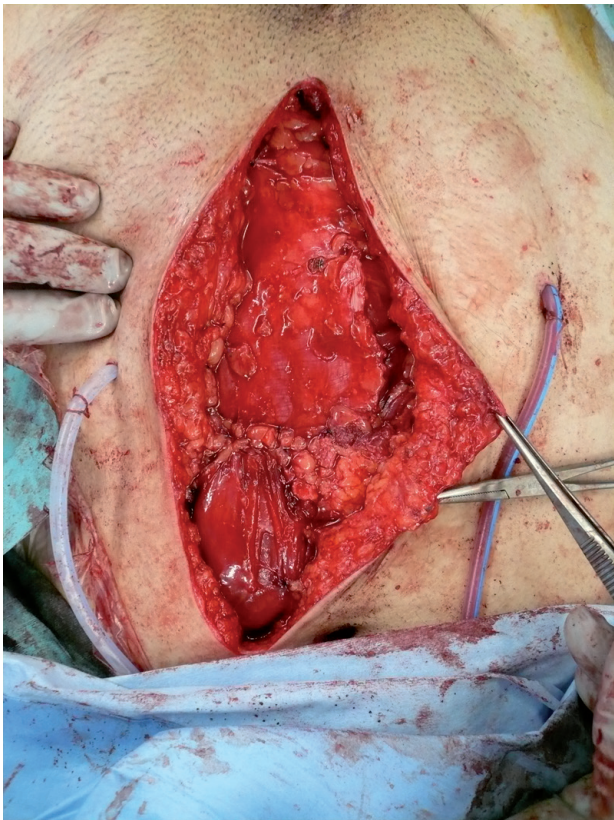


Figure 29.
The muscle flap was tunneled under the rectus femoris muscle and transferred to the muscle defect.

flap concept has many advantages. Parrett et al. revealed in a retrospective study that analyzed 290 flaps that blood circulation of the perforator flaps is supplied from isolated perforating vessels of a stem artery [38]. So, the most significant advantage of the perforator flap is that there is no need to sacrifice any main arteries, which means that there is minimal morbidity at the donor site [41, 42]. Also, microvascular anastomoses have the potential disadvantages that they require high-level surgical skill and prolong the operative period.

This new concept highlights again that local flaps could be a good option for the coverage of a difficult area of the upper abdomen, whose optimal reconstruction was previously thought to be possible with only free flap transfer.

Bilateral lower abdominal artery perforator flaps provide a well-vascularized skin paddle with an easy procedure, which does not require complicated microsurgical techniques. I believe that the use of this perforator flap is a good option to reconstruct large abdominal wall defects associated with many complications.

4. Conclusion

Reconstruction of a major abdominal wall defect in patients with a non-healing wound with infection due to continuous contamination from the ruptured ileum is challenging. The main problem is to separate the wound from draining digestive juice. A simple and the recommended method is stoma use, which requires a durable skin component in order to create a new stoma. To resolve these problems, flap transfer is required.

Conflict of interest

This manuscript has not benefited from any source of funding support or grants, and the author has no conflicting financial interest.

IntechOpen

IntechOpen

Author details

Masaki Fujioka^{1,2}

1 Department of Plastic and Reconstructive Surgery, National Hospital Organization Nagasaki Medical Center, Ohmura, Nagasaki, Japan

2 Clinical Research Center, National Hospital Organization Nagasaki Medical Center, Ohmura, Nagasaki, Japan

*Address all correspondence to: inazumahayato7@gmail.com

IntechOpen

© 2018 The Author(s). Licensee IntechOpen. This chapter is distributed under the terms of the Creative Commons Attribution License (<http://creativecommons.org/licenses/by/3.0>), which permits unrestricted use, distribution, and reproduction in any medium, provided the original work is properly cited. 

References

- [1] Whitehead A, Cataldo PA. Technical considerations in stoma creation. *Clinics in Colon and Rectal Surgery*. 2017;**30**(3):162-171
- [2] Watson MJ, Kundu N, Coppa C, Djohan R, Hashimoto K, Eghesad B, et al. Role of tissue expanders in patients with loss of abdominal domain awaiting intestinal transplantation. *Transplant International*. 2013;**26**(12):1184-1190
- [3] Delaney CP, Fazio VW. Ileostomy construction in complex reoperative surgery with associated abdominal wall defects. *American Journal of Surgery*. 2000;**180**(1):51-52
- [4] Yezhelyev MV, Deigni O, Losken A. Management of full-thickness abdominal wall defects following tumor resection. *Annals of Plastic Surgery*. 2012;**69**(2):186-191
- [5] Stone HH, Fabian TC, Turkleson ML, Jurkiewicz MJ. Management of acute full-thickness losses of abdominal wall. *Annals of Surgery*. 1981;**193**:612-618
- [6] Cederna JP, Davies BW. Total abdominal wall reconstruction. *Annals of Plastic Surgery*. 1990;**25**:65-70
- [7] Fujioka M, Miyazato O, Yamamoto T, Nishimura G. Full thickness rectus abdominis muscle defect due to the contact burn. *Burns*. 2002;**28**:391-393
- [8] Kendrick JH, Casali RE, Lang NP, Read RC. The complicated septic abdominal wound. *Archives of Surgery*. 1982;**117**(4):464-468
- [9] Ali F, Safawi EB, Zakaria Z, Basiron N. Abdominal wall reconstruction after resection of an enterocutaneous fistula with an island pedicled anterolateral thigh perforator flap. Case report. *La Clinica Terapeutica*. 2013;**164**(5):413-415
- [10] Slade DA, Carlson GL. Takedown of enter cutaneous fistula and complex abdominal wall reconstruction. *The Surgical Clinics of North America*. 2013;**93**(5):1163-1183
- [11] Meguid MM, McIvor A, Xenos L. Creation of a neoabdominal wall to facilitate emergency placement of a terminal ileostomy in a morbidly obese patient. *American Journal of Surgery*. 1997;**173**(4):298-300
- [12] Steinhagen E, Colwell J, Lisa M. Intestinal stomas—Postoperative stoma care and peristomal skin complications. *Clinics in Colon and Rectal Surgery*. 2017;**30**(3):184-192
- [13] Carlsen BT, Farmer DG, Busuttil RW, Miller TA, Rudkin GH. Incidence and management of abdominal wall defects after intestinal and multivisceral transplantation. *Plastic and Reconstructive Surgery*. 2007;**119**:1247-1255
- [14] Fazio VW. Crohn's disease. In: Keighley MRB, Pemberton JH, Fazio VW, Parc R, editors. *Atlas of Colorectal Surgery*. New York: Churchill Livingstone; 1996. pp. 61-91
- [15] Atema JJ, Furnée EJ, Maeda Y, Warusavitarne J, Tanis PJ, Bemelman WA, et al. Major complex abdominal wall repair in contaminated fields with use of a non-cross-linked biologic mesh: A dual-institutional experience. *World Journal of Surgery*. 2017;**41**(8):1993-1999
- [16] Connolly PT, Teubner A, Lees NP, Anderson ID, Scott NA, Carlson GL. Outcome of reconstructive surgery for intestinal fistula in the open abdomen. *Annals of Surgery*. 2008;**247**(3):440-444
- [17] Asham E, Uknis C, Rastellini C, Elias G, Cicalese L. Acellular dermal

matrix provides a good option for abdominal wall closure following small bowel transplantation: A case report. *Transplantation Proceedings*. 2006;**38**:1770-1771

[18] Zanfi C, Cescon M, Lauro A, et al. Incidence and management of abdominal closure-related complications in adult intestinal transplantation. *Transplantation*. 2008;**85**:1607-1609

[19] Gondolesi G, Selvaggi G, Tzakis A, et al. Use of the abdominal rectus fascia as a nonvascularized allograft for abdominal wall closure after liver, intestinal, and multivisceral transplantation. *Transplantation*. 2009;**87**:1884-1888

[20] Clifton MS, Heiss KF, Keating JJ, Mackay G, Ricketts RR. Use of tissue expanders in the repair of complex abdominal wall defects. *Journal of Pediatric Surgery*. 2011;**46**:372-377

[21] de Vries Reilingh TS, van Goor H, Rosman C, Bemelmans MH, de Jong D, van Nieuwenhoven EJ, et al. "Components separation technique" for the repair of large abdominal wall hernias. *Journal of the American College of Surgeons*. 2003;**196**(1):32

[22] Ramirez OM, Ruas E, Dellon AL. "Components separation" method for closure of abdominal-wall defects: An anatomic and clinical study. *Plastic and Reconstructive Surgery*. 1990;**86**:519-526

[23] Christy MR, Apostolides J, Rodriguez ED, Manson PN, Gens D, Scalea T. Eplasty. 2012;**12**:e17

[24] Ferreira P, Malheiro E, Choupina M, et al. Gunshot abdominal wall injury reconstructed with an innervated latissimus dorsi free flap. *The Journal of Trauma*. 2007;**63**:691-695

[25] Wong CH, Lin CH, Fu B, Fang JF. Reconstruction of complex abdominal

wall defects with free flaps: Indications and clinical outcome. *Plastic and Reconstructive Surgery*. 2009;**124**:500-509

[26] Kayano S, Sakuraba M, Miyamoto S, Nagamatsu S, Taji M, Umezawa H, et al. Comparison of pedicled and free anterolateral thigh flaps for reconstruction of complex defects of the abdominal wall: Review of 20 consecutive cases. *Journal of Plastic, Reconstructive & Aesthetic Surgery*. 2012;**65**(11):1525-1529

[27] Williams JK, Carlson GW, dsChalain T, Howel R, Coleman JJ. Role of tensor fasciae latae in abdominal wall reconstruction. *Plastic and Reconstructive Surgery*. 1998;**101**:713-718

[28] Koshima I, Fujitsu M, Ushio S, Sugiyama N, Yamashita S. Flow-through anterior thigh flaps with a short pedicle for reconstruction of lower leg and foot defects. *Plastic and Reconstructive Surgery*. 2005;**115**(1):155-162

[29] Ao M, Nagase Y, Mae O, Namba Y. Reconstruction of posttraumatic defects of the foot by flow-through anterolateral or anteromedial thigh flaps with preservation of posterior tibial vessels. *Annals of Plastic Surgery*. 1997;**38**:598-603

[30] Fujioka M, Hayashida K, Morooka S, Saijou H, Nonaka T. Combined serratus anterior and latissimus dorsi myocutaneous flap for obliteration of an irradiated pelvic exenteration defect and simultaneous site for colostomy revision. *World Journal of Surgical Oncology*. 2014;**12**(1):319-323

[31] Strawberry CW, Jacobs JS, McCraw JB. Reconstruction for cervical irradiation ulcers with myocutaneous flaps. *Head & Neck Surgery*. 1984;**6**(4):836-841

[32] Calderon W, Chang N, Mathes SJ. Comparison of the effect of bacterial

inoculation in musculocutaneous and fasciocutaneous flaps. *Plastic and Reconstructive Surgery*. 1986;**77**:785-792

[33] Russell RC, Graham DR, Feller AM, et al. Experimental evaluation of the antibiotic carrying capacity of a muscle flap into a fibrotic cavity. *Plastic and Reconstructive Surgery*. 1988;**81**:162-168

[34] Rudolph R, Arganese T, Woodward M. The ultrastructure and etiology of chronic radiotherapy damage in human skin. *Annals of Plastic Surgery*. 1982;**9**(4):282-292

[35] Schaverien M, Saint-Cyr M. Perforators of the lower leg: Analysis of perforator locations and clinical application for pedicled perforator flaps. *Plastic and Reconstructive Surgery*. 2008;**122**:161-170

[36] Taylor GI, Pan WR. Angiosomes of the leg: Anatomic study and clinical implications. *Plastic and Reconstructive Surgery*. 1998;**102**:599-616

[37] Carriquiry C, Aparecida Costa M, Vasconez LO. An anatomic study of the septocutaneous vessels of the leg. *Plastic and Reconstructive Surgery*. 1985;**76**:354-363

[38] Parrett BM, Matros E, Pribaz JJ, et al. Lower extremity trauma: Trends in the management of soft-tissue reconstruction of open tibia-fibula fractures. *Plastic and Reconstructive Surgery*. 2006;**117**:1315-1322

[39] El-Sabbagh AH. Skin perforator flaps: An algorithm for leg reconstruction. *Journal of Reconstructive Microsurgery*. 2011;**27**:511-523

[40] Sameem M, Au M, Wood T, Farrokhyar F, Mahoney J. A systematic review of complication and recurrence rates of musculocutaneous, fasciocutaneous, and perforator-based flaps for treatment of pressure sores.

Plastic and Reconstructive Surgery. 2012;**130**(1):67e-77e

[41] Ragoowansi R, Yii N, Niranjana N. Immediate vulvar and vaginal reconstruction using the gluteal-fold flap: Long-term results. *British Journal of Plastic Surgery*. 2004;**57**(5):406-410

[42] Fujioka M, Hayashida K, Murakami C. Resurfacing patella using pedicled soleus perforator flap. *Techniques in Knee Surgery*. 2012;**11**(3):147-150