

We are IntechOpen, the world's leading publisher of Open Access books Built by scientists, for scientists

6,900

Open access books available

185,000

International authors and editors

200M

Downloads

Our authors are among the

154

Countries delivered to

TOP 1%

most cited scientists

12.2%

Contributors from top 500 universities



WEB OF SCIENCE™

Selection of our books indexed in the Book Citation Index
in Web of Science™ Core Collection (BKCI)

Interested in publishing with us?
Contact book.department@intechopen.com

Numbers displayed above are based on latest data collected.
For more information visit www.intechopen.com



Robotic-assisted Laparoscopic Renal and Adrenal Surgery

Yves Caumartin, Jeffrey Warren and Patrick P.W. Luke

*London Health Sciences Centre, CSTAR, The University of Western Ontario, Schulich School of Medicine
Canada*

1. Introduction and Historical Perspective

The worldwide evolution of robotic surgery continues to advance at a staggering pace. In less than 20 years, the technology has grown exponentially from theoretical military application to daily use in operating rooms around the globe. In fact, the overwhelming success of robotic surgery with regards to invention, innovation, and adaptation is an excellent example of collaboration between surgeons, industry, and government. While the first robotic device to be used clinically dates back to computerized tomography-guided stereotactic neurosurgery by Kwoh *et al* in 1988¹, the first urological application in a human was not described until Davies *et al*² used a modified industrial robotic arm to perform a transurethral resection of the prostate three years later. The first commercial application in laparoscopy did not come until the Automated Endoscopic System for Optimal Positioning (AESOP™) was FDA approved in the United States in 1993⁷. Originally designed by the U.S. military, the table-mounted device could precisely guide a laparoscope and was later put into production by Computer Motion Inc. (Santa Barbara, California).³ Computer Motion Inc. would later introduce the ZEUS™ robotic system onto the U.S. market in 1998, just months after the unveiling of another surgical robot, the da Vinci® (Intuitive Surgical, Sunnyvale, California). The da Vinci® system was born out of technology designed by NASA, also originally intended for use by the U.S. military, but quickly adopted for civilian use. In 2003, Intuitive Surgical took over Computer Motion Inc., thereby paving the way for the da Vinci® robot, along with its newly FDA approved EndoWrist™, to dominate surgical robotic use worldwide.³ Today, the vast majority of published literature on robotic-assisted renal surgery has employed the use of the da Vinci® system, and it is the only commercially available master-slave robotic system in production today.

Few studies have addressed the comparative performance and efficiency between the three most cited robotic platforms, namely AESOP, ZEUS and da Vinci®. Sung *et al*⁴ initially looked at this question in a porcine model, and we later compared our results in a cohort of patients undergoing pyeloplasty for ureteropelvic junction obstruction (UPJO).⁵ Both groups concluded that the da Vinci® system was superior in terms of shorter operative time, quicker anastomotic time, and flatter learning curve. We also found the majority of technical manoeuvring inherently more intuitive with the da Vinci® system compared to the ZEUS system. There does exist some earlier reports of experience with the ZEUS

Source: Medical Robotics, Book edited by Vanja Bozovic, ISBN 978-3-902613-18-9, pp.526, I-Tech Education and Publishing, Vienna, Austria

Telesurgical System by ourselves⁶ and others;^{7,8} however, the vast majority of published data in recent years has focused almost exclusively on the da Vinci[®] system. And since the da Vinci[®] robot is the only master-slave robotic platform currently in production and available commercially, the focus of this chapter will center on this particular system as it applies to renal and adrenal surgical applications.

While the field of urology was not the first medical discipline to embrace robotic technology, it has adopted the technology with open arms. Through innovation and research, robotic-assisted surgery is quickly becoming a routine tool in the urologist's armamentarium. Currently, the majority of clinical indications for the da Vinci[®] system are for urological use. The majority of published research and clinical experience in the past has focused on robot-assisted radical prostatectomy.^{3,9,10} However, the role of robotics in renal surgery continues to be defined. With the exception of robot-assisted laparoscopic pyeloplasty (RALP), the majority of literary publications consist of case series and reports. As such, the emphasis of this chapter will be on RALP. For most other applications, the true role of robot-assisted renal surgery is yet to be defined. Herein we focus on the indications, techniques, and surgical experiences described in the literature to date as it applies specifically to robotic-assisted laparoscopic renal surgery.

2. Nephrectomy and Nephroureterectomy

Robot-assisted extirpative renal surgery has been described as a useful minimally invasive technique for both malignant and benign conditions. While a standard laparoscopic approach is usually employed for nephrectomy and at most centers today, robot-assisted technique are attractive to surgeons with minimal laparoscopic experience. In contrast, most surgeons facile with basic laparoscopic skills have difficulty justifying the use of robotics for what is considered by many a relatively straightforward procedure. Also, the da Vinci[®] system is not compatible with multi-fire clip appliers or standard endovascular stapling devices required for renovascular ligation and division, further discouraging routine use in the extirpative kidney surgery setting.⁹

Following induction of general anesthesia, the patient is placed in a modified 60° lateral decubitus position with the affected side elevated. Patients are placed on a clear fluid diet 48 hours before surgery and receive an oral mechanical bowel prep the day before. All pressure points are adequately padded and the patient fully secured to the operating table. Using standard laparoscopic techniques, intraperitoneal access is achieved with a 12-mm port for the laparoscope at the level of the umbilicus along the pararectus border on the affected side. Two additional trocars are placed for docking the robotic arms in a typical triangle configuration as per standard laparoscopic nephrectomy (Figure 1). A fourth port is placed at the umbilicus for the surgical assistant, to facilitate instrument exchanges, provide suction-irrigation, insert and remove suture material, and apply clips to the renal vessels¹⁰. The entire dissection is carried out robotically with the surgeon positioned at the remote console. Once the specimen is completely dissected, hemostasis is achieved with vascular staplers or clips. The specimen is removed via extension of the most inferolateral trocar site or Pfannenstiel incision after endoscopic entrapment in a bag.

A 12-mm camera port is placed just lateral to the rectus at the level of the umbilicus. Technique varies depending on surgeon preference. Additional ports are placed after pneumoperitoneum is established. Two 8-mm robotic arm ports are then positioned

equidistant (approximately 8 to 10 cm or a handwidth) from the camera port at right angles to each other. The surgical area of interest should fall in the center of the triangle created. A 12-mm assistant port is placed at the umbilicus. An extra port can be placed subxiphoid as needed (ie. for liver retraction). These recommendations may need adjustment on a case-by-case basis depending on patient body habitus and clinical scenario.

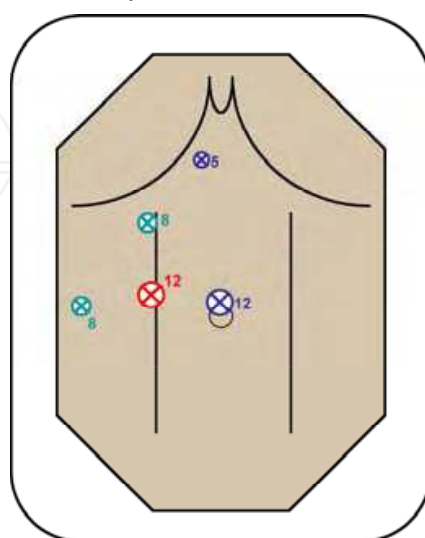


Figure 1. Recommended port placement for transperitoneal robot-assisted laparoscopic nephrectomy and adrenalectomy

While Gill *et al* was the first to report the feasibility of robotic-assisted nephrectomy in a porcine model in 2000¹¹, the first published report in a human was described by Guillonnet *et al*¹² the following year. The patient was a 77-year-old woman with a hydronephrotic non-functioning kidney secondary to ureteropelvic junction obstruction (UPJO). The ZEUS robotic surgical system was employed with total operating time of 200 minutes and blood loss of less than 100 mL. There were no peri-operative complications. Recently, Storm *et al*¹³ presented on 100 cases of robot-assisted laparoscopic nephrectomy. Sixty-six were for suspicious renal masses and non-functioning kidneys, and the remaining 34 were live donors. Median operative time was 170 minutes, estimated blood loss 100 mL, and length of hospital stay was 48 hours. Peri-operative complications occurred in five patients and included atelectasis, pancreatitis, wound infection, bowel injury, and a post-operative death. There were 2 conversions: one to hand-assisted laparoscopic nephrectomy and the other to open nephrectomy. The authors concluded robotic-assisted laparoscopic nephrectomy is safe, efficacious, and compares favorably with other minimally invasive techniques. The authors did not comment on cost.

While the need for robotic-assistance in simple and radical nephrectomy is questionable, reports employing the da Vinci® system in more complicated cases continue to be published. Recently, Finley *et al*¹⁴ described combined robot-assisted nephroureterectomy with a hand-assist port followed by robot-assisted radical prostatectomy in a 57-year-old man. Ureteric mobilization and excision of a cuff of bladder was performed robotically followed by standard robotic prostatectomy. Lastly, nephrectomy was performed using a hand-assisted laparoscopy. Total operative time 6.5 hours, blood loss was 200cc, and the post-operative course was uneventful. Nanigian *et*

*al*¹⁵ similarly describe a case series of ten patients of robotic-assisted distal ureterectomy with a cuff of bladder and pure laparoscopic nephrectomy for a case of upper tract transition cell carcinoma. These reports highlight the potential benefits of combining pure laparoscopic, hand-assisted laparoscopic, and robot-assisted laparoscopic techniques in complex cases.

Employing a retroperitoneal technique, Rose *et al*¹⁶ described robot-assisted nephroureterectomy in two patients – one for a distal ureteric urothelial tumor and the other for a poorly functioning kidney with primary obstructed megaureter. With a mean operative time of 182.5 minutes, blood loss of 75 mL, and no post-operative complications, the authors concluded this is a feasible approach in select patients.

The observation that there have been limited published series in the literature on robot-assisted laparoscopic radical or simple nephrectomy since the initial report by Guillonneau in 2001¹² underscores the tenuous role for robotics in this setting. As experience with more complex combined upper and lower tract procedures are reported in the literature, the role for robotic-assistance in these settings will become further defined.

3. Live Donor Nephrectomy

The greatest experience with extirpative robot-assisted renal surgery involves live donor nephrectomy. While some centers still consider open live donor nephrectomy the “gold standard”¹⁷, experience with laparoscopic donor nephrectomy, both purely laparoscopic and hand-assisted, continues to gain popularity. Advantages of a minimally invasive approach include less post-operative pain, shortened hospital stay, and a quicker return to regular daily activities.¹⁸⁻²⁰ Minimally invasive live donor nephrectomy is believed to have increased the donor pool by decreasing morbidity compared to open live donor nephrectomy.²¹ However, the technically demanding nature of laparoscopic live donor nephrectomy has made it an attractive candidate for robotic assistance. Docking of the robotic arms, laparoscope, and assistant port is identical to that described for nephrectomy for other indications. Special considerations include maximal preservation of renal vessel length, a Pfannenstiel extraction incision, and immediate cold flush on ice with an appropriate preservation solution.¹¹

Evidence exists that robotic-assisted live donor nephrectomy (RALDN) is safe, feasible, and with results equivalent to both open and other minimally invasive techniques. Experience from four independent series is summarized in Table 1. The first reported and most extensive series in the literature comes from the group at The University of Chicago. Horgan *et al*²² described their first 13 cases in 2002 and updated their data on 273 consecutive RALDNs using a hand-assisted technique through April 2006.²³ Their results from both donor and recipient perspectives are similar to other published live donor nephrectomy series and the authors acknowledge the evolution of their own surgical technique over time. Talimini *et al*²⁴ included their first 15 RALDNs in an early analysis of 211 robotic-assisted surgeries, noting the safety, feasibility, and quick recovery associated with the da Vinci® robotic system. Renoult and colleagues²⁵ compared their initial 13 cases of RALDN with 13 matched open donor nephrectomies. The only statistically significant differences between the groups were longer warm and cold ischemia times and longer operative times in the RALDN arm; however, the absolute differences were unlikely to be clinically significant. Nonetheless, this does highlight the fact that a learning curve still exists with robotic-assisted techniques.

Author	Year	N	Mean OR time (min)	Mean WIT (sec)	Mean LOS (days)	Allograft outcome	Complications
Horgan ²²	2002	12	166	79	1.9	No DGF	C.diff colitis in 1 pt; wound infection in 1 pt
Talamini ²⁴	2003	15	143	--	1.0	Not commented on	None
Renoult ²⁵	2006	13	185	430	5.8	POD 5 Mean ClCr = 62 mL/min	DVT in 1 pt
Horgan ²³	2007	273	150	98	2.3	Mean Cr = 1.4 mg/dL at 6 mos	Overall 9 "major"; 1 death unrelated to OR

WIT = warm ischemic time. LOS = length of stay in hospital. DGF = delayed graft function. POD = post-op day. ClCr = creatinine clearance. DVT = deep venous thrombosis

Table 1. A summary of published surgical series on robot-assisted live donor nephrectomy

4. Partial Nephrectomy

In an era when the majority of renal tumors are discovered incidentally via abdominal imaging for an unrelated indication,²⁶ these tumors are frequently amenable to nephron-sparing extirpative techniques. Patients with exophytic lesions less than 4 cm are ideal candidates for partial nephrectomy in the elective setting.²⁷ These techniques are further justified in patients with baseline compromised renal function, the potential for future renal deterioration, or a solitary kidney.^{28,29} In recent years, there has been an explosion of reports describing minimally invasive laparoscopic techniques for partial nephrectomy.³⁰⁻³⁴ However, purely laparoscopic partial nephrectomy is technically challenging, and strategies to simplify resection and reconstruction while minimizing ischemic time have been sought. Theoretically, the enhanced ability to adjust resection angles facilitate intracorporeal suturing with the EndoWrist™ instruments has made robot-assisted partial nephrectomy (RALPN) an especially attractive alternative.

To our knowledge, the first published feasibility report of RALPN was by Gettman *et al* in 2004.³⁵ Several authors have since described their technique and a number of these publications are summarized in Table 2. All authors have used the da Vinci® surgical robotic system with a transperitoneal approach. Some authors have advocated performing the initial dissection with standard laparoscopic or hand-assisted laparoscopic techniques, reserving the robot to facilitate resection of the tumor and reconstruction after hilar clamping. Use and technique of intra-operative ultrasound, intra-operative frozen sections, argon beam coagulation, and adjuvant hemostatic agents differ between reports. In Gettman’s series of 13 cases from the Mayo clinic, 8 cases employed an intra-renal artery occlusion balloon catheter for infusion of cooling solution. The authors report the

angiocatheter provided effective arterial occlusion and prevented venous backflow in all cases. However, others have questioned the cost, necessity, and invasiveness of this strategy in the absence of well-controlled prospective series looking at functional renal outcomes.³⁶

Author	Year	N	Mean lesion size (cm)	Mean OR time (min)	Hilar clamp time (min)	EBL (mL)	Mean LOS (days)	Complications
Gettman ³⁵	2004	13	3.5	215	22	170	4.3	1 post-op ileus
Stifelman ¹⁰⁵	2005	1	2.0	230	32	150	2.0	None
Phillips ³⁷	2005	12	1.8	265	26	240	2.7	2 open conversions for bleeding; 1 conversion for robot malfunction; 1 post-op urine leak
Caruso ³⁶	2006	10	1.9	279	26	240	2.6	2 conversions for bleeding, poor visualization; 1 post-op urinary retention
Kaul ³⁸	2007	10	2.0	158	21		1.5	None commented on

EBL = estimated blood loss. LOS = length of hospital stay.

Table 2. Summary of published reports of robot-assisted partial nephrectomy with the da Vinci[®] system

Phillips *et al*³⁷ described their initial experience with 12 RALPNs. They highlighted the need for conversion in 3 patients (one of each to standard laparoscopy, hand-assisted laparoscopy, and open) and summarized advantages and disadvantages of robotic assistance in this setting. Specifically, the six degrees of freedom offered by the da Vinci[®] EndoWrist[™], 3-D stereoscopic visualization, movement scale-down, negation of tremor, and console surgeon comfort were notable benefits. Purported disadvantages included cost, set-up time, equipment malfunction, need for robotic training, lack of haptic feedback, and dependence on the table-side assistant at many critical points during the procedure. Caruso *et al*³⁶, in evaluation of their first 10 RALPNs, found no convincing advantages of the robot over standard laparoscopic partial nephrectomy in experienced hands. They no longer perform RALPN at their institution, but instead emphasize the need for a randomized study in this population. Similarly, Kaul *et al*³⁸ summarized their initial 10 cases of RALPN at the Vattikuti Institute in Detroit. Their results were similar to other small series in the literature with no conversions and no positive margins. They also noted the need for larger evaluation in multi-center trials and recommended RALPN be performed by surgeons facile in advanced laparoscopy and robotics in order to minimize patient morbidity during the learning phase.

While experience with robotic-assisted renal surgery continues to expand, the exact role of RALPN has yet to be defined. Larger prospective studies with adequate follow-up are necessary to delineate whether or not a robotic approach is safe and effective compared to the “gold standard” open partial nephrectomy. We must also keep in mind that all minimally invasive surgical techniques in this setting are still considered experimental at many centers.

5. Adrenalectomy

The adrenal gland is particularly well suited for a laparoscopic surgical approach. Most adrenal lesions are small but often require a large incision for open surgical access. Since the first laparoscopic adrenalectomy by Gagner in 1992^{39,40}, a paradigm shift has taken place in favor of laparoscopic adrenalectomy versus the previous standard open approach. Similar to laparoscopic renal surgery, adrenalectomy has immeasurably improved the post-operative recovery in these patients. Objective benefits have been proven regarding shorter hospital stay, reduced pain scores, and faster return to regular activities.⁴¹⁻⁴⁵ To date, however, the robotic experience in this population is limited and the role for robotic-assisted adrenalectomy is not yet clear.

Gill *et al*¹¹ reported the first experience with robot-assisted laparoscopic adrenalectomy in a porcine model. An inferior vena cava injury was repaired via intracorporeal suturing without the need for conversion. Young *et al*⁴⁶ later performed a robotic-assisted adrenalectomy (RAA) for an incidental left adrenal mass in a patient being evaluated for a widened mediastinum. Final pathology revealed an adrenal oncocytoma. In 2002, Bantas *et al*⁴⁷ reported on four robotic-assisted transperitoneal adrenalectomies. There were no complications or conversions. Similarly, Desai *et al*⁴⁸ described their experience with two robot-assisted adrenalectomies, including one for pheochromocytoma. There were no peri-operative complications and the patients were discharged home on post-op days 2 and 3, respectively. In an interesting case report, St. Julien and colleagues⁴⁹ recently reported a robot-assisted cortical-sparing adrenalectomy in an 18-year old male with Von Hippel-Lindau disease. The patient had presented with a metachronous pheochromocytoma of his remaining solitary adrenal. There were no peri-operative complications and the patient did not require adrenal cortical replacement medication at follow-up. Lastly, Winter *et al*⁵⁰ recently published the largest series of robotic-assisted laparoscopic adrenalectomy to date. The series of 30 patients had a median operative time of 185 minutes. They reported a 7% complication rate, including one patient with a prolonged ileus post-op and a brief episode of hypoxemia on the ward in another. There were no open conversions and operative time decreased with increasing surgeon experience. Mean length of hospital stay was 2 days. According to their cost analysis, laparoscopic adrenalectomy was more economical compared to an open approach primarily because of shorter hospitalization, with only a slight difference in favor of standard laparoscopic versus robotic-assisted techniques (\$11,599 versus \$12,977, respectively).

There are two reports in the literature comparing standard laparoscopic adrenalectomy and robotic adrenalectomy. Brunaud *et al*⁵¹ evaluated their results of 14 robotic-assisted adrenalectomies with 14 standard laparoscopic adrenalectomies. They found an overall longer mean operative time in the robotic arm (111 versus 83 minutes), but a progressive decrease with increasing experience. They concluded no significant advantages to the robotic approach. However, they did highlight that an increased body mass index did not adversely affect the technique of robotic-assisted adrenalectomy, suggesting a possible benefit in larger patients. The same group reported a one-year follow-up quality of life study that did not show any difference between the two groups.⁵² Morino *et al*⁵³ reported their experience with 10 robotic-assisted adrenalectomies (two for pheochromocytoma) and compared them with 10 standard laparoscopic adrenalectomies. Operative time was significantly longer in the robotic group (mean 107 versus 82 minutes) and there were no adverse peri-operative complications. However, four of the robotic cases were converted to standard laparoscopy for technical reasons. Furthermore, cost was strongly in favor of the standard laparoscopic approach (\$2,737 versus \$3,467). Publications about RAA are summarized in Table 3.

Author	Year	Comparison	N	Median OR time (min)	Complications (%)	Conversion (%)	LOS (day)	Comments
St. Julien ⁴⁹	2006		1		0	0	NA	Partial adrenalectomy on VHL patient
Winter ⁵⁰	2006		30	185	7	0	2	RAA \$12, 997 LA \$11, 599 OA \$14, 600
Morino ⁵³	2004	LA	10	82	0	0	5.4	\$2, 737
		RAA	10	107	20	40 to LA	5.7	\$3, 467
Brunaud ⁵¹	2003	LA	14	83	21	7		Similar Q of L ⁵²
		RAA	14	111	21	7		
D’Annibale ¹⁰⁶	2004		1	110	0	0	2	
Desai ⁴⁸	2002		2	135	0	0	2.5	
Bentas. ⁴⁷	2002		4	220	0	0	5	
Young ⁴⁶	2002		1	100	0	0	1	

LA = laparoscopic adrenalectomy. RAA = robot-assisted adrenalectomy. OA = open adrenalectomy. LOS = length of stay in hospital. Q of L = quality of life. NA = non available

Table 3. Summary of published reports of robot-assisted adrenalectomy with the da Vinci® robotic system

6. Pyeloplasty

Open dismembered pyeloplasty is the gold standard treatment for adult ureteropelvic junction obstruction (UPJO) with published success rates consistently over 90%.^{54,55} However, the morbidity of an open flank incision led to experimentation with other less invasive modalities such as endopyelotomy and laparoscopic techniques. Following the first description by Schuessler *et al*⁵⁶, modern laparoscopic pyeloplasty series consistently demonstrate equivalent success rates to open series with improved postoperative convalescence.⁵⁷⁻⁶² The need for complex intracorporeal reconstruction has limited the widespread application of standard laparoscopic pyeloplasty, thereby paving the road for a robotic-assisted approach. The da Vinci® surgical robotic platform offers features that simplify intracorporeal reconstruction and suturing, thereby shortening the learning curve for residents, clinical fellows, and other novice laparoscopists alike.

Sung and colleagues^{4,63} were the first to explore the feasibility of robotic-assisted laparoscopic pyeloplasty (RALP) in pigs. Guillonneau⁶⁴ later confirmed the technical feasibility and safety of a robotic approach in an animal model. The first clinical experience in humans was reported in 2002 by Gettman *et al*,^{65,66} and provided satisfactory short-term results in a small number of patients. Since then, several other groups have reported their experience with robotic-assisted laparoscopic pyeloplasty. These reports are summarized in Tables 4 and 5.

Diagnosis of UPJO is based on clinical presentation (ie. renal colic, febrile urinary tract infection) and imaging studies. Traditional diagnostic investigations include excretory urogram, renal ultrasound, and CT, classically revealing hydronephrosis with a non-dilated ureter and no obvious cause for obstruction (ie. stone or tumor). Functional obstruction is typically confirmed by furosemide-nuclear renogram, providing information on the degree of obstruction and split renal function. It also serves as a baseline if surgical intervention is planned. In select cases, if a primary endoscopic treatment is planned, the presence of a crossing vessel can be established using CT⁶⁷, Magnetic Resonance Imaging (MRI)⁶⁸ or contrast-enhanced Doppler ultrasonography.⁶⁹⁻⁷¹

The indications for RALP are the same as standard laparoscopic or open pyeloplasty. RALP has been performed safely and effectively in patients with primary UPJO or secondary UPJO following a failed previous repair.⁷²⁻⁷⁵ RALP in pelvic and horseshoe kidneys has been reported with good results.^{72,74,76} Also, the robotic approach can be used to successfully manage concomitant renal stones at the time of the surgery.^{74,76-78} Contraindications to RALP are the same as standard laparoscopic pyeloplasty and include poor renal function, poor surgical candidate, uncorrected coagulopathy, abdominal wall infection, and bowel obstruction. The technique for RALP has been well described in a number of reports. At our center, all patients receive a full mechanical bowel preparation the day before surgery. Prophylactic antibiotics are administered 30-60 minutes before the initial incision and deep venous thrombosis prophylaxis is routinely employed based on patient risk stratification (sequential compression device or thrombo-embolic stockings +/- subcutaneous heparin).

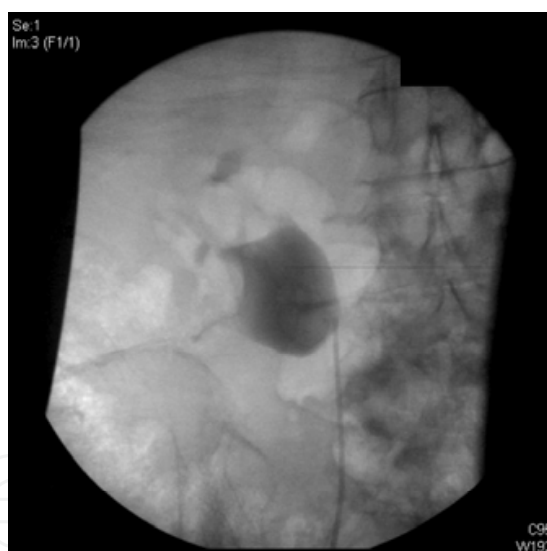


Figure 2. Pre-operative retrograde pyelogram demonstrating findings consistent with a right ureteropelvic junction obstruction

The use of an indwelling ureteral stent is recommended, but the timing and method of placement is based on surgeon preference. At our institution, after induction of general anesthesia we perform a retrograde pyelogram with the patient supine to confirm the diagnosis (Figure 2). The UPJ is localized and the overlying skin is marked for future reference and as a guide for port-placement. A double-“J” ureteral stent is then inserted under fluoroscopic guidance.^{74,79-81} A 3-way bladder catheter is inserted and connected to a 1-litre bag of sterile normal saline with methylene blue. Some authors prefer an indwelling 5-French open-ended ureteral catheter prepped in the surgical field. This can later be used

to exchange for a double-“J” stent with a guide wire under laparoscopic visualization.^{77,82,83} Finally, others prefer to insert a double-“J” stent antegrade over a guidewire through the assistant port^{72,76,84} or through a large-bore angiocath directly through the abdominal wall in a subcostal position.⁸⁵ With these latter strategies, it is recommended to confirm proper placement of the distal end of the stent intra-operatively by filling the bladder and observing for reflux laparoscopically. Alternatively, cystoscopy can be performed intra-operatively or placement confirmed with a single abdominal film in the recovery room. Once the double-“J” stent placement is confirmed, the patient is placed and secured in a modified 60° lateral decubitus position with a beanbag and tape. We do not routinely flex the table and we ensure that all pressure points are padded appropriately. An orogastric tube is useful to decompress the stomach and increase the working spaces for left-sided procedures. Figure 3 give an overview of the operating room setup. Pneumoperitoneum is achieved with a Veress needle or Hasson trochar and the initial 12-mm port is placed at the umbilicus. Most authors use this port for the laparoscope. Two additional 8-mm robotic arm ports are then placed so as to form an isosceles triangle with the base facing laterally (Figure 4). Depending on surgeon preference, a 12-mm assistant-port is placed either subxyphoid, inferior to the camera port, or just caudal to McBurney’s point on the ipsilateral side. This port can be used for suction-irrigation, to help with retraction, introducing and removing suturing material, and placement of a double-“J” stent. Nephroscopy and basket stone extraction can also be performed through this port as needed. Some authors, especially in the pediatric setting, use only 3 ports altogether.^{74,85,86}

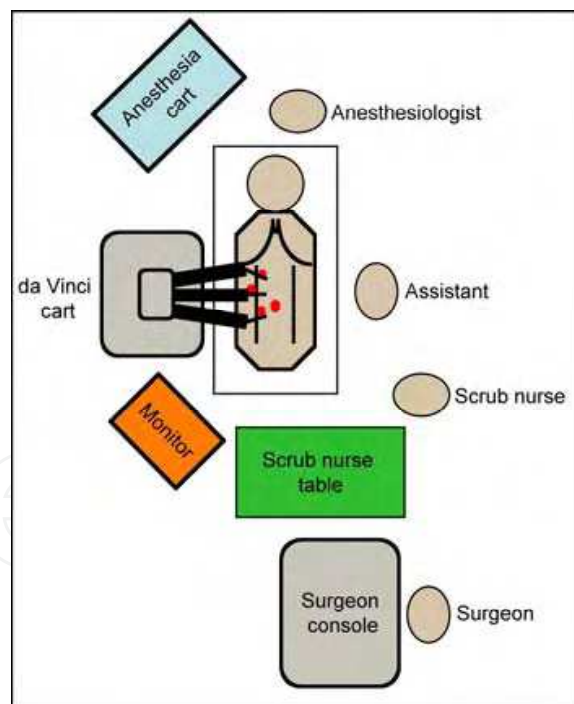


Figure 3. Operating room setup for robotic-assisted laparoscopic pyeloplasty

The patient is placed in a 60° lateral decubitus position. After port placement, the da Vinci[®] system is positioned over the patient’s ipsilateral flank. The primary surgeon is seated at the remote surgical console. The surgical assistant is situated on the contralateral side across from the robot. A scrub nurse is near the foot of the bed. A monitor is positioned in view of the surgical assistant and scrub nurse. The anesthesiologist is at the head of the table.

A 12-mm camera port is placed at the umbilicus. Two robotic arm ports are then placed to create a triangle with the base facing laterally. A 12-mm assistant port can be placed as per surgeon preference -- subxyphoid, just medial to the camera port, or caudally in the vicinity of McBurney's point.

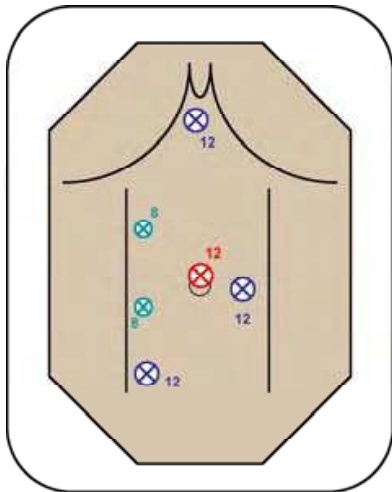


Figure 4. Port placement for transperitoneal robot-assisted laparoscopic pyeloplasty, as usually described in the literature

Our own technique is a somewhat different. We use a 12-mm umbilical port for the assistant. The laparoscope is placed at the skin marker previously set during retrograde pyelography. This point usually lies along the anterior axillary line. We then place two additional 8-mm robotic arm ports to create an isosceles triangle with the base facing medially (Figure 5). We feel this technique allows more freedom for the assistant to maneuver. The subxyphoid position is often constrained by the patient's arm and a too-medial position often is restricting due to nearby loops of bowel.

A 12-mm port is inserted at the umbilicus as described by Hassan and pneumoperitoneum is established. This serves as the assistant's. A second 12-mm camera port is placed lateral at the estimated location of the UPJ. Lastly, two robotic arm ports are placed medial to camera port so as to create a triangle with the base facing medially.

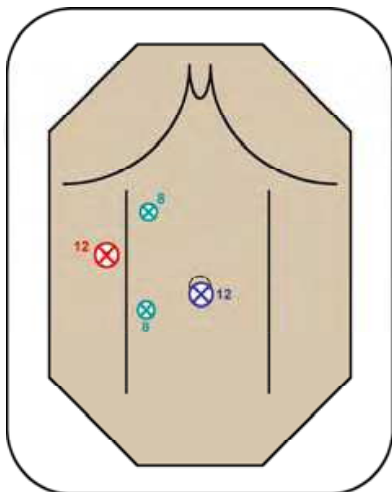


Figure 5. Port placement for transperitoneal robot-assisted laparoscopic pyeloplasty as per Luke's modification

Using the da Vinci® platform, all steps of traditional Anderson-Hynes dismembered pyeloplasty, Y-V plasty and Fenger-plasty can be performed.^{65,72,74,77,87} We usually employ a dismembered technique as we believe this provides the best results in open and standard laparoscopic pyeloplasty. It also allows versatility in almost all clinical scenarios, including crossing vessels, renal calculi, a large pelvis that needs to be reduced, and secondary repairs.⁸⁸ A standard set of laparoscopic instruments is required in addition to the robotic ones, namely monopolar hook cautery, forceps, needle drivers and scissors.

Some authors described a hybrid approach whereby the initial dissection of the colon, renal pelvis and proximal ureter is performed using standard laparoscopic techniques, reserving the robot for the ureteropelvic anastomosis.^{74,77,83,84,89} We routinely perform the entire procedure robotically to minimize operative time changing and exchanging instruments. The robot is positioned on the ipsilateral side of the patient, angled over their exposed flank and the three robotic arms are engaged with the working ports and the camera port (Figure 6). For right-sided UPJO, the line of Toldt is incised and the hepatic flexure is retracted medially to identify Gerota's fascia. For left-sided UPJO, the standard approach similarly involves incision of the line of Toldt and medial mobilization of the descending colon to expose Gerota's fascia. In thin or pediatric patients with left-sided UPJO, an alternative transmesenteric approach has been described.^{72,74,85,86,90} The ureter is identified distally and followed cephalad to the UPJ. The UPJ itself and any associated crossing vessels are then dissected free. If renal calculi are present,^{74,76-78} a small pyelotomy incision is made at the UPJ and flexible nephroscopy and stone extraction are performed through the assistant port. Stones are removed via basket extraction or placed in an extraction bag, depending on size and number. Next, the UPJ is transected, the stenotic segment is excised, and the ureteral end is spatulated laterally. The proximal end of the stent is removed from the renal pelvis and, if necessary, the pelvis is reduced by a diamond-shape excision. If an anterior crossing vessel is present, the renal pelvis is transposed anterior to the vessel and the posterior aspect of the anastomosis is performed with a running 5-0 polydioxanone suture, cut to 15 cm in length. The proximal end of the stent is then replaced into the renal pelvis. The anterior wall of the anastomosis is completed with a second running suture. Occasionally there is some redundancy of the proximal renal pelvis necessitating a third running suture for adequate closure. We then fill the bladder with the methylene blue saline solution to assess for reflux and ensure the anastomosis is watertight. Any obvious leak is corrected with additional suture. Once hemostasis is achieved and confirmed at low insufflation pressure, a 7-mm Jackson-Pratt close-suction drain is inserted through one of the 8-mm ports once the robot is undocked. The fascia of the 12-mm ports and skin are re-approximated as per surgeon preference.

Postoperative management is usually uneventful. The bladder catheter is removed in 1-2 days. The close-suction drain is then removed if there is no significant increase in output with spontaneous voiding. Patients are discharged home on post-operative day 1 or 2 pending no complications. We typically remove the ureteral stent 4 weeks post-op. A follow-up furosemide-nuclear renogram is performed at approximately 10 weeks and 6 months post-operatively. Follow-up ultrasound is obtained in pediatric patients, reserving a renogram for select cases or surgeon preference. Some authors prefer repeat

imaging on an annual basis. In the context of normal post-operative imaging and no symptoms we usually stop follow-up at 6 months, recognizing that late recurrence in this setting is rare.⁶¹

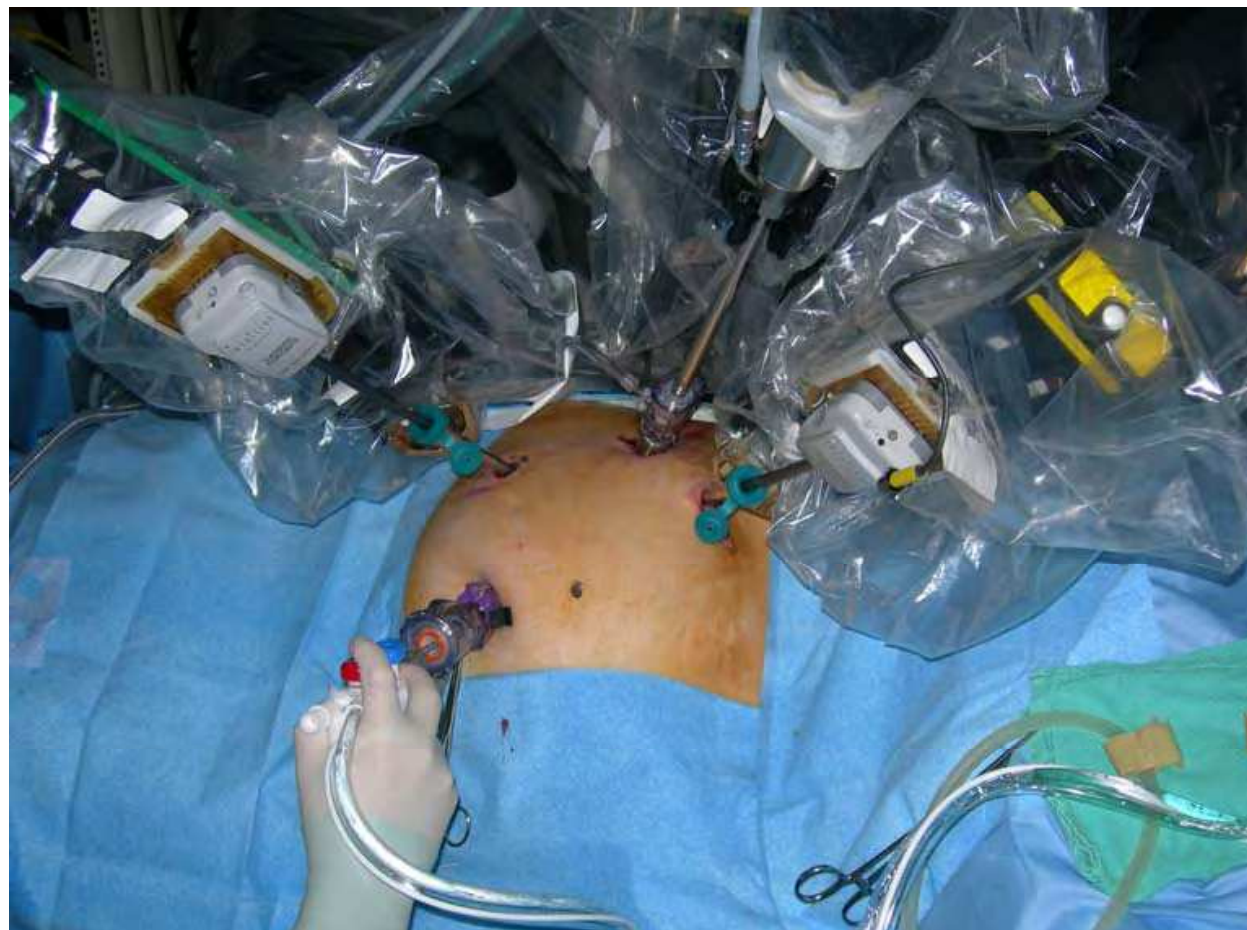

Figure 6. Port placement and robot docking position for a patient undergoing a right robotic pyeloplasty

There is an expanding body of literature on RALP, a summary of which is presented in Table 4. Comparative studies between RALP and open or standard laparoscopic pyeloplasty are summarized in Table 5. Schwentner *et al*⁷² reported on the largest series of RALP with a relatively long median follow up of 39 months. All 92 patients underwent Anderson-Hynes dismembered RALP. Twelve patients had secondary UPJO and 2 patients had a horseshoe kidney. There were no intra-operative complications and no open conversion. Anterior crossing vessels were found in 45 patients (49%). The mean operative time was 108 minutes, including time to dock and undock the robot. As similarly reported by many other authors,^{72,74,77,84,87,90,91} their operative time decreased significantly with increased experience of the surgical team and the technical staff. The mean anastomotic time was only 25 minutes and the average blood loss was less than 50 ml. There were three notable post-operative complications: one patient developed clot colic requiring stent exchange and percutaneous nephrostomy; another patient bled into the collecting system that was managed non-operatively; and one patient developed a prolonged urine leak managed conservatively. The mean hospital stay was 4.6 days and the overall success rate was 96.7%.

Mean age (years)	Crossing vessel (%)	Secondary UPJO (%)	Associated calculi (%)	Horseshoe or pelvic kidney (%)	OR time (min)	Suturing time (min)	Blood loss (ml)	Complications (%)	LOS (days)	Success (%)
NA	NA	22	NA	NA	139	62	< 50	11 (leak requiring reintervention)	4.7	100
NA	36	0	NA	NA	197	NA	50	0	5.5	100
73	100	0	0	0	300	45	150	0	4	NA
NA	NA	19	NA	NA	124	NA	50	2 (leak requiring open repair)	NA	100
39.5	25	NA	100	NA	275	54	48	0	1.1	100
12	43	0	NA	NA	184	40	31	0	1.2	100
31.2	44	9	23	NA	300	NA	50	6 (1 UTI, 1 stent migration)	1.1	94.4
39.3	26	5	5	2.5	226	64	77	10.5 (3 UTI, 1 gluteal compartment syndrome)	2.9	94.7
31	30	10	NA	NA	122	20	40	0	1.1	100
34.5	42	15	23	4	245	47	69	11 (1 UTI, 1 leak, 1 hernia)	2	95
33.6	41	16	NA	NA	229 (primary UPJO 219 vs secondary UPJO 280)	NA	50	0	1.1	100
44.6	0	0	66	100	148	NA	<100	33 (1 UTI)	7.6	100
5.6 months	0	0	NA	NA	123	60	NA	0	1.4	100
35.1	49	13	NA	2	108	25	<50	3 (1 leak, 1 hemorrhage, 1 clots in urine)	4.6	96.7

UPJO = ureteropelvic junction obstruction. LOS = length of stay in hospital. UTI = urinary tract infection. NA = non available

Table 4. Summary of published reports of robot-assisted pyeloplasty with the da Vinci® system

Author	Gettman ⁶⁵				Bernie ⁸¹		Lee ⁸⁶		Link ⁸⁰		Weise ⁸²		Yee ⁷⁵	
Year	2002				2005		2006		2006		2006		2006	
Comparison	LP		RALP		LP	RALP	OP	RALP	LP	RALP	LP	RALP	OP	RALP
Surgical technique	DM	FP	DM	FP	DM	DM	DM	DM	DM	DM	Combined	Combined	DM	DM
N	4	2	4	2	7	7	33	33	10	10	14	31	8	8
Mean f-up (months)	NA	NA	NA	NA	24	10	20	10	NA	NA	10	6	53.2	14.7
Mean age (years)	NA	NA	NA	NA	34	32	7.6	7.8	38	46.5	24.5	26	9.8	11.5
Crossing vessel (%)	NA	NA	NA	NA	86	57	45	33	NA	NA	50	74	NA	NA
Secondary UPJO (%)	NA	NA	NA	NA	0	0	0	0	0	0	7	0	0	12.5
OR time (min)	235	100	140	78	312	324	181	219	81	123	299	271	248	363
Suturing time (min)	120	28	70	13	NA	NA	NA	NA	NA	NA	NA	60	NA	NA
Blood loss (ml)	50		50		40	60	15	3	NA	NA	<100	<100	59	13
Complications (%)	0	0	0	0	28 (2 leak)	14 (1 UTI)	0	3 (1 missed crossing vessel)	0	10 (1 leak)	14 (1 port hernia, 1 hematoma)	6 (1 leak, 1 UTI)	0	12.5 (1 ileus)
LOS (days)	4		4		3	2.5	3.5	2.3	NA	NA	2.6	2.1	3.3	2.4
Success (%)	NA		NA		100	100	100	94	100	100	100	97	86	100
Cost									RALP 2.7X the cost of LP. 1.7X if they excluded robot depreciation					

DM = dismembered. FP = Fenger-plasty. UPJO = ureteropelvic junction obstruction. LOS = length of stay in hospital. UTI = urinary tract infection. LP = laparoscopic pyeloplasty. RALP = robot-assisted laparoscopic pyeloplasty. OP = open pyeloplasty. LOS = length of stay in hospital. Q of L = quality of life. NA = non available

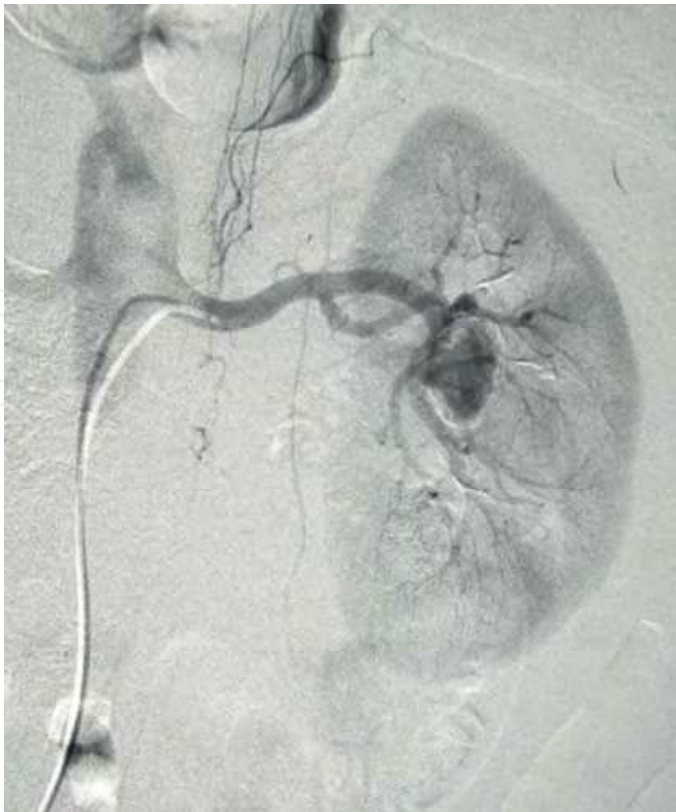Table 5. Summary of published reports comparing robot-assisted pyeloplasty with the da Vinci® system to standard laparoscopic pyeloplasty or open pyeloplasty

Patel *et al*⁸⁷ published a series of 50 patients with a median follow up of 11.7 months. There were no post-op complications and most patients went home on post-operative day one. Ninety-six percent had both objective and subjective improvement. As shown in Table 4 and in a recent publication by Shah and colleagues,⁷⁹ most series report operative times between 108 to 300 minutes and estimated blood loss from 30 to 100 ml. Complications ranged from 0 to 11% and include urine leak, urinary tract infection, stent migration, port site hernias, hemorrhage and hematoma. One group⁹² reported a gluteal compartment syndrome in an obese patient following a long procedure at the beginning of their experience. Another group⁸⁶ reported missing a crossing vessel during a retroperitoneal RALP in a child. A second transperitoneal RALP was performed successfully. Most authors considered subjective improvement in symptoms and improved drainage on furosemide-nuclear renogram as markers for success. Reported success rates vary from 94 to 100%. Subgroup analysis by some authors reported comparable results for high-risk patients including secondary UPJO, UPJO in a horseshoe kidney, concomitant pelvicalyceal calculi, and infants less than 3 months old.^{75,83,85,86,93} In an interesting case report Yee and colleagues described a robot-assisted reconstruction of a post-traumatic urteropelvic junction disruption. The procedure was performed one month after the injury with a satisfactory result.⁹⁴ Based on these and other publications directly comparing RALP with open or standard laparoscopic pyeloplasty, we conclude that the robotic approach appears safe and effective (see Table 5). Intermediate-term results are slowly accumulating in the literature and compare favorably with open pyeloplasty results. Unfortunately, as with other applications of robotic-assisted surgery, the biggest drawback and criticism centers on the purported lack of cost-effectiveness compared to other less expensive modalities.^{80,95-97}

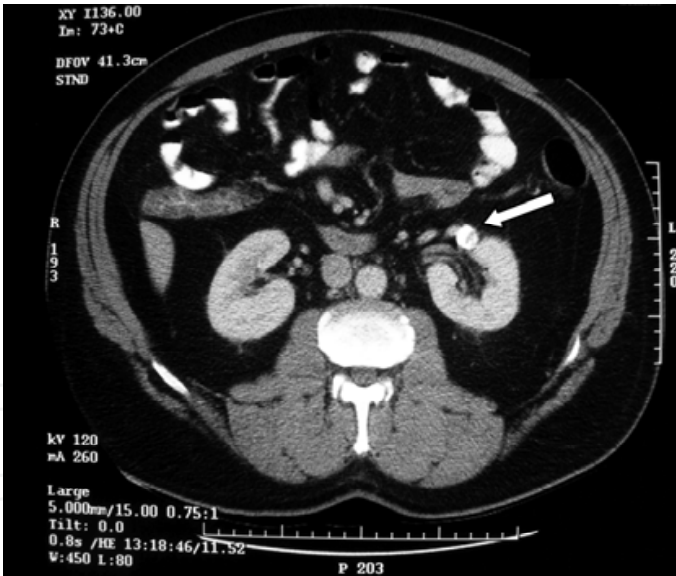
7. Other Applications of Robotic-assisted Renal Surgery

There are numerous case reports and a few case series in the literature describing novel and innovative applications of surgical robots. A few examples of these applications have been described specifically pertaining to renal surgery.

Luke *et al*⁹⁸ described a technique of robotic-assisted renal artery aneurysm resection and reconstruction using the da Vinci[®] system. The patient was a 54-year-old male with a serially expanding 2.5-cm incompletely calcified saccular renal artery aneurysm on the left side (Figure 7). Using a 5-trochar technique, the entire dissection, resection and end-end anastomotic reconstruction was carried out robotically (Figure 8). A saphenous vein interposition graft was harvested but not needed during the reconstruction. Total operative time was 360 minutes, warm ischemic time was 59 minutes, and arterial anastomotic time was 10.5 minutes. The estimated blood loss was 650 mL and the post-operative course was uneventful. At 2 months follow-up split renal function on renal scan was 55:45 for right and left, respectively. Follow-up CT-scan performed two years after surgery showed complete absence of aneurysmal dilatation and prompt, complete uptake of contrast by the kidney (Figure 9).

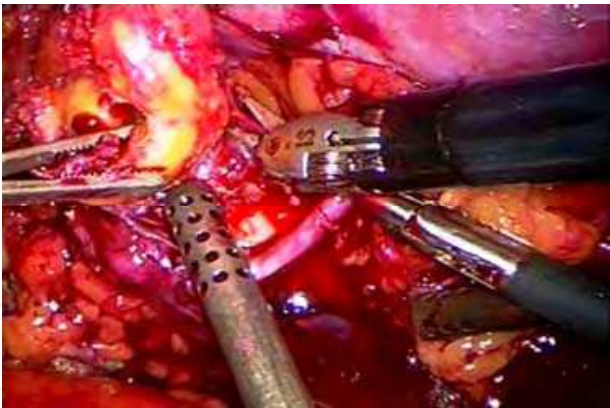


a)

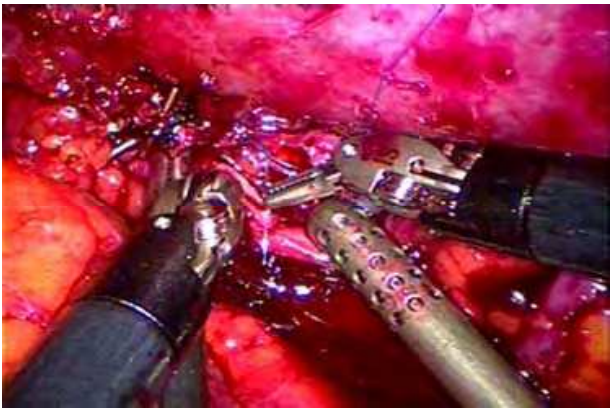


b)

Figure 7. a) Preoperative renal angiography demonstrates a calcified 2.5 cm left-sided saccular aneurysm. b) Preoperative abdominal CT scan shows the hilar location of the renal aneurysm (white arrow)



a)



b)

Figure 8. a) Videoscopic view of the renal artery aneurysm during its excision with the laparoscopic scissors. b) Videoscopic view during robotic-assisted reconstruction of the anterior wall of the renal artery

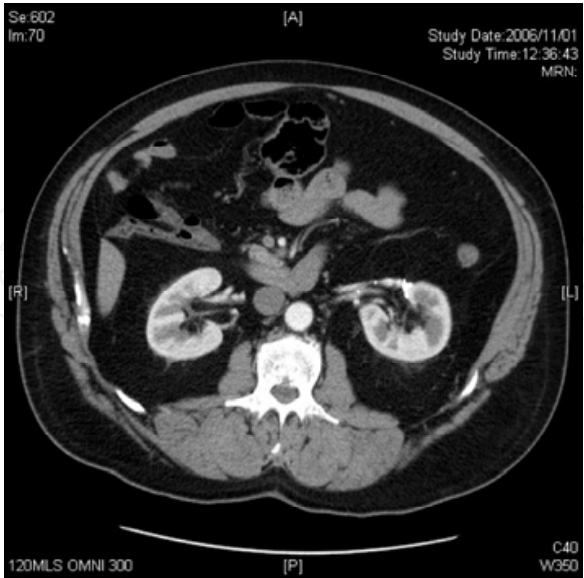


Figure 9. Follow-up abdominal CT scan performed 30 months postoperatively, confirming resolution of the aneurysm and prompt arterial flow to the left kidney

Hoznek *et al*⁹⁹ have described a robotic-assisted kidney transplant. The recipient was 26-year-old male with end-stage renal disease secondary to focal segmental glomerulosclerosis and a prior rejected transplant. The allograft was a right kidney with inferior vena cava reconstruction from a heart-beating cadaveric donor. The surgical assistant made a left lower quadrant Gibson incision, developed the retroperitoneal working space, positioned the retractor, provided cautery hemostasis, and placed vascular clamps. The external iliac arterial and venous dissections and the vascular anastomoses were performed entirely by the console surgeon. A Lich-Gregoir ureteroneocystostomy was also performed robotically. Cold ischemia time was over 26 hours, operative time was 178 minutes, and anastomotic time was 57 minutes. Delayed graft function secondary to acute tubular necrosis resolved after one week and there was satisfactory graft function at two months.

Orvieto *et al*¹⁰⁰ described robotic-assisted reconstruction of a strictured transplant ureter. The patient was a 35-year-old recipient of a combined kidney-pancreas transplant. An extensive allograft ureteric stricture was diagnosed following recurrent urinary tract infections and an episode of urosepsis. The da Vinci[®] robot was employed for pyeloureterostomy from the allograft renal pelvis to the native ureter. The initial right lower quadrant dissection was performed with the Harmonic Scalpel[®] (Ethicon Endo-Surgery Inc.) and standard laparoscopic techniques. Total operative time was 320 minutes, estimated blood loss was 20 mL, and the patient was discharged home on post-operative day 4. Allograft function remained stable, radiographic resolution of obstruction was documented, and there were no recurrent episodes of infection at 12-month follow-up. The authors concluded that robotic assistance allowed for efficient complex reconstruction without sacrificing the benefits of a minimally invasive approach.

The above case reports highlight the potential role for robotic-assisted surgery in complex renal reconstructive procedures. And while certainly none of these techniques will become routine practice in the foreseeable future, pushing the boundaries of current technology will undoubtedly help form the basis for future innovation. Furthermore, exercises such as these will help define the collaborative role of open, laparoscopic, and robotic surgery in the future.

8. Future Considerations

Robotic surgery is still in its infancy. The fields of urology, cardiac surgery, neurosurgery, orthopedics, and fetal surgery have already embraced this new technology with the ambition of advancing medical frontiers and application. The goal of applied surgical robotics is improved patient care. Through active clinical and laboratory experimentation, applications specific to robotic renal surgery will hopefully advance in parallel with other disciplines.

Future invention and innovation with regards to surgical robotic technology currently evolves around a number of spheres. At the forefront is improved visualization technology in the form of augmented reality and image guided surgery. Enhanced real-time imaging has been proposed for the next generation surgical robot.¹⁰¹ Robotic ultrasound and acoustic holography may soon provide real-time imaging that can predict normal from abnormal tissues intraoperatively. Robotic-enhanced haptic and temperature sensors may someday solve the problem of lack of haptic feedback with current surgical robots, and will likely mimic human tactile feeling with greater sensitivity and precision.¹⁰² Diagnostic sensors engaged on robotic arms may preclude the need for biopsy and pathological

analysis to detect cancer. Lastly, collaboration between nanotechnology and microbiology may someday permit “DNA-assembly robots” to perform “surgery” on the molecular level analogous to the console surgeon with the da Vinci[®] system today. A detailed synopsis on the future of robotic surgical technology is beyond the scope of this chapter.¹⁰²

The current status of any new or developed discipline can quickly be gleaned from the number of students trying to learn it. The interest in acquiring laparoscopic skills, in general, and robotic skills, in particular, is evidenced by dramatic shifts in residency training programs. In a survey of American and Canadian urology residents on laparoscopic and robotic surgery, 54% of respondents reported robotic surgery was being performed at their center. Twenty-two percent of resident respondents had been trained in robotic surgery and 34% anticipated performing robotic surgery upon completion of residency. Questions in the survey addressed both robotic prostatectomy and pyeloplasty.¹⁰³ In contrast, results of a similar survey of residents and practicing urologists published just two years prior did not even address robotic surgery.¹⁰⁴ This observation highlights the shift in attitudes towards robotic surgery in urology in contemporary times.

Although the future role of robotics in renal surgery is still unclear, robotic-assisted surgery in urology as it pertains to prostatectomy appears here to stay. As a niche for robotic-assisted pyeloplasty and partial nephrectomy continues to be carved out, interest in radical extirpative renal surgery appears to have waned in recent years. And while there may be a role for robotic-assistance in complicated renal reconstructive procedures, this role has yet to be defined and for the time being consists solely of enlightening case reports. Nonetheless, these are interesting times in the collaborative fields of both urology and robotics, and the next decade of research and exploration will likely clarify some of these issues as robotic technology continues to mature. Hopefully, through further education, technological advancement and commercial competition, surgical robotics will become more accessible to the majority of practicing urologists and their patients in the near future.

9. References

- Kwoh YS, Hou J, Jonckheere EA and Hayati S: A robot with improved absolute positioning accuracy for CT guided stereotactic brain surgery. *IEEE Trans Biomed Eng.* 35: 153-60, 1988.[1]
- Davies BL, Hibberd RD, Ng WS, Timoney AG and Wickham JE: The development of a surgeon robot for prostatectomies. *Proc Inst Mech Eng [H].* 205: 35-8, 1991. [2]
- Eichel L: Robotics in urologic surgery: risks and benefits: *AUA Update Series*, 2005, vol. 24, pp 106-112. [3]
- Sung GT and Gill IS: Robotic laparoscopic surgery: a comparison of the DA Vinci and Zeus systems. *Urology.* 58: 893-8, 2001. [4]
- Nguan C, Kwan K, Al Omar M, Beasley KA and Luke PP: Robotic pyeloplasty: experience with three robotic platforms. *Can J Urol.* 14: 3571-6, 2007. [5]
- Luke PP, Girvan AR, Al Omar M, Beasley KA and Carson M: Laparoscopic robotic pyeloplasty using the Zeus Telesurgical System. *Can J Urol.* 11: 2396-400, 2004. [6]
- Miyake O, Kiuchi H, Yoshimura K and Okuyama A: Urological robotic surgery: preliminary experience with the Zeus system. *Int J Urol.* 12: 928-32, 2005.[7]
- Lorincz A, Knight CG, Kant AJ, Langenburg SE, Rabah R, Gidell K, Dawe E, Klein MD and McLorie G: Totally minimally invasive robot-assisted unstented pyeloplasty using the Zeus Microwrist Surgical System: an animal study. *J Pediatr Surg.* 40: 418-22, 2005. [8]

- Kaul S and Menon M: Robotics in laparoscopic urology. *Minim Invasive Ther Allied Technol.* 14: 62-70, 2005. [9]
- Hoznek A, Hubert J, Antiphon P, Gettman MT, Hemal AK and Abbou CC: Robotic renal surgery. *Urol Clin North Am.* 31: 731-6, 2004. [10]
- Gill IS, Sung GT, Hsu TH and Meraney AM: Robotic remote laparoscopic nephrectomy and adrenalectomy: the initial experience. *J Urol.* 164: 2082-5, 2000. [11]
- Guillonneau B, Jayet C, Tewari A and Vallancien G: Robot assisted laparoscopic nephrectomy. *J Urol.* 166: 200-1, 2001. [12]
- Storm D, Fulmer B, Danella J, Sumfest J and Rukstalis D: Robotic-assisted laparoscopic nephrectomy: experience with 100 cases. Abst.#697. *The Journal of Urology.* 177: 234, 2007. [13]
- Finley DS, Melamud O and Ornstein DK: Combined robot-assisted laparoscopic nephroureterectomy and radical prostatectomy. *J Endourol.* 21: 411-4, 2007. [14]
- Nanigian DK, Smith W and Ellison LM: Robot-assisted laparoscopic nephroureterectomy. *J Endourol.* 20: 463-5; discussion 465-6, 2006. [15]
- Rose K, Khan S, Godbole H, Olsburgh J and Dasgupta P: Robotic assisted retroperitoneoscopic nephroureterectomy -- first experience and the hybrid port technique. *Int J Clin Pract.* 60: 12-4, 2006. [16]
- Najarian JS, Chavers BM, McHugh LE and Matas AJ: 20 years or more of follow-up of living kidney donors. *Lancet.* 340: 807-10, 1992. [17]
- Tooher RL, Rao MM, Scott DF, Wall DR, Francis DM, Bridgewater FH and Maddern GJ: A systematic review of laparoscopic live-donor nephrectomy. *Transplantation.* 78: 404-14, 2004. [18]
- Novotny MJ: Laparoscopic live donor nephrectomy. *Urol Clin North Am.* 28: 127-35, 2001. [19]
- Leventhal JR, Deeik RK, Joehl RJ, Rege RV, Herman CH, Fryer JP, Kaufman D, Abecassis M and Stuart FP: Laparoscopic live donor nephrectomy--is it safe? *Transplantation.* 70: 602-6, 2000. [20]
- Lee BR, Chow GK, Ratner LE and Kavoussi LR: Laparoscopic live donor nephrectomy: outcomes equivalent to open surgery. *J Endourol.* 14: 811-9; discussion 819-20, 2000. [21]
- Horgan S, Vanuno D, Sileri P, Cicalese L and Benedetti E: Robotic-assisted laparoscopic donor nephrectomy for kidney transplantation. *Transplantation.* 73: 1474-9, 2002. [22]
- Horgan S, Galvani C, Gorodner MV, Jacobsen GR, Moser F, Manzelli A, Oberholzer J, Fisichella MP, Bogetti D, Testa G, Sankary HN and Benedetti E: Effect of robotic assistance on the "learning curve" for laparoscopic hand-assisted donor nephrectomy. *Surg Endosc.* 2007. [23]
- Talamini MA, Chapman S, Horgan S and Melvin WS: A prospective analysis of 211 robotic-assisted surgical procedures. *Surg Endosc.* 17: 1521-4, 2003. [24]
- Renoult E, Hubert J, Ladriere M, Billaut N, Mourey E, Feuillu B and Kessler M: Robot-assisted laparoscopic and open live-donor nephrectomy: a comparison of donor morbidity and early renal allograft outcomes. *Nephrol Dial Transplant.* 21: 472-7, 2006. [25]
- Pantuck AJ, Zisman A, Rauch MK and Belldegrun A: Incidental renal tumors. *Urology.* 56: 190-6, 2000. [26]

- Herr HW: Partial nephrectomy for unilateral renal carcinoma and a normal contralateral kidney: 10-year followup. *J Urol.* 161: 33-4; discussion 34-5, 1999. [27]
- Lau WK, Blute ML, Weaver AL, Torres VE and Zincke H: Matched comparison of radical nephrectomy vs nephron-sparing surgery in patients with unilateral renal cell carcinoma and a normal contralateral kidney. *Mayo Clin Proc.* 75: 1236-42, 2000. [28]
- Fergany AF, Hafez KS and Novick AC: Long-term results of nephron sparing surgery for localized renal cell carcinoma: 10-year followup. *J Urol.* 163: 442-5, 2000. [29]
- Beasley KA, Al Omar M, Shaikh A, Bochinski D, Khakhar A, Izawa JI, Welch RO, Chin JL, Kapoor A and Luke PP: Laparoscopic versus open partial nephrectomy. *Urology.* 64: 458-61, 2004. [30]
- Simon SD, Ferrigni RG, Novicki DE, Lamm DL, Swanson SS and Andrews PE: Mayo Clinic Scottsdale experience with laparoscopic nephron sparing surgery for renal tumors. *J Urol.* 169: 2059-62, 2003. [31]
- Ogan K and Cadeddu JA: Minimally invasive management of the small renal tumor: review of laparoscopic partial nephrectomy and ablative techniques. *J Endourol.* 16: 635-43, 2002. [32]
- Haber GP and Gill IS: Laparoscopic partial nephrectomy: contemporary technique and outcomes. *Eur Urol.* 49: 660-5, 2006. [33]
- Guillonneau B, Bermudez H, Gholami S, El Fettouh H, Gupta R, Adorno Rosa J, Baumert H, Cathelineau X, Fromont G and Vallancien G: Laparoscopic partial nephrectomy for renal tumor: single center experience comparing clamping and no clamping techniques of the renal vasculature. *J Urol.* 169: 483-6, 2003. [34]
- Gettman MT, Blute ML, Chow GK, Neururer R, Bartsch G and Peschel R: Robotic-assisted laparoscopic partial nephrectomy: technique and initial clinical experience with DaVinci robotic system. *Urology.* 64: 914-8, 2004. [35]
- Caruso RP, Phillips CK, Kau E, Taneja SS and Stifelman MD: Robot assisted laparoscopic partial nephrectomy: initial experience. *J Urol.* 176: 36-9, 2006. [36]
- Phillips CK, Taneja SS and Stifelman MD: Robot-assisted laparoscopic partial nephrectomy: the NYU technique. *J Endourol.* 19: 441-5; discussion 445, 2005. [37]
- Kaul S, Laungani R, Sarle R, Stricker H, Peabody J, Littleton R and Menon M: da Vinci-assisted robotic partial nephrectomy: technique and results at a mean of 15 months of follow-up. *Eur Urol.* 51: 186-91; discussion 191-2, 2007. [38]
- Gagner M, Lacroix A, Prinz RA, Bolte E, Albala D, Potvin C, Hamet P, Kuchel O, Querin S and Pomp A: Early experience with laparoscopic approach for adrenalectomy. *Surgery.* 114: 1120-4; discussion 1124-5, 1993. [39]
- Gagner M, Lacroix A and Bolte E: Laparoscopic adrenalectomy in Cushing's syndrome and pheochromocytoma. *N Engl J Med.* 327: 1033, 1992. [40]
- Thompson GB, Grant CS, van Heerden JA, Schlinkert RT, Young WF, Jr., Farley DR and Ilstrup DM: Laparoscopic versus open posterior adrenalectomy: a case-control study of 100 patients. *Surgery.* 122: 1132-6, 1997. [41]
- Stanford A, Upperman JS, Nguyen N, Barksdale E, Jr. and Wiener ES: Surgical management of open versus laparoscopic adrenalectomy: outcome analysis. *J Pediatr Surg.* 37: 1027-9, 2002. [42]
- Schell SR, Talamini MA and Udelsman R: Laparoscopic adrenalectomy for nonmalignant disease: improved safety, morbidity, and cost-effectiveness. *Surg Endosc.* 13: 30-4, 1999. [43]

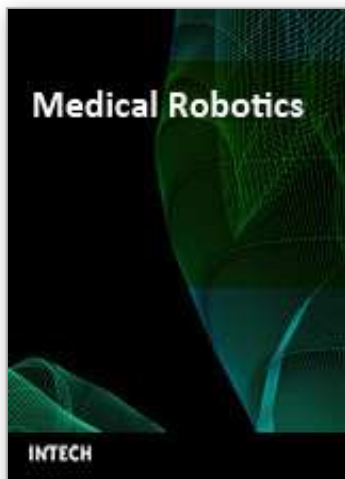- Janetschek G: Surgical options in adrenalectomy: laparoscopic versus open surgery. *Curr Opin Urol.* 9: 213-8, 1999. [44]
- Brunt LM: The positive impact of laparoscopic adrenalectomy on complications of adrenal surgery. *Surg Endosc.* 16: 252-7, 2002. [45]
- Young JA, Chapman WH, 3rd, Kim VB, Albrecht RJ, Ng PC, Nifong LW and Chitwood WR, Jr.: Robotic-assisted adrenalectomy for adrenal incidentaloma: case and review of the technique. *Surg Laparosc Endosc Percutan Tech.* 12: 126-30, 2002. [46]
- Bentas W, Wolfram M, Brautigam R and Binder J: Laparoscopic transperitoneal adrenalectomy using a remote-controlled robotic surgical system. *J Endourol.* 16: 373-6, 2002. [47]
- Desai MM, Gill IS, Kaouk JH, Matin SF, Sung GT and Bravo EL: Robotic-assisted laparoscopic adrenalectomy. *Urology.* 60: 1104-7, 2002. [48]
- Julien JS, Ball D and Schulick R: Robot-assisted cortical-sparing adrenalectomy in a patient with von hippel-lindau disease and bilateral pheochromocytomas separated by 9 years. *J Laparoendosc Adv Surg Tech A.* 16: 473-7, 2006. [49]
- Winter JM, Talamini MA, Stanfield CL, Chang DC, Hundt JD, Dackiw AP, Campbell KA and Schulick RD: Thirty robotic adrenalectomies: a single institution's experience. *Surg Endosc.* 20: 119-24, 2006. [50]
- Brunaud L, Bresler L, Ayav A, Tretou S, Cormier L, Klein M and Boissel P: [Advantages of using robotic Da Vinci system for unilateral adrenalectomy: early results]. *Ann Chir.* 128: 530-5, 2003. [51]
- Brunaud L, Bresler L, Zarnegar R, Ayav A, Cormier L, Tretou S and Boissel P: Does robotic adrenalectomy improve patient quality of life when compared to laparoscopic adrenalectomy? *World J Surg.* 28: 1180-5, 2004. [52]
- Morino M, Beninca G, Giraudo G, Del Genio GM, Rebecchi F and Garrone C: Robot-assisted vs laparoscopic adrenalectomy: a prospective randomized controlled trial. *Surg Endosc.* 18: 1742-6, 2004. [53]
- Tan BJ and Smith AD: Ureteropelvic junction obstruction repair: when, how, what? *Curr Opin Urol.* 14: 55-9, 2004. [54]
- O'Reilly PH, Brooman PJ, Mak S, Jones M, Pickup C, Atkinson C and Pollard AJ: The long-term results of Anderson-Hynes pyeloplasty. *BJU Int.* 87: 287-9, 2001. [55]
- Schuessler WW, Grune MT, Tecuanhuey LV and Preminger GM: Laparoscopic dismembered pyeloplasty. *J Urol.* 150: 1795-9, 1993. [56]
- Zhang X, Li HZ, Ma X, Zheng T, Lang B, Zhang J, Fu B, Xu K and Guo XL: Retrospective comparison of retroperitoneal laparoscopic versus open dismembered pyeloplasty for ureteropelvic junction obstruction. *J Urol.* 176: 1077-80, 2006. [57]
- Winfield HN: Management of adult ureteropelvic junction obstruction--is it time for a new gold standard? *J Urol.* 176: 866-7, 2006. [58]
- Inagaki T, Rha KH, Ong AM, Kavoussi LR and Jarrett TW: Laparoscopic pyeloplasty: current status. *BJU Int.* 95 Suppl 2: 102-5, 2005. [59]
- Munver R, Sosa RE and del Pizzo JJ: Laparoscopic pyeloplasty: history, evolution, and future. *J Endourol.* 18: 748-55, 2004. [60]
- Jarrett TW, Chan DY, Charambura TC, Fugita O and Kavoussi LR: Laparoscopic pyeloplasty: the first 100 cases. *J Urol.* 167: 1253-6, 2002. [61]
- Janetschek G, Peschel R and Frauscher F: Laparoscopic pyeloplasty. *Urol Clin North Am.* 27: 695-704, 2000. [62]

- Sung GT, Gill IS and Hsu TH: Robotic-assisted laparoscopic pyeloplasty: a pilot study. *Urology*. 53: 1099-103, 1999. [63]
- Guillonneau B, Rietbergen JB, Fromont G and Vallancien G: Robotically assisted laparoscopic dismembered pyeloplasty: a chronic porcine study. *Urology*. 61: 1063-6, 2003. [64]
- Gettman MT, Peschel R, Neururer R and Bartsch G: A comparison of laparoscopic pyeloplasty performed with the daVinci robotic system versus standard laparoscopic techniques: initial clinical results. *Eur Urol*. 42: 453-7; discussion 457-8, 2002. [65]
- Gettman MT, Neururer R, Bartsch G and Peschel R: Anderson-Hynes dismembered pyeloplasty performed using the da Vinci robotic system. *Urology*. 60: 509-13, 2002. [66]
- El-Nahas AR, Abou-El-Ghar M, Shoma AM, Eraky I, El-Kenawy MR and El-Kappany H: Role of multiphasic helical computed tomography in planning surgical treatment for pelvi-ureteric junction obstruction. *BJU Int*. 94: 582-7, 2004. [67]
- Wang DS, Stolpen AH, Bird VG, Ishigami K, Rayhill SC and Winfield HN: Correlation of preoperative three-dimensional magnetic resonance angiography with intraoperative findings in laparoscopic renal surgery. *J Endourol*. 19: 193-9, 2005. [68]
- Veyrac C, Baud C, Lopez C, Couture A, Saguintaah M and Averous M: The value of colour Doppler ultrasonography for identification of crossing vessels in children with pelvi-ureteric junction obstruction. *Pediatr Radiol*. 33: 745-51, 2003. [69]
- Frauscher F, Janetschek G, Klauser A, Peschel R, Halpern EJ, Pallwein L, Helweg G, zur Nedden D and Bartsch G: Laparoscopic pyeloplasty for UPJ obstruction with crossing vessels: contrast-enhanced color Doppler findings and long-term outcome. *Urology*. 59: 500-5, 2002. [70]
- Frauscher F, Janetschek G, Helweg G, Strasser H, Bartsch G and zur Nedden D: Crossing vessels at the ureteropelvic junction: detection with contrast-enhanced color Doppler imaging. *Radiology*. 210: 727-31, 1999. [71]
- Schwentner C, Pelzer A, Neururer R, Springer B, Horninger W, Bartsch G and Peschel R: Robotic Anderson-Hynes pyeloplasty: 5-year experience of one centre. *BJU Int*, 2007. [72]
- Atug F, Burgess SV, Castle EP and Thomas R: Role of robotics in the management of secondary ureteropelvic junction obstruction. *Int J Clin Pract*. 60: 9-11, 2006. [73]
- Siddiq FM, Leveillee RJ, Villicana P and Bird VG: Computer-assisted laparoscopic pyeloplasty: University of Miami experience with the daVinci Surgical System. *J Endourol*. 19: 387-92, 2005. [74]
- Yee DS, Shanberg AM, Duel BP, Rodriguez E, Eichel L and Rajpoot D: Initial comparison of robotic-assisted laparoscopic versus open pyeloplasty in children. *Urology*. 67: 599-602, 2006. [75]
- Chammas M, Jr., Feuillu B, Coissard A and Hubert J: Laparoscopic robotic-assisted management of pelvi-ureteric junction obstruction in patients with horseshoe kidneys: technique and 1-year follow-up. *BJU Int*. 97: 579-83, 2006. [76]
- Mendez-Torres F, Woods M and Thomas R: Technical modifications for robot-assisted laparoscopic pyeloplasty. *J Endourol*. 19: 393-6, 2005. [77]

- Atug F, Castle EP, Burgess SV and Thomas R: Concomitant management of renal calculi and pelvi-ureteric junction obstruction with robotic laparoscopic surgery. *BJU Int.* 96: 1365-8, 2005. [78]
- Shah KK, Louie M, Thaly RK and Patel VR: Robot assisted laparoscopic pyeloplasty: a review of the current status. *Int J Med Robot.* 3: 35-40, 2007. [79]
- Link RE, Bhayani SB and Kavoussi LR: A prospective comparison of robotic and laparoscopic pyeloplasty. *Ann Surg.* 243: 486-91, 2006. [80]
- Bernie JE, Venkatesh R, Brown J, Gardner TA and Sundaram CP: Comparison of laparoscopic pyeloplasty with and without robotic assistance. *Jsls.* 9: 258-61, 2005. [81]
- Weise ES and Winfield HN: Robotic computer-assisted pyeloplasty versus conventional laparoscopic pyeloplasty. *J Endourol.* 20: 813-9, 2006. [82]
- Atug F, Woods M, Burgess SV, Castle EP and Thomas R: Robotic assisted laparoscopic pyeloplasty in children. *J Urol.* 174: 1440-2, 2005. [83]
- Palese MA, Munver R, Phillips CK, Dinlenc C, Stifelman M and DelPizzo JJ: Robot-assisted laparoscopic dismembered pyeloplasty. *Jsls.* 9: 252-7, 2005. [84]
- Kutikov A, Nguyen M, Guzzo T, Canter D and Casale P: Robot assisted pyeloplasty in the infant-lessons learned. *J Urol.* 176: 2237-9; discussion 2239-40, 2006. [85]
- Lee RS, Retik AB, Borer JG and Peters CA: Pediatric robot assisted laparoscopic dismembered pyeloplasty: comparison with a cohort of open surgery. *J Urol.* 175: 683-7; discussion 687, 2006. [86]
- Patel V: Robotic-assisted laparoscopic dismembered pyeloplasty. *Urology.* 66: 45-9, 2005. [87]
- Klingler HC, Remzi M, Janetschek G, Kratzik C and Marberger MJ: Comparison of open versus laparoscopic pyeloplasty techniques in treatment of uretero-pelvic junction obstruction. *Eur Urol.* 44: 340-5, 2003. [88]
- Yohannes P and Burjonrappa SC: Rapid communication: laparoscopic Anderson-Hynes dismembered pyeloplasty using the da Vinci robot: technical considerations. *J Endourol.* 17: 79-83, 2003. [89]
- Lee RS and Borer JG: Robotic surgery for ureteropelvic junction obstruction. *Curr Opin Urol.* 16: 291-4, 2006. [90]
- Bentas W, Wolfram M, Brautigam R, Probst M, Beecken WD, Jonas D and Binder J: Da Vinci robot assisted Anderson-Hynes dismembered pyeloplasty: technique and 1 year follow-up. *World J Urol.* 21: 133-8, 2003. [91]
- Palese MA, Stifelman MD, Munver R, Sosa RE, Philipps CK, Dinlenc C and Del Pizzo JJ: Robot-assisted laparoscopic dismembered pyeloplasty: a combined experience. *J Endourol.* 19: 382-6, 2005. [92]
- Estrada CR and Passerotti CC: [Robotic surgery in pediatric urology]. *Arch Esp Urol.* 60: 471-9, 2007. [93]
- Yee DS, Klein RB and Shanberg AM: Case report: robot-assisted laparoscopic reconstruction of a ureteropelvic junction disruption. *J Endourol.* 20: 326-9, 2006. [94]
- Eden CG: Minimally Invasive Treatment of Ureteropelvic Junction Obstruction: A Critical Analysis of Results. *Eur Urol.* 2007. [95]
- Badwan K and Bhayani S: Robotic pyeloplasty: a critical appraisal. *Int J Med Robot.* 3: 20-2, 2007. [96]
- Bhayani SB, Link RE, Varkarakis JM and Kavoussi LR: Complete daVinci versus laparoscopic pyeloplasty: cost analysis. *J Endourol.* 19: 327-32, 2005. [97]

- Luke P, Knudsen BE, Nguan CY, Pautler SE, Swinnimer S, Kiaii R and Kapoor A: Robot-assisted laparoscopic renal artery aneurysm reconstruction. *J Vasc Surg.* 44: 651-3, 2006. [98]
- Hoznek A, Zaki SK, Samadi DB, Salomon L, Lobontiu A, Lang P and Abbou CC: Robotic assisted kidney transplantation: an initial experience. *J Urol.* 167: 1604-6, 2002. [99]
- Orvieto MA, Chien GW, Shalhav AL, Tolhurst SR, Rapp DE, Galocy RM and Harland RC: Case report: robot-assisted laparoscopic pyeloureterostomy in a transplanted kidney with ureteral stricture. *J Endourol.* 20: 31-2, 2006. [100]
- Cleary K and Nguyen C: State of the art in surgical robotics: clinical applications and technology challenges. *Comput Aided Surg.* 6: 312-28, 2001. [101]
- Pandya A and Auner G: Robotics technology: a journey into the future. *Urol Clin North Am.* 31: 793-800, x, 2004. [102]
- Duchene DA, Moinzadeh A, Gill IS, Clayman RV and Winfield HN: Survey of residency training in laparoscopic and robotic surgery. *J Urol.* 176: 2158-66; discussion 2167, 2006. [103]
- Wang DS and Winfield HN: Survey of urological laparoscopic practice patterns in the midwest. *J Urol.* 172: 2282-6, 2004. [104]
- Stifelman MD, Caruso RP, Nieder AM and Taneja SS: Robot-assisted laparoscopic partial nephrectomy. *Jsls.* 9: 83-6, 2005. [105]
- D'Annibale A, Fiscon V, Trevisan P, Pozzobon M, Gianfreda V, Sovernigo G, Morpurgo E, Orsini C and Del Monte D: The da Vinci robot in right adrenalectomy: considerations on technique. *Surg Laparosc Endosc Percutan Tech.* 14: 38-41, 2004. [106]

IntechOpen



Medical Robotics

Edited by Vanja Bozovic

ISBN 978-3-902613-18-9

Hard cover, 526 pages

Publisher I-Tech Education and Publishing

Published online 01, January, 2008

Published in print edition January, 2008

The first generation of surgical robots are already being installed in a number of operating rooms around the world. Robotics is being introduced to medicine because it allows for unprecedented control and precision of surgical instruments in minimally invasive procedures. So far, robots have been used to position an endoscope, perform gallbladder surgery and correct gastroesophageal reflux and heartburn. The ultimate goal of the robotic surgery field is to design a robot that can be used to perform closed-chest, beating-heart surgery. The use of robotics in surgery will expand over the next decades without any doubt. Minimally Invasive Surgery (MIS) is a revolutionary approach in surgery. In MIS, the operation is performed with instruments and viewing equipment inserted into the body through small incisions created by the surgeon, in contrast to open surgery with large incisions. This minimizes surgical trauma and damage to healthy tissue, resulting in shorter patient recovery time. The aim of this book is to provide an overview of the state-of-art, to present new ideas, original results and practical experiences in this expanding area. Nevertheless, many chapters in the book concern advanced research on this growing area. The book provides critical analysis of clinical trials, assessment of the benefits and risks of the application of these technologies. This book is certainly a small sample of the research activity on Medical Robotics going on around the globe as you read it, but it surely covers a good deal of what has been done in the field recently, and as such it works as a valuable source for researchers interested in the involved subjects, whether they are currently “medical roboticists” or not.

How to reference

In order to correctly reference this scholarly work, feel free to copy and paste the following:

Yves Caumartin, Jeffrey Warren and Patrick P.W. Luke (2008). Robotic-assisted Laparoscopic Renal and Adrenal Surgery, Medical Robotics, Vanja Bozovic (Ed.), ISBN: 978-3-902613-18-9, InTech, Available from: http://www.intechopen.com/books/medical_robotics/robotic-assisted_laparoscopic_renal_and_adrenal_surgery

INTECH
open science | open minds

InTech Europe

University Campus STeP Ri
Slavka Krautzeka 83/A
51000 Rijeka, Croatia
Phone: +385 (51) 770 447

InTech China

Unit 405, Office Block, Hotel Equatorial Shanghai
No.65, Yan An Road (West), Shanghai, 200040, China
中国上海市延安西路65号上海国际贵都大饭店办公楼405单元
Phone: +86-21-62489820

www.intechopen.com

Fax: +385 (51) 686 166
www.intechopen.com

Fax: +86-21-62489821

IntechOpen

IntechOpen

© 2008 The Author(s). Licensee IntechOpen. This chapter is distributed under the terms of the [Creative Commons Attribution-NonCommercial-ShareAlike-3.0 License](https://creativecommons.org/licenses/by-nc-sa/3.0/), which permits use, distribution and reproduction for non-commercial purposes, provided the original is properly cited and derivative works building on this content are distributed under the same license.

IntechOpen

IntechOpen