

We are IntechOpen, the world's leading publisher of Open Access books Built by scientists, for scientists

6,900

Open access books available

185,000

International authors and editors

200M

Downloads

Our authors are among the

154

Countries delivered to

TOP 1%

most cited scientists

12.2%

Contributors from top 500 universities



WEB OF SCIENCE™

Selection of our books indexed in the Book Citation Index
in Web of Science™ Core Collection (BKCI)

Interested in publishing with us?
Contact book.department@intechopen.com

Numbers displayed above are based on latest data collected.
For more information visit www.intechopen.com



Tuberculosis and Immunosuppressive Treatment in Uveitis Patients

François Willermann, Laure Caspers, Weber Celia and Dorine Makhoul

Abstract

Uveitis is reported to be related to tuberculosis in 0.2–20% of cases. This large range reflects prevalence variations of tuberculosis around the globe as well as differences in diagnostic criteria. In addition, patients with noninfectious uveitis are frequently treated by immunomodulatory drugs and are thus at risk of TB reactivation. Search for tuberculosis infection is thus an important aspect in the work-up of patients with uveitis, even in low prevalence area. In the work up of such patients, the first question to ask is whether the patient has been infected by mycobacterium tuberculosis or not. The second question is to determine whether the uveitis is due or linked to this mycobacterial infection or not. Classical tuberculosis screening tools are used to answer the first question (TST, IGRA and chest X ray). The answer to the second question is much more challenging and will require the exclusion of other causes, to consider epidemiological data and clinical signs, polymerase chain reaction (PCR) on ocular fluids and therapeutically treatment trial. Disease prevalence will greatly influence all proposed tests and the final diagnosis. Tuberculosis prevalence in Western countries has progressively decreased during the twentieth century but remains elevated in cities with large migrating populations and drug addicts, with an increase of ultra-resistant cases. All those data must be carefully analyzed in order to collect enough evidences supporting tuberculosis uveitis before the initiation of a treatment with potential serious side and adapt the treatment to the increasing resistance.

Keywords: tuberculosis, uveitis, immunosuppressive agents, immunomodulatory agents

1. Introduction

Tuberculosis (TB) is a worldwide problem and a main concern for the World Health Organization. Nowadays, 30% of the human population is infected with the Koch bacillus and tuberculosis remains one of the major health problems on earth [1–4]. In 2014 alone, 9.6 million people were thought to be infected with *Mycobacterium tuberculosis* (Mtb) globally, in the vast majority of cases, infection leads to a latent form of tuberculosis, active disease being found in only 10% [1]. Latent tuberculosis (LTBI) occurs when individuals have been exposed to TB but remained systemically healthy. This latency relies on the presence of an active

immune response against Mtb. All those people are thus at risk of TB reactivation in case of immunodepression. With area of globalization, all countries are affected with varying rates of infection, with high endemic countries from where migrant groups settle.

Uveitis is reported to be related to tuberculosis in 0.2–20% of cases [5]. This large range reflects prevalence variations of tuberculosis around the globe as well as differences in diagnostic criteria. The etiological relationship between tuberculosis and ocular inflammation is complex. Hence, direct demonstration of the presence of Mtb inside the eye is fairly rare because of the pauci-bacillary nature of the infection. If the patient has the evidence of systemic active TB infection, the uveitis may indicate direct ocular involvement by Mtb. However, in most cases, a diagnosis of presumed ocular tuberculosis will be made on the basis of the presence of compatible ophthalmological signs in the setting of a systemic (usually latent) infection [6–8]. In this context, recent studies suggest that in patients with vision-threatening uveitis with no identifiable cause who have LTBI, the recurrence rate of uveitis is greatly reduced with concomitant anti-tubercular therapy (ATT) and immunosuppressive treatment [9–11]. Another important issue, reopened with the introduction of biologics, is obviously the risk of inducing tuberculosis reactivation in patients with severe vision-threatening non-infectious uveitis where systemic corticosteroids and steroid-sparing agents are required. Search for tuberculosis infection is thus an important aspect in the work-up of patients with uveitis, even in low prevalence area in order to prevent reactivation of LTBI [10]. In this chapter, we will review those important aspects of the relation between TB and immunosuppressive (IS) drugs/immunomodulatory treatment (IMT) in uveitis patients.

2. Screening in non-infectious uveitis patients for LTBI infection before starting IS or IMT

The mainstay therapy of sight-threatening noninfectious uveitis is based on corticosteroids and immunosuppressive drugs administration. IS drugs are usually restricted to refractory cases and to patients requiring high doses of steroids, in which visual prognosis depends on more aggressive therapeutic approaches. Their long-term use is limited by ocular and systemic side effects.

The introduction of biological agents such as anti-tumor necrosis factor (anti-TNF- α), which is a key cytokine in host defense against intracellular infection as Mtb, by regulating the integrity of granuloma where TB is contained, led to the upsurge of TB reactivation [12]. In contrast, none anti-TNF- α targeted biologics like IL-6 inhibitor tocilizumab (TCZ), anti-CD20 rituximab (RTX) and more are not likely associated to any increase risk [13]. To date available TNF alpha blocking agents are: infliximab (IFX), adalimumab (ADA), golimumab (GOL), certolizumab peg (CZP) which are monoclonal antibodies directed against TNF alpha, and etanercept (ETN) which is a soluble receptor blocking agent. Several publications reported the effectiveness of anti TNF- drugs in the treatment of uveitis [14, 15]. Anti-TNF treatment had a profound effect on the management of autoimmune vision threatening uveitis with known etiology. ADA is the first licensed anti-TNF treatment for uveitis patients. It is important to emphasize that anti-TNF α agents (infliximab, adalimumab, golimumab) may be more efficient than soluble receptors of TNF α (etanercept) in decreasing the risk of uveitis [16]. But also paradoxical reactions during treatment with a biologic agent, like palmoplantar pustular and psoriasiform reactions, psoriatic arthritis, hidradenitis, inflammatory bowel disease, pyoderma gangrenosum, granulomatous reactions, and vasculitis have subsequently been reported through anecdotal cases, cohort studies, and analysis of

drug event databases, showing also that uveitis can flare during anti-TNF- α therapy especially with etanercept [17].

Because of the risk of developing active systemic TB, screening strategies for LTBI detection and preventive therapy for patients undergoing therapy with biological agents have been developed. LTBI is detected either by tuberculin skin test (TST), also named Mantoux test, or by blood-based interferon-gamma release assay (IGRA) including QuantiFERON TB Gold in Tube (QFT). Based on the WHO recommendations, either TST or IGRA are acceptable for LTBI screening [18]. Clinicians may consider, before starting IS, to use IGRA in persons with a history of BCG, but if the index of suspicion of LTBI is high, independently of BCG vaccination, both IGRA and TST may be done, especially prior to initiating anti TNF- α therapy [19]. Recent studies have evaluated the effectiveness of QFT and TST in the screening of arthritis patients and patients with inflammatory bowel disease [20, 21]. Concordance between the two tests was moderate, and it appears lower with immunosuppression. QFT alone may be appropriate in immunosuppressant-naïve patients but both tests should be considered in immunosuppressed patients. In guidelines pertaining to medical immunosuppression, the recommendations for screening varied considerably between the use of TST and IGRA. Concurrent testing with both TST and IGRA was supported by many guidelines [19–23]. Lu et al. conducted a systematic review and meta-analysis to compare the accuracy of IGRAs and TST for the diagnosis of Mtb [24]. IGRAs showed better performance than TST for the diagnosis of the tuberculosis. Data on comparative and cumulative sensitivity and specificity indexes for both tests are detailed in **Table 1**. Cotter and Rosa et al. reported an interesting approach to choose the eligibility for treatment of LTBI after screening with TST and IGRA in immunosuppressed and immuno-competent patients suffering from inflammatory bowel disease, based on a very practical algorithm adapted from Duarte et al. to trace the routes to be followed to decide which patients has LTBI and need tuberculosis treatment according to IGRA and TST [25]. We think that this algorithm can be extrapolated to all patients with inflammatory diseases like uveitis (**Table 2**). Patients with inflammatory diseases who require long-term maintenance medical immunosuppression with a negative screening TST or IGRA may not need further evaluation in the absence of risk factors and/or absence of clinical suspicion for TB in low TB risk countries [19, 21]. Annual evaluation is highly recommended if they live, travel, or work in situations where TB exposure is likely while they continue treatment with biologic agents [23]. It is important to decrease false-positive LTBI testing that may lead to potential toxic antibiotic treatment and result in the unnecessary interruption of biologic therapy. After screening, if either test is positive (TST or IGRA), a chest CT- Scan is mandatory to exclude active pulmonary TB.

LTBI can progress to active TB in 5–10% in subjects who are at higher risk like recent contact, people leaving with HIV, children below 5 years, also an age > 65, immigrants from high TB prevalence countries and candidates of biological

	QFT-IT	TST
Sensitivities	0.842 (95 % CI 0.811-0.870)	0.665 (CI 0.635-0.693)
Specificities	0.745 (95 % CI 0.715-0.775)	0.633 (CI 0.605-0.661);

Table 1.
Data on comparative and cumulative sensitivity and specificity indexes of IGRAs and TST for the diagnosis of tuberculosis.

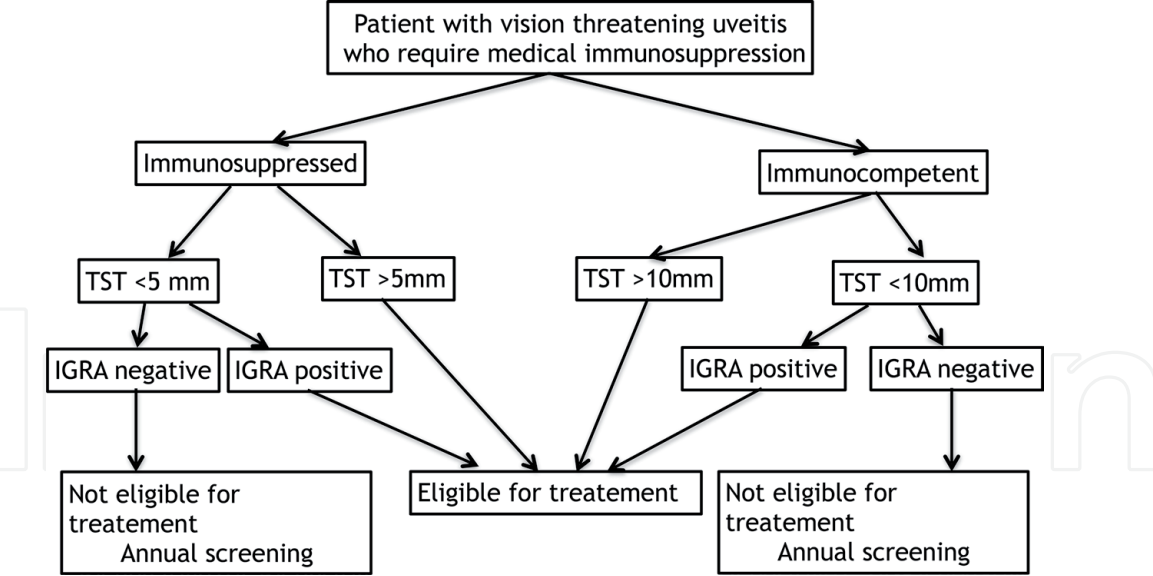


Table 2.
Algorithm for treatment of latent tuberculosis infection in uveitis patients adapted from Duarte et al.

treatment [18]. When the patient is evaluated, clinicians should also take in account other variables including the host-related TB risk based on age, socioeconomic status, lifestyle, malnutrition, immune-suppression conditions and co-morbidities. The underlying disease itself is also associated with a higher TB risk, with a peak ranging from 2.0 to 8.9 in rheumatoid arthritis patients not receiving biologic therapies, and a lower risk in those with ankylosing spondylitis (AS), psoriatic arthritis (PsA), and psoriasis (Pso) [21–23, 26]. Systemic TB reactivation has rarely been reported as side effect related to Anti-TNF- α therapy in patients with refractory relapsing chronic posterior uveitis [14, 15]. A review of the US Food and Drug Administration (FDA) Adverse Event Reporting System data revealed 70 cases of active TB in 147,000 patients receiving IFX worldwide [22]. Of these, 47 occurred in patients with RA, 18 in those with Crohn’s disease, and 5 in people with other types of arthritis, with a median interval of 12 weeks from starting the biologic therapy. The incidence rate of TB was 4 times higher in IFX-treated patients with RA than the estimated incidence in people with RA not receiving biologic therapy. As mentioned, there is an evidence of single biological-related risk as reported by Cantini et al. [10]. The risk is at least 3–4 times higher in patients exposed to monoclonal antibodies IFX and ADA than in those receiving the soluble receptor ETN. Subsequent studies aimed to establish the relative risk (RR) of TB in patients using TNF- α inhibitors (and other biologics) compared to that in the general population. Registries for patients on biologics have provided a valuable resource for studies that aimed to determine the risk of TB associated with these therapies. A French study using the RATIO registry found age- and sex-standardized incidence ratios (SIR) for infliximab, adalimumab, and etanercept of 18.6 (95% CI, 13.4–25.8), 29.3 (95% CI, 20.3–42.4), and 1.8 (95% CI, 0.7–4.3), respectively, compared to that in the general population [27].

Of note, the combined use of anti-TNF agents and traditional DMARDs exposes to a higher risk of TB reactivation in subjects with LTBI compared to patients treated with anti-TNF- α monotherapy. But practitioners need to be aware that patients with inflammatory diseases, for which biologics are prescribed, already have an increased risk of TB associated with their immunosuppressed disease state and often also have co-morbidities and additional medications that themselves have an increased risk of TB compared to that of the general population [28]. The risk

of TB reactivation in inflammatory patients treated with non-anti-TNF- α target biologics like IL-6 inhibitor tocilizumab (TCZ), anti-CD20 rituximab (RTX) and IL-1 inhibitor anakinra (ANK) and more are not likely associated to any increase risk [13, 29, 30].

Recommendations state that in the case of a diagnosis of LTBI (positive score to an immune diagnostic test (TST or IGRA) and a chest radiograph negative for active TB lesions), active TB prevention with a 6–9-month course of isoniazid is recommended associated to pyridoxine supplementation (vitamin B6), with an average protective effect against TB of 60% during the observation period [31]. There is no clear evidence in the literature concerning the optimal interval between the beginning of the preventive therapy for TB reactivation and biologic therapy [23]. Biologic therapy is suggested to be postponed for at least 1 month thereafter. Therefore, the decision to treat an individual must balance the potential personal benefits against the risk of drug hepatotoxicity and neurotoxicity which is higher in chronic alcoholics, malnourished persons, and pregnant women or healthy individuals (0.2%) due to the inhibitory effect of isoniazid on the function of pyridoxine metabolites. Daily rifampicin alone for 3–4 months compared to placebo has shown a 59% reduction of incident TB [32]. A multi-center clinical trial comparing 4 months of self-administered rifampicin to 9 months of daily isoniazid therapy has been recently completed in 2017. Daily therapy with isoniazid plus rifampicin for 3 months and standard therapy with isoniazid for 6–12 months were equivalent in terms of efficacy and as expected, given the shorter regimen and direct observation, treatment completion was significantly higher in the combination therapy group (82.1% vs. 69.0%). Toxicity was also less reported in the shorter regimen, with fewer individuals taking rifampicin/isoniazid developing drug-related hepatotoxicity [33].

Considering the most frequently used IS and IMT drugs for treatment of non-infectious uveitis, a few specific ophthalmologic reports aims to provide an overview on their use in patients with a recent or past history of systemic serious infection presumably unrelated to their inflammatory eye diseases (IED) [34]. Recently, an expert committee considered assessment and investigation of patients with severe IED initiating immunosuppressive and/or biologic therapy [35]. Infections that may be exacerbated or reactivated as a result of systemic immunosuppressive of biological therapy include: Tuberculosis, hepatitis B virus, hepatitis C virus, HIV and toxoplasmosis. These infection risks should be assessed or exclude before the initiation of such therapy. We keep our focus on risk of TB reactivation in IED patients. Studies regarding this issue are mainly focused on biological therapy, although some studies have indicate the potential risk for developing a TB when using traditional IS agents, particularly MTX [36]. But a significant relationship between the use of MTX and increased incidence of active TB was not established but should be still considered.

While it has been described that If TB develops during anti-TNF- α treatment, it is more likely to be disseminated and extra-pulmonary than are other TB cases. Few reports addressed the occurrence of uveitis tuberculosis development during anti-TNF treatment. A French group reported the uveitis cases occurring in patients with chronic rheumatic diseases, chronic inflammatory intestinal diseases or connective tissue diseases, while treated with disease-modifying anti-rheumatic drugs (DMARDs) and/or biologic therapies. A total of 32 cases of uveitis were reported, and 5 were of infectious origin, 2 toxoplasmosis, 2 herpes virus and 1 tuberculosis [37]. We faced one case of patient with SA and anterior uveitis treated with ADA for years, who developed a panuveitis with choroidal granulomas (**Figure 1**), associated with progressive cough, dyspnea, and pyrexia. A computed tomographic scan

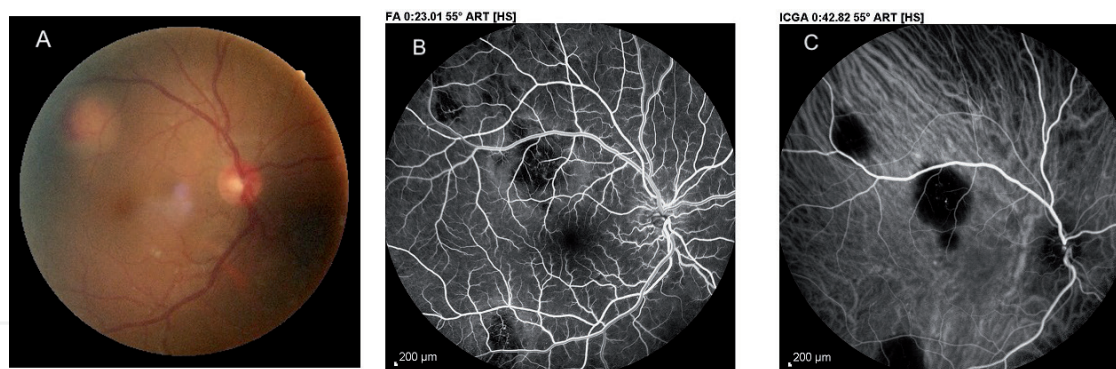


Figure 1. Bilateral tuberculosis panuveitis developing in a SA patients while under ADA therapy. (A) Eye fundus of the right eye displayed mild vitritis with yellowish deep round infiltrate lesion with discrete subretinal hemorrhage; (B) fluorescein angiogram (FA) at early phase revealed some multifocal hypofluorescent areas, which were easily seen on early stage indocyanin green angiogram (ICG); (C) ICG revealed larger hypofluorescent areas, better delimited with sharp edges, confirming the choroidal localization of these multiple lesions corresponding to tuberculous granulomas.

revealed extensive thoracic lymphadenopathy and interstitial shadowing of the lungs. Culture and polymerase chain reaction (PCR) of a mediastinal lymph node biopsy specimen showed acid-fast bacilli.

3. Ocular tuberculosis and IMT

There is a great deal of ambiguity in establishing a firm relationship between tuberculosis and ocular inflammation. It's not uncommon, when investigating patients with uveitis, that there is no identifiable systemic or ocular disease and that the only positive test is Mantoux test or QFT associated or not to abnormalities on the chest X-ray. In those patients classically classified as idiopathic uveitis, and treated by immunomodulation, the role of Mtb in disease development has been questioned. On the other hand, the role of immunomodulation in the treatment of well-established tubercular uveitis is also debated.

Severe studies tried to establish a cause/effect relationship between TB and uveitis using some criteria for presumption of tubercular etiology including positive Mantoux test/QFR, healed lesions on the chest X-ray, no other etiology, and suggestive clinical presentation of uveitis [5, 6]. In such patients, the question arises as to whether the uveitis is related to TB or not, leading to the other question of establishing or not ATT.

Intra-ocular TB accounts for 6.9–10.5% of uveitis cases without a known active systemic disease and 1.4–6.8% of patients with active pulmonary disease have concurrent ocular TB [38, 39]. In some patients there is a direct invasion by TB mycobacterium, into local ocular tissues, such as in choroidal granuloma, as evidenced by the histopathological examination of the biopsied involved ocular tissue, smears and cultures of the tissue fluid, and the polymerase chain reaction (PCR). In other patients, there is no clinical evidence to suggest active ocular TB infection. The pathogenesis of uveitis in these patients remains unclear. It is uncertain whether the uveitis is the result of reactivation of LTBI or a hypersensitivity response to Mtb [38, 40]. Bansal proposed guidelines for the diagnosis of intra-ocular TB including a combination of clinical ocular findings, ocular and systemic investigations, exclusion of other etiology and response to ATT [41]. Based on these and their own results, Gupta et al. proposed to classify intra-ocular TB into confirmed, probable, and possible intra-ocular TB [11]. Recently The Collaborative Ocular Tuberculosis Study (COTS)-1 tried to clarify through a multinational retrospective review,

what are the suggestive clinical features and approach to diagnosis of patients with tubercular uveitis. The diagnostic criteria for tubercular uveitis used in COTS-1 are developed in **Table 3** [42]. Based on those criteria, we propose a diagram explaining the diagnostic pathways for patients suspected of having TB (**Table 4**). In 2018, they provided in more details the different phenotypes of choroidal involvement in tubercular uveitis, also geographical variations in the phenotypic expression and treatment outcomes. The phenotypic variants reported were serpiginous-like choroiditis (SLC) in 46.1%, choroidal tuberculomas (CTC) in 13.5%, and multifocal choroiditis (MFC) in 9.4%. Other rare phenotypic variants of choroiditis were observed including ampiginous choroiditis (APC) in 9.0% and acute posterior multifocal placoid pigment epitheliopathy (APMPPE) in 3.3% and other indeterminate type of choroiditis in 18.8%. Those varied clinical phenotypes are probably based on the interaction and activity of mycobacterium bacilli and immune system. While SLC was clearly the most prevalent phenotype in the Asia Pacific region, it was less prevalent in the West. Furthermore, APC is a phenotype of choroiditis that is infrequently reported in association with tubercular uveitis [43].

Because TB can be sometimes confined purely to the eye, and as a pauci-bacillary infection, there is a lack of agreed management guidelines among ophthalmologists in establishing the diagnosis of intra-ocular TB. Similarly, there is no agreed consensus between ophthalmologists and other physicians with regards to role of ATT and duration of treatment in cases of isolated intra-ocular TB. Bansal et al. assessed the long-term impact of adding anti-tubercular treatment to the standard anti-inflammatory therapy consisting mostly of corticosteroids in patients with uveitis and evidence of latent or manifest TB. The group speculated that if uveitis was related to hypersensitivity reaction to tubercular antigens attributable to latent TB, the elimination of LTBI would lead to elimination of future recurrences of uveitis in these patients. The administration of anti-tubercular therapy in these patients

Patients have to satisfy 1 and 2, along with either 3 or 4 for the diagnosis of ocular TB.

<p>1. Any of the following clinical signs suggestive of ocular tuberculosis including:</p> <ul style="list-style-type: none">a. Anterior uveitis (granulomatous or non-granulomatous) with or without iris nodules or Ciliary body granuloma orb. Intermediate uveitis (granulomatous or non-granulomatous with exudates in the pars plana or peripheral uvea with snow balls) orc. Posterior or Panuveitis - Choroidal tubercle or Choroidal granuloma or Subretinal abscess or Serpiginous-like choroiditis or Retinitis or Retinal vasculitis or Neuroretinitis or Optic neuritis or Endogenous ophthalmitis or Panophthalmitis or Scleritis
<p>2. Exclusion of other uveitic entities where relevant based on clinical manifestations of disease and regional epidemiology</p>
<p>3. Investigations documenting the mycobacteria or its genome</p> <ul style="list-style-type: none">a. Demonstration of Acid-Fast Bacilli (AFB) by microscopy or culture of M. tuberculosis from ocular fluidb. Positive polymerase chain reaction from ocular fluid for IS 6110 or other conserved sequences in mycobacterial genomec. Evidence of confirmed active pulmonary or extrapulmonary tuberculosis (by microscopic examination or culture of a tissue sample from the affected tissue)
<p>4. Corroborative investigations</p> <ul style="list-style-type: none">a. Positive Mantoux reaction (must be accompanied by information regarding antigen and amount of tuberculin injected, along with institutional practices in interpreting the test)b. Interferon Gamma Release Assay (IGRA) such as Quantiferon TB Gold (must be accompanied by information regarding institutional practices in interpreting the test)c. Evidence of healed or active tuberculosis on chest radiography (must be accompanied by information regarding practices by institution radiologists regarding clinical features that are considered evidence in this regard)

Table 3.
(COTS)-1 clarify, through a multinational retrospective review, the suggestive clinical features and approach to diagnosis of patients with tubercular (TB) uveitis.

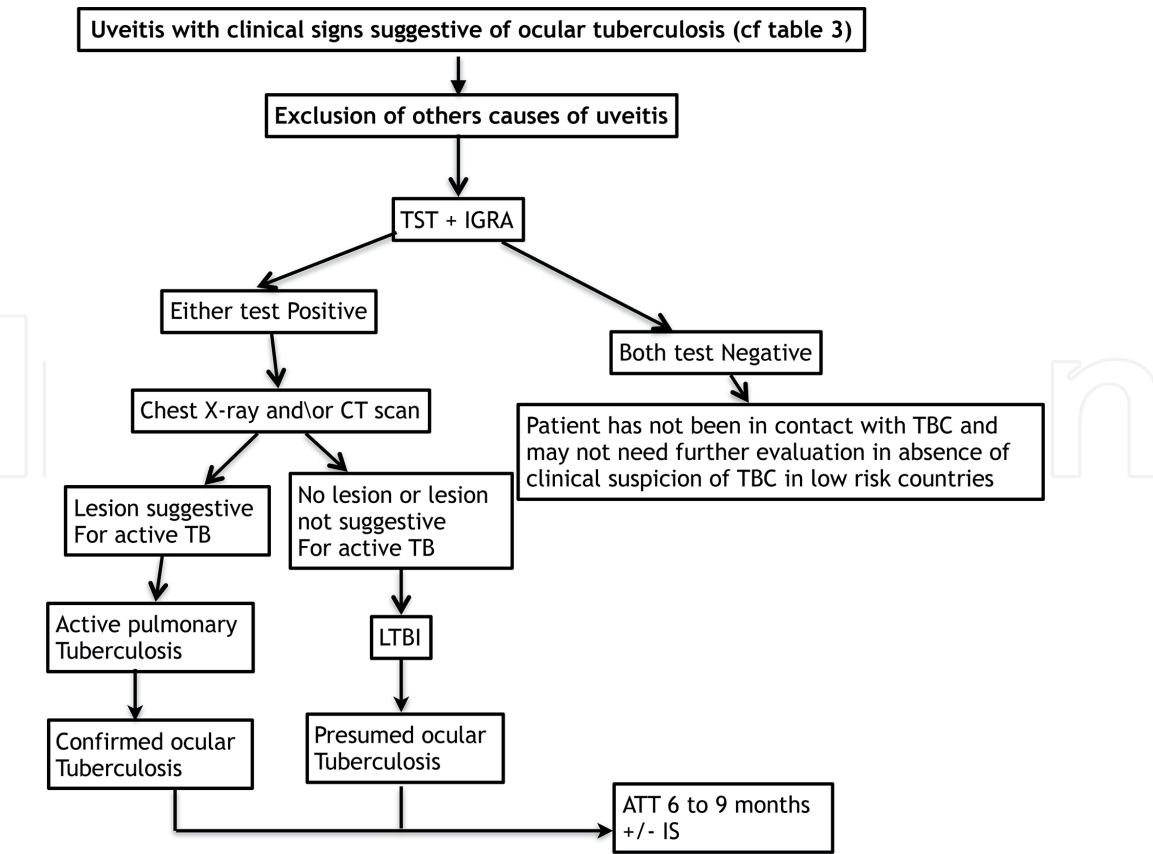


Table 4.
Diagram explaining the diagnostic pathways for patients suspected of having TB.

substantially reduces recurrences when given along with standard corticosteroid therapy. Corticosteroids may limit damage to ocular tissues caused from delayed type hypersensitivity [41]. The use of ATT to manage presumed ocular tuberculosis is regarded as an effective tool for tubercular uveitis and response to therapy can be a good surrogate for diagnosis of presumed ocular tuberculosis.

A case control study conducted by Chee et al. on patients with uveitis with evidence of latent TB and no other underlying disease, who were treated with ATT for more than 9 months duration, were approximately 11 times less likely to develop recurrence of inflammation compared with patients who had not received ATT. This association was independent of potential confounders such as demographics, classification of uveitis and corticosteroid therapy. On the other hand, patients who were treated with ATT for <6 months or 6–9 months duration did have a reduction in recurrence, but this was not statistically significant [39]. The Collaborative Ocular Tuberculosis Study (COTS)-1 group also reported the role of ATT in the management of patients with TB uveitis from a multinational cohort and explore potential correlations of clinical features with treatment response. A low treatment failure rate was reported in patients with TB uveitis treated with ATT. On multivariate regression analysis, they showed that the presence of choroidal involvement with vitreous haze and snowballs in patients with panuveitis was associated with a higher risk of recurrence. Concerning the addition of corticosteroids to ATT, their results suggests that patients treated with corticosteroids may have had poorer outcomes than those who were not [42]. Effectively, the possible beneficial effect of immunomodulation in association of ATT in the management of tubercular uveitis is still debated. A recent meta analyze was conducted on 37 articles to assess the effect of ATT associated or not to IMT on ocular outcome of patients with presumed ocular TB. The meta-analysis revealed that 84% of the patients receiving ATT showed

non-recurrence of inflammation during the follow-up period. A successful outcome was observed in 85% of patients treated with ATT alone; in 82% of patients treated with ATT and systemic steroids and in 85% of patients treated with ATT and systemic steroids and immunomodulators. It was not possible to conclude which regimen was the best to control ocular inflammation [44–46].

4. Conclusion

The link between tuberculosis, uveitis and immunosuppression are important and complex. First, patients with inflammatory diseases treated with IMT agents, including noninfectious uveitis patients, are at risk to develop active tuberculosis, including ocular tuberculosis. Secondly, many data suggest that Mtb might play a role in disease development of idiopathic uveitis in LTBI patients and that ATT must be considered in such cases. Finally, inflammatory and immune reaction are likely to play a role during ocular tuberculosis and immunomodulation has a beneficial effect.

In summary, we have to keep in mind that the main concern of TB screening for ophthalmologist is to avoid systemic TB reactivation in front of a sight threatening uveitis with known etiology destined to IS/IMT. But when facing an idiopathic uveitis under IS/IMT, there is another risks which has to be considered, the risk of ocular TB misdiagnosis with a non- or partial response to immunosuppressive treatment. Introduction of ATT in those cases will control inflammation, will help to discontinue most IMT and will prevent recurrences.

Author details


François Willermain^{1,2}, Laure Caspers¹, Weber Celia^{1,2} and Dorine Makhoul^{1,2*}

1 Department of Ophthalmology, CHU Saint-Pierre, Université Libre de Bruxelles, Brussels, Belgium

2 Department of Ophthalmology, CHU Brugmann, Université Libre de Bruxelles, Brussels, Belgium

*Address all correspondence to: domakhoul@gmail.com

IntechOpen

© 2019 The Author(s). Licensee IntechOpen. This chapter is distributed under the terms of the Creative Commons Attribution License (<http://creativecommons.org/licenses/by/3.0>), which permits unrestricted use, distribution, and reproduction in any medium, provided the original work is properly cited. 

References

- [1] Wirth T, Hildebrand F, Allix-Béguec C, et al. Origin, spread and demography of the *Mycobacterium tuberculosis* complex. *PLoS Pathogen*. 2008;**4**:e100160
- [2] Dye C, Scheele S, Dolin P, Pathania V, Raviglione MC. Consensus statement. Global burden of tuberculosis: Estimated incidence, prevalence, and mortality by country. WHO global surveillance and monitoring project. *JAMA*. 1999;**282**:677-686
- [3] Lonnroth K, Raviglione M. Global epidemiology of tuberculosis: Prospects for control. *Seminars in Respiratory and Critical Care Medicine*. 2008;**29**:481-491
- [4] Maartens G, Wilkinson RJ. Tuberculosis. *Lancet*. 2007;**370**:2030-2043
- [5] Gupta V, Gupta A, Rao NR. Intraocular tuberculosis—An update. *Survey of Ophthalmology*. 2007;**52**:561-587
- [6] Cunningham ET. TB or not TB ? The perennial question. *The British Journal of Ophthalmology*. 2001;**85**:127-129
- [7] Agrawal R, Gupta B, González-López JJ, et al. Spectrum of choroidal involvement in presumed ocular tuberculosis: Report from a population with low endemic setting for tuberculosis. *Ocular Immunology and Inflammation*. 2017;**25**(1):97-104
- [8] Agrawal R, Gunasekeran DV, Grant R, et al. Clinical features and outcomes of patients with tubercular uveitis treated with antitubercular therapy in the collaborative ocular tuberculosis study (COTS)-1. *JAMA Ophthalmology*. DOI: 10.1001/jamaophthalmol.2017.4485. 2017.10.26
- [9] Agrawal R, Gupta B, Gonzalez-Lopez JJ, et al. The role of anti-tubercular therapy in patients with presumed ocular tuberculosis. *Ocular Immunology and Inflammation*. 2015;**23**(1):40-46
- [10] Cantini F, Niccoli L, Goletti D. Adalimumab, etanercept, infliximab, and the risk of tuberculosis: Data from clinical trials, national registries, and postmarketing surveillance. *The Journal of Rheumatology. Supplement*. 2014;**91**:47-55
- [11] Bansal R, Gupta A, Gupta V, et al. Role of anti-tubercular therapy in uveitis with latent/manifest tuberculosis. *American Journal of Ophthalmology*. 2008;**146**(5):772-779
- [12] Shobha V, Chandrashekara S, Rao V, Desai A, Jois R, Dharmanand BG, et al. Biologics and risk of tuberculosis in autoimmune rheumatic diseases: A real-world clinical experience from India. *International Journal of Rheumatic Diseases*. 2018
- [13] Cantini F, Nannini C, Niccoli L, Petrone L, Ippolito G, Goletti D. Risk of tuberculosis reactivation in patients with rheumatoid arthritis, ankylosing spondylitis, and psoriatic arthritis receiving non-anti-TNF-targeted biologics. *Mediators of Inflammation*. 2017;**2017**:8909834
- [14] Calvo-Río V, Blanco R, Beltrán E, Sánchez-Bursón J, Mesquida M, Adán A, et al. Anti-TNF- α therapy in patients with refractory uveitis due to Behçet's disease: A 1-year follow-up study of 124 patients. *Rheumatology (Oxford, England)*. 2014 Dec;**53**(12):2223-2231
- [15] Joseph A, Raj D, Dua HS, Powell PT, Lanyon PC, Powell RJ. Infliximab in the treatment of refractory posterior uveitis. *Ophthalmology*. 2003 Jul;**110**(7):1449-1453
- [16] Mitulescu TC, Trandafir M, Dimăncescu MG, Ciuluvică RC, Popescu

V, Predeteanu D, et al. Advances in the treatment of uveitis in patients with spondyloarthritis—Is it the time for biologic therapy? *Romanian Journal of Ophthalmology*. 2018;**62**(2):114-122. Review

[17] Puig L. Paradoxical reactions: Anti-tumor necrosis factor alpha agents, ustekinumab, secukinumab, ixekizumab, and others. *Current Problems in Dermatology*

[18] Getahun H, Chaisson RE, Raviglione M. Latent mycobacterium tuberculosis infection. *The New England Journal of Medicine*. 2015;**373**(12):1179-1180

[19] Goletti D, Petrone L, Ippolito G, Niccoli L, Nannini C, Cantini F. Preventive therapy for tuberculosis in rheumatological patients undergoing therapy with biological drugs. *Expert Review of Anti-Infective Therapy*. 2018;**16**(6):501-512

[20] Lee H, Park HY, Jeon K, Jeong BH, Hwang JW, Lee J, et al. QuantiFERON-TB gold in-tube assay for screening arthritis patients for latent tuberculosis infection before starting anti-tumor necrosis factor treatment. *PLoS One*. 2015;**10**(3):e0119260

[21] Mantzaris GJ, Tsironikos D, Tzanetakou X, Grispou E, Karatzas P, Kalogeropoulos I, et al. The impact of immunosuppressive therapy on QuantiFERON and tuberculin skin test for screening of latent tuberculosis in patients with inflammatory bowel disease scheduled for anti-TNF therapy. *Scandinavian Journal of Gastroenterology*. 2015;**50**(12):1451-1455

[22] Cantini F, Nannini C, Niccoli L, Iannone F, Delogu G, Garlaschi G, et al. Guidance for the management of patients with latent tuberculosis infection requiring biologic therapy in rheumatology and dermatology clinical practice. *Autoimmunity Reviews*. 2015;**14**(6):503-509

[23] Iannone F, Cantini F, Lapadula G. Diagnosis of latent tuberculosis and prevention of reactivation in rheumatic patients on biologic therapy: The international recommendations. *The Journal of Rheumatology. Supplement*. 2014;**91**:41-46

[24] Lu P, Chen X, Zhu L, Yang H. Interferon-gamma release assays for the diagnosis of tuberculosis: A systematic review and meta-analysis. *Lung*. 2016;**194**(3):447-458

[25] Duarte R, Campainha S, Cotter J, Rosa B, Varela P, Correia A, et al. Position paper on tuberculosis screening in patients with immune mediated inflammatory diseases candidates for biological therapy. *Acta Reumatológica Portuguesa*. 2012;**37**(3):253-259

[26] Wong SH, Gao Q, Tsoi KK, Wu WK, Tam LS, Lee N, et al. Effect of immunosuppressive therapy on interferon γ release assay for latent tuberculosis screening in patients with autoimmune diseases: A systematic review and meta-analysis. *Thorax*. 2016;**71**(1):64-72

[27] Dobler CC. Biologic agents and tuberculosis. *Microbiology Spectrum*. 2016;**4**(6)

[28] Lorenzetti R, Zullo A, Ridola L, Diamanti AP, Laganà B, Gatta L, et al. Higher risk of tuberculosis reactivation when anti-TNF is combined with immunosuppressive agents: A systematic review of randomized controlled trials. *Annals of Medicine*. 2014;**46**:547-554

[29] Payet S, Soubrier M, Perrodeau E, Bardin T, Cantagrel A, Combe B, et al. Efficacy and safety of rituximab in elderly patients with rheumatoid arthritis enrolled in a French Society of Rheumatology registry. *Arthritis Care and Research*. 2014;**66**:1289-1295

[30] Cantarini L, Lopalco G, Caso F, Costa L, Iannone F, Lapadula G, et al.

Effectiveness and tuberculosis-related safety profile of interleukin-1 blocking agents in the management of Behçet's disease. *Autoimmunity Reviews*. 2015;**14**:1-9

[31] International Union Against Tuberculosis Committee on Prophylaxis. Efficacy of various durations of isoniazid preventive therapy for tuberculosis: Five years of follow-up in the IUAT trial. *Bulletin of the World Health Organization*. 1982;**60**(4):555-564

[32] Menzies D. Randomized clinical trial comparing RIF vs. INH for LTBI treatment-effectiveness. 2016. NCT00931736

[33] Ena J, Valls V. Short-course therapy with rifampin plus isoniazid, compared with standard therapy with isoniazid, for latent tuberculosis infection: A meta-analysis. *Clinical Infectious Diseases*. 2005;**40**(5):670-676

[34] Cordero-Coma M, Salazar-Méndez R, Yilmaz T. Treatment of severe non-infectious uveitis in high-risk conditions (part 2): Systemic infections; management and safety issues. *Expert Opinion on Drug Safety*. 2015;**14**(9):1353-1371

[35] Wakefield D, McCluskey P, Wildner G, Thureau S, Carr G, Chee SP, et al. Inflammatory eye disease: Pre-treatment assessment of patients prior to commencing immunosuppressive and biologic therapy: Recommendations from an expert committee. *Autoimmunity Reviews*. 2017;**16**(3):213-222

[36] Zorlu M, Kiskac M, Karatoprak C, et al. Pott's disease and hypercalcemia in a patient with rheumatoid arthritis receiving methotrexate monotherapy. *Indian Journal of Pharmacology*. 2013;**45**(6):631-633

[37] Cabane L, Baillif S, Baldin B, Breuil V, Euler-Ziegler L, Tieulié N. Uveitis treated with biotherapy and/or DMARD: Analysis from the French Pharmacovigilance Study Base. *Journal Français d'Ophtalmologie*. 2018;**41**(4):350-356

[38] Alvarez GG, Roth VR, Hodge W. Ocular tuberculosis: Diagnostic and treatment challenges. *International Journal of Infectious Diseases*. 2009;**13**(4):432-435

[39] Ang M, Hedayatfar A, Wong W, et al. Duration of anti-tubercular therapy in uveitis associated with latent tuberculosis: A case-control study. *The British Journal of Ophthalmology*. 2012;**96**(3):332-336

[40] Helm CJ, Holland GN. Ocular tuberculosis. *Survey of Ophthalmology*. 1993;**38**:229-256

[41] Bansal R, Gupta A, Gupta V, et al. Tubercular serpiginous-like choroiditis presenting as multifocal serpiginoid choroiditis. *Ophthalmology*. 2012;**119**(11):2334-2342

[42] Agrawal R, Gunasekeran DV, Grant R, Agarwal A, Kon OM, Nguyen QD, et al. Clinical features and outcomes of patients with tubercular uveitis treated with antitubercular therapy in the collaborative ocular tuberculosis study (COTS)-1. *JAMA Ophthalmology*. 2017;**135**(12):1318-1327

[43] Agrawal R, Gunasekeran DV, Agarwal A, Carreño E, Aggarwal K, Gupta B, et al. The collaborative ocular tuberculosis study (COTS)-1: A multinational description of the spectrum of choroidal involvement in 245 patients with tubercular uveitis. *Ocular Immunology and Inflammation*. 2018;**29**:1-1

[44] Kee AR, Gonzalez-Lopez JJ, Al-Hity A, Gupta B, Lee CS, Gunasekeran

DV, et al. Anti-tubercular therapy for intraocular tuberculosis: A systematic review and meta-analysis. *Survey of Ophthalmology*. 2016;**61**(5):628-653

[45] Bajema KL, Pakzad-Vaezi K, Hawn T, Pepple KL. Tuberculous uveitis: Association between anti-tuberculous therapy and clinical response in a non-endemic country. *Journal of Ophthalmic Inflammation and Infection*. 2017;**7**(1):19

[46] Tomkins-Netzer O, Leong BCS, Zhang X, Lightman S, McCluskey PJ, Sydney-London Latent Ocular TB Study Group. Effect of antituberculous therapy on uveitis associated with latent tuberculosis. *American Journal of Ophthalmology*. 2018;**190**:164-170