

# We are IntechOpen, the world's leading publisher of Open Access books Built by scientists, for scientists

6,900

Open access books available

186,000

International authors and editors

200M

Downloads

Our authors are among the

154

Countries delivered to

TOP 1%

most cited scientists

12.2%

Contributors from top 500 universities



WEB OF SCIENCE™

Selection of our books indexed in the Book Citation Index  
in Web of Science™ Core Collection (BKCI)

Interested in publishing with us?  
Contact [book.department@intechopen.com](mailto:book.department@intechopen.com)

Numbers displayed above are based on latest data collected.  
For more information visit [www.intechopen.com](http://www.intechopen.com)



# The Clinical Spectrum of Amyloidosis

*Aswanth Reddy, Enrique Ballesteros  
and Jonathan Scott Harrison*

## Abstract

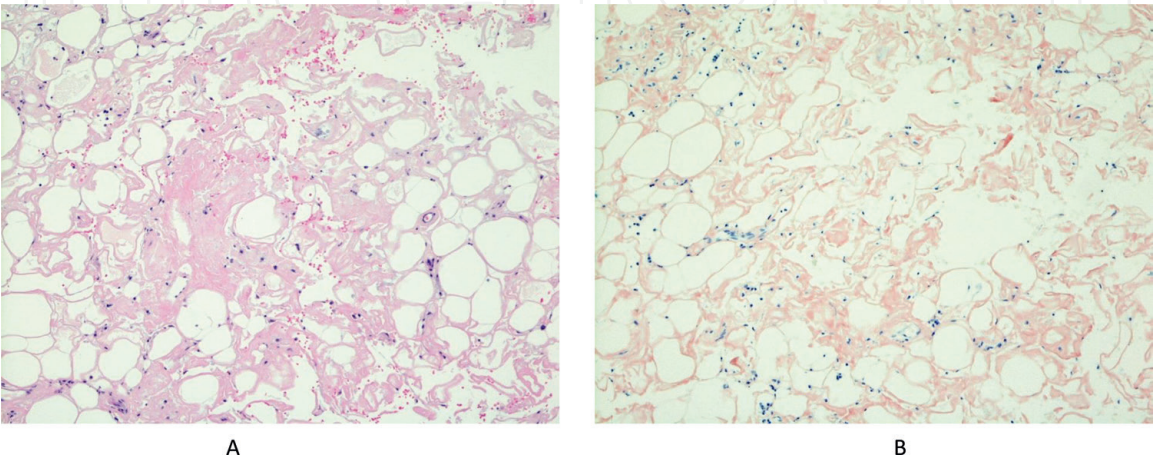
Amyloidosis is a group of disorders that share a common pathobiology: in each case, a protein that exhibits misfolding is deposited in one or multiple organs leading to disruption in organ function. These amyloid proteins are recognized as amorphous pink material in Hematoxylin and Eosin staining, with confirmation by staining with Congo red and yellow or green birefringence under polarized light microscope. To date at least 36 different types of amyloid proteins have been identified. Worldwide, AA amyloidosis is the most common type, and this occurs secondary to chronic inflammatory disease states—such as chronic infections and rheumatological disorders. In western countries, the incidence of AA amyloidosis is decreasing, and AL is the most common type of amyloidosis, characterized by amyloid due to light chain deposition. ATTR amyloidosis, which can be either hereditary or acquired, is a unique variant of systemic amyloidosis that results from mutations in the transthyretin (TTR) gene. Our review will focus on clinical features of the most common systemic amyloidosis, with a detailed review on evaluation and management of AA, AL and ATTR amyloidosis.

**Keywords:** AA amyloidosis, AL amyloidosis, ATTR amyloidosis

## 1. Introduction

Amyloidosis is a group of disorders that share the common feature of deposition into tissues of any one of a number of different proteins. The uniform underlying pathobiology is the finding that in each case, the protein—termed amyloid—deposited into the target organ has undergone abnormal three-dimensional folding. The abnormal folding of the peptide results in accumulation in tissues as micro-fibrillary structures. The deposition of amyloid protein, regardless of which specific protein forms the amyloid, results in disruption in the function of the organ in which the amyloid protein is deposited. The common histopathologic feature of all amyloidosis is the finding, by light microscopy, of amorphous protein in one or more organs, typically initially recognized upon histologic review of a biopsy, as an amorphous pink material on Hematoxylin and Eosin staining (**Figure 1**). Per the International Society of Amyloidosis 2016 nomenclature guidelines, amyloid fibrils must exhibit affinity for the histologic stain Congo red, showing green, yellow or orange birefringence when the Congo red-stained deposits are viewed with polarized light. At least 36 different proteins can undergo abnormal folding and result in deposition of amyloid, causing clinical disease. It is conventional to describe a

particular amyloid protein as “Amyloid Protein AX,” where the X is a suffix to the designation, based on the identity of the amyloid protein. The more commonly encountered subtypes are, for example Amyloid Protein AL, Amyloid Protein AA, and Amyloid Protein ATTR, as discussed below. This chapter is an overview of the different categories of amyloidosis, with a focus on the clinical features, prognosis, and management of focal or systemic amyloidosis. Symptoms depend on the type and amount of amyloid protein, and are often variable. The manifestations depend on the identity of the underlying protein that forms the amyloid fibrils, the burden of amyloid, and the organs involved, as well as comorbidities of an individual patient (see **Table 1**).



**Figure 1.** Photomicrographs of a lymph node biopsy with AL amyloidosis. Panel A: 10× magnification of a left axillary lymph node biopsy stained using Hematoxylin and Eosin, demonstrating amorphous pink material typical of amyloid infiltration. White areas are fat that has been leached from the tissue in processing. Panel B: 10× magnification of the same lymph node stained using Congo red, viewed by light microscopy.

Symptoms commonly seen in systemic amyloidosis	
	Fatigue
	Edema at one or more sites
	Lightheadedness upon standing (due to orthostatic hypotension)
	Diarrhea
	Focal pain (due to peripheral neuropathy)
Physical signs commonly seen in systemic amyloidosis	
	Edema at one or more sites (due to either heart failure, nephrotic syndrome, or both)
	Focal mass lesions (amyloid deposition focally)
	Orthostatic hypotension (due to autonomic nerve dysfunction)
	enlarged tongue (macroglossia)
	Purpura (due to either coagulation disorder, skin fragility due to amyloid infiltration, or both)

**Table 1.** Clinical manifestation of systemic amyloidosis.

## 2. Types of systemic amyloidosis

### 2.1 AA amyloidosis

Worldwide, AA amyloidosis is the most common type of systemic amyloidosis. Although AA amyloid currently is the most common form of amyloidosis, the incidence is decreasing over time in western countries. This has been attributed to a significant decrease in chronic infections, as well as improved therapies for

inflammatory diseases. A review from the UK in 2013 estimated in excess of 8.0 per million cases of amyloidosis every year and AA being second most common (18%) [1]. The underlying causes of systemic AA amyloidosis include a wide range of inflammatory diseases, including but not limited to chronic inflammatory disorders, infections, and malignancy (**Table 2**). The amyloid fibril AA is most often a result of abnormal folding and aggregation of serum apolipoprotein A (SAA), which is an acute phase reactant—that is, the level becomes elevated in the blood in response to inflammation [2]. AA amyloid fibrils form through a process of cleavage, misfolding, and aggregation into a highly ordered abnormal  $\beta$ -sheet conformation. Amyloid fibrils associate anatomically with other moieties, including glycosaminoglycans and serum amyloid P component (SAP), forming deposits that disrupt the structure and function of tissues and organs [3].

In the healthy, physiological state in humans, the serum SAA concentration is relatively low, but the level increases about a thousand fold during an inflammatory reaction. In humans, SAA is expressed in three different isoforms: SAA1, SAA2 and SAA4 and are encoded by different genes. SAA1 and SAA2 are solely expressed in liver and are entirely bound to plasma High Density Lipoprotein in plasma [4]. Inflammation increases the secretion of cytokines, including IL-1, IL-6 and TNF, which in turn increases the production of SAA [5]. SAA functions to transport and recycle cholesterol from sites of tissue injury, thereby modulating the immune response. Not all individuals with high SAA levels develop amyloidosis; it appears that certain polymorphisms and mutations in the SAA genes predispose to abnormal protein folding and therefore amyloid formation [6]. The formation of amyloid fibril from precursor SAA protein is the result of complex interaction with glycosaminoglycans, including most prominently heparan sulfate [7]. Impairing this interaction or the degrading of heparan sulfate by a heparinase has been shown to prevent formation of amyloid fibrils, and this has led to an area of research for potential treatment.

More recently, a protein named A Leukocyte Chemotactic factor 2 (ALECT2) protein has been shown to be a cause of AA amyloidosis, with a propensity to cause renal amyloidosis [8]. The human ALECT2 gene, discovered only in 2008, has been localized to chromosome 5 (5q31.1-q32) [9]. ALECT2 is being increasingly recognized as a cause of AA amyloidosis.

Inherited forms of AA amyloidosis arise due to mutations in a variety of proteins that can undergo abnormal folding and consequent deposition into tissues,

Chronic disorders [64–66]	Infections	Malignancy [74]
Rheumatoid arthritis (RA)	Leprosy [71]	Hodgkin disease
Alzheimer's disease	Osteomyelitis	Non-Hodgkin lymphoma
Juvenile idiopathic arthritis	Tuberculosis [72]	Renal cell carcinoma
Ankylosing spondylitis	Chronic bronchiectasis	Gastrointestinal cancers
Psoriasis and psoriatic arthritis	[73]	Lung cancer [75]
Still disease [67]		Urogenital carcinoma
Behçet syndrome [68]		Mesothelioma [76]
Familial Mediterranean fever		
Crohn's disease		
Castleman disease [69]		
Cryopyrin-associated periodic syndromes (CAPS) [70]		
TNF-receptor-associated periodic fever syndrome		
Vasculitis		

**Table 2.**  
*Causes of AA amyloidosis.*



resulting in organ dysfunction. These include mutations in the genes encoding transthyretin, the fibrinogen A  $\alpha$ -chain, apolipoprotein A-I, apolipoprotein A-II, and lysozyme [10]. These mutations appear to account for the vast majority of relatively rare familial amyloidosis. Each of these has clinical characteristics that are somewhat peculiar to the specific etiology of the inherited disorder.

### *2.1.1 Clinical features of systemic AA amyloidosis*

Amyloidosis may be localized, or systemic. The clinical symptoms of AA amyloidosis depend on the organ involved by the amyloid fibril. Liver and spleen are the most common sites of deposition, but they are asymptomatic until late in the course of the disease. Hepatosplenomegaly and adrenal insufficiency are common in the advanced stage of AA amyloidosis. Renal involvement damages the glomerular membrane, resulting in nephrotic syndrome and proteinuria. Proteinuria is one of the earliest signs of AA amyloidosis, and seen in approximately 95% of patients with AA amyloidosis [2, 11]. Persistent, untreated renal damage results in end stage renal disease (ESRD), requiring some form of renal substitute therapy—either dialysis or renal transplantation. Cardiac involvement is by deposition of fibrils into cardiac muscle, but clinical cardiac dysfunction is extremely rare in AA amyloidosis, occurring in only 2% of patients in most series [12]. Gastrointestinal involvement results in diarrhea, malabsorption and pseudo obstruction of the bowel. There are several reports of thyroid gland involvement, manifesting as goiter [13].

### *2.1.2 Treatment*

Treatment of AA amyloidosis is challenging due to diverse underlying causes. Ideally, in inflammatory disorders—whether chronic infectious disease (e.g., mycobacterium tuberculosis, staphylococcal osteomyelitis, and other chronic infections), autoimmune disease (e.g., rheumatoid arthritis, scleroderma, and other immune mediated inflammatory diseases), idiopathic (e.g., sarcoidosis), and chronic low-grade malignancy (e.g., B and T cell low-grade lymphomas, Hodgkin disease) the treatment of AA amyloidosis is the treatment of the underlying disease process. The role of controlling inflammation is also essential in the management of AA amyloidosis in patients with chronic rheumatologic diseases. In the era of advanced therapies, the incidence of rheumatic arthritis leading to AA amyloidosis has declined significantly; this was at one time among the most common causes. Specific treatments such as surgical excision in Castleman disease, high dose colchicine for familial Mediterranean fever (FMF) and effective therapy for tuberculosis have shown to significantly reduce serum SAA levels thereby improvement in end organ dysfunction. Treatments of malignancy with chemotherapy and surgery have shown to reverse organ function.

Several anti-inflammatory agents have been studied as potential therapy to reduce the levels of SAA. Tocilizumab, a monoclonal antibody against IL-6 has been successful in significantly reducing circulating levels of SAA when used in autoimmune diseases. A recent series showed significant reduction in acute phase reactants as well as an improvement in proteinuria in patients treated with Tocilizumab for FMF [14].

In vitro studies have shown low molecular weight heparin to impair amyloid deposition by impeding the structural changes necessary for fibril formation. Eposidate, a sulfonated small molecule similar to heparin sulfate binds competitively to glycosaminoglycan and reduces inflammation and amyloid deposition. This was initially studied as an agent to retard progressive renal failure, and it resulted in a favorable response in a phase II clinical trial [15]. Unfortunately, a

phase III trial did not meet the targeted endpoints, and so Eporsidate has not been developed further to date [16]. Dimethyl sulfoxide (DMSO) is a derivative of intercellular low-density lipoprotein, which reduces levels of acute phase reactants including SAA, and has been shown to improve symptoms in patients with gastrointestinal involvement by AA amyloid [17].

Anti-SAP antibody, R-1-[6-[R-2-carboxy-pyrrolidin-1-yl]-6-oxo-hexanoyl]pyrrolidine-2-carboxylic acid (CPHPC) was studied in AL and AA amyloidosis with favorable responses in an open label study [18]. A recent phase Ib trial of SAP inhibitor, Miridesap followed by humanized monoclonal antibody Dezamizumab against SAP showed clearance of amyloid fibrils in liver and spleen, confirmed by I-SAP scintigraphy [19]. Further studies are ongoing and these treatments are a real potential for future management of amyloidosis.

## 2.2 AL amyloidosis

AL amyloidosis results from the deposition of abnormally folded immunoglobulin light chains into tissues. The formation of amyloid fibrils from immunoglobulin light chains requires abnormal three-dimensional folding of the light chain, resulting in filaments of  $\beta$ -sheets of relatively insoluble protein [20]. AL amyloid may arise from either polyclonal immunoglobulin light chains or, much more commonly, from monoclonal immunoglobulin light chains. In order for polyclonal AL amyloidosis to result, however, the light chains must fold abnormally—in order to form amyloid and accumulate in target organs. Further, the local concentration of these peptides must, in general, be high. In AL amyloidosis, whether polyclonal or monoclonal, the specific light chains have a peptide sequence that results in a predisposition to abnormal folding of the peptide. In some cases, this appears to be due to genetic polymorphisms in the light chain gene structure. Among the variable regions of the light chain gene products, several (V $\lambda$ 1, V $\lambda$ 2, V $\lambda$ 3, V $\lambda$ 6, and V $\kappa$ 1) are over-represented as amyloid protein, suggesting that these peptide sequences have a predilection to fold abnormally and become amyloid. In monoclonal AL amyloidosis, the tendency of monoclonal light chain to fold abnormally may be due, rather, to a mutational event attributable to genomic instability of the clone, rather than a genetic polymorphism in the light chain sequence. Several laboratories have demonstrated that peptide sequences from patients with different levels of secreted light chain have distinct differences in the location of non-conservative mutations in the light chain genes. This implies that the location of non-conservative mutations may be one determinant of the amyloidogenic propensity of light chains in some cases. Three-dimensional structure analyses and site-mutagenesis experiments indicate that both replacement of conserved polar residues in light chains, and loss of hydrogen bonding sites, are common features seen in amyloidogenic immunoglobulin light chains [21–24]. Separately, there is evidence that posttranslational modification of light chains can influence the propensity for amyloid to accumulate, including peptide glycosylation, lysine modification, and rate of proteolysis. Impaired function of metalloproteases that degrade extracellular matrix proteins have been implicated in the propensity of amyloid to accumulate. There is also strong evidence that glycosaminoglycans of the extracellular matrix—particularly heparan sulfate, but also dermatan sulfate and chondroitin sulfate, interact with amyloid protein, providing a scaffold for the polymerized amyloid fibrils [25]. The relative concentration of these glycosaminoglycans appears to impact on the propensity of amyloid to be deposited. It should be noted that in a recent series from China, Huang and Liu reported that immunoglobulin heavy chain amyloidosis accounted for 3.7% of cases of amyloidosis, as compared to AL amyloidosis accounting for 93% of cases. In that report, AA amyloidosis accounted for only 2.2% of all patients with systemic amyloidosis [26].

### *2.2.1 Polyclonal AL amyloidosis*

The Mayo Clinic pioneered the use of Mass Spectroscopy and High Performance Chromatography to identify the specific proteins present in amyloid tissue specimens. They have applied that technology to determine, from patient samples, whether a patient's amyloid is AA or AL, and to further characterize if an AL specimen is entirely kappa or lambda light chains—consistent with a monoclonal process; or if the AL amyloid is an approximately equal mix of both kappa and lambda light chains—suggesting a polyclonal process. In a 2013 report, Grogg and colleagues identified two patients with pulmonary amyloidosis in whom Liquid Chromatography-Mass Spectroscopy documented equal amounts of kappa and of lambda light chain in the amyloid deposits. In addition, the polyclonal identity of the amyloid was demonstrated by immunohistochemical staining for kappa and lambda light chains, and polymerase chain reaction amplification of immunoglobulin gene sequence showed only a polyclonal population in these patients [27]. In 2016, the Mayo Clinic studied in detail a patient with localized amyloidosis of the oropharynx. Liquid Chromatography and Mass Spectroscopy documented polyclonal AL amyloid, with equal proportions of kappa and lambda light chains present. No monoclonal protein was identified, and no monoclonal lymphoid or plasma cell population was present. Thus, this group has well documented the process of localized amyloidosis attributable to polyclonal light chain deposition. In that report they also summarized data regarding an additional 17 patients identified from the medical literature with isolated amyloidosis of the palate [28]. In three of those seventeen cases, a plasma cell dyscrasia was present (MGUS in two and myeloma in one). Similarly, Wey and colleagues from Taiwan reported a patient with Sjogren's syndrome complicated by localized, cutaneous nodular amyloidosis of the legs. In this case, C-reactive protein 0.12 mg/dL antinuclear antibody titer, anti-centromere antibody titer, and anti-Ro/SSA antibody titer were all pathologically elevated and polyclonal gammaglobulinemia was detected by serum immune-electrophoresis [29]. Thus, multiple investigators have substantiated the observation that AL amyloid can be polyclonal. Definitive data regarding the relative incidence of monoclonal versus polyclonal AL amyloid is not available. However, it does appear from these cases that polyclonal AL amyloidosis seems to be a more indolent process and less aggressive than AL amyloidosis, and is most often a localized process. In these cases, local therapy appears likely to control the disease. Nonetheless, there are documented cases of systemic polyclonal AL amyloidosis with multi-organ involvement and relatively poor prognosis as compared to age-matched individuals without amyloidosis.

Localized amyloidosis is much rarer than systemic amyloidosis, predominantly affects the skin or mucosal tissues (86%), and is usually of the AL subtype (98%). It is generally accepted that localized AL amyloidosis results from monoclonal light chains. However, the most recent amyloid nomenclature developed by the International Society of Amyloidosis in 2014 does not distinguish between monoclonal and polyclonal sources.

### *2.2.2 Monoclonal AL amyloidosis*

In contrast to polyclonal AL amyloidosis, monoclonal AL amyloidosis is typically an aggressive, multi-organ disease with a generally poor prognosis. The disease process is driven by production of a monoclonal immunoglobulin light chain—hence the name AL (amyloid, light chain). As noted previously, only a minority of monoclonal light chain gammopathy results in amyloidosis. The exonic coding sequence for the specific light chain will most often have either a mutation, or a



polymorphism, that results in abnormal protein folding, in order for the light chain to be deposited as amyloid and cause organ dysfunction, as previously discussed. AL amyloid is found both extracellularly and intracellularly, in affected organs. Kyle and colleagues at the Mayo Clinic reported that the incidence of AL amyloid in Olmsted County, Minnesota, was in the range of 3–5 cases per million annually [30]. Others have estimated the annual incidence to be in the range of 10–14 patients per million. In contrast, it is estimated that the annual incidence of MGUS in men is 120 per 100,000 population at the age of 50 years, and increases to 530 per 100,000 population at the age of 90 years. The incidence of multiple myeloma is in the range of 85 cases per million annually in the United States. Thus, only a very small minority of patients with MGUS or overt multiple myeloma develop clinical AL amyloidosis. The average age at diagnosis of patients with AL amyloidosis is approximately 64. The disease appears to occur more commonly in males than females [31].

Presenting signs and symptoms of amyloidosis are the consequences of specific organ involvement. Cardiac involvement occurs in the majority of patients diagnosed as having AL amyloidosis, most typically presenting with symptoms and signs of heart failure syndrome but with a preserved left ventricular ejection fraction. In an excellent recent review, Gertz reported that 71% of patients with AL amyloidosis seen at the Mayo Clinic had cardiac involvement, with 58% having kidney disease [32]. Renal involvement most often includes nephrotic range proteinuria; in an early series reported by Kyle in 1975, of all patients reviewed in that series with any type of amyloidosis, approximately 90% had some degree of proteinuria. Neurologic involvement occurs in approximately 25% of patients, and may include peripheral neuropathies, including, most commonly carpet tunnel syndrome; or autonomic neuropathy—most prominently orthostatic hypotension but also including anhydrosis [33]. Organ enlargement is common, with as many as half of patients having hepatomegaly, and an enlarged tongue (macroglossia) occurs in approximately a quarter of patients. Kyle also described purpura, particularly periorbital purpura, as a notable finding.

AL amyloid is most commonly a systemic disorder. However, there are cases of AL amyloidosis localized to a single site. The sites of localized AL amyloid reported include the skin, the larynx, the gastrointestinal tract, and the urinary bladder. Diagnosis must be confirmed by tissue biopsy, in order to demonstrate the presence of the amyloid by Congo red histologic staining. When a clinician encounters a patient over the age of 60 with suspected systemic AL amyloidosis, serum protein electrophoresis is essential to determine if a monoclonal serum para-protein is present. If a monoclonal protein is either suspected or identified, then serum protein immune-electro fixation or immunoelectrophoresis is indicated. Once a monoclonal serum paraprotein is identified, bone marrow biopsy and aspirate should be obtained in order to assess the percentage of clonal plasma cells infiltrating of the marrow, and determine if the patient meets the criteria for diagnosis of multiple myeloma or a lymphoplasmacytic lymphoma. In patients with a clonal AL amyloid, treatment to eradicate the clone of plasma cells or lymphocytes producing the light chain, if successful, will prevent synthesis of new immunoglobulin light chains, and, if the patient can be supported to survive long enough, organ recovery may occur over time as the relatively insoluble amyloid is ultimately metabolized and broken down.

### *2.2.3 Clinical features of AL amyloidosis*

The clinical features of AL amyloidosis are extremely variable from one patient to the next; nearly every organ can potentially be involved. However, the disease has a stereotypic pattern of presentation in many cases. As noted earlier, systemic AL amyloidosis involves the heart in approximately 70–80% of cases, depending



on the series. The most common clinical presentation of symptomatic organic heart disease due to AL amyloidosis is heart failure syndrome, with dyspnea and often leg swelling (edema), although angina pectoris (chest pain due to ischemia) may also occur, as well as arrhythmias. Prior to onset of clinically evident heart disease, nearly all patients with cardiac involvement by amyloidosis will have an elevated serum level of N-terminal Pro-natriuretic peptide Type B (NT-ProBNP). Progressive elevation of the Pro-BNP correlates with progressively poorer prognosis, and the level of Pro-BNP is a criterion for risk stratification and prognosis in several staging systems for cardiac amyloidosis. Similarly, cardiac troponin T (cTnT) and cardiac troponin I (cTnI) are sensitive (although not specific) markers of myocardial damage. The degree of elevation of these proteins are additional markers of myocardial cell damage in cardiac amyloidosis [34]. A characteristic finding on electrocardiogram is decreased voltage in the limb leads, as compared to normal; however, this is not a consistent finding even in patients with biopsy proven cardiac amyloidosis. Imaging of the heart by echocardiogram may demonstrate the characteristic amyloidosis findings of pathologically increased ventricular wall thickness, as well as a granular, sparkling appearance of the myocardium on three-dimensional echocardiographic imaging. Again, there is the caveat that early in the disease process these findings may not be evident. A longitudinal “strain” pattern may also be present, but again is not a specific finding for amyloidosis [35]. Technetium-99 pyrophosphate scanning of the heart, particularly with single photon emission computed tomography (SPECT), is a sensitive imaging technique that will show retention of the radionuclide in cases of cardiac amyloidosis; this is widely considered a diagnostic study of choice. Technetium-99 pyrophosphate scanning of the heart can often distinguish between ATTR amyloid and AL amyloid. Magnetic Resonance Imaging of the heart using the contrast agent gadolinium for enhancement, a more costly approach than echocardiogram or Technetium-99 scan, can provide evidence of cardiac amyloidosis. Delayed enhancement pulse sequences following infusion of the gadolinium will most often demonstrate a diffuse and irregular hyper-enhancement of the myocardium in patients with cardiac amyloidosis. Subendocardial late gadolinium enhancement (LGE) occurs more commonly in AL amyloidosis, and transmural LGE more commonly in ATTR cardiac amyloidosis. In this context, even greater specificity may be achieved using a Magnetic Resonance Imaging technique termed “myocardial nulling.” This technique exploits the observation that gadolinium contrast accumulates excessively and abnormally in myocardial tissue, that has accumulated amyloid, and the findings are quite specific for amyloidosis of the heart.

Several groups have developed staging systems that stratify cardiac prognosis in patients with AL amyloidosis. The Mayo Clinic group Cardiac Staging System stratifies patients based on the combination of NT-proBNP together with either the cTnT or the cTnI. These parameters may be used to assess prognosis at the time of initial diagnosis, and often form a part of eligibility criteria for clinical trials [36].

As noted, clinically evident heart disease in AL amyloidosis manifests most often as congestive heart failure syndrome, despite preservation of the left ventricular ejection fraction. The symptoms most often include fatigue and exertional dyspnea, as well as edema due to heart failure, in some cases. Signs may include a lateral shift of the cardiac point of maximal impulse, as well as adventitious heart sounds and murmurs. Cardiomegaly may be evident on chest radiogram. Due to amyloid deposition, a fraction of patients will have electrical conduction abnormalities, and resultant cardiac arrhythmias. Such arrhythmias may result in sudden cardiac death, if the abnormal rhythm does not result in non-lethal signs or symptoms first.

Second to cardiac manifestations, the most common organ clinically involved by systemic AL amyloidosis are the kidneys. Kidney disease due to amyloid seen in

approximately 50–60% of patients, depending on the series. The organ tropism of AL amyloid correlates with the variable region gene sequence, and the IGLV6-57 gene sequence appears to predispose to renal involvement. Within the affected kidney, amyloid deposits are seen prominently in the glomeruli, with additional amyloid seen in blood vessels, in tubular-basement membranes, and in the interstitial space. Uptake of amyloid by mesangial cells induces a functional change in phenotype resulting in cellular dysfunction. In experimental models, uptake of amyloid results in a transformation of a mesangial cell from a smooth muscle cells to a macrophage phenotype. Renal dysfunction clinically is typically manifest first as a protein wasting process, which typically progresses to nephrotic range proteinuria. Nephrotic range proteinuria results in edema and with time leads to chronic kidney disease with progressive edema, followed by electrolyte disorders and progressively worsening glomerular filtration rate [37]. Because of urinary loss of natural anticoagulants such as Protein C, which has a relatively short half-life, venous thrombosis may occur in patients with Amyloidosis and renal disease. Both renal involvement by AL amyloidosis, and cardiac disease due to AL amyloidosis, contribute to the generalized weakness experienced by a majority of patients who have AL amyloidosis.

The nervous system is clinically involved in AL amyloidosis in approximately 20% of patients. The most common neurologic process seen is a sensory peripheral neuropathy, which is often painful. Dysautonomia is also seen, particularly manifesting as orthostatic hypotension due to amyloid damaging the autonomic regulation of blood pressure. Orthostatic hypotension can be disabling, and may result in falls and therefore fractures. Patients with severe orthostatic hypotension may remain bedridden to avoid symptoms, and are then at risk both for developing decubitus ulcers, as well as venous thromboses. Myopathy may also occur because of AL amyloid deposition, and may present as pseudo-hypertrophy, or may clinically mimic other muscle wasting diseases [38].

The gastrointestinal tract is involved by AL amyloidosis. In a recent report from Stanford University Medical Center, Yen and colleagues reported that in a retrospective analysis of 583 patients with amyloidosis, approximately 16% had gastrointestinal symptoms. They observed that 50% of patients with amyloid had nausea, vomiting, or abdominal pain. In this cohort, approximately 82% of patients had AL amyloid. A classic finding reported in the earliest descriptions of amyloidosis is macroglossia, an enlarged tongue. However, it is estimated that this is seen in only about 15% of patients [39]. Malabsorption is often seen in amyloidosis of the gastrointestinal tract, with consequence diarrhea, abdominal discomfort, and weight loss on this basis.

Patients with kappa light chain AL amyloidosis have been reported to have a greater propensity for hepatic involvement than lambda light chain amyloidosis [40]. In contrast, dominant soft-tissue and bone involvement is associated with the IGLV3-1 gene, and in some reports, the Kappa 1 light chain. Hepatic involvement is typically manifest as hepatomegaly, and biopsy typically documents the presence of amyloid [41]. Splenomegaly is also common, particularly when hepatomegaly is present, and splenomegaly may result in blood cell sequestration in the spleen, with cytopenias.

Amyloid infiltration has been reported in virtually every gland, although these reports suggest that direct endocrine dysfunction due to amyloidosis is relatively less common than involvement by the heart, kidneys, and neurologic systems [42]. Amyloidosis of the breast have been reported, as well as amyloidosis of the seminal vesicles also occurs. Amyloidosis can infiltrate the pancreas, and amyloid infiltration of the adrenal gland may result in adrenal insufficiency. Similarly, amyloid infiltration of the pituitary gland can result in polyendocrine dysfunction.

Cutaneous AL amyloidosis is well described, and most often presents as either hemorrhagic bullous lesions, or, classically, as purpura or ecchymosis. Among the early classic descriptions of cutaneous manifestations of amyloidosis is the phenomenon of periorbital purpura [43].

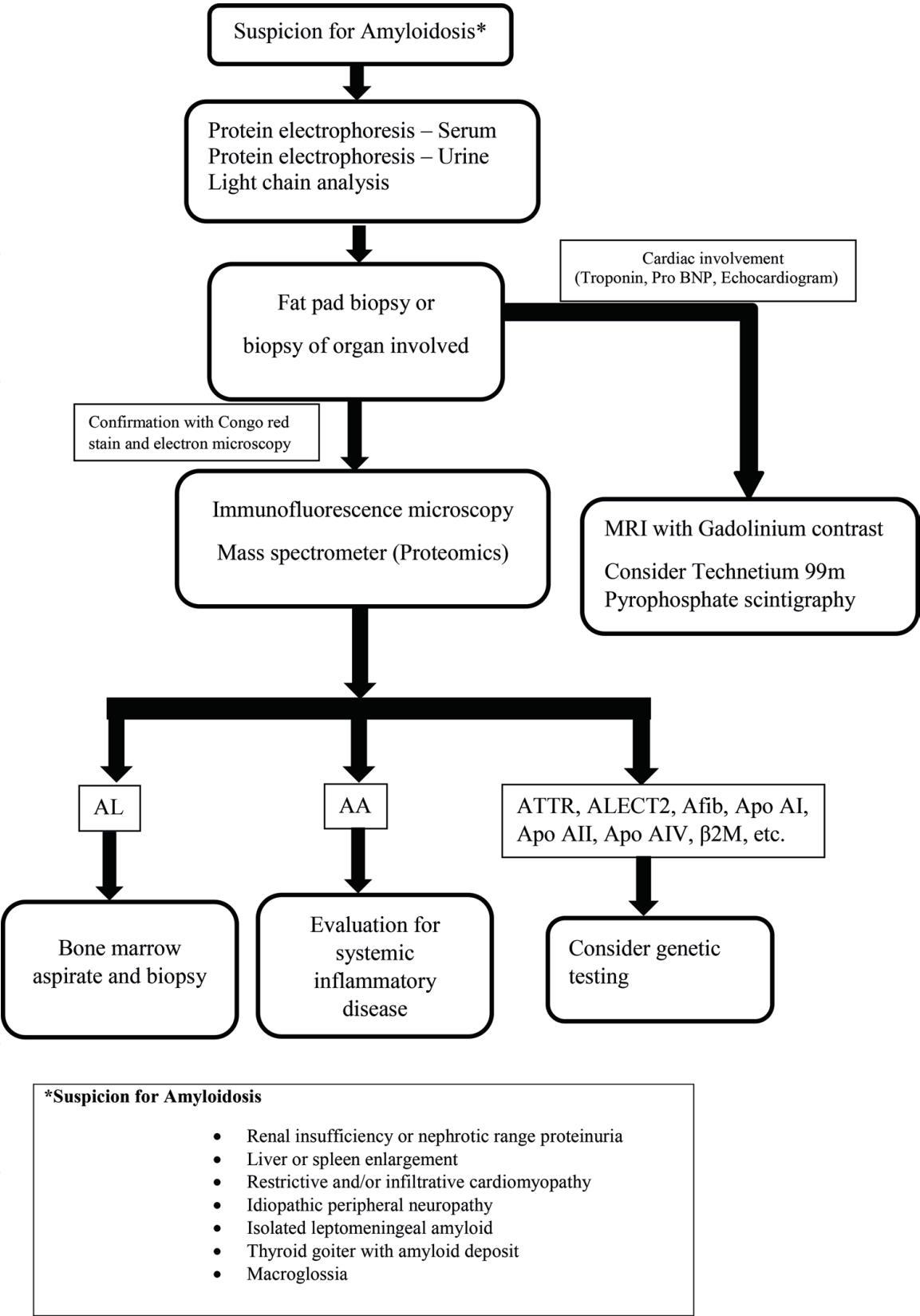
Patients with AL amyloidosis may have one or more acquired coagulopathies, resulting in a bleeding diathesis. This may be due to impaired synthesis of clotting proteins by a liver involved by amyloid infiltration; however, adsorption of coagulation proteins, most commonly Factor X, but other factors as well, results in increased clearance of coagulation proteins and a bleeding disorder. Other than Factor X, adsorption of Factor V and of von Willebrand factor have been reported in a number of series. In such cases, frequent infusion of the deficient factor can temporarily control bleeding [44]. An algorithm for diagnostic evaluation is seen in **Figure 2**.

#### *2.2.4 Treatment of AL amyloidosis*

Management of AL amyloidosis is, in the first instance, management of end-organ dysfunction, with the goal to support the patient. However, definitive therapy requires eradication of the clone of B cells producing the immunoglobulin light chains that are misfolded and deposited as amyloid. Clinical trials have documented that the combination of the alkylating anti-neoplastic agent L-phenylalanine mustard (Melphalan) together with a potent corticosteroid such as Prednisone or Dexamethasone, can suppress production of new light chains, and, with adequate time, alter the balance of production and very slow degradation of AL amyloid. High dose Melphalan with autologous hematopoietic rescue was compared to conventional dose Melphalan plus dexamethasone in a prospective, randomized clinical trial published in 2007 [45]. That study reported inferior survival for patients randomized to high dose chemotherapy with autologous hematopoietic rescue (autologous transplant). However, in the past decade, the morbidity and mortality from autologous transplant has declined, and the risk-benefit ratio appears to have improved. An analysis by the Center for International Blood and Marrow Transplant Research (CIBMTR) published in 2015 reported that five-year overall survival following autologous transplant for AL amyloidosis had improved from 55% during the period of 1995–2000, to 77% in the time period from 2007 to 2012. Thus, outcome for transplant now appears superior to outcome from conventional dose anti-neoplastic therapy [46]. However, there have been no new prospective randomized clinical trials of autologous transplant versus non-transplant therapy. Newer therapies that are effective in reducing the burden of neoplastic plasma cells producing AL amyloid include proteasome inhibitors, and monoclonal antibodies that target plasma cells, such as daratumumab, an anti-CD38 monoclonal antibody. There are being studied, with promising results; however, no mature randomized data is available as of this writing from use of the agents. Anti-SAP antibody is a promising modality that appears to remove AL amyloid with relative efficiency; however, this agent remains investigational as of this writing [47].

### **2.3 ATTR amyloidosis**

Hereditary transthyretin amyloidosis is an autosomal dominant, progressive, life-threatening disease caused by mutations in the gene encoding transthyretin. Transthyretin (TTR) is a homotetramer plasma transport protein secreted primarily by liver but also in retinal pigment epithelium and choroid plexus. It functions to transport thyroxine and retinol-binding protein and hence the name transthyretin [48]. ATTR amyloidosis results from deposition of abnormal TTR protein, which is a result of destabilized TTR-tetramer misfolding and fibril formation. ATTR



**Figure 2.**  
*Diagnostic algorithm of systemic amyloidosis.*

amyloidosis can be hereditary or wild type. There are more the 130 mutations identified worldwide in the hereditary form with the most common being Val30Met mutation [49]. ATTR amyloidosis is a rare disease but recently it has been identified more commonly from advances in diagnostics. Wild type ATTR, occasionally called senile systemic amyloidosis because of the late age of onset is reported at an incidence of 10% in people more than 80 years of age [50].



### 2.3.1 Clinical features of ATTR amyloidosis

Phenotypically the ATTR results in clinical syndrome with respect to the organ involved. The three main clinical entities are polyneuropathy, cardiomyopathy and leptomeningeal disease. Fiber length-dependent neuropathy is pathognomonic of the disease. In the initial phase, small fiber neuropathy results in pain, paresthesia, allodynia, hyperalgesia, dysesthesia and impaired sensation to temperature. In later stages, large fiber dysfunction results in loss of vibration sense and balance, ultimately leading to difficulty with ambulation from progressive motor weakness [51]. Autonomic dysfunction results in orthostatic hypotension, neurogenic bladder, sexual dysfunction and gastrointestinal symptoms such as diarrhea and/or constipation [52]. Some patients with wild type ATTR develop carpal tunnel syndrome as their initial presentation and are also related to specific TTR mutations such as Leu58His, Ile84Ser and Tyr114His [53].

Familial amyloid cardiomyopathy occurs commonly with Val122Ile TTR mutation and they present with EKG abnormalities, heart failure, intractable arrhythmias and conduction abnormalities. Echocardiogram reveals a granular sparkling with ventricular and septal wall thickening [54]. MRI can show a classical late gadolinium enhancement but cardiac scintigraphy by Technetium-99 m pyrophosphate has the highest sensitivity and specificity in diagnosis [55]. Leptomeningeal amyloidosis occurs in patients with Asp18Gly, Ala25Thr and Tyr114Cys mutations. TTR protein is secreted by choroid plexus and gets deposited in cerebral and subarachnoid blood vessels and leptomeninges [49, 56]. Symptoms include transient ischemic attack, cerebral infarction or hemorrhage, subarachnoid hemorrhage, hydrocephalus, ataxia, spastic paralysis, convulsion, and dementia. Isolated leptomeningeal involvement is infrequent and occurs in patients harboring Val30Met mutation [57]. Ocular, renal and isolated gastrointestinal involvements are also reported in ATTR amyloidosis.

### 2.3.2 Treatment of ATTR amyloidosis

Once untreatable, hereditary ATTR amyloidosis is now primarily treated with liver transplantation, especially in Japan where it has shown better survival benefit and life expectancy. Liver transplantation is not widely practiced outside Japan due to low availability of living donors [58]. The transplantation replaces the abnormal TTR protein to a wild type protein. Overall studies have shown better outcomes in patients with early disease and Val30Met mutation compared to late onset and non-Val30Met patients. Leptomeningeal disease and retinal involvement do not improve by liver transplantation. Cardiac involvement continues to progress even after liver transplantation in some cases due to deposition of wild type ATTR.

Although liver transplantation has better outcome, not all patients are eligible due to advanced disease and multiple other sites of involvement. The tetramer destabilization is the initial step in the process of amyloid fibril formation and this was studied as a potential for treatment. Tafamidis, a benzoxazole derivative binds to thyroxine-binding sites of transthyretin and inhibits the dissociation of tetramers thereby blocking the rate-limiting step in monomer formation. In a randomized double-blinded phase II/III study in patients with polyneuropathy, Tafamidis did not meet the co-primary endpoints in the intention to treat population but did show significant improvement of neuropathy improvement score and quality of life in efficacy-evaluable population [59]. In another Phase III study for patients with ATTR related cardiomyopathy, Tafamidis was superior to placebo in decreasing the all-cause mortality and cardiovascular-related hospitalizations [60]. It is approved in both Europe and Japan for use in familial amyloid polyneuropathy and received

FDA approval in the United States in 2018 for treatment of transthyretin cardiomyopathy. Difunisal, a nonsteroidal anti-inflammatory drug used to treat pain and osteoarthritis was studied as an agent to stabilize the amyloid tetramer. It functions by binding to the T4 binding site in TTR. In a phase II/III study it had significant improvement in neuropathy score in patients with amyloid polyneuropathy [61].

RNA interference is a phenomenon in which the gene expression is blocked by small RNA molecules. This approach has been studied in several diseases by introducing a small RNA into the cell and obscures a gene hence forth potentially inactivating the gene. Partisan is a RNA interference molecule developed to block production of abnormal TTR protein in liver. In a phase III trial, patients with hereditary transthyretin amyloidosis neuropathy received Partisan (dose 0.3 mg/kg every 3 weeks) and had statistically significant improvement in modified Neuropathy Impairment Score+7 [62].

Antisense oligonucleotides (ASO) are chemically modified oligonucleotides designed to selectively bind the RNA in the cell and prevent the target protein expression by interfering with translation. A phase III trial is ongoing for ISIS-TTRRx, an ASO specific to TTR mRNA [63].

## Author details

Aswanth Reddy, Enrique Ballesteros and Jonathan Scott Harrison\*  
University of Connecticut, Farmington, CT, USA

\*Address all correspondence to: [joharrison@uchc.edu](mailto:joharrison@uchc.edu)

## IntechOpen

© 2018 The Author(s). Licensee IntechOpen. This chapter is distributed under the terms of the Creative Commons Attribution License (<http://creativecommons.org/licenses/by/3.0>), which permits unrestricted use, distribution, and reproduction in any medium, provided the original work is properly cited. 

## References

- [1] Lane T, Pinney JH, Gilbertson JA, Hutt DF, Rowczenio DM, Mahmood S, et al. Changing epidemiology of AA amyloidosis: Clinical observations over 25 years at a single national referral Centre. *Amyloid*. 2017;**24**:162-166. DOI: 10.1080/13506129.2017.1342235
- [2] Lachmann H, Goodman HJB, Gilbertson J, Gallimore R, Sabin C, Gillmore J, et al. Natural history and outcome in systemic AA amyloidosis. *The New England Journal of Medicine*. 2007;**356**:2361-2371. DOI: 10.1056/NEJMoa070265
- [3] Obici L, Raimondi S, Lavatelli F, Bellotti V, Merlini G. Susceptibility to AA amyloidosis in rheumatic diseases: A critical overview. *Arthritis and Rheumatism*. 2009;**61**:1435-1440. DOI: 10.1002/art.24735
- [4] Husby G, Marhaug G, Dowton B, Sletten K, Sipe JD. Serum amyloid A (SAA): Biochemistry, genetics and the pathogenesis of AA amyloidosis. *Amyloid*. 1994;**1**:119-137. DOI: 10.3109/13506129409148635
- [5] Kisilevsky R, Manley P. Acute-phase serum amyloid A: Perspectives on its physiological and pathological roles. *Amyloid*. 2012;**19**:5-14. DOI: 10.3109/13506129.2011.654294
- [6] Booth DR, Booth SE, Gillmore JD, Hawkins PN, Pepys MB. SAA1 alleles as risk factors in reactive systemic AA amyloidosis. *Amyloid*. 1998;**5**:262-265. DOI: 10.3109/13506129809007299
- [7] Noborn F, Ancsin JB, Ubhayasekera W, Kisilevsky R, Li JP. Heparan sulfate dissociates serum amyloid A (SAA) from acute-phase high-density lipoprotein, promoting SAA aggregation. *The Journal of Biological Chemistry*. 2012;**287**:25669-25677. DOI: 10.1074/jbc.M112.363895
- [8] Larsen CP, Kossmann RJ, Beggs ML, Solomon A, Walker PD. Clinical, morphologic, and genetic features of renal leukocyte chemotactic factor 2 amyloidosis. *Kidney International*. 2014;**86**:378-382. DOI: 10.1038/ki.2014.11
- [9] Benson MD, James S, Scott K, Liepnieks JJ, Kluve-Beckerman B. Leukocyte chemotactic factor 2: A novel renal protein. *Kidney International*. 2008;**74**:218-222. DOI: 10.1038/ki.2008.152
- [10] Das M, Gursky O. Amyloid-forming properties of human apolipoproteins: Sequence analyses and structural insights. *Advances in Experimental Medicine and Biology*. 2015;**855**:175-211. DOI: 10.1007/978-3-319-17344-3\_8
- [11] Enríquez R, Sirvent AE, Padilla S, Noguera-Pons R, Andrada E, Ardoy F, et al. Nephrotic syndrome and AA amyloidosis revealing adult-onset cryopyrin-associated periodic syndrome. *Renal Failure*. 2013;**35**:738-741. DOI: 10.3109/0886022X.2013.790300
- [12] Dubrey S, Cha K, Simms R, Skinner M, Falk R. Electrocardiography and Doppler echocardiography in secondary (AA) amyloidosis. *The American Journal of Cardiology*. 1996;**77**:313-315. DOI: 10.1016/S0002-9149(97)89403-9
- [13] Lagha EK, M'sakni I, Bougrine F, Laabidi B, Ghachem DB, Bouziani A. Amyloid goiter: First manifestation of systemic amyloidosis. *European Annals of Otorhinolaryngology, Head and Neck Diseases*. 2010;**127**:134-136. DOI: 10.1016/j.anorl.2010.02.013
- [14] Ugurlu S, Hacıoglu A, Adibnia Y, Hamuryudan V, Ozdogan H. Tocilizumab in the treatment of twelve cases with aa amyloidosis secondary to

familial mediterranean fever. Orphanet Journal of Rare Diseases. 2017;**12**:105. DOI: 10.1186/s13023-017-0642-0

[15] Dember LM, Hawkins PN, Hazenberg B, Gorevic PD, Merlini G, Butrimiene I, et al. Eprodisate for the treatment of renal disease in AA amyloidosis. The New England Journal of Medicine. 2007;**356**:2349-2360. DOI: 10.1056/NEJMoa065644

[16] Press Release JUNE 20, 2016. BELLUS Health Announces Top-Line Phase 3 Results of KIIACTA™ for the Treatment of AA Amyloidosis

[17] Amemori S, Iwakiri R, Endo H, Ootani A, Ogata S, Noda T, et al. Oral dimethyl sulfoxide for systemic amyloid A amyloidosis complication in chronic inflammatory disease: A retrospective patient chart review. Journal of Gastroenterology. 2006;**41**:444-449. DOI: 10.1007/s00535-006-1792-3

[18] Pepys MB, Herbert J, Hutchinson WL, Tennent GA, Lachmann HJ, Gallimore JR, et al. Targeted pharmacological depletion of serum amyloid P component for treatment of human amyloidosis. Nature. 2002;**417**:254-259. DOI: 10.1038/417254a

[19] Richards DB, Cookson LM, Barton SV, Liefwaard L, Lane T, Hutt DF, et al. Repeat doses of antibody to serum amyloid P component clear amyloid deposits in patients with systemic amyloidosis. Science Translational Medicine. 2018;**10**:3128. DOI: 10.1126/scitranslmed.aan3128

[20] Merlini G, Bellotti V. Molecular mechanisms of amyloidosis. The New England Journal of Medicine. 2003;**349**:583-596

[21] Perfetti V, Casarini S, Palladini G, et al. Analysis of V(lambda)-J(lambda) expression in plasma cells from primary (AL) amyloidosis and normal bone

marrow identifies 3r (lambdaIII) as a new amyloid-associated germline gene segment. Blood. 2002;**100**:948-953

[22] Perfetti V, Ubbiali P, Vignarelli MC, et al. Evidence that amyloidogenic light chains undergo antigen-driven selection. Blood. 1998;**91**:2948-2954

[23] Hurle MR, Helms LR, Li L, Chan W, Wetzel R. A role for destabilizing amino acid replacements in light-chain amyloidosis. Proceedings of the National Academy of Sciences of the United States of America. 1994;**91**:5446-5450

[24] Stevens FJ. Four structural risk factors identify most fibril-forming kappa light chains. Amyloid. 2000;**7**:200-211

[25] McLaurin J, Yang D, Yip CM, Fraser PE. Modulating factors in amyloid-beta fibril formation. Journal of Structural Biology. 2000;**130**:259-270

[26] Huang X-H, Liu Z-H. The clinical presentation and management of systemic light-chain amyloidosis in China. Kidney Diseases. 2016;**2**:1-9

[27] Grogg KL, Aubry MC, Vrana JA, Theis JD, Dogan A. Nodular pulmonary amyloidosis is characterized by localized immunoglobulin deposition and is frequently associated with an indolent B-cell lymphoproliferative disorder. American Journal of Surgical Pathology. 2013;**37**:406-412

[28] Ravindran A, Grogg KL, Domaas DA, Go RS. Polyclonal localized light chain amyloidosis—A distinct entity. Clinical Lymphoma, Myeloma & Leukemia. 2016;**16**:588-592

[29] Wey SJ, Chen YM, Lai PJ, Chen DY. Primary Sjogren syndrome manifesting as localized cutaneous nodular amyloidosis. Journal of Clinical Rheumatology. 2011;**17**:368-370



- [30] Kyle RA, Linos A, Beard CM, et al. Incidence and natural history of primary systemic amyloidosis in Olmsted County, Minnesota, 1950 through 1989. *Blood*. 1992;**79**:1817-1822
- [31] Nienhuis HLA, Bijzet J, Hazenberg BPC. The prevalence and management of systemic amyloidosis in western countries. *Kidney Diseases*. 2016;**2**:10-19
- [32] Gertz MA. Immunoglobulin light chain amyloidosis diagnosis and treatment algorithm 2018. *Blood Cancer Journal*. 2018;**8**:44-56
- [33] Kyle RA, Bayrd ED. Amyloidosis: Review of 236 cases. *Medicine (Baltimore)*. 1975;**54**:271-299
- [34] Aimo A, Buda G, Fontana M, et al. Therapies for cardiac light chain amyloidosis: An update. *International Journal of Cardiology*. 2018;**271**:152-160
- [35] Tuzovic M, Yang EH, Baas AS, et al. Cardiac amyloidosis: Diagnosis and treatment strategies. *Current Oncology Reports*. 2017;**19**:46-57
- [36] Dispenzieri A, Gertz MA, Kyle RA, et al. Serum cardiac troponins and N-terminal pro-brain natriuretic peptide: A staging system for primary systemic amyloidosis. *Journal of Clinical Oncology*. 2004;**22**:3751-3757
- [37] Zhang C, Huang X, Li J. Light chain amyloidosis: Where are the light chains from and how they play their pathogenic role? *Blood Reviews*. 2017;**31**:261-270
- [38] Gertz MA, Kyle RA. Myopathy in primary systemic amyloidosis. *Journal of Neurology, Neurosurgery, and Psychiatry*. 1996;**60**:655-660
- [39] Yen T, Chen FW, Witteles RM, et al. Clinical implications of gastrointestinal symptoms in systemic amyloidosis. *Neurogastroenterology and Motility*. 2018;**30**:e3229
- [40] Rowe K, Pankow J, Nehme F, Salyers W. Gastrointestinal amyloidosis: Review of the literature. *Cureus*. 2017;**8**:e1228
- [41] Matsuda S, Motosugi U, Kato R, et al. Hepatic amyloidosis with an extremely high stiffness value on magnetic resonance elastography. *Magnetic Resonance in Medical Sciences*. 2016;**15**:251-252
- [42] Ozdemir D, Dagdelen S, Erbas T. Endocrine involvement in systemic amyloidosis. *Endocrine Practice*. 2010;**16**:1056-1063
- [43] Rubinow A, Cohen AS. Skin involvement in generalized amyloidosis: A study of clinically involved and uninvolved skin in 50 patients with primary and secondary amyloidosis. *Annals of Internal Medicine*. 1978;**88**:781-785
- [44] Harrison JS, Frazier SR, McConnell DD, et al. Evidence of both von Willebrand factor deposition and factor V deposition onto AL amyloid as the etiology of a severe bleeding diathesis. *Blood Coagulation & Fibrinolysis*. 2017;**28**:342-347
- [45] Jaccard A, Moreau P, Leblond V, et al. High-dose melphalan versus melphalan plus dexamethasone for AL amyloidosis. *The New England Journal of Medicine*. 2007;**57**:1083-1093
- [46] D'Souza A, Dispenzieri A, Wirk B, et al. Improved outcomes after autologous hematopoietic cell transplantation for light chain amyloidosis: A Center for International Blood and Marrow Transplant Research Study. *Journal of Clinical Oncology*. 2015;**33**:3741-3749
- [47] Milani P, Merlini G, Palladini G. Light chain amyloidosis. *Mediterranean Journal of Hematology and Infectious Diseases*. 2018;**10**(1):e2018022. DOI: 10.4084/MJHID.2018.022
- [48] Hamilton J, Benson M. Transthyretin: A review from a

structural perspective. *Cellular and Molecular Life Sciences*. 2001;**58**:1491. DOI: 10.1007-PL00000791

[49] Sekijima Y, Ueda M, Koike H, Misawa S, Ishii T, Ando Y. Diagnosis and management of transthyretin familial amyloid polyneuropathy in Japan: Red-flag symptom clusters and treatment algorithm. *Orphanet Journal of Rare Diseases*. 2018;**13**:6. DOI: 10.1186/s13023-017-0726-x

[50] Ueda M, Horibata Y, Shono M, Misumi Y, Oshima T, Su Y, et al. Clinicopathological features of senile systemic amyloidosis: An ante- and post-mortem study. *Modern Pathology*. 2011;**24**:1533-1544. DOI: 10.1038/modpathol.2011.117

[51] Koike H, Misu K, Sugiura M, Iijima M, Mori K, Yamamoto M, et al. Pathology of early- vs late-onset TTR Met30 familial amyloid polyneuropathy. *Neurology*. 2004;**63**:129-138

[52] Koike H, Tanaka F, Hashimoto R, et al. Natural history of transthyretin Val30Met familial amyloid polyneuropathy: Analysis of late-onset cases from non-endemic areas. *Journal of Neurology, Neurosurgery, and Psychiatry*. 2012;**83**:152-158. DOI: 10.1136/jnnp-2011-301299

[53] Sekijima Y, Yoshida K, Tokuda T, et al. Familial Transthyretin Amyloidosis in: *GeneReviews at GeneTests: Medical Genetics Information Resource [Database Online]* Copyright. Seattle: University of Washington; 1993-2014. <http://www.ncbi.nlm.nih.gov/books/NBK1194>

[54] Ruberg FL, Berk JL. Transthyretin (TTR) cardiac amyloidosis. *Circulation*. 2012;**126**:1286-1300. DOI: 10.1161/CIRCULATIONAHA.111.078915

[55] Bokhari S, Castano A, Pozniakoff T, Deslisle S, Latif F, Maurer MS. (99m)Tc pyrophosphate scintigraphy for differentiating

light-chain cardiac amyloidosis from the transthyretin-related familial and senile cardiac amyloidoses. *Circulation. Cardiovascular Imaging*. 2013;**6**:195-201. DOI: 10.1161/CIRCIMAGING.112.000132

[56] Jin K, Sato S, Takahashi T, et al. Familial leptomeningeal amyloidosis with a transthyretin variant Asp18Gly representing repeated subarachnoid haemorrhages with superficial siderosis. *Journal of Neurology, Neurosurgery & Psychiatry*. 2004;**75**:1463-1466. DOI: 10.1136/jnnp.2003.029942

[57] Maia LF, Magalhaes R, Freitas J, et al. CNS involvement in V30M transthyretin amyloidosis: Clinical, neuropathological and biochemical findings. *Journal of Neurology, Neurosurgery, and Psychiatry*. 2014;**86**:159-167. DOI: 10.1136/jnnp-2014-308107

[58] Sekijima Y. Transthyretin (ATTR) amyloidosis: Clinical spectrum, molecular pathogenesis and disease-modifying treatments. *Journal of Neurology, Neurosurgery, and Psychiatry*. 2015;**86**:1036-1043. DOI: 10.1136/jnnp-2014-308724

[59] Coelho T, Maia LF, Martins da Silva A, et al. Tafamidis for transthyretin familial amyloid polyneuropathy: A randomized, controlled trial. *Neurology*. 2012;**79**:785-792. DOI: 10.1212/WNL.0b013e3182661eb1

[60] Maurer MS, Schwartz JH, Gundapaneni B, et al. Tafamidis treatment for patients with transthyretin amyloid cardiomyopathy. *The New England Journal of Medicine*. 2018;**379**:1007-1016. DOI: 10.1056/NEJMoa1805689

[61] Berk JL, Suhr OB, Obici L, Sekijima Y, Zeldenrust SR, Yamashita T, et al. Repurposing diflunisal for familial amyloid polyneuropathy: A randomized clinical trial. *JAMA*. 2013;**310**:2658-2667. DOI: 10.1001/jama.2013.283815

- [62] Adams D, Gonzalez-Duarte A, O’Riordan WD, et al. Patisiran, an RNAi therapeutic, for hereditary transthyretin amyloidosis. *New England Journal of Medicine*. 2018;**379**:11-21. DOI: 10.1056/NEJMoa1716153
- [63] Millns H, Bergemann R, Ackermann E, Monia B, Lukas MA. A phase 3 clinical trial with ISIS-TTRRx, a 2nd-generation antisense oligonucleotide targeting transthyretin (TTR), for the treatment of TTR amyloid cardiomyopathy. *Orphanet Journal of Rare Diseases*. 2015;**10**:8. DOI: 10.1186/1750-1172-10-S1-P8
- [64] Girnius S, Dember L, Doros G, Skinner M. The changing face of AA amyloidosis: A single center experience. *Amyloid*. 2011;**18**:226-228. DOI: 10.3109/13506129.2011.574354085
- [65] Simms RW, Prout MN, Cohen AS. The epidemiology of AL and AA amyloidosis. *Baillière's Clinical Rheumatology*. 1994;**8**:627-634. DOI: 10.1016/S0950-3579(05)80119-0
- [66] Bunker D, Gorevic P. AA amyloidosis: Mount Sinai experience, 1997-2012. *Mount Sinai Journal of Medicine*. 2012;**79**:749-756. DOI: 10.1002/msj.21342
- [67] Oh YB, Bae SC, Jung JH, Kim TH, Jun JB, Jung SS, et al. Secondary renal amyloidosis in adult onset Still's disease: Case report and review of the literature. *The Korean Journal of Internal Medicine*. 2000;**15**:131-134. DOI: 10.3904/kjim.2000.15.2.131
- [68] Harzallah A, El Jery HK, Hajji M, Mami I, Goucha R, Turki S, et al. Amyloidosis complicating Behcet's disease. *Open Journal of Clinical Diagnostics*. 2016;**6**:42-46. DOI: 10.4236/ojcd.2016.63008
- [69] Gaduputi V, Tariq H, Badipatla K, Ihimoyan A. Systemic reactive amyloidosis associated with Castleman's disease. *Case Reports in Gastroenterology*. 2013;**12**:476-481. DOI: 10.1159/000356825
- [70] Georgin-Lavialle S, Stankovic Stojanovic K, Buob D, et al. French amyloidosis CAPS study: AA amyloidosis complicating cryopyrin-associated periodic syndrome: A study on 14 cases and review of 53 cases from literature. *Pediatric Rheumatology Online Journal*. 2015;**13**:32. DOI: 10.1186/1546-0096-13-S1-P32
- [71] Sanz-Martín N, Samillán-Sosa Kdel R, De Miguel J, Martínez-Miguel P. Renal amyloidosis in leprosy, an infrequent cause of nephrotic syndrome in Europe. *BML Case Reports*. 2016;**3**:bcr2016216038. DOI: 10.1136/bcr-2016-216038
- [72] Balwani MR, Kute VB, Shah PR, Wakhare P, Trivedi HL. Secondary renal amyloidosis in a patient of pulmonary tuberculosis and common variable immunodeficiency. *Journal of Nephropharmacology*. 2015;**4**:69-71
- [73] Akçay S, Akman B, Ozdemir H, Eyüboğlu FO, Karacan O, Ozdemir N. Bronchiectasis-related amyloidosis as a cause of chronic renal failure. *Renal Failure*. 2002;**24**:815-823
- [74] Azzopardi JG, Lehner T. Systemic amyloidosis and malignant disease. *Journal of Clinical Pathology*. 1966;**19**:539-548
- [75] Gueutin V, Langlois AL, Shehwaro N, Elharraqui R, Rouvier P, Izzedine H. Nephrotic syndrome associated with lung Cancer: A rare case of malignancy associated with AA amyloidosis. *Case Reports in Nephrology*. 2013;**2013**:831903 10.1155/2013/831903
- [76] Husby G, Marhaug G, Sletten K. Amyloid A in systemic amyloidosis associated with cancer. *Clinical investigations. AACR*. 1982;**42**:1600-1603