

We are IntechOpen, the world's leading publisher of Open Access books Built by scientists, for scientists

6,900

Open access books available

185,000

International authors and editors

200M

Downloads

Our authors are among the

154

Countries delivered to

TOP 1%

most cited scientists

12.2%

Contributors from top 500 universities



WEB OF SCIENCE™

Selection of our books indexed in the Book Citation Index
in Web of Science™ Core Collection (BKCI)

Interested in publishing with us?
Contact book.department@intechopen.com

Numbers displayed above are based on latest data collected.
For more information visit www.intechopen.com



The Role of Imaging in Age-Related Macular Degeneration

Andi Arus Victor

Abstract

Age-related macular degeneration (ARMD) is the leading cause of blindness affecting adults. The disease alters the macula, center of the retina, responsible for the keenest vision. Although ARMD is part of the aging process, the exact pathophysiology is still unknown. The evidence suggests that oxidative stress, lipofuscin accumulation, drusen accumulation, chronic inflammation, choroidal neovascularization, and mutations of the complement contribute to the development of ARMD. Early recognition and prompt treatment halt the progression of the disease. The advanced technology in imaging modalities provides comprehensive and complete management at the earliest stage of ARMD.

Keywords: macular degeneration, age-related macular degeneration, imaging, fundus photography, fundus autofluorescence, fundus fluorescence angiography, indocyanine green angiography, optical coherence tomography, optical coherence tomography angiography

1. Introduction

Macular degeneration or age-related macular degeneration (ARMD) is the leading cause of blindness affecting elder individuals. In 2004, it was estimated that 1.75 million people over 40 years old in the USA develop ARMD, and the number is expected to increase twice the number in the next decades [1]. The prevalence of ARMD varies among ethnicity group. A study by Wong et al. gathered the pooled prevalence (age ranges from 45 to 85 years) was 8.69%, with the highest prevalence found in European decent 11.9% and the lowest among Asian decent 6.81% [2]. The progression of the disease is worsening with age, a systematic review of European studies found increasing trend of early ARMD prevalence from 3.5% in age group 55–59 years to 17.6% in age group >85 years old and from 0.1% in those aged 55–59 years to 9.8% in those aged >85 years old for late ARMD [3]. Thus, aging is the pivotal factors behind ARMD development and progression.

Age at diagnosis of ARMD is the key element to halt ARMD progression [4]. Advancement in technology of imaging modalities provides a comprehensive and complete examination of the ocular condition at the earliest stage of ARMD. Imaging modalities include fundus photography, fundus fluorescence angiography, indocyanine green angiography (ICGA), fundus autofluorescence, optical coherence tomography (OCT), and optical coherence tomography angiography (OCTA) [4–7]. This chapter will further discuss the superiority of each modality.

2. An overview of age-related macular degeneration

Age-related macular degeneration is commonly classified based on its characteristics into dry (nonexudative) ARMD and wet (exudative) ARMD [5, 7]. Meanwhile, according to the natural course of the disease, it categorizes into early, intermediate, and advanced ARMD [6, 7]. Dry ARMD represents approximately 90% of diagnosed ARMD cases [5, 7]. This type is distinguished by the presence of drusen accumulation, the absence of choroid neovascularization, and retinal pigment epithelium (RPE) atrophy [8]. The hallmark of wet ARMD is the development of choroidal neovascularization, and this fragile new blood vessel tends to leak forming exudates [9]. It counts for 10% of ARMD cases and has been linked with rapid deterioration toward blindness [7].

Beyond aging process, smoking and ethnicity are the only consistent risk factors related with ARMD documented in studies. A cohort study of 65 years old or older patients found smoking doubles the risk of having ARMD in 5 years compared to nonsmokers [10]. The exact underlying pathophysiology of ARMD is still unknown. Several theories are hypothesized to be the fundamental factors behind ARMD. These include lipofuscin accumulation, drusen accumulation, chronic inflammation, oxidative stress, reduction of antioxidant, mutation of complements, and choroidal neovascularization [10, 11]. The new blood vessels are fragile and generate complications to the surrounding structure causing hemorrhages, exudate, RPE and/or retinal detachment, and scar, hence the progression into the end-stage ARMD, which is exudative ARMD [5, 6, 9, 12].

The identification of ARMD in patients is a crucial aspect in delivering early treatment. Elder patients especially those aged above 40 years are more susceptible to develop ARMD. According to the American Academy of Ophthalmology, it is suggested that individuals aged 40 years and above should be screened for the possible ARMD. Binocular slit-lamp examination with three mirror lens or condensing lens is also needed to disclose drusen, profound signs of CNV such as macular edema, subretinal fluid, hemorrhages, atrophy of retinal pigment epithelium, and RPE atrophy [6]. High-risk individuals are suggested to regularly conduct further comprehensive eye examinations. A comprehensive eye examination includes noninvasive and invasive imaging to detect any subtle changes in the retina structures [6].

3. Multimodal imaging in age-related macular degeneration

Imaging not only holds an important diagnostic tool in ARMD but also provides better understanding of ARMD pathophysiology, determines treatment options, and evaluates the treatment response and disease progression [7, 13]. Imaging aids clinicians to visualize abnormalities exhibited by ARMD such as lipofuscin, RPE atrophy, drusen deposits, choroidal neovascularization, and subretinal fluid [7, 14, 15]. The characteristics found during the imaging determine the treatment options and prognosis of the patient. The various modalities are color fundus photography, fundus fluorescence angiography (FFA), indocyanine green angiography (ICGA), fundus autofluorescence (FAF), optical coherence tomography (OCT), and OCTA [13]. Despite the various imaging technologies, fluorescein angiography remains as a gold standard for diagnosis of the wet ARMD.

3.1 The role of fundus photography in age-related macular degeneration

Fundus photography (FP) is one of the simplest imaging modalities that can be utilized in detecting ARMD. Fundus photography was found at the end of the

nineteenth century. In the 1950s, electronic flash and 35 mm cameras were adapted; thus modern ophthalmic camera was born. This examination uses fundus camera, which projects light into the dilated pupil to illuminate fundus. Fundus camera usually possesses 30—35° optical angle of view conceiving a 2.5 times life size 2D image [13, 15].

This modality is useful to detect both dry and wet ARMD. It can display various ARMD abnormalities consisting lipofuscin, drusen as a yellow deposit, reticular pseudodrusen, well-defined area of RPE atrophy, and choroid neovascularization [14, 15]. In nonexudative ARMD, FP allows visualization of drusen that appears as yellowish round lesion, pigmentary deposit around macula, while atrophic RPE shows a hypopigmentation around the macula. This imaging also enables measurement of drusen characteristics and size. The hard drusen appears as well-defined border yellow deposit, while soft drusen exhibits an ill-defined border yellow deposit [16]. The size of drusen is categorized into small ($<63\ \mu\text{m}$), intermediate ($63\text{--}124\ \mu\text{m}$), and large ($\geq 125\ \mu\text{m}$). **Figure 1A** shows the characteristics of soft and hard drusen. This also contributes to staging of ARMD. Meanwhile, the utilization of color fundus photography in wet ARMD is beneficial in the detection of any exudative complications such as macular edema and macular detachment [7].

Regardless of its convenience, color fundus photography has several disadvantages. First, the image created is in 2D and thus lacks depth and generates problem in visualizing small details. Any abnormalities in the refractive media such as cataract result in lower image clarity [15]. When used as single imaging procedure, fundus photography has lower sensitivity to detect choroidal neovascularization 78% compared to OCT 94% [17]. Fundus photography has better accuracy when in conjunction with other imaging modalities. Ly et al. found that fundus photography has 61% accuracy in diagnosing ARMD and its accuracy was proven by 5% with additional imaging [18]. This was also documented in **Figure 1** that the FP image only shows the presence of drusen but upon OCT examination, subretinal and fibrovascular pigment epithelial detachment is evident. FP alone is inadequate to

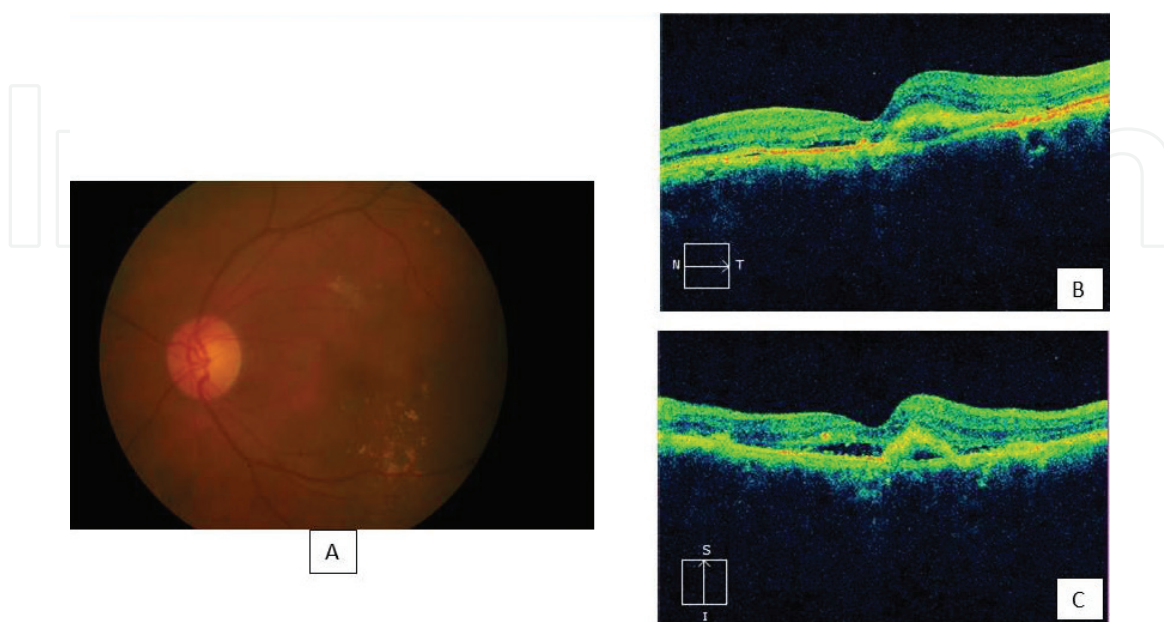


Figure 1.
Drusen appearance on FP and OCT of the same patient. The color fundus photography (FP) shows the presence of soft drusen and hard drusen at the inferior to fovea (A). Upon OCT examination, the presence of drusen is noticeable as a low mounds on the RPE layer. The OCT also shows that subretinal fluid and fibrovascular pigment epithelial detachment are also evident on the OCT (B) and (C) indicating a typical wet ARMD.

diagnose wet ARMD as it underestimates the presence of choroidal neovascularization. Hence, another modality is needed to complement FP limitations.

3.2 The fundus autofluorescence

Fundus autofluorescence (FAF) is an imaging method using a specific wavelength of light to trigger the fundus fluorescent characteristics without the need of contrast [7, 13, 15]. This autofluorescence characteristic is mainly due to lipofuscin, by-product of RPE, with its toxic component biretinoid fluorophore [7, 19, 20]. Specific wavelength of light around 300–500 nm is used to excite the lipofuscin, which then emits 500–700 nm [15]. FAF is done using fundus spectrophotometer, confocal scanning laser ophthalmoscope, or a fundus camera. Confocal scanning laser ophthalmoscope (cSLO) is more superior to others as it has capability to reduce the noise from other autofluorescence sources commonly from anterior segment of the eye [15, 19]. In comparison with color fundus photography, fundus autofluorescence has the ability to detect retinal changes in early and intermediate ARMD that may appear normal in color fundus photography [19].

FAF images have the capability to detect numerous retinal abnormalities such as pigmentary changes, drusen, and reticular pseudodrusen [19]. Lipofuscin deposits in RPE exhibit hyperautofluorescence due to the presence of *N-retinyl-N-retinylidene ethanolamine* (A2E), while RPE atrophy appears hypoautofluorescence. The condition where these hyperautofluorescence and hypoautofluorescence coincide suggests that an area of hyperautofluorescence (lipofuscin) surrounding a hypoautofluorescence could be a predictive tool for enlargement of RPE atrophy and thus useful for monitoring GA progression. This was exhibited by Gobel et al. who discovered enlargement of GA mainly occurred in area of hyperautofluorescence and the size increases four times the original size within 9 years of follow-up [15]. This corresponds to the hypothesis of lipofuscin containing toxic that causes the RPE cell death [20, 21].

Meanwhile, drusen appears in numerous fashions on imaging. In FAF, drusen can appear as hypoautofluorescence, hyperautofluorescence, and normal lesion, owing to the variability of fluorophore components and the size of drusen [19]. Hard drusen, especially small ones, is hard to detect using FAF. Soft drusen under FAF appears as hyperautofluorescence around the edges and slightly hypoautofluorescence in the center. Reticular pseudodrusen resembles as a well-organized network hypoautofluorescence lesion surrounding the normal retina. This is hypothesized due to its subretinal location that obstructs the autofluorescence of lipofuscin in RPE [19, 22].

A patchy pattern, reticular pattern, and linear pattern documented on FAF have been associated with the development of neovascular ARMD. Cohort study by Batioglu et al. discovered that initial findings of patchy pattern were the most associated FAF pattern linked with the development of exudative ARMD with frequency rate of 30.4%, followed by linear pattern and reticular pattern (25 and 20.8%, respectively) during 2.5 years' follow-up, showing that FAF is useful as a prognostic tool to predict the incidence of neovascular ARMD [23]. Similar finding was also exhibited by Cachulo et al., whereas the patchy pattern was the most associated FAF pattern abnormality converted to exudative ARMD (29%) [24].

In neovascular ARMD, FAF images exhibit various FAF pattern. Hemorrhages, scarring, and fibrovascular membranes are hypoautofluorescence lesion. Subretinal fluid appears as hyperautofluorescence. Break in RPE exhibits as reduced autofluorescence [19]. In classic neovascular ARMD, Peng et al. described the FAF findings as reduced FAF at the lesion core with elevated FAF around the lesion border. The author also compared the FAF image with fundus fluorescence angiography; the

lesion on FFA appeared smaller than that in FAF showing that FAF has more advantages in detailing the alteration in RPE. In occult neovascular ARMD, FAF images exhibit diverse FAF characteristics with both reduced FAF and elevated patchy FAF [25]. FAF has high sensitivity in detecting neovascular ARMD (93%) but relatively low specificity (37%) in comparison with FFA as the gold standard [24].

Near-infrared autofluorescence (NIA) is another imaging technique that utilizes the other fluorophore characteristics of retina, melanin. Melanin is found predominantly in RPE cell and small amount in choroid. Unlike the ordinary FAF, NIA adapts longer wavelength (diode laser light) for excitation 787 nm and capture specific wavelength above 800 nm. The image is captured using confocal scanning laser ophthalmoscope, producing $30 \times 30^\circ$ images [26, 27]. In visualizing the retina, NIA exhibits comparable retina characteristics taken by FAF. The NIA images show high hyperautofluorescence in the center of fovea owing to the high melanin contents in RPE cells [26]. In dry ARMD patients, both NIA and FAF appear dark in atrophic region, meanwhile the area adjacent to the atrophic region appeared increased intensity. Kellner et al. found that half of their ARMD patients have increased NIA in normal FAF site; the author suggests that there is an increase in melanin activity prior to lipofuscin activity [27]. In wet ARMD, the image appears dark in both NIA and FAF due to obstructed autofluorescence signal by subretinal fluid, hemorrhage, or choroidal neovascularization. However, it was found that FAF (56.5%) is more effective in detailing exudative activity compared to NIA (33.9%) [27]. **Figure 2** shows the comparison of regular fundus autofluorescence and infrared autofluorescence.

Retromode imaging (RM) is another imaging modality employing infrared laser at 790 nm, equipped with a laterally deviated confocal aperture with central stop. The imaging utilizes confocal scanning laser ophthalmoscope, yielding a pseudo-3D appearance of deeper retinal layers and choroid. This imaging modality is found to be useful in identifying pathological structures in dry and wet ARMD. It was found that drusen was more apparent in retromode imaging compared to fundus photography, and even smaller-size drusen is easily detected [28]. In wet ARMD, Pilotto et al. found that RM has a superior intermethod agreement with OCT in visualizing macular edema, but relatively low for RPE detachment and poor for neuroretinal detachment [29].

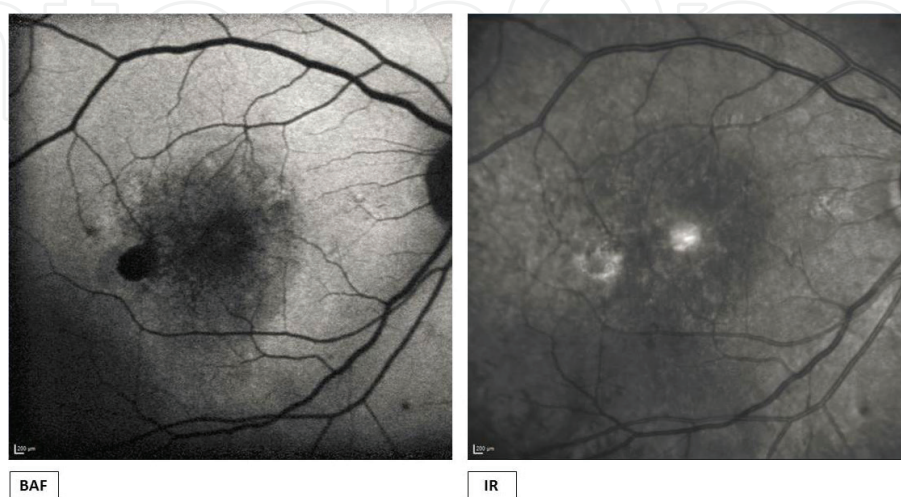


Figure 2.
Fundus autofluorescence of wet ARMD. BluePeak Autofluorescence (BAF) shows a hypoautofluorescence at the fovea and periphery due to macular detachment accompanied by exudates. Meanwhile in infrared (IR) autofluorescence, the macular detachment and exudates appear as hyperautofluorescence; the reduced IR was blocked due to probable subretinal fluid and hemorrhage.

3.3 Fundus fluorescence angiography

Fundus fluorescence angiography (FFA) is an invasive imaging modality that uses intravenous fluorescent contrast called resorcinolphthalein sodium. FFA serves as the gold standard for neovascular ARMD. It allows visualization of the blood vessel structure and integrity. A camera with a ring-shaped flash 485–500 nm is used to excite the molecule in the contrast. The projected blue light is then reflected back by retina layers. Some light is absorbed by the fluorescein and emits back as green light at wavelength of 520–535 nm. The emitted green light is then captured by 520–535 nm green filter onto digital surface, producing image at 2.5× magnification and 30° of angle view. In FFA, there is early state and late state [14].

Compared to other modalities, FFA excels in detailing the state of choroid neovascularization in its structural and leakage state. Based on the location of CNV, it is classified as extrafoveal, subfoveal, and juxtafoveal. Extrafoveal CNV is neovascular located around 200–2500 µm from the center of foveal avascular zone (FAZ). Subfoveal CNV is located underneath the center of FAZ. Lastly, juxtafoveal CNV is located up to 199 µm from the center of FAZ and some part of FAZ excluding the center portion [14]. Identification of the CNV location is a useful prognostic factor and treatment options.

FFA also provides leakage property of the CNV, which is then further classified into occult CNV (type I), classic CNV (type II), and retinal angiomatous proliferation (type III) [6, 14, 22]. Occult CNV appears as poorly defined mottled and patchy hyperfluorescence in early-phase angiogram and leaks at the later phase of angiogram, forming larger hyperfluorescence dots. The occult CNV is further classified based on its leakage characteristics found upon FFA examinations. Type I occult CNV is fibrovascular PED and is described as stippled hyperfluorescence upon early phase (1–2 minutes after fluorescein dye injection) followed by poorly defined progressive leakage upon late-phase angiogram (**Figure 3**). Type II occult CNV is late leakage from undetermined source and is described as CNV does not appear hyperfluorescence during early phase but shows speckled hyperfluorescence upon mid- to late-phase angiogram (2–5 minutes after dye injection) [30]. Classic CNV presents as well-defined hyperfluorescence network membrane in early phase, followed by progressive leakage in late-phase angiogram [14, 22].

Another neovascularization lesion often found in ARMD patients is retinal angiomatous proliferation (RAP). RAP is recently described as neovascularization arising from intraretinal layer and infiltrating into the choroid layer forming a retinal-choroidal anastomosis (RCA) [22]. According to classification by Yannuzzi et al., there are three stages of RAP. Stage I is intraretinal capillary proliferation rising from deep capillary plexus in paramacular region [31]. Upon FFA examination,

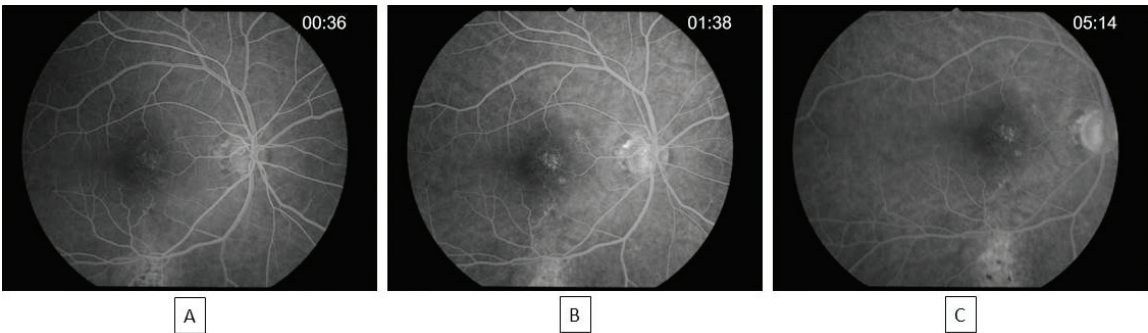


Figure 3. Fundus fluorescence angiography ((FFA) characteristics of occult CNV, fibrovascular PED type). The early phase (A) shows a stippled hyperfluorescence followed by progressive increase of hyperfluorescence at mid-phase (B) and late-phase angiogram (C).

it appears as well-defined border of hyperfluorescence at the focal area surrounded with intraretinal edema [32]. Stage II is defined as neovascularization that has extended through photoreceptor layer infiltrating into subretinal space [31]. FFA reveals a hyperfluorescence at focal area indicating intraretinal neovascularization and at subretinal spaces followed by subretinal leakage, often interpreted as occult CNV [32]. Stage III is described as the presence of choroid neovascularization (CNV), anastomosis of retina and choroid, and pigment epithelial detachment [31]. On FFA examination, sometimes it is difficult to detect stage III as the detailed layer of subretinal neovascularization, choroid neovascularization, and detached RPE combined into homogenous nonspecific hyperfluorescence [32]. Hence, another imaging technique such as indocyanine green angiography is needed to offer a better visualization of the lesion.

Drawbacks of the FFA procedure are its systemic complication from the injected fluorescent dye. The complications are nausea, allergic reaction, and anaphylaxis reaction. The dye used leaks extensively to the surrounding tissue, which could alter detailing of the CNV. Thus in some cases of type I CNV, PCV, and RAP, ICGA is the more preferable method compared to FFA [33].

3.4 Indocyanine green angiography

Indocyanine green angiography (ICGA) uses indocyanine green dye, a high-molecular weight contrast (775kD), and projects 790 nm infrared light directed into the eyes that allows deep penetration to the RPE structure [14, 22]. The dye used in ICGA binds to plasma proteins and thus leaks less compared to FFA imaging. The ICGA leakage then reabsorbed, thus producing hypercyanescent in the late phase [13, 14]. Similar to FFA, ICGA is an invasive procedure using injection of intravenous dye into the systemic circulation, which could trigger systemic complication such as nausea, vomiting, urticarial, allergic reaction, and anaphylactic reaction [14].

Abnormalities exhibited by ICGA appear as hypercyanescent plaque, focal hot spot, or combination of both. ICGA readings have three timed phase, early phase, mid phase, and late phase. ICGA is well suited in identification of type I CNV or occult CNV, the early phase often showing ill-defined hypercyanescent lesion, progressive intensity in mid phase, and the late-phase hypercyanescent plaque [33, 34]. However, ICGA is less superior in detecting classic CNV; this type of CNV appears as well-defined hypercyanescent [34].

Other types of CNV pivotal in determining the treatment options and outcome are polypoidal choroidal vasculopathy (PCV) and retinal angiomatous proliferation (RAP). Polypoidal choroidal vasculopathy (PCV) is described as branching of abnormal choroidal vascular network with aneurysmal dilatation (polypoidal characteristics) at its edge. The exact origin of PCV is still in dispute; some suggest that PCV arises from choroidal abnormalities, while others speculate that PCV is another type 1 CNV modification [35–37]. Upon FFA imaging, PCV often masks the appearance of occult CNV or classic CNV and thus ICGA serves as the gold standard in identification of PCV as its appearance masked by the RPE layers in FFA. On ICG angiography examination, PCV appears as hypercyanescent hot spot in the early angiogram with a grape-like/polypoid structure (**Figures 4 and 5**) [38]. **Figure 5** is an example where PCV lesion masking an occult CNV on FFA and the ICGA examination revealed hypercyanescent hot spot with polypoid structure upon early, mid, and with “wash out” phenomenon in late-phase angiogram.

The occurrence of PCV has been associated with serosanguineous PED, neurosensory detachment, high recurrent case, and poor visual outcome [38]. It was found that the poor outcome despite the effective treatment of anti-VEGF should always suspect the occurrence of PCV [39].

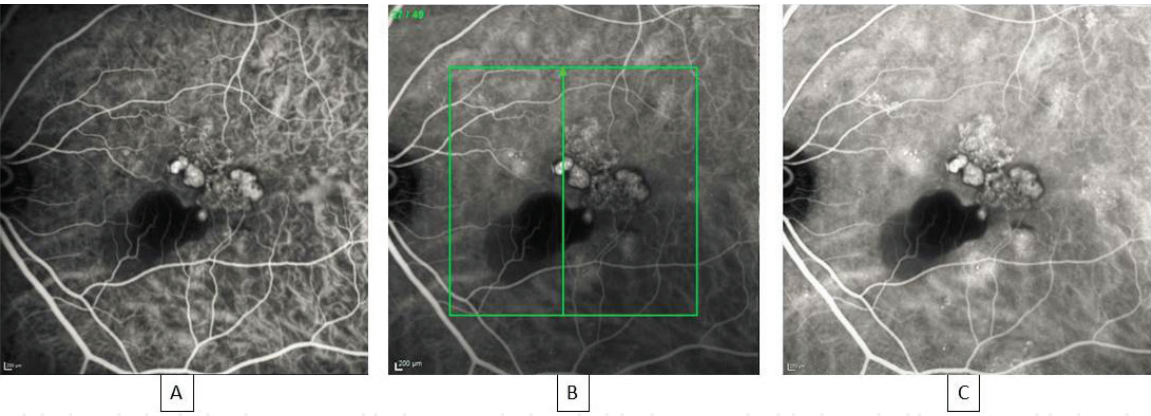

Figure 4. ICGA examination of a patient (A) early phase at 1 minute 45 seconds shows a well-demarcated hypercyanescent lesion with polypoidal characteristics (B) increasing intensity at mid phase at 3 minute 51 seconds and late phase 5 minute 59 seconds (C) indicating PCV lesion.

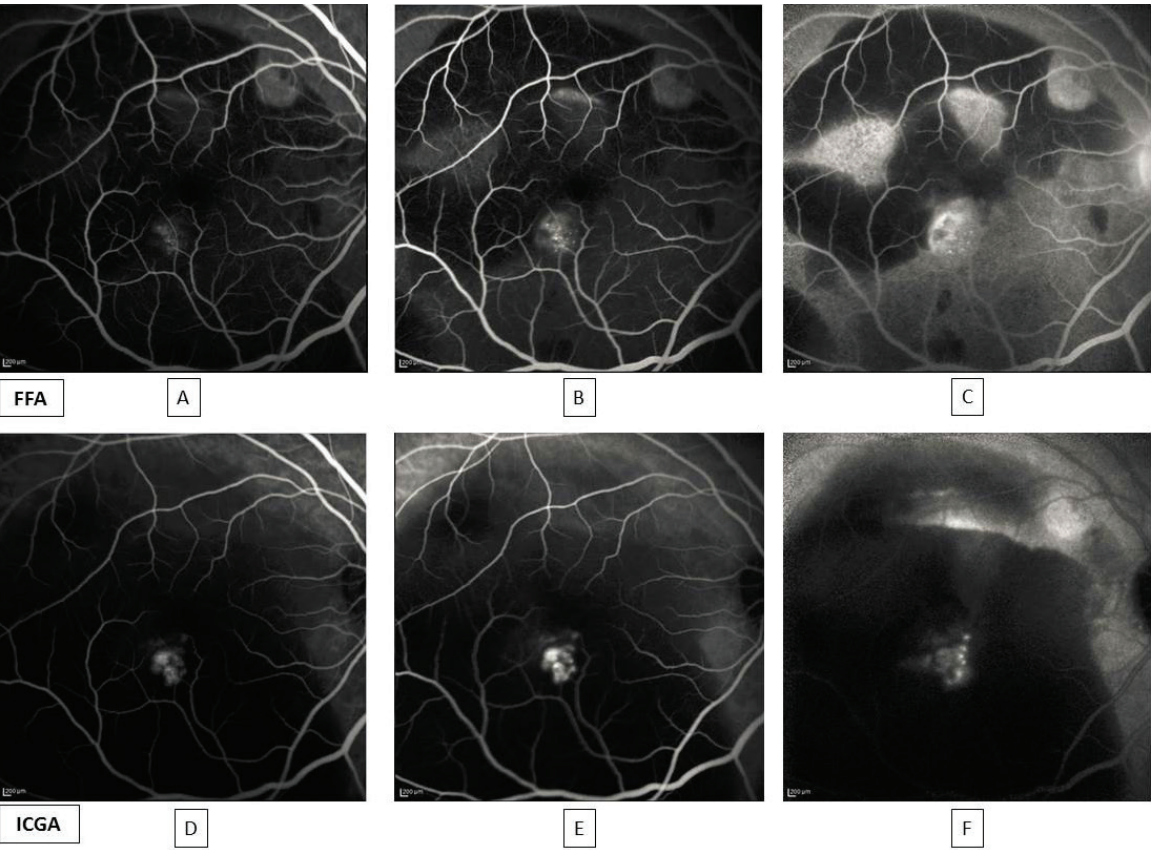


Figure 5. FFA image shows appearance of what looks like occult CNV. Ill-defined stippled hyperfluorescence is visible upon early phase (A), progressively increasing in intensity during mid-phase (B) and late-phase angiogram (C). However, upon ICGA examination, the lesion appears to have PCV characteristics. “Hot-spot” with polypoid appearance is evident upon early angiography (D) followed by progressive intensity upon mid phase (E) and “wash-out” on late phase (F). The choroidal structure is blocked by the presence of massive submacular hemorrhage, which appears as hypofluorescence background.

Retinal angiomatous proliferation (RAP) is also a type of CNV best visualized by ICGA. This lesion appears as early hyperfluorescence hot spot with apparent retinal artery communication into the CNV, followed by progressive increase in both size and intensity in the late phase [32, 40]. Identification of RAP on one eye has been linked with the increased chance of neovascularization on the other eye reaching almost 100% risk within 3 years of follow-up [41].

As mentioned before, ICGA operates on longer wavelength of infrared compared to FFA, thus allowing deeper penetration to RPE and choroidal structure providing more specific information regarding CNV location [14, 22]. These advantages also allow the image to further penetrate any subretinal fluid or hemorrhages and pigment epithelium detachment that often alter imaging in FFA. Kramer et al. found that upon FFA examination, most of their patients with retinal hemorrhage exhibit ill-defined hyperfluorescence surrounded with area of blocked fluorescence (23/30), while under ICGA, these lesions appear to be hypercyanescent hot spot in 12 cases, plaque in 8 cases, and combination in 8 cases [40]. Thus in the presence of hemorrhage, ICGA image offers more detailed characteristics of CNV in ARMD patients compared to FFA.

3.5 The utilization of optical coherence tomography in age-related macular degeneration

Optical coherence tomography (OCT) is performed by projecting low coherence laser into retina. The image is a product of time delay and backscattered lights resulting in cross section of retina layers [13, 14]. Time domain OCT (TD-OCT) is the first OCT invented and requires longer time to produce image. TD-OCT produces axial and lateral resolution 15 μm . Spectral domain OCT requires less time to acquire images, resulting in greater density and better image quality (axial 3 μm , transverse resolution 10 μm) [14, 22]. Polarization-sensitive SD-OCT (PS-SD-OCT) is a modified form of SD-OCT in purpose to overcome limitation to detect RPE unity and condition [42]. Lastly, the newly developed swept-source OCT uses longer wavelength and simpler methods and thus enables deeper tissue penetration and shorter duration of image acquisition compared to SD-OCT.

Image produced by OCT is in the form of hyperreflective and hyporefective bands representing the layer of retina [43]. In clinical practices, there are four hyperreflective bands that are observed in ARMD patients. These hyperreflective bands are presumed to represent external limiting membrane, inner/outer segment of photoreceptor, RPE, and Bruch's membrane [44]. OCT is capable to exhibit ARMD abnormalities such as drusen deposits, pseudodrusen, subretinal fluid, RPE detachment, and choroid neovascularization. In OCT, drusen deposits appear as low mounds underneath RPE layer [22]. Findings of drusen in OCT are found to be significantly correlated with drusen findings in FAF in the study of Landa et al. [45].

Reticular pseudodrusen presents as hyperreflective deposit localized under the retina layer [22]. The presence of pseudodrusen in ARMD patients has been linked with the increased risk for end-stage ARMD, geographic atrophy, or neovascular ARMD. Ueda-Arakawa et al. found that OCT has the highest sensitivity (94.6%) and specificity (98.4%) in detecting the presence of pseudodrusen in comparison with other imaging modalities [46]. The presence of reticular pseudodrusen also alters the choroid function proven by thinning of choroid thickness [47, 48].

In geography atrophy, the RPE atrophy exhibits a feathered-like pattern projected deep into the RPE due to laser beam penetrated into RPE [14]. OCT images also exhibit a progressive loss of retinal bands, which includes external limiting membrane, inner/outer segments of photoreceptor layer, RPE membrane, and outer nuclear membrane [15]. These findings are in concordance with the study of Fleckenstein et al.; the authors discover that the enlargement of the atrophic region was associated with gradual loss of the outer hyperreflective bands and thinning of outer nuclear layer, outer plexiform layer, RPE membrane, and Bruch's membrane during 12 months of follow-up [49, 50]. The authors also discovered that GA was linked with increased of retinal thickness by 14.09 μm [49]. Their other study also found separation of inner and outer parts of band 4, presumed to be RPE/Bruch's membrane [50].

Neovascularization activity is visualized on OCT based on accumulation of fluid in various levels of retina. Subretinal fluid is described as hyporeflective lesion located above the RPE and beneath the retina [14, 22]. RPE detachment appears as dome shaped at RPE layer [14]. The exudative activity is one of determining factors for neovascular ARMD treatment. Increased choroid thickness could represent the possible choroid; however, these cannot differ between classic ARMD and polypoidal choroidal vasculopathy [22]. Another structural abnormality of the retina found in OCT is outer retinal tubule. This lesion appears as hyporeflective center surrounded by hyperreflective border. Outer retinal tubule represents the degenerated photoreceptors and thus does not represent exudative activity for neovascularization and does not need treatment for neovascular ARMD [51].

OCT is one of the most convenience imaging modalities to detect and monitor ARMD. It provides information of retinal changes without an invasive procedure and systemic complication as required in invasive angiographic imaging such as fundus fluorescence angiography (FFA) and indocyanine green angiography (ICGA). OCT is reported to have higher sensitivity in detecting CNV (94%) compared to FP (78%) [17]. However, comparing OCT to FA as the gold standard for CNV, OCT possesses lower sensitivity (40%) and relatively moderate specificity (69%) [52]. Unfortunately, the advancement of OCT still has limitation in detailing and grading CNV. **Figure 6** exhibits the utilization of multimodal imaging in wet ARMD resulting in detailed characteristics of RAP after OCTA successfully provided the appearance of CNV in all retina and choroid layer. This shows that the limitation can be overcome by conducting fundus fluorescence angiography or OCTA in conjunction with OCT when indicated.

3.6 The new advance in retinal imaging for age-related macular degeneration

OCT technology is continuously developed. The previously developed spectral domain OCT (SD-OCT) has limitation in detecting structures under hemorrhage and capturing the integrity of RPE layers. It was then proposed by Ahlers et al. [42],

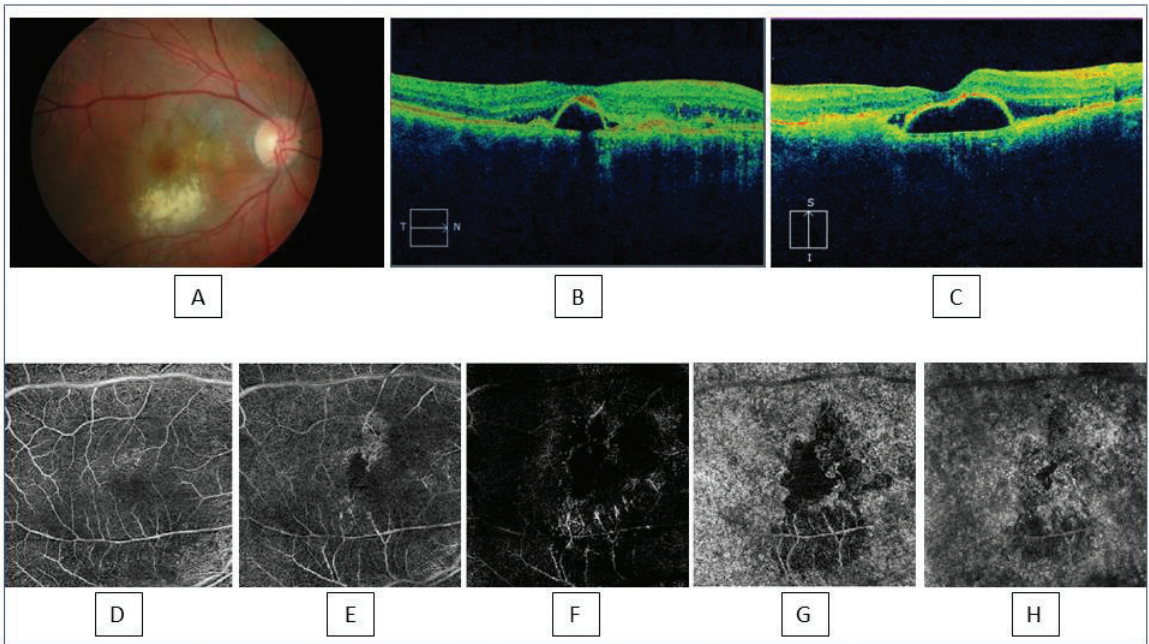


Figure 6. Multimodal imaging on a neovascular ARMD patient. The color fundus photography exhibits pale macula with the presence of drusen, hard exudate on color fundus photography, and macular detachment (A). Upon OCT examination, pigment epithelial detachment is apparent along with subretinal fluid (B). Meanwhile, on OCTA examination, choroidal neovascularization is evident arising from choroid layer (H), choriocapillaris layer (G), avascular zone (F), extending into deep vascular layer (E) and superficial vascular layer (D), which is a characteristic of typical RAP.

where the SD-OCT was modified adding its capability to detect depolarization characteristics of RPE layers, called polarization-sensitive (PS) SD-OCT. The use of PS-SD-OCT was observed in both dry and wet ARMD. The PS-SD-OCT was successful in visualizing the continuous layer of RPE located under the drusen, larger RPE atrophy area, and focal skip lesions in the RPE layer, which was unable to be visualized using the standard SD-OCT [42].

Another modification of OCT is done by implementation of adaptive optics (AO). OCT has a greater capability in producing high axial resolutions; however, its transverse resolution is limited due to the ocular aberration. This aberration is due to cornea, crystalline lens, and the size of the pupil. AO aids in correction of ocular aberrations, increases lateral resolutions, reduces artifacts, and increases detection to weak reflections [53]. Combining these two techniques enhances OCT capability, thus allowing visualization of cellular structures; hence, early recognition of cellular pathology afore the visual alteration occurs. A comparison of commercial B-scans OCT with AO-OCT resulted higher reflectivity and reduced speckle size in retina images taken with AO-OCT [54]. Utilization of AO-OCT in ARMD has been documented in several studies. One of the studies conducted by Athanasios et al. shows the application of AO-OCT in geographic atrophy patients. The AO-OCT successfully provided detailed extralimiting membrane loss, inner and outer segment loss, and RPE loss in geographic atrophy (GA). In advanced GA, the AO-OCT capable of visualizing calcified drusen and drusenoid pigment epithelial detachment. This modification also allows the clinicians to directly witness the destruction of photoreceptor cell caused by drusen [55].

In 2008, swept-source OCT (SS-OCT) was introduced. This new technique uses tunable laser, which possesses longer wavelength (1050 nm) for deeper tissue penetration and predivided spectrum for simpler mechanisms, hence faster image acquisition [56]. Therefore, SS-OCT is greater in visualizing the choroidal structure and RPE. In comparison to SD-OCT, SS-OCT has greater capability in identifying retinal thickness. It was found that the agreement between these two methods of OCT is low, especially in those with active wet ARMD [57]. The author argues that the active disease, such as hemorrhage and subretinal fluid, obscures the OCT signals in SD-OCT. The superiority of SS-OCT is also supported by Copete et al. [58]; the SD-OCT was unable to identify choroidosclera border in those with thicker choroid (23%) upon SS-OCT examination. The odd ratio of SD-OCT failure is greatest (10.3) at 400 μm of subfoveal choroidal thickness.

Age-related macular degeneration affects elderly; thus the use of fluorescence dye results in worse side effects. However, the visualization of retina and choroidal microvasculature in ARMD detection is crucial in management of ARMD. Thus, the development of noninvasive angiographic imaging technique is essential. The advancement of OCT technology helps in the development of OCTA. The shortened OCT image acquisition allows the development of OCTA as multiple image retrieval is required. The breakthrough in OCTA began after the discovery in OCT signal differences caused by blood flow. This contrast is classified as Doppler phase shift and speckle variance [59]. However, Doppler phase shift is found to be ineffective to visualize retinal and choroidal microvasculature [59]. It was then discovered in 2005 by Barton et al. where the speckle variation in OCT signal arises from scatterer motion. Speckle variation was further classified into phase based and amplitude or intensity.

OCTA is a noninvasive imaging examination that allows visualization of retina and choroid vascular structure. By utilizing the principle of OCT, it detects erythrocyte flow using sequential B-scans to detect the variable amplitudes and signal intensity gradients. This gradient is then processed through full-spectrum or split-spectrum processing [22, 59, 60]. It can produce en face or cross-sectional image displaying neo-vascular network. En face OCTA is the most commonly utilized technique in clinical practices. This allows visualization of vascular characteristics from retina, superficial

vascular, deep vascular, avascular zone, choriocapillaris zone, and choroid zone. However, OCTA does not allow any leakage property of the vascular zone [22, 47].

OCTA is best to describe abnormalities existing in both exudative and nonexudative CNV. In nonexudative CNV, the use of OCTA is beneficial in visualizing choriocapillaris blood flow, especially in atrophy region. Kvanta et al. found a significant decrease in choriocapillaris flow in atrophic zone extending outside the geographic atrophy area. This could potentially describe the choriocapillaris alteration in dry ARMD [61]. OCTA was also used in the study of Toto et al. in which the author found significant decreased vessel density by 9% in dry ARMD patients in both superficial vascular layer and deep vascular layer compared with healthy individuals [48]. However, reading OCTA in dry ARMD should be done in careful manner because the drusen affects the signal, thus lowering image quality especially for area below drusen.

OCTA allows to visualize the neovascular network afore the leakage, hence early detection and prompt treatment. CNV appears as hyperfluorescence high flow network varying on the depth of the retina involvement according to the degree of CNV [22]. OCTA has been proven to have a comparable detection capability in visualizing CNV compared to other imaging such as FFA and ICGA. Type I CNV appears on the choriocapillaris layer penetrating the Bruch's membrane and below the RPE [62]. This CNV appears as a minimal demarcated vascularization arising from choroid, choriocapillaris, and RPE with no evidence of neovascularization in outer retina [63]. A retrospective case series by Roisman et al. found that OCTA exhibits more detailed images in detecting CNV compared to FFA and ICGA in asymptomatic ARMD patients [64]. In their study, the authors discover that CNV, which appears on FFA as a minimal leakage and macular plaques on ICGA, was a type I CNV in OCTA imaging. However, this finding is contradict with the study conducted by Told et al. in which the capability of OCTA to detect occult CNV was found to be less sensitive and specific compared to ICGA [65].

Meanwhile, type II CNV presents as choroidal neovascularization arising into RPE and subretinal space [22]. It appears as a sharp demarcated vascular changes

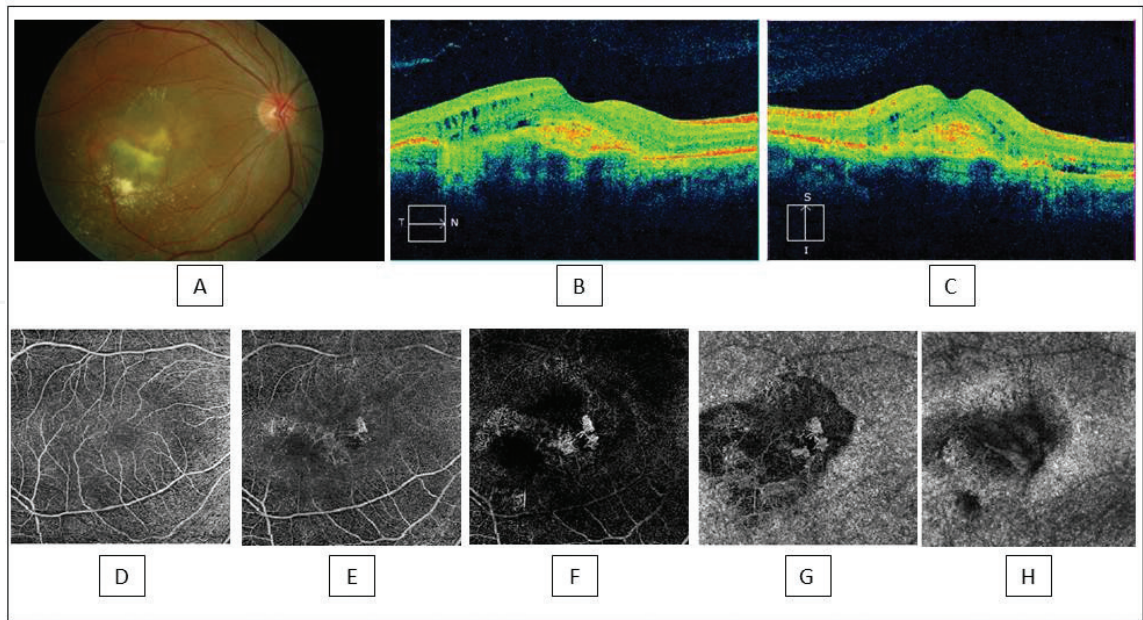


Figure 7. Color fundus photography shows an appearance of drusen surrounding the macula. The presence of exudates due to subretinal fluid is also evident, showing characteristics of wet ARMD (A). The OCT image shows the presence of macular edema with intraretinal and subretinal fluid; hyperreflective lesion is also noted below the RPE suggesting choroid neovascularization (B). The presence of choroid neovascularization is confirmed by OCTA, arising from choroid (H), choriocapillaris (G), avascular zone (F), into deep vascular layer (E), except superficial vascular layer (D), exhibiting a type III CNV.

at the choroid, choriocapillaris, RPE, and extending to outer retina [63]. Lastly, the appearance of RAP or type III CNV is hyperreflective cluster situated in outer retinal layer with interconnecting vessel with the inner retinal circulation (**Figure 7**) [66]. Comparing OCTA and FFA in detecting exudative ARMD, OCTA has lower sensitivity 81.3% where large subretinal hemorrhage was found on the false-negative patient. The authors argue that the subretinal hemorrhage weakens the OCTA signal to detect CNV [67]. Another limitation of OCTA was documented in Told et al. and Costanzo et al., which OCTA tends to underestimate the CNV size compared to ICGA [33, 65].

The ongoing development of OCT affects greatly in the development of OCTA. The most common OCT system used by OCTA is SD-OCT. However, some suggest that the SS-OCT system provides more superior image quality compared to SD-OCT system in the presence of intraretinal hemorrhage. The longer wavelength used in SS-OCT system is thought to be able to penetrate any obscuring materials such as hemorrhage or subretinal fluid and thus provides more detailed structure on RPE and choroidal layer for ARMD patients. Miller et al. found that the CNV areas appeared to be larger upon SS-OCTA compared with SD-OCTA both on 3×3 and 6×6 mm² scans [68].

4. Conclusions

Early diagnosis of age-related macular degeneration has the major role in delaying the progression of advanced ARMD. The advance in technology provides detailed structure of retina alteration in ARMD without the need of invasive procedure. The utilization of multimodal imaging in diagnosis of ARMD results in early detection and comprehensive management of ARMD.

Acknowledgment


This article's publication is supported by the United States Agency for International Development (USAID) through the Sustainable Higher Education Research Alliance (SHERA) Program for Universitas Indonesia's Scientific Modeling, Application, Research and Training for City-centered Innovation and Technology (SMART CITY) Project, Grant #AID-497-A-1600004, Sub Grant #IIE-00000078-UI-1.

Author details

Andi Arus Victor
Department of Ophthalmology, Faculty of Medicine, Cipto Mangunkusumo
National General Hospital, Universitas Indonesia, Jakarta, Indonesia

*Address all correspondence to: arvimadao@yahoo.com

IntechOpen

© 2019 The Author(s). Licensee IntechOpen. This chapter is distributed under the terms of the Creative Commons Attribution License (<http://creativecommons.org/licenses/by/3.0>), which permits unrestricted use, distribution, and reproduction in any medium, provided the original work is properly cited. 

References

- [1] Friedman DS, O'Colmain BJ, Munoz B, Tomany SC, McCarty C, de Jong PT, et al. Prevalence of age-related macular degeneration in the United States. *Archives of Ophthalmology*. 2004;**122**(4):564-572
- [2] Wong WL, Su X, Li X, Cheung CM, Klein R, Cheng CY, et al. Global prevalence of age-related macular degeneration and disease burden projection for 2020 and 2040: A systematic review and meta-analysis. *The Lancet Global Health*. 2014;**2**(2):e106-e116
- [3] Colijn JM, Buitendijk GHS, Prokofyeva E, Alves D, Cachulo ML, Khawaja AP, et al. Prevalence of age-related macular degeneration in Europe: The past and the future. *Ophthalmology*. 2017;**124**(12):1753-1763
- [4] Schwartz R, Loewenstein A. Early detection of age related macular degeneration: Current status. *International Journal of Retina and Vitreous*. 2015;**1**:20
- [5] Cunningham J. Recognizing age-related macular degeneration in primary care. *Journal of the American Academy of Physician Assistants*. 2017;**30**(3):18-22
- [6] Panel AAoORV. Preferred Practice Pattern Guideline Age-Related Macular Degeneration. San Francisco, CA: American Academy of Ophthalmology Retina/Vitreous Panel; 2015
- [7] Al-Zamil WM, Yassin SA. Recent developments in age-related macular degeneration: A review. *Clinical Interventions in Aging*. 2017;**12**:1313-1330
- [8] Bowes Rickman C, Farsiu S, Toth CA, Klingeborn M. Dry age-related macular degeneration: Mechanisms, therapeutic targets, and imaging. *Investigative Ophthalmology & Visual Science*. 2013;**54**(14):ORSF68-ORSF80
- [9] Kaszubski P, Ben Ami T, Saade C, Smith RT. Geographic atrophy and choroidal neovascularization in the same eye: A review. *Ophthalmic Research*. 2016;**55**(4):185-193
- [10] Jonasson F, Fisher DE, Eiriksdottir G, Sigurdsson S, Klein R, Launer LJ, et al. Five-year incidence, progression, and risk factors for age-related macular degeneration: The age, gene/environment susceptibility study. *Ophthalmology*. 2014;**121**(9):1766-1772
- [11] Chew EY, Clemons TE, Agron E, Sperduto RD, Sangiovanni JP, Kurinij N, et al. Long-term effects of vitamins C and E, beta-carotene, and zinc on age-related macular degeneration: AREDS report no. 35. *Ophthalmology*. 2013;**120**(8):1604-11.e4
- [12] Nowak JZ. Age-related macular degeneration (AMD): Pathogenesis and therapy. *Pharmacological Reports*. 2006;**58**(3):353-363
- [13] Keane PA, Sim DA, Sadda SR. Advances in imaging in age-related macular degeneration. *Current Ophthalmology Reports*. 2013;**1**(1):1-11
- [14] Gess AJ, Fung AE, Rodriguez JG. Imaging in neovascular age-related macular degeneration. *Seminars in Ophthalmology*. 2011;**26**(3):225-233
- [15] Gobel AP, Fleckenstein M, Schmitz-Valckenberg S, Brinkmann CK, Holz FG. Imaging geographic atrophy in age-related macular degeneration. *Ophthalmologica*. 2011;**226**(4):182-190
- [16] Abdelsalam A, Del Priore L, Zarbin MA. Drusen in age-related macular degeneration: Pathogenesis, natural course, and

laser photocoagulation-induced regression. *Survey of Ophthalmology*. 1999;**44**(1):1-29

[17] Mokwa NF, Ristau T, Keane PA, Kirchhof B, Sadda SR, Liakopoulos S. Grading of age-related macular degeneration: Comparison between color fundus photography, fluorescein angiography, and spectral domain optical coherence tomography. *Journal of Ophthalmology*. 2013;**2013**:385915

[18] Ly A, Nivison-Smith L, Zangerl B, Assaad N, Kalloniatis M. Advanced imaging for the diagnosis of age-related macular degeneration: A case vignettes study. *Clinical & Experimental Optometry*. 2018;**101**(2):243-254

[19] Ly A, Nivison-Smith L, Assaad N, Kalloniatis M. Fundus autofluorescence in age-related macular degeneration. *Optometry and Vision Science*. 2017;**94**(2):246-259

[20] Suter M, Reme C, Grimm C, Wenzel A, Jaattela M, Esser P, et al. Age-related macular degeneration. The lipofusion component N-retinyl-N-retinylidene ethanolamine detaches proapoptotic proteins from mitochondria and induces apoptosis in mammalian retinal pigment epithelial cells. *The Journal of Biological Chemistry*. 2000;**275**(50):39625-39630

[21] Sparrow JR, Boulton M. RPE lipofuscin and its role in retinal pathobiology. *Experimental Eye Research*. 2005;**80**(5):595-606

[22] Talks SJ, Aftab AM, Ashfaq I, Soomro T. The role of new imaging methods in managing age-related macular degeneration. *The Asia-Pacific Journal of Ophthalmology*. 2017;**6**(6):498-507

[23] Batioglu F, Demirel S, Ozmert E, Oguz YG, Ozyol P. Autofluorescence patterns as a predictive factor for neovascularization. *Optometry and Vision Science*. 2014;**91**(8):950-955

[24] Cachulo L, Silva R, Fonseca P, Pires I, Carvajal-Gonzalez S, Bernardes R, et al. Early markers of choroidal neovascularization in the fellow eye of patients with unilateral exudative age-related macular degeneration. *Ophthalmologica*. 2011;**225**(3):144-149

[25] Peng Q, Dong Y, Zhao PQ. Fundus autofluorescence in exudative age-related macular degeneration. *Genetics and Molecular Research*. 2013;**12**(4):6140-6148

[26] Keilhauer CN, Delori FC. Near-infrared autofluorescence imaging of the fundus: Visualization of ocular melanin. *Investigative Ophthalmology & Visual Science*. 2006;**47**(8):3556-3564

[27] Kellner U, Kellner S, Weinitz S. Fundus autofluorescence (488 nm) and near-infrared autofluorescence (787 nm) visualize different retinal pigment epithelium alterations in patients with age-related macular degeneration. *Retina*. 2010;**30**(1):6-15

[28] Acton JH, Cubbidge RP, King H, Galsworthy P, Gibson JM. Drusen detection in retro-mode imaging by a scanning laser ophthalmoscope. *Acta Ophthalmologica*. 2011;**89**(5):e404-e411

[29] Pilotto E, Sportiello P, Alemany-Rubio E, Vujosevic S, Segalina S, Fregona I, et al. Confocal scanning laser ophthalmoscope in the retromode imaging modality in exudative age-related macular degeneration. *Graefes Archive for Clinical and Experimental Ophthalmology*. 2013;**251**(1):27-34

[30] Luis Arias JM. Fluorescein angiography. In: Bandello F, editor. *Age-Related Macular Degeneration*. Portugal: Grupo De Estudos Da Retina; 2011

[31] Yannuzzi LA, Negrao S, Iida T, Carvalho C, Rodriguez-Coleman H, Slakter J, et al. Retinal angiomatous proliferation in age-related

macular degeneration. *Retina*. 2001;**21**(5):416-434

[32] Donati MC, Carifi G, Virgili G, Menchini U. Retinal angiomatous proliferation: Association with clinical and angiographic features. *Ophthalmologica*. 2006;**220**(1):31-36

[33] Costanzo E, Miere A, Querques G, Capuano V, Jung C, Souied EH. Type 1 choroidal neovascularization lesion size: indocyanine green angiography versus optical coherence tomography angiography. *Investigative Ophthalmology & Visual Science*. 2016;**57**(9):OCT307-OCT313

[34] Eandi CM, Ciardella A, Parravano M, Missiroli F, Aloveri C, Veronese C, et al. Indocyanine green angiography and optical coherence tomography angiography of choroidal neovascularization in age-related macular degeneration. *Investigative Ophthalmology & Visual Science*. 2017;**58**(9):3690-3696

[35] Yannuzzi LA, Sorenson J, Spaide RF, Lipson B. Idiopathic polypoidal choroidal vasculopathy (IPCV). *Retina*. 1990;**10**(1):1-8

[36] Yuzawa M, Mori R, Kawamura A. The origins of polypoidal choroidal vasculopathy. *The British Journal of Ophthalmology*. 2005;**89**(5):602-607

[37] Yannuzzi LA, Wong DW, Sforzolini BS, Goldbaum M, Tang KC, Spaide RF, et al. Polypoidal choroidal vasculopathy and neovascularized age-related macular degeneration. *Archives of Ophthalmology*. 1999;**117**(11):1503-1510

[38] Maribel Fernandez MG, Gonzalez F, Gomez-Ulla F. Diagnostic usefulness of indocyanine green angiography (ICGA) in age-related macular degeneration (AMD). In: Bandello F, editor. *AMD Book*. GER Group: Portugal; 2017

[39] Wong CW, Yanagi Y, Lee WK, Ogura Y, Yeo I, Wong TY, et al. Age-related macular degeneration and polypoidal choroidal vasculopathy in Asians. *Progress in Retinal and Eye Research*. 2016;**53**:107-139

[40] Kramer M, Mimouni K, Priel E, Yassur Y, Weinberger D. Comparison of fluorescein angiography and indocyanine green angiography for imaging of choroidal neovascularization in hemorrhagic age-related macular degeneration. *American Journal of Ophthalmology*. 2000;**129**(4):495-500

[41] Gross NE, Aizman A, Brucker A, Klancnik JM Jr, Yannuzzi LA. Nature and risk of neovascularization in the fellow eye of patients with unilateral retinal angiomatous proliferation. *Retina*. 2005;**25**(6):713-718

[42] Ahlers C, Gotzinger E, Pircher M, Golbaz I, Prager F, Schutze C, et al. Imaging of the retinal pigment epithelium in age-related macular degeneration using polarization-sensitive optical coherence tomography. *Investigative Ophthalmology & Visual Science*. 2010;**51**(4):2149-2157

[43] Karampelas M, Sim DA, Keane PA, Papastefanou VP, Sadda SR, Tufail A, et al. Evaluation of retinal pigment epithelium-Bruch's membrane complex thickness in dry age-related macular degeneration using optical coherence tomography. *The British Journal of Ophthalmology*. 2013;**97**(10):1256-1261

[44] Pircher M, Gotzinger E, Findl O, Michels S, Geitzenauer W, Leydolt C, et al. Human macula investigated in vivo with polarization-sensitive optical coherence tomography. *Investigative Ophthalmology & Visual Science*. 2006;**47**(12):5487-5494

[45] Landa G, Rosen RB, Pilavas J, Garcia PM. Drusen characteristics revealed by spectral-domain optical

coherence tomography and their corresponding fundus autofluorescence appearance in dry age-related macular degeneration. *Ophthalmic Research*. 2012;**47**(2):81-86

[46] Ueda-Arakawa N, Ooto S, Tsujikawa A, Yamashiro K, Oishi A, Yoshimura N. Sensitivity and specificity of detecting reticular pseudodrusen in multimodal imaging in Japanese patients. *Retina*. 2013;**33**(3):490-497

[47] Cicinelli MV, Rabiolo A, Sacconi R, Carnevali A, Querques L, Bandello F, et al. Optical coherence tomography angiography in dry age-related macular degeneration. *Survey of Ophthalmology*. 2018;**63**(2):236-244

[48] Toto L, Borrelli E, Di Antonio L, Carpineto P, Mastropasqua R. Retinal vascular Plexuses' changes in dry age-related macular degeneration, evaluated by means of optical coherence tomography angiography. *Retina*. 2016;**36**(8):1566-1572

[49] Fleckenstein M, Schmitz-Valckenberg S, Adrion C, Kramer I, Eter N, Helb HM, et al. Tracking progression with spectral-domain optical coherence tomography in geographic atrophy caused by age-related macular degeneration. *Investigative Ophthalmology & Visual Science*. 2010;**51**(8):3846-3852

[50] Fleckenstein M, Schmitz-Valckenberg S, Martens C, Kosanetzky S, Brinkmann CK, Hageman GS, et al. Fundus autofluorescence and spectral-domain optical coherence tomography characteristics in a rapidly progressing form of geographic atrophy. *Investigative Ophthalmology & Visual Science*. 2011;**52**(6):3761-3766

[51] Zweifel SA, Engelbert M, Laud K, Margolis R, Spaide RF, Freund KB. Outer retinal tubulation: A novel optical coherence tomography

finding. *Archives of Ophthalmology*. 2009;**127**(12):1596-1602

[52] Do DV, Gower EW, Cassard SD, Boyer D, Bressler NM, Bressler SB, et al. Detection of new-onset choroidal neovascularization using optical coherence tomography: The AMD DOC study. *Ophthalmology*. 2012;**119**(4):771-778

[53] Jonnal RS, Kocaoglu OP, Zawadzki RJ, Liu Z, Miller DT, Werner JS. A review of adaptive optics optical coherence tomography: Technical advances, scientific applications, and the future. *Investigative Ophthalmology & Visual Science*. 2016;**57**(9):OCT51-OCT68

[54] Kenta Sudo BC, editor. Adaptive optics-assisted optical coherence tomography for imaging of patients with age related macular degeneration. In: *Ophthalmic Technologies XXIII: Proceedings of SPIE 8567*. 2013; DOI: <https://doi.org/10.1117/12.2004165>

[55] Panorgias A, Zawadzki RJ, Capps AG, Hunter AA, Morse LS, Werner JS. Multimodal assessment of microscopic morphology and retinal function in patients with geographic atrophy. *Investigative Ophthalmology & Visual Science*. 2013;**54**(6):4372-4384

[56] Kishi S. Impact of swept source optical coherence tomography on ophthalmology. *Taiwan Journal of Ophthalmology*. 2016;**6**(2):58-68

[57] Hanumunthadu D, Ilginis T, Balaggan KS, Patel PJ. Agreement of swept-source and spectral-domain optical coherence-tomography retinal thickness measurements in neovascular age-related macular degeneration. *Clinical Ophthalmology*. 2017;**11**:2121-2123

[58] Copete S, Flores-Moreno I, Montero JA, Duker JS, Ruiz-Moreno JM. Direct

comparison of spectral-domain and swept-source OCT in the measurement of choroidal thickness in normal eyes. *The British Journal of Ophthalmology*. 2014;**98**(3):334-338

[59] Gao SS, Jia Y, Zhang M, Su JP, Liu G, Hwang TS, et al. Optical coherence tomography angiography. *Investigative Ophthalmology & Visual Science*. 2016;**57**(9):OCT27-OCT36

[60] Hagag AM, Gao SS, Jia Y, Huang D. Optical coherence tomography angiography: Technical principles and clinical applications in ophthalmology. *Taiwan Journal of Ophthalmology*. 2017;**7**(3):115-129

[61] Kvanta A, Casselholm de Salles M, Amren U, Bartuma H. Optical coherence tomography angiography of the foveal microvasculature in geographic atrophy. *Retina*. 2017;**37**(5):936-942

[62] Cohen SY, Creuzot-Garcher C, Darmon J, Desmettre T, Korobelnik JF, Levrat F, et al. Types of choroidal neovascularisation in newly diagnosed exudative age-related macular degeneration. *The British Journal of Ophthalmology*. 2007;**91**(9):1173-1176

[63] Farecki ML, Gutfleisch M, Faatz H, Rothaus K, Heimes B, Spital G, et al. Characteristics of type 1 and 2 CNV in exudative AMD in OCT-angiography. *Graefe's Archive for Clinical and Experimental Ophthalmology*. 2017;**255**(5):913-921

[64] Roisman L, Zhang Q, Wang RK, Gregori G, Zhang A, Chen CL, et al. Optical coherence tomography angiography of asymptomatic neovascularization in intermediate age-related macular degeneration. *Ophthalmology*. 2016;**123**(6):1309-1319

[65] Told R, Sacu S, Hecht A, Baratsits M, Eibenberger K, Kroh ME, et al. Comparison of SD-optical coherence tomography angiography and

indocyanine green angiography in type 1 and 2 neovascular age-related macular degeneration. *Investigative Ophthalmology & Visual Science*. 2018;**59**(6):2393-2400

[66] Chalam KV, Sambhav K. Optical coherence tomography angiography in retinal diseases. *Journal of Ophthalmic and Vision Research*. 2016;**11**(1):84-92

[67] Faridi A, Jia Y, Gao SS, Huang D, Bhavsar KV, Wilson DJ, et al. Sensitivity and specificity of OCT angiography to detect choroidal neovascularization. *Ophthalmology Retina*. 2017;**1**(4):294-303

[68] Miller AR, Roisman L, Zhang Q, Zheng F, Rafael de Oliveira Dias J, Yehoshua Z, et al. Comparison between spectral-domain and swept-source optical coherence tomography angiographic imaging of choroidal neovascularization. *Investigative Ophthalmology & Visual Science*. 2017;**58**(3):1499-1505