

# We are IntechOpen, the world's leading publisher of Open Access books Built by scientists, for scientists

6,900

Open access books available

186,000

International authors and editors

200M

Downloads

Our authors are among the

154

Countries delivered to

TOP 1%

most cited scientists

12.2%

Contributors from top 500 universities



WEB OF SCIENCE™

Selection of our books indexed in the Book Citation Index  
in Web of Science™ Core Collection (BKCI)

Interested in publishing with us?  
Contact [book.department@intechopen.com](mailto:book.department@intechopen.com)

Numbers displayed above are based on latest data collected.  
For more information visit [www.intechopen.com](http://www.intechopen.com)



---

# Surgery First Approach

---

Ayşe Gülşen

Additional information is available at the end of the chapter

<http://dx.doi.org/10.5772/intechopen.80951>

---

## Abstract

The surgery first approach (SFA) was presented by some researchers in earlier years, but SFA in a combined treatment, with the surgery first and the orthodontic treatment second, as introduced by Brachvogel et al. and by Nagasaka et al., has gained attention in the past 10 years. The advantages of SFA were reported in the literature, and the research into this method continues. One of the advantages of the SFA is the shorter total treatment time, and another is that patients begin treatment with a much improved face esthetically. The protocol of presurgical orthodontics is well known in dentofacial anomalies, but in SFA, especially in complex cases, the meticulous treatment is very important. In this chapter, SFA will be discussed.

**Keywords:** surgery first, orthognathic surgery, orthodontics

---

## 1. Introduction

The treatment of skeletal discrepancies requires orthognathic surgery in combination with orthodontic treatment to improve malocclusion, function, facial, and smile esthetics.

In the 1960s, the surgeons performed orthognathic surgery without orthodontic treatment [1–3]. But it was clearly understood that mandibular or maxillary movement was limited without tooth movement. For example, amount of mandibular setback was limited by the overjet in Class III cases. To achieve a proper setback and to have a good the occlusal and facial esthetics results, orthodontic alignment of malaligned teeth and solving the compensation of teeth to the malposed jaws are required before surgery [4–6]. After the 1970s, orthognathic surgery in combination with orthodontic treatment began to have good standards and showed popularity [7–11].

In conventional orthognathic surgery approach, the surgery follows the orthodontic treatment (orthodontic-first approach). Teeth are tended to compensate for skeletal discrepancies to have functional occlusion. The presurgical orthodontic treatment is needed to solve the dental decompensation that reveals the true extent of the skeletal deformity to align the teeth and to fit the maxilla and mandible into a good occlusion after surgery [11, 12]. Following the orthodontic treatment, orthognathic surgery corrects the skeletal discrepancy to obtain a good jaw alignment with good facial proportions. As the direction of presurgical orthodontic treatment is opposite to that of natural dental compensation forces, the orthodontic treatment time is said to require time to overcome the natural compensation forces [13]. The presurgical orthodontic treatment period which includes aligning dental occlusion, reversing incisor decompensation, correcting tooth rotation, and arch coordination lasts for 12–36 months depending on the complexity of case and also for a period after the surgery [13].

In last 10 years, surgery first approach (SFA) has begun to be implemented in some centers [14] and created broader interest [15–20].

The surgery first approach (SFA) is the orthognathic surgery approach that the orthognathic surgery precedes the orthodontic treatment. In the beginning of the treatment, surgery is performed without orthodontic preparation, and the orthodontic treatment is done after the surgery.

Historically, the SFA was presented by some researchers in earlier years [2, 21–24], but SFA in a combined treatment, which was introduced officially by Brachvogel et al. [25] and by Nagasaka et al., has gained attention in the past 10 years [26].

Among the published studies about SFA regarding the type of malocclusion, Class III is the most prevalent. Class III with openbite and asymmetry cases with SFA are the other published studies. SFA in Class II cases and in some deformities like TMJ disorders or condylar hyperplasia is rare [27–29].

## 2. The advantages of SFA

The advantages of SFA reported in literature continue. One of the advantages of the SFA is the shorter total treatment time [13, 15, 30]. Other advantages are that patients begin treatment with a much improved face esthetically in the beginning of the treatment and that the patient's chief complaint, dental function, and facial esthetics are achieved and improved in the beginning of the treatment [31, 32] and a psychosocial benefit of improved body image in the beginning of the treatment instead of worsening the facial appearance because of the presurgical decompensation of incisors [31, 34]. Improved corporation of the patient during the treatment may be the other advantage of SFA due to rapid profile improvement [33, 35]. SFA is also preferred in early correction of obstructive sleep apnea patients. On the other side, due to the early correction of skeletal and soft tissue problems, orthodontic treatment may be easier due to normalized surrounding soft tissue [23]. It was reported that the patients with preexisting TMJ dysfunction might experience a significant improvement of TMD signs and symptoms after SFA [29].

One of the reasons for the shorter duration of treatment in SFA is the regional accelerated phenomenon (RAP) which is the increase of the osteoclastic and metabolic activities due to the surgery. Selective bone injury activates stimulus for anabolic and catabolic responses in the periodontium adjacent to the osteotomies performed during orthognathic surgery and increases bone reorganization [32, 36–45]. It was reported that RAP in humans began in a few days after surgery and peaked at 1–2 months and took 6 months to more than 24 months to subside [39]. Liou et al. also studied the causes of rapid postoperative orthodontic treatment time in SFA cases, and they found that the levels of serum alkaline phosphatase and C-terminal telopeptide of type I collagen (ICTP) increased, which supported the postoperative accelerated orthodontic tooth movement caused the orthognathic surgery [15]. Zingler et al. found that crevicular fluids in SFA cases were higher levels of bone remodeling factors for fracture healing [32].

The other reason for the shorter duration of treatment in SFA than in the conventional approach may be improvement of function. Choi and Bradley reported that teeth tended

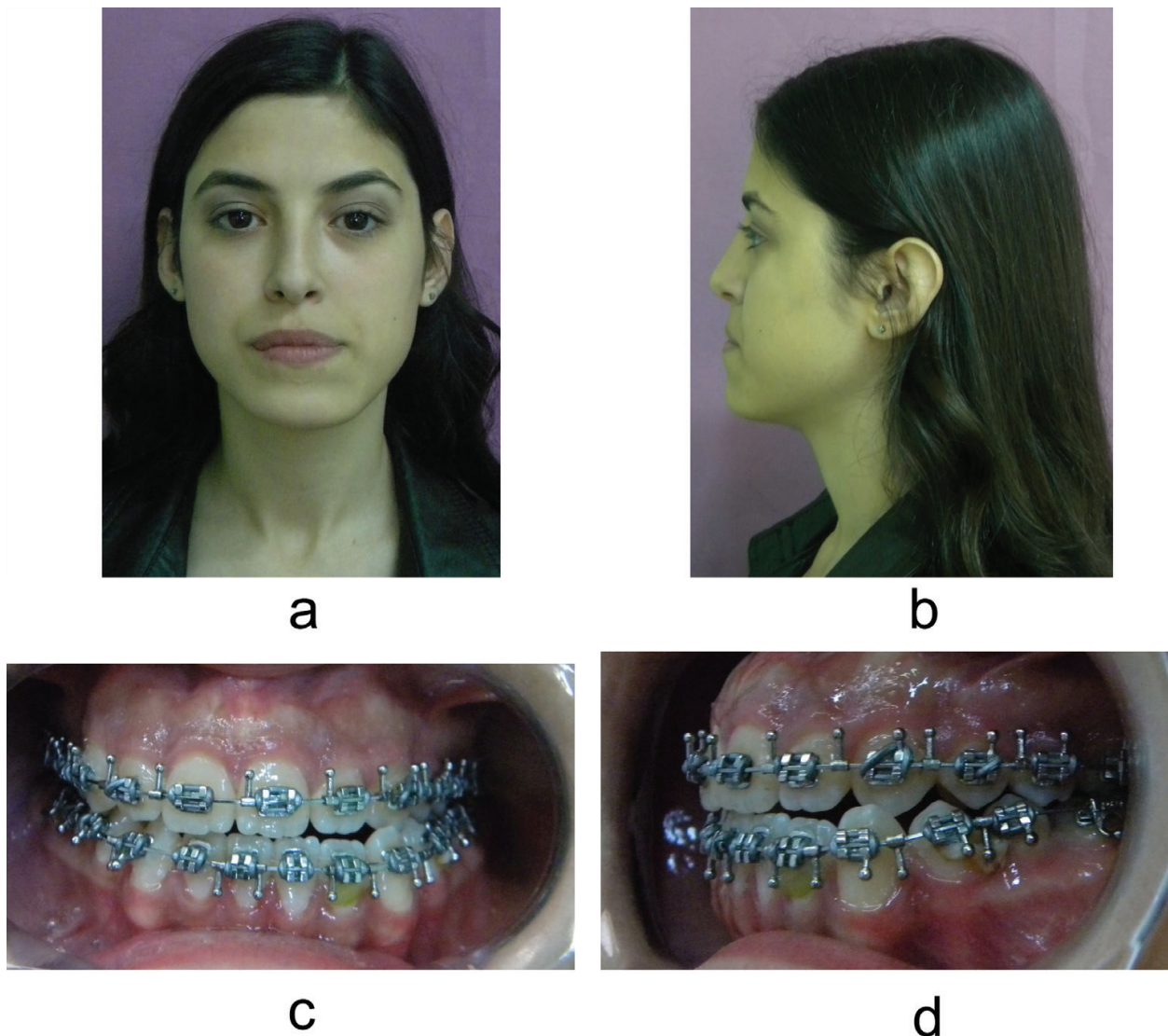


Figure 1. a-d: Facial asymmetry case. Passive arch wires were inserted the day before surgery.



to move in the direction of decompensation to perform the function following the surgery [46]. Postoperative orthodontic direction and function improve the efficiency of decompensation. Additionally, orthodontic movement via a more rapid natural dental adaptation by facilitating natural compensation may be performed easier with less occluded occlusion.

Orthodontic treatment time depends on the complexity of case. The shortest reported treatment time is 4 months (**Figure 1a-d, 2a-d**) but generally it takes 6–12 months [17, 26, 28, 33, 35, 47–50]. Tooth extraction is the factor that influences the total treatment time [13], and in some cases, the time range was reported between 10 and 19 months [51–53].

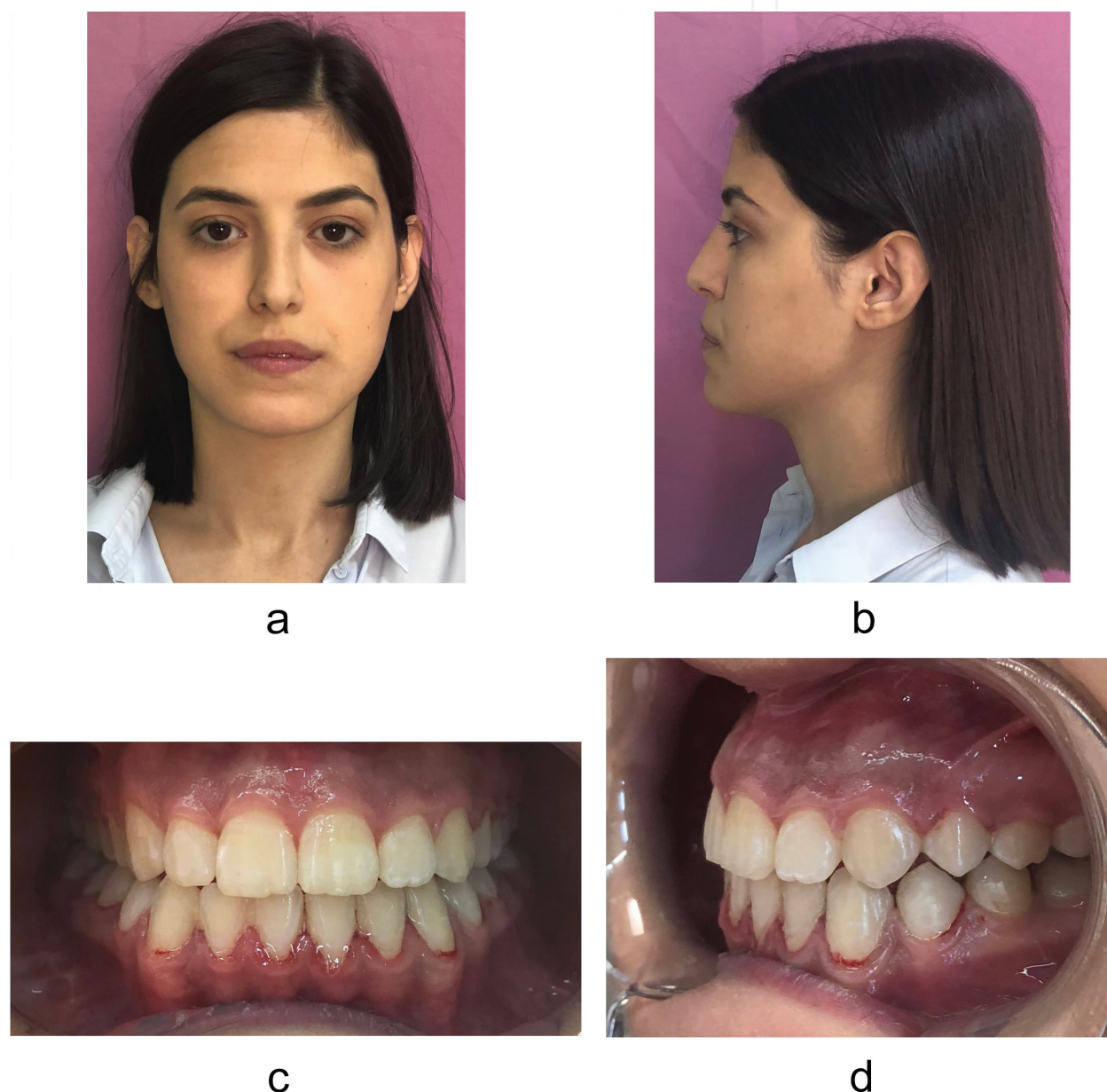

Figure 2. a-d: Three months later after surgery. Total treatment time 3 and half months.

### 3. Treatment plan in SFA

SFA is indicated more common in some cases like well-aligned to mildly crowded anterior teeth, flat to mildly curve of Spee, and normal to mildly proclined/retroclined incisor inclination. The protocol of presurgical orthodontics is well known in conventional approach [4, 8]; however, treatment plan including orthodontic treatment is questioned in SFA especially in complex cases. The orthodontic management and treatment plan are different in SFA compared with the conventional approaches.

In treatment plan, accurate and detailed prediction of the postoperative orthodontic treatment is required at the beginning of all treatment [50]. Following the analysis of occlusion with model mounting, of detailed clinical and cephalometrics, presurgical orthodontic setup that is useful for accurate prediction and simulation of postsurgical orthodontics and cephalometric setup may be required before the surgery [13, 51].

The model surgery is a setup according to the cephalometric and molar relationship. Three stable occlusion points between the upper and lower dentitions are required [38]. Liou et al. reported that the molar relationship could be set up in Class I in cases of nonextraction or bimaxillary first premolar extraction, Class III in cases of lower first premolar extraction, and Class II in cases of maxillary first premolar extraction [16].

Following cephalometric, model, and clinical diagnosis, the aim is to optimize the position of facial components to attain the most desirable results in esthetics, function, and stability. The skeletal movements in all anteroposterior, vertical, and transverse directions are determined to obtain good facial proportions, smile esthetics, and occlusion.

Liou et al. have made some suggestions in treatment plan of SFA [16]. In Class III cases, to correct the decompensation of maxillary incisor, first premolar extraction and retraction of anterior teeth can be done by orthodontics or by anterior segmental osteotomy. If the case has moderately retroclined and crowded lower incisors, the molars in a Class I relationship with an excessive incisor overjet can be planned. In cases with severe crowding and retroclination in mandible, first premolar extraction and lower anterior setback osteotomy can be planned. In Class III cases with deep curve of Spee, leveling of Spee can be corrected before the surgery or can be corrected with lower anterior segmental osteotomy surgically to avoid upward-forward rotation of mandible postoperatively, which is not preferred in Class III cases. The chin cap therapy may be used to prevent the skeletal postsurgical relapse after surgery for 3 months [16]. In Class II cases, in mandibular retrognathia with deep curve of Spee, mandibular advancement with surgical intrusion of anterior segment to advance mandible properly or mandibular advancement followed by orthodontically intrusion of lower incisor postsurgically is proposed to obtain a better chin profile. Otherwise, the mandible cannot be advanced properly and lower face can be longer with correction of posterior openbite after surgery, and this cannot be preferred in some long face case. But in some cases where advancements are not required much, correction of posterior openbite only with posterior extrusion can be preferred [54].

#### 4. Time for orthodontic bonding and force application

On the basis of simulated model surgery setup, surgical guidance splint is prepared. Before the surgery, orthodontic bracket bonding/banding is placed but no arch wire is used. Bonding orthodontic bracket was reported as immediately before surgery [26, 47, 48], 1 week before surgery [16, 26, 38], and 1–2 months before surgery [50]. Some studies reported the usage of passive archwire before the surgery [49, 50, 52, 53, 55]. Passive arch can be used 1–3 days before the surgery [17, 35]. In some cases, the orthodontist can prefer minimal orthodontic preparation during 6 months [49] before the surgery, and then, they are continuing the orthodontic treatment after the surgery. Intermaxillary fixation of jaws during the surgery can be done by bony screws following the surgical guidance splints placements in cases without arch wires [47, 50, 51]. Kim et al. maintained intermaxillary fixation without surgical splint for 2 weeks but used intermaxillary elastic [50]. The osteotomized bones are fixed by rigid fixation.

Postoperatively, surgical splint is left for 2–4 weeks [34, 50, 53], and intermaxillary elastics usage may begin after orthodontic wire was placed.

There is no definitive consensus about postsurgical orthodontic force application time. But generally, the orthodontic treatment in SFA begins in 1 or 2 weeks after surgery. The surgical splint and inter-maxillary fixation were removed for the tooth movement. Liao et al. reported that postsurgical orthodontics begun immediately after surgery [17]. This is beneficial to shorten the orthodontic treatment time due to the regional accelerated phenomena. The studies showed that the orthognathic surgery triggers a 3- to 4-month period of higher osteoclastic activity, serum findings, and metabolic changes and that in the dentoalveolar bone postoperatively [15, 56]. Archwire changes took place every 2–3 weeks. Arch coordination may be managed with transpalatal elastics or active transpalatal arch. In segmental surgery patients, passive continuous arches which were placed before surgery are changed with sectional arches at first orthodontic appointment after surgery.

#### 5. Relapse in SFA

The short- and long-term relapse rates in SFA have been investigated, and the results are good by comparison with the conventional surgical approach with a maximum follow-up of 3 years [19, 57–59]. Without presurgical orthodontics, the patients may have likely to develop unstable occlusion after surgery leading to relapse. However, some of the comparative studies between conventional and surgery first approach showed no statistical differences in relapse and almost equal for those achieved using the more traditional orthodontics-first approach [17, 19, 51, 53, 59–63]. Advancement of fixation system enabled more stabilized results due to more stable fixation of bony segments. On the other side, based on one research and on the meta-analysis, SFA showed more relapses than in the conventional approach [57, 64]. Larger overbite, a deeper curve of Spee, a greater negative overjet, and a greater mandibular setback were reported to affect stability in SFA cases [59].

Although there are benefits of the SFA, there are some difficulties like the prediction of final occlusion, instability of postsurgical transient occlusion [10, 65], the requirement of presurgical orthodontic setup before surgery in some complex cases, and requirement of frequent orthodontic appointment due to RAP. The treatment plan requires detailed and meticulous planning.

## 6. Conclusion

The surgery first approach is an alternative method that may be more satisfying for orthodontists and patients by minimizing the treatment time required for orthodontic treatment compared to conventional approach.

## Author details

Ayşe Gülşen

Address all correspondence to: [aysegulsen1968@gmail.com](mailto:aysegulsen1968@gmail.com)

Department of Plastic Reconstructive and Esthetic Surgery, University of Gazi, Ankara, Turkey

## References

- [1] Obwegeser HL. Surgical correction of small or retrodisplaced maxillae. The “dish-face” deformity. *Plastic and Reconstructive Surgery*. 1969;**43**:351-365
- [2] Poulton DR, Taylor RC, Ware WH. Cephalometric x-ray evaluation of the vertical osteotomy correction of mandibular prognathism. *Oral Surgery, Oral Medicine, and Oral Pathology*. 1963;**16**:807-820
- [3] Poulton DR, Ware WH. Surgical-orthodontic treatment of severe mandibular retrusion. II. *American Journal of Orthodontics*. 1973;**3**:237-255
- [4] Bell WH, Creekmore TD. Surgical-orthodontic correction of mandibular prognathism. *American Journal of Orthodontics*. 1973;**63**:256-270
- [5] Bell WH, Proffit WR, White RP. *Surgical Correction of Dentofacial Deformities*. Philadelphia: Saunders; 1980. pp. 1-3
- [6] Worms FW, Isaacson RJ, Speidel TM. Surgical orthodontic treatment planning: Profile analysis and mandibular surgery. *The Angle Orthodontist*. 1976;**46**:1-25
- [7] Proffit WR, White RP Jr. Who needs surgical-orthodontic treatment? *The International Journal of Adult Orthodontics and Orthognathic Surgery*. 1990;**5**:81-89



- [8] Proffit WR, Miguel JA. The duration and sequencing of surgical-orthodontic treatment. *The International Journal of Adult Orthodontics and Orthognathic Surgery*. 1995;10:35-42
- [9] Proffit WR, White RP, Sarver DM. Combining surgery and orthognathics: Who does what, when? In: Proffit WR, White RP, Sarver DM, editors. *Contemporary Treatment of Dentofacial Deformity*. St Louis, MO. Mosby; 2003. pp. 245-267
- [10] Sabri R. Orthodontic objectives in orthognathic surgery: State of the art today. *World Journal of Orthodontics*. 2006;7:177-191
- [11] Grubb J, Evans C. Orthodontic management of dentofacial skeletal deformities. *Clinics in Plastic Surgery*. 2007;34:403-415
- [12] Liou EJW, Chen PH, Wang YC, Yu CC, Huang CS, , and Chen YR: Can a surgery-first orthognathic approach reduce the total treatment time time? *Journal of Oral and Maxillofacial Surgery*. 2011;69:771-780
- [13] Jeong WS, Choi JW, Kim DY, Lee JY, Kwon SM. Can a surgery-first orthognathic approach reduce the total treatment time? *International Journal of Oral and Maxillofacial Surgery*. 2017;46:473-482
- [14] Assael LA. The biggest movement: Orthognathic surgery undergoes another paradigm shift. *Journal of Oral and Maxillofacial Surgery*. 2008;66:419-420
- [15] Liou EJ, Chen PH, Wang YC, Yu CC, Huang CS, Chen YR. Surgery-first accelerated orthognathic surgery: Postoperative rapid orthodontic tooth movement. *Journal of Oral and Maxillofacial Surgery*. 2011;69:781-785
- [16] Liou EJ, Chen PH, Wang YC, Yu CC, Huang CS, Chen YR. Surgery- first accelerated orthognathic surgery: Orthodontic guidelines and setup for model surgery. *Journal of Oral and Maxillofacial Surgery*. 2011;69:771-780
- [17] Liao YF, Chiu YT, Huang CS, Ko EW, Chen YR. Presurgical orthodontics versus no pre-surgical orthodontics: Treatment outcome of surgical-orthodontic correction for skeletal class III open bite. *Plastic and Reconstructive Surgery*. 2010;126:2074-2083
- [18] Park SH, Hyon WS, Lee JK, Lee YK. Paradigm shift in orthognathic surgery: Surgery first orthognathic approach and aesthetic two-jaw surgery. *Journal of the Korean Society for Aesthetic Plastic Surgery*. 2010;16(1):9-14
- [19] Park KH, Sandor GK, Kim YD. Skeletal stability of surgery-first bimaxillary orthognathic surgery for skeletal class III malocclusion, using standardized criteria. *International Journal of Oral and Maxillofacial Surgery*. 2016;45:35-40
- [20] Park HM, Lee YK, Choi JY, Baek SH. Maxillaryincisorinclinationof skeletal Class III patients treated with extraction of the upper first premolars and two-jaw surgery: conventional orthognathic surgery vs surgery-first approach. *The Angle Orthodontist*. 2014;84:720-729
- [21] Dingman RO. Surgical correction of developmental deformities of the mandible. *Plastic and Reconstructive Surgery*. 1946;3(2):124-146

- [22] Epker BN, Fish L. Surgical-orthodontic correction of open-bite deformity. *American Journal of Orthodontics*. 1977;**71**:278-299
- [23] Behrman SJ, Behrman DA. Oral surgeons' considerations in surgical orthodontic treatment. *Dental Clinics of North America*. 1988;**32**:481-507
- [24] Lee RT. The benefits of post-surgical orthodontic treatment. *British Journal of Orthodontics*. 1994;**21**:265-274
- [25] Brachvogel P, Berten JL, Hausamen JE. Surgery before orthodontic treatment: A concept for timing the combined therapy of skeletal dysgnathias. *Deutsche Zahn-, Mund-, und Kieferheilkunde mit Zentralblatt*. 1991;**79**(7):557-563
- [26] Nagasaka H, Sugawara J, Kawamura H, Nanda R. "Surgery first" skeletal Class III correction using the Skeletal Anchorage System. *Journal of Clinical Orthodontics*. 2009;**43**:97-105
- [27] Park KR, Kim SY, Park HS, Jung YS. Surgery-first approach on patients with temporomandibular joint disease by intraoral vertical ramus osteotomy. *Oral Surgery, Oral Medicine, Oral Pathology, Oral Radiology*. 2013 Dec;**116**(6):e429-e436
- [28] López DF, Aristizábal JF, Martínez-Smit R. Condylectomy and "surgery first" approach: An expedited treatment for condylar hyperplasia in a patient with facial asymmetry. *Dental Press Journal of Orthodontics*. 2017;**22**(4):86-96
- [29] Pelo S, Saponaro G, De Angelis P, Gasparini G, Garagiola U, Moro A. Effect of surgery first orthognathic approach on the temporomandibular joint. *The Journal of Craniofacial Surgery*. 2018;**29**(3):671-675
- [30] Uribe F, Adabi S, Janakiraman N, Allareddy V, Steinbacher D, Shafer D, et al. Treatment duration and factors associated with the surgery-first approach: A two-center study. *Progress in Orthodontics*. 2015;**16**:29-35
- [31] Pelo S, Gasparini G, Garagiola U, Cordaro M, Di Nardo F, Staderini E, et al. Surgery-first orthognathic approach vs traditional orthognathic approach: Oral health-related quality of life assessed with 2 questionnaires. *American Journal of Orthodontics and Dentofacial Orthopedics*. 2017;**152**(2):250-254
- [32] Zingler S, Hakim E, Finke D, Brunner M, Saure D, Hoffmann J, et al. Surgery-first approach in orthognathic surgery: Psychological and biological aspects. *Journal of Cranio-Maxillo-Facial Surgery*. 2017;**45**:1293-1301
- [33] Hernández-Alfaro F, Guijarro-Martínez R, Molina-Coral A, Badía-Escriche C. "Surgery first" in bimaxillary orthognathic surgery. *Journal of Oral and Maxillofacial Surgery*. 2011;**69**:e201-e207
- [34] Feu D, de Oliveira BH, Palomares NB, Celeste RG, Migue JAM. Oral health-related quality of life changes in patients with severe Class III malocclusion treated with the 2-jaw surgery-first approach. *American Journal of Orthodontics and Dentofacial Orthopedics*. 2017;**151**:1048-1057

- [35] Hernandez-Alfaro F, Guijarro-Martinez R, MA P-G. Surgery first in orthognathic surgery: what have we learned? A comprehensive workflow based on 45 consecutive cases. *Journal of Oral and Maxillofacial Surgery*. 2014;**72**:376-390
- [36] Hajji SS. The Influence of Accelerated Osteogenic Response on Mandibular Crowding. St. Louis, Missouri: St. Louis University, Center for Advanced Dental Education. 2000:1-49
- [37] Wilcko WM, Wilcko T, Bouquot JE, Ferguson DJ. Rapid orthodontics with alveolar reshaping: two case reports of decrowding. *The International Journal of Periodontics & Restorative Dentistry*. 2001;**21**:9-19
- [38] Villegas C, Uribe F, Sugawara J, Nanda R. Expedited correction of significant dentofacial asymmetry using a “surgery first” approach. *Journal of Clinical Orthodontics*. 2010;**44**:97-103
- [39] Bogoch E, Gschwend N, Rahn B, Moran E, Perren S. Healing of cancellous bone osteotomy in rabbits—Part I: Regulation of bone volume and the regional acceleratory phenomenon in normal bone. *Journal of Clinical Orthodontics*. 1993;**11**:285-289
- [40] Yaffe A, Fine N, Binderman I. Regional accelerated phenomenon in the mandible following mucoperiosteal flap surgery. *Journal of Periodontology*. 1994;**65**:79-83
- [41] Bogoch E, Gschwend N, Rahn B, Moran E, Perren S. Healing of cancellous bone osteotomy in rabbits—Part II: Local reversal of arthritis-induced osteopenia after osteotomy. *Journal of Orthopaedic Research*. 1993;**11**:292-298
- [42] Frost MH. The biology of fracture healing: An overview for clinicians part I. *Clinical Orthopaedics*. 1989;**248**:283-293
- [43] Frost MH. The biology of fracture healing: An overview for clinicians part II. *Clinical Orthopaedics*. 1989;**248**:294-309
- [44] Staffilino H, Levy S, Gargiulo A.: Histologic study of cellular mobilization and repair following a periosteal retention operation via split thickness mucogingival flap surgery. *Journal of Periodontology*. 1966;**37**:117-131
- [45] Pfeifer JS. The reaction of alveolar bone to flap procedure in man. *Periodontics*. 1965;**3**:135-140
- [46] Choi JW, Bradley JP. Surgery first orthognathic approach without presurgical orthodontic treatment: Questions and answers. *The Journal of Craniofacial Surgery*. 2017 Jul;**28**(5):1330-1333
- [47] Sugawara J, Aymach Z, Nagasaka DH, Kawamura H, Nanda R. “Surgery first” orthognathics to correct a skeletal class II malocclusion with an impinging bite. *Journal of Clinical Orthodontics*. 2010;**44**:429-438
- [48] Sugawara J, Aymach Z, Nagasaka DH, Yu CC, Chen PH, Liou EJ, et al. A surgery-first approach in surgical-orthodontic treatment of mandibular prognathism—a case report. *Chang Gung Medical Journal*. 2009;**33**:699-705

- [49] Wang YC, Ko EW, Huang CS, Chen YR, Takano-Yamamoto T. Comparison of transverse dimensional changes in surgical skeletal Class III patients with and without presurgical orthodontics. *Journal of Oral and Maxillofacial Surgery*. 2010;**68**:1807-1812
- [50] Baek SH, Ahn HW, Kwon YH, Choi JY. Surgery- first approach in skeletal class III malocclusion treated with 2-jaw surgery: Evaluation of surgical movement and postoperative orthodontic treatment. *The Journal of Craniofacial Surgery*. 2010;**21**:332-338
- [51] Choi JW, Lee JY, Yang SJ, Koh KS. The reliability of a surgery-first orthognathic approach without presurgical orthodontic treatment for skeletal class III dentofacial deformity. *Annals of Plastic Surgery*. 2015;**74**:333-341
- [52] Ko EW, Hsu SS, Hsieh HY, Wang YC, Huang CS, Chen YR. Comparison of progressive cephalometric changes and postsurgical stability of skeletal Class III correction with and without presurgical orthodontic treatment. *Journal of Oral and Maxillofacial Surgery*. 2011;**69**:1469-1477
- [53] Kim CS, Lee SC, Kyung HM, Park HS, Kwon TG. Stability of mandibular setback surgery with and without presurgical orthodontics. *Journal of Oral and Maxillofacial Surgery*. 2014;**72**:779-787
- [54] Kochar GD, Chakranarayan A, Londhe SM, Varghese B, Jayan B, Chopra SS, et al. Management of skeletal class II malocclusion by surgery-first approach. *The Journal of Craniofacial Surgery*. 2017;**29**(3):671-675
- [55] Kim JY, Jung HD, Kim SY, Park HS, Jung YS. Postoperativestability for surgery-first approach using intraoral vertical ramus osteotomy: 12 month follow-up. *The British Journal of Oral & Maxillofacial Surgery*. 2014;**52**:539-544
- [56] Sebaoun JD, Ferguson DJ, Wilcko MT, Wilcko WM. Alveolar osteotomy and rapid orthodontic treatments. *L'Orthodontie Française*. 2007;**78**:217-225
- [57] Mah DH, Kim SG, Oh JS, You JS, Jung SY, Kim WG, et al. Comparative study of post-operative stability between conventional orthognathic surgery and a surgery-first orthognathic approach after bilateral sagittal split ramus osteotomy for skeletal Class III correction. *Journal of the Korean Association of Oral and Maxillofacial Surgeons*. 2017;**43**:23-28
- [58] Park HM, Yang II-H, Choi JY, Lee JH, Kim MJ, Baek SH. Postsurgical relapse in Class III patients treated with two-jaw surgery: Conventional three-stage method versus surgery-first approach. *The Journal of Craniofacial Surgery*. 2015;**26**:2357-2563
- [59] Ko EW, Lin SC, Chen YR, Huang CS. Skeletal and dental variables related to the stability of orthognathic surgery in skeletal class III malocclusion with a surgery-first approach. *Journal of Oral and Maxillofacial Surgery*. 2013;**71**:e215-e223
- [60] Huang CS, Hsu SSP, Chen YR. Systematic review of the surgery-first approach in orthognathic surgery. *Biomedical Journal*. 2014;**37**(4):184-190



- [61] Guo J, Wang T, Han JJ, Jung S, Kook MS, Park HJ, et al. Corrective outcome and transverse stability after orthognathic surgery using a surgery-first approach in mandibular prognathism with and without facial asymmetry. *Oral Surgery, Oral Medicine, Oral Pathology, Oral Radiology*. 2018;**5**:22-30
- [62] Jeong WS, Lee JY, Choi JW. Large-scale study of long-term vertical skeletal stability in a surgery-first orthognathic approach without presurgical orthodontic treatment: Part II. *The Journal of Craniofacial Surgery*. 2018;**29**(4):953-958
- [63] Lian YK, Hsieh AMC, Tsai MS, Jiang HR, Yen CY, Hsia YJ, et al. Treatment efficiency and stability of skeletal class III malocclusion with a surgery-first approach. *Orthodontics & Craniofacial Research*. 2018;**21**(2):90-95
- [64] Wei H, Liu Z, Zang J, Wang X. Surgery-first/early-orthognathic approach may yield poorer postoperative stability than conventional orthodontics-first approach: A systematic review and meta-analysis. *Oral Surgery, Oral Medicine, Oral Pathology, Oral Radiology*. 2018;**126**(2):107-116
- [65] Diaz PM, Garcia RG, Gias LN, Aquirre- Jaime A, Pe ´rez JS, de la Plata MM, et al. Time used for orthodontic surgical treatment of dentofacial deformities in white patients. *Journal of Oral and Maxillofacial Surgery*. 2010;**68**:88-92