

We are IntechOpen, the world's leading publisher of Open Access books Built by scientists, for scientists

6,900

Open access books available

186,000

International authors and editors

200M

Downloads

Our authors are among the

154

Countries delivered to

TOP 1%

most cited scientists

12.2%

Contributors from top 500 universities



WEB OF SCIENCE™

Selection of our books indexed in the Book Citation Index
in Web of Science™ Core Collection (BKCI)

Interested in publishing with us?
Contact book.department@intechopen.com

Numbers displayed above are based on latest data collected.
For more information visit www.intechopen.com



Topical NSAIDs in Prevention of Postcataract Macular Edema

Ahmed Alnagdy, Ahmed M. Eissa and Amr El-Kannishy

Abstract

Postoperative macular edema is considered one cause of diminished vision after cataract surgery. It was approved that inflammatory mediators especially prostaglandins play a key role in macular edema formation especially in the presence of risk factors that affect blood-retinal barrier such as diabetes, uveitis, tear of posterior capsule, and vitreous loss. So, anti-inflammatory medications like corticosteroids and NSAIDs are the cornerstone of macular edema managements. In spite of using corticosteroids as gold standard for treatment of ocular inflammation, they cannot be used for prolonged period due to associated adverse effects. Lastly, there were many studies about benefits of NSAIDs in management and prevention of macular edema to avoid the side effects of corticosteroids.

Keywords: NSAIDs, macular edema, phacoemulsification, cataract, blood-retinal barrier

1. Introduction

Macula is an important part of the retina, which is responsible for color vision, contrast sensitivity, sharp vision, communications and interpersonal relationships [1].

Macular thickening is well-known postoperative complication after cataract surgery, even with uncomplicated small incision phacoemulsification surgery. Sub-clinical cystoid macular edema (CME) is diagnosed with fluorescein angiography as leakage from perifoveal dilated capillaries without visual acuity affection [2]. Although fluorescein angiography is considered gold standard for diagnosis of macular edema, quantification of fluorescein leakage is difficult. Optical coherence tomography (OCT) nowadays has an upper hand in diagnosis of macular edema because of its advantages as a noninvasive device and can detect macular edema quantitatively and qualitatively [3].

Clinical CME can be identified on biomicroscopic examination and is associated with decreased visual acuity [4].

The pathogenesis of CME is disruption of blood-retinal barrier (BRB) by inflammatory mediators generated through several cascades as a result of surgical trauma to iris, ciliary body, or lens epithelial cells. Also, preexisting ocular conditions such as diabetes, hypertension, and uveitis, which affect BRB, can increase risk of CME [5].

The blood-retinal barrier in diabetic eyes is impaired to a variable degree, which plays a role in development of postoperative CME. CME in diabetic patients is affected by many factors including duration, severity of the disease, presence of

retinopathy, and previous treatment with photocoagulation [6]. Total ophthalmic payments were documented to be 47% higher in patients who developed postoperative CME [7]. So, prophylactic prevention or even decreased CME severity is cost savings, particularly among diabetic patients.

2. Macular anatomy and physiology

Being the main part of clear vision, the macula is located in the heart of the retina between upper and lower arcades measured about 4.5–6 mm in diameter. It can be divided into central fovea, surrounded by parafovea and outer perifovea (**Figure 1**) [8].

- Retinal vascular plexus was described simply into two planes: inner one at ganglion cell layer and outer plexus at inner nuclear layer [9] (**Figure 2**).

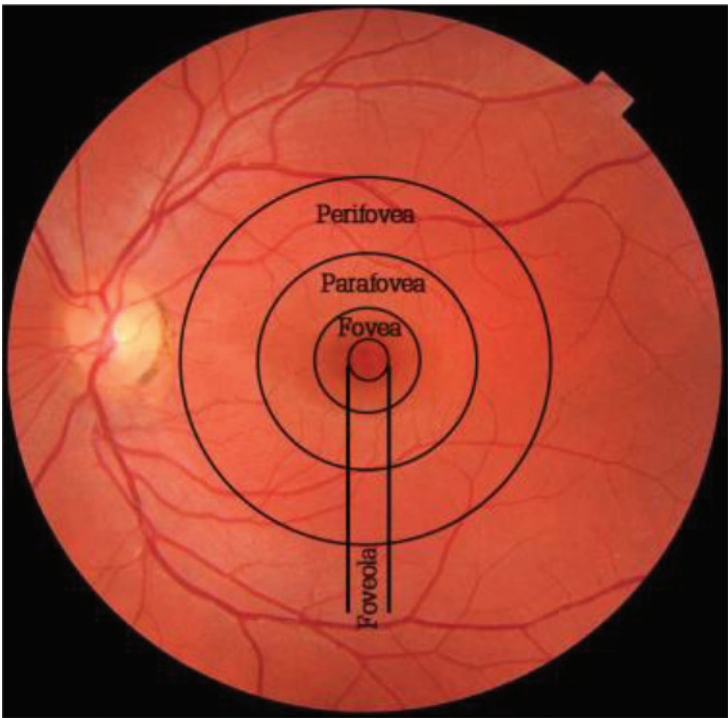


Figure 1. Parts of the macula from inside to outside: foveola, fovea, parafovea, and perifovea [8].

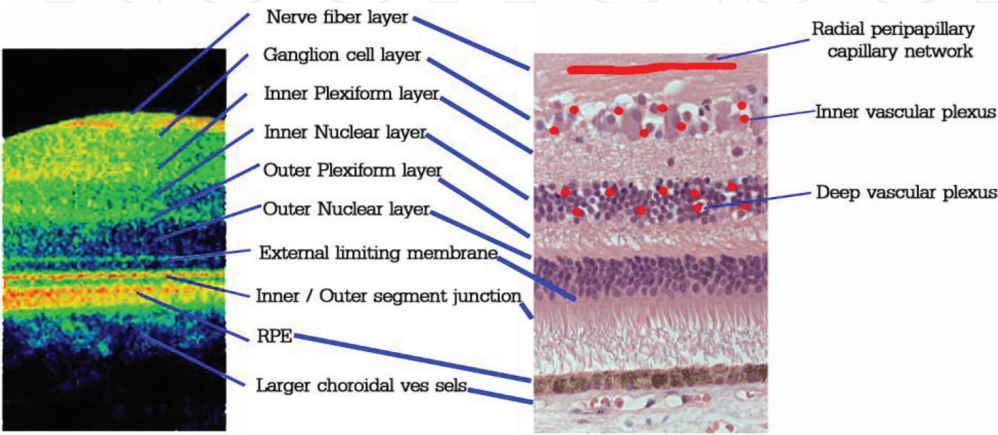


Figure 2. Vascular plexus position in layers of retina: inner vascular plexus in ganglion cell layer and deep vascular plexus in inner nuclear layer [9].

- As a whole, the retina blood supply is divided into outer part supplied by choriocapillaris and inner part supplied by retinal vascular plexus branch of posterior ciliary arteries [10].

3. The blood-retinal barrier

The blood-retinal barrier (BRB) is a barrier that physiologically establishes and maintains specific substrate and ion concentrations to allow proper neural function. BRB regulates flux of substances in retina such as ion, protein, and water and also regulates infiltration of immune competent cells and blood toxins. BRB is formed at two levels, inner and outer BRB. The inner one is composed of tight junctions between retinal vascular endothelial cells. The outer barrier is composed of tight junction between retinal pigment epithelium cells [11].

Pericytes secrete angiopoietin 1, which induces tight junction protein expression to support endothelial cells barrier [12].

3.1 Tight junction

Tight junction is mainly apical junctional complex, which has a barrier function against solute flux and movement of proteins and lipids into retinal parenchyma. This junction is showed as transmembrane proteins and junctional adhesion molecule (JAM) [13].

3.2 Adherens junction

Adherens junction is second barrier beneath the tight junction. This junction is important for development of the barrier as it affects formation of tight junction [14].

Tight junction: Transmembrane proteins claudins, occludin, and junctional adhesion molecule (JAM) connected with scaffolding protein ZO to actin.

Adherens junction: Vascular endothelial (VE) cadherin connected to actin through complex of β -catenin, α -catenin, and vinculin.

4. Pathophysiology

The macula is responsible for central 30 degrees of sharp vision with color vision, interpersonal relationships, communications, and contrast sensitivity [1]. The retina is very sensitive to fluctuation in blood oxygen levels and intraocular changes, as it consumes oxygen more than other tissues, being highly active tissue. Microchanges not felt by patient visual acuity are also not seen by inspection ophthalmoscopy examination [15].

It has been reported that clinical affection due to CME after uneventful phacoemulsification is between 0 and 9%. Furthermore, clinical affection between 9.1 and 20.4% with angiographic leakage is reported [16]. Interruption of blood-retinal barrier is the most accepted explanation of postoperative macular edema, which causes macular thickening. Surgical trauma disrupts the blood-aqueous barrier, release of prostaglandins, and increase of perifoveal capillaries' permeability of liquid in extracellular spaces, which cause macular thickening and CME [17]. The pathophysiology of these macular changes may be considered consecutively as follows: (1) release of inflammatory mediators into anterior chamber produced by surgical procedures; (2) removal of normally lens barrier, which separate posterior

segment from anterior segment; (3) local effect of inflammatory mediators on macular area; and (4) anterior displacement of vitreous leading to increase traction on macula [18].

Recently, being noninvasive, OCT has been established to be the main method for examining retinal architecture [19]. OCT can measure microhistological retinal changes in difference to fluorescein angiography, which detects it as a leakage that cannot be detected by biomicroscopy [20]. It was reported that subclinical increase in retinal thickness and volume can be found in the early course postoperatively at 4 weeks after phacoemulsification [21].

5. Nonsteroidal anti-inflammatory drugs

Surgical trauma stimulates arachidonic acid cascade, which stimulates phospholipase A2 enzyme to release arachidonic acid from membrane phospholipids and produces inflammatory mediators including prostaglandins (PGs) and leukotriene by activation of cyclooxygenase (COX) enzymes. COX-1 and COX-2 isoforms are believed to be the primary mediator of ocular inflammation. PG is an important mediator of postoperative complications, associated with symptoms including pain, ciliary injection, cystoid macular edema, impaired vision, and intraoperative miosis [22].

So, treatment of ocular inflammation depends mainly on stopping of arachidonic cascades by corticosteroids and nonsteroidal anti-inflammatory drugs (NSAIDs). Corticosteroids inhibit the activity of phospholipase A2 enzyme, but NSAIDs inhibit PGs synthesis irreversibly and nonspecifically by direct inhibition of COX-1 and COX-2 activity [23] (Figure 3).

5.1 Corticosteroids

In spite of using corticosteroids as gold standard for treatment of ocular inflammation, they cannot be used for prolonged period due to associated adverse effects.

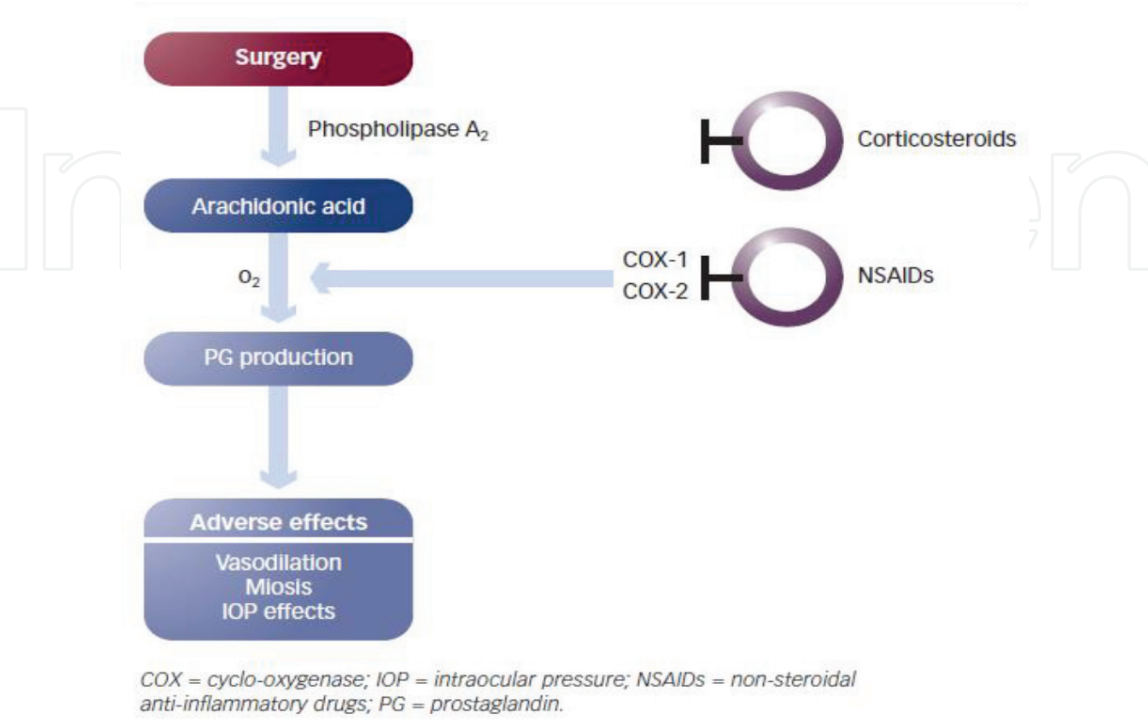


Figure 3.
Action of corticosteroid and NSAIDs on arachidonic acid cascade [23].

Side effects of corticosteroids include increased susceptibility to infections as a result of suppression of host immune response, retardation of corneal wound healing, and increased intraocular pressure (IOP) [24].

5.2 Nonsteroidal anti-inflammatory drugs

NSAIDs are considered as safety option used for treatment of ocular inflammation. NSAIDs inhibit COX activity patently by several chemically heterogeneous classes [25].

Currently, the uses of topical NSAIDs in ophthalmology to reduce pain and discomfort after cataract and refractive surgery prevent intraoperative miosis during cataract surgery and manage postoperative inflammation (**Table 1**) and are also reported to have a role in prevention of CME after cataract surgery [25, 27].

NSAIDs have beneficial effects over corticosteroids including analgesia effect, maintaining pupillary dilatation if used preoperatively (**Figure 4**), and also reduce the risk of secondary infections and increased IOP [25].

5.3 Pharmacokinetics

Diclofenac: Plasma levels reached (10 ng/mL) during a 4 hours period after instillation of two drops in each eye [29].

Flurbiprofen: No information about systemic absorption was approved.

Ketorolac: The use of ketorolac in 26 patients with one drop in each eye three times daily resulted in 5/26 (= 19.2%) with detectable plasma level of ketorolac (10.7–22.5 ng/mL) after 10 days.

Bromfenac: After topical administration, plasma level is expected to be below the detectable limit (50 ng/mL).

Nepafenac: It is an inactive prodrug, which penetrates corneal epithelium and is converted by ocular tissue hydrolases to active form amfenac. Plasma levels of bromfenac and amfenac were detected 2–3 hours in most patients after installation of nepafenac in both eyes but with low plasma level.

Drug	Indications	
Diclofenac sodium	Management of postoperative inflammation in patients after cataract extraction Decrease of pain and photophobia in patients after corneal refractive surgery	
Flurbiprofen sodium	Maintenance of intraoperative pupil dilatation	
Ketorolac tromethamine	(0.5%)	Temporary relief of ocular itching associated with seasonal allergic conjunctivitis Management of postoperative inflammation in patients after cataract extraction
	(0.4%)	Decrease of ocular pain and burning/stinging in patients undergoing corneal refractive surgery
	(0.45%)	Reduction of ocular pain and inflammation associated with/following
	(0.5%)	cataract surgery
Bromfenac sodium	Management of postoperative inflammation and pain after cataract surgery	
Nepafenac	Management of inflammation and pain associated with cataract surgery	

Table 1.
Ophthalmic NSAIDs’ FDA-approved indications [26].

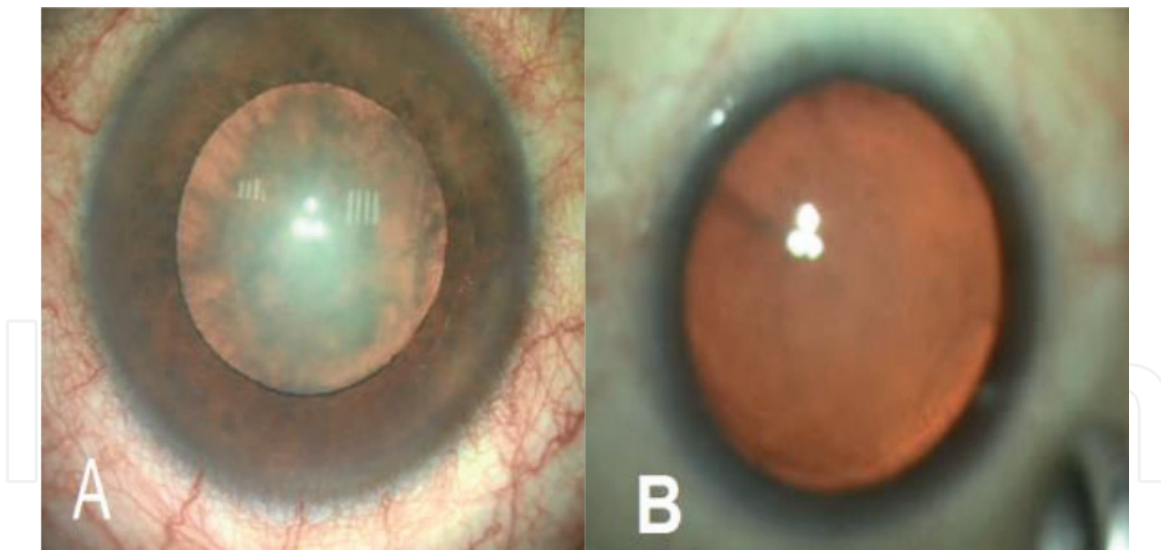


Figure 4.
Comparing pupil poor dilatation in control group (A) and full dilated pupil with NSAIDs (B) [28].

5.4. Limitation of NSAIDs

Topical NSAIDs contain some warnings, which include the following:

1. Prolonged bleeding time [30].
2. Cross-sensitivity with phenyl acetic acid derivatives, acetylsalicylic acid, and other NSAIDs [31].
3. Delay wound healing mainly if used in combination with corticosteroids [32].
4. Topical NSAIDs may cause ocular surface toxicity especially in patients having dry eye syndrome, corneal denervation, corneal epithelial defects, or diabetes [33].

6. Discussion

In the last few years, there were many studies using NSAIDs to prevent postoperative CME in different situations. In **Table 2**, some studies focus on the effect of NSAIDs in prevention of postoperative CME in diabetic patients. All of them approved significant low macular thickening in diabetic patients receiving NSAID bromfenac only [34], classical postoperative steroid regimen in addition of nepafenac [35] or either nepafenac or ketorolac with classical postoperative steroid regimen [28].

Other studies documented the effect of NSAIDs in a mixed population (nondiabetic and diabetic patients) without cystoid macular edema preoperatively and with no predisposing factors for developing cystoid macular edema (**Table 3**). Some studies documented that topical steroid medication may not be absolutely essential after uneventful cataract surgery [37, 44]. Topical nonsteroidal started 1 day before surgery and continued for 1 month by Almeida et al. [37], while Nishino et al. [44] started medication postoperatively and continued for 1 month. On the other hand, many studies approved the significant importance of topical NSAIDs in prevention of macular edema [36, 38–43, 45, 46]. topical ketorolac had more effect in decreasing macular edema than prednisolone only, if started 2 days before surgery and continued for 1 month postoperatively in combination with

Study	Number	Groups	Follow-up	Conclusion
Endo et al. [34]	62 (26 patients with nonproliferative diabetic retinopathy)	1. Bromfenac (<i>n</i> = 31) (16 with NPDR) 2. Steroidal solution (<i>n</i> = 31) (11 with NPDR)	OCT 6 weeks	The perifoveal values were significantly lower in the bromfenac group
Singh et al. [35]	263 patients with nonproliferative diabetic retinopathy	1. Nepafenac (<i>n</i> = 125) 2. Vehicle (<i>n</i> = 126)	OCT 90 days	Significantly lower percentage of patients in the nepafenac group developed macular edema
Alnagdy et al. [28]	80 without diabetic retinopathy	1. Placebo group + prednisolone 2. Nepafenac 0.1% + prednisolone 3. Ketorolac 0.4% + prednisolone	OCT 3 months	Perioperative NSAIDs reduce the frequency and severity of CME in diabetic eyes following cataract surgery

Table 2.
Clinical trials using ophthalmic NSAIDs to prevent postoperative macular edema in diabetic patients without cystoid macular edema preoperatively and with no predisposing factors for developing cystoid macular edema.

Study	Number	Groups	Follow-up	Conclusion
Almeida et al. [36]	106	1. Prednisolone 1% 2. Prednisolone 1% + ketorolac 0.5%	OCT 1 month	After cataract surgery, ketorolac 0.5% effectively decreases postoperative macular edema
Almeida et al. [37]	193	1. Prednisolone 1% 2. Prednisolone 1% + nepafenac 0.1% 3. Prednisolone 1% + ketorolac 0.5% (1 day before surgery for 1 month postoperative)	OCT 1 month	There was no difference in macular volume between the placebo, ketorolac, and nepafenac
Cable et al. [38]	20 diabetic patients without edema could be enrolled	1. Prednisolone + bromfenac 2. Prednisolone + nepafenac	OCT 6 weeks	Postoperative bromfenac showed a trend toward improved vision, less retinal thickening, and more stable macular volumes overall
Cervantes-Coste et al. [39]	60 excluding proliferative DR, macular edema, uncontrolled DM	1. Dexamethasone 2. Dexamethasone + nepafenac	OCT 6 weeks	Nepafenac has a role in reducing macular edema after cataract surgery and in maintaining intraoperative mydriasis
Rossetti et al. 1996 [40]	88	1. Diclofenac 2. Placebo	Ocular inflammation and FFA and visual acuity 6 months	Diclofenac eye drops effectively reduced incidence of angiographic CME and ocular inflammation after cataract surgery

Study	Number	Groups	Follow-up	Conclusion
Miyake et al. [41]	118 without complications from diabetes mellitus	1. Fluorometholone 2. Diclofenac	Fundus fluorescein angiography (FFA) 8 weeks	Diclofenac was effective in prevention of CME following cataract surgery
Miyake et al. [42]	62	1. Fluorometholone 2. Diclofenac	FFA 5 weeks	Diclofenac was more effective than fluorometholone in preventing cystoid macular edema
Miyake et al. [43]	60	1. Fluorometholone 2. Nepafenac	OCT 5 weeks	Nepafenac was more effective than fluorometholone in preventing cystoid macular edema
Nishino et al. [44]	21	1. Bromfenac 2. Fluorometholone	FFA 1 month	Topical steroid medication may not be absolutely essential after uneventful phacoemulsification
Weber et al. [45]	123	1. Indomethacin 0.1% 2. Ketorolac 0.5%	OCT 90 days	Indomethacin 0.1% had the same effect as ketorolac 0.5% at first day postoperative and more effective than ketorolac 0.5% at first week in treating ocular inflammation after uncomplicated cataract surgery. There was no change from baseline in retinal thickness in two groups
Wittpenn et al. [46]	546	1. Ketorolac 0.4% (only 1 hour prior to surgery) + prednisolone for 1 month 2. Ketorolac 0.4 + prednisolone for 1 month	OCT 4–6 weeks	Perioperative ketorolac to postoperative prednisolone significantly reduces the macular thickening after cataract surgery

Table 3.
Clinical trials using ophthalmic NSAIDs to prevent postoperative macular edema in a mixed population (nondiabetic and diabetic patients) without cystoid macular edema preoperatively and with no predisposing factors for developing cystoid macular edema.

prednisolone had more effect in decreasing macular edema in comparison to post-operative topical prednisolone alone [36]. Wittpenn et al. approved that starting ketorolac 1 hour before surgery had significant effects in preventing macular edema [46]. Cervantes-Coste et al. documented that diclofenac effectively maintains mydriasis and decreases macular thickness [39]. Also, diclofenac eye drops in Rossetti et al. effectively reduced incidence of angiographic CME and ocular inflammation after cataract surgery [40], while Miyake et al. suggested that diclofenac effectively decreases CME in comparison to fluorometholone [41] and also approved its effect in preventing chronological change in choroidal blood flow and disruption of the blood-aqueous barrier [42]. In 2011, there was another study by

Miyake et al. which approved that nepafenac was more effective than fluorometholone in preventing cystoid macular edema [43]. In other hand, some studies compared the effect of different NSAIDs similar to the study by Cable et al. who suggested that bromfenac is more effective than nepafenac [38] and Weber et al. who suggested that there was no change from baseline in retinal thickness between indomethacin group and ketorolac group.

Nondiabetic patients who have undergone cataract surgery without preoperative macular edema and with no predisposing factors for developing cystoid macular edema were enrolled in studies in **Table 4**. In glaucoma patients after cataract surgery, Miyake et al. approved that diclofenac seems to prevent macular edema formation enhanced by latanoprost therapy [49], and timolol and its preservative benzalkonium chloride [50].

Study	Number	Groups	Follow-up	Conclusion
Donnenfeld et al. [47]	100	1. Prednisolone acetate 2. Ketorolac (3 days preoperative and 3 weeks postoperative) + prednisolone 3. Ketorolac (1 day preoperative and 3 weeks postoperative) + prednisolone 4. Ketorolac (1 hour preoperative and 3 weeks postoperative) + prednisolone	OCT 3 months	The preoperative use of ketorolac tromethamine 0.4% for 3 days followed by 1-day preoperatively provided optimum efficacy and superior outcomes relative to 1 hour preoperatively used
Mathys et al. [48]	84	1. Nepafenac 0.01% (three times before surgery) + prednisolone acetate 1% 2. Nepafenac 0.01% (three times before surgery and for 1 month) + prednisolone acetate 1%	OCT 8 weeks	The increase in postoperative macular thickness was small in both the control and treatment groups
Miyake et al. [49]	80 eyes with primary open-angle glaucoma, normal tension glaucoma, or ocular hypertension	1. Fluorometholone acetate 2. 0.1% diclofenac sodium	FFA 5 weeks	Administration of nonsteroidal eye drops such as diclofenac seems to prevent macular edema formation enhanced by latanoprost therapy
Miyake et al. [50]	60 eyes with primary open-angle glaucoma, normal-tension glaucoma, or ocular hypertension	1. 0.1% fluorometholone acetate 2. 0.5% diclofenac sodium	FFA	Diclofenac prevents cystoid macular edema caused by timolol and its preservative, benzalkonium chloride
Miyanaga et al. [51]	72	1. 0.1% betamethasone 1 month, then 0.1% fluorometholone 1 month 2. 0.1% bromfenac for 2 months 3. 0.1% betamethasone 1 month, then 0.1% fluorometholone 1 month, and 0.1% bromfenac twice 2 months	OCT 2 months	There were no significant differences in anti-inflammatory effects among the three groups

Study	Number	Groups	Follow-up	Conclusion
Moschos et al. [52]	79	1. Dexamethasone sodium phosphate 0.1% 2. Dexamethasone sodium phosphate + diclofenac sodium 0.1%	OCT 28 days	The addition of diclofenac did not seem to offer any additional benefit after uneventful phacoemulsification
Ticly et al. [53]	91	1. Prednisolone acetate 1% 2. Prednisolone acetate 1% + ketorolac tromethamine 0.4%	FFA 5 weeks	The addition of ketorolac tromethamine 0.4% did not seem to offer any additional benefit after uneventful phacoemulsification
Wang et al. [54]	240	1. Oral prednisone tablets 15 mg for 7 days + fluorometholone 0.1% for 1 month 2. Oral prednisone tablets 15 mg for 7 days + dexamethasone 0.1% for 1 month 3. Oral prednisone tablets 15 mg for 7 days + bromfenac 0.1% for 1 month 4. Oral prednisone tablets 15 mg for 7 days + bromfenac 0.1% for 2 months	OCT 2 months	Bromfenac sodium was more effective and safer than fluorometholone and dexamethasone as an anti-inflammatory
Yavas et al. [55]	189	1. Prednisolone 2. Prednisolone + indomethacin for 3 days preoperative and 1 month postoperative 3. Prednisolone + indomethacin for 1 month postoperative	FFA 3 months	Preoperative nonsteroidal anti-inflammatory drugs decreased the incidence of CME more than postoperative use only
Capote et al. [56]	243	1. Diclofenac sodium 0.1% 2. Bromfenac 0.09% 3. Nepafenac 0.1% All received prednisolone 1%	OCT 6 months	Bromfenac is more effective than diclofenac and nepafenac in reducing macular thickness after phacoemulsification
McCafferty et al. [57]	1000	1. Placebo 2. Nepafenac 0.3%	OCT FFA 5 weeks	Topical nepafenac 0.3% reduces macular edema in patients with preoperative risk compared to placebo, but there were no differences in patients without risk factors
Stock et al. [58]	77	1. Nepafenac 2. Propylene glycol as control 3. Ketorolac tromethamine	OCT 45 days	There were no significant differences in macular thickness between the three groups

Study	Number	Groups	Follow-up	Conclusion
Milla et al. [59]	38 glaucoma patients	1. Nepafenac group (<i>n</i> = 15) 2. Nonnepafenac group (<i>n</i> = 23) All received dexamethasone	OCT	Nepafenac has a prophylactic effect against postoperative macular edema
Tzelikis et al. [60]	224	Bilateral cataract was included in this study Each patient was assigned randomly to receive nepafenac 0.3% drops in one eye and a placebo in the fellow eye	OCT 12 weeks	Nepafenac 0.3% was effective in reducing macular thickness compared with a placebo 5 weeks postoperatively

Table 4.
Clinical trials using ophthalmic NSAIDs to prevent postoperative macular edema in nondiabetic patients without cystoid macular edema preoperatively and with no predisposing factors for developing cystoid macular edema.

Donnenfeld et al. documented that early started ketorolac 3 days or 1 day preoperatively provided superior outcomes over ketorolac starts only 1 hour preoperatively [47]. Also, preoperative indomethacin drugs decreased the incidence of CME more than postoperative use only in the study of Yavas et al. [55].

In comparative study between different NSAIDs, Capote et al. approved that bromfenac is more effective than diclofenac and nepafenac in reducing macular thickness after phacoemulsification [56]. In other study, bromfenac was more effective and safer in comparison to topical steroid; inspite of using oral prednisones for all patients in the study [54].

In other studies, NSAIDs did not seem to offer any additional benefit after uneventful phacoemulsification of diclofenac in the study of Moschos et al. [52] and ketorolac in the study of Ticly et al. [53]. Miyanaga et al. documented that 2 months' use of topical NSAIDs, different topical steroids, or alternating steroids and NSAIDs had no significant differences [51]. Stock et al. suggested no differences between nepafenac, control, and ketorolac through 45-day follow-up [58].

Mathys et al. told that routine use of preoperative nepafenac may be necessary to achieve excellent visual recovery if continued for 3 weeks postoperatively or not [48].

In the study of McCafferty et al., postoperative topical nepafenac reduces macular edema in patients with preoperative risk (diabetic retinopathy, contralateral CME, or prostaglandin use) compared to placebo, but there were no differences in patients without risk factors [57]. Nepafenac was effective in reducing macular thickness compared with a placebo in fellow eye 5 weeks postoperatively in patients who had bilateral phacoemulsification enrolled in the study of Tzelikis et al. [60].

7. Conclusion(s)

The most important line of management of postoperative macular edema is by prevention. NSAIDs have large effects in prevention of postoperative macular edema with minimal side effects. Furthermore, some studies have suggested that NSAIDs may have a greater effect in re-establishment of the blood-aqueous barrier than corticosteroids. The claim about synergistic effects of NSAIDs and corticosteroids is made by several authors. Although several studies may have favored

starting NSAID treatment preoperatively, there are no comparison studies about starting corticosteroids preoperatively.

Conflict of interest

The authors declare that they have no conflict of interest.

Author details


Ahmed Alnagdy^{1*}, Ahmed M. Eissa² and Amr El-Kannishy¹

1 Mansoura Ophthalmology Center, Mansoura University, Egypt

2 The General Organization of Teaching Hospitals and Institutes, Egypt

*Address all correspondence to: alnagdy28@gmail.com

IntechOpen

© 2019 The Author(s). Licensee IntechOpen. This chapter is distributed under the terms of the Creative Commons Attribution License (<http://creativecommons.org/licenses/by/3.0>), which permits unrestricted use, distribution, and reproduction in any medium, provided the original work is properly cited. 

References

- [1] DeBuc D, Somfai G. Early detection of retinal thickness changes in diabetes using optical coherence tomography. *Medical Science Monitor*. 2010;**16**: MT15-MT21
- [2] Montes J, Erakgun T, Afrashi F, Kerci G. Incidence of cystoid macular edema after uncomplicated phacoemulsification. *Ophthalmologica*. 2003;**217**:408-412. DOI: 10.1159/000073070
- [3] Soliman W, Sander B, Jørgensen T. Enhanced optical coherence patterns of diabetic macular oedema and their correlation with the pathophysiology. *Acta Ophthalmologica*. 2007;**85**:613-617. DOI: 10.1111/j.1600-0420.2007.00917.x
- [4] Lobo C. Pseudophakic cystoid macular edema. *Ophthalmologica*. 2012; **227**:61-67. DOI: 10.1159/000331277
- [5] Miyake K, Ibaraki N. Prostaglandins and cystoid macular edema. *Survey of Ophthalmology*. 2002;**47**:S203-S218. DOI: 10.1016/S0039-6257(02)00294-1
- [6] Krepler K, Biowski R, Schrey S, Jandrasits K, Wedrich A. Cataract surgery in patients with diabetic retinopathy: Visual outcome, progression of diabetic retinopathy, and incidence of diabetic macular oedema. *Graefes Archive for Clinical and Experimental Ophthalmology*. 2002;**240**:735-738
- [7] Schmier JK, Halpern MT, Covert DW, Matthews GP. Evaluation of costs for cystoid macular edema among patients after cataract surgery. *Retina*. 2007;**27**:621-628
- [8] Sawides L, de Castro A, Burns S. The organization of the cone photoreceptor mosaic measured in the living human retina. *Vision Research*. 2016;**132**:34-44. DOI: 10.1016/j.visres.2016.06.006
- [9] Spaide R, Klancnik J, Cooney M. Retinal vascular layers imaged by fluorescein angiography and optical coherence tomography angiography. *JAMA Ophthalmology*. 2015;**133**:45-50. DOI: 10.1001
- [10] Ramírez J, Rojas B, Gallego B, García-Martín E, Triviño A, Ramírez A, et al. Glia and blood-retinal barrier: Effects of ocular hypertension. In: *Cardiovascular Disease II*. Hong Kong: Concept Press. 2014. pp. 123-162
- [11] Cunha-Vaz J, Bernardes R, Lobo C. Blood-retinal barrier. *European Journal of Ophthalmology*. 2010;**21**:S3-S9. DOI: 10.1371/journal.pone.0095420
- [12] Hori S, Ohtsuki S, Hosoya K, Nakashima E, Terasaki T. A pericyte-derived angiopoietin-1 multimeric complex induces occludin gene expression in brain capillary endothelial cells through tie-2 activation in vitro. *Journal of Neurochemistry*. 2004;**89**: 503-513. DOI: 10.1111/j.1471-4159.2004.02343.x
- [13] Runkle E, Antonetti D. The blood-retinal barrier: Structure and functional significance. In: Nag S, *The Blood-Brain and Other Neural Barriers: Reviews and Protocols*. Totowa, NJ: Humana Press, Springer. 2011. pp. 133-148. https://doi.org/10.1007/978-1-60761-938-3_5
- [14] Miyoshi J, Takai Y. Molecular perspective on tight-junction assembly and epithelial polarity. *Advanced Drug Delivery Reviews*. 2005;**57**:815-855. DOI: 10.1016/j.addr.2005.01.008
- [15] Hee M, Izatt J, Swanson E, Huang D, Schuman J, Lin C, et al. Optical coherence tomography of the human retina. *Archives of Ophthalmology*. 1995;**113**:325-332. DOI: 10.1001/archophth.1995.01100030081025
- [16] Gulkilik G, Kocabora S, Taskapili M, Engin G. Cystoid macular edema after phacoemulsification: Risk factors and

- effect on visual acuity. *Canadian Journal of Ophthalmology*. 2006;**41**:699-703. DOI: 10.3129/i06-062
- [17] Ursell P, Spalton D, Whitcup S, Nussenblatt R. Cystoid macular edema after phacoemulsification: Relationship to blood–aqueous barrier damage and visual acuity. *Journal of Cataract and Refractive Surgery*. 1999;**25**:1492-1497. DOI: 10.1016/S0886-3350(99)00196-0
- [18] Kičová N, Bertelmann T, Irle S, Sekundo W, Mennel S. Evaluation of a posterior vitreous detachment: A comparison of biomicroscopy, B-scan ultrasonography and optical coherence tomography to surgical findings with chromodissection. *Acta Ophthalmologica*. 2012;**90**:e264-e268. DOI: 10.1111/j.1755-3768.2011.02330.x
- [19] Vukicevic M, Gin T, Al-Qureshi S. Prevalence of optical coherence tomography-diagnosed postoperative cystoid macular oedema in patients following uncomplicated phacoemulsification cataract surgery. *Clinical & Experimental Ophthalmology*. 2012;**40**:282-287. DOI: 10.1111/j.1442-9071.2011.02638.x
- [20] Muscat S, Parks S, Kemp E, Keating D. Repeatability and reproducibility of macular thickness measurements with the Humphrey OCT system. *Investigative Ophthalmology & Visual Science*. 2002;**43**:490-495
- [21] Degenring R, Vey S, Kamppeter B, Budde W, Jonas J, Sauder G. Effect of uncomplicated phacoemulsification on the central retina in diabetic and non-diabetic subjects. *Graefes archive for Clinical and Experimental Ophthalmology*. 2007;**245**:18-23
- [22] Cho H, Wolf K, Wolf E. Management of ocular inflammation and pain following cataract surgery: Focus on bromfenac ophthalmic solution. *Clinical Ophthalmology*. 2009;**3**:199-210
- [23] Polansky J, Weinreb R. Anti-inflammatory agents. In: *Pharmacology of the Eye*. Berlin, Heidelberg: Springer; 1984. pp. 459-538. https://doi.org/10.1007/978-3-642-69222-2_11
- [24] McGhee C, Dean S, Danesh-Meyer H. Locally administered ocular corticosteroids. *Drug Safety*. 2002;**25**:33-55
- [25] O'Brien T. Emerging guidelines for use of NSAID therapy to optimize cataract surgery patient care. *Current Medical Research and Opinion*. 2005;**21**:1131-1137. DOI: 10.1185/030079905X50651
- [26] Drugs@FDA [Internet]. 2018. Rockville (MD): Food and Drug Administration (US), Center for Drug Evaluation and Research. Available from: <http://www.accessdata.fda.gov/scripts/cder/drugsatfda/index.cfm> [cited: July 2018]
- [27] Heier J, Topping T, Baumann W, Dirks M, Chern S. Ketorolac versus prednisolone versus combination therapy in the treatment of acute pseudophakic cystoid macular edema. *Ophthalmology*. 2000;**107**:2034-2038. DOI: 10.1016/S0161-6420(00)00365-1
- [28] Alnagdy A, Abouelkheir H, El-Khouly S, Tarshouby S. Impact of topical nonsteroidal anti-inflammatory drugs in prevention of macular edema following cataract surgery in diabetic patients. *International Journal of Ophthalmology*. 2018;**11**(4):616-622. DOI: 10.18240/ijo.2018.04.133738
- [29] Gaynes B, Fiscella R. Topical nonsteroidal anti-inflammatory drugs for ophthalmic use. *Drug Safety*. 2002;**25**:233-250
- [30] Hernández-Díaz S, Rodríguez LAG. Association between nonsteroidal anti-

inflammatory drugs and upper gastrointestinal tract bleeding/perforation: An overview of epidemiologic studies published in the 1990s. *Archives of Internal Medicine*. 2000;**160**:2093-2099. DOI: 10.1001/archinte.160.14.2093

[31] Canto MG, Andreu I, Fernandez J, Blanca M. Selective immediate hypersensitivity reactions to NSAIDs. *Current Opinion in Allergy and Clinical Immunology*. 2009;**9**:293-297. DOI: 10.1097/ACI.0b013e32832db943

[32] Sun WH, Tsuji S, Tsujii M, Gunawan E, Sawaoka H, Kawai N, et al. Cyclo-oxygenase-2 inhibitors suppress epithelial cell kinetics and delay gastric wound healing in rats. *Journal of Gastroenterology and Hepatology*. 2000;**15**:752-761. DOI: 10.1046/j.1440-1746.2000.02242.x

[33] Sekhar C, Pathapati R, Varalakshmi U, Harshita S, Patra R, Divyalasya T. Head-to-head comparison of tolerability and acceptability of single dose of four topical NSAIDs in patients undergoing cataract surgery. *Evidence-based Healthcare*. 2015;**2**:4568-4573. DOI: 10.18410/jebmh/2015/643

[34] Endo N, Kato S, Haruyama K, Shoji M, Kitano S. Efficacy of bromfenac sodium ophthalmic solution in preventing cystoid macular oedema after cataract surgery in patients with diabetes. *Acta Ophthalmologica*. 2010;**88**(8):896-900. DOI: 10.1111/j.1755-3768.2009.01582.x

[35] Singh R, Alpern L, Jaffe G, et al. Evaluation of nepafenac in prevention of macular edema following cataract surgery in patients with diabetic retinopathy. *Clinical Ophthalmology*. 2012;**6**(1):1259-1269. DOI: 10.2147/OPHTH.S31902. PMCID: PMC3422154

[36] Almeida D, Johnson D, Hollands H, et al. Effect of prophylactic nonsteroidal antiinflammatory drugs on cystoid

macular edema assessed using optical coherence tomography quantification of total macular volume after cataract surgery. *Journal of Cataract and Refractive Surgery*. 2008;**34**(1):64-69. DOI: 10.1016/j.jcrs.2007.08.034

[37] Almeida D, Khan Z, Xing L, et al. Prophylactic nepafenac and ketorolac versus placebo in preventing postoperative macular edema after uneventful phacoemulsification. *Journal of Cataract and Refractive Surgery*. 2012;**38**(9):1537-1543. DOI: 10.1016/j.jcrs.2012.04.034

[38] Cable M. Comparison of bromfenac 0.09% QD to nepafenac 0.1% TID after cataract surgery: Pilot evaluation of visual acuity, macular volume, and retinal thickness at a single site. *Clinical Ophthalmology*. 2012;**6**(1):997-1004. DOI: 10.2147/OPHTH.S32179. PMCID: PMC3399390

[39] Cervantes-Coste G, Sanchez-Castro YG, Orozco-Carroll M, Mendoza-Schuster E, Velasco-Barona C. Inhibition of surgically induced miosis and prevention of postoperative macular edema with nepafenac. *Clinical Ophthalmology*. 2009;**3**(1):219-226

[40] Rossetti L, Bujtar E, Castoldi D, Torrazza C, Orzalesi N. Effectiveness of diclofenac eyedrops in reducing inflammation and the incidence of cystoid macular edema after cataract surgery. *Journal of Cataract and Refractive Surgery*. 1996;**22**:794-799. DOI: 10.1016/S0886-3350(96)80164-7

[41] Miyake K, Masuda K, Shirato S, et al. Comparison of diclofenac and fluorometholone in preventing cystoid macular edema after small incision cataract surgery: A multicentered prospective trial. *Japanese Journal of Ophthalmology*. 2000;**44**(1):58-67. DOI: 10.1016/S0021-5155(99)00176-8

[42] Miyake K, Nishimura K, Harino S, et al. The effect of topical diclofenac on

choroidal blood flow in early postoperative pseudophakias with regard to cystoid macular edema formation. *Investigative Ophthalmology & Visual Science*. 2007;**48**(12): 5647-5652. DOI: 10.1167/iovs.07-0262

[43] Miyake K, Ota I, Miyake G, Numaga J. Nepafenac 0.1% versus fluorometholone 0.1% for preventing cystoid macular edema after cataract surgery. *Journal of Cataract and Refractive Surgery*. 2011;**37**(9): 1581-1588. DOI: 10.1167/iovs.07-0262

[44] Nishino M, Eguchi H, Iwata A, Shiota H, Tanaka M, Tanaka T. Are topical steroids essential after an uneventful cataract surgery? The *Journal of Medical Investigation*. 2009; **56**(1-2):11-15. DOI: 10.2152/jmi.56.11

[45] Weber M, Kodjikian L, Kruse F, Zagorski Z, Allaire C. Efficacy and safety of indomethacin 0.1% eye drops compared with ketorolac 0.5% eye drops in management of ocular inflammation after cataract surgery. *Acta Ophthalmologica*. 2013;**91**(1):e15-e21. DOI: 10.1111/j.1755-3768.2012.02520.x

[46] Wittpenn J, Silverstein S, Heier J, Kenyon K, Hunkeler J, Randomized EMA. Masked comparison of topical ketorolac 0.4% plus steroid vs steroid alone in low-risk cataract surgery patients. *American Journal of Ophthalmology*. 2008;**146**(4): 554-560. DOI: 10.1016/j.ajo.2008.04.036. e551

[47] Donnenfeld E, Perry H, Wittpenn J, Solomon R, Nattis A, Chou T. Preoperative ketorolac tromethamine 0.4% in phacoemulsification outcomes: Pharmacokinetic-response curve. *Journal of Cataract and Refractive Surgery*. 2006;**32**(9):1474-1482. DOI: 10.1016/j.jcrs.2006.04.009

[48] Mathys K, Cohen K. Impact of nepafenac 0.1% on macular thickness

and postoperative visual acuity after cataract surgery in patients at low risk for cystoid macular oedema. *Eye* (London, England). 2010;**24**(1):90-96

[49] Miyake K, Ota I, Maekubo K, Ichihashi S, Miyake S. Latanoprost accelerates disruption of the blood-aqueous barrier and the incidence of angiographic cystoid macular edema in early postoperative pseudophakias. *Archives of Ophthalmology*. 1999; **117**(1):34-40. DOI: 10.1001/archophth.117.1.34

[50] Miyake K, Ota I, Ibaraki N, et al. Enhanced disruption of the blood-aqueous barrier and the incidence of angiographic cystoid macular edema by topical timolol and its preservative in early postoperative pseudophakia. *Archives of Ophthalmology*. 2001; **119**(3):387-394. DOI: :10.1001/archophth.119.3.387

[51] Miyanaga M, Miyai T, Nejima R, Maruyama Y, Miyata K, Kato S. Effect of bromfenac ophthalmic solution on ocular inflammation following cataract surgery. *Acta Ophthalmologica*. 2009; **87**(3):300-305. DOI: 10.1111/j.1755-3768.2008.01433.x

[52] Moschos M, Chatziralli I, Pantazis P, Rouvas A, Sergentanis T. Is topical diclofenac essential before and after uneventful phacoemulsification cataract surgery? *Journal of Ocular Pharmacology and Therapeutics*. 2012; **28**(4):335-339.29. DOI: 10.1089/jop.2011.0256

[53] Ticly F, Lira R, Zanetti F, Machado M, Rodrigues G, Arieta C. Prophylactic use of ketorolac tromethamine in cataract surgery: A randomized trial. *Journal of Ocular Pharmacology and Therapeutics*. 2014;**30**(6):495-501. DOI: 10.1089/jop.2013.0214

[54] Wang Q, Yao K, Xu W, et al. Bromfenac sodium 0.1%, fluorometholone 0.1% and

dexamethasone 0.1% for control of ocular inflammation and prevention of cystoid macular edema after phacoemulsification. *Ophthalmologica*. 2013;**229**(4):187-194. DOI: 10.1159/000346847

of nepafenac 0.3% for the prevention of macular edema after phacoemulsification. *Journal of Cataract & Refractive Surgery*. 2018;**44**(4):440-446. DOI: 10.1016/j.jcrs.2018.01.026

[55] Yavas G, Ozturk F, Kusbeci T. Preoperative topical indomethacin to prevent pseudophakic cystoid macular edema. *Journal of Cataract and Refractive Surgery*. 2007;**33**(5):804-807. DOI: 10.1016/j.jcrs.2007.01.033

[56] Capote A, Soto M, Ruiz R, Peláez C, Vazquez G, OftaCosta G, et al. Comparative study of the efficacy and safety of bromfenac, nepafenac and diclofenac sodium for the prevention of cystoid macular edema after phacoemulsification. *International Journal of Ophthalmology*. 2018;**11**(7):1210. DOI: 10.18240/ijo.2018.07.22

[57] McCafferty S, Harris A, Kew C, Kassam T, Lane L, Levine J, et al. Pseudophakic cystoid macular edema prevention and risk factors; prospective study with adjunctive once daily topical nepafenac 0.3% versus placebo. *BMC Ophthalmology*. 2017;**17**(1):16. DOI: 10.1186/s12886-017-0405-7

[58] Stock A, Galvan K, Godoy R, Bonamigo L. Comparison of macular thickness by optical coherence tomography measurements after uneventful phacoemulsification using ketorolac tromethamine, nepafenac, vs a control group, preoperatively and postoperatively. *Clinical Ophthalmology*. 2018;**12**:607. DOI: 10.2147/OPTH.S157738

[59] Milla E, Stirbu O, Franco J, Hernández G, Rios J, Duch S. Effect of nepafenac on the foveal profile of glaucomatous patients undergoing phacoemulsification. *International Ophthalmology*. 2017;**37**(5):1147-1153

[60] Tzelikis P, Morato C, Neves N, Hida W, Alves M. Intraindividual comparison