

# We are IntechOpen, the world's leading publisher of Open Access books Built by scientists, for scientists

6,900

Open access books available

185,000

International authors and editors

200M

Downloads

Our authors are among the

154

Countries delivered to

TOP 1%

most cited scientists

12.2%

Contributors from top 500 universities



WEB OF SCIENCE™

Selection of our books indexed in the Book Citation Index  
in Web of Science™ Core Collection (BKCI)

Interested in publishing with us?  
Contact [book.department@intechopen.com](mailto:book.department@intechopen.com)

Numbers displayed above are based on latest data collected.  
For more information visit [www.intechopen.com](http://www.intechopen.com)



---

## Flow Optimization, Management, and Prevention of LV Distention during VA-ECMO

---

Cristiano Amarelli, Francesco Musumeci,  
Antonio Loforte, Andrea Montalto,  
Sveva Di Franco and Jaime Hernandez-Montfort

Additional information is available at the end of the chapter

<http://dx.doi.org/10.5772/intechopen.80265>

---

### Abstract

Cardiogenic shock (CS) still carries an unacceptably high mortality (30–60%), despite several therapeutic approaches; the SHOCK II trial questioned the benefit of intra-aortic balloon pump (IABP), while IMPRESS and CULPRIT-SHOCK trials confirmed heterogeneity in disease spectrum and patient selection for acute myocardial infarction-related CS requiring acute mechanical circulatory support (AMCS). The heterogeneity of devices employed as AMCS, including temporary micro-axial flow pumps (Impella), percutaneous bypass (TandemHeart), and extracorporeal life support (VA-ECMO), contributed to the actual dramatic scenario, where CS is defined clinically rather than hemodynamically. To date, the role of VA-ECMO is emerging as rapid strategy to mitigate mortality rates of severe refractory states, despite the lack of data regarding the best practices of management and flows control. VA-ECMO's flow represents the “dose” of treatment and higher flows are less tolerated percutaneously requiring, to prevent deleterious pulmonary edema and ventricular distention, additional approaches such as pulmonary, left atrial, or left ventricular unloading. Any efforts have to be directed to (1) determine adequate management of patients on VA-ECMO, (2) define the safer duration of VA-ECMO support, and (3) establish algorithms and techniques to predict and obtain stable weaning from ECMO or ensure fast transition to durable VAD and/or heart transplant.

**Keywords:** ECMO, myocardial recovery, cardiogenic shock, ventricular unloading, VA-ECMO, Impella, ECLS, ECPELLA, ECMO dose retrieval

---

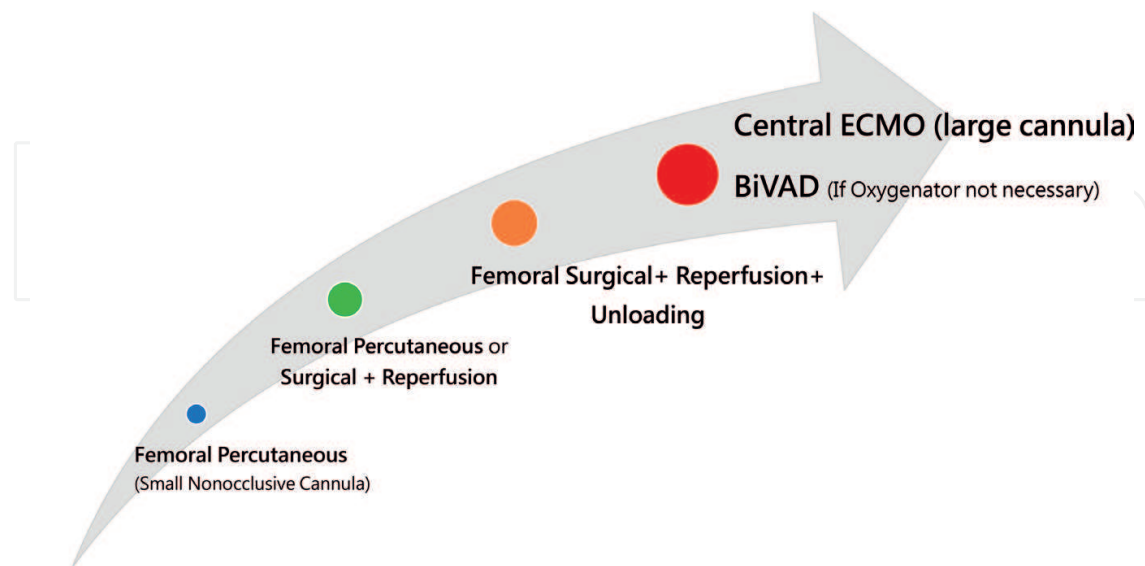
## 1. Introduction

Cardiogenic shock (CS) continues to exhibit a high mortality rate (30–60%), despite several therapeutic approaches; recent data derived from the SHOCK II trial [1] questioned the benefit of intra-aortic balloon pump (IABP) in the treatment of the CS. Subsequently, IMPRESS [2] and CULPRIT-SHOCK [3] confirmed heterogeneity in disease spectrum (using a non-hemodynamic clinical definition for CS) and patient selection for AMI-related cardiogenic shock requiring acute mechanical circulatory support (AMCS) with alternative strategies to counterpulsation such as temporary micro-axial flow pumps (Impella), percutaneous left atrium-aortic bypass (TandemHeart) and venoarterial extracorporeal membrane support (VA-ECMO) [4]. In this dramatic clinical scenario, VA-ECMO is emerging as an alternative strategy to mitigate such elevated mortality. Although a beneficial effect on peripheral perfusion/circulation has been demonstrated with VA-ECMO implantation in patients affected by CS, there is a potential for increasing loading conditions into the left ventricle potentially compromising transition to myocardial recovery. Contemporary VA-ECMO systems are now widely used with a broad spectrum of configurations. Due to case mix and implantation timing differences (from report to report and depending on the institutions), outcomes have wide variability and are limited by its retrospective nature and lack of granular profiling prior and after support. The timing of the implantation potentially accounts for further differences in outcomes between different institutions. Central cannulation, when feasible, warrants the best peripheral flows, the best cardiac perfusion, and unloads adequately both ventricles but is still complicated by a high incidence of bleeding and need of multiple re-sternotomy. Moreover, central VA-ECMO is not always bedside available. Despite the growing experience in the use of VA-ECMO, the target flow has still not been identified, and in literature, there is a lack of data regarding best practices with management. Indeed, VA-ECMO flow represents the “dose” of the treatment: the lower dose corresponding to lower flow may be readily achieved through percutaneous cannulation, while the higher the dose or higher flow can be obtained through larger cannulas (**Figure 1**) and may require modifying VA-ECMO configuration during support aiming to prevent the common complications due to overflow. However, a higher flow warrants optimal peripheral organ perfusion, lower venous pressure, and higher mean pressure. The decongestion of the venous side appears a critical factor in recovery end-organ function and is pivotal both for renal and liver function recovery. The building of the circuit should always aim at the lowest venous pressure to restore a normal perfusion pressure despite low continuous flow pressure. On the other hand, high flow not only induces highly turbulent flows, increasing shear stress, and damaging platelets but also increase the quota of shunt and the left ventricular afterload. The latter mechanism may explain the increased risk of pulmonary edema and moreover the reduced hazard of myocardial recovery [5].

Preventing pulmonary edema is one of the principal targets to reduce the biologic impact of VA-ECMO and possibly to maintain the patients extubated and even ambulatory. A large number of possible approaches have been described to aim through a small-incision pulmonary, left atrial, or left ventricular unloading, thus preventing pulmonary edema. The implantation of a double ECLS (extracorporeal life support) circuit (surgical with CentriMag or percutaneous with TandemHeart) thus aiming to reduce all the possible complications due to the need of an oxygenator [6–8] represents one of the possible solutions.

## Preventing Ventricular Distention during ECMO

ECMO configuration based on dose of treatment (needed flow)



**Figure 1.** ECMO configuration tailored on needed flow. Representation of the existing relation from type of cannula, site and technique of insertion and flow rates. The figure defines that according to the needed flow the operator may utilize different approaches starting from lower flows provided with a femoral percutaneous small nonocclusive cannula (blue dot) reaching the higher flows with a large cannula in central ECMO or BiVAD.

Today, the first indication of treatment is myocardial recovery as clearly shown both from data coming from leading centers in the VA-ECMO implantation and ELSO registries [9, 10]. This target is more frequently achieved in myocarditis or potentially reversible diseases [11] and stresses the importance of etiological diagnosis at the moment of implantation to define the strategy of implantation. To warrant optimal outcomes, many efforts have to be directed to:

1. Determine adequate management of patients on VA-ECMO.
2. Minimize the time the patient is on VA-ECMO.
3. Establish algorithms and techniques to predict and obtain stable weaning from VA-ECMO.

When pathology is reversible, probably, the quality of myocardial unloading can potentially make an essential difference in the platform for transition (recovery vs. VAD and/or heart transplant). Recent data support the need to reason about a transition to a midterm platform as soon as a stable organ perfusion and function have been warranted, possibly between day 7 [12] and before day 14 [13]. Data emerging on the beneficial effect of early myocardial unloading on the acutely failing hearts with temporary micro-axial flow pumps continue to arise [14–16]; however, there is no clear consensus or longitudinal hemodynamic data to support a specific combination or transition strategy for severe refractory, hemometabolic, and/or biventricular cardiogenic shock, and although it appears that the most commonly described combination is VA-ECMO with LV unloading via an Impella device, the emerging alternative

of high-profile biventricular support with combination of Impella 5.0 and RP or percutaneous biatrial VA-ECMO is also possible.

This chapter aims to evaluate best practices and strategies that can be implemented to prevent and reduce ventricular distention and to increase the likelihood of recovery and survival during and after VA-ECMO support.

## 2. Incidence of complications and ECMO configuration

VA-ECMO currently represents the most effective minimally invasive circulatory support system. VA-ECMO has evolved and can now be placed quickly at the bedside, in the medical unit, or in the cardiac intensive care unit. It provides oxygenation, it is the best option in the setting of associated lung injury, it can be placed peripherally (without thoracotomy), and it is the only percutaneous option for biventricular support. It may provide sufficient support to enable adequate tissue perfusion even in cardiac arrest, and it is a suitable device for acute resuscitation of a patient in shock, even if mortality for cardiogenic shock did not significantly change and is still ranging between 50 and 70% [17].

Moreover, many publications have disclosed a dramatic burden of complications using percutaneous VA-ECMO leading to higher costs and ethical discussions on the right clinical settings for its clinical adoption [9, 18–20].

Looking critically at the landscape of effects and complications of different configurations of mechanical circulatory support and specifically of VA-ECMO emerges the importance to select the right device and the right VA-ECMO's configuration to warrant the best outcome. The crucial factor in selecting the device and the VA-ECMO's configuration is the amount of flow needed to restore organ function. Venous oxygen saturation has been indicated by many authors as a good goal to direct VA-ECMO perfusion [21].

Percutaneous VA-ECMO appears fitted to restore peripheral flows when the patient experiences a moderate reduction of cardiac output. When the patient needs higher flows, the risk of pulmonary edema and left ventricular distention increases [22], and additional cares may be necessary to unload the left ventricle and eventually to restore pulmonary function after pulmonary edema [23–25].

Although a beneficial effect on peripheral perfusion/circulation has been demonstrated with VA-ECMO implantation in patients affected by cardiogenic shock, there is a potential for increasing loading conditions into the left ventricle potentially compromising transition to myocardial recovery. Contemporary VA-ECMO systems are increasingly being used with a wide spectrum of configurations.

## 3. Destination of VA-ECMO

Contemporary registries and center reports support the ultimate finality of therapy for acute decompensated heart failure being myocardial recovery [26]. When pathology is reversible,



the time to recovery on the basis of the etiopathology of the disease plays a pivotal role together with the modality of support aiming to help myocardial healing [27].

Therefore, if during the acute phase of VA-ECMO implantation the “dose” is a critical factor to recovery the end-organ function, the complementary goal is to reduce the biologic impact of support and favor myocardial healing. Many data are emerging in support of a role of myocardial unloading to reach this aim [28]. Data coming out from experimental data on animal and computer simulations seem to support the hypothesis that ventricular unloading is more effective than atrial unloading. Data emerging on the beneficial effect of early myocardial unloading on the acutely failing hearts with temporary micro-axial flow pumps continue to arise; however, there is no clear consensus or data to support a specific combination or transition strategy for severe refractory, hemometabolic, and/or biventricular cardiogenic shock.

VA-ECMO has multiple effects on the left ventricular myocardium:

- The decrease of venous return and the volume work may reduce the wall tension of the heart and subsequently the LVEDV and LVEDP.
- The increase of arterial pressure (MAP) and reduction of venous pressure improve the pressure gradient and then the myocardial perfusion.
- The increase of blood pressure increases afterload and the pressure work of myocardium affecting the Frank-Starling law.

The overall effect of the decrease in volume work and the increase in pressure work depends on the “dose” of VA-ECMO as well as myocardial function and its response to these phenomena. Peripheral ECMO with a high flow may further increase afterload due to the reversal of flow in the most of the aorta [29, 30].

The real question remains if myocardial unloading is always beneficial or potentially detrimental by increasing the complexity of management and when is indeed indicated the transition from ECMO support to ECMO + LV unloading.

Although it appears that the most commonly described combination is VA-ECMO with LV unloading via an Impella device, the emerging alternative of high-profile biventricular support with the combination of Impella 5.0 and RP or percutaneous biatrial ECMO is also possible valuable solutions [31].

Many contradictory data are emerging regarding the effect of VA-ECMO on LV contractile function. LV afterload before ECMO is related to systemic arterial pressure, and the Starling curve generated before initiation of ECMO flow predicts the filling pressure associated with any target SV at that systemic pressure. The addition of ECMO flow or alterations solely in SVR does not alter the relationship between filling pressure and native LV SV, and then the abrupt increase of afterload due to the ECMO flow may be useful to predict ventricular distension during ECMO support [32].

In the presence of severe LV dysfunction, the left ventricle is unable to eject a sufficient volume of blood against the increased afterload caused by the ECMO flow, resulting in impairment of

various parameters of LV performance [33–35] and, in extreme situations, the aortic valve can remain closed even during systole.

When VA-ECMO is established due to ongoing cardiogenic shock, it is possible to measure PCWP and LV SV directly. The additional systemic flow conferred by ECMO may be offset by volume reduction of venous return that may cause a reduction in PCWP. When VA-ECMO is established for cardiogenic shock due to right ventricle failure, PCWP is typically low, and the LV is relatively afterload insensitive.

The presence of a pulse pressure depends (without IABP) on the stroke volume of the left ventricle. The absence of arterial pulsatility may prove an appropriate level of support (60–80% of the predicted cardiac output allowing for the remaining 20–40% to pass through the lungs and heart). However, on the other end, it indicates also the inability of the myocardium to overcome the superimposed afterload worsened by a decreased preload and volume work.

When mitral regurgitation is absent, and a significant amount of blood returns in the LV, blood may stagnate within the left ventricle and at the aortic root. The persistent closure of the aortic valve may increase the risk of thrombus formation and subsequent embolic. Besides, the reduction of the stroke volume and of the transmitral flow due to VA-ECMO, the increase of the PCWP, the persistent venous return from thebesian and bronchial veins lead to overdistension of the LV. The distention of the LV measured in terms of LVEDV leads to an LVEDP; impairing coronary perfusion pressure may further worsen the ischemic subendocardial injury to the myocardium. In some instance, left ventricular distension may cause tethering of a previously competent mitral valve causing functional mitral insufficiency due to annular dilation. In this scenario, a pulmonary artery catheter may demonstrate an increase in the telediastolic pulmonary capillary occlusion pressure. The presence of severe mitral regurgitation may worsen left atrial hypertension congesting the pulmonary bed leading to pulmonary edema and even hemorrhage. Functional assessment of the heart in a partially bypassed state can be challenging, but transesophageal echocardiography may aid in confirming aortic valve opening as well as by providing an assessment of the variations of the left ventricular end-diastolic dimension after VA-ECMO institution. The serial evaluation of LVED and of the PCWP should be routinely used during VA-ECMO to give a prompt indication to LV unloading when the simple physiopathologic and/or eventual simulation models do not already suggest the need of an unloading. Recently, the option to first unload and then evaluate the need of VA-ECMO has been prompted. The increase in systemic pressure, in this scenario, is slight, and a modest increase in PCWP would accompany the increase in LV afterload without a significant change in LV SV.

When VA-ECMO is established for cardiogenic shock due to acute LV failure, the magnitude in afterload change depends on the increase of systemic pressure. In this scenario, if PCWP is already high and without a substantial improvement in LV contractility, a dramatic rise in PCWP with LV distension is expected. LV and pulmonary venous distension lead shortly to a massive acute pulmonary edema and blood stasis in the left heart with a serious risk of thrombus formation. Prompt diagnosis and a high suspicion have to be kept in this situation as it is imperative to both unload the central circulation while maintaining a minimal LV SV. The effectiveness of oxygenation and drainage is a vital factor for the diagnosis as if the patient is well drained and perfused; the diagnosis of pulmonary edema may be masked by ECMO. VA-ECMO differs from the standard cardiopulmonary bypass circuit due to the absence of a venous reservoir halting

the possibility to control the amount of venous return to the left heart during VA-ECMO; the blood volume bypassing the venous cannula due to incomplete drainage or coursing through the bronchial circulation returns to the left heart; this represents the additional LV output to VA-ECMO flow in the systemic circulation. While this additional flow may be altered by changes in circulating blood volume (e.g., diuresis), the LV will require a preset inflow pressure warranting to deliver a target SV (to prevent blood stasis) depending on the Starling relations. The risk of ventricular distention after initiation of VA-ECMO is related to the preinitiation EF in a setting of high afterload sensitivity as contractile strength is reduced. Even a moderate reduction in pre-ECMO EF (less than 50%) may predict high PCWP after VA-ECMO institution, due to the abrupt increase of systemic pressure and afterload when peripheral cannulation is accomplished.

Placed in the setting of hypotension and cardiogenic shock, the increase in MAP after initiation of VA-ECMO is associated with a significant increase in PCWP and decrease in LV SV, counteracting the emptying of the ventricle and its work.

Careful management of patients on VA-ECMO should include monitoring of intravascular volume status, MAP, and PCWP.

Volume status should be managed in a way to warrant a minimally acceptable LV SV, while the MAP should be kept down acting on VA-ECMO flow rates and by pharmacologic manipulation of SVR. VA-ECMO flows can be reduced in an attempt to reduce afterload. However, this maneuver may not be possible if it compromises oxygen delivery and end-organ perfusion due to the inability of the heart to produce a compensatory increase in native cardiac output. The value of PCWP depends on LV contractility and MAP but not on the method by which MAP is controlled while maintaining a minimal LV SV.

LV overload and distension except for pulmonary edema may induce increased wall stress and myocardial oxygen consumption [36]. During acute decompensation of chronic heart failure leading to cardiogenic shock, the left ventricle is compliant, and the mitral valve is frequently incompetent as a result of chronic annular dilation and mitral valve leaflet tethering. Mitral regurgitation in this setting decompresses the left ventricle to some extent but may result in elevation of left atrial pressure and pulmonary edema [21, 37]. In contrast, acute myocarditis or myocardial infarction is associated with a noncompliant left ventricle and competent mitral valve. LV distension in this setting will result in a significant rise in intraventricular pressure and wall tension, which could be detrimental to the damaged myocardium, and reduced coronary blood flow, causing subendocardial myocardial ischemia [38]. Aortic regurgitation should always be kept into account in ECMO patients due to its potentially detrimental effects [39].

Commonly, myocardial recovery on VA-ECMO support is suggested by an increase in pulse pressure and by improved contractility on echocardiography, but the appearance of pulsatility on the arterial waveform may also reflect a worsening volume overload. Tracking PCWP or repeat echocardiographic assessment may help to ascertain to manage the patient at the best.

The ultimate test of myocardial recovery, however, is accomplished by assessing hemodynamic stability on minimal or no support. Under adequate heparinization, the “dose” of VA-ECMO can be decreased to achieve ~1 L/min of flow or the cannulas can be briefly clamped to ascertain the ability of the native ventricle to handle the full cardiac output. When the myocardium has recovered, during the weaning phases or temporary withdrawal,



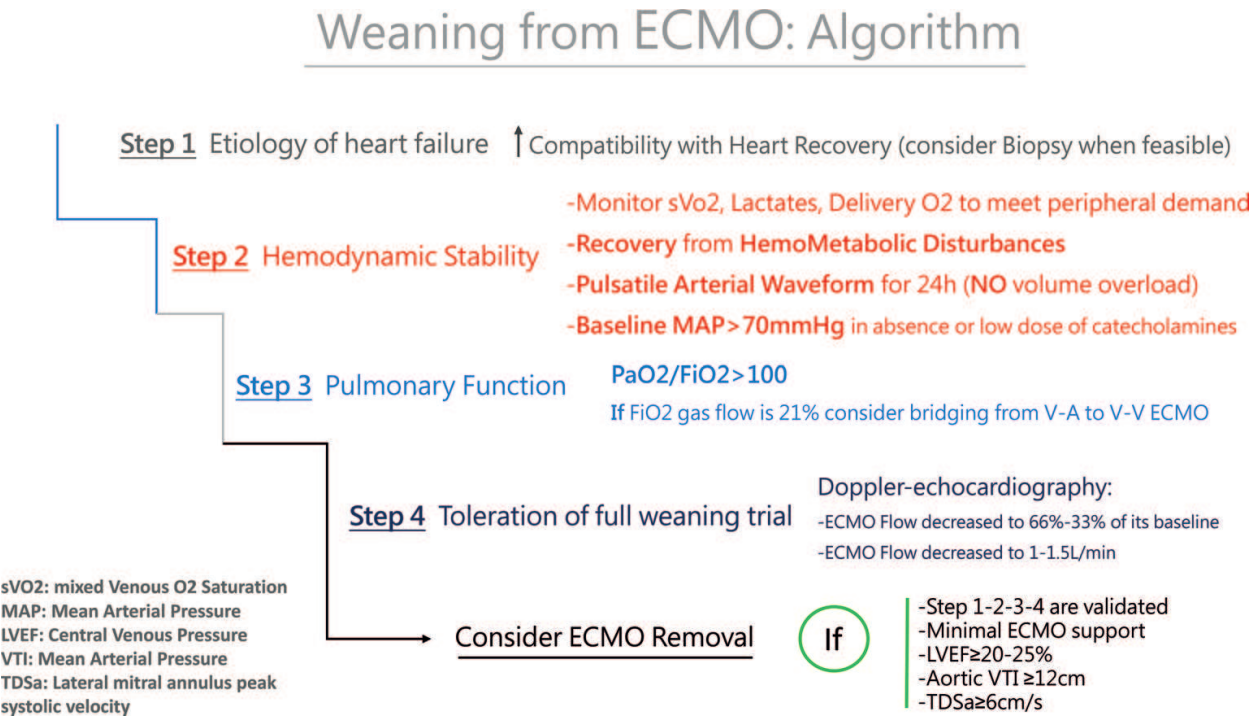


Figure 2. Flow-chart for ECMO management.

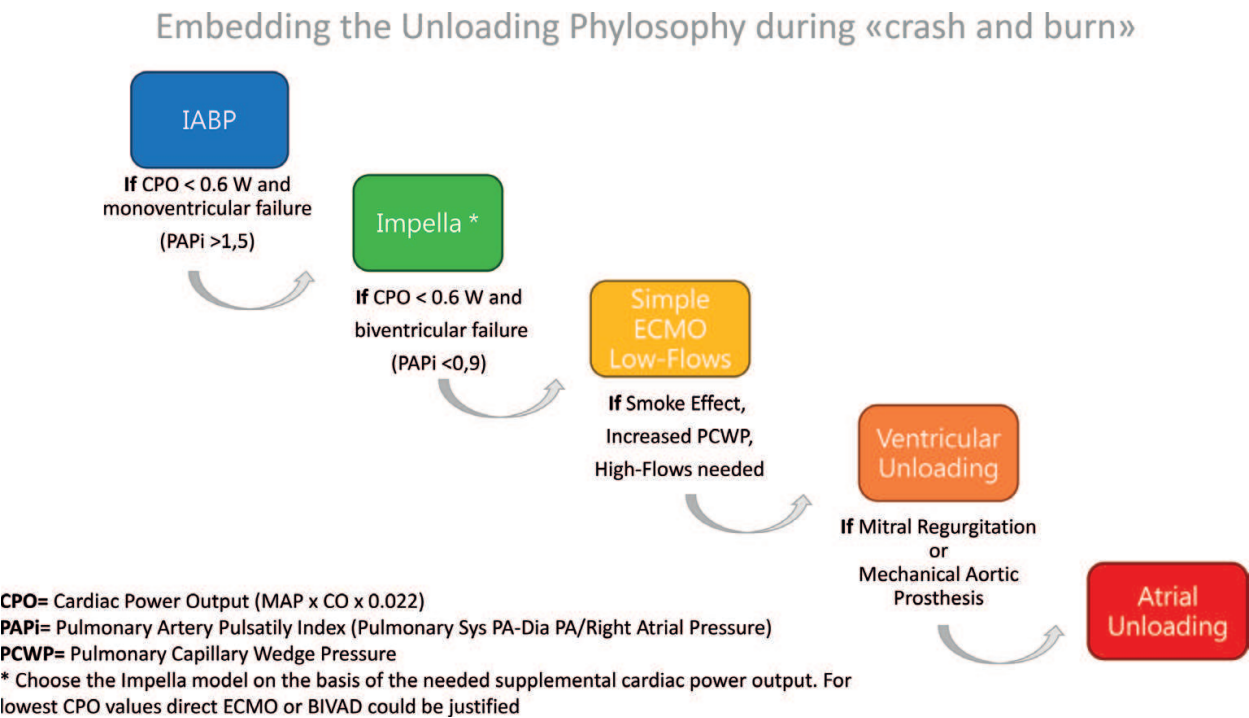


Figure 3. Flow-chart describing the suggested therapeutical strategy according to patient's clinical conditions and needs.

acceptable contractility on echocardiography and stable hemodynamics (MAP, CVP and heart rate) has to be checked. We provide a schematic view of the Flow-chart for ECMO management from step 1 to step 4 and complete weaning (Figure 2). Hypotension, a rising

CVP, atrial fibrillation, and a poorly contractile myocardium on echocardiography suggest weak recovery and a high risk of need of support [40, 41]. Recently, the group of Esposito and Kapur [42] has suggested a facilitating effect in withdrawal when the patients have an Impella in place to sustain left ventricular function. This knowledge, merged with the knowledge of the need of a short period of ECMO support and to the capability of Impella to interrupt the vicious cycle leading the patient to biventricular failure, may suggest the adoption of Impella when cardiac power output falls under 0.6 and IABP is judged not enough to maintain adequate end-organ perfusion [43], in this case ECMO need has to be evaluated. In **Figure 3**, it has been represented a scheme of the associations between patients' clinical conditions and the suggested therapeutical strategy to face patients' hemodynamic needs.

#### 4. IABP during ECMO

Intra-aortic balloon pump (IABP) has long been clinically applied to augment pulsatility, decrease afterload, and improve blood flow in native coronary arteries and bypass grafts [44, 45].

The inflations and deflations of the 30–50 ml balloon delivered by the IABP device are synchronized with cardiac cycle: the deflation just before systolic ejection aims to decrease afterload and improve LV ejection, while the inflation during diastole warrants increased diastolic perfusion aiming at improve coronary, cerebral, and visceral blood flow.

Despite the controversial data from the Intra-Aortic Balloon Pump in cardiogenic SHOCK (IABP-SHOCK) II trial [1], IABP currently remains one of the most commonly used mechanical circulatory support devices in the treatment of acute heart failure. When administered promptly, it can play a critical role in the rescue of patients with acute myocardial damage, reversing the ongoing vicious cycle leading to death. It has been shown in animal models that IABP may improve several parameters of LV performance during VA-ECMO support [46]. Currently, several centers use IABP during VA-ECMO therapy to reduce LV afterload and warrant pulsatility in the end-organ capillary bed [47]. In a group of 219 patients treated with VA-ECMO after cardiac surgery, Doll et al. [18] found that the use of IABP during ECMO support was associated with a significantly higher survival rate. Ma et al. [48] reported 54 adult patients with acute heart failure who received combined ECMO and IABP support, all of whom showed improvements in terms of overall circulation. Thirty-four of the patients were successfully weaned from mechanical circulatory support, and 21 (39%) survived to hospital discharge. Petroni et al. [49] showed that adding an IABP to peripheral VA-ECMO was associated with improved LV function, and discontinuation of intra-aortic balloon pumping was associated with higher pulmonary artery wedge pressure, increased LV end-, and end-diastolic diameters, while decreasing pulse pressure ( $15 \pm 13$  versus  $29 \pm 22$  mmHg;  $P = 0.02$ ) [49]. Park et al. [50] did not find any mortality or morbidity benefit with IABP in the group of 96 VA-ECMO-treated patients with cardiogenic shock due to acute myocardial infarction. Recent data coming out from the Shock trial suggest that cardiac power output ( $CPO = \text{cardiac output} \times \text{MAP} \times 0.022$ ) may be the best predictor of the effectiveness of IABP during impending cardiogenic shock [51]. Impella or VA-ECMO is needed when CPO is very low or upgrading of the MCS is necessary. Eventually the upgrade to ECMO or ECPella

(VA-ECMO + IMPELLA) may portend both optimal perfusion and ventricular unloading aiming to myocardial recovery. Etiologic definition and eventual correction of the cause should be mandatory to increase the chance of recovery.

A marked increase in systemic blood pressure caused by VA-ECMO and retrograde aortic ECMO flow may increase cardiac afterload, together with severe systolic dysfunction, resulting in LV overload with a subsequent increase in left atrial pressure, severe pulmonary edema, myocardial ischemia, elevated pulmonary pressures, blood stasis, and potential thrombus formation, jeopardizing ventricular recovery.

Echocardiographic monitoring should be strictly recommended to detect a fluid overload early, and a Swan-Ganz catheter should be inserted to measure the pulmonary capillary wedge pressure to detect high left ventricular filling pressures as an indicator for left ventricular distension. Ventilation with low tidal volumes and positive end-expiratory pressure (PEEP) has been suggested to keep the lung open. A higher PEEP is advisable in patients with ongoing pulmonary edema. Early extubation is feasible and desired when the patient has a low risk of pulmonary edema because optimal unloading.

To date, there are several possibilities to decrease the likelihood of left ventricular distension on ECMO, but the cohort of patients who benefit from left ventricular venting is unclear.

Decreasing afterload leads to a decrease in workload and  $O_2$  consumption. In case of an extremely poor left ventricular function, it is advisable to administer inotropes with a sufficient mean arterial pressure of 50–60 mmHg. Physiologic lactate levels, normal pH levels, and regular central venous saturations as a guide and flow rates of 2.5–4 L/min are probably sufficient in most cases. Even if sometimes lower pump flow rates also reduce the perfusion-related afterload [21].

Intra-aortic balloon pumping (IABP) concomitant to retrograde aortal perfusion is seen controversial as the inflated balloon in the descending aorta might hinder proper perfusion. IABP counterpulsation is a device that inflates and deflates a 30–50 cm balloon in the descending aorta. The balloon inflations and deflations are synchronized with cardiac cycle, and, therefore, deflation just before systolic ejection may decrease afterload and improve LV ejection. Moreover, increased diastolic pressure on IABP could also improve coronary blood flow [52, 53].

Despite the general expectations that IABP is useful during VA-ECMO for a supposed “perfusion benefit” which indeed is overcome by ECMO blood flow, our belief is that the rationale of the combined use of VA-ECMO and IABP is to provide a pressure unloading to the left ventricle especially when a certain amount of residual SV is provided by the native circulation.

Although in a very unstable patient ECMO can stabilize end organs and restore their function, the lack of left ventricular unloading and reduced ventricular work threaten the myocardium worsening the already impaired myocardial performance superimposing an extremely high afterload further compromising wall tension and myocardial oxygen demand. Multiple studies have shown that coronary perfusion worsens, especially if the patient is cannulated peripherally. Because relative cerebral or coronary hypoxia occurs in many situations due to a “watershed” effect, it is imperative to check blood saturations at multiple sites to determine

if perfusion is adequate everywhere to avoid to misdiagnose the “Harlequin syndrome” due to inadequate mixing of the two parallel circulations (ECMO and native heart) [23, 54, 55].

As a matter of fact, IABP should be already in place at the time of VA-ECMO implantation, as stated by ELSO Guidelines 2017 [www.else.org]. For those patients who do not have one, it should be placed via the contralateral femoral artery, associating earlier the hemodynamic effects of IABP to those of VA-ECMO; from a mechanistic point of view IABP could neutralize some of the unwanted effects of VA-ECMO [56].

The role of IABP in patients suffering from cardiogenic shock should be highlighted as (I) it is rapidly deployable at any hospital and therefore reduces the duration of “uncontrolled shock”; (II) it allows, thereafter, safe transport to MCS units; (III) it does allow for exploiting the same vascular access for Impella implant; and (IV) it has a major role in weaning from VA-ECMO and therefore reduces the burden of the complications related to ECLS.

Despite the controversial data from the intra-aortic balloon pump in cardiogenic SHOCK (IABP-SHOCK) II trial, which could not demonstrate a survival benefit for the IABP application, IABP currently remains one of the most commonly used mechanical circulatory support devices in the treatment of acute heart failure. The bad news is that for none of the percutaneous devices, used in LV venting, a survival benefit has yet been documented in adequately sized randomized clinical trials (RCTs). A meta-analysis, by Cheng et al., including a total of 100 patients in three small RCTs with the TandemHeart and the Impella PL2.5 pump did not see a survival benefit in comparison to the IABP, despite better hemodynamic effects [57].

When administered in a timely manner, IABP can play a critical role in the rescue of patients with acute myocardial damage. It has been shown in animal models that insertion of IABP during VA-ECMO support may improve several parameters of LV performance and can reduce mean arterial pressure as well as oxygen saturation in the coronary sinus [24].

The combination of IABP and VA-ECMO can be found in the nationwide Japanese Diagnosis Procedure Combination national inpatient database; IABP combined with VA-ECMO was associated with reduced mortality and successful weaning from VA-ECMO. They also concluded, of course, that randomized controlled studies are required to confirm the mortality-reducing effect of the combination of IABP and VA-ECMO [57].

Despite the lack of clarity, in a systematic literature search, the use of concomitant IABP with ECMO is widespread. IABP was present in approximately 55% of all ECMO cases reviewed, stretching across all etiologies of cardiac failure beyond acute myocardial infarction (AMI).

The rationale for concomitant IABP use is primarily for LV venting [58]. The incremental benefit of IABP support for afterload reduction and increasing organ perfusion in the presence of ECMO support is relatively minimal. Regarding improved diastolic pressures and coronary flow, despite the previously held belief of an estimated 11% survival benefit from pooled analyses of retrospective studies of IABP use in AMI, it is now known from the prospective and randomized IABP-SHOCK II study that the use of IABP in this cohort had no survival benefit [59].



Early IABP, or, when CPO is very low and Impella offering the adequate flow, would significantly impact the management of cardiogenic shock as it would avoid the administration of “toxic doses” of inotropes, allowing for smoother transition to VA-ECMO and routine unloading of the LV [44–60].

Even though, the combined use of IABP and VA-ECMO or Impella and VA-ECMO is well described to improve the hemodynamic facilitating and supporting conditions for recovery or ventricular assist device implantation [61, 62].

Recently, a simulation published on the ASAIO Journal [63] has supported the relevance of optimal medical management, fluid removal while minimizing VA-ECMO flow, reducing blood pressure, and eventually adding inotropes to reduce PCWP and prevent pulmonary edema [64]. Recent clinical data support this notion for different clinical settings and do not advocate a routine combination of VA-ECMO and IABP. Clinical studies have shown a slight reduction in PCWP, LV dimensions, and pulmonary edema in-line with the computer simulation [65].

Patients showing PCWP above 25 mmHg or a virtually non-ejecting LV will require interventional or surgical adjunct measures, which theoretically reduce PCWP by more than 5 mmHg. It has to be kept in mind that sometimes when you think of adding an unloading is too late for the patient, a proactive management reasoning on the patient characteristics and hemodynamics is pivotal.

In a recent computer simulation, this combined approach showed only limited LV unloading, although pulsatility and increased stroke volume were noted. The CPO before VA-ECMO implantation and the native heart stroke volume after VA-ECMO implantation could be relevant determinants of the effectiveness of IABP also during VA-ECMO perfusion (**Figure 3**), while a low PAPI may push toward biventricular support with Impella or TandemHeart.

## 5. Differences between atrial and ventricular unloading

When echocardiographic monitoring discloses surrogates of low contractility, LV distention or high filling pressure (PCWP) of the left ventricle, inotropic support should be considered or up titrated to increase contractility of the myocardium, and volume load should be assessed and eventually treated. Other conditions to be considered as drivers for unloading need have been represented in (**Figure 4**).

There are different drivers for atrial or ventricular unloading (**Figure 5**).

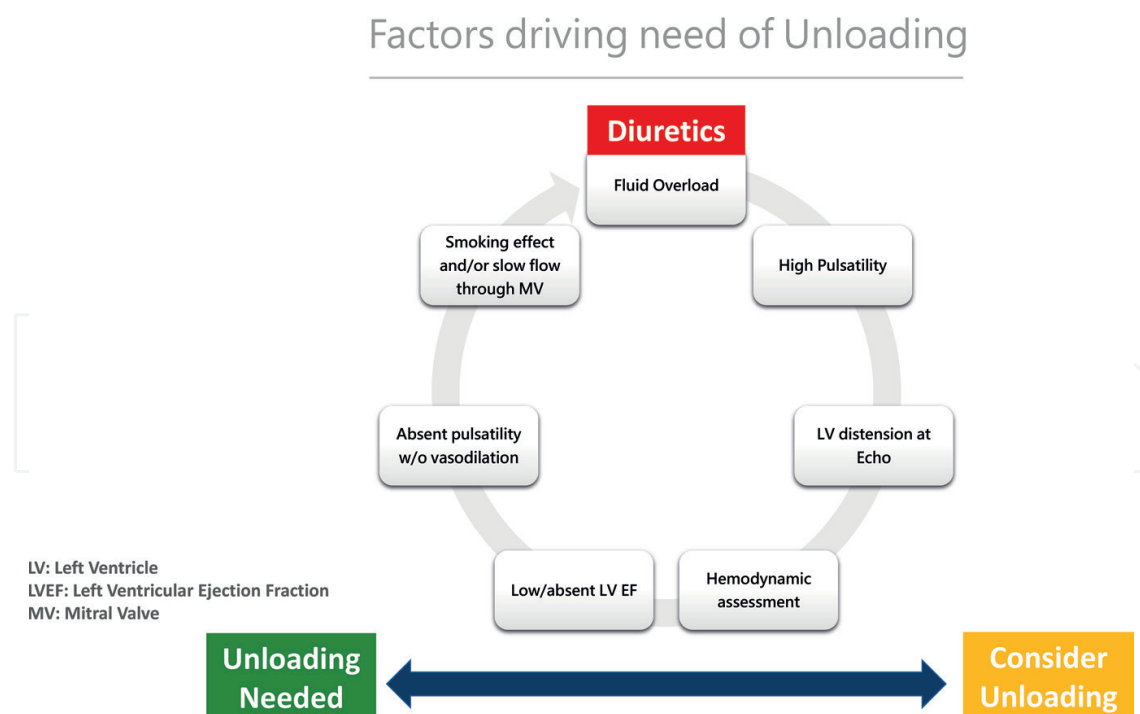
The kind of left side's chamber decompression is strictly related to the mechanism of pulmonary congestion and left ventricular distension. The variables that need to be kept in mind are:

- Adequacy of venous drainage: if the venous drainage may be considered poor, placement of pulmonary artery or left atrial drainage (comprised septostomy) may be sufficient.
- Mitral regurgitation: atrial drainage may be sufficient to unload the ventricle if a significant mitral regurgitation impedes the distension of the left ventricle.

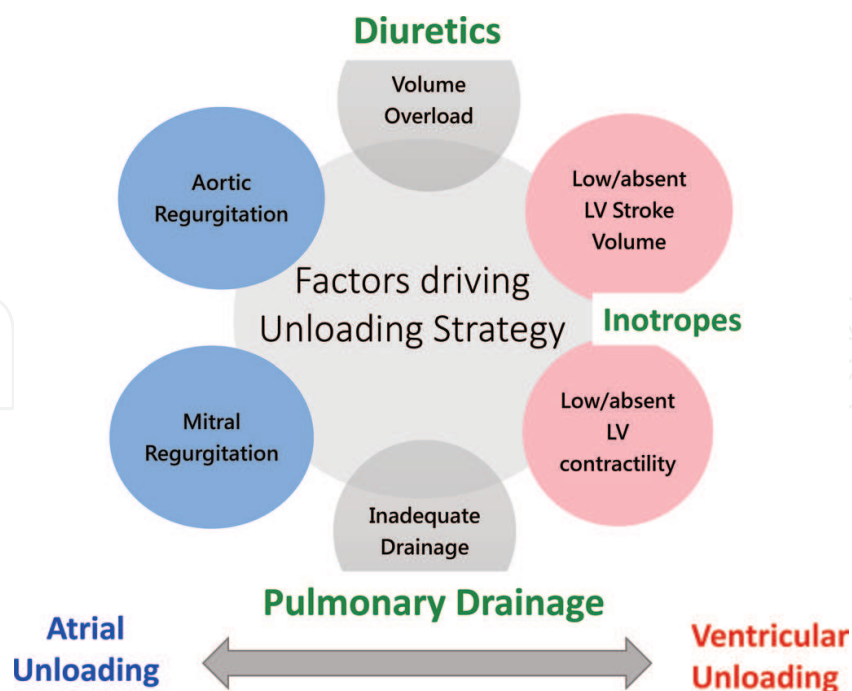


- Reversibility of left ventricle damage: ventricular unloading is pivotal to increase the chance of recovery.
- Aortic regurgitation: addressing aortic valve may be needed to avoid blood recirculation and stagnation.

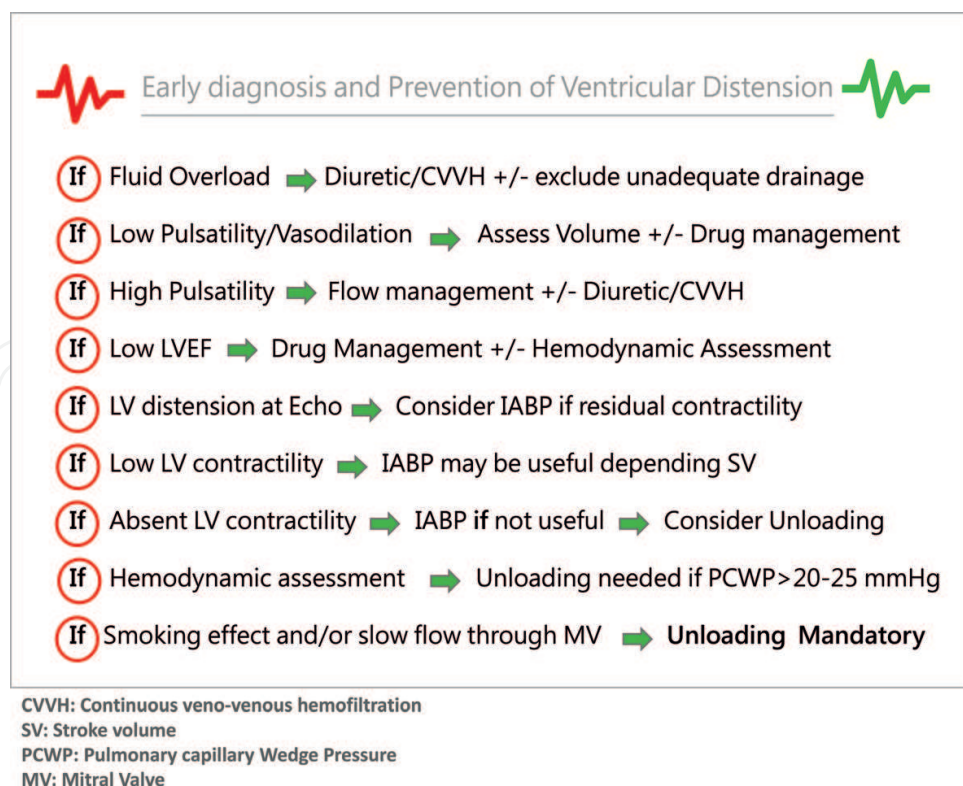
**Figure 6** shows the decisional process of management of conditions that may require unloading if not properly treated, the only condition where unloading seems to be mandatory is smoking effect or slow flow through the MV. **Figure 7** shows the possible surgical invasive, minimally invasive and percutaneous approaches aiming at ventricle unloading. When atrial unloading may be sufficient, a percutaneous left atrial septostomy may be accomplished, which allows blood from the LA to drain down its pressure gradient into the right atrium (RA) to then be drained via the venous cannula. This procedure is quite common in many hemodynamic lab especially used to treat pediatric patients. A cannula may also be placed into the LA through a transseptal puncture to facilitate drainage [66]. In addition, the left atrium or left ventricle can be directly cannulated allowing blood to be vented into the venous arm of the ECMO circuit. The transition to a BiVAD (TandemHeart or Centrimag or Rotaflow) could be considered if the oxygenator is no longer needed [67]. Finally, the use of a left ventricular assist device such as the Impella (Abiomed, Danvers, MA) or BiPella (left and right Impella RP) [68] to provide left ventricular decompression as well as forward flow has been described and is gaining success due to its ease also bedside.



**Figure 4.** Factors driving unloading need in crash and burn patients. It has to be considered the possibility of unloading LV if signs of fluid overload (high pulsatility and LV distension at Echo and hemodynamic data) are not effectively treated with diuretics. Unloading is needed when there is low or absent LVEF, absent pulsatility without vasodilatation, smoking effect or slow flow through the MV.

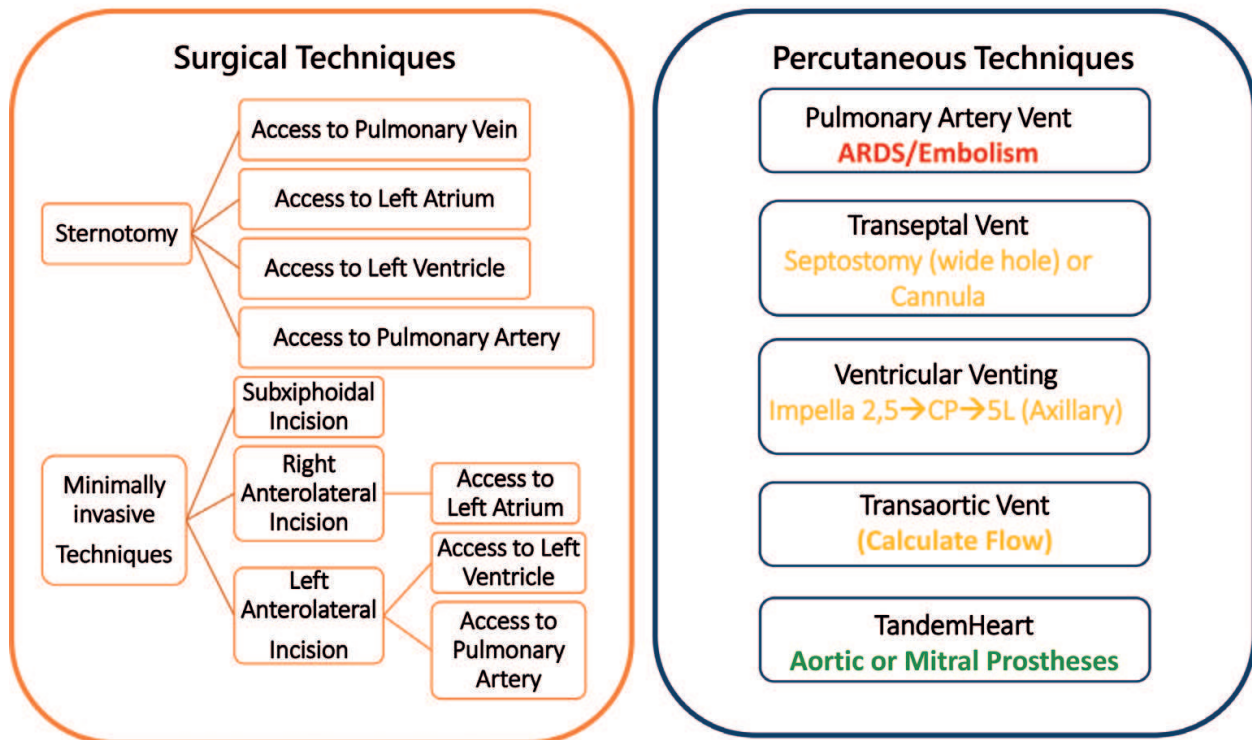


**Figure 5.** Atrial or ventricular unloading, decision making graph. In the graph, the pathological conditions in the blue dots are drivers of ventricular unloading while that ones in the red dots are drivers for atrial decompression. In green the first step therapy according to etiology.



**Figure 6.** Management of conditions that may require unloading if not properly treated.

## HOW TO VENT LEFT VENTRICLE

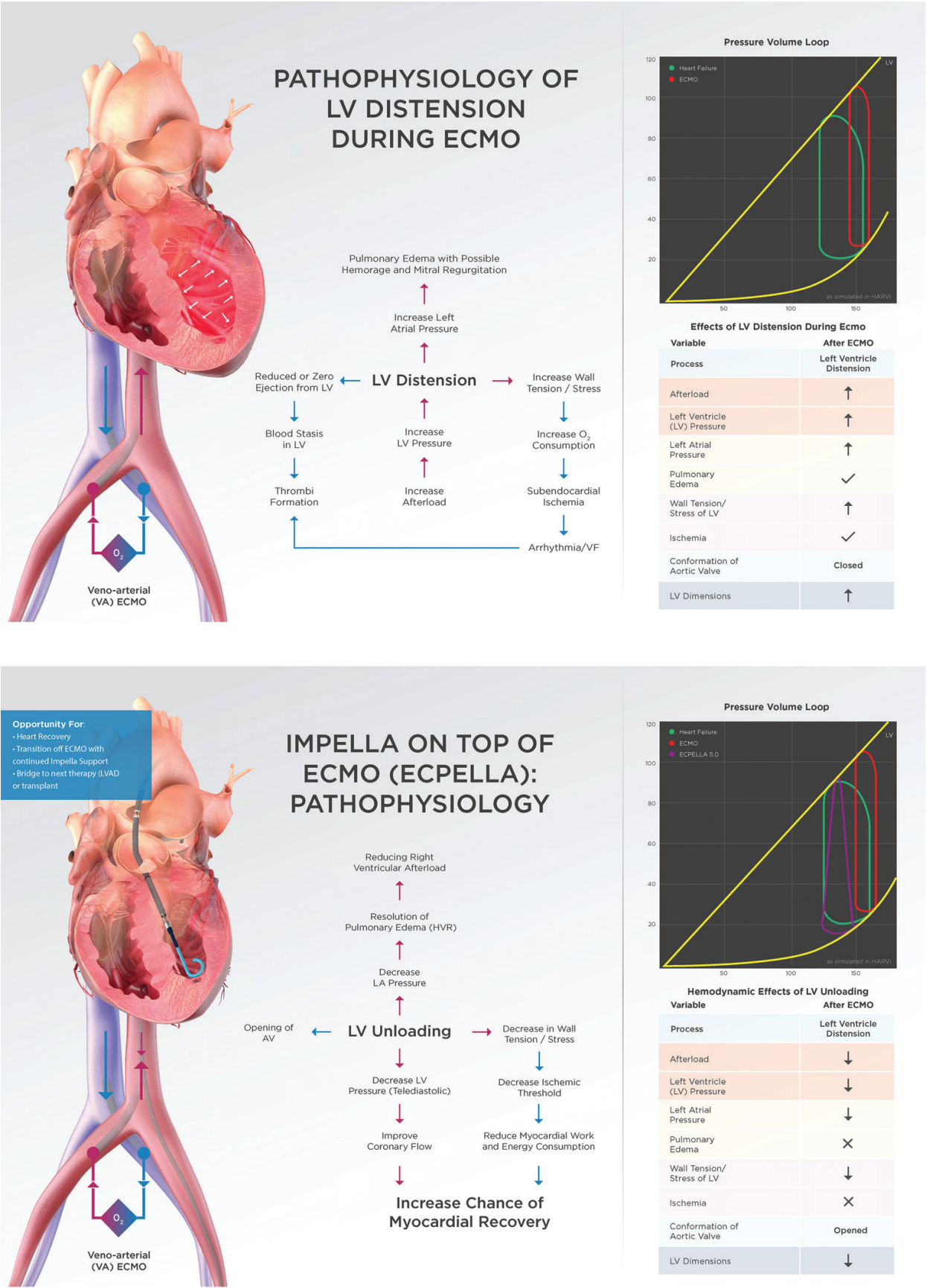


**Figure 7.** Surgical invasive, minimally invasive and percutaneous approaches to ventricle unloading.

Left-to-right shunt can achieve effective decompression of the left ventricle in the setting of VA-ECMO at the presence of atrial communication (atrial septal defect or patent foramen ovale); atrial shunt can be, however, created also artificially with a percutaneous blade or balloon septostomy [69]. The procedure may be fruitful to induce pulmonary decongestion reducing atrial pressure and pulmonary edema but led to a suboptimal LV decompression.

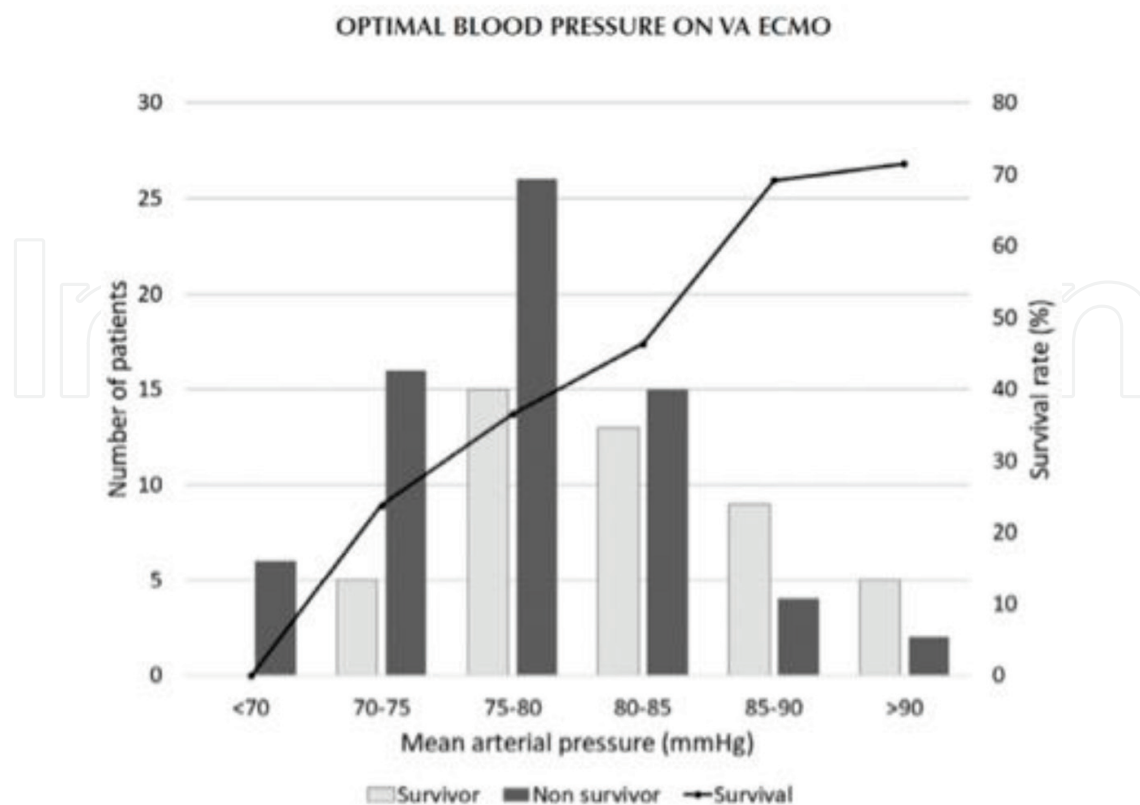
An alternative way to perform atrial unloading, under guidance by bedside transoesophageal echocardiography, is by transeptal puncture and placement of a drain (8 Fr to 15 Fr). The percutaneous atrial transeptal cannula can then be placed and connected to the inflow part of the ECMO circuit, thus, decompressing the pulmonary circulation [70].

The left ventricle can be vented directly by placing a transaortic vent through the axillary artery or by echocardiography-guided insertion of a pigtail catheter into the left ventricle through the aortic valve and connected to the inflow part of the ECMO circuit [71]. Fumagalli et al. [72] achieved the decompression with a catheter placed percutaneously through the aortic valve into the left ventricle. The blood drained from the left ventricle was pumped into the femoral artery through the VA-ECMO circuit. The normalization of left heart filling pressures led to the resolution of pulmonary edema, and the patient underwent successful heart transplantation. Barbone et al. [73] claimed LV unloading with a 7 Fr pigtail catheter inserted into the left ventricle via the femoral artery contralateral to the arterial outflow cannula. Using this approach in three different patients, the authors described resolution of LV distension and prevention of lung congestion without major complications. However, a so long and tight



**Figure 8.** Techniques to unload the heart during ECMO. (1) Pathophysiology of LV distension during ECMO and (2) Impella on top of ECMO (ECPELLA): pathophysiology.





**Figure 9.** Optimal Arterial Pressure on VA-ECMO (Copyright from ASAIO).

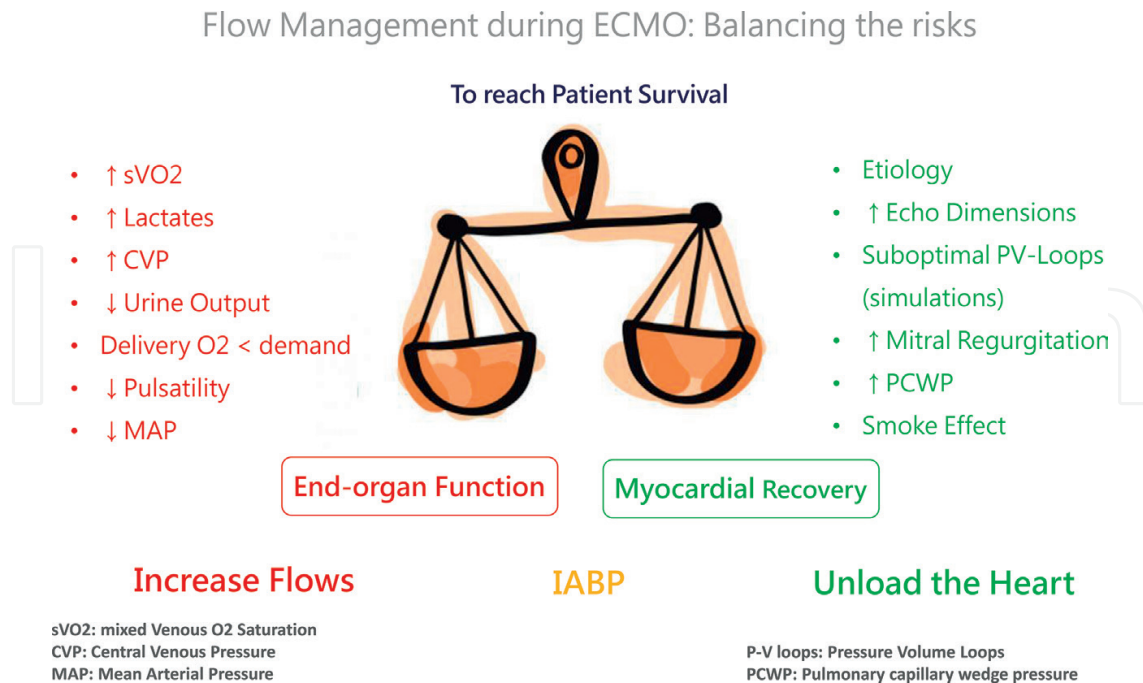
line may be argued ineffective to warrant a large amount of drainage as it is generally needed. Indeed, a recent paper indicates an algorithm to select the right dimension of the pig aiming to reach the right unloading flow [74].

An alternative approach to LV decompression is the percutaneous insertion of a venous cannula into the pulmonary artery and connection of this cannula to the inflow part of the ECMO circuit [75]. A small (15 Fr) venous cannula may be placed percutaneously to the pulmonary artery and connected to the ECMO circuit to decompress the left heart and to facilitate LV function. Surgical minimal invasive access to directly drain the pulmonary artery has been also suggested.

Impella (Abiomed Inc., USA) is a catheter-based transaortic axial flow pump that can be introduced through a percutaneous femoral approach. The device is placed across the aortic valve and pumps up (2.5–5 L/min) of blood on the basis of the model (2.5, CP or 5 L) from the left ventricle to the ascending aorta. The 2.5 and the CP are placed in the groin percutaneously while the 5.0 is generally placed surgically in the right axillary artery to warrant to the patient the possibility to be extubated and ambulatory.

Koeckert et al. [75] reported the use of Impella LP 2.5 for left ventricle decompression in a 70-year-old man with acutely decompensated heart failure who was placed on VA-ECMO for cardiogenic shock with severe pulmonary edema and respiratory failure. Both devices were successfully weaned on day 5 after myocardial recovery. Narain et al. [76] described a case involving 31-year-old man with fulminant myocarditis treated with the Impella device and





**Figure 10.** Patient survival from end-organ function to myocardial recovery.

VA-ECMO. On full mechanical circulatory support, the hemodynamic status improved, and both systems were explanted after 48 h. Many centers are now moving toward the adoption of Impella as bailout for weaning and to unload the ventricle during VA-ECMO even if many warnings have been expressed regarding the risks to add more complexity to the management of an already complex patient [77, 78]. **Figure 8** shows the pathophysiology of Left Ventricle distention due to ECMO (**Figure 8-1**) and the effects of adding Impella during ECMO (**Figure 8-2**).

**Figure 9** shows all the possible surgical and percutaneous solutions to unload the left circulation, preventing pulmonary edema and, possibly, facilitating the myocardial recovery when the underlying disease is potentially reversible. According to what said before, to reach patient survival, from end-organ function to myocardial recovery, we should balance arterial pressure, flow rate and unloading passing through IABP if necessary. The delicate balance of this therapeutical strategy is described in **Figure 10**.

## 6. Arterial pressure management during ECMO

While maintenance of flows is crucial to the care of the patient on VA-ECMO, attention must also be paid to the mean arterial pressure, as the end organs require both a cardiac output and a perfusion pressure for optimal function and a low venous pressure. A goal MAP >65 mmHg may be used as a starting point but can be adjusted either lower or higher given individual circumstances keeping in mind that the differential pressure between MAP and LAP is the driving force of organ perfusion and function. On the other side, MAP should never exceed 90 mmHg to limit afterload and to promote forward flow, especially when peripheral

cannulation limits the adequacy of drainage and leaves a remarkable amount of blood stagnating in the lung bed. A recent paper on the ASAIO Journal showed an inverse relationship between mortality and MAP in VA-ECMO but not in VV-ECMO (**Figure 10**) [79]. In the hypotensive patient, MAP may be increased by manipulating either CO or SVR. The total cardiac output of the body is composed of native cardiac output and VA-ECMO flows. Thus, hypotension may potentially be corrected by increasing VA-ECMO flows and its contribution to total CO. Assuming a centrifugal pump, this may be achieved by administering volume or by increasing the RPMs of the pump. If the problem is related to SVR, such as with septic shock, a vasoconstrictor may be needed to increase MAP, although this must be weighed against the effect of increased afterload and the increase in pressure work of the left ventricle.

Many different policies exist on the management of arterial pressure during VA-ECMO: one concern is about the equivalence of MAP in patients with or without pulsatility. Physiologic autoregulation is pivotal for end-organ perfusion and particularly for the brain and kidney. Many studies dealt with ideal MAP value in the ICU patient, the most identify a cutoff of 65 mmHg, as a value usually sufficient also if the study [80] suggested a MAP of 75–85 as protective for acute kidney injury in patients with a previous history of hypertension. To our knowledge, however, there has been only few studies examining optimal MAP for patients on ECMO and evidences in support of every practice are still weak.

Clearly, the physiology of VA-ECMO patients is considerably different from other critically ill patients. Several studies identified to determine the optimal pressure on cardiopulmonary bypass (CPB) during cardiac surgery [81–83] and the majority supports a MAP higher than 70 mm Hg on CPB. VA-ECMO is quite different from CPB: CPB is usually initiated electively for patients on stable patients, while VA-ECMO intervenes on an unstable circulatory condition. Moreover, the circuit is not open as in the CPB, the heart is not arrested, and there is not a reservoir to avoid pulmonary fluid overload. The heart is in a dynamic parallel circulation with ECMO aiming to reach an equilibrium to eject against incoming blood flow from the ECMO circuit. The amount of workload may often be incompatible with the failing heart performance of most VA-ECMO patients. VA-ECMO could induce increased afterload and further worsen myocardial dysfunction. If a lower MAP could have the rationale to permit the heart to eject against a lower resistance decreasing the myocardial oxygen demand, the clinical impact of hypotension on the patient in cardiogenic shock has to be carefully judged. Furthermore, it may not be suitable to compare the MAP of patients with and without pulsatility because patients without pulsatility may require a higher MAP for end-organ perfusion. It may not be suitable to compare the MAP of patients with and without pulsatility because patients without pulsatility may require a higher MAP for end-organ perfusion.

Pulsatility is a dynamic property due to the interaction between the two concurrent parallel circulations; indeed a loss of pulsatility may signal worsening myocardial function, while the appearance of pulsatility or an improvement in pulse pressure may signal recovery. However, the loss of pulsatility may also suggest that VA-ECMO flows are too high, so reducing the amount of blood managed from the impaired native circulation. The higher the ECMO flows, the more blood that drains into the circuit causing a more significant decrease in LV preload, stroke volume, and pulse pressure. Total bypass, where the ECMO circuit takes over 100% of the cardiac output, creates a flat, non-pulsatile arterial tracing and signifies the lack of ejection of blood from the left

ventricle. A recent study from Sakir Akin and the Erasmus group has shown how the peripheral recovery of pulsatility is a predictor of recovery that should push to weaning of ECMO [84].

Reduced pulsatility may also reflect a decrease in intravascular volume or a mechanical cause of decreased venous return (i.e., atrial tamponade) that may cause a decrease in LV preload leading decreased stroke volume and pulse pressure.

VA-ECMO reduces the volume work of the right ventricle through the decreased RV preload, while pulmonary edema may cause hypoxic pulmonary vasoconstriction worsening pulmonary hypertension and increasing RV pressure work. If this setting, the right ventricle may be unable to pump to the left side of the heart, flattening arterial pressure waveform and decreasing the stroke volume. Nitric oxide with inodilators such as milrinone and dobutamine (which will also provide inotropic assistance) are needed. If systemic pressures allow, nitroglycerin or nitroprusside may also be utilized.

7. Conclusions

Today, the first indication of treatment is weaning from ECMO and myocardial recovery. This target is more frequently achieved in myocarditis or potentially reversible diseases and stresses the importance of etiological diagnosis at the moment of implantation to define the strategy of implantation. In **Figure 11** there is a flow chart that clarifies how VA-ECMO should be managed, according to the etiology, to reach the weaning from ECMO goal and myocardial recovery, analysing the phases of the hemodynamic support and detecting unloading need at the right time.

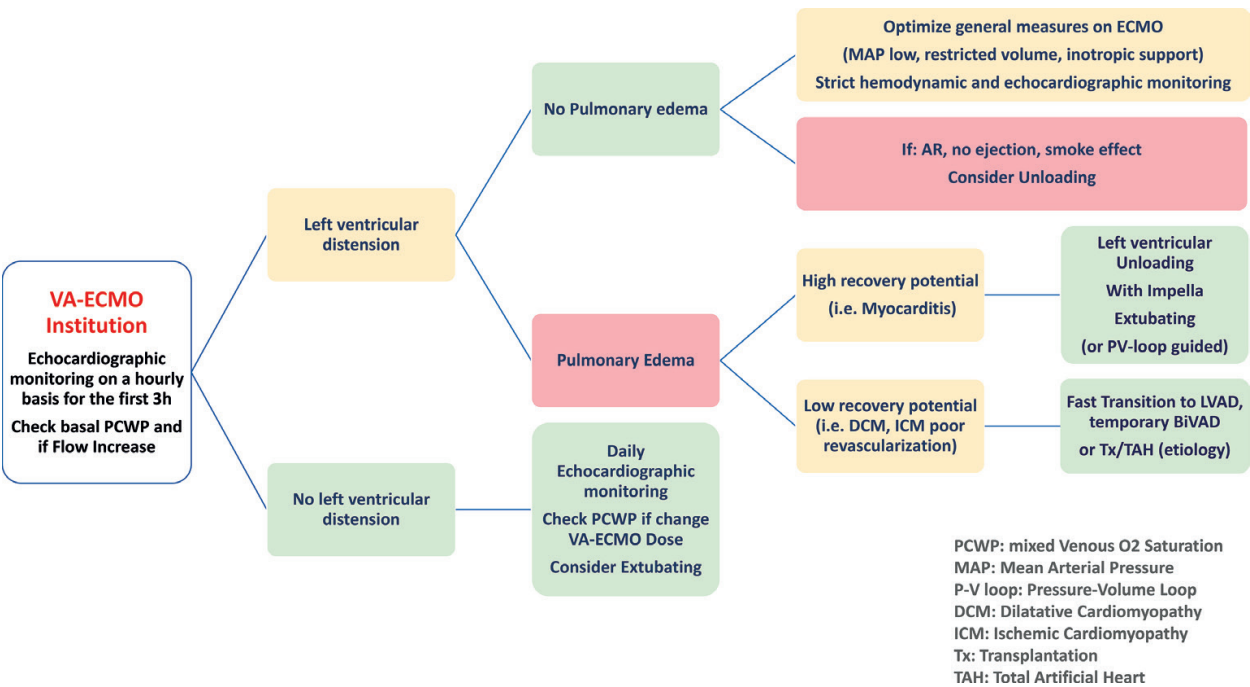


Figure 11. Flow chart on VA-ECMO management according to etiology.

VA-ECMO has to be deemed as temporary short-term support, and the risks related to the permanence of an oxygenator must focus on a rapid transition to further MCS systems. The assessment of left atrial pressure (direct or indirect) should be a mandatory tool in patients with VA-ECMO to increase the chance of recovery or transition to next support or treatment. When left atrial pressure is deemed increased in surgical unloading, or percutaneous unloading has to be considered preferring whenever possible ventricular unloading especially when mitral regurgitation is absent.

Randomized trials and registries will have to answer some of the open questions the clinician has to solve daily, dealing with the patient on VA-ECMO:

- Which goal directs the “dose” of VA-ECMO?
- Does one VA-ECMO configuration fit all?
- When unload before and when after VA-ECMO institution?
- Which clinical and hemodynamic profiles favor upfront VA-ECMO with LV venting?
- To vent or not to vent?
- When is vent mandatory?
- How vent without harm the patient?
- Should we transition to durable LVAD or BiVAD as soon as the end organs recovers?
- What are the granular aspects of management that should be included in trial design for VA-ECMO and LV venting?

## Acknowledgements

Cristiano Amarelli acknowledges the Abiomed for the figures freely provided on the association between ECMO and Impella.

This section of your manuscript may also include funding information.

## Conflict of interest

No conflict of interest to declare.

## Notes/thanks/other declarations

Thanks to IntechOpen for trusting and awaiting for the work to be finished.

## Author details

Cristiano Amarelli<sup>1\*</sup>, Francesco Musumeci<sup>2</sup>, Antonio Loforte<sup>3</sup>, Andrea Montalto<sup>2</sup>, Sveva Di Franco<sup>4</sup> and Jaime Hernandez-Montfort<sup>5</sup>

\*Address all correspondence to: camarell@tiscali.it

1 Department of Cardiac Surgery and Transplants, Monaldi Azienda dei Colli, Napoli, Italy

2 Department of Heart and Vessels, Cardiac Surgery Unit and Heart Transplantation Center, S. Camillo-Forlanini Hospital, Rome, Italy

3 Department of Cardiovascular Surgery and Transplantation, S. Orsola-Malpighi Hospital, Bologna University, Bologna, Italy

4 Department of Anaesthesiology and Critical Care Medicine, L. Vanvitelli University, Naples, Italy

5 Department of Cardiology, University of Texas Medical Branch, Galveston, USA

## References

- [1] Thiele H, Zeymer U, Neumann F-J, Ferenc M, Olbrich H-G, Hausleiter J, et al. Intraaortic balloon support for myocardial infarction with cardiogenic shock. *New England Journal of Medicine*. 2012;**367**(14):1287-1296. DOI: 10.1056/NEJMoa1208410
- [2] Ouwenel DM, Eriksen E, Sjaauw KD, van Dongen IM, Hirsch A, Packer EJS, et al. Impella CP versus intra-aortic balloon pump in acute myocardial infarction complicated by cardiogenic shock: The IMPRESS trial. *Journal of the American College of Cardiology*. 2017;**69**(3):278-287. DOI: 10.1016/j.jacc.2016.10.022. [Epub 2016 Oct 31]
- [3] Thiele H, Akin I, Sandri M, Fuernau G, de Waha S, Meyer-Saraei R, et al. PCI strategies in patients with acute myocardial infarction and cardiogenic shock. *New England Journal of Medicine*. 2017;**377**(25):2419-2432. DOI: 10.1056/NEJMoa1710261
- [4] Csepe TA, Kilic A. Advancements in mechanical circulatory support for patients in acute and chronic heart failure. *Journal of Thoracic Disease*. 2017;**9**(10). Retrieved from: <http://jtd.amegroups.com/article/view/16372>
- [5] Kawashima D, Gojo S, Nishimura T, Itoda Y, Kitahori K, Motomura N, et al. Left ventricular mechanical support with impella provides more ventricular unloading in heart failure than extracorporeal membrane oxygenation. *ASAIO Journal*. 2011;**57**(3):169-176. DOI: 10.1097/MAT.0b013e31820e121c. Retrieved from: [https://journals.lww.com/asaiojournal/Fulltext/2011/05000/Left\\_Ventricular\\_Mechanical\\_Support\\_with\\_Impella.5.aspx](https://journals.lww.com/asaiojournal/Fulltext/2011/05000/Left_Ventricular_Mechanical_Support_with_Impella.5.aspx)
- [6] Amarelli C, Mastroianni C, Brechot N. Prompt diagnosis of a new clinical entity: Membrane oxygenator infection during ECMO. *ASAIO Journal*. 2013;**59**(4):367. DOI: 10.1097/MAT.0b013e31829c5d21



- [7] Beely BM, Campbell JE, Meyer A, Langer T, Negaard K, Chung KK, et al. Electron microscopy as a tool for assessment of anticoagulation strategies during extracorporeal life support: The proof is on the membrane. *ASAIO Journal*. 2016;**62**(5):525-532. DOI: 10.1097/MAT.0000000000000394. Retrieved from: [https://journals.lww.com/asaiojournal/Fulltext/2016/09000/Electron\\_Microscopy\\_as\\_a\\_Tool\\_for\\_Assessment\\_of.5.aspx](https://journals.lww.com/asaiojournal/Fulltext/2016/09000/Electron_Microscopy_as_a_Tool_for_Assessment_of.5.aspx)
- [8] Wilm J, Philipp A, Müller T, Bredthauer A, Gleich O, Schmid C, et al. Leukocyte adhesion as an indicator of oxygenator thrombosis during extracorporeal membrane oxygenation therapy? *ASAIO Journal*. 2018;**64**(1):24-30. DOI: 10.1097/MAT.0000000000000586. Retrieved from [https://journals.lww.com/asaiojournal/Fulltext/2018/01000/Leukocyte\\_Adhesion\\_as\\_an\\_Indicator\\_of\\_Oxygenator.4.aspx](https://journals.lww.com/asaiojournal/Fulltext/2018/01000/Leukocyte_Adhesion_as_an_Indicator_of_Oxygenator.4.aspx)
- [9] Karagiannidis C, Brodie D, Strassmann S, et al. Extracorporeal membrane oxygenation: Evolving epidemiology and mortality. *Intensive Care Medicine*. 2016;**42**:889-896
- [10] Smith M, Vukomanovic A, Brodie D, Thiagarajan R, Rycus P, Buscher H. Duration of veno-arterial extracorporeal life support (VA ECMO) and outcome: An analysis of the extracorporeal life support organization (ELSO) registry. *Critical Care*. 2017;**21**(1):45. DOI: 10.1186/s13054-017-1633-1
- [11] Nakamura T, Ishida K, Taniguchi Y, Nakagawa T, Seguchi M, Wada H. Prognosis of patients with fulminant myocarditis managed by peripheral venoarterial extracorporeal membranous oxygenation support: A retrospective single-center study. *Journal of Intensive Care*. 2015;**3**(1). DOI: 10.1186/s40560-014-0069-9
- [12] Rousse N, Juthier F, Pinçon C, Hysi I, Banfi C, Robin E, et al. ECMO as a bridge to decision: Recovery, VAD, or heart transplantation? *International Journal of Cardiology*. 2015;**187**(1):620-627. DOI: 10.1016/j.ijcard.2015.03.283
- [13] Durinka JB, Bogar LJ, Hirose H, Brehm C, Koerner MM, Pae WE, et al. End-organ recovery is key to success for extracorporeal membrane oxygenation as a bridge to implantable left ventricular assist device. *ASAIO Journal (American Society for Artificial Internal Organs: 1992)*. 2014;**60**(2):189-192. DOI: 10.1097/MAT.0000000000000043
- [14] Cheng A, Swartz MF, Massey HT. Impella to unload the left ventricle during peripheral extracorporeal membrane oxygenation. *ASAIO Journal*. 2013;**59**(5):533-536. DOI: 10.1097/MAT.0b013e31829f0e52
- [15] Pappalardo F, Schulte C, Pieri M, Schrage B, Contri R, Soeffker G, et al. Concomitant implantation of Impella® on top of veno-arterial extracorporeal membrane oxygenation may improve survival of patients with cardiogenic shock. *European Journal of Heart Failure*. 2017;**19**(3):404-412. DOI: 10.1002/ehf.668
- [16] Patel SM, Lipinski J, Al-Kindi SG, Patel T, Saric P, Li J, et al. Simultaneous venoarterial extracorporeal membrane oxygenation and percutaneous left ventricular decompression therapy with impella is associated with improved outcomes in refractory cardiogenic shock. *ASAIO Journal*. 2018:1. DOI: 10.1097/MAT.0000000000000767. [Epub ahead of print]

- [17] Goldberg RJ, Spencer FA, Gore JM, Lessard D, Yarzebski J. Thirty-year trends (1975 to 2005) in the magnitude of, management of, and hospital death rates associated with cardiogenic shock in patients with acute myocardial infarction a population-based perspective. *Circulation*. 2009;**119**(9):1211-1219. DOI: 10.1161/CIRCULATIONAHA.108.814947
- [18] Doll N, Kiaii B, Borger M, et al. Five-year results of 219 consecutive patients treated with extracorporeal membrane oxygenation for refractory postoperative cardiogenic shock. *The Annals of Thoracic Surgery*. 2004;**77**:151-157
- [19] Sauer CM, Yuh DD, Bonde P. Extracorporeal membrane oxygenation use has increased by 433% in adults in the United States from 2006 to 2011. *ASAIO Journal*. 2015;**61**(1):31-36. DOI: 10.1097/MAT.0000000000000160
- [20] Han JJ, Swain JBD. The perfect ECMO candidate. *Journal of the American College of Cardiology*. 2018;**71**(10):1178-1182. DOI: 10.1016/j.jacc.2018.02.001
- [21] Chung M, Shiloh AL, Carlese A. Monitoring of the adult patient on venoarterial extracorporeal membrane oxygenation. *The Scientific World Journal*. 2014;**2014**:393258. DOI: 10.1155/2014/393258
- [22] Truby LK, Takeda K, Mauro C, Yuzefpolskaya M, Garan AR, Kirtane AJ, et al. Incidence and implications of left ventricular distention during venoarterial extracorporeal membrane oxygenation support. *ASAIO Journal*. 2017;**63**(3):257-265. DOI: 10.1097/MAT.0000000000000553
- [23] Rupperecht L, Flörchinger B, Schopka S, et al. Cardiac decompression on extracorporeal life support: A review and discussion of the literature. *ASAIO Journal*. 2013;**59**(6):547-553. DOI: 10.1097/MAT.0b013e3182a4b2f6
- [24] Strunina S, Ostadal P. Left ventricle unloading during veno-arterial extracorporeal membrane oxygenation. *Current Research: Cardiology*. 2016;**3**(1):5-8
- [25] Bernhardt AM, Hillebrand M, Yildirim Y, Hakmi S, Wagner FM, Blankenberg S, et al. Percutaneous left atrial unloading to prevent pulmonary oedema and to facilitate ventricular recovery under extracorporeal membrane oxygenation therapy. *Interactive Cardiovascular and Thoracic Surgery*. 2018;**26**(1):4-7. DOI: 10.1093/icvts/ivx266
- [26] Flecher E, Anselmi A, Corbineau H, Langanay T, Verhoye J-P, Felix C, et al. Current aspects of extracorporeal membrane oxygenation in a tertiary referral Centre: Determinants of survival at follow-up. *European Journal of Cardio-Thoracic Surgery*. 2014;**46**(4):665-671. DOI: 10.1093/ejcts/ezu029
- [27] Meani P, Pappalardo F. The step forward for VA ECMO: Left ventricular unloading! *Journal of Thoracic Disease*. 2017;**9**(11):4149-4151. <http://doi.org/10.21037/jtd.2017.10.14>
- [28] Hireche-Chikaoui H, Grüber MR, Bloch A, Windecker S, Bloechlinger S, Hunziker L. Nonejecting hearts on femoral veno-arterial extracorporeal membrane oxygenation. *Critical Care Medicine*. 2018;**1**:e459-e464. DOI: 10.1097/CCM.0000000000000296

- [29] Hékimian G, Jovanovic T, Bréchet N, Lebreton G, Leprince P, Trouillet J, et al. When the heart gets the flu. *Journal of Critical Care*. 2018;**47**:61-64
- [30] Stevens MC, Callaghan FM, Forrest P, Bannon PG, Grieve SM. Flow mixing during peripheral veno-arterial extra corporeal membrane oxygenation—A simulation study. *Journal of Biomechanics*. 2017;**55**:64-70. DOI: 10.1016/j.jbiomech.2017.02.009
- [31] Meani P, Gelsomino S, Natour E, Johnson DM, Rocca HPBL, Pappalardo F, et al. Modalities and effects of left ventricle unloading on extracorporeal life support: A review of the current literature. *European Journal of Heart Failure*. 2017;**19**:84-91. DOI: 10.1002/ejhf.850
- [32] Dickstein ML. The starling relationship and veno-arterial ECMO. *ASAIO Journal*. 2018;**64**(4):497-501. DOI: 10.1097/MAT.0000000000000660
- [33] Ostadal P, Mlcek M, Kruger A, et al. Increasing venoarterial extracorporeal membrane oxygenation flow negatively affects left ventricular performance in a porcine model of cardiogenic shock. *Journal of Translational Medicine*. 2015;**13**:266
- [34] Aissaoui N, Guerot E, Combes A, et al. Two-dimensional strain rate and Doppler tissue myocardial velocities: Analysis by echocardiography of hemodynamic and functional changes of the failed left ventricle during different degrees of extracorporeal life support. *Journal of the American Society of Echocardiography*. 2012;**25**:632-640
- [35] Soleimani B, Pae WE. Management of left ventricular distension during peripheral extracorporeal membrane oxygenation for cardiogenic shock. *Perfusion*. 2012;**27**:326-331
- [36] Fuhrman BP, Hernan LJ, Rotta AT, Heard CMB, Rosenkranz ER. Pathophysiology of cardiac extracorporeal membrane oxygenation. *Artificial Organs*. 1999;**23**:966-969
- [37] Burkhoff D, Sayer G, Doshi D, Uriel N. Hemodynamics of mechanical circulatory support. *Journal of the American College of Cardiology*. 2015;**66**(23):2663-2674. DOI: 10.1016/j.jacc.2015.10.017
- [38] Doufle G, Ferguson ND. Monitoring during extracorporeal membrane oxygenation. *Current Opinion in Critical Care*. 2016;**22**(3):230-8. DOI: 10.1097/MCC.0000000000000309
- [39] Sidebotham D, Allen S, McGeorge A, Beca J. Catastrophic left heart distension following initiation of venoarterial extracorporeal membrane oxygenation in a patient with mild aortic regurgitation. *Anaesthesia and Intensive Care*. 2012;**40**:568-569
- [40] Douflé G, Roscoe A, Billia F, Fan E. Echocardiography for adult patients supported with extracorporeal membrane oxygenation. *Critical Care*. 2015;**19**:326. DOI: 10.1186/s13054-015-1042-2
- [41] Donker DW, Meuwese CL, Braithwaite SA, Broomé M, van der Heijden JJ, Hermens JA, et al. Echocardiography in extracorporeal life support: A key player in procedural guidance, tailoring and monitoring. *Perfusion (United Kingdom)*. 2018;**33**(1\_suppl):31-41. DOI: 10.1177/0267659118766438

- [42] Esposito ML, Kapur NK. Acute mechanical circulatory support for cardiogenic shock: The “door to support” time. *F1000Research*. 2017;**6**:737. DOI: 10.12688/f1000research.11150.1
- [43] Truesdell AG, Tehrani B, Singh R, Desai S, Saulino P, Barnett S, et al. “Combat” approach to cardiogenic shock. *Interventional Cardiology Review*. 2018;**13**(2):81-86. <http://doi.org/10.15420/icr.2017:35:3>
- [44] Williams DO, Korr KS, Gewirtz H, Most AS. The effect of intraaortic balloon counterpulsation on regional myocardial blood flow and oxygen consumption in the presence of coronary artery stenosis in patients with unstable angina. *Circulation*. 1982;**66**(3):593-597. DOI: 10.1161/01.CIR.66.3.593
- [45] Marra C, De Santo LS, Amarelli C, Della Corte A, Onorati F, Torella M, et al. Coronary artery bypass grafting in patients with severe left ventricular dysfunction: A prospective randomized study on the timing of perioperative intraaortic balloon pump support. *International Journal of Artificial Organs*. 2002;**25**(2):141-146
- [46] Zobel G, Dacar D, Kuttig M, Rodl S, Rigler B. Mechanical support of the left ventricle in ischemia induced left ventricular failure: An experimental study. *The International Journal of Artificial Organs*. 1992;**15**(2):114-119
- [47] Werdan K, Gielen S, Ebelt H, Hochman JS. Mechanical circulatory support in cardiogenic shock. *European Heart Journal*. 2014;**35**(3):156-167. DOI: 10.1093/eurheartj/eh248. [Epub 2013 Sep 7]
- [48] Ma P, Zhang Z, Song T, Yang Y, Meng G, Zhao J, et al. Combining ECMO with IABP for the treatment of critically ill adult heart failure patients. *Heart Lung and Circulation*. 2014;**23**(4):363-368. DOI: 10.1016/j.hlc.2013.10.081
- [49] Petroni T, Harrois A, Amour J, et al. Intra-aortic balloon pump effects on macrocirculation and microcirculation in cardiogenic shock patients supported by venoarterial extra-corporeal membrane oxygenation. *Critical Care Medicine*. 2014;**42**:2075-2082
- [50] Park TK, Yang JH, Choi SH, et al. Clinical impact of intra-aortic balloon pump during extracorporeal life support in patients with acute myocardial infarction complicated by cardiogenic shock. *BMC Anesthesiology*. 2014;**14**:27
- [51] Fincke R, Hochman JS, Lowe AM, Menon V, Slater JN, Webb JG, et al. Cardiac power is the strongest hemodynamic correlate of mortality in cardiogenic shock: A report from the SHOCK trial registry. *Journal of the American College of Cardiology*. 2004;**44**(2):340-348. DOI: 10.1016/j.jacc.2004.03.060
- [52] De Silva K, Lumley M, Kailey B, Alastruey J, Guilcher A, Asrress KN, et al. Coronary and microvascular physiology during intra-aortic balloon counterpulsation. *JACC: Cardiovascular Interventions*. 2014;**7**(6):631-640. DOI: 10.1016/j.jcin.2013.11.023
- [53] Scandroglio AM, Pieri M, Pappalardo F, Landoni G. Intra-aortic balloon pump during venoarterial extracorporeal membrane oxygenation: Still a matter of debate? Contemporary multi-device approach to cardiogenic shock. *Journal of Thoracic Disease*. 2017;**9**(5):E522-E524



- [54] Shishehbor MH, Moazami N, Tong MZY, Unai S, Tang WHW, Soltesz EG. Cardiogenic shock: From ECMO to Impella and beyond. *Cleveland Clinic Journal of Medicine*. 2017;**84**(4):287-295. DOI: 10.3949/ccjm.84gr.17002
- [55] Hoeper MM, Tudorache I, Kühn C, Marsch G, Hartung D, Wiesner O, et al. Extracorporeal membrane oxygenation watershed. *Circulation*. 2014;**130**(10):864-865. DOI: 10.1161/CIRCULATIONAHA.114.011677
- [56] Lin LY, Liao CW, Wang CH, Chi NH, Yu HY, Chou NK, et al. Effects of additional intra-aortic balloon counter-pulsation therapy to cardiogenic shock patients supported by extra-corporeal membranous oxygenation. *Scientific Reports*. 2016;**6**:23838 DOI: 10.1038/srep23838
- [57] Cheng JM, den Uil CA, Hoeks SE, et al. Percutaneous left ventricular assist devices vs. intra-aortic balloon pump counterpulsation for treatment of cardiogenic shock: A meta-analysis of controlled trials. *European Heart Journal*. 2009;**30**:2102-2108
- [58] Nuding S, Werdan K. IABP plus ECMO—Is one and one more than two? *Journal of Thoracic Disease*. 2017;**9**(4):961-964
- [59] Sauren LDC, Accord RE, Hamzeh K, De Jong M, Van Der Nagel T, Van Der Veen FH, et al. Combined Impella and intra-aortic balloon pump support to improve both ventricular unloading and coronary blood flow for myocardial recovery: An experimental study. *Artificial Organs*. 2007;**31**(11):839-842. DOI: 10.1111/j.1525-1594.2007.00477.x
- [60] O'Connor CM, Rogers JG. Evidence for overturning the guidelines in cardiogenic shock. *New England Journal of Medicine*. 2012;**367**(14):1349-1350. DOI: 10.1056/NEJMe1209601
- [61] Gaudard P, Mourad M, Eliet J, Zeroual N, Culas G, Rouvière P, et al. Management and outcome of patients supported with Impella 5.0 for refractory cardiogenic shock. *Critical Care*. 2015;**19**(1). DOI: 10.1186/s13054-015-1073-8
- [62] Pieri M, Contri R, Winterton D, Montorfano M, Colombo A, Zangrillo A, et al. The contemporary role of Impella in a comprehensive mechanical circulatory support program: A single institutional experience. *BMC Cardiovascular Disorders*. 2015;**15**(1):126. DOI: 10.1186/s12872-015-0119-9
- [63] Donker DW, Brodie D, Henriques JPS, Broomé M. Left ventricular unloading during veno-arterial ECMO. *ASAIO Journal*. 2018. DOI: 10.1097/MAT.0000000000000755. [Epub ahead of print]
- [64] Bréchet N, Demondion P, Santi F, Lebreton G, Pham T, Dalakidis A, et al. Intra-aortic balloon pump protects against hydrostatic pulmonary oedema during peripheral venoarterial-extracorporeal membrane oxygenation. *European Heart Journal: Acute Cardiovascular Care*. 2018;**7**(1):62-69. DOI: 10.1177/2048872617711169. [Epub 2017 Jun 2]
- [65] Cheng R, Hachamovitch R, Makkar R, Ramzy D, Moriguchi JD, Arabia FA, et al. Lack of survival benefit found with use of intraaortic balloon pump in extracorporeal membrane oxygenation: A pooled experience of 1517 patients. *Journal of Invasive Cardiology*. 2015;**27**(10):453-458



- [66] Baruteau A-E, Barnetche T, Morin L, Jalal Z, Boscamp NS, Le Bret E, et al. Percutaneous balloon atrial septostomy on top of venoarterial extracorporeal membrane oxygenation results in safe and effective left heart decompression. *European Heart Journal: Acute Cardiovascular Care*. 2018;**7**(1):70-79. DOI: 10.1177/2048872616675485. [Epub 2016 Oct 14]
- [67] Saffarzadeh A, Bonde P. Options for temporary mechanical circulatory support. *Journal of Thoracic Disease*. 2015;**7**(12):2102-2111. DOI: 10.3978/j.issn.2072-1439.2015.09.14
- [68] Kuchibhotla S, Esposito ML, Breton C, Pedicini R, Mullin A, O'Kelly R, et al. Acute biventricular mechanical circulatory support for cardiogenic shock. *Journal of the American Heart Association*. 2017;**6**(10). pii:e006670. DOI: 10.1161/JAHA.117.006670
- [69] Seib PM, Faulkner SC, Erickson CC, Van Devanter SH, Harrell JE, Fasules JW, et al. Blade and balloon atrial septostomy for left heart decompression in patients with severe ventricular dysfunction on extracorporeal membrane oxygenation. *Catheterization and Cardiovascular Interventions*. 1999;**46**(2):179-186. DOI: 10.1002/(SICI)1522-726X(199902)46:2<179::AID-CCD13>3.0.CO;2-W
- [70] Aiyagari RM, Rocchini AP, Remenapp RT, Graziano JN. Decompression of the left atrium during extracorporeal membrane oxygenation using a transeptal cannula incorporated into the circuit. *Critical Care Medicine*. 2006;**34**(10):2603-2606. DOI: 10.1097/01.CCM.0000239113.02836.F1
- [71] Avalli L, Maggioni E, Sangalli F, Favini G, Formica F, Fumagalli R. Percutaneous left-heart decompression during extracorporeal membrane oxygenation: An alternative to surgical and transeptal venting in adult patients. *ASAIO Journal*. 2011;**57**(1):38-40. DOI: 10.1097/MAT.0b013e3181fe5d0b
- [72] Fumagalli R, Bombino M, Borelli M, Rossi F, Colombo V, Osculati G, et al. Percutaneous bridge to heart transplantation by venoarterial ECMO and transaortic left ventricular venting. *International Journal of Artificial Organs*. 2004;**27**(5):410-413. DOI: 10.1177/039139880402700510
- [73] Barbone A, Malvindi PG, Ferrara P, Tarelli G. Left ventricle unloading by percutaneous pigtail during extracorporeal membrane oxygenation. *Interactive Cardiovascular and Thoracic Surgery*. 2011;**13**(3):293-295. DOI: 10.1510/icvts.2011.269795
- [74] Kim WH, Hong TH, Byun JH, Kim JW, Kim SH, Moon SH, et al. Flow rate through pigtail catheter used for left heart decompression in an artificial model of extracorporeal membrane oxygenation circuit. *ASAIO Journal*. 2017;**63**(3):346-350. DOI: 10.1097/MAT.0000000000000472
- [75] Koeckert MS, Jorde UP, Naka Y, Moses JW, Takayama H. Impella LP 2.5 for left ventricular unloading during venoarterial extracorporeal membrane oxygenation support. *Journal of Cardiac Surgery*. 2011;**26**:666-668
- [76] Narain S, Paparcuri G, Fuhrman TM, Silverman RB, Peruzzi WT. Novel combination of Impella and extra corporeal membrane oxygenation as a bridge to full recovery in fulminant myocarditis. *Case Reports in Critical Care*. 2012;**2012**:1-3. DOI: 10.1155/2012/459296

- [77] Camboni D, Schmid C. To vent or not on veno-arterial extracorporeal membrane oxygenation, does it improve myocardial recovery and outcome? *Journal of Thoracic Disease*. 2017;**9**(12):4915-4918. <https://doi.org/10.21037/jtd.2017.11.98>
- [78] Akanni OJ, Takeda K, Truby LK, Kurlansky PA, Chiuзан C, Han J, et al. EC-VAD: Combined use of extracorporeal membrane oxygenation and percutaneous microaxial pump left ventricular assist device. *ASAIO Journal*. 2018. DOI: 10.1097/MAT.0000000000000804 [Epub ahead of print]. Retrieved from: [https://journals.lww.com/asaiojournal/Fulltext/onlinefirst/EC\\_VAD\\_Combined\\_Use\\_of\\_Extracorporeal\\_Membrane.98870.aspx](https://journals.lww.com/asaiojournal/Fulltext/onlinefirst/EC_VAD_Combined_Use_of_Extracorporeal_Membrane.98870.aspx)
- [79] Tanaka D, Shimada S, Mullin M, Kreitler K, Cavarocchi N, Hirose H. What is the optimal blood pressure on Veno-arterial extracorporeal membrane oxygenation? Impact of mean arterial pressure on survival. *ASAIO Journal*. 2018. DOI: 10.1097/MAT.0000000000000824. [Epub ahead of print]. Retrieved from: [https://journals.lww.com/asaiojournal/Fulltext/onlinefirst/What\\_Is\\_the\\_Optimal\\_Blood\\_Pressure\\_on.98853.aspx](https://journals.lww.com/asaiojournal/Fulltext/onlinefirst/What_Is_the_Optimal_Blood_Pressure_on.98853.aspx)
- [80] Leone M, Asfar P, Radermacher P, Vincent JL, Martin C. Optimizing mean arterial pressure in septic shock: A critical reappraisal of the literature. *Critical Care*. 2015;**19**:101. DOI: 10.1186/s13054-015-0794-z
- [81] Gold JP, Charlson ME, Williams-Russo P, Szatrowski TP, Peterson JC, Pirraglia PA, et al. Improvement of outcomes after coronary artery bypass: A randomized trial comparing intraoperative high versus low mean arterial pressure. *The Journal of Thoracic and Cardiovascular Surgery*. 1995;**110**(5):1302-1314. DOI: 10.1016/S0022-5223(95)70053-6
- [82] Murphy GS, Hessel EA, Groom RC. Optimal perfusion during cardiopulmonary bypass: An evidence-based approach. *Anesthesia and Analgesia*. 2009;**108**(5):1394-1417. DOI: 10.1213/ane.0b013e3181875e2e
- [83] Levin MA, Lin HM, Castillo JG, Adams DH, Reich DL, Fischer GW. Early on-cardiopulmonary bypass hypotension and other factors associated with vasoplegic syndrome. *Circulation*. 2009;**120**(17):1664-1671. DOI: 10.1161/CIRCULATIONAHA.108.814533
- [84] Akin S, dos Reis Miranda D, Caliskan K, Soliman OI, Guven G, Struijs A, et al. Functional evaluation of sublingual microcirculation indicates successful weaning from VA-ECMO in cardiogenic shock. *Critical Care*. 2017;**21**(1):265. DOI: 10.1186/s13054-017-1855-2

