

# We are IntechOpen, the world's leading publisher of Open Access books Built by scientists, for scientists

6,900

Open access books available

186,000

International authors and editors

200M

Downloads

Our authors are among the

154

Countries delivered to

TOP 1%

most cited scientists

12.2%

Contributors from top 500 universities



WEB OF SCIENCE™

Selection of our books indexed in the Book Citation Index  
in Web of Science™ Core Collection (BKCI)

Interested in publishing with us?  
Contact [book.department@intechopen.com](mailto:book.department@intechopen.com)

Numbers displayed above are based on latest data collected.  
For more information visit [www.intechopen.com](http://www.intechopen.com)



---

# Endoscopic Extraperitoneal Transvesicocapsular Adenectomy of Prostate (EETAP): A New Operative Method with an Innovative Learning Protocol for Its Performance

---

Genadiev Tsvetin Trifonov

Additional information is available at the end of the chapter

<http://dx.doi.org/10.5772/intechopen.82225>

---

## Abstract

The standard surgical treatment of obstructive symptoms of the lower urinary tract by benign prostatic hyperplasia is transurethral resection or classical simple prostatectomy. Inspired by our experience with laparoscopic radical prostatectomy and for the protection of urethra from stricture during prolonged transurethral resection, we studied the literature and started a prospective study for performing a laparoscopic simple prostatectomy. Following informed patient consent, we performed laparoscopic extraperitoneal simple prostatectomy in 17 patients with moderate to severe obstructive symptoms of benign prostatic hyperplasia with a prostate volume of over 80 ml. We did not find a laparoscopic technique for a simple prostatectomy which is the same as our method that we describe and publish. We called our method endoscopic extraperitoneal transvesicocapsular adenectomy of prostate. We identified an abbreviation for the method of its popularization and systematic presentation, EETAP. In this chapter, we publish for the first time in the literature a minimally invasive surgical method for endoscopic extraperitoneal transvesicocapsular prostate adenectomy. We describe and publish the details of the method, the abbreviation of the method, an innovative learning protocol for its performance, as well as hypotheses for preoperative and intraoperative differential diagnosis. In our opinion, a multicenter study of this method could lead to its standardization in the broad urological practice.

**Keywords:** new minimal invasive operative method, simple prostatectomy, endoscopic extraperitoneal transvesicocapsular adenectomy, prostate, EETAP, obstructive symptoms of the lower urinary tract, benign prostatic hyperplasia, laparoscopic extraperitoneal simple prostatectomy, innovative learning protocol, preoperative and intraoperative differential diagnosis, urine genetic test, new urine prostate cancer test indications

---

## 1. Introduction

For operative treatment of benign prostatic hyperplasia, transurethral resection is used as a standard for prostatic volume up to 75 ml. For larger volumes of the prostate, there is a classic open simple prostatectomy, which we call adenomectomy. The laparoscopic surgical technique was introduced into urology in 1991 with the publication of Schuessler et al. for pelvic lymph node dissection for prostate cancer staging [1]. Shortly thereafter, the first laparoscopic radical prostatectomy published by the same author was performed [2]. The first laparoscopic simple prostatectomy was performed in 1999 by Mariano Mirandolino [3]. In the last 10 years, the laparoscopic surgical technique has been used for the operative treatment of benign prostatic hyperplasia. Various minimally invasive methods for simple prostatectomy performed by laparoscopy are found in the literature. Laparoscopy is performed by transperitoneal access, classical laparoscopy, and extraperitoneal access—endoscopic extraperitoneal technique. A greater number of methods are not described in detail and consistently. Encouraged by our experience with laparoscopic radical prostatectomy and for the protection of the urethra from stricture during prolonged transurethral resection, we started a prospective study to perform and validate endoscopic extraperitoneal surgery for simple prostatectomy in benign prostatic hyperplasia, BPH. We have defined and described the main points of the surgical technique of simple prostatectomy. We present a detailed step-by-step approach to our method. In order to use the experience of a similar laparoscopic method, we compared all the steps of the new method with the previously described surgical technique for endoscopic extraperitoneal radical prostatectomy. We created an innovative protocol for learning and performing the new method based on a comparison of the two surgical methods performed in prostate cancer and prostate adenoma. From this protocol, we built a hypothesis for a new intraoperative approach to suspected carcinoma by express histological examination of the enucleated adenomatous tissue and an assessment of the volume of surgery—radical prostatectomy or adenomectomy. This hypothesis is to be explored. We have also developed a second hypothesis for preoperative differential diagnosis of aggressive prostate cancer by a noninvasive urine test SelectMDx/MDxHealth, Irvine, CA, USA, and Europe, to avoid classical biopsy in selected patients. The role of this hypothesis is related to the presence of 10% incidental cancer in patients after simple prostatectomy, and some authors perform a preoperative classical prostate biopsy on all patients. The indications for urine test performance are limited by the use of 5-alpha-reductase inhibitors as well as in patients with permanent urethral catheter due to inability to spontaneously urinate. However, the method could be used in patients who are candidates for a simple prostatectomy in order to prevent a second operation for incidental prostate cancer. Until now, such indications have not been determined for this urine test.

## 2. Materials and methods

### 2.1. Patients

For the period 2014–2017, 17 men,  $n = 17$ , of average age 64 years, from 48 to 76, were operated in the Urology Department of Vita Hospital, Sofia, and in the Urology Clinic of Uni

Hospital, City of Panagurishte. In all, endoscopic extraperitoneal transvesicocapsular adenectomy of the prostate (EETAP) was done. Preoperative prostate diagnosis was made by PSA total and free, rectal digital prostate examination, transrectal ultrasound, abdominal ultrasound, and flexible urethrocystoscopy. The mean volume of prostate adenoma measured by transrectal ultrasound was 95 ml, 75–140. We performed an evaluation of the international prostate symptom score preoperatively only in patients without residual urine. We have used uroflowmetry in patients with early symptoms of prostate obstruction. Four patients underwent transrectal tru-cut ultrasound prostate biopsy before adenectomy. We did not have a patient with transurethral resection of the prostate before surgery. All patients signed informed consent for the proposed operation and probability of occlusive prostate cancer despite negative preoperative diagnosis and biopsy. The surgical team has experience in prostate cancer diagnosis and laparoscopic radical prostatectomy. All operations were performed by a single major operator, TTG. This operator is a laparoscopic urologist with experience in endoscopic extraperitoneal radical prostatectomy, experienced in transvesical open simple prostatectomy, but not experienced in open transcapsular Millin adenectomy.

## **2.2. Indications**

Patients with benign prostatic hyperplasia (BPH), prostate adenoma, and symptoms of obstruction of the lower urinary tract. Prostate volume over 75 ml measured by transrectal ultrasound.

## **2.3. Contraindications**

General contraindications for laparoscopic method—impaired pulmonary and cardiovascular status—as well as those with impaired blood clotting. Patients with a history of a brain accident in the past have been consulting a neurologist to determine the risk of surgery related to Trendelenburg position. Patients with prior inguinal hernioplasty, with or without mesh plastic, have not been contraindicated. Patients with bladder stones or a large prostatic middle lobe are not contraindicated for our method. Asymptomatic uroinfection is not a contraindication to surgery. We do not have pre-treatment and apply a triple antibiotic combination at the beginning of the operation.

## **3. Operative technique EETAP**

In EETAP, preoperative patient preparation, anesthesia, patient's operating table position, operating team position, equipment location in the operating room, type of apparatus and instruments, and position and type of trocars completely coincide with those of endoscopic extraperitoneal radical prostatectomy, EERPE [Table 1]. An additional tool is the laparoscopic morcellation device with its own trocar 10 or 12 mm.

### **3.1. Preoperative patient preparation**

Diet regimen, the day before the operation, is as follows: normal daily meals and liquid supper at 18o'clock. Preoperative laxative preparation with suppositories for rectal administration.

	Author/year of publication	Patients, n =	Title name of the method and his abbreviation, if there is, according to the author's publication	Pelvic operative access—trans- or extraperitoneal	Access to adenoma via bladder wall incision, prostatic capsule incision, or vesicocapsular incision	Method of extraction the adenoma from the patient endobag or morcellation
1	Mariano et al., 2002 [3]	1	Laparoscopic prostatectomy with vascular control for benign prostatic hyperplasia	Trans	Midline bladder and capsular incision	Morcellation
2	Nadler et al., 2004 [19]	1	Preperitoneal laparoscopic simple prostatectomy	Extra	Transversal capsular incision	Endobag umbilical extraction
3	van Velthoven et al., 2004 [20]	18	Laparoscopic extraperitoneal adenomectomy (Millin)	Extra	Transversal anterior incision of the prostate capsule	Is not explained
4	Rey et al., 2005 [21]	5	Laparoscopic adenectomy: a novel technique for managing benign prostatic hyperplasia	Extra pre-peritoneal space by a Veress needle	Prostatic capsule is opened 3–4 cm transversally	Laparoscopic bag extracted through the enlarged umbilical incision
5	Sotelo et al., 2005 [22]	17	Laparoscopic simple retropubic prostatectomy	Extra	Transverse cystotomy	Endobag
6	Rehman et al., 2005 [23]	20	Laparoscopic extraperitoneal adenomectomy (LEA)	More than 20	Transversal capsulotomy	Endobag morcellated removed through the subumbilical incision
7	Mariano et al., 2006 [24]	60	Laparoscopic prostatectomy for benign prostatic hyperplasia, a 6-year experience	Extra	Midline incision anterior aspect of the prostatic capsule and bladder neck	Morcellation
8	Porpiglia et al., 2006 [25]	20	Transcapsular adenomectomy (Millin): a comparative study, extraperitoneal laparoscopy versus open surgery	Extra	Transversal capsular incision	Endobag through umbilical port
9	Oktay et al., 2011 [26]	16	Laparoscopic extraperitoneal simple prostatectomy for benign prostate hyperplasia	Extra	Transverse incision at the vesicoprostatic junction of the bladder	Is not explained

	Author/year of publication	Patients, n =	Title name of the method and his abbreviation, if there is, according to the author's publication	Pelvic operative access—trans- or extraperitoneal	Access to adenoma via bladder wall incision, prostatic capsule incision, or vesicocapsular incision	Method of extraction the adenoma from the patient endobag or morcellation
10	Ramón de Fata Chillón et al., 2010 [27]	10	Laparoscopic extraperitoneal adenomectomy	Extra	Vertical capsulotomy from the prostatic apex up to 1 cm above the bladder neck	Laparoscopic bag through the enlarged umbilical incision
11	Yun et al., 2010 [28]	11	Laparoscopic retropubic simple prostatectomy	Extra	Transverse incision of the anterior prostatic capsule	Endobag sac
12	García-Segui and Gascón-Mir, 2012 [29]	28	Laparoscopic extraperitoneal adenomectomy (LEA)	Extra	Transverse incision is made at the vesicoprostatic junction	Endobag sac
13	Xing et al., 2010 [30]	51	Laparoscopic simple prostatectomy with prostatic urethra preservation	Extra	Transverse prostatic capsular incision	Endobag
14	Pedro Romanelli de Castro et al., 2013 [31]	15	Laparoscopic retropubic prostatectomy: initial experience	Ten trans Five extra peritoneal	Opening of the prostate capsule and the bladder neck was made by longitudinal incision	Bagged and removed after morcellation through the umbilical incision
15	Al-Aown, 2015 [32]	11	Laparoscopic simple prostatectomy (LSP)	Extra	3–4 cm vertical cystotomy incision	Endobag
16	Autorino et al., 2015 [18]	843	Minimal invasive simple prostatectomy (MISP)	Extra	Is not explained	Is not explained
17	Garcia-Segu et al., 2015 [33]	26	“Knotless” laparoscopic adenomectomy	Extra	Is not explained	Morcellated adenoma extracted through the umbilical incision
18	Nicoline et al. 2016 [34]	17	Endoscopic transvesical adenomectomy of the prostate (ETAP)	Extraperitoneal but trans vesical percutaneous access	Intravesical bladder incision	Endobag/extraction bag/no data on how exactly to do this

	Author/year of publication	Patients, n =	Title name of the method and his abbreviation, if there is, according to the author's publication	Pelvic operative access—trans- or extraperitoneal	Access to adenoma via bladder wall incision, prostatic capsule incision, or vesicocapsular incision	Method of extraction the adenoma from the patient endobag or morcellation
19	Biktimirov et al., 2017 [35]	79	Minimal invasive simple prostatectomy MISP	Extra	Transverse incision of the anterior prostatic capsule	Removed through the 10 mm port site beneath the umbilicus
20	Baldini et al., 2017 [36]	28	Laparoscopic transcapsular prostatectomy (LTP)	Transperitoneal	Transverse prostatic capsular incision	Is not explained
21	Genadiev TS, 2018 [12]	17	Endoscopic extraperitoneal transvesicocapsular adenomectomy of the prostate (EETAP)	Extra	Transvesicocapsular incision	Morcelation and fragment extraction through the trocar or not morcelated in bag extraction through the left lateral trocar
Extra = extraperitoneal access. Trans = transperitoneal access. Is not explained = there is no explanation of the method in the text.						

**Table 1.** The cited authors on the topic with their main points of the surgical method.



Scheme of administration is as follows: the evening before the surgery at 8 o'clock a suppository and in the morning at 6 o'clock before surgery the second suppository. In patients with delayed intestinal passage, we prescribe the oral laxative tablets the day before the operation. Exceptionally, with an unsatisfactory laxative effect, we perform rectal cleansing enema in the morning before the operation. The field of operation is hairless in the evening before the day of surgery. All patients enter the operating room with elastic socks on the legs up to the middle of the thigh. Patients with permanent urethral catheter and urinary tract infections enter the operating room without a catheter. At the beginning of the operation, a combination of antibiotics—cephalosporin, aminoglycoside, and metronidazole—is administered intravenously. In the postoperative period, cephalosporin continues until the patient's discharge, usually 3 days. According to our protocol, prophylaxis with low molecular heparin begins at the sixth hour after the end of the operation. In patients with cardiovascular risk or postoperative bleeding, prophylaxis occurs outside of this protocol.

### 3.2. Anesthesia

All patients were operated under intubation endotracheal anesthesia with a peripheral venous pathway. Nasogastric tube is not required due to low pressure in the peritoneal cavity in extraperitoneal access. In order to provide free space for the cameramen behind the patient's head, it is necessary to use extended infusion and inhalation systems that distance the anesthesia team and the inhalation device from the patient. A preoperative discussion of the operating time is performed due to the faster onset of hypercapnia in the patient, which is typical for extraperitoneal laparoscopic access. This can be offset by the use of an insufflator with controlled maintenance of the working pressure and dosing of the carbon dioxide flow.

### 3.3. Position of the patient and operating team

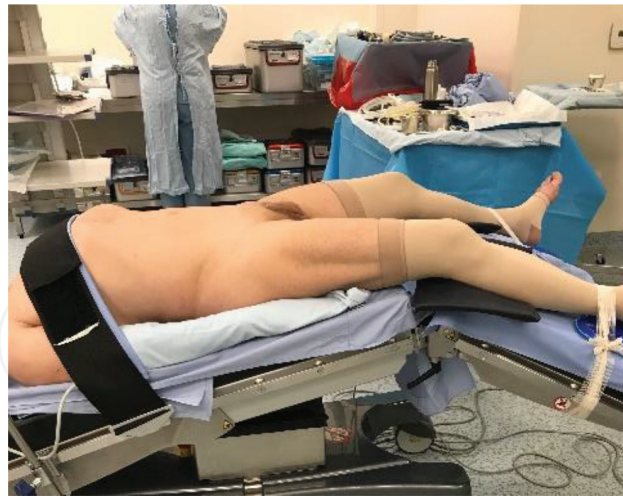The operating table should have a height of less than 60 cm from the floor level to achieve a good patient operating position and team ergonomics. The patient on the operating table is in the supine position. The hands are fixed to the body. To prevent compartment syndrome and for good blood circulation, the patient's legs remain on the horizontal pads of the operating table without the use of footwell attachments. Also the patient's legs are at the chest level during the Trendelenburg position. The legs remain dissolved at about 30° for access to the rectum, if necessary. At the patient's chest level, a moderately tight belt, 15 cm wide, with a soft pad, is provided to secure the 15° Trendelenburg position—**Figure 1**. Attention is needed against strong chest tightness and difficulty in breathing, as well as against mammary gland trauma.

Location of the operating team—the operator is to the left of the patient, assistant first to the right of the patient, second assistant, and cameramen, behind the patient's head. Surgical nurse is in front of assistant first, to the right of the patient, **Figure 2**.

### 3.4. Equipment and instruments

Olympus laparoscopic set with automatic insufflator. High-frequency bipolar current generator and ultrasound—Thunderbeat, manufactured by Olympus, Germany, **Figure 3**. Laparoscopic





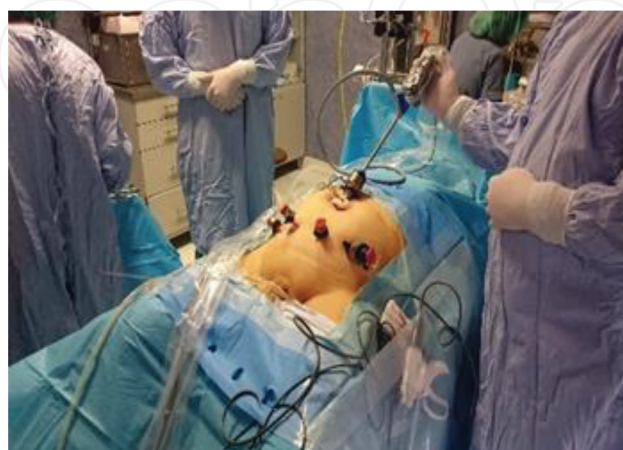**Figure 1.** Patient's position on the operative table.

instruments manufactured by Olympus, reusable trocars 5 and 10 mm, Hasson conical trocar 10 mm, and Thunderbeat laparoscopic instrument handle 5 mm, with combined action ultrasonic scissors and bipolar coagulation. Bipolar and traction forceps, needle holders, 5 mm cannula for aspiration, and irrigation with buttons and with piston handle. We do not use any cold scissors during the operation. Stitches are cut with Thunderbeat instrument. The Laparoscope 10 mm with detachable camera head, 0°. Working pressure of carbon dioxide is 12–14 mm mercury. Laparoscopic morcellator device with 10 mm trocar and grasping forceps 10 mm, manufactured by Richard Wolf, Germany. Morcellation operating speed is 1000 rpm.

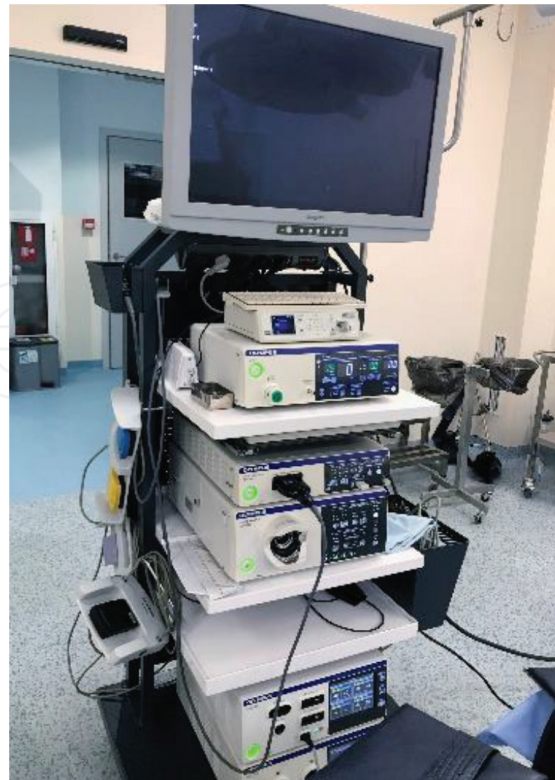The key instruments are Thunderbeat instrument, bipolar forceps, and suction/irrigation 5 mm cannula with pistol handle with two buttons, **Figure 4**.

### 3.5. Operative access to the pelvis

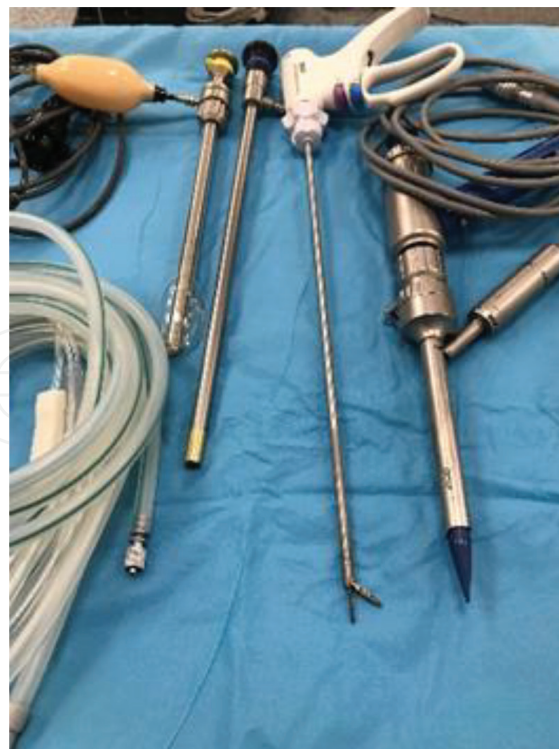Operative pelvis access is an endoscopic extraperitoneal balloon dissection of the Retzius space. Performing the pelvic operative field and trocars placement is carried out in a horizontal



**Figure 2.** Position of the operating team.

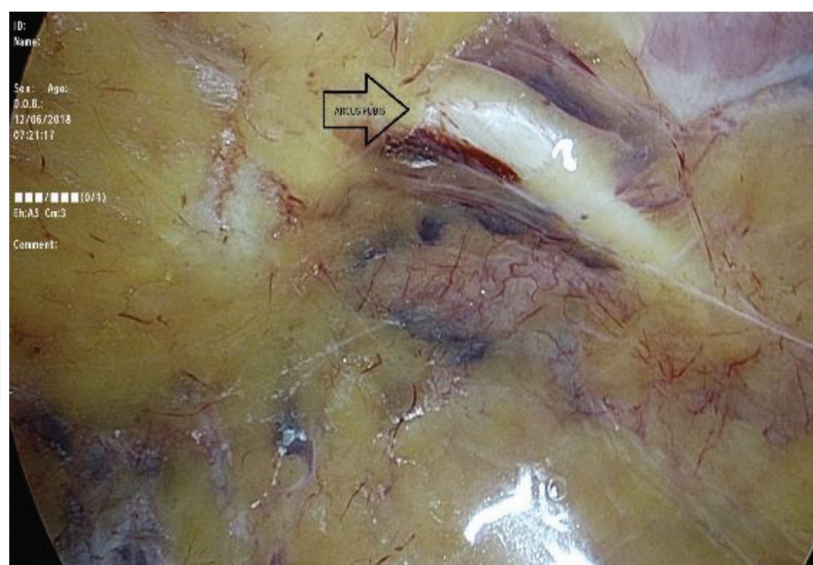


**Figure 3.** Olympus laparoscopic set with automatic insufflator with high-frequency bipolar current generator with ultrasound source, Thunderbeat, manufactured by Olympus, Germany.



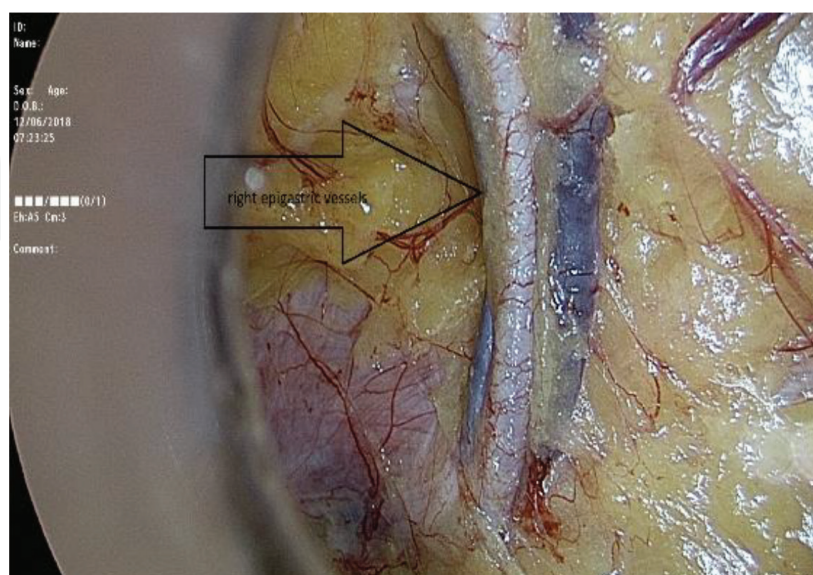
**Figure 4.** Key instruments: laparoscopic morcellator device with 10 mm trocar, manufactured by Richard wolf, Germany. Thunderbeat instrument 5 mm, Herloon system for extraperitoneal access.





**Figure 5.** Internal pelvic view through balloon dissector with 10 mm laparoscope shown arcus pubis.

position of the patient to prevent the unnecessary Trendelenburg position. We use balloon dissection device manufactured by Covidien/OMSPDB1000 PDP Round Distension Balloon disposable balloon disposer or by B. Brown or the Herloon System for extraperitoneal access, B. Braun, Aesculap AG, Tuttlingen, Germany. Laparoscopic morcellator device with 10 mm trocar and grasping forceps 10 mm, manufactured by Richard Wolf, Germany. Approximately 2 cm below the navel is a horizontal 2 cm incision of the skin. The incision site is determined by the depth and width of the pelvis of the patient to ensure good distance of the optic trocar to operative field and against collision with the other trocars. If the patient has a narrow pelvis, then the skin incision can be made slightly to the right of the assistant's side to ensure a good distance between the trocars of the operator. After the skin incision, the fascia of the anterior

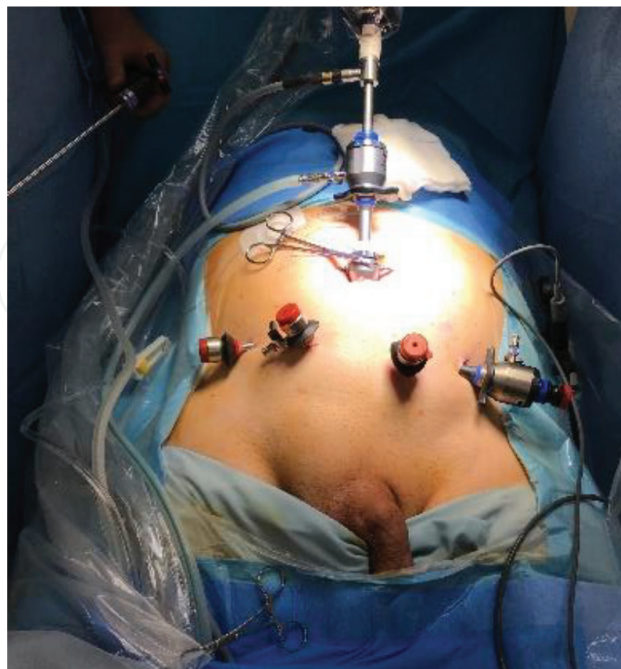

**Figure 6.** Internal pelvic view through balloon dissector with 10 mm laparoscope shown epigastric vessels.

abdominal wall is reached, which is the anterior fascia of the right abdominal muscles. It is incised transversely about 1–2 cm. Under the fascia, the right abdominal muscles are separated until the peritoneum is detected. Between the peritoneum and the anterior abdominal wall, with the help of the index finger on the right arm, enough space is created for the balloon dissector. The balloon is pumped under visual optical control until the appearance of the pubic arc and the internal epigastric vessels on both sides, **Figures 5 and 6**. After removing the balloon, a Hasson conical trocar is placed and fixed to the abdominal fascia with two slowly absorbable 2/0 Vicryl sutures with “j”-shaped needle, which are finally used to close the fascial insertion. In the case of adhesions of the anterior abdominal wall, which the balloon dissector cannot overcome, the trocars on the opposite side are placed. Adhesion dissection is performed, and access for other trocars is made.

### 3.6. Trocars: number, type, sequence of placement, and position

The trocars are five. Just the Hasson optical trocar has a smooth surface, because the cone allows to adjust the trocar penetration. Other working trocars must have a spiral surface or accessory fixators to adjust their depth due to the small operative field in the pelvis. Order of placement is as follows: 10 mm cone trocar for laparoscope with adjustable and fixed depth, left side lateral trocar 10 mm with 5 mm reducer, followed by left medial 5 mm, right lateral 5 mm, and right medial 5 mm. Trocars' position is as follows: the two lateral trocars are placed about 2 cm medial from the spina iliaca anterior superior, **Figure 7**. The two medial trocars are placed about 4–5 cm from the lateral ones at a position that provides about 45° of angle between the two working instruments, especially important for inner suturing. These trocars should be placed more cranially for easier suturing of the bladder wall.



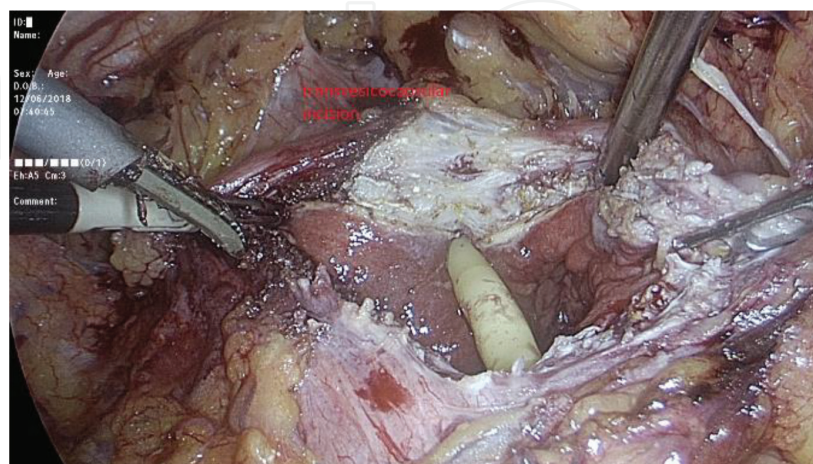
**Figure 7.** Trocar's position.

## 4. Operative technique of the inner part of the EETAP

### 4.1. Incision of the prostatic capsule and bladder neck: transvesicocapsular access to prostate adenoma

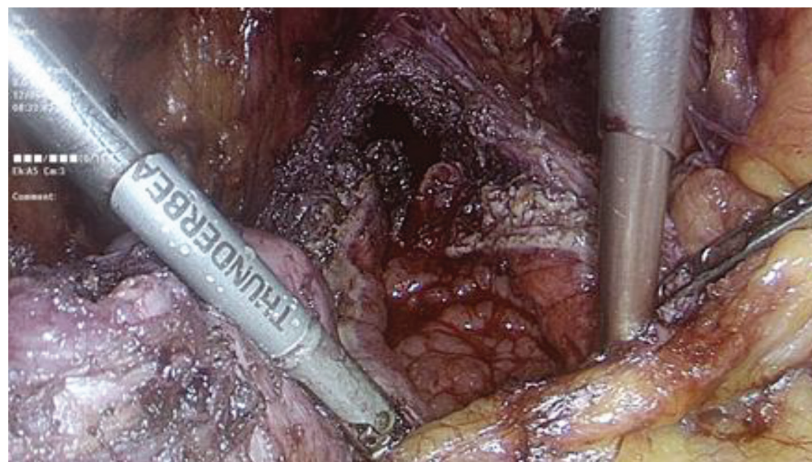
Fatty tissue and blood vessels of plexus Santorini are dissected to discovery just the middle surface of the prostatic capsule and the anterior surface of the bladder neck. No hemostatic ligatures on the bladder or capsule are required. The endopelvic fascia, the prostatic ligaments, and dorsal vein complex remain intact. The balloon catheter traction can be used to find bladder neck. The ultrasonic instrument Thunderbeat performs an incision of about 2 cm on the front wall of the bladder in the area of the bladder neck. Immediately after opening the bladder and finding the urethral catheter, the incision continues with the opening of the anterior surface of the bladder neck in the direction of the prostate capsule. Longitudinal incision of the prostatic capsule extends beyond the level of the puboprostatic ligaments to allow good apical dissection and urethral cutting. This is a key point in the EETAP operation and is called transvesicocapsular incision, **Figures 8 and 9**.

The advantages of this method are as follows: provides bladder access and inner examination, access to prostate adenoma, good plan for enucleation even in large median lobe, accessibility and good visibility for dissection of the apical part of the urethra without extreme traction of adenoma, good possibilities for bladder trigonisation, large postoperative bladder neck and possibility to avoid trigonisation; spares the inner pelvic anatomy such as dorsal vein complex, puboprostatic ligaments, the prostatovesical pedicles, and the endopelvic fascia to allow conversion to radical prostatectomy if necessary; and allows the same trocars position as EERPE in case of conversion. This method allows good large enucleation plan with prostate capsule preservation from rupturing in the lateral direction where the vascular bundles are located, which is important for our hypothesis of switching to radical prostatectomy during surgery. Last but not least, the transvesicocapsular incision is intuitive to perform and recover for a right-handed surgeon without changing the trocars during inner suturing.



**Figure 8.** Transvesicocapsular incision—*before* adenoma enucleation. The bladder neck is incised at 12 o'clock position longitudinally close to prostatic ligaments. The incision is in deep to the adenoma.

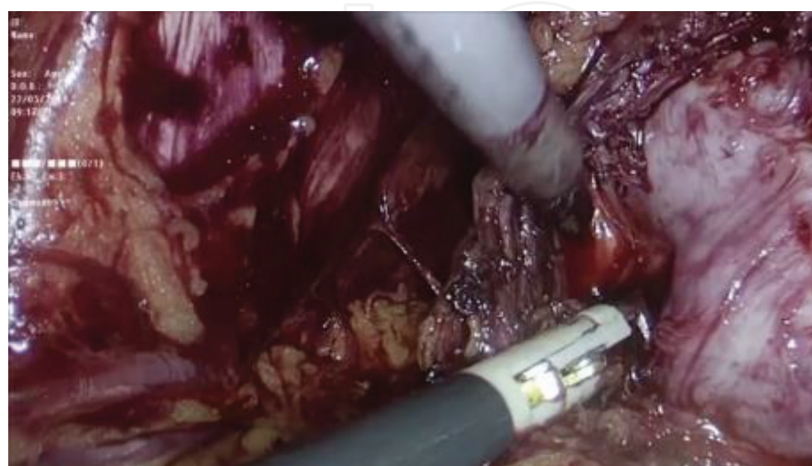




**Figure 9.** Transvesicocapsular incision—after adenoma enucleation. The prostatic bed is empty. Adenoma is on the left side of the picture.

#### 4.2. Enucleation of adenoma

The enucleation of the adenoma begins with the finding of a plan between the prostate capsule and the adenomatous tissue. This is most often done from the front surface of the bladder neck that is already open to the incision. So if there is a middle prostatic lobe, it does not make it difficult to find a plan. Moreover, if the middle lobe is large, a good plan can be found between its mucosa and the adenoma starting from 6 o'clock position of the bladder neck. The enucleation of adenoma is performed by Thunderbeat/Olympus combined with ultrasonic scissors and bipolar coagulation forceps and second bipolar forceps, **Figure 10**. Thus, the bipolar coagulation is possible on the two hands of the operator. With these two instruments, all enucleation is performed without the need for hemostatic ligatures of the internal prostatic pedicles that are coagulated with bipolar forceps. Enucleation is performed under visual control and in a visible manner between the capsule and the adenomatous tissue, following a good and possible plan. If the plan is lost, it goes into another plan. In the case of difficulties in the volume

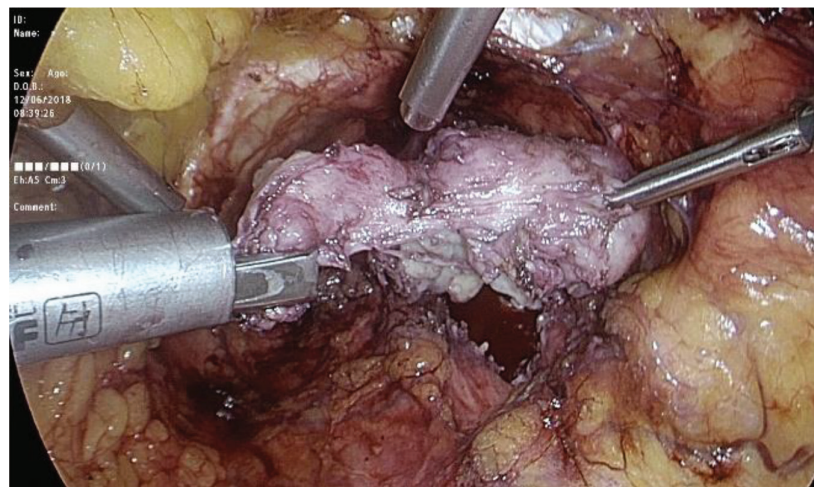


**Figure 10.** Enucleation plan between capsule and adenoma of the prostate via bipolar forceps and Thunderbeat instrument.

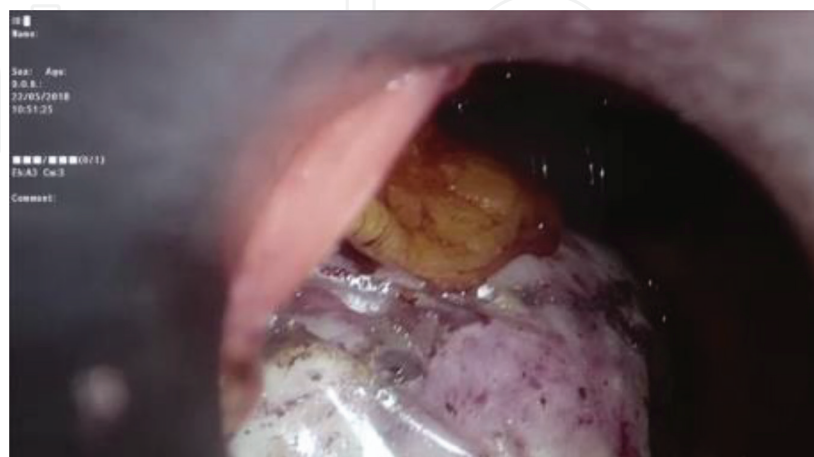of adenoma, it goes to its division and enucleation of parts. Apical dissection of the urethra requires attention. In this method, this is done with mild or without any traction, and a visible plan to find urethra and colliculus seminalis is to ensure good postoperative urine continence.

#### 4.3. Removing adenoma out of the patient

In our method, removal of the adenoma from the patient is done in two ways. The first method is as follows: a left lateral trocar is extracted and replaced with the laparoscopic morcellator with his own trocar without expanding the trocar hole. The adenoma is morcellating over the prostatic capsule with extraction of the each fragment via grasper immediately after his own morcellation. Beware of residual fragments in the bladder and on the pelvic wall! At the end of the morcellation, a revision of residual fragments is performed. The morcellator is pulled out under optics control, and the working trocar is reinserted, **Figure 11**.



**Figure 11.** Morcellation of the adenoma. The morsellator is placed through the left lateral trocar hole without skin extension.



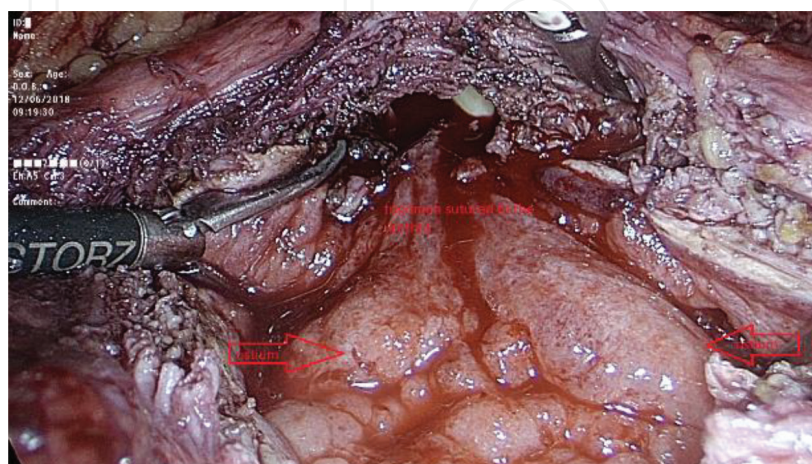
**Figure 12.** Enucleated adenoma in endobag and fixed through the left lateral trocar hole. The endobag can be extracted for histology examination.



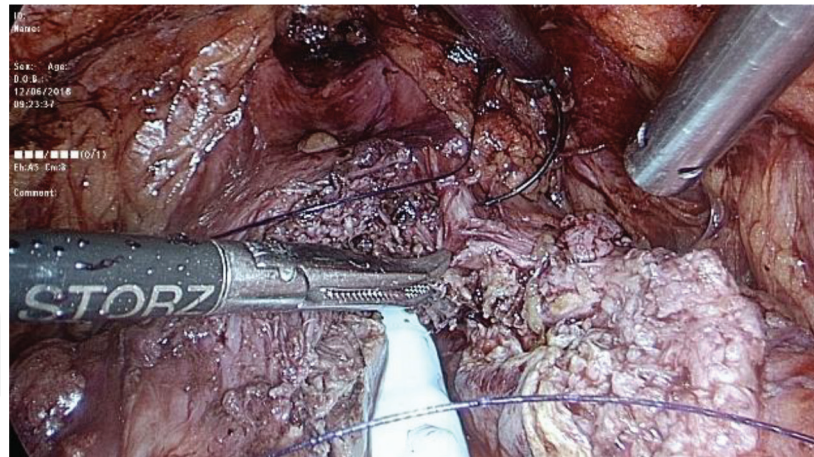
The second method is as follows: after complete release of the adenoma, it is placed in an endobag/sterile laparoscopic plastic bag that is fixed around the left lateral trocar and remains thus until the end of the inner part of the operation, **Figure 12**. This method is the same as in EERPE technique and allows extracting adenoma for an express histology test for cancer during the operation. If not necessary, then at the end of the operation, the left lateral trocar is removed, and his opening widens, and the endobag is removed through it. In order not to extend the trocar hole too far, the adenoma is subdivided by ultrasonic scissors into smaller fragments within the endobag. The removed material is fixed in formalin for a histological preparation.

#### 4.4. Closure of the transvesicocapsular incision

Prostatic bed hemostasis is performed with bipolar coagulation at reduced working pressure of carbon dioxide up to 8 mm mercury. After hemostasis of the prostatic bed, 3-0/Monocryl™ Plus, MCP 4160, Ethicon®, needle 1/2c, 26 mm, and Johnson and Johnson; hemostatic sutures of the bladder neck on the 5 and 7 o'clock position are made, and suturing the trigonum as close as possible to the urethra is performed. This is the so-called trigonisation, **Figure 13**. Following trigonisation, a three-way 22 charier catheter is inserted in the urethra to the bladder. The incision of the prostate and bladder wall is restored with continuous suture 2-0 monocryl/Vicryl™, Ethicon®, Johnson and Johnson, W9121, 26 mm, 1/2c needle, **Figure 14**. The suture starts from the apical part of the prostatic capsule and continues to the bladder wall up to the end of incision. Care should be taken not to suture the catheter. At the end of suturing, the catheter is checked for mobility. Then the balloon is placed sure in the bladder and inflated with 60 ml saline. Verification of the bladder for leakage, and start the irrigation through the catheter. Place a 14–16 charier tube drainage through a right lateral trocar hole. The skin of the trocar holes is closed with tissue glue/Hystoacryl® 0.5 ml, B. Braun Surgical, S.A./except for the hole in the tube drain. In this method the bladder neck inside remains open, with the suture engaging only the front of the bladder wall. Thus, we believe that a broad bladder-to-prostate communication is created to prevent post-operative bladder neck



**Figure 13.** Bladder trigonisation. The wide bladder neck remains open after incision closure.



**Figure 14.** Closure of the transvesicocapsular incision with 2/0 Monocryl continuous suture over the urethral catheter.

sclerosis. Furthermore, this extensive communication does not make trigonisation mandatory if there are technical difficulties to do so.

#### 4.5. Postoperative protocol

Our postoperative recovery protocol for EETAP is the same as our EERPE protocol. The only difference is the catheter irrigation after adenomectomy. This recovery protocol has the following steps: 6 hours after anesthesia, the patient is under monitoring, moves up, and takes fluids at the end of the sixth hour after the end of anesthesia. Thirty minutes before the movement, a subcutaneous application of low molecular heparin was administered. The irrigation of the catheter is stopped the next day, which is the first postoperative day. The balloon of the catheter remains inflated till the cystography. On a second or third postoperative day, the patient leaves the clinic. Ambulatory therapy for a total of 10 days with antibiotic per oral and prophylaxis with low molecular heparin is used. After the sixth postoperative day, cystography is performed in the ambulatory, and the urethral catheter is removed. We monitor and interview the patient monthly for urinary infection and sclerosis of the bladder neck until the third postoperative month.

### 5. Results

Average operative time skin to skin was 150 minutes (from 90 to 180). Average catheter stay was 7 days/6–9 days. There was no case of blood transfusions. There was no case of operative conversion or postoperative open or laparoscopic revision. There was no case of major complication such as vessel thrombosis or postoperative death. There was one case of early postoperative transurethral revision due to hematuria but without prolonged catheter stay and blood transfusion. The our second patient, who had the 140 ml prostate,

mainly with big median lobe, required transurethral resection on the third month after EETAP due to the large prostatic residual tissue on both sides. In fact we had removal just the big middle lobe. One patient reports stress incontinence until 6 postoperative months. Without patients with new catheterization due to urinary retention. None of the patients reported impaired erectile function or full urine incontinence. There are five cases of subdermal hematomas, typical after extraperitoneal access. Preoperative prostate biopsy was performed in four patients. We did not have a case with accidentally exposed prostate cancer. All patients reported satisfaction with the first urination after catheter removal. From our postoperative observation and patient interview to 90 postoperative day, we did not have a patient with bladder neck sclerosis, bladder stones, or other urological postoperative complications.

## 6. Discussion

Our laparoscopic practice began in 2003 with our first laparoscopic staging lymph node dissection in prostate cancer [4]. In 2005 we introduced in our practice the Montsouris technique of transperitoneal radical prostatectomy [5, 6]. Three years later we start to perform the endoscopic extraperitoneal radical prostatectomy technique described by Stolzenburg et al., [7, 8]. We published a new endoscopic extraperitoneal method for bladder stones in 2011 [9]. In our diagnostic practice, we introduced the transrectal ultrasound tru-cut prostate biopsy in 2004 [10], the ratio of free to total PSA in 2005 [11], and urine test SelectMDx in 2017 [12]. These circumstances and the protection of the urethra from prolonged transurethral resection motivated us to carry out and validate the new EETAP method. For exploring and describing our method, we were guided by the main points of our technique—surgical access, access to the prostate capsule and adenoma, a method of removing adenoma from the patient. We only discuss sources and authors that are closely related to the keywords of our method. Authors describing laparoscopic robot-assisted, single-port, hybrid, and operative techniques other than our method are not discussed here.

According to the Guidelines of European Association of Urology, the term minimal invasive simple prostatectomy (MISP) includes laparoscopic simple prostatectomy (LSP) and robot-assisted simple prostatectomy (RASP) [13]. Both methods are based on the transcapsular (Millin) or transvesical (Freyer) techniques. According to Guidelines of American Urological Association, the methods with minimal invasion are called minimally invasive surgical therapies, MIST. There is no abbreviation for laparoscopic simple prostatectomy [14]. According to Canadian UA Guideline 2010 Update: Guidelines for the Management of Benign Prostatic Hyperplasia, minimally invasive surgical therapies (MIST), and in the open simple prostatectomy section, there is no word laparoscopy or other laparoscopic simple prostatectomies. No current data from the Canadian urologist association are available on this topic [15].

Sequence of stages and their steps	Surgical technique step by step	EERPE Prostate cancer Stages and steps	EETAP Prostate adenoma Stages and steps	Match between EERPE and EETAP
<b>First stage in seven steps: preoperative and operative preparation</b>				
1	Preoperative patient preparation	Yes	Yes	Match
2	Operating team	Yes	Yes	Match
3	Position of team in the operating room	Yes	Yes	Match
4	Patient table position	Yes	Yes	Match
5	Trendelenburg position	Yes	Yes	Match
6	Equipment	Yes	Yes	Match
7	Instrumental equipment	Yes	Yes	Match
<b>Second stage in four steps: operative access</b>				
8	Pelvic endoscopic access via balloon dissection	Yes	Yes	Match
9	Trocars: numbers and kinds	Yes	Yes	Match
10	Trocar position	Yes	Yes	Match
11	Access to the prostatic surface	Yes	Yes	Match
<b>Stage three in seven steps: intracorporeal part of both operative techniques</b>				
12	Endopelvic fascia incision	Yes	No	Matchless
13	Ligation of the dorsal vessels of the penis	Yes	No	Matchless
14	Longitudinal transvesicocapsular incision of the prostate capsule and bladder neck	No	Yes	Matchless
15	Interruption of the bladder neck	Yes	No	Matchless
16	Enucleation of prostatic adenoma	No	Yes	Matchless
17	Prostatovesiculectomy	Yes	No	Matchless
18	Urethrovesical anastomosis	Yes	No	Matchless
<b>Stage four in five steps: final steps of the operations</b>				
19	Removal of operative tissue via morcellation	No	Yes	Matchless
20	Lymph node dissection	Yes	No	Matchless



Sequence of stages and their steps	Surgical technique step by step	EERPE Prostate cancer Stages and steps	EETAP Prostate adenoma Stages and steps	Match between EERPE and EETAP
21	Removal tissue via endobag extraction	Yes	Yes	Match
22	Inner suture	Yes	Yes	Match
23	Kind of suture materials	Yes	Yes	Match
24	Trocars hole closure	Yes	Yes	Match
Stage five in three steps: postoperative protocol				
25	Postoperative recovery period/ catheter irrigation mentioned	Yes	Yes	Match
26	Patient discharge on POD 3–4	Yes	Yes	Match
27	Cystography on POD 5–7	Yes	Yes	Match
Steps number, 27		24/3	21/6	
Steps matching/correlation ratio, yes/no				
Both techniques in this protocol are presented with the same full steps, 27, and the same stages, 5. EERPE and EETAP are comparable and matching them in almost complete. Endobag = laparoscopic plastic bag.				

**Table 2.** This table presents the innovative learning protocol based on matching according to the main stages and the individual steps for each of the both operative techniques—EERPE and EETAP.

According to Tagard, transvesicocapsular adenomectomy was first described in 1948 by Ogier Ward, later from Bourque in 1954 and Watss in 1956 [16]. In this method, the prostatic capsule and bladder neck are open longitudinally. We have appreciated this and have adopted this method as a key and fundamental feature in our new operating technique.

Historically the first laparoscopic radical prostatectomy was performed and published by Schuessler et al. [2]. According to Delgado-Guerrero, 2016, the first case of laparoscopic simple prostatectomy, adenomectomy, was published by Dr. Mariano Mirandolino, who in 1999 performed the first adenomectomy of a 71-year-old man in Brazil through an extraperitoneal longitudinal incision of the prostate capsule [17]. Dr. Mariano Mirandolino is the pioneer of this operation. He published his 60 operated patients, but he did not describe the surgical technique in detail [24]. Autorino et al. published results from multicenter study and summarized that the laparoscopic simple prostatectomy was performed using different personal techniques developed based on the principles of transcapsular (Millin), transvesical (Freyer), or transvesicocapsular (Bourque) techniques, described for open simple prostatectomy. The

same author said that each investigator adopted specific operative strategies and technical moments to optimize this procedure [18]. We completely agree with this after our study of the literature on this topic. We find a lot of author's papers who present the simple prostatectomy on the principles of laparoscopy. They mainly describe the indications and results of the method without providing a detailed description of the surgical technique and the significance of each stage of it. We have not found another description of a laparoscopic method for simple prostatectomy that coincides with ours.

Obviously the laparoscopic simple prostatectomy is not difficult for an experienced laparoscopic urologist. More of cited authors mentioned their laparoscopic radical prostatectomy experience. From a review of literature, it can be seen that laparoscopic radical prostatectomy and laparoscopic simple prostatectomy began their development together [2, 3]. Probably due to standardized transurethral monopolar resection and classical open simple prostatectomy, laparoscopic simple prostatectomy develops more slowly. However, the lack of a consistent description of the details of the method does not allow it to be used for comparative training. The study of many different methods does not allow to create a true value and to standardize one of them. We classified the publications closest to our method according to the benchmarks of the operating technique, as it is shown in **Table 1**.

Therefore, we accept that operative methods published by other authors cannot serve for training. That is why we have decided to describe our new method in detail by comparing it to a similar one in prostate cancer, which is widely used, endoscopic extraperitoneal radical prostatectomy (EERPE) [8]. We have not found another description of a laparoscopic method for simple prostatectomy that coincides with ours. There is one method with abbreviation similar to ours but in fact is completely different [34]. So we did an innovative learning protocol. This protocol compares the EERPE surgical procedure to our adenomectomy surgical technique, EETAP. Moreover, training protocols for endoscopic extraperitoneal radical prostatectomy are found in the literature that can serve to build operator skills as a basis for our method [37–39]. According to the learning protocol of Stolzenburg JU, even residents without open surgery skills can perform EERPE after learning this protocol [40]. Thus, the operator's skills for one method can be applied to the other method, as shown in **Table 2**. Through it we believe that it is possible to introduce and standardize our method in practice.

The correlation ratio in **Table 2** between the two techniques shows that the skills for EERPE can be the basis for implementing EETAP. Moreover, this confirms our hypothesis for intraoperative conversion of adenomectomy into radical prostatectomy, if necessary. Mariano et al., 2006, reported a prostate biopsy in all 60 patients before being operated by laparoscopic simple prostatectomy [24]. Van Velthoven et al. [20], published in 11% of the operated patient's prostate cancer and three high-grade pin [26]. We have done prostate biopsy to four of our patients. Fortunately, we do not have a postoperative prostate cancer patient. None of the authors described behavior in patients with postoperative prostate cancer. Are they performing a second operation or applying another method? We assume that

our hypothesis for an intraoperative solution based on express histological examination in selected cases can solve this problem. The disadvantage of this hypothesis is the absence of a pathological preoperative stage, as is achieved in the puncture prostate biopsy. We also offer a second hypothesis for preoperative differential diagnosis of prostate cancer suspected patients by performing a noninvasive urine test SelectMDx [41, 42]. This test is popular as a liquid biopsy because of its high negative predictive value for aggressive prostate cancer with Gleason score of 7 to 10. The test is recommended of prostate cancer diagnosis in the European Urological Guidelines for 2018 [43]. We introduced this test in our daily practice since November 2017 [12]. The negative predictive value of the test is 98% for prostate cancer Gleason score 7, 99% for Gleason scores 8–10. Thus, this test can be the modern solution for preoperative diagnosis. Via SelectMDx test, patients who are candidates for BPH surgery can minimize incidental cancer to 8% or less and could replace the preoperative classical prostate biopsy. We cannot prove this hypothesis at this new indication due to lack of enough cases from our practice. However, this new hypothesis may be the basis for a prospective study to determine a new indication for this urine test. Patients receiving 5-alpha reductase inhibitors as well as those with a permanent urethral catheter are contraindicated or not be able to this method.

## 7. Conclusion

The operative treatment of urinary symptoms of benign enlarged prostate is performed with the main purpose of achieving satisfactory spontaneous urination for the patient. Our main motive is to find and describe a surgical method that protects the urethra from damage and brings to the patient the benefits of the open simple prostatectomy without its complications. Various surgical techniques for laparoscopic simple prostatectomy are found in the literature. Published cases are a bit about world practice. The world's largest urological recommendations do not define a proven method for laparoscopic simple prostatectomy. There is no detailed description of a method to be adopted and standardized. For the first time in the literature, a surgical method of endoscopic extraperitoneal transvesicocapsular adenomectomy of the prostate (EETAP) is discussed and published. This method may be performed by an operator with experience in endoscopic extraperitoneal radical prostatectomy according to our innovative learning protocol in this respect. In our opinion, this new method, its detailed description, its abbreviation, the innovative protocol for its application, and the new diagnostic hypotheses can serve as a basis for multicenter studies and conclusions for its standardization in the broad urological practice.

## Conflict of interest

The author declares no conflict of interest.



## Author details

Genadiev Tsvetin Trifonov

Address all correspondence to: genadievi@abv.bg

Department of Urology, Vita Hospital, Sofia, Bulgaria

## References

- [1] Schuessler WW, Vancaillie TG, Reich H, Griffith DP. Transperitoneal endosurgical lymphadenectomy in patients with localized prostate cancer. *The Journal of Urology*. 1991;**145**(5):988-991
- [2] Schuessler WW, Kavoussi LR, Clayman RV, Vancaille TH. Laparoscopic radical prostatectomy: Initial case report. *The Journal of Urology*. 1992;**147**:246A
- [3] Mariano MB, Graziottin TM, Tefilli MV. Laparoscopic prostatectomy with vascular control for benign prostatic hyperplasia. *The Journal of Urology*. 2002;**167**(6):2528-2529
- [4] Tsvetin G. Laparoscopic pelvic lymph dissection—First results. *Oncologos*. 2003;**4**:42-47. In Bulgarian
- [5] Guillonneau B, Vallancien G. Laparoscopic radical prostatectomy: The Montsouris experience. *The Journal of Urology*. 2000;**163**:418-422
- [6] Genadiev Tsvetin TR. Laparoscopic radical prostatectomy: Initial 22 cases in Bulgarian urological practice. *Acta Medica Bulgarica*. 2008;**1**:43-46
- [7] Genadiev Tsvetin TR, Gaidarov D, Veleva V. Endoscopic extraperitoneal radical prostatectomy—First results. *Uronet*. 2009;**1**:5-7. In Bulgarian
- [8] Stolzenburg JU, Do M, Pfeiffer H, König F, Aedtner B, Dorschner W. The endoscopic extraperitoneal radical prostatectomy (EERPE): Technique and initial experience. *World Journal of Urology*. 2002;**20**(1):48-55
- [9] Genadiev Tsvetin TR. In: Meinhold-Heerlein I, editor. *Laparoscopic Extraperitoneal Approach for Urinary Bladder Stones Removal—A New Operative Technique, Laparoscopy—An Interdisciplinary Approach*. Rijeka, Croatia: InTech; 2011
- [10] Genadiev Tsvetin TR. Transrectal puncture biopsy of the prostate. *Urology*. 2004;**10**:3, 71-74. In Bulgarian
- [11] Boncheva M, Genadiev Tsvetin TR, Petrov P, Halachev N, Gaidarov D, Nakov E. Diagnostic sensitivity and diagnostic specificity of the PSA ratio. *Medinfo*. 2005;**7**:9-10. In Bulgarian
- [12] Genadiev Tsvetin TR, Hristov C, Gaidarov D. Urine genetic test SelectMDx for prostate cancer diagnosis—Initial clinical experience. *GP News*. 2018;**6**(216):24-26. In Bulgarian

- [13] <http://uroweb.org/guideline/treatment-of-non-neurogenic-male-luts/#5>
- [14] [http://auanet.org/guidelines/benign-prostatic-hyperplasia/lower-urinary-tract-symptoms-\(2018\)#x8196](http://auanet.org/guidelines/benign-prostatic-hyperplasia/lower-urinary-tract-symptoms-(2018)#x8196)
- [15] <https://www.cua.org/en/guidelines>
- [16] Tagart REB. Prostatectomy by the vesico-capsular method. *British Medical Journal*. 1961;**4**:621-626
- [17] Delgado-Guerreroa F, Covarrubias-Méndez LM, González-Gómezb A, Bernal Hernándezb J, Torres-Aguilera J, Arellano-Cuadros R. Experience with laparoscopic prostatic adenectomy. *Revista Mexicana de Urología*. 2016;**76**(1):17-22
- [18] Autorino R, Zargar H, Mariano MB, Sanchez-Salas R, et al. Perioperative outcomes of robotic and laparoscopic simple prostatectomy: A European-American multi-institutional analysis. *European Urology*. 2015;**68**(1):86-94
- [19] Nadler RB, Blunt LW Jr, User HM, Vallancien G. Preperitoneal laparoscopic simple prostatectomy. *Urology*. 2004;**63**(4):778-779
- [20] Van Velthoven R, Peltier A, Laguna MP, Piechaud T. Laparoscopic extraperitoneal adenectomy (Millin): Pilot study on feasibility. *European Urology*. 2004;**45**(1):103-109
- [21] Rey D, Ducarme G, Hoepffner JL, Staerman F. Laparoscopic adenectomy: A novel technique for managing benign prostatic hyperplasia. *BJU International*. 2005;**95**(4):676-678
- [22] Sotelo R, Spaliviero M, Garcia-Segui A, Hasan W, Novoa J, Desai MM, et al. Laparoscopic retropubic simple prostatectomy. *The Journal of Urology*. 2005;**173**(3):757-760
- [23] Rehman J, Khan SA, Sukkariéh T, Chughtai B, Waltzer WC. Extraperitoneal laparoscopic prostatectomy (adenectomy) for obstructing benign prostatic hyperplasia: Transvesical and transcapsular (Millin) techniques. *Journal of Endourology*. 2005;**19**(4):491-496
- [24] Mariano MB, Tefilli MV, Graziottin TM, Morales CM, Goldraich IH. Laparoscopic prostatectomy for benign prostatic hyperplasia—A six-year experience. *European Urology*. 2006;**49**(1):127-131
- [25] Porpiglia F, Terrone C, Renard J, Grande S, Musso F, Cossu M, et al. Transcapsular adenectomy (Millin): A comparative study, extraperitoneal laparoscopy versus open surgery. *European Urology*. 2006;**49**(1):120-126
- [26] Oktay B, Koc G, Vuruskan H, Danisoglu ME, Kordan Y. Laparoscopic extraperitoneal simple prostatectomy for benign prostate hyperplasia: A two-year experience. *Urology Journal*. 2011;**8**(2):107-112
- [27] Ramón de Fata Chillón F, Nuñez Mora C, García Mediero JM, Cabrera Castillo P, García Tello A, Angulo Cuesta J. Laparoscopic extraperitoneal adenectomy: Surgical technique and preliminary results. *Actas Urológicas Españolas*. 2010;**34**(9):806-810

- [28] Yun HK, Kwon JB, Cho SR, Kim JS. Early experience with laparoscopic retropubic simple prostatectomy in patients with voluminous benign prostatic hyperplasia (BPH). *Korean Journal of Urology*. 2010;**51**(5):323-329
- [29] García-Segui A, Gascón-Mir M. Comparative study between laparoscopic extraperitoneal and open adenomectomy. *Actas Urológicas Españolas*. 2012;**36**(2):110-116
- [30] Xing N, Guo Y, Yang F, Tian L, Zhang J, Yan Y, et al. Laparoscopic simple prostatectomy with prostatic urethra preservation for benign prostatic hyperplasia. *Translational Andrology and Urology*. 2012;**1**(1):9-13
- [31] de Castro PR, Nishimoto RH, Pinheiro RGÂ, Arantes PB d O, Issa AMN, Issa HMN. Laparoscopic retropubic prostatectomy: Initial experience. *Revista Médica de Minas Gerais*. 2013;**23**(2):178-181
- [32] Al-Aown A, Liatsikos E, Panagopoulos V, Kyriazis I, Kallidonis P, Georgiopoulos I, et al. Laparoscopic simple prostatectomy: A reasonable option for large prostatic adenomas. *Urology Annals*. 2015;**7**(3):297-302
- [33] Garcia-Segui A, Verges A, Galán-Llopis JA, Garcia-Tello A, Ramón de Fata F, Angulo JC. "Knotless" laparoscopic extraperitoneal adenomectomy. *Actas Urológicas Españolas*. 2015;**39**(2):128-136
- [34] Kil NMP, Fossion LMCL. Endoscopische transvesicale adenomectomie van de prostaat (ETAP). Resultaten van de eerste 17 patiënten in een perifeerziekenhuis. *Tijdschrift voor Urologie*. 2016;**6**:104-112
- [35] Biktimirov RG, Martov AG, Biktimirov TR, Kaputovskii AA. The role of extraperitoneoscopic adenomectomy in the management of benign prostatic hyperplasia greater than 80 cm<sup>3</sup>. *Urologiia*. 2017;**(6)**:76-81
- [36] Baldini A, Fassi-Fehri H, Duarte RC, Crouzet S, Ecochard R, Abid N, et al. Holmium laser enucleation of the prostate versus laparoscopic transcapsular prostatectomy: Perioperative results and three-month follow-up. *Current Urology*. 2017;**10**(2):81-86. DOI: 10.1159/000447156
- [37] Tobias-Machado M, Pazeto CL, Neves-Neto OC, Nunes-Silva I, Zampolli HC. A safe teaching protocol of LRP (laparoscopic radical prostatectomy). *International Brazilian Journal of Urology*. 2018;**44**(2):273-279
- [38] Klein J, Teber D, Frede T, Stock C, Hruza M, Gözen A, et al. Development, validation and operating room-transfer of a six-step laparoscopic training program for the vesicourethral anastomosis. *Journal of Endourology*. 2013;**27**(3):349-354
- [39] Stolzenburg JU, Schwaibold H, Bhanot SM, Rabenalt R, Do M, Truss M, et al. Modular surgical training for endoscopic extraperitoneal radical prostatectomy. *BJU International*. 2005;**96**(7):1022-1027

- [40] Stolzenburg JU, Rabenalt R, Do M, Horn LC, Liatsikos EN. Modular training for residents with no prior experience with open pelvic surgery in endoscopic extraperitoneal radical prostatectomy. *European Urology*. 2006;**49**(3):491-498
- [41] <https://mdxhealth.com/company-overview>
- [42] Leyten GH et al. Identification of a candidate gene panel for the early diagnosis of prostate cancer. *Clinical Cancer Research*. 2015;**21**(13):3061-3070
- [43] <https://uroweb.org/guideline/prostate-cancer/#5>

