

We are IntechOpen, the world's leading publisher of Open Access books Built by scientists, for scientists

6,900

Open access books available

185,000

International authors and editors

200M

Downloads

Our authors are among the

154

Countries delivered to

TOP 1%

most cited scientists

12.2%

Contributors from top 500 universities



WEB OF SCIENCE™

Selection of our books indexed in the Book Citation Index
in Web of Science™ Core Collection (BKCI)

Interested in publishing with us?
Contact book.department@intechopen.com

Numbers displayed above are based on latest data collected.
For more information visit www.intechopen.com



Neuroimaging in Parkinson Disease

Roohi Mohammad and Fatima Mubarak

Abstract

Over many decades, neuroimaging which included structural, functional and molecular modalities—have provided invaluable insights into the mechanisms underlying Parkinson disease (PD). These studies have shown changes in brain structure and metabolic activity. Although it is now considered to be complex, still neuroimaging modalities are recommended for routine use in clinical practice. Special sequences such as susceptibility weighted and proton density sequences are recommended for characterization. Now, the world is switching more towards the deep brain stimulation so the neuroimaging also helps in pretreatment planning and post treatment complications assessments. This chapter discusses the radiological anatomy, sequencing and imaging appearances. It will also discuss new approaches with potential applicability to clinical practice.

Keywords: MRI, PET, deep brain stimulation, Parkinson, substantia nigra

1. Introduction

Parkinson's disease (PD) is a communal neurodegenerative disorder with a prevalence of 160/100,000 in Western Europe rising to 4% of the population over 80 [1]. With an increase in average age, the management of PD is increasingly imperative and perplexing aspect of medical practice for the neurologists and general physicians. The pathogenesis of the disease has been advanced in the last decade with the identification of several gene mutations and the mechanisms of pathogenesis in sporadic cases of PD. The diagnosis of PD remains fundamentally a clinical, and it is significant to recognize the early features together with symptoms and signs suggesting other causes of Parkinsonism. There has also been a rapid expansion in the management options together with a greater awareness of non-motor complications. Guidelines for the diagnosis and management of patients with PD have been published from the National Institute for Health and Clinical Excellence (NICE) in the UK [2]. Parkinson disease can be diagnosed with Magnetic resonance imaging (MRI). Apart from good clinical diagnosis the imaging also helps in either endorsing the diagnosis or ruling out other possible differential possibilities. MRI can take a long time and it needs pre-scan screening of patients who cannot undergo this exams as there are certain contraindications which are beyond the scope of this chapter.

2. Neuroimaging in Parkinson's disease

Over the past decades, neuroimaging studies which include structural, functional and molecular modalities—have provided priceless understandings about the Parkinson disease (PD) [3]. Although PD is very complex, no neuroimaging modalities are specifically recommended for routine use in clinical practice. However, conventional MRI and dopamine transporter imaging are used as adjuvant apparatuses in the differential diagnosis between PD and other causes of Parkinsonism. Single-photon emission CT and PET are equally effective at differentiating between degenerative and nondegenerative causes of parkinsonism; MRI and PET can differentiate between PD and atypical parkinsonism, but need sophisticated enhancement methods [4]. Dopaminergic and serotonergic PET can be used to monitor PD progression, motor and nonmotor symptoms, and complications, whereas cholinergic PET is currently the most sensitive approach for assessing PD dementia. PET and other neuroimaging techniques should have a primary role in the development of protocols for new clinical trials, particularly those investigating cell therapy. Hybrid PET-MRI technology could offer a revolution in PD imaging [5].

The development of imaging which targets specific sites in the brain represents a significant advance in neurodegenerative diseases and Parkinson's disease. The major roles of imaging include: (1) the use of neuroimaging in order to improve the accuracy, timeliness, and reliability of diagnosis; (2) objective monitoring of the progression of disease; (3) the evaluation of s “disease-modifying” treatments designed to retard the progression of disease by interfering with pathways thought implicated in the ongoing neuronal loss or replace dopamine-producing cells; (4) planning and evaluation of deep brain stimulation technique in candidates of surgery [6].

2.1 Radiological anatomy

In Parkinson disease, the main part involved is extrapyramidal system. The substantia nigra is the main brainstem nucleus and other one is the nucleus. The substantia nigra is seen in axial slices at both superior and inferior colliculi and red nuclei within an axial slice at the superior colliculi (see **Figure 1**). These nuclei are situated in the anterior midbrain and mark the transition point of the tegmentum and cerebral peduncles.

Substantia nigra consists of a compact part (dark, containing melanin) called pars compacta and a reticular part (reddish, containing iron) known as pars reticulata. Most of its axons are projected diffusely to other brain areas and not arranged into tracts. Numerous axonal tracts terminate in the substantia nigra: from caudate nucleus (striatonigral fibers) from anterior cerebral cortex (corticonigral fibers) and from putamen from precentral cortex.

High resolution T2*/SWI weighted MRI is able to recognize the substantia nigra and red nuclei. They appear as hypointense on T2W, proton density and SWI sequences.

2.2 Protocol in neuroimaging

Magnetic resonance imaging (MRI) has proven to be the mainstay imaging technique in making the differential diagnosis between atypical Parkinsonism and Parkinson's disease.

Conventional T1- and T2-weighted MRI sequences are not very helpful in diagnosing idiopathic Parkinson's disease because nigral structures appear normal

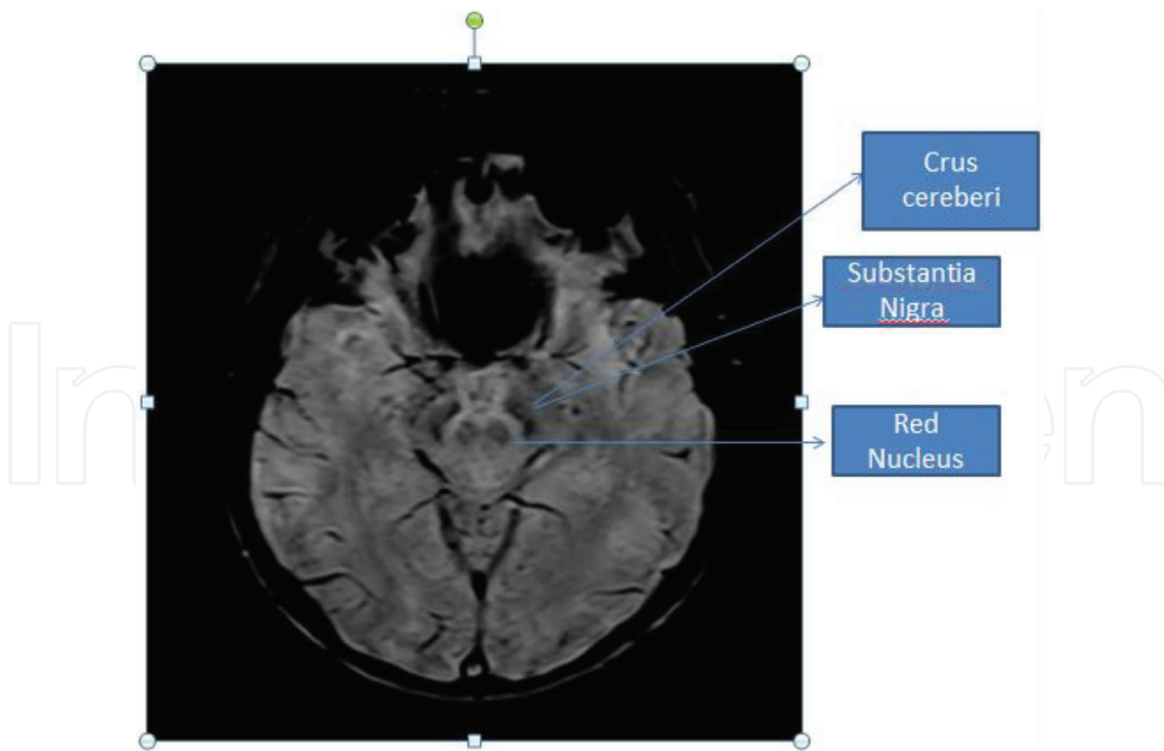


Figure 1.
 MRI anatomy of deep brain stem nuclei.

in these routine sequences. Standard MRI sequences are very helpful in excluding secondary causes of Parkinsonism like structural basal ganglia lesions like granulomas, calcification, vascular lesions, Wilsons disease/ephedrine poisoning.

With the advent of newer techniques—such as neuromelanin-sensitive MRI, T2/T2* relaxometry (quantification of iron overload), proton spectroscopy, diffusion-weighted imaging (DWI), diffusion tensor imaging (DTI), magnetization transfer imaging, susceptibility-weighted imaging, perfusion-weighted imaging, and functional MRI—the role of MRI has evolved as has its role in the differential diagnosis between Parkinson’s disease and atypical parkinsonism.

Conventional MRI scans with T1-weighted, T2-weighted, weighted, fluid-attenuated inversion recovery sequences and proton density—are usually normal in Parkinson’s disease. In Parkinson’s disease in axial T2-weighted sequences and susceptibility-weighted sequences significant thinning of the substantia nigra pars compacta diffuse cortical atrophy is noted however this imaging feature has shown high specificity, but low sensitivity and is found only in advanced stages of the disease [7].

2.3 Role of diffusion in Parkinson’s disease

In patients of Parkinson’s disease changes in water diffusion can be found in other regions of the brain even in its early stages, even when there is no significant cortical atrophy. It has been shown in studies that the fractional anisotropy is seen to be lower in the motor, premotor, and supplemental motor cortices of patients with Parkinson’s disease than that of control patients, likely due to degeneration in the corticostriatal and thalamocortical projections in the former [8].

Susceptibility-weighted imaging (SWI) uses the differences in magnetic susceptibility of tissues. By applying a gradient-recalled echo (GRE) sequence, a SW image combines a phase image with a magnitude image under high-intensity magnetic field such as 3 T and 7 T. In healthy individuals, in posterior one third of

substantia nigra a linear or comma shaped high signal intensity called Nigrosome-1 is located it shows a distinct likeness to the split tail of sparrow in patients with Parkinson's disease, the high SWI signal in nigrosome-1 is lost and the normal 'swallow tail sign' cannot be seen.

Advanced MRI sequences in high field magnets have opened the possibility of in vivo visualization of substantia nigra (SN) and has been able to investigate pathological changes specific to PD. It thus has enabled the development of high precision tools for disease diagnosis in early stages.

Early in the course of the disease and in preclinical stages there is diminution of dopaminergic neurons in the substantia nigra (SN) pars compacta (SNpc) and nor-adrenergic neurons in the locus coeruleus (LC), which is characteristic of PD [9].

Depigmentation of the SN and LC is a discernible pathological feature of PD, which results due to the loss of a melanin pigment called neuromelanin.

A Japanese group in 2006 first described the use of specific MRI sequence that allowed the visualization of neuromelanin to the study of PD patients. Authors first described a high signal on specific T1-weighted images which is related to paramagnetic properties of melanin pigment and has allowed for the first time in vivo of pathologic characteristics of PD. Neuromelanin (NM)-sensitive MR imaging is a T1-weighted fast spin-echo (FSE) sequence performed on 3.0 Tesla. NM-sensitive sequences have been successful in depicting neuromelanin signals through the use of high signal-to-noise ratio (using 3.0 T magnetic fields), the prolonged T1 relaxation time of the brain and an indirect magnetization transfer effect [10].

Quantitative measurement of volumes of various regions of the brain are done by the use of advanced MR software. Voxel-based morphometry can be applied to volumetric MRI to see significant brain volume reduction in patients of Parkinson's disease at voxel level. Patients with Parkinson's disease studied with voxel-based morphometry, significant hippocampal, thalamic, and anterior cingulate atrophy can be detected of the brain [11].

MR spectroscopy has proven to be helpful in determining the levels of different metabolites in the brain parenchyma. Spectroscopy done in the affected region of brain shows a decreased N-acetyl aspartate to creatine (NAA/Cr) ratio. Evaluation of the pons, midbrain and putamen can be done for differentiating the various subtypes [12].

Magnetization transfer imaging: Different studies in literature have shown that magnetization transfer (MT) ratios are decreased in the affected areas of the brain. Therefore measurement of MT ratios in the substantia nigra, putamen and brainstem can be very helpful not in the diagnosis of PD but also to differentiate one from the other subtypes [13].

2.4 Role of NICE guidelines in Diagnosis of Parkinson's disease

Parkinson's disease is one of the most common neurodegenerative diseases, it was first described by James Parkinson in 1817, and the disease occurs due to nigral degeneration and striatal dopamine deficiency. Parkinson's disease is clinically, characterized by motor symptoms such as stiffness, bradykinesia, resting tremor, and postural instability.

Symptoms PD do not appear until approximately 50% of the nigral dopamine (DA) neurons are lost. Expert clinical opinion is the gold-standard diagnostic technique in PD. In clinicopathological studies the sensitivity for establishing a clinical diagnosis of PD by a movement disorder specialist is reported to be as high as 91.1% in [14].

According to NICE guidelines for diagnosis of Parkinson's disease:

1.2.1 Suspect Parkinson's disease in people presenting with tremor, stiffness, slowness, balance problems and/or gait disorders [2006].

1.2.2 If Parkinson's disease is suspected, refer people quickly and untreated to a specialist with expertise in the differential diagnosis of this condition [2006, amended 2017].

2.4.1 Clinical and post-mortem diagnosis

1.2.3 Diagnose Parkinson's disease clinically, based on the UK Parkinson's Disease Society Brain Bank Clinical Diagnostic Criteria. [2006].

1.2.4 Encourage healthcare professionals to discuss with people with Parkinson's disease the possibility of donating tissue to a brain bank for diagnostic confirmation and research. [2006].

2.4.2 Review of diagnosis

1.2.5 Review the diagnosis of Parkinson's disease regularly, and reconsider it if atypical clinical features develop. (People diagnosed with Parkinson's disease should be seen at regular intervals of 6–12 months to review their diagnosis.) [2006] Single photon emission computed tomography.

1.2.6 Consider ^{123}I -FP-CIT single photon emission computed tomography (SPECT) for people with tremor if essential tremor cannot be clinically differentiated from Parkinsonism [2006, amended 2017].

1.2.7 ^{123}I -FP-CIT SPECT should be available to specialists with expertise in its use and interpretation. [2006].

2.4.3 Positron emission tomography

1.2.8 Do not use positron emission tomography (PET) in the differential diagnosis of parkinsonian syndromes, except in the context of clinical trials [2006, amended 2017].

2.4.4 Structural MRI

1.2.9 Do not use structural MRI to diagnose Parkinson's disease [2006, amended 2017].

1.2.10 Structural MRI may be considered in the differential diagnosis of other parkinsonian syndromes [2006].

2.4.5 Magnetic resonance volumetry

1.2.11. Do not use magnetic resonance volumetry in the differential diagnosis of parkinsonian syndromes, except in the context of clinical trials [2006, amended 2017].

2.4.6 Magnetic resonance spectroscopy

1.2.12. Do not use magnetic resonance spectroscopy in the differential diagnosis of parkinsonian syndromes [2006, amended 2017].

2.4.7 Acute levodopa and apomorphine challenge tests

1.2.13. Do not use acute levodopa and apomorphine challenge tests in the differential diagnosis of parkinsonian syndromes [2006, amended 2017].

2.4.8 Objective smell testing

1.2.14. Do not use objective smell testing in the differential diagnosis of parkinsonian syndromes, except in the context of clinical trials [2006, amended 2017].

2.5 Emerging role of neuroimaging

Structural and functional neuroimaging has become a valuable tool both in neuroscience research and in clinical settings. Different clinical and research applications of functional neuroimaging to Parkinson's disease (PD) have advanced over the past decade.

2.5.1 Hybrid imaging

Hybrid PET/MRI has made it possible to obtain structural (MRI) and functional (PET) information simultaneously. The advantage of PET/MRI as a single-investigation for the comprehensive evaluation of neurodegenerative disorders like PD is foreseeable. The role of PET/MRI, utilizing the F-18 florbetaben labeled stilbene derivative, a radiopharmaceutical that is developed to visualize beta-amyloid plaques in the brain in diagnosing patient's with Alzheimer's disease (AD) and is helpful in differentiating it from with Lewy body dementia (LBD) of Parkinson's disease has been reported [15].

2.5.2 Functional imaging-SPECT and PET

In PD the imaging pattern of striatal involvement for all tracers shows an asymmetric striatal decrease, which appears marked in side contralateral to the clinically affected side with a rostro-caudal gradient of uptake in this the posterior putamen is maximally affected [16].

2.5.3 Perfusion and metabolism imaging

Resting-state measurement of regional glucose utilization in the brain can be calculated by using F-18 Fluorodeoxyglucose (FDG) PET. The pattern that is specific for PD is known as 'Parkinson's disease related pattern' (PDRP), in which there is characteristic pallidothalamic and pontine hypermetabolism with hypometabolism seen in the prefrontal and parieto-occipital cortices. This pattern results from the underlying dopaminergic deficit in PD [17].

In patients with medically refractory tremors deep brain stimulation (DBS) of the motor thalamus and, the ventral intermedius nucleus (VIM), was first used in 1986 [18]. In Parkinson's disease, DBS of the internal globus pallidus (GPi) and the subthalamic nucleus (STN) were found to be safe and effective.

At present subthalamic nucleus (STN) is the main target nucleus for DBS in PD. Symptoms like rigidity, tremor akinesia and postural instability, that usually respond well to levodopa can be effectively treated by subthalamic nucleus (STN) DBS. Studies have shown that best outcome might be achieved by stimulation of the dorsolateral motor part of the STN. DBS should usually be performed bilaterally to relieve motor symptoms on both sides that allows for optimal reduction of medication.

In our institution we had diagnosed cases of Parkinson's disease who underwent deep brain stimulation and they responded very well and there was significant reduction in motor symptoms of the patients.

3. Insight in brain activation studies for motor functions

This is an overview of brain activation studies which describes findings that help in our understanding of the pathophysiology of motor, cognitive, and behavioral symptoms seen in Parkinson's disease PD and the underlying neuronal changes. Activation studies of PD patients have been utilized to see the basal-ganglia-thalamocortical circuit function. Several types of motor tasks have been used in conjunction with different neuroimaging techniques to study the motor circuit in PD.

Most common tests included the repetitive tasks, involving either of these two, one was repeated thumb to other finger opposition movements second was manipulation of a joystick in different directions. When normal subjects did repetitive right-hand joystick movements in different directions while they underwent [^{15}O]H $_2$ O PET, an increase in regional cerebral blood flow (rCBF) was noted in the contralateral primary sensorimotor cortex and lentiform nucleus. Activation was also noted in the bilateral anterior cingulate gyrus, supplementary motor area (SMA), lateral premotor cortex, and dorsolateral prefrontal cortex. Opposite to that, PD patients showed a more complex activation pattern, which showed impaired rCBF changes in the lentiform nucleus, anterior cingulate gyrus, SMA, and dorsolateral prefrontal cortex. However normal activation was seen at the level of sensorimotor cortex, lateral, and parietal premotor cortex when compared with healthy controls [19].

The pattern of activation in PD varies significantly depending upon the stage of the disease, use of medication, and the type of motor task. In 1997 Samuel et al. hypothesized that nigrostriatal dopaminergic degeneration leads to hypoactivation of a mesial premotor system (SMA, anterior cingulate gyrus, and dorsolateral prefrontal cortex), frequently involved in self-paced movements.

The activation of the SMA was markedly improved when akinesia was reversed with apomorphine [19], rCBF was measured in PD patients at rest and when they performed joystick movements with the right hand in one of four freely chosen directions. All such patients were studied before and after treatment, in off state, and when "on" with apomorphine. It was seen that under resting conditions apomorphine had no effect on CBF, while significant activation of the SMA was observed while using the joystick with apomorphine.

The same group was also able to demonstrate that activation of the SMA significantly improved when akinesia was reversed with apomorphine [19]. In particular, rCBF was measured in PD patients at rest and when performing paced joystick movements with the right hand in one of four freely chosen directions. All patients were studied before treatment, in an off state, and when "on" with apomorphine. Under resting conditions apomorphine had no effect on CBF, while significant activation of the SMA was observed while using the joystick with apomorphine [20].

Studies in the past few years have suggested that chronic electrical stimulation of the primary motor cortex (MCS) may alleviate motor symptoms of PD. This new approach can be viewed as another alternative approach for PD patients who are not ideal candidates for DBS of these subthalamic nuclei (STN). A study was conducted by Strafella et al. to understand the cortical and subcortical effects of MCS. Interestingly, they found that MCS at 50 and 130 Hz did not produce significant changes in joystick motor performance or rCBF at cortical or subcortical levels. Therefore they concluded that while MCS was although a simpler and safer surgical procedure than DBS of the STN, it was not able to modify the pattern of movement related rCBF activation in PD patients [21, 22].

In conclusion, brain activation studies have been able to show the pathophysiology of PD and the neurobiological foundation of its motor, cognitive, and behavioral manifestations.

4. An overview of the current clinical evidence for morphological changes in the brain associated with symptoms (i.e. motor symptoms) and potential associated neural mechanisms

Parkinson's disease (PD) is characteristically shown to have motor symptoms including resting tremor, rigidity, and bradykinesia but cognitive and behavioral problems in PD are more common and they have a direct effect on the quality of life.

The estimated prevalence of dementia in patients with PD ranges between 24 and 31% has conservatively been estimated to range between 24 and 31%. Cognitive function in PD patients with dementia (PDD) is significantly different than that of the cortical dementia of Alzheimer's disease (AD). Patients with PDD often exhibit difficulties with executive functions, the retrieval aspects of memory, and visuo-spatial skills [23].

Patients with PDD often show a typical pattern of cognitive decline which shows characteristically a subcortical dementia that can be differentiated from AD in which cortical areas are affected early in the disease process and often include clear aphasia, apraxia, or agnosia. Dementia in PD is gradual in onset, and it is typically exhibited years after the onset of motor symptoms.

There is a difference between the pathophysiology of cognitive symptoms in PD and the pathophysiology of motor symptoms as well. Various factors have been implicated in the mechanism of disease process these, include dopamine depletion in the striatum and, to a lesser degree, in the prefrontal cortex. Due to disruption of dopamine levels at either site may there is resultant frontal-like deficits either directly or via downstream effects in striatal-pallidal-thalamocortical loops (CSPTC) [24].

Evidence has shown widespread cortical cholinergic dysfunction to be factor of cognitive decline in PD. Adrenergic and serotonergic deficits have also been described in PD but they have been associated with behavioral rather than cognitive function. Regional cortical Lewy body formation, have also been implicated in cognitive decline in PD.

Antiparkinsonian therapy either surgical or medical has shown heterogeneous effects on cognitive functioning. Neuroimaging and behavioral studies in PD patients as well as experimental models have associated this heterogeneity to (i) task-specific differences in regional activation responses, (ii) differences in the location/degree of dopaminergic denervation which in turn depends on the stage of disease progression, (iii) baseline genetic features such as the COMT genotype, and (iv) on individual treatment status [25].

In short, neuroimaging studies have contributed significantly to the current understanding of cognitive functioning in PD, therefore because of the high variability seen in the time course of cognitive decline with advancing disease, and in cognitive response to antiparkinsonian treatment, further research and work are warranted.

5. Conclusion

PD is now a common neurodegenerative disease. A combination of genetic and environmental factors are likely cause leading to cell dysfunction and then death. The diagnosis is essentially clinical, and there should be a high index of suspicion to exclude other causes of Parkinsonism. A large number of investigation tools together with surgical interventions are now available to treat early and late complications of PD. Increasing consideration is being given to the diagnosis and treatment in PD.

Conflict of interest

There are no conflict of interest.

Notes/Thanks/Other declarations

Nil.

Author details

Roohi Mohammad and Fatima Mubarak*
Aga Khan University Hospital, Karachi, Pakistan

*Address all correspondence to: fatima.mubarak@aku.edu

IntechOpen

© 2019 The Author(s). Licensee IntechOpen. This chapter is distributed under the terms of the Creative Commons Attribution License (<http://creativecommons.org/licenses/by/3.0>), which permits unrestricted use, distribution, and reproduction in any medium, provided the original work is properly cited. 

References

- [1] Mutch WJ, Dingwall-Fordyce I, Downie AW, et al. Parkinson's disease in a Scottish City. *BMJ*. 1986;**292**:534-536
- [2] National Institute for Health and Clinical Excellence. Guideline development methods: Information for national collaborating centres and guideline developers. London: National Institute for Health and Clinical Excellence; 2004. Ref ID: 20114
- [3] Vymazal J, Righini A, Brooks RA, et al. T1 and T2 in the brain of healthy subjects, patients with Parkinson disease, and patients with multiple system atrophy: Relation to iron content. *Radiology*. 1999;**211**:489-495
- [4] McKeith I. Dementia with Lewy bodies and parkinson's disease with dementia: Where two worlds collide. *Practical Neurology*. 2007;**7**:374-382
- [5] Benazzouz A, Breit S, Koudsie A, et al. Intraoperative microrecordings of the subthalamic nucleus in Parkinson's disease. *Movement Disorders*. 2002;**17**:S145-S149
- [6] Laruelle M. Imaging synaptic neurotransmission with in vivo binding competition techniques: A critical review. *Journal of Cerebral Blood Flow and Metabolism*. 2000;**20**:423-451
- [7] Meijer FJ, Goraj B. Brain MRI in Parkinson's disease. *Frontiers in Bioscience (Elite Edition)*. 2014;**6**:360-369
- [8] Zhan W, Kang GA, Glass GA, et al. Regional alterations of brain microstructure in Parkinson's disease using diffusion tensor imaging. *Movement Disorders*. 2012;**27**:90-97
- [9] Mann DM, Yates PO. Pathological basis for neurotransmitter changes in Parkinson's disease. *Neuropathology and Applied Neurobiology*. 1983;**9**:3-19
- [10] Sasaki M, Shibata E, Tohyama K, et al. Neuromelanin magnetic resonance imaging of locus coeruleus and substantia nigra in Parkinson's disease. *Neuroreport*. 2006;**17**:1215-1218
- [11] Summerfield C¹, Junqué C, Tolosa E, Salgado-Pineda P, Gómez-Ansón B, Martí MJ, Pastor P, Ramírez-Ruiz B, Mercader J. Structural brain changes in Parkinson disease with dementia: Avoxel-based morphometry study. *Archives of Neurology*. 2005 Feb;**62**(2):281-285
- [12] Seppi K, Schocke MF. An update on conventional and advanced magnetic resonance imaging techniques in the differential diagnosis of neurodegenerative parkinsonism. *Current Opinion in Neurology*. 2005;**18**:370-375
- [13] Seppi K, Poewe W. Brain magnetic resonance imaging techniques in the diagnosis of parkinsonian syndromes. *Neuroimaging Clinics of North America*. 2010;**20**:29-55
- [14] Hughes AJ, Daniel SE, Shlomo YB, Lees AJ. The accuracy of diagnosis of parkinsonian syndromes in a specialist movement disorder service. *Brain*. 2002;**125**:861-870
- [15] Werner P, Barthel H, Drezetzga A, Sabri O. Current status and future role of brain PET/MRI in clinical and research settings. *European Journal of Nuclear Medicine and Molecular Imaging*. 2015;**42**:512-516
- [16] Brooks DJ, Ibanez V, Sawle GV, Quinn N, Lees AJ, Mathias CJ, et al. Differing patterns of striatal F-18-dopa uptake in Parkinsons disease, multiple system atrophy and progressive supranuclear palsy. *Annals of Neurology*. 1990;**28**:547-545
- [17] Hirano S, Eckert T, Flanagan T, Eidelberg D. Metabolic networks for

assessment of therapy and diagnosis in Parkinson's disease. *Movement Disorders*. 2009;**24**:S725-SS31

[18] Benabid AL, Pollak P, Louveau A, Henry S, de Rougemont J. Combined (thalamotomy and stimulation) stereotactic surgery of the VIM thalamic nucleus for bilateral Parkinson disease. *Applied Neurophysiology*. 1987;**50**(1-6):344-346

[19] Playford ED, Jenkins IH, Passingham RE, Nutt J, Frackowiak RS, Brooks DJ. Impaired mesial frontal and putamen activation in Parkinson's disease: A positron emission tomography study. *Annals of Neurology*. 1992;**32**(2):151-161

[20] Jenkins IH, Fernandez W, Playford ED, Lees AJ, Frackowiak RS, Passingham RE, et al. Impaired activation of the supplementary motor area in Parkinson's disease is reversed when akinesia is treated with apomorphine. *Annals of Neurology*. 1992;**32**(6):749-757

[21] Canavero S, Paolotti R, Bonicalzi V, Castellano G, Greco-Crasto S, Rizzo L, et al. Extradural motor cortex stimulation for advanced Parkinson disease. Report of two cases. *Journal of Neurosurgery*. 2002;**97**(5):1208-1211

[22] Strafella AP, Agha AD, Sadikot AF. Cerebral blood flow changes induced by subthalamic stimulation in Parkinson's disease. *Neurology*. 2003;**60**(6):1039-1042

[23] Aarsland D, Larsen JP, Karlsen K, Lim NG, Tandberg E. Mental symptoms in Parkinson's disease are important contributors to caregiver distress. *International Journal of Geriatric Psychiatry*. 1999;**14**:866-874

[24] Scatton B, Javoy-Agid F, Rouquier L, Dubois B, Agid Y. Reduction of cortical dopamine, noradrenaline, serotonin and their metabolites in Parkinson's disease. *Brain Research*. 1983;**275**:321-328

[25] Cools R, Stefanova E, Barker RA, Robbins TW, Owen AM. Dopaminergic modulation of high-level cognition in Parkinson's disease: The role of the prefrontal cortex revealed by PET. *Brain*. 2002;**125**:584-594