

We are IntechOpen, the world's leading publisher of Open Access books Built by scientists, for scientists

6,900

Open access books available

185,000

International authors and editors

200M

Downloads

Our authors are among the

154

Countries delivered to

TOP 1%

most cited scientists

12.2%

Contributors from top 500 universities



WEB OF SCIENCE™

Selection of our books indexed in the Book Citation Index
in Web of Science™ Core Collection (BKCI)

Interested in publishing with us?
Contact book.department@intechopen.com

Numbers displayed above are based on latest data collected.
For more information visit www.intechopen.com



Perihilar or (Hilar) Cholangiocarcinoma: Interventional to Surgical Management

Pankaj Prasoon, Kohei Miura, Kizuki Yuza, Yuki Hirose, Jun Sakata and Toshifumi Wakai

Abstract

Peri-hilar cholangiocarcinoma (PHC) or hilar cholangiocarcinoma (HCCA) characterizes a critical effort to assess significantly sick patients. The existing scenery and proof to the diagnosis and treatments for hilar cholangiocarcinoma are improving day by day. Patients with HCCA encounter numerous obstacles in acquiring efficient therapies. The condition is uncommon, and the majority patients don't have any distinct risk factors, doing selection process inadequate. The initial signs and symptoms in many cases are non-specific, and in many patients the tumors are not resectable because of involvement of the perihilar structures. MRI with MRCP offers further information about the extent of biliary involvement. Furthermore, endoscopic stenting and percutaneous drain could be useful for intricate hilar strictures. Surgical resections with negative margins are related to good likelihood of survival for patients representing with HCCA. Regardless of the accessibility of curative treatment strategies such as operative resection and liver transplantation, most sufferers with HCCA shows with repeated, metastases or locally advanced disease with a poor prognosis. Within this chapter, we have tried to elaborate the modalities of treatment from intervention to surgical approach for HCCA.

Keywords: perihilar cholangiocarcinoma (PHC), hilar cholangiocarcinoma (HCCA), biliary drainage (BD), magnetic resonance cholangiopancreatography (MRCP), surgical resection, magnetic resonance imaging (MRI)

1. Introduction

Perihilar cholangiocarcinoma (PHC) is the typical tumor also referred as Klatskin tumor, is liable for nearly 60% of biliary tract cholangiocarcinoma [1]. These types of tumors develop through the biliary tract epithelium and may even appear in entire intra hepatic biliary duct. It could be subdivided on the basis of their location for instance, intrahepatic, perihilar and distal HCCA [1]. These types of malignancy commence within the extrahepatic bile duct proximal to the origin of the cystic duct. PHC is typically alienated based on Bismuth-Corlette classification in accordance with the proximal magnitude of the tumor into the biliary tract [2].

HCCA incorporates a very poor prognosis, and surgical treatment continues to be the only preventive alternatives. Nevertheless, very few patients are determined in a treatable phase, and palliative remedies are, consequently, necessary. Endoscopy has a beneficial role while in the investigation of the patients with HCCA who definitely are not fit for surgical treatment. Primary sclerosing cholangitis (PSC) is regarded as the prevalent risk factor for PHC in European nations and about 8–40% sufferers acquire this type of malignancy [3]. Hepatobiliary flukes, together with *Clonorchis sinensis* and *Opisthorchis viverrini*, are the risk issues for cholangiocarcinoma in southeast Asian continent [4]. Additional acknowledged risk factors for cholangiocarcinoma are intra-hepatic stones, biliary abnormalities such as Caroli disease, HCV infection, liver cirrhosis and acquaintance to thorium-containing contrast media [5, 6]. Cholangiocarcinoma affects more commonly in men than women, and the Asians are having higher incidence nearly twice over whites and blacks [7].

HCCA frequently reveals an increasingly gradual pattern than intrahepatic cholangiocarcinomas, through which slower tumor progression is ultimately shadowed by permeation of the perihilar region, adenopathy and direct liver invasion. The caudate lobe is generally intricate as a result of additionally direct or ductal invasion [8]. Distant metastasis through the lymphatic system can also take place [9]. The differential diagnosis incorporates benign strictures, including all those attributable to PSC, Mirizzi syndrome, HIV cholangiopathy and postoperative bile duct injuries. Additionally, other tumors, together with lymphoma, can imitate hilar cholangiocarcinoma [9]. The most prevalent clinical manifestation of HCCA is uncomplicated obstructive jaundice. Nevertheless, not all patients having a speculated hilar stricture could have cholangiocarcinoma [10].

Despite the fact that there is dispute in regards to the aftereffect of preoperative biliary decompression on operative consequence in sufferers with malignant biliary blockages, many experts have stated that liver dysfunction attributable to obstructive jaundice might be a considerable risk factor in significant hepatectomy [11–13].

Specifically, when it comes to perihilar cholangiocarcinoma, extended hepatectomy is usually necessary to offer the most effective possibility of treatment. It is actually preferable to conduct preoperative biliary drainage (PBD) for the future remnant liver (FRL) to maintain postoperative liver functionality. Additionally, selective cholangiography by having a PBD catheter generally offers much more specific information regarding the tumor level across the biliary duct [14].

Nevertheless, disputes remain to be around the best way to accomplish PBD in patients with perihilar PHC. There are numerous disagreements within the clinical benefits of percutaneous transhepatic biliary drainage (PTBD) compared to endoscopic biliary drainage (EBD), stated before that may be affected by either (ERBD) endoscopic retrograde biliary drainage or (ENBD) endoscopic nasobiliary drainage. PTBD have been the most favored method for preliminary PBD [15, 16]. Actually, while contemplating PBD it is mandatory to bear in mind about the perils associated with cholangitis, extended pre-operative stay in the hospital, failing to boost the nutritional state and higher post-operative additional complications [17, 18].

2. Preoperative biliary drainage (PBD)

HCCA is usually a tumor of the extrahepatic bile duct relating to the left and right main hepatic duct or their confluence. Biliary drainage in HCCA is oftentimes technically difficult as a consequence of difficulties linked to the degree of biliary obstruction. This could lead to some unfavorable situations, particularly in acute

cholangitis. Therefore, the conclusion on the indication and techniques of biliary drainage in patients with HCCA ought to be meticulously assessed [17]. PBD might have additional advantages in selected patients with the extreme lack of nutrition or biliary sepsis as well as in individuals considering the postponed surgical procedure depending upon on (PVE) portal vein embolization or chemo-radio therapy [19]. Furthermore, cholangiography attained by PTBD or ENBD can offer much more specific information relating to the complex segmental anatomy with the intrahepatic bile ducts and also the extent of cancer across the segregated biliary ducts [17].

So far, the ideal serum bilirubin level for surgical treatment has not yet been established. Moreover, the suitable time period of PBD hasn't been evidently established. Extended use of biliary drainage would raise the potential risk of drainage malfunction, tract seeding, and additional inflammatory alterations towards the bile duct.

Even though biliary drainage varies concerning proximal and distal biliary obstructions, most scientific studies reviewed the different degrees of biliary obstruction being a solitary entity [20].

2.1 Percutaneous transhepatic biliary drainage (PTBD)

The potential advantages of preoperative biliary drainage consist of its possible ways to converse with cholestasis-associated hepatic and synthetic ferocity along with improvement of the nutritional status of the body and boosting the immune function [21–23]. The use of multiple catheters along with the contrast agent in PTBD procedure offers drainage of the liver and enables far additional accurate description of the tumor, and could produce added exploratory advantages through surgical observation of the liver hilum [16, 24]. It has been specifically learned that the reintervention rate or even an alternate drainage technique, is commonly reduced PTBD technique when compared to EBD [24, 25]. Kim et al. [22] witnessed a minimal alteration proportion in the PTBD group compared to the EBD group, consistent with other preceding research. Alteration to PTBD within the EBD group was as a result of issues induced by EBD and failure to attain adequate decompression for the FRL. Cholangitis, which is probably the additional complications that may take place following PBD, is really a distinctive dilemma that frequently necessitates reintervention [22]. There could possibly be feasible clarification in EBD group with an increased rate of conversion compared to the PTBD group. Certainly, cholangitis could be the major side-effect of post-ERCP in patients with PHC, as contrast medium is injected into the biliary tract to delineate the tumor that could not subsequently be drained and further it could aggravate the cholangitis.

Regardless of the several advantages of PTBD being a preoperative biliary drainage method, it offers one particular terrific weak point; the potential of cancers dissemination alongside catheter tract. It is really an unalterable event contrary to other additional complications for instance cholangitis, bleeding, and pancreatitis. According to Hwang et al. [26]; 231 patients of PHC gone through PTBD preoperatively revealed that; 4 patients or 1.7% patients encountered recurrence along with the PTBD tract on an average of 13.5 months following surgical procedure. Takahashi et al. [27], described in the patients with PHC and distal cholangiocarcinoma who undergone resection following PTBD, he witnessed recurrence within the PTBD catheter tract in 23 (5.2%) of 445 patients. The authors recommended that likelihood of PTBD tract recurrence could possibly be underrated due to the fact even though metastatic deposits could progress at any site, earlier recognition of recurrence catheter piercing site location for example the skin, abdominal wall, and liver parenchyma, is actually difficult to assess [27]. In the research of

Kim [22] et al., there were 52 patients who went through surgical resection within the PTBD group, two patients (3.8%) got catheter tract site metastasis during the follow-up period. They demonstrated a relatively brief mean time to recurrence as opposed to other 28 patients who encountered tumor recurrence within the PTBD group devoid of catheter tract metastasis (10.5 months vs. 16 months). Preceding researchers have pondered that several catheters drain along with an extended time-span PTBD techniques are probable risk components for catheter tract recurrence [27].

Conferring to Kim et al. [22]; EBD was linked with a higher likelihood of technique associated issues for instance cholangitis and pancreatitis compared to PTBD, understanding that PTBD was linked to a lot fewer complications than EBD, providing a significantly reduced regularity of reintervention following PTBD. On the other hand, these issues were being conveniently handled devoid of intense morbidity in many instances. While the other study outcomes recommend that there might be an edge to utilizing ENBD instead of ERBD for biliary decompression for the FRL. During initial PBD in patients with resectable PHC. PTBD might be of interest the following best alternate when ENBD just isn't attainable or inadequate for biliary decompression as a result of authentic, even though minimal risk of fatal catheter tract metastasis [27].

PTBD allows for accurate lobar selection coupled with lowering the potential risk of unveiling the biliary tree to duodenal contents. This might conceptually enhance the achievement's biliary drainage and prevent cholangitis [28]. Accomplishment of PTBD necessitates slight sedation, hereafter achievable even in unstable or comorbid patients who cannot endure anesthesia [29]. Conversely, PTBD is associated to discomfort and pain to the skin piercing site. Occasionally, PTBD really should be followed up by internalization of stent that might be related to increased infection and bleeding issues [29, 30].

Percutaneous self-expandable metallic stents; could probably be carefully chosen for preparatory biliary drainage in patients with advanced type III or IV hilar cholangiocarcinoma, provided that increased preliminary efficacy and minimal degree of procedure-related cholangitis [31, 32].

Within a recent meta-analysis, it's been demonstrated that PTBD group has considerably greater drainage results when compared with EBD group. Patients who experienced PTBD had comparatively fewer cholangitis attacks; nevertheless, there wasn't any significant difference in pancreatitis and over-all complications within both groups. Fatality rate within 30 days was equivalent within both groups; this might be apt to be as a result of hidden characteristics of the disease by itself. PTBD group, on the other hand, experienced greater post procedure hemorrhage. This may be due to the second step with the PTBD tactic in certain individuals who requires internalization of the stent [33]. Although, PTBD appears allied with substantial postoperative morbidity, additional prospective research is needed in order to determine the suitable method of biliary drainage in PHC [34, 35]. Moreover, PTBD could be challenging as it may cause (PVT) portal vein thrombosis as well it may cause tract related seeding of tumor that could alter operative measures of the tumor [36, 37]. According to latest study [37]; they have stated that PTBD enhances the likelihood of seeding metastasis and reduces the length of the postoperative survival in patients with PHC. Endoscopic biliary drainage is usually recommended because the optimum solution to preoperative biliary drainage [37].

The suitable drainage strategy is still contentious topic, wherein specialists are likely to prefer the percutaneous method with the explanations of straight approachability to bile duct and utilization of the intraluminal drains postoperatively and throughout the hepaticojejunostomy [38].

2.2 Endoscopic retrograde biliary drainage (ERBD) or endoscopic nasobiliary drainage (ENBD)

Furthermore, tumor encasement of portal vessels and bile ducts can result in segmental or lobar atrophy in PHC (**Figure 1**). In patients with PHC, liver resection or lobes can be determined by MDCT (**Figure 2**), and biliary decompression to relieve cholestasis for the FRL [39].

ERBD has some positive aspects of being more physiologic, improves nutrition, decreases endotoxemia, stabilizes lipid alterations, and boosts the immune system capabilities [40]. ENBD is the endorsed approach in several parts of Asia. As with PTBD, it offers much more specific information about the extent of tumor over the biliary ducts [14]. Some authors described fewer difficulties and an extraordinary accomplishment rate of ENBD equated to EBD [25, 41]. Unilateral ENBD into the future remnant lobe(s) demonstrated a higher rate of success, recommending that it must be an efficient and appropriate preoperative drainage means for perihilar cholangiocarcinoma even just in sufferers with B-C type III to IV tumors. At our institute we commonly perform ENBD for pre-operative biliary drainage (**Figure 3**). To scale back the postprocedural issues, ENBD really should be carried out without having EST or pancreatography [41]. The ENBD of HCCA is usually very complicated and sophisticated. ERBD has got the disadvantage of further complicating the intraoperative assessment of the longitudinal tumor expansion and postponing the surgical procedure [24, 42].

Not too long ago, it has been established that ENBD may be the treatment of preference and PTBD could be the second choice. ENBD might be unpleasant, as a result of the nasal catheter, as compared with endoscopic retrograde biliary drainage, utilizing a plastic-type material or expanding metallic stent [41].

Even though we could keep track of real-time bile output in patients with ENBD, earlier recognition of catheter issues regarding the catheter insertion or malfunction with the drainage catheter, for instance blockage or dislocation, is achievable and catheter complication become evident with time-lag offering with segmental cholangitis. Continual jaundice or decline of clinical parameters regarding liver function or systemic inflammation may occur in patients with ERBD [43]. In patients with Bismuth

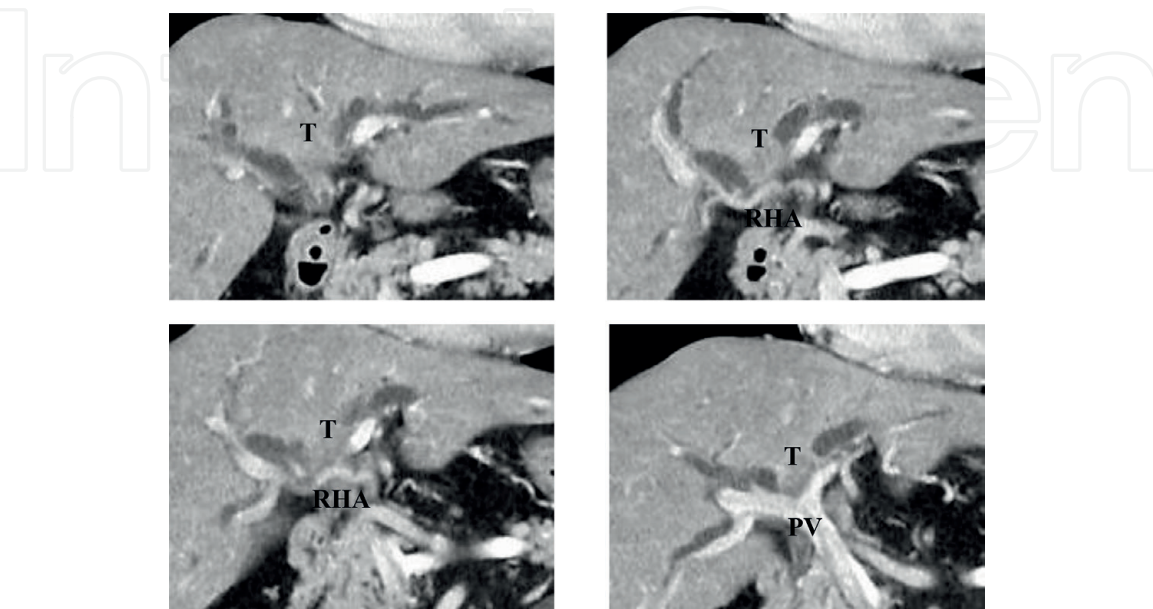


Figure 1.
Abdominal contrast CT examination findings of left sided Bismuth IV type perihilar cholangiocarcinoma.
T: tumor, RHA: right hepatic artery, PV: portal vein.

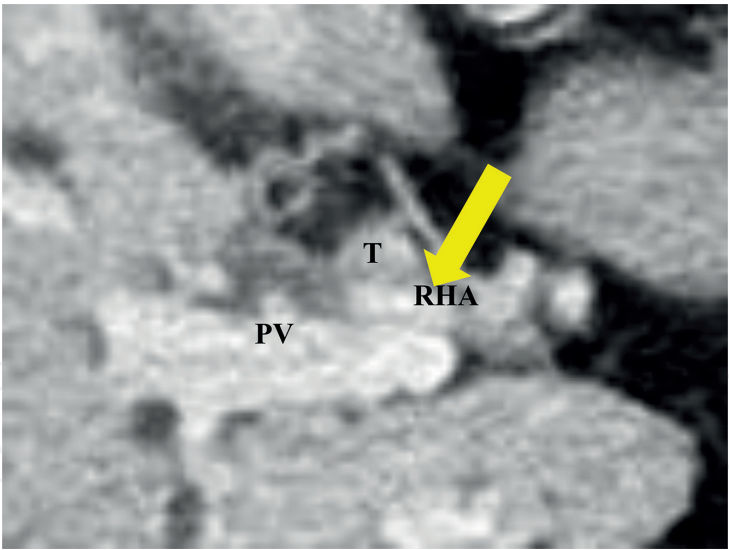


Figure 2.
Abdominal contrast CT showed invasion into the right hepatic artery (yellow arrow) was suspected.

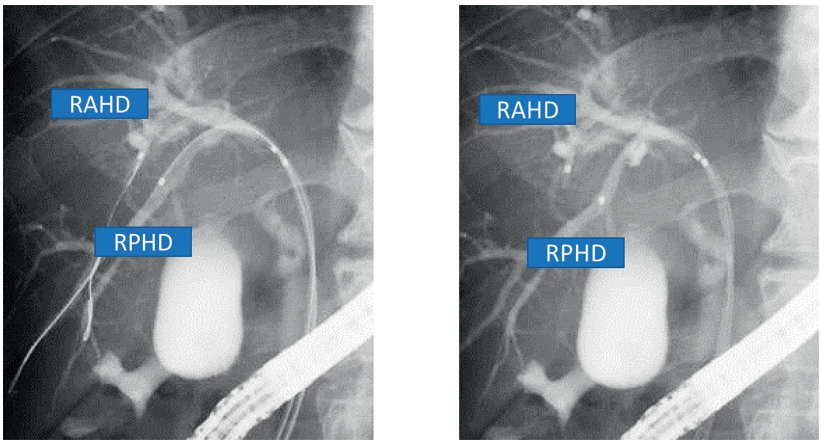


Figure 3.
Biliary imaging (ERCP) findings showed tumor invasion to the junction of the RAHD (right anterior hepatic duct) and RPHD right posterior hepatic duct (Bismuth-type IV). Insertion of ENBD tubes into anterior and posterior intrahepatic bile ducts.

type I and II HCCA, it is a popular opinion that endoscopic biliary drainage (EBD) is preferred over PTBD as it is rapid and moderately minimal invasive procedure [41].

Nevertheless, in patients with advanced and unopenable hilar malignancies including Bismuth types III and IV, it is indistinct if one method is superior to the other. Research have shown mixed results equating both these approaches [24, 31, 44–47]. In case of Bismuth type III and IV HCCA [48], numerous occasion of biliary decompression and drainage are needed. Even though several or bilateral ENBD is competent and carried out in certain determined conditions, three or more stenting only with regards to an endoscopic approach might be challenging to sustain adequate biliary drainage [39].

Cherqui et al. revealed the operative outcomes of 20 biliary cancer sufferers who gone through major hepatobiliary resection devoid of preoperative biliary drainage; the postoperative morbidity was substantially greater within the jaundiced patients, as the liver failure rate was 5% postoperatively, and fatality rate was recorded within the identical scenarios [49]. Besides PTBD, ERBD works extremely well as the preliminary treatment approach to strengthen obstructive jaundice in patients with unresectable HCCA if there’s an extended time period of drainage patency following an effective drainage [44].

A latest multi intuitional retrospective analysis from Japan revealed that there are not considerable benefits of ENBD over EBS because the preliminary PBD for resectable hilar malignant biliary obstruction. On the other hand, the technical rate of success of preoperative ENBD was higher. Its re-intervention rate had not been diminutive and unexpected re-intervention was confederated with a poor prognosis in resected hilar biliary obstruction [50]. Authors quoted that [50]; ENBD for hilar biliary obstruction currently requires re-interventions, equally in the planned and unexpected way. It would need additional research in order to strengthen safety and efficiency of ENBD in those patients.

3. Portal vein embolization (PVE)

PVE and PBD are the two commonly used approaches to improve the FLR while preparing of major hepatectomy. According to our point of view ipsilateral portal vein occlusion along with the tumor with it could result in contralateral lobe hypertrophy. Preoperative PVE is actually performed to review the episode while planning for surgical procedure. In the event, FRL is not adequate for resection, PVE could be the conventional interposition to improve the volume of the FRL. Any local hemodynamic alterations could cause discharge of a varieties of growth factors and interleukins and that could possibly cause the hypertrophy of nonembolized hepatic lobe.

Within a CT volumetric review pre-operative PVE commonly offers somewhere around 10% of volume improvement in the FRL in contrast to 10% volume reduction in the embolized liver to get resected 2 weeks following PVE [51, 52]. Another study with PHC patients revealed that the FRL volume of less than 40% and liver function lesser than $2.7\%/min/m^2$ is the cutoff point for proceeding with PVE [38]. There is no need of biliary drainage within the embolized lobe without cholangitis, considering that there actually has a synergistic impact with unilateral cholestasis on the hypertrophy response on the non-embolized lobe. Over 3 weeks, following PVE, CT volumetric analysis and HBS should be replicated and reevaluated. Research showed that functional enhancement takes place more quickly than the volume level, implying that a reduced waiting time right up until resection can be done [53]. Within the series by Nagoya group from Japan revealed that PVE may enhance the operative outcomes of PHC [54]. PVE is recognized as a secure technique by having 2.2% of morbidity rate. Most commonly encountered complications are hemobilia, hematoma, septicemia, embolization material dislodgement and could consequently leads to thrombosis within the FRL [55].

Olthof et al. [56]; appraised the occurrence of postoperative liver failure in a collective succession of two European centers focused in PHC. They have recommended the risk score for PVE based upon FRL volume. It was coupled with jaundice at presentation, preoperative cholangitis and preoperative bilirubin level $> 50 \mu\text{mol/L}$ [56]. PVE preceding to hepatectomy enables resection in the sufferer to advanced primary hepatobiliary tumors and insufficient FLR, with higher long-term survival [57]. Faster tumor development owing to PVE does not appear to impact the endurance to PHC patients [57, 58]. PVE, nonetheless, determine the resection of lobe and whenever newest findings that could need to have an alteration of approach, this can't be changed. During the waiting period if disease advancement occurs and inoperability ensues by the atrophy-hypertrophy reaction balances, extensive liver volume and its overall performance continued to be unaffected [38].

Having said that, the endurance with the atrophied, contaminated liver lobe might be associated with unwanted side-effects. For instance, liver abscess may

further complicate the palliative management of the sufferer who commonly requires the repetitive procedures with stents [59]. Further embolization of (quadrate lobe) while preparing of extended right hemi hepatectomy is undoubtedly an alternative with regards to the targeted increment of FRL volume should be achieved. As a consequence, the left portal vein to quadrate lobes is occluded together with embolization of the right portal system. The strategy is complicated and needs a highly skilled interventional radiologist given that accessibility to left portal venous system can provide further injury risk. Backflow and dislodgement of embolization material in the left venous system may result in thrombosis in the portal veins offering the FRL. Additionally, to diminish these hazards, partially embolization of just segment 4a can be carried out [55, 60].

4. Surgical resection

Surgery provides the only opportunity of remedy in affected individuals with PHC. Surgical resection is depending upon the anatomical position and tumor and corresponding vessels and bile duct within the hepatic duct confluence. The operative consequences continue to be inadequate as a result of maximum recurrence [61]. The purposes of surgical procedures for PHC are to attain an R0 resection coupled with regional lymph nodes resection. Most often extrahepatic biliary duct resection with extended hepatectomy is mandatory based on the tumor location and its proximal extension on the segmental biliary ducts. In PHC, most often concomitant vascular resections and reconstruction are needed in order to achieve the negative margin. Our latest research implies that count of positive lymph nodes much better anticipates survival following surgical resection compared to lymph node resection in extrahepatic cholangiocarcinoma, given that lymph node assessment is enough [62]. Substantial number of lymph nodes, resection is justified for appropriate staging of nodal ailment. We firmly assume that comprehensive localized lymphadenectomy definitely seems to be required for effective resection of extrahepatic cholangiocarcinoma [62].

As the tumor ordinarily triggers biliary obstruction that is why hepatectomy in PHC is related to have high postoperative morbidity. PBD can be cast-off to generate a less hazardous setting in advance of surgical procedures, but biliary drainage might be detrimental when extreme drainage-related complications worsen the patients' condition or enhance the potential risk of postoperative morbidity [35].

Surgical resection is definitely the only possible curative remedy for HCCA; Bile duct resection in conjunction with significant hepatectomy could be the conventional treatment for HCCA. This treatment technique accomplishes an increased cure rate compared to that with bile duct resection alone [63]. While witnessing and assessing imaging reports, it is very imperative to comprehend three-dimensional fashion of the tumor locations and vascular and biliary involvement. The tumor expands across the left and right biliary ducts or in anterior and posterior course into the S4 or S1, correspondingly [38].

The Japanese institutes from the Nagoya were being the first one to demonstrate within the early 90s, that the intense strategy ended in much better long-term survival. The outcomes demonstrate that extreme surgical procedure of HCCA provides excellent consequences by having an adequate fatality rate [64]. Nevertheless, pursuing these guidelines, radical resection consists of hepatectomy or extended hemihepatectomy together with S4 and also the caudate lobe. Complete lymphadenectomy along with hepatoduodenal ligament and excision of the portal vein bifurcation should be done whenever required [65]. Approaches to optimize liver function as well as minimize removing functional liver parenchyma was connected

with a reduction in fatality rate (7%) although an endeavor extended resection for HCCA by having an R0 resection rate of 92% [65].

Pathological study of the biliary ducts is carried out to substantiate radicality within the ductal level. The level of biliary resection could be expanded in the event of existence residual tumor in the resection margin. Survival was even worse within those patients as compared to the patient that had a preliminary free margin [66].

However, the segment one bile ducts typically drain within the left hepatic duct. Nevertheless, it could drain into any section of the hepatic duct confluence. These ducts are likely to be intricate by tumor concomitantly. Since 1998, authors routinely performing S1 resection en bloc coupled with extended hemihepatectomy and their results showed the substantial rates of R0 resections, and having an enhanced survival rate [67].

First of all, there is close proximity of the location of the biliary confluence and hepatoduodenal ligament in such circumstances the right sided liver resection enables additional comprehensive tumor margin. Quite often the right sided hepatic duct is normally shorter or lesser than 1 cm in length. In few instances it is missing in case existence of three confluences within the hepatic ducts. However, the left sided hepatic duct has a comparatively long and conventional course until attaining the left portal vein and splitting off into segments two and three hepatic ducts [68].

Consequently, malignancies that occupy the right intrahepatic ducts and perhaps the segment 4 in case of Bismuth-Corlette type IIIa-IV tumors. In such instances extended right hemihepatectomy should be considered. The potential drawback of such procedure is that segment two and three, are minor and quite smaller and therefore, in several patients right PVE is essential prior to extended right hemihepatectomy [38].

Tumors mainly relating to the left biliary duct, for instance, Bismuth-Corlette types IIb-IV needs to have a left-sided approach. The main benefit of a left sided resection is usually that the remnant liver of the right liver normally has additional volume and resection could be expanded further to the right lobe of liver. Distinctly the volume of segments 6 plus 7 generally are higher than those of segments 2 and 3, which might lead the option of a right or left-sided technique [38]. An extended left hemihepatectomy adopting right hepatic vein with medial margin is technically challenging and dependent upon entanglement of the segment 8 biliary ducts.

5. Vascular resection and reconstruction

Portal vein resection and reconstruction (PVRR) prior to parenchymal transection are achievable in right-sided hepatectomies [69]. Neuhaus et al. described oncological advantages of hilar *en bloc* resection by means of 'no-touch' method for the handling of hilar cholangiocarcinoma [70]. In another study, the authors achieved PVRR through right-sided approach in case of decisive or extremely suspected invasion by the tumor to the portal vein [39]. Segmental resection along with end to end anastomosis is achievable in numerous instances. Segmental resection with autologous vein grafting is unusual in the right hepatectomy.

An autologous graft is required in the event of portal vein resection length is about 5–6 cm resection [39]. An external iliac vein is frequently used for an autologous graft for PVRR considering that the dimension of the harvested vein length is comparable to those of reconstruction. About 1/4th of the external iliac veins possess a valve, so normograde reconstruction of the portal vein is essential in order to avoid portal obstruction [39]. In portal vein reconstruction while utilizing an interposition graft, the proximal anastomosis is done prior to distal one. A distal anastomosis ought to be carried out following liberating the proximal clamp in

order to inflate the anastomotic side. In left hepatectomies, PVRR ahead of liver resection take time and effort and apart from that exceptional, and segmental vein grafting is frequently necessary for reconstruction [39].

At our institute we use autologous vein grafting for PVRR (**Figure 4**). It depends upon the defect in the resected portal vein to get reconstructed, an immediate transverse suture can be used. Whenever we clamp the root of the left portal vein of umbilical part during right hepatectomy, we commonly evaluate the anticipated right-side hepatectomy to get achievable in terms of the PVRR. During an exceptional scenario where the bifurcation of the left lateral superior (P2) and umbilical portion of the left portal vein are intricate, and distal part of these portal branches are isolated, we commonly discretely fixed and obliquely resected from umbilical portion of the left portal vein to P2 during right hepatectomy. Most often an external iliac vein graft is essential for this type of portal vein resection as well as distinct performance is cast-off for the distal anastomosis to repair a big and oblique portal vein resection margin. The bilateral sides of the distal end of the graft are longitudinally incised to evolve the obliquely resected portal vein stump. In left-sided hepatectomies, the critical procedure necessitates the separation and fixing with the right posterior sectional or the right anterior portal vein. For the end to end anastomosis of the portal vein, a stay suture is positioned for both sides as well as an intraluminal method is ordinarily employed for the anastomosis of posterior wall. It is accompanied by anterior wall anastomosis with 6–0 prolene suture. Hepatobiliary surgeon should never be reluctant to carry out PVRR during hepatobiliary resection in case of an encouraging R0 resection in order to obtain a good outcome in locally advanced cholangiocarcinoma [39].

Right hemihepatectomy is superlative to achieve R0 resection in Bismuth type I or II with decisive or suspected involvement of right hepatic artery (RHA) [48, 71]. On the other hand, left hemihepatectomy with RHA resection and reconstruction is probably the alternate approaches for sufferers with deprived liver functional reserve [39]. An even additional intense strategy to patients with advanced predominant perihilar cholangiocarcinoma in the left side has now been utilized via trisegmentectomy by using RHA resection and reconstruction with or without simultaneous PVRR [72].

Whenever there is the need of concurrent vascular reconstruction, generally portal vein reconstruction must come before hepatic arterial reconstruction (**Figures 5 and 6**). Exactly where arterial reconstruction doesn't seem possible,

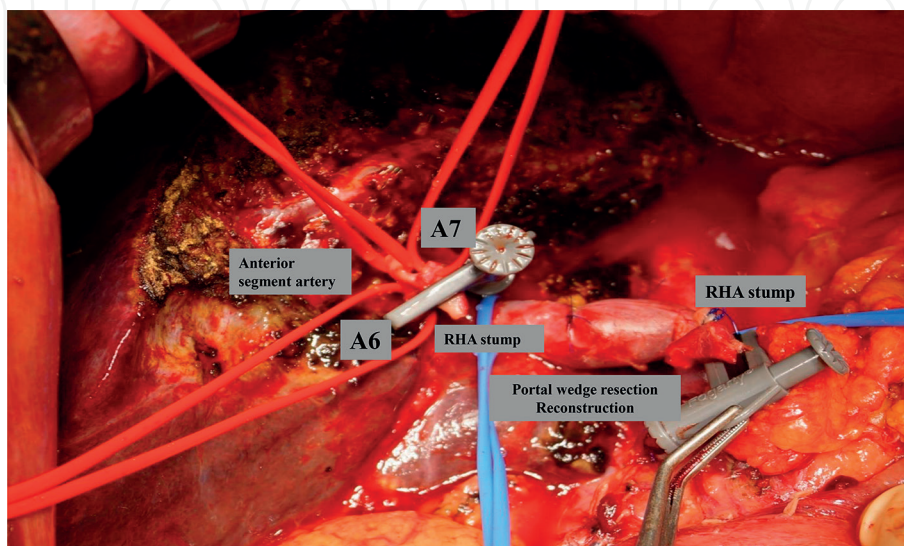


Figure 4.
Intra-operative illustrations of portal vein and right hepatic artery reconstruction.

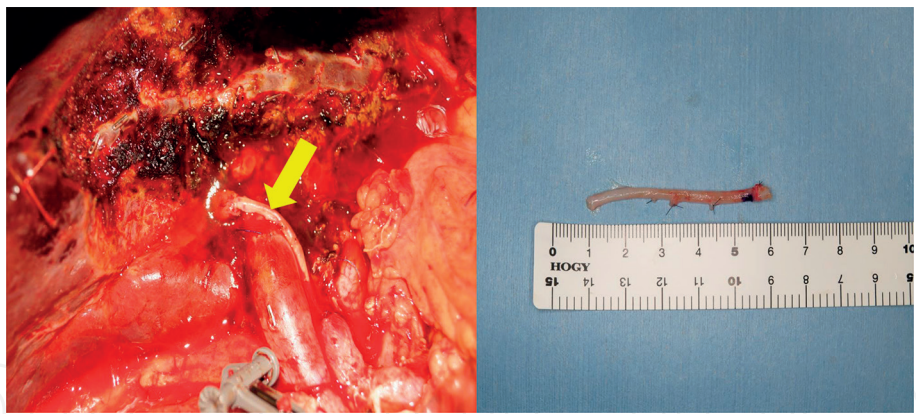


Figure 5.
Right hepatic artery reconstruction by using left radial artery (yellow arrow).

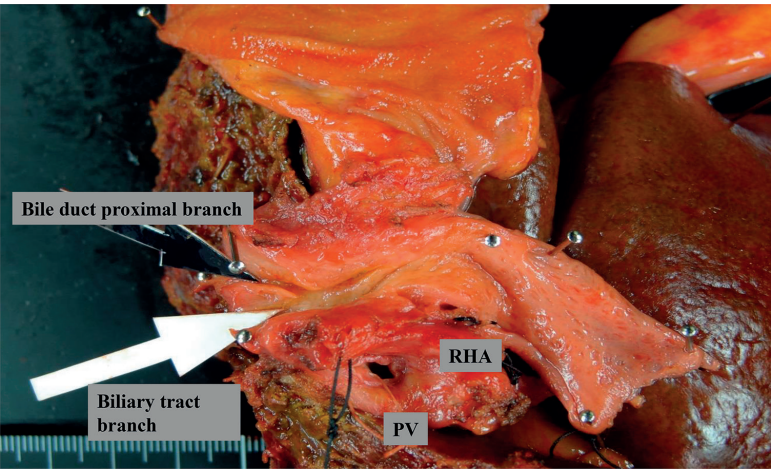


Figure 6.
Post-operative specimen illustrating the tumor invasion to the proximal branch and biliary tract including right hepatic artery and portal vein.

arteriportal shunting can be done by arterialization of the portal vein [73]. Side-to-oblique anastomosis is achieved between the common hepatic artery and the main portal vein, in order to avoid additional portal hypertension. Transcatheter arterial embolization of the common hepatic artery is conducted approximately 3 weeks right after surgical procedure. It could possibly evade liver infarction or abscess within the liver resulting in postoperative hepatic failure. Nevertheless, portal vein arterialization is phenomenal and also the ultimate disestablished alternative [39]. Adequate arterial perfusion is indispensable for the proper function of the remnant liver parenchyma. The left hepatic artery (LHA) cross transversely to the medial part of hepatoduodenal ligament and has significantly less risk for tumor engrossment.

The RHA having its right anterior and posterior branches is most often penetrated by tumor. Conducting a left or right arterial resection is frequently determined with the facet of the liver and the location where the branches of hepatic artery are free from the tumor. In PHC primarily relating to the left liver, extended or left hemihepatectomy with concomitant RHA resection is sometimes difficult in order to achieve tumor free margin. Intrahepatic distal stump for arterial reconstruction should be considered particularly when tumor mass is considerable. Micro surgical approaches are often employed to develop a risk-free anastomosis with the right posterior branch of the right hepatic artery in these instances (Figure 5). In Nagoya Japan, this complicated approach was associated with a fatality rate of 2% along with 30% of 5-year survival rate in advanced cholangiocarcinoma patients [72].

6. ALPPS for perihilar cholangiocarcinoma

Associating liver partition and portal vein ligation for staged hepatectomy (ALPPS) has become unveiled as a novel approach in liver surgery that causes speedy FLR hypertrophy assessed in liver volume and therefore, enables extensive resections. The initial report on the international ALPPS registry implemented and shown a deduction of fatality rate to 9% in 202 patients [74]. The foremost 25 patients series, explained the possibility of ALPPS to offer therapeutic resection primary or secondary advanced hepatic tumors, nevertheless, mortality rate was 12% [75].

Within one study, authors established that operative procedure of PHC employing ALPPS triggered a 48% mortality rate within 90 days. Coordinated sufferers that went through resection without having ALPPS had 28% mortality when compared with ALPPS (48%) patients, nevertheless, the main variance failed to achieve statistical importance [76].

Mortality resulting resection of PHC has been stated to vary from 5 to 18% in high volume centers [77–79]. PHC patient who was handled with ALPPS is highly recommended as very high risk patients and really should be in contrast to suitable risky controls. Having said that, along with the higher perils associated with ALPPS compared to the lower hazards of PVE, it could be much better to carry out a controlled PVE as the starting point rather than straight-up ALPPS. When it comes to inadequate hypertrophy, ALPPS could possibly be thought to be the last measure even though ALPPS-induced hypertrophy doesn't appear to be prone to prior PVE, most often designated as eventually salvage ALPPS [80]. Additionally, PHC sufferers have generally suffered with cholestasis, which hinders the restorative capability [81]. Consequently, the high re-forming response brought by ALPPS hypothetically may gain advantage to PHC patients. A disadvantage to PVE in the context of PHC is usually that long term embolization doesn't allow an intra-operative alteration of resection strategy, i.e. left to right or vice versa hepatectomy dependent upon intra-operative results [82].

ALPPS has got the advantages how the final choice to continue is usually obtained through the procedure. Nevertheless, the functional valuation on the speedy boost in liver volume noticed following phase one in ALPPS requires additional clinical evaluation [76]. According the latest study it has been recommended do not to consider ALPPS in PHC and one should relatively contemplate for PVE with selective embolization of the left portal vein to segment 4 for expansion of FRL volume in patients necessitating right trisegmentectomy [38]. When ALPPS is considered for PHC, the procedures needed to be carried out in specialized centers with substantial experience. On the other hand, depending on the existing details, PHC for ALPPS just isn't encouraged [76].

7. Summary

The management of PHC is complicated and needs close multidisciplinary team in order to gauge the preoperative planning for biliary drainage and determine the indications of operability. Imaging modalities such a MRCP could provide an additional assistance for tumor location. Patients with PHC usually presents with features of biliary issues, obstruction of biliary tract and jaundice. Biliary decompression is much-debated issue at present. We firmly believe that ENBD could a best modality for biliary decompression. Additional research is mandatory to validate this contentious issue. It is well known that obstructive jaundice hinders liver regeneration, biliary drainage remains recommended in the case of a small FLR and subsequently it could provide the likelihood of surgical resection. PVE is usually

an extensively recognized interventional technique to enhance FRL volume and overall performance just before starting major liver resection. This approach of liver enlargement is particularly of great benefit in sufferers with PHC who are required extensive liver resection in pre-damaged livers.

The most significant prognostic factor for long-term survival of PHC is R0 in the hilar tumor with lymph node resection. In skilled and expertise hands, even Bismuth-Corlette type IV tumors could be resected with curative intent. R0 resection necessitates an aggressive operative technique encompassing hilar resection combined with extended liver resection, typically associated with vascular resection and reconstructions. The main advantages of en bloc, resection of the portal vein bifurcation is not yet determined. While it's remained associated with substantial morbidity and fatality rate, a hostile operative strategy adjacent to extended liver resection, regional lymphadenectomy and PVVR increase the only possibility of long-term survival.

Author details

Pankaj Prasoon, Kohei Miura, Kizuki Yuza, Yuki Hirose, Jun Sakata and Toshifumi Wakai*

Division of Digestive and General Surgery, Niigata University Graduate School of Medical and Dental Sciences, Niigata City, Japan

*Address all correspondence to: wakait@med.niigata-u.ac.jp

IntechOpen

© 2018 The Author(s). Licensee IntechOpen. This chapter is distributed under the terms of the Creative Commons Attribution License (<http://creativecommons.org/licenses/by/3.0>), which permits unrestricted use, distribution, and reproduction in any medium, provided the original work is properly cited. 

References

- [1] Gatto M, Alvaro D. New insights on cholangiocarcinoma. *World Journal of Gastrointestinal Oncology*. 2010;**2**(3):136-145
- [2] Bismuth H, Nakache R, Diamond T. Management strategies in resection for hilar cholangiocarcinoma. *Annals of Surgery*. 1992;**215**(1):31-38
- [3] Khan SA, Thomas HC, Davidson BR, Taylor-Robinson SD. Cholangiocarcinoma. *Lancet* (London, England). 2005;**366**(9493):1303-1314
- [4] Watanapa P, Watanapa WB. Liver fluke-associated cholangiocarcinoma. *The British Journal of Surgery*. 2002;**89**(8):962-970
- [5] Shaib YH, El-Serag HB, Nooka AK, Thomas M, Brown TD, Patt YZ, et al. Risk factors for intrahepatic and extrahepatic cholangiocarcinoma: A hospital-based case-control study. *The American Journal of Gastroenterology*. 2007;**102**(5):1016-1021
- [6] Walker NJ, Crockett PW, Nyska A, Brix AE, Jokinen MP, Sells DM, et al. Dose-additive carcinogenicity of a defined mixture of "dioxin-like compounds". *Environmental Health Perspectives*. 2005;**113**(1):43-48
- [7] Shaib Y, El-Serag HB. The epidemiology of cholangiocarcinoma. *Seminars in Liver Disease*. 2004;**24**(2): 115-125
- [8] Nimura Y, Hayakawa N, Kamiya J, Kondo S, Shionoya S. Hepatic segmentectomy with caudate lobe resection for bile duct carcinoma of the hepatic hilus. *World Journal of Surgery*. 1990;**14**(4):535-543; discussion 44
- [9] Parodi A, Fisher D, Giovannini M, Baron T, Conio M. Endoscopic management of hilar cholangiocarcinoma. *Nature Reviews Gastroenterology & Hepatology*. 2012;**9**(2):105-112
- [10] Wetter LA, Ring EJ, Pellegrini CA, Way LW. Differential diagnosis of sclerosing cholangiocarcinomas of the common hepatic duct (Klatskin tumors). *American Journal of Surgery*. 1991;**161**(1):57-62; discussion-3
- [11] Shigeta H, Nagino M, Kamiya J, Uesaka K, Sano T, Yamamoto H, et al. Bacteremia after hepatectomy: An analysis of a single-center, 10-year experience with 407 patients. *Langenbeck's Archives of Surgery*. 2002;**387**(3-4):117-124
- [12] Dixon JM, Armstrong CP, Duffy SW, Davies GC. Factors affecting morbidity and mortality after surgery for obstructive jaundice: A review of 373 patients. *Gut*. 1983;**24**(9):845-852
- [13] Blamey SL, Fearon KC, Gilmour WH, Osborne DH, Carter DC. Prediction of risk in biliary surgery. *The British Journal of Surgery*. 1983;**70**(9):535-538
- [14] Nimura Y. Preoperative biliary drainage before resection for cholangiocarcinoma (pro). *HPB: The Official Journal of the International Hepato Pancreato Biliary Association*. 2008;**10**(2):130-133
- [15] Kawasaki S, Imamura H, Kobayashi A, Noike T, Miwa S, Miyagawa S. Results of surgical resection for patients with hilar bile duct cancer: Application of extended hepatectomy after biliary drainage and hemihepatic portal vein embolization. *Annals of Surgery*. 2003;**238**(1):84-92
- [16] Maguchi H, Takahashi K, Katanuma A, Osanai M, Nakahara K, Matuzaki S, et al. Preoperative biliary drainage for hilar cholangiocarcinoma. *Journal*

of Hepato-Biliary-Pancreatic Surgery. 2007;**14**(5):441-446

[17] Paik WH, Loganathan N, Hwang JH. Preoperative biliary drainage in hilar cholangiocarcinoma: When and how? *World Journal of Gastrointestinal Endoscopy*. 2014;**6**(3):68-73

[18] Pitt HA, Gomes AS, Lois JF, Mann LL, Deutsch LS, Longmire WP Jr. Does preoperative percutaneous biliary drainage reduce operative risk or increase hospital cost? *Annals of Surgery*. 1985;**201**(5):545-553

[19] Lau SH, Lau WY. Current therapy of hilar cholangiocarcinoma. *Hepatobiliary & Pancreatic Diseases International: HBPD INT*. 2012;**11**(1):12-17

[20] Belghiti J, Hiramatsu K, Benoist S, Massault P, Sauvanet A, Farges O. Seven hundred forty-seven hepatectomies in the 1990s: An update to evaluate the actual risk of liver resection. *Journal of the American College of Surgeons*. 2000;**191**(1):38-46

[21] Gundry SR, Strodel WE, Knol JA, Eckhauser FE, Thompson NW. Efficacy of preoperative biliary tract decompression in patients with obstructive jaundice. *Archives of Surgery (Chicago, Ill: 1960)*. 1984;**119**(6):703-708

[22] Kim KM, Park JW, Lee JK, Lee KH, Lee KT, Shim SG. A comparison of preoperative biliary drainage methods for perihilar cholangiocarcinoma: Endoscopic versus percutaneous transhepatic biliary drainage. *Gut and Liver*. 2015;**9**(6):791-799

[23] van der Gaag NA, Kloek JJ, de Castro SM, Busch OR, van Gulik TM, Gouma DJ. Preoperative biliary drainage in patients with obstructive jaundice: History and current status. *Journal of Gastrointestinal Surgery: Official Journal of the Society for Surgery of the Alimentary Tract*. 2009;**13**(4):814-820

[24] Kloek JJ, van der Gaag NA, Aziz Y, Rauws EA, van Delden OM, Lameris JS, et al. Endoscopic and percutaneous preoperative biliary drainage in patients with suspected hilar cholangiocarcinoma. *Journal of Gastrointestinal Surgery: Official Journal of the Society for Surgery of the Alimentary Tract*. 2010;**14**(1):119-125

[25] Kawakami H, Kuwatani M, Onodera M, Haba S, Eto K, Ehira N, et al. Endoscopic nasobiliary drainage is the most suitable preoperative biliary drainage method in the management of patients with hilar cholangiocarcinoma. *Journal of Gastroenterology*. 2011;**46**(2):242-248

[26] Hwang S, Song GW, Ha TY, Lee YJ, Kim KH, Ahn CS, et al. Reappraisal of percutaneous transhepatic biliary drainage tract recurrence after resection of perihilar bile duct cancer. *World Journal of Surgery*. 2012;**36**(2):379-385

[27] Takahashi Y, Nagino M, Nishio H, Ebata T, Igami T, Nimura Y. Percutaneous transhepatic biliary drainage catheter tract recurrence in cholangiocarcinoma. *The British Journal of Surgery*. 2010;**97**(12):1860-1866

[28] Mansfield SD, Barakat O, Charnley RM, Jaques BC, O'Suilleabhain CB, Atherton PJ, et al. Management of hilar cholangiocarcinoma in the North of England: Pathology, treatment, and outcome. *World Journal of Gastroenterology*. 2005;**11**(48):7625-7630

[29] Goenka MK, Goenka U. Palliation: Hilar cholangiocarcinoma. *World Journal of Hepatology*. 2014;**6**(8):559-569

[30] Rerknimitr R, Angsuwatcharakon P, Ratanachu-ek T, Khor CJ, Ponnudurai R, Moon JH, et al. Asia-Pacific consensus recommendations for endoscopic and interventional management of hilar cholangiocarcinoma. *Journal of*

Gastroenterology and Hepatology. 2013;**28**(4):593-607

[31] Paik WH, Park YS, Hwang JH, Lee SH, Yoon CJ, Kang SG, et al. Palliative treatment with self-expandable metallic stents in patients with advanced type III or IV hilar cholangiocarcinoma: A percutaneous versus endoscopic approach. *Gastrointestinal Endoscopy*. 2009;**69**(1):55-62

[32] Rerknimitr R, Kladcharoen N, Mahachai V, Kullavanijaya P. Result of endoscopic biliary drainage in hilar cholangiocarcinoma. *Journal of Clinical Gastroenterology*. 2004;**38**(6):518-523

[33] Moole H, Dharmapuri S, Duvvuri A, Dharmapuri S, Boddireddy R, Moole V, et al. Endoscopic versus percutaneous biliary drainage in palliation of advanced malignant hilar obstruction: A meta-analysis and systematic review. 2016;**2016**:4726078

[34] Celotti A, Solaini L, Montori G, Coccolini F, Tognali D, Baiocchi G. Preoperative biliary drainage in hilar cholangiocarcinoma: Systematic review and meta-analysis. *European Journal of Surgical Oncology: The Journal of the European Society of Surgical Oncology and the British Association of Surgical Oncology*. 2017;**43**(9):1628-1635

[35] Wiggers JK, Coelen RJ, Rauws EA, van Delden OM, van Eijck CH, de Jonge J, et al. Preoperative endoscopic versus percutaneous transhepatic biliary drainage in potentially resectable perihilar cholangiocarcinoma (DRAINAGE trial): Design and rationale of a randomized controlled trial. *BMC Gastroenterology*. 2015;**15**:20

[36] Jo JH, Chung MJ, Han DH, Park JY, Bang S, Park SW, et al. Best options for preoperative biliary drainage in patients with Klatskin tumors. *Surgical Endoscopy*. 2017;**31**(1):422-429

[37] Komaya K, Ebata T, Yokoyama Y, Igami T, Sugawara G, Mizuno T, et al. Verification of the oncologic inferiority of percutaneous biliary drainage to endoscopic drainage: A propensity score matching analysis of resectable perihilar cholangiocarcinoma. *Surgery*. 2017;**161**(2):394-404

[38] Rassam F, Roos E, van Lienden KP, van Hooft JE, Klumpen HJ, van Tienhoven G, et al. Modern work-up and extended resection in perihilar cholangiocarcinoma: The AMC experience. *Langenbeck's Archives of Surgery*. 2018;**403**(3):289-307

[39] Sano T, Shimizu Y, Senda Y, Kinoshita T, Nimura Y. Assessing resectability in cholangiocarcinoma. *Hepatic Oncology*. 2014;**1**(1):39-51

[40] Sewnath ME, Karsten TM, Prins MH, Rauws EJ, Obertop H, Gouma DJ. A meta-analysis on the efficacy of preoperative biliary drainage for tumors causing obstructive jaundice. *Annals of Surgery*. 2002;**236**(1):17-27

[41] Kawashima H, Itoh A, Ohno E, Itoh Y, Ebata T, Nagino M, et al. Preoperative endoscopic nasobiliary drainage in 164 consecutive patients with suspected perihilar cholangiocarcinoma: A retrospective study of efficacy and risk factors related to complications. *Annals of Surgery*. 2013;**257**(1):121-127

[42] Ratti F, Cipriani F, Ferla F, Catena M, Paganelli M, Aldrighetti LA. Hilar cholangiocarcinoma: Preoperative liver optimization with multidisciplinary approach. Toward a better outcome. *World Journal of Surgery*. 2013;**37**(6):1388-1396

[43] Kanai M, Nimura Y, Kamiya J, Kondo S, Nagino M, Miyachi M, et al. Preoperative intrahepatic segmental cholangitis in patients with advanced carcinoma involving the hepatic hilus. *Surgery*. 1996;**119**(5):498-504

- [44] Choi J, Ryu JK, Lee SH, Ahn DW, Hwang JH, Kim YT, et al. Biliary drainage for obstructive jaundice caused by unresectable hepatocellular carcinoma: The endoscopic versus percutaneous approach. *Hepatobiliary & Pancreatic Diseases International: HBPD INT*. 2012;**11**(6):636-642
- [45] Saluja SS, Gulati M, Garg PK, Pal H, Pal S, Sahni P, et al. Endoscopic or percutaneous biliary drainage for gallbladder cancer: A randomized trial and quality of life assessment. *Clinical Gastroenterology and Hepatology: The Official Clinical Practice Journal of the American Gastroenterological Association*. 2008;**6**(8):944-50.e3
- [46] Pinol V, Castells A, Bordas JM, Real MI, Llach J, Montana X, et al. Percutaneous self-expanding metal stents versus endoscopic polyethylene endoprotheses for treating malignant biliary obstruction: Randomized clinical trial. *Radiology*. 2002;**225**(1):27-34
- [47] Born P, Rosch T, Bruhl K, Sandsch W, Weigert N, Ott R, et al. Long-term outcome in patients with advanced hilar bile duct tumors undergoing palliative endoscopic or percutaneous drainage. *Zeitschrift fur Gastroenterologie*. 2000;**38**(6):483-489
- [48] Bismuth H, Corlette MB. Intrahepatic cholangioenteric anastomosis in carcinoma of the hilus of the liver. *Surgery, Gynecology & Obstetrics*. 1975;**140**(2):170-178
- [49] Cherqui D, Benoist S, Malassagne B, Humeres R, Rodriguez V, Fagniez PL. Major liver resection for carcinoma in jaundiced patients without preoperative biliary drainage. *Archives of Surgery (Chicago, Ill: 1960)*. 2000;**135**(3):302-308
- [50] Nakai Y, Yamamoto R, Matsuyama M, Sakai Y, Takayama Y, Ushio J, et al. Multicenter study of endoscopic preoperative biliary drainage for malignant hilar biliary obstruction: E-POD hilar study. *Journal of Gastroenterology and Hepatology*. 2018;**33**(5):1146-1153
- [51] Makuuchi M, Thai BL, Takayasu K, Takayama T, Kosuge T, Gunven P, et al. Preoperative portal embolization to increase safety of major hepatectomy for hilar bile duct carcinoma: A preliminary report. *Surgery*. 1990;**107**(5):521-527
- [52] Nagino M, Nimura Y, Kamiya J, Kondo S, Uesaka K, Kin Y, et al. Changes in hepatic lobe volume in biliary tract cancer patients after right portal vein embolization. *Hepatology (Baltimore, Md)*. 1995;**21**(2):434-439
- [53] de Graaf W, van Lienden KP, van den Esschert JW, Bennink RJ, van Gulik TM. Increase in future remnant liver function after preoperative portal vein embolization. *The British Journal of Surgery*. 2011;**98**(6):825-834
- [54] Nagino M, Ebata T, Yokoyama Y, Igami T, Sugawara G, Takahashi Y, et al. Evolution of surgical treatment for perihilar cholangiocarcinoma: A single-center 34-year review of 574 consecutive resections. *Annals of Surgery*. 2013;**258**(1):129-140
- [55] van Gulik TM, van den Esschert JW, de Graaf W, van Lienden KP, Busch OR, Heger M, et al. Controversies in the use of portal vein embolization. *Digestive Surgery*. 2008;**25**(6):436-444
- [56] Olthof PB, Wiggers JK, Groot Koerkamp B, Coelen RJ, Allen PJ, Besselink MG, et al. Postoperative liver failure risk score: Identifying patients with resectable perihilar cholangiocarcinoma who can benefit from portal vein embolization. *Journal of the American College of Surgeons*. 2017;**225**(3):387-394
- [57] Glantzounis GK, Tokidis E, Basourakos SP, Ntzani EE, Lianos GD, Pentheroudakis G. The role of portal

vein embolization in the surgical management of primary hepatobiliary cancers. A systematic review. *European Journal of Surgical Oncology: The Journal of the European Society of Surgical Oncology and the British Association of Surgical Oncology*. 2017;**43**(1):32-41

[58] Hayashi S, Baba Y, Ueno K, Nakajo M, Kubo F, Ueno S, et al. Acceleration of primary liver tumor growth rate in embolized hepatic lobe after portal vein embolization. *Acta Radiologica* (Stockholm, Sweden: 1987). 2007;**48**(7):721-727

[59] Huisman F, Cieslak KP, van Lienden KP, Bennink RJ, van Gulik TM. Liver related complications in unresectable disease after portal vein embolization. *Hepatobiliary Surgery and Nutrition*. 2017;**6**(6):379-386

[60] van Lienden KP, van den Esschert JW, de Graaf W, Bipat S, Lameris JS, van Gulik TM, et al. Portal vein embolization before liver resection: A systematic review. *Cardiovascular and Interventional Radiology*. 2013;**36**(1):25-34

[61] Wakai T, Sakata J. Surgical management of carcinoma in situ at ductal resection margins in patients with extrahepatic cholangiocarcinoma. 2018;**2**(5):359-366

[62] Sakata J, Wakai T, Matsuda Y, Ohashi T, Hirose Y, Ichikawa H, et al. Comparison of number versus ratio of positive lymph nodes in the assessment of lymph node status in extrahepatic cholangiocarcinoma. *Annals of Surgical Oncology*. 2016;**23**(1):225-234

[63] Ito F, Agni R, Rettammel RJ, Been MJ, Cho CS, Mahvi DM, et al. Resection of hilar cholangiocarcinoma: Concomitant liver resection decreases hepatic recurrence. *Annals of Surgery*. 2008;**248**(2):273-279

[64] Nishio H, Nagino M, Nimura Y. Surgical management of hilar cholangiocarcinoma: The Nagoya experience. *HPB: The Official Journal of the International Hepato Pancreato Biliary Association*. 2005;**7**(4):259-262

[65] van Gulik TM, Ruys AT, Busch OR, Rauws EA, Gouma DJ. Extent of liver resection for hilar cholangiocarcinoma (Klatskin tumor): How much is enough? *Digestive Surgery*. 2011;**28**(2):141-147

[66] Wiggers JK, Groot Koerkamp B, Coelen RJ, Rauws EA, Schattner MA, Nio CY, et al. Preoperative biliary drainage in perihilar cholangiocarcinoma: Identifying patients who require percutaneous drainage after failed endoscopic drainage. *Endoscopy*. 2015;**47**(12):1124-1131

[67] Dinant S, Gerhards MF, Busch ORC, Obertop H, Gouma DJ, Van Gulik TM. The importance of complete excision of the caudate lobe in resection of hilar cholangiocarcinoma. *HPB: The Official Journal of the International Hepato Pancreato Biliary Association*. 2005;**7**(4):263-267

[68] Bismuth H. Surgical anatomy and anatomical surgery of the liver. *World Journal of Surgery*. 1982;**6**(1):3-9

[69] Kondo S, Katoh H, Hirano S, Ambo Y, Tanaka E, Okushiba S. Portal vein resection and reconstruction prior to hepatic dissection during right hepatectomy and caudate lobectomy for hepatobiliary cancer. *The British Journal of Surgery*. 2003;**90**(6):694-697

[70] Neuhaus P, Thelen A, Jonas S, Puhl G, Denecke T, Veltzke-Schlieker W, et al. Oncological superiority of hilar en bloc resection for the treatment of hilar cholangiocarcinoma. *Annals of Surgical Oncology*. 2012;**19**(5):1602-1608

[71] Ikeyama T, Nagino M, Oda K, Ebata T, Nishio H, Nimura Y. Surgical approach to Bismuth type I and II hilar

cholangiocarcinomas: Audit of 54 consecutive cases. *Annals of Surgery*. 2007;**246**(6):1052-1057

[72] Nagino M, Nimura Y, Nishio H, Ebata T, Igami T, Matsushita M, et al. Hepatectomy with simultaneous resection of the portal vein and hepatic artery for advanced perihilar cholangiocarcinoma: An audit of 50 consecutive cases. *Annals of Surgery*. 2010;**252**(1):115-123

[73] Kondo S, Hirano S, Ambo Y, Tanaka E, Kubota T, Katoh H. Arterioportal shunting as an alternative to microvascular reconstruction after hepatic artery resection. *The British Journal of Surgery*. 2004;**91**(2):248-251

[74] Schadde E, Ardiles V, Robles-Campos R, Malago M, Machado M, Hernandez-Alejandro R, et al. Early survival and safety of ALPPS: First report of the International ALPPS Registry. *Annals of Surgery*. 2014;**260**(5):829-836; discussion 36-8

[75] Schnitzbauer AA, Lang SA, Goessmann H, Nadalin S, Baumgart J, Farkas SA, et al. Right portal vein ligation combined with in situ splitting induces rapid left lateral liver lobe hypertrophy enabling 2-staged extended right hepatic resection in small-for-size settings. *Annals of Surgery*. 2012;**255**(3):405-414

[76] Olthof PB, Coelen RJS, Wiggers JK, Groot Koerkamp B, Malago M, Hernandez-Alejandro R, et al. High mortality after ALPPS for perihilar cholangiocarcinoma: Case-control analysis including the first series from the International ALPPS registry. *HPB: The Official Journal of the International Hepato Pancreato Biliary Association*. 2017;**19**(5):381-387

[77] Olthof PB, Coelen RJ, Wiggers JK, Besselink MG, Busch OR, van Gulik TM. External biliary drainage following major liver resection for perihilar

cholangiocarcinoma: Impact on development of liver failure and biliary leakage. *HPB: The Official Journal of the International Hepato Pancreato Biliary Association*. 2016;**18**(4):348-353

[78] Kaiser GM, Paul A, Sgourakis G, Molmenti EP, Dechene A, Trarbach T, et al. Novel prognostic scoring system after surgery for Klatskin tumor. *The American Surgeon*. 2013;**79**(1):90-95

[79] DeOliveira ML, Cunningham SC, Cameron JL, Kamangar F, Winter JM, Lillemoe KD, et al. Cholangiocarcinoma: Thirty-one-year experience with 564 patients at a single institution. *Annals of Surgery*. 2007;**245**(5):755-762

[80] Bjornsson B, Gasslander T, Sandstrom P. In situ split of the liver when portal venous embolization fails to induce hypertrophy: A report of two cases. *Case Reports in Surgery*. 2013;**2013**:238675

[81] Yokoyama Y, Nagino M, Nimura Y. Mechanism of impaired hepatic regeneration in cholestatic liver. *Journal of Hepato-Biliary-Pancreatic Surgery*. 2007;**14**(2):159-166

[82] Donati M, Stavrou GA, van Gulik TM, Oldhafer KJ. Associating liver partition and portal vein ligation for staged hepatectomy for Klatskin tumours: Hinc sunt Leones! *ANZ Journal of Surgery*. 2015;**85**(1-2):3-4