

# We are IntechOpen, the world's leading publisher of Open Access books Built by scientists, for scientists

6,900

Open access books available

186,000

International authors and editors

200M

Downloads

Our authors are among the

154

Countries delivered to

TOP 1%

most cited scientists

12.2%

Contributors from top 500 universities



WEB OF SCIENCE™

Selection of our books indexed in the Book Citation Index  
in Web of Science™ Core Collection (BKCI)

Interested in publishing with us?  
Contact [book.department@intechopen.com](mailto:book.department@intechopen.com)

Numbers displayed above are based on latest data collected.  
For more information visit [www.intechopen.com](http://www.intechopen.com)



# Laparoscopic Live Donor Nephrectomy: Techniques and Results

*Maroun Moukarzel, Charbel Chalouhy, Nabil Harake and Freda Richa*

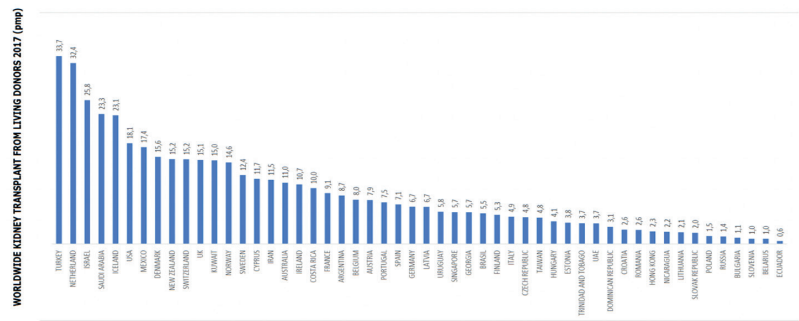
## Abstract

Living donation is still needed to overcome organ shortage. All countries seem to increase and encourage such kind of donation according to medical and ethical guidelines. The results of renal transplantation from living donors are better compared to those from cadaveric kidneys. Since the first successful kidney transplantation from a living donor, some 63 years ago, surgery has shifted toward a less invasive approach offering to the donor less pain, better cosmesis, a shorter hospital stay, and a quick return to normal activities. Laparoscopic living-donor nephrectomy (LLDN) is now considered as the gold standard approach for kidney retrieval on live donors and has undoubtedly revolutionized kidney donation. It must offer to the donor safety, low morbidity, and fast recovery and must obtain a graft with adequate vessel length, short warm ischemia time, and well-preserved ureteral blood supply. We describe our technique of LLDN according to safety principles and reproducible steps. Highly qualified and well-trained surgeons are allowed to perform such techniques within a very well-equipped environment and with experienced surgical staff. A living donor program should undertake at least 30 cases per year to maintain adequate experience and offer less complication rate.

**Keywords:** live donor, laparoscopy, nephrectomy, kidney transplantation, living kidney donation

## 1. Introduction

Living kidney donation has successfully improved the lives of many patients worldwide for over half a century. Do we still have the same need for living donors in 2018? The answer is obviously yes and for many reasons. The first is organ shortage with a widening gap between renal supply and demand in all countries that increases every year despite the use of marginal deceased donors. Waiting lists are growing everywhere. The site of the US Government Information on Organ Donation and Transplantation, [organdonor.gov](http://organdonor.gov), shows recently a transplant waiting list of more than 114,000 patients of whom 83% are potential kidney recipients [1]. The second reason is the significant graft survival advantage and the reduction of the waiting time between end-stage renal disease and graft implantation. The results of renal transplantation from living donors are better compared to those from cadaveric kidneys with a graft half-life of 18 versus



**Figure 1.** Worldwide kidney transplant from living donors in 2017. International Registry in Organ Donation and Transplantation.

12 years, respectively [2]. Kidney transplantation from a living donor, when possible, is the best treatment for most patients with end-stage renal disease. This is related to multiple factors such as less time from dialysis to transplantation, shorter cold ischemia time, and better quality of the graft. The third reason stands for pediatric recipients where a prompt transplantation from a living donor, mostly a parent, can help for a better growth, quick return to school, and a good psychological stability; it is considered today as the gold standard therapy for children with end-stage renal disease. The fourth argument is that living donation provides a good opportunity to perform a preemptive transplantation avoiding the need of going through dialysis. A fifth reason is that we are still too far to overcome organ shortage by using xenografts from transgenic animals, or engineered organs from stem cells.

Currently, 40% of kidney grafts in the United States are from living donors [1]. In Europe, the level is highly variable between countries, standing for approximately 10% in France and up to 60% in Norway and Sweden [2, 3]. Approximately, one in three kidney transplants performed in the UK are from living donors [4], and according to the Global Observatory on Donation and Transplantation (GODT), 84,347 kidney transplants were done worldwide in 2015, of which 41.8% were from living donors [5].

In some countries, namely Middle Eastern and Eastern, kidney transplantation is relying only or mostly on living donors [6, 7]. Worldwide kidney transplant from living donors in 2017, based on the International Registry in Organ Donation and Transplantation, is shown in **Figure 1** [8].

Women traditionally outrank men in their enthusiasm to donate one of their kidneys. Although most recipients are male, women represented 63% of all living donations in 2016 [9].

In regard to these facts, living donors have exceptional courage and nobility; they go through a major surgery, accepting all surgical and medical risks and of no medical and physical benefit for them. It is our vocation and duty to provide them a safe and good practice according to legal and ethical bylaws and to protect their health in the long term.

2. Historical milestones

The first true altruistic voluntary living donation happened in Paris at Necker Hospital on December 25, 1952, when a mother, Gilberte Renard, convinced the medical team to give her kidney to her son Marius, 16 years old, apprentice carpenter who had his right solitary kidney removed after falling from a scaffolding. Unfortunately, the graft remained functional for approximately 3 weeks despite the

use of steroids and Marius died on January 27, 1953. His donating mother died in 1992 at age 85 [10, 11].

The second important milestone happened 1 year later on December 23, 1954 at Brigham Hospital in Boston USA, when Dr. Murray performed a successful renal transplantation on Richard Hersick, the donor being his monozygotic identical twin brother Ronald. The kidney was removed from Ronald by the urologist Harrison. No effort was made to preserve the isograft; but nonetheless, it functioned promptly despite 82 min of warm ischemia [12]. The graft remained functional for 8 years and was lost due to a recurrence of the renal disease and causing the death of Richard. His brother Ronald died in 2010 at age 79, after a cardiac surgery, just 4 days after the 56th anniversary of his pioneering kidney operation [11, 13].

The next two following years, the Brigham team performed seven successful kidney transplants also between identical twins. The most famous was that of Edith Helm, the third case at Brigham, who got pregnant 2 years after her transplant and was the first kidney recipient to carry to term and give birth to a child. Edith Helm also holds the record of the best graft longevity of 55 years; she died in 2011 at age 76, with a functioning graft. Her donating identical twin sister, Wanda Foster, gave birth three times following her kidney donation and was still alive in 2016 [11, 14].

In 1960, the first kidney transplantation between genetically nonrelated patients was performed using immunosuppression. Late in 1963, a conference near Washington DC was held to present the overall findings from 216 recipients of renal allografts. The results were not gratifying: 52% of all those receiving grafts from related donors had died, and 81% of those with kidneys from unrelated or cadaveric donors. Joseph Murray concluded at that time that “kidney transplantation is still highly experimental and not yet a therapeutic procedure.” By 1965, 1 year survival rates of allografted kidneys from living related donors were much better approaching 80%, due to better immunosuppression [12, 15].

In 1987, Alexandre et al. in Belgium published a first series of ABO-incompatible (ABO-I) living donors using splenectomy and heavy immunosuppressive regimen in the recipient. Results were fairly optimal [16].

Then, since 1989 and due to organ shortage, most ABO-I kidney transplantations have taken place in Japan with recently published data showing an excellent long-term outcome. Currently, ABO-I reached approximately 30% of all living donor renal transplantation in Japan [17, 18].

From the surgical point of view, all donor nephrectomies were done by open techniques mostly using a lumbar retroperitoneal approach; and the first successful trial of removing a live donor kidney using a laparoscopic approach was in 1995 at John's Hopkins hospital by Ratner et al. [19]. Since then, considerable numbers of transplant centers worldwide have adopted laparoscopic donor nephrectomy (LDN) which is now considered as the gold standard approach for kidney retrieval on live donors and has undoubtedly revolutionized kidney donation.

### **3. Living donor evaluation**

Suitability of the potential kidney recipient for transplantation must be established before starting donor assessment. There is a significant variability among transplant programs in the criteria used to evaluate donors. ABO blood grouping is an important early screening test. Initial assessment of donor and recipient histocompatibility status must be undertaken at an early stage in living donor kidney transplant workup to avoid unnecessary and invasive clinical investigation [4]. Although donors are not true patients, they must undergo a complete and extensive evaluation before considering kidney removal. This evaluation includes medical and



surgical past history, risk factors like alcohol intake and smoking, family history (mainly renal disease, hypertension, and diabetes), renal, liver, and cardiopulmonary function. They should have no active malignancy or infection. The waiting period before transplant in recipients with a history of malignancy depends on the type, TNM stage and grade of the tumor, and recipient's age and general health. Recipients with tumors that have a low recurrence rate can be considered for immediate transplantation after successful treatment. Active HBV and HCV are usually contraindications to living donor kidney donation; and HIV infection is an absolute contraindication. Screening of serum prostate-specific antigen (PSA) is mandatory in males above 54 years as also mammograms in women. A urine albumin/creatinine ratio done on a spot urine sample is a recommended screening test and it should be  $<30$  mg/mmol. The presence of persistent microhematuria (two or more positive urine analysis) or recently called "persistent nonvisible hematuria," with no evident explanation like stones, neoplasms, and infection, should be investigated with cystoscopy and renal biopsy. Assessment of renal function is based on serum creatinine and calculation of creatinine clearance. Differential kidney function, using DMSA isotope scanning, is recommended when there is  $>10\%$  variation in kidney size or abnormal renal anatomy [4]. Donors with mild and well-controlled hypertension, on one or two antihypertensive drugs, and with no evidence of end organ damage (retinopathy, left ventricular hypertrophy, proteinuria), might be accepted [20]. Data regarding long-term safety of nephrectomy in hypertensive donors are modest; but small studies with short-term follow-up suggest no increase in the incidence of kidney disease or worsening of the control of hypertension in donors with a history of mild well-controlled hypertension [21]. The Amsterdam Forum consensus guidelines in 2004 stated that some patients (age  $> 50$ , GFR  $>80$ , and with low urine albumin excretion of  $<30$  mg/d) with easily controlled hypertension can represent a low-risk group for the development of kidney disease but might be considered as donors [22]. A psychosocial assessment is recommended for all donors with appropriate referral to a mental health professional who can be a psychologist or a psychiatrist. This assessment also evaluates whether the decision to donate is free of constraint and other undue pressures. Donor age is suggested to be between 22 and 75 years; but the upper age limit can be beyond if the donor is in good health and with a normal range of age-related change in kidney function (e.g., advisory threshold GFR levels considered acceptable at age 80 years is  $58$  ml/min/ $1.73$  m<sup>2</sup> for males and  $49$  ml/min/ $1.73$  m<sup>2</sup> for females). A safe threshold level of predonation kidney function is one that leaves sufficient function after donation to maintain the donor in normal status without affecting lifespan [4]. Old donors ( $> 60$  years) should be aware of a greater risk of pre- and postoperative complications. We are very cautious about young donors who are less than 30 years old because their absolute risk over a lifetime, particularly with additional risk factors for end-stage renal disease (like hypertension, obesity, and diabetes), is likely to be more significant [4]. Living donors should ideally have a body mass index (BMI) that is less than  $30$  kg/m<sup>2</sup>. Data on the safety of kidney donation in the very obese (BMI  $>35$  kg/m<sup>2</sup>) are limited and donation should be discouraged. Morbid obesity increases the risk of hypertension, dyslipidemia, insulin resistance and diabetes, heart disease, stroke, sleep apnea, and certain cancers [23]. On the other hand, data suggest that laparoscopic living-donor nephrectomy (LLDN) is an increasingly safe procedure in the otherwise healthy obese kidney donor and does not result in a high rate of major perioperative complications [24, 25]. Also, transplantation from an old or obese donor is most probably better than dialysis or transplantation from a deceased donor [26]. Computed tomography and tomographic angiography are used to assess renal vascular anatomy (presence of accessory vessels, intervessel distance, distance from ostium to the first division, presence of atherosclerotic disease), renal dimensions, presence of

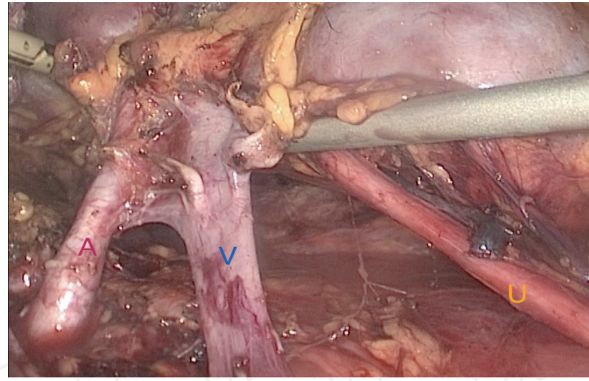
stones, urinary tract anatomy, and the existence of any suspicious lesion not seen on ultrasound. Around 25% of will have multiple arteries to one kidney and 7% will have multiple vessels to both kidneys [27]. Renal pedicles with less than three arteries are accepted.

The presence of multiple renal cystic lesions in a potential living kidney donor requires careful evaluation and a detailed family history; in those with a family history of polycystic kidney disease under the age of 40 years, the presence of two or more cysts (unilateral or bilateral) indicates autosomal dominant polycystic disease (ADPKD) and exclude donation [28]. For those aged 40–59 years, the absence of at least two cysts in each kidney gives a 100% negative predictive value for ADPKD, while for those older, up to four cysts are acceptable in each kidney [4]. History or current presence of bilateral renal stones is a contra indication for donation; but in some centers, donors with a history of nephrolithiasis are accepted as long as stones are no longer present and metabolic studies are normal [29].

#### 4. Surgical technique

Multiple techniques have been described to harvest a kidney from a living donor. The old classic open surgery performed through a lumbar or subcostal incision is nowadays much less popular compared to mini-invasive approaches using laparoscopic extra corporeal manipulation and magnified ultrahigh definition view of the surgical field. But regardless of how minimally invasive laparoscopy can be, living donor nephrectomy remains a maximally invasive surgery because we are dealing with major vessels and consequently very serious and sometimes lethal hemorrhagic complications might occur. Highly qualified, competent, and well-trained surgeons are allowed to perform such techniques within a very well-equipped environment and with experienced surgical staff. A living donor program should undertake at least 30 cases per year to maintain adequate experience. Today, laparoscopy is by far the preferred procedure for kidney removal in live donors, offering a quick recovery, less pain, and a shorter hospital stay; and it will be the technique detailed in this chapter. A well-informed consent is obtained prior to surgery. The surgeon performing living donor nephrectomy has a particular responsibility to ensure that the donor fully understands the potential risks and long-term effects of the operation. Surgery must offer to the donor safety, low morbidity, and fast recovery; and must obtain a graft with adequate vessel length, short warm ischemia time, and well-preserved ureteral blood supply. A donor kidney with a single renal artery should, whenever possible, be chosen for transplantation to minimize the risk of vascular complications in the recipient procedure; similarly, single renal veins are usually preferred. Many transplant centers prefer the left kidney for LLDN because of the longer vein and perhaps an easier surgery on the left side; but with increasing experience, kidney side was not a real obstacle [30] although for some authors the right kidney was the only risk factor for early graft thrombosis [31, 32]. The answer to which kidney to take when facing a donor with two arteries on the left and a single artery on the right is based on the surgeon's experience of laparoscopic right nephrectomy and his skills in reconstructing the vasculature of the graft. The presence of a retroaortic renal vein is of no problem with no increased complications; and it is even an easier case because of the large distance between the artery and the retroaortic vein which is in an inferior position (**Figure 2**). The most important criterion regarding the side to be chosen for retrieval is to keep the better kidney for the living donor.

There is variability among different centers on the choice of laparoscopic technique between only pure laparoscopy (transperitoneal versus retroperitoneal), only hand-assisted laparoscopy or a combination of both. Laparoendoscopic single-site



**Figure 2.**  
*Retroaortic vein (V). See the distance between the artery (A) and the vein (V). U = ureter.*

surgery (LESS), natural orifice transluminal endoscopic surgery (NOTES), and robotic-assisted are other interesting techniques that still need to be evaluated. In our experience, we started our first 10 cases with hand assistance, given the increased security that it provides, and then switched to pure transperitoneal laparoscopic approach which will be detailed in this chapter.

#### 4.1 Anesthesia

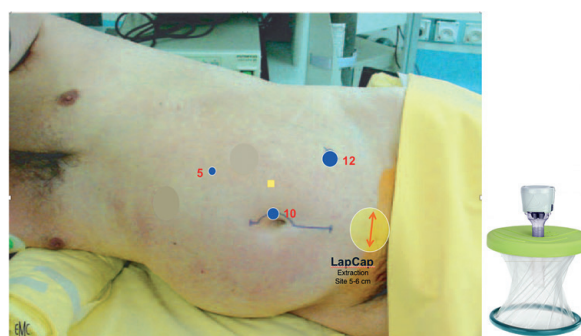Laparoscopic donor nephrectomy has had a big impact on anesthesia and recovery of this special category of patients. Intraoperative anesthesia for laparoscopic live donors follows the rules of laparoscopic kidney surgery as far as sedation and muscle relaxation but the concept of protection of the donor kidney is mandatory throughout the case, one among many disparities compared to other kidney surgeries [33]. Nowadays, two large-bore IV catheters are considered more than enough as far as vascular access and risk of bleeding. Arterial lines are not recommended and noninvasive blood pressure monitoring is a reasonable option [34]. After induction of anesthesia, classically with propofol and a neuromuscular blocking agent, maintenance of anesthesia has been the subject of many studies to evaluate the nephrotoxicity of various agents. While isoflurane and desflurane were considered safe and with the least toxicity on the kidney, this was not the case with sevoflurane that is associated with production of compound A in the circulation; a direct nephrotoxic substance [35]. Despite many works, the type of anesthetic agent was not shown to impact serum creatinine or GFR in transplanted grafts and it was concluded that toxicity, if any, was minimal. Nitrous oxide is one agent preferably avoided in laparoscopic surgery as it can cause bowel distention in more than 50% of cases and subsequent compromise of insufflation or surgical field exposure in near 25% of laparoscopic donor nephrectomy, increasing the need even more for neuromuscular blocking agents [36]. Mechanical ventilation settings are not different from other laparoscopic procedures. Special considerations for donor nephrectomy would include tolerance of mild hypercapnia to 45 mmHg since it helps better tissue perfusion and circulation in light of pneumoperitoneum. Positive-end expiratory pressure (PEEP) at 5–10 mmHg, a 20–30% increase in minute ventilation reflecting an increased respiratory rate with constant volumes, is similar to other laparoscopic procedures. The effects of pneumoperitoneum were explored by studies on rats demonstrating that abdominal insufflation with CO<sub>2</sub> during laparoscopy in subjects with chronic renal function impairment should not be a contraindication to surgery [37]. Additionally, if insufflation had a substantial negative effect on kidney function, we would have expected this to have a great impact on kidney donors out of concern on the retained kidney, which has not been



born out in the literature. IV hydration holds a crucial place in counteracting the notorious effects of pneumoperitoneum on tissue perfusion and renal plasma flow caused by an increased intraperitoneal pressure sometimes near 15 mmHg. Some studies emphasized the great effects of hydration on mean arterial pressure preservation and ensuring hemodynamic stability [38]. Whether this is realized by giving donors colloid boluses preoperatively or during surgery is based on institutional protocols and the team preferences. In general, a patient undergoing laparoscopic donor nephrectomy should get 4–6 L during the procedure to maintain at least a urine output >50 mL/h [38]. This will help avoid the use of any vasopressors or inotrope agents because of the associated deleterious renal vasoconstriction. If they become really needed, ephedrine is the best agent to start with, giving small boluses in order to attain the desired effects. IV fluids should be warmed and full measures should be taken to prevent hypothermia. There is a mounting evidence to suggest that 0.9% normal saline can be detrimental to patient outcome, and may indeed contribute to renal dysfunction, and therefore, the use of this solution in donors cannot be recommended; Ringer's lactate solution is the intravenous fluid of choice [4]. The administration of mannitol 12–25 g once or twice, or furosemide at small doses during the case, is another example of common practice depending on departmental protocols, but they lack any definite data or evidence to support it.

#### 4.2 Antibiotics, patient position, and trocar placement

We routinely give antibiotic prophylaxis based on one single shot of cefazolin. After placement of a Foley catheter, the patient is put in a complete lateral decubitus position almost 90° to the table without any flexure or kidney rest; the belly being on the external border of the table. Arms and legs are well secured with pillows and gel pads to prevent any vascular or nerve compression. We start by doing the extraction site as a small transverse supra pubic incision 6–8 cm width, depending on donor kidney size, with opening of the peritoneum and insertion of a LapCap device (Applied Medical-Alexis Laparoscopic System with Kii® Fios® First Entry) (**Figure 3** and Video 1 (<https://youtu.be/LBWxDCD2Upk>)). Pneumoperitoneum induction is made through this device. Intraabdominal CO<sub>2</sub> pressure is fixed at 12 mm Hg. The use of low-pressure pneumoperitoneum with deep neuromuscular block did not seem to reduce postoperative pain scores or improve the overall quality of recovery after surgery [39]. After complete insufflation, we insert all trocars under direct vision. On the left side, the first is a 10 mm placed umbilical or para umbilical depending on obesity status; the second is a 5 mm placed subcostal on the level of the anterior axillary line, and the third one is a 12 mm trocar (which comes in the LapCap package) placed in the left iliac fossa (**Figure 3**). On the right side,



**Figure 3.**  
*Left side: position of patient and 3 trocar placement: 5 mm subcostal, 10 mm umbilical or para umbilical (yellow dot) depending on obesity, and 12 mm left iliac fossa. LapCap device shown on the right.*



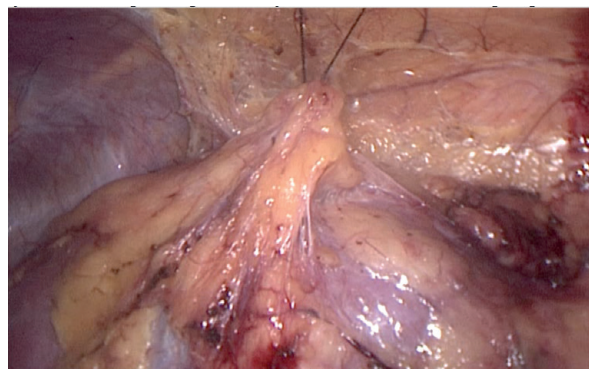
trocar placement is the same with an additional 5 mm one, inserted at the xiphoid for liver retraction. Additional ports can be used in some rare difficult cases and sometimes we do percutaneous kidney suspension using a 2/0 silk on a straight needle through Gerota's fascia and perirenal fat (**Figure 4**).

### 4.3 Surgical steps

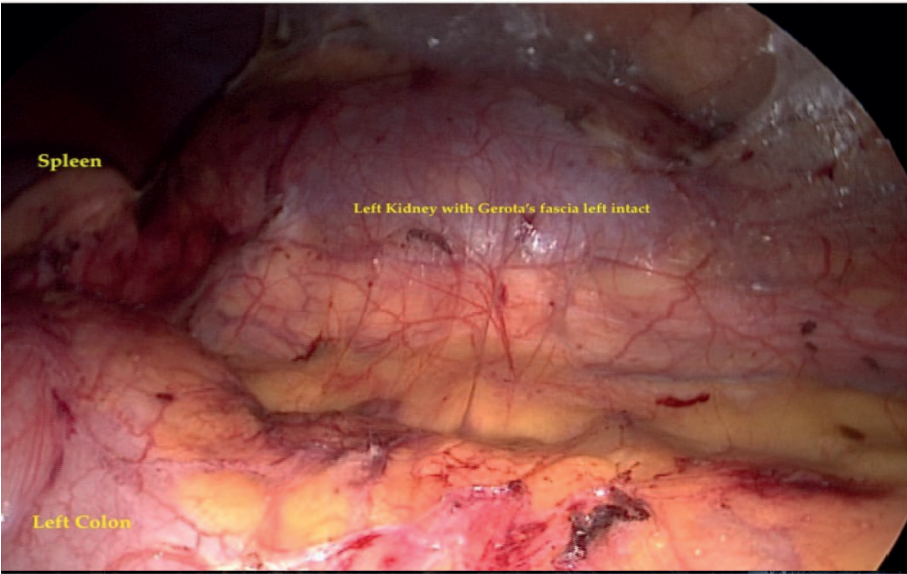
As described in all transperitoneal approaches, we start by taking the colon off the kidney medially along the Toldt's fascia from the iliac vessels up to the colonic angle (splenic flexure on the left and hepatic flexure on the right). Gerota's fascia is left intact on the kidney (**Figure 5**). The lateral and parietal attachments of the kidney are left in place to prevent the kidney from slipping down and disturbing later the hilar dissection. We use from the start a LigaSure™ Maryland 5 mm (Covidien) sealing device. We then dissect and isolate the ureter inferiorly down to the iliac vessels with identification of the psoas muscle and the genital vessels. All periureteral and inferior renal pole fat must be well preserved to keep a well-vascularized ureter (**Figure 6**). Avoid any injury to the genitofemoral nerve and try to keep the psoas fascia in place. The gonadal vein can be divided proximally and distally and kept with the ureter in order to protect ureteric vascularity. This is thought to be the cause of postoperative ipsilateral orchialgia, which occurs in 6.2–9.6% of male donors [40, 41]. Large studies, however, have demonstrated that leaving the gonadal vein in situ does not lead to increased ureteric complications in the transplant recipient [42] and prevents orchialgia [40, 43].

#### 4.3.1 Left-sided nephrectomy

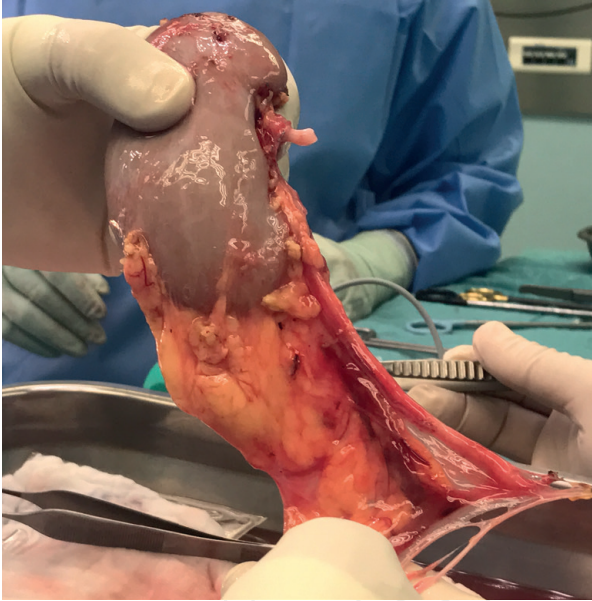
The ureter and its peri ureteral fat are lifted up to undertake an upper dissection along the genital vein until we reach the inferior border and the anterior aspect of the renal vein (Video 2 (<https://youtu.be/Ms38M9mIV0Q>)). Then, the spleen and tail of the pancreas are completely mobilized by cutting the splenorenal and splenophrenic ligaments (Video 3 (<https://youtu.be/lKNHPx66Mgo>)). Care is taken not to injure the pancreas, the splenic artery, and the stomach near the level of the crus of the diaphragm where dissection ends. By achieving this step, the space between the spleen and the kidney is usually widely opened and permits partial mobilization of the upper renal pole (**Figure 7**). We then proceed to adrenal dissection and separation starting very carefully from the upper border of the renal vein toward the upper pole of the kidney with division of the adrenal vein using LigaSure sealing without any clip placement and caring not to injure the anterior branch of the renal artery or small upper pole accessory



**Figure 4.**  
*Left kidney suspended with a 2/0 silk suture on the parietal wall.*



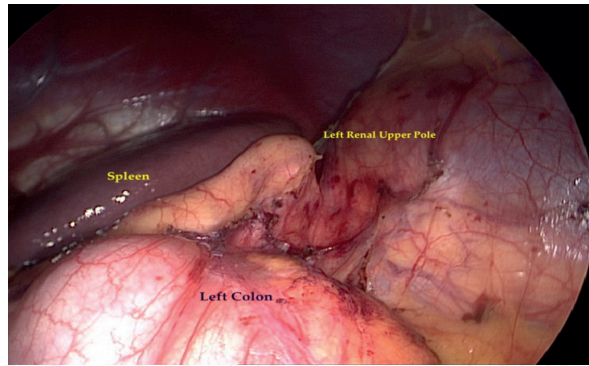
**Figure 5.**  
*Left renal aspect after colon dissection. Gerota's fascia is left intact.*



**Figure 6.**  
*Ureter with well-preserved periureteral fat and vasculature.*

arteries not detected on the preoperative renal angio CT scan (Video 4 (<https://youtu.be/WbgzAzZZprk>)). This step will almost complete the upper pole release.

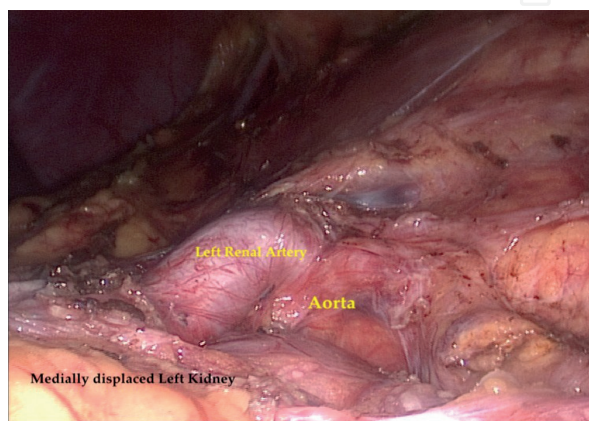
The renal pedicle is now ready to be dissected. Before starting the hilar dissection, 12–25 mg of mannitol is administered. All lymphatics and autonomic nerve plexuses superior to the vein and around the renal artery are sealed and cut. Some small segments of these structures are sometimes difficult or possibly dangerous to access, and in such a case, they are quickly sealed and cut after the stapling of the renal pedicle. Very careful and minutious dissection is undertaken between the artery and vein to prepare a clear, precise, and secure positioning of the stapling device. The left renal artery is dissected at its aortic origin (Video 5 (<https://youtu.be/5wyqkJz7ick>)). If vasospasm is noted, the renal artery can be bathed in a papaverine solution (30 mg/ml) [44]. In some cases, retroperitoneal veins (lumbar, ascending lumbar, and hemiazygos) join the left renal vein in up to 75% of individuals, and it must be sealed and cut [45]. Clips are avoided on all venous branches



**Figure 7.**  
*Spleen separated from the left renal upper pole.*

to prevent their later insertion between the jaws of the stapling device leading to misfire and serious malfunction [46].

The ureter and its periureteral fat are again lifted up at the level of the iliac vessels and posterior dissection will start from here and go up to the whole posterior surface of the kidney. The ureter is isolated with a generous periureteric fat. After completing this posterior release, the kidney is completely lying medially and we can free the posterior aspect of the renal artery (**Figure 8**; Video 6 (<https://youtu.be/xQswiMds4Nc>)). Now the kidney is supposed to hold only on the artery, vein, and ureter and is ready to be harvested. The patient is given another dose of mannitol. An Endocatch bag 15 mm (Covidien) is inserted through the LapCap. The distal ureter is clipped and sectioned. A good flow of urine should be noticed before pedicle clamping. A number of vascular transfixing stapling devices are available for surgeons to secure the renal vessels. The choice of which device to use is down to surgeon preference. Recently, we rely on two stapling devices: Endo-TA 30 stapler (30-mm length, 2.5-mm staples-Covidien) if maximum length is needed because this device delivers three rows of staplers without a cutting knife and no articulation; and vessels are cut with cold scissors; and Echelon Flex™ Powered Vascular Stapler 35 mm (Ethicon) with manual articulation for more precise placement, a narrow curved blunt tip, and reduction in tip movement during firing; this device delivers four rows of staples (instead of six) in a staggered pattern and gives a very secure vascular control and less loss in vessel length with nonbloody surgical field because of the absent backflow. Stapling starts on the renal artery and then quickly on the vein, and the kidney is rapidly placed in the Endo bag and extracted through the LapCap (Videos 7 (<https://youtu.be/RfIGOjtqpD8>) and 8 (<https://youtu.be/dGUKd3R23Yo>)). We do not give intravenous heparin prior to vascular occlusion.



**Figure 8.**  
*Laparoscopic view after posterior left renal dissection.*



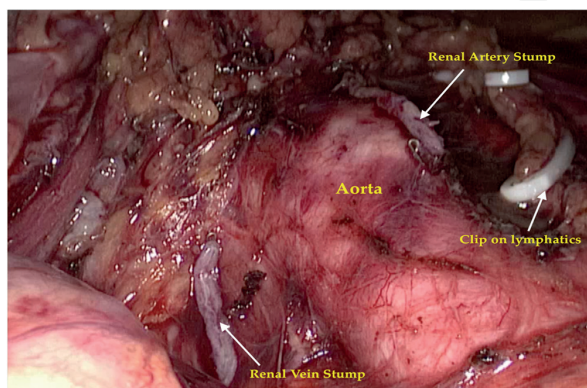
Warm ischemia time is usually around 3–5 min before the kidney is flushed out on ice with the preservation solution.

Originally, the artery was secured using locking polymer clips that are much cheaper than staples. On April 2006, the manufacturer of Weck Hem-o-lok ligating clips, Teleflex Medical, added a contraindication to the use of these clips on renal vessels in laparoscopic live donor nephrectomy, after receiving 15 medical device reports of 12 injuries and 3 deaths, all of which occurred between November 19, 2001 and March 20, 2005. All reports were associated with using the clips for ligation of the renal artery during LLDN [47, 48]. Clip dislodgement may occur several hours following the procedure resulting in fatal hemorrhage on the ward [49]. US Food and Drug Administration (FDA) issued on May 2011 a warning to healthcare providers that Weck Hem-o-Lok ligating clips should not be used for the ligation of the renal artery during LLDN because of serious risks and potential life-threatening complications to the donor [50]. On the other hand, surgeons must be aware that reported failure rates for staplers are 3.0% [51]. Stapler misfire rates can be reduced by avoiding the use of titanium and other clips around the hilar structures before securing the renal pedicle [46].

Before ending the surgery, latero aortic and inter aorto caval lymphatics are clipped (Hem-o-lok clips) to prevent chylous leakage (Video 9 ([https://youtu.be/\\_c4rjTtvITw](https://youtu.be/_c4rjTtvITw))). Meticulous and extensive clipping remains the safest way of securing lymphatic channels along the dissection area despite being usually burned with energy-based sealing devices. It has been shown that bipolar cautery can effectively ligate and control lymph leakage as also other laparoscopic dissection devices using bipolar and ultrasonic energy but monopolar scissors were unreliable with respect to sealing lymphatic channels [52, 53]. Last view of the whole surgical field is done with particular inspection of the vascular stumps (**Figure 9**). Pneumoperitoneum is exsufflated. No drainage is usually needed. Port and extraction sites are closed.

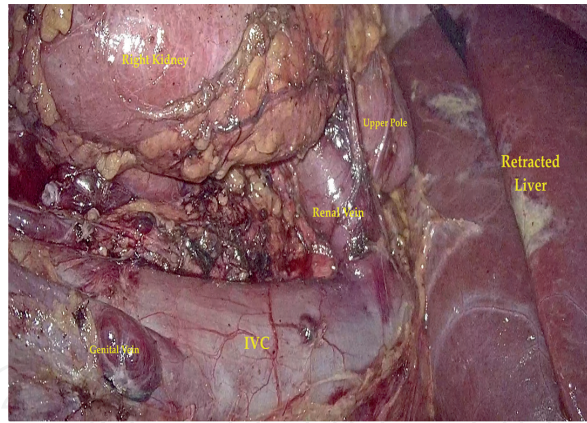
#### 4.3.2 Right-sided nephrectomy

In some patients, the right side seems to be easier than the left. Steps are almost the same. Trocar placement has the same distribution as on the left except for an additional 5 mm trocar inserted at the xiphoid for liver retraction (**Figure 10**). Less right colon dissection is needed and careful duodenal displacement is performed to expose the inferior vena cava (IVC). Genital vein is usually kept in place. The renal upper pole is carefully separated from the adrenal as on the left side starting from the upper border of the right vein. Renal vessels are also approached from below after isolation of the ureter and periureteral fat and identification of the psoas muscle and lifting up the kidney. The right renal vein is exposed at its insertion into

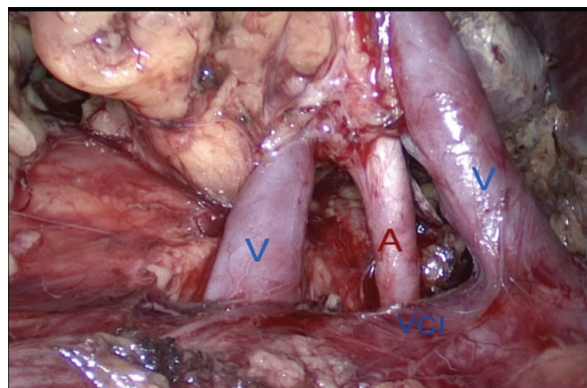


**Figure 9.**  
*Left renal artery and vein stumps after stapling and kidney harvesting. Clips on lymphatics are placed after vascular stapling.*





**Figure 10.**  
*Liver retracted through a 5-mm xiphoid trocar.*



**Figure 11.**  
*Laparoscopic view of right donor kidney with two veins (V) and one artery (A).*

the IVC. Duplication of renal vein is more common on the right side and is reported in as much as 15% of potential renal donors [54] (**Figure 11**). The adrenal vein, gonadal vein, and retroperitoneal veins (lumbar, ascending lumbar, and hemiazygos) may drain into the right renal vein in 30, 7, and 3% of cases, respectively [55]. The IVC must be well dissected below and above the renal vein to permit later easy positioning of the stapler device. In usual anatomy, the renal artery is classically found just behind the vein and the space between artery and vein is normally easily created. Retrocaval area is a difficult area to work at during LLDN; therefore, the exact location of the first segmental branch of right renal artery with respect to the IVC should be clearly identified in the pretransplant angio CT scan. In some cases, posterior release of the artery behind the IVC is necessary to reach the main trunk (Video 10 (<https://youtu.be/DPGFtpAVar8>)) especially if the artery is in an upper position to the vein (Video 11 (<https://youtu.be/BfbPdO-U8zU>)); or even rarely, access to the artery is done through the inter aorto caval space. Caval countertraction is applied just prior to firing the endovascular stapler, so that adequate venous length is obtained. The renal vein is usually 2–3 mm shorter compared with the open surgery. Operative time and warm ischemia time may be greater when performing a right-sided LLDN, but this does not result in delayed allograft function [56].

## 5. Postoperative care

The early postoperative period after laparoscopic donor nephrectomy is a particular moment in the management of kidney donors. Extubation is done after

normothermic state. Orogastric tube is removed prior to extubation. Hemoglobin measurement is realized every 6 h postsurgery, and if normal, it will be repeated the next morning with serum creatinine and electrolytes. Urine output is monitored. Shoulder tip discomfort and pain is a major complaint after LLDN perhaps from residual pneumoperitoneum. Epidural analgesia is ineffective for shoulder pain. There has been collective belief to aggressively minimize pain postoperatively in this special category of patients who are usually narcotics naïve. IV “patient-controlled analgesia” (PCA; fentanyl or morphine less commonly) was considered to be the modality of choice to achieve that. If PCA is not available, pain control is achieved with IV paracetamol and if needed ketoprofen or ketorolac over the first 24 h [57]. To reduce the risk of nephrotoxicity, the patient should be kept well hydrated. Opiates also have an effective role for breakthrough pain when opiate-sparing strategies have not been effective. Clear liquids are started on the day of surgery with increase of diet later. The emergence of enhanced recovery after surgery (ERAS) brought major changes to the traditional standard of care. Many centers across the USA have adopted the enhanced recovery programs that include intraoperative fluid restriction to 3 ml/kg/h preventing excessive third spacing and bowel edema, urine output of 0.5 ml/kg/h, use of local subfascial bupivacaine or other anesthetics as well as a postoperative narcotic-free pain control regimen, i.e., acetaminophen, ketorolac, etc. [58]. Novelties in this management were associated with reduced length of hospital stay, better pain control, and increased patient satisfaction. It has become evident that ERAS would potentially enhance the benefits of laparoscopic surgery for kidney donors [59].

Foley catheter is removed on the morning of day 1 and ambulation started as soon as possible either during the evening of day 0 or the next morning. Living kidney donors are classified as “medium risk” patients for deep venous thrombosis (DVT) and pulmonary embolism [4]. All living donors must have intra- and postoperative compression stockings and should receive adequate thromboprophylaxis with low-molecular weight-heparin and continuing for at least 1 week. Patient is discharged most frequently on day 2 and seen back 10 days later with a follow-up at 6 months, 1 year, and 2 years after donation. Donors must resume a normal life-style as soon as possible with regular surveillance of their blood pressure and their weight. They should be warned about avoiding nephrotoxic medications.

## 6. Complications

LLDN appears to be a safe procedure or at least as safe as the open one. But serious complications including death may occur. Overall mortality rate is approximately 0.03% [34] although some large series reported no mortality [60–63]. Most of these deaths occurred in the postoperative period and were due to hemorrhage [47], CO<sub>2</sub> gas embolism [64], and pulmonary embolism [34]. The risk of a major intraoperative hemorrhage during LLDN is between 0.6 and 1.6% [60, 63]. Conversion to open surgery has been reported to occur in 0 to 13% of cases, but in most large series, conversion rates of 1–2% are reported [4, 60–63]. Other intraoperative complications are splenic or liver laceration, ureteral and intestinal injury, and pleural laceration. The total incidence of surgical complications is 5.46% [61]. All major complications occurred in the first 100 cases [62]. This raises the question of the learning curve and how many laparoscopic nephrectomies should be done before performing the first LLDN? There is no precise answer but a number between 50 and 100 seems to be convincing for this type of surgery to be learned.

Postoperative complications of LLDN are hematomas, fever, urinary tract infection, pneumonia, pulmonary embolism, wound infection, incisional hernias, prolonged ileus, chylous ascites, and left testicular pain perhaps due to gonadal vein

division or extensive mobilization of the left colon which may damage the neural plexus supplying the testis and may also disrupt lymphatic drainage [65]. Chylous leakage is a rare complication of LLDN. Prevention is assured by doing a meticulous and extensive clipping of lymphatic channels along the dissection area [52, 66].

Long-term complications are arterial hypertension, renal failure, and proteinuria, particularly in more high-risk donors, such as those with obesity, old or young donors, hypertensive donors, and those with kidney stones [67, 68]. Following kidney donation, there is a compensatory increase in function in the remaining kidney. By 3 months, remnant kidney clearance increases to a mean GFR of around 65–75% of predonation renal function [4]. The average decrease in GFR after donation was 26 mL/min/1.73 m<sup>2</sup> (range 8–50) [4, 69]. The incidence of end-stage renal disease (ESRD) in living kidney donors appears to be similar to or lower than that seen in the unselected general population despite a reduction in GFR [4, 24, 70]. The estimated lifetime risk of ESRD was 90 per 10,000 in donors, 326 per 10,000 in the general population, and 14 per 10,000 in matched healthy nondonor controls [71]. Live donor nephrectomy alone will not lead to renal failure [72].

Concerning hypertension, a large meta-analysis demonstrated that donors have an increased systolic blood pressure of 5 mmHg after 5–10 years from donation [73]. The rate of hypertension in donors was similar to that of the general population [74]. But it seems that there are no effects on kidney function and microalbuminuria at least in Caucasian population. Blacks and Hispanics may have higher risks of hypertension-associated kidney disease after donation [75, 76].

Finally, it is interesting to know that longevity of live donors remains greater compared to the general population [24, 72, 77].

## **7. Conclusion**

Living donation is a success story that saved many patients with end-stage renal disease from dialysis and offered them a better quality of life and longer life expectancy. Donor surgery has shifted from the old open technique to a mini-invasive approach that offers less pain to this category of people who are not true patients but true heroes full of courage and nobility. Ensuring the safety and excellent long-term outcomes of these donors is our duty, through all steps from preoperative workup, surgery, and postoperative care.

Donors must be aware of all potential complications before acceptance and should feel free to resign at any moment. Complications of LLDN are present and must be prevented by entrusting them to highly qualified and experienced surgeons.

IntechOpen

## Author details

Maroun Moukarzel<sup>1\*</sup>, Charbel Chalouhy<sup>1</sup>, Nabil Harake<sup>1</sup> and Freda Richa<sup>2</sup>

<sup>1</sup> Division of Urology and Kidney Transplantation, Hôtel Dieu de France University Hospital, Saint Joseph University Medical School, Beirut, Lebanon

<sup>2</sup> Anesthesia and Intensive Care Department, Hôtel Dieu de France University Hospital, Saint Joseph University Medical School, Beirut, Lebanon

\*Address all correspondence to: [marounmoukarzel@gmail.com](mailto:marounmoukarzel@gmail.com)

## IntechOpen

© 2018 The Author(s). Licensee IntechOpen. This chapter is distributed under the terms of the Creative Commons Attribution License (<http://creativecommons.org/licenses/by/3.0>), which permits unrestricted use, distribution, and reproduction in any medium, provided the original work is properly cited. 



## References

- [1] US Government Information on Organ Donation and Transplantation. Available from: <https://organdonor.gov> [Accessed: 24 June, 2018]
- [2] Delaporte V. Transplantation rénale à partir d'un donneur vivant. *Progrès en Urologie*. 2011;**21**:789-792. DOI: 10.1016/j.purbl.2011.09.003
- [3] Hiesse C. Kidney transplantation epidemiology in France. *Néphrologie & Thérapeutique*. 2013;**9**(6):441-450. DOI: 10.1016/j.nepho.2013.02.002
- [4] Guidelines for Living Donor Kidney Transplantation. Fourth Edition: March 2018. British Transplantation Society and The Renal Association. BTS/RA. <http://www.bts.org.uk>
- [5] Global Observatory on Donation and Transplantation. Available from: <http://www.transplant-observatory.org/Pages/Home.aspx> [Accessed: 24 June, 2018]
- [6] Ali A, Hendawy A. Renal transplantation in the Middle East: Strengths, weaknesses, opportunities and threats (SWOT) analysis. *Urology & Nephrology Open Access Journal*. 2015;**2**(2):00028. DOI: 10.15406/unoaj.2015.02.00028
- [7] Shaheen FA, Souqiyyeh MZ. Current obstacles to organ transplant in Middle Eastern countries. *Experimental and Clinical Transplantation*. 2015;**13**(Suppl 1):1-3. PMID: 25894118
- [8] International Registry in Organ Donation and Transplantation. Available from: <http://www.irodat.org/?p=database> [Accessed: 27 June, 2018]
- [9] Gill J, Joffres Y, Rose C, Lesage J, Landsberg D, Kadatz M, et al. The change in living kidney donation in women and men in the United States (2005-2015): A population-based analysis. *Journal of the American Society of Nephrology*. 2018;**29**:1301-1308; published ahead of print March 8, 2018. DOI: 10.1681/ASN.2017111160
- [10] Michon L, Hamburger J, Oeconomos N, Delinotte P, Richet G, Vaysse J, et al. An attempted kidney transplantation in man: Medical and biological aspects. *Presse Médicale*. 1953;**61**:1419-1423
- [11] Timsit MO, Kleinclauss F, Thuret R. History of kidney transplantation surgery. *Progrès en Urologie*. 2016;**26**:874-881. DOI: 10.1016/j.parol.2016.08.003
- [12] History of Renal Transplant—Renal Medicine. Available from: [www.renalmed.co.uk/history-of/renal-transplant](http://www.renalmed.co.uk/history-of/renal-transplant) [Accessed: 27 June, 2018]
- [13] Merrill JP, Murray JE, Harrison J, Guild W. Successful homotransplantation of the human kidney between identical twins. *Journal of the American Medical Association*. 1956;**160**(4):277-282. PMID: 13278189
- [14] Murray JE. Edith Helm (April 29, 1935–April 4, 2011): The world's longest surviving transplant recipient: Letter to the editor. *American Journal of Transplantation*. 2011;**11**:1545-1546. DOI: 10.1111/j.1600-6143.2011.03607.x
- [15] Joseph E Murray. Nobel Prize Lecture: The first successful transplants in man. Presented on 8 December 1990, at Karolinska Institutet, Stockholm
- [16] Squifflet J-P, De Meyer M, Malaise J, Latinne D, Pirson Y, Alexandre GPJ. Lessons learned from ABO-incompatible living donor kidney transplantation: 20 years later. *Experimental and Clinical Transplantation*. 2004;**2**(1):208-213. PMID: 15859930
- [17] Takahashi K, Saito K, Takahara S, Okuyama A, Tanabe K, Toma H,

- et al. Excellent long-term outcome of ABO-incompatible living donor kidney transplantation in Japan. *American Journal of Transplantation*. 2004;**4**(7):1089-1096. PMID: 15196066. DOI: 10.1111/j.1600-6143.2004.00464.x
- [18] Tai Yeon Koo, Jaeseok Yang. Current progress in ABO-incompatible kidney transplantation; open access article under the CC BY-NC-ND license (<http://creativecommons.org/licenses/by-nc-nd/4.0/>). DOI 10.1016/j.krcp.2015.08.005
- [19] Ratner LE, Ciseck LJ, Moore RG, Cigarroa FG, Kaufman HS, Kavoussi LR. Laparoscopic live donor nephrectomy. *Transplantation*. 1995;**60**(9):1047-1049. [MEDLINE: 7491680]
- [20] Karpinski M, Knoll G, Cohn A, et al. The impact of accepting living kidney donors with mild hypertension or proteinuria on transplantation rates. *American Journal of Kidney Diseases*. 2006;**47**:317-323
- [21] Townsend RR, Reese PP, Lim MA. Should living kidney donors with hypertension be considered for organ donation? *Current Opinion in Nephrology and Hypertension*. 2015;**24**(6):594-601. DOI: 10.1097/MNH.0000000000000169
- [22] Delmonico F. A report of the Amsterdam Forum on the care of the live kidney donor: Data and medical guidelines. *Transplantation*. 2005;**79**:S53
- [23] Nguyen NT, Magno CP, Lane KT, Hinojosa MW, Lane JS. Association of hypertension, diabetes, dyslipidemia, and metabolic syndrome with obesity: Findings from the national health and nutrition examination survey, 1999 to 2004. *Journal of the American College of Surgeons*. 2008;**207**:928-934
- [24] Segev DL, Muzaale AD, Caffo BS, et al. Perioperative mortality and long-term survival following live kidney donation. *Journal of the American Medical Association*. 2010;**303**:959-966
- [25] Lentine KL, Lam NN, Axelrod D, et al. Perioperative complications after living kidney donation: A national study. *American Journal of Transplantation*. 2016;**16**:1848-1857
- [26] Johnson SR et al. Older living donors provide excellent quality kidneys: A single center experience (older living donors). *Clinical Transplantation*. 2005;**19**(5):600-606
- [27] Weinstein SH, Navarre RJ, Loening SA, Corry RJ. Experiences with live donor nephrectomy. *The Journal of Urology*. 1980;**124**:321-323
- [28] Pei Y, Obaji J, Dupuis A, et al. Unified criteria for ultrasonographic diagnosis of ADPKD. *Journal of the American Society of Nephrology*. 2009;**20**:205-212
- [29] Mandelbrot DA, Pavlakis M, Danovitch GM, Johnson SR, Karp SJ, Khwaja K, et al. The medical evaluation of living kidney donors: A survey of US transplant centers. *American Journal of Transplantation*. 2007;**7**(10):2333-2343. [PubMed: 17845567]
- [30] Liu N et al. Maximizing the donor pool: Left versus right laparoscopic live donor nephrectomy—Systematic review and meta-analysis. *International Urology and Nephrology*. 2014;**46**(8):1511. DOI: 10.1007/s11255-014-0671-8. Epub Mar 5, 2014. <https://www.ncbi.nlm.nih.gov/pubmed/24595603>
- [31] Amézquita Y, Mendez C, Fernandez A, et al. Risk factors for early renal graft thrombosis: A case controlled study in grafts from the same donor. *Transplantation Proceedings*. 2008;**40**(9):2891-2893. DOI: 10.1016/j.transproceed.2008.09.014

- [32] Hsu JW, Reese PP, Naji A, Levine MH, Abt PL. Increased early graft failure in right-sided living donor nephrectomy. *Transplantation*. 2011;**91**(1):108-114. DOI: 10.1097/TP.0b013e3181fd0179
- [33] Joshi GP, Cunningham A. Anesthesia for laparoscopic and robotic surgeries. In: Barash PG, editor. *Clinical Anesthesia*. Vol. 7th. Philadelphia: Lippincott Williams Wilkins; 2013. pp. 1257-1273
- [34] Matas AJ, Bartlett ST, Leichtman AB, Delmonico FL. Morbidity and mortality after living kidney donation, 1999-2001: Survey of United States transplant centers. *American Journal of Transplantation*. 2003;**3**:830
- [35] Ong Sio LCL, Dela Cruz RGC, et al. A comparison of renal responses to sevoflurane and isoflurane in patients undergoing donor nephrectomy: A randomized controlled trial. *Medical Gas Research*. 2017;**7**(1):19-27. eCollection 2017 Jan-Mar
- [36] El-Galley R, Hammontree L, et al. Anesthesia for laparoscopic donor nephrectomy: Is nitrous oxide contraindicated? *The Journal of Urology*. 2007;**178**(1):225-227
- [37] Dolkart O et al. Pneumoperitoneum in the presence of acute and chronic kidney injury: An experimental model in rats. *The Journal of Urology*. 2014;**192**:1266-1271. DOI: 10.1016/j.juro.2014.03.114
- [38] Mertens zur Borg IRA, Di Biase M, Verbrugge S, IJzermans JNM, Gommers D. Comparison of three perioperative fluid regimes for laparoscopic donor nephrectomy: A prospective randomized dose-finding study. *Surgical Endoscopy*. 2008;**22**(1):146-150. Published online 24 May, 2007. PMID: PMC2169269; PMID: 17522928. DOI: 10.1007/s00464-007-9391-9
- [39] Brunschot D O-v, Scheffer GJ, van der Jagt M, Langenhuijsen H, Dahan A, Mulder JEEA, et al. Quality of recovery after low-pressure laparoscopic donor nephrectomy facilitated by deep neuromuscular blockade: A randomized controlled study. *World Journal of Surgery*. 2017;**41**:2950-2958. DOI: 10.1007/s00268-017-4080-x
- [40] Shirodkar SP, Gorin MA, Sageshima J, et al. Technical modification for laparoscopic donor nephrectomy to minimize testicular pain: A complication with significant morbidity. *American Journal of Transplantation*. 2011;**11**:1031-1034
- [41] Kim FJ, Pinto P, Su LM, et al. Ipsilateral orchialgia after laparoscopic donor nephrectomy. *Journal of Endourology*. 2003;**17**:405-409
- [42] Kocak B, Baker TB, Koffron AJ, Leventhal JR. Ureteral complications in the era of laparoscopic living donor nephrectomy: Do we need to preserve the gonadal vein with the specimen? *Journal of Endourology*. 2010;**24**:247-251
- [43] Banga N, Nicol D. Techniques in laparoscopic donor nephrectomy. *BJU International*. 2012;**110**:1368-1373. DOI: 10.1111/j.1464-410X.2012.11058.x
- [44] Simforoosh N, Bassiri A, Ziaee SA, Maghsoodi R, Salim NS, Shafi H, et al. Laparoscopic versus open live donor nephrectomy: The first randomized clinical trial. *Transplantation Proceedings*. 2003;**35**:2553-2554
- [45] Arévalo Pérez J, Gragera Torres F, Marín Toribio A, et al. Angio CT assessment of anatomical variants in renal vasculature: Its importance in the living donor. *Insights into Imaging*. 2013;**4**:199. DOI: 10.1007/s13244-012-0217-5
- [46] Rosenblatt GS, Conlin MJ. Clipless management of the renal vein during hand-assist laparoscopic donor nephrectomy. *BMC Urology*. 2006;**6**:23



- [47] Friedman AL, Peters TG, Jones KW, Boulware LE, Ratner LE. Fatal and nonfatal hemorrhagic complications of living kidney donation. *Annals of Surgery*. 2006;**243**:126-130
- [48] Ahearn AJ, Posselt AM, Kang SM, Roberts JP, Freise CE. Experience with laparoscopic donor nephrectomy among more than 1000 cases: Low complication rates, despite more challenging cases. *Archives of Surgery*. 2011;**146**:859-864. [PMID: 21768434]. DOI: 10.1001/archsurg.2011.156
- [49] Dekel Y, Mor E. Hem-o-lok clip dislodgment causing death of the donor after laparoscopic living donor nephrectomy. *Transplantation*. 2008;**86**:887
- [50] U.S. Food & Drug Administration. Available from: <https://www.fda.gov/> [Accessed: 27 July, 2018]
- [51] Hsi RS, Ojogho ON, Baldwin DD. Analysis of techniques to secure the renal hilum during laparoscopic donor nephrectomy: Review of the FDA database. *Urology*. 2009;**74**:142-147
- [52] Capocasale E, Iaria M, Vistoli F, et al. Incidence, diagnosis, and treatment of chylous leakage after laparoscopic live donor nephrectomy. *Transplantation*. 2012;**93**(1):82-86
- [53] Box GN, Lee HJ, Abraham JB, et al. Comparative study of in vivo lymphatic sealing capability of the porcine thoracic duct using laparoscopic dissection devices. *The Journal of Urology*. 2009;**181**(1):387-391
- [54] Kawamoto S, Fishman EK. MDCT angiography of living laparoscopic renal donors. *Abdominal Imaging*. 2006;**31**:361-373
- [55] Sebastià C, Peri L, Salvador R, Buñesch L, Revuelta I, Alcaraz A, et al. Multi-detector CT of living renal donors: Lessons learned from surgeons. *Radiographics*. 2010;**30**:1875-1890
- [56] Keller JE, Dolce CJ, Griffin D, Heniford BT, Kercher KW. Maximizing the donor pool: Use of right kidneys and kidneys with multiple arteries for live donor transplantation. *Surgical Endoscopy*. 2009;**23**:2327-2331. [PMID: 19263162]. DOI: 10.1007/s00464-009-0330-9
- [57] Breda A, Bui MH, Liao JC, Schulam PG. Association of bowel rest and ketorolac analgesia with short hospital stay after laparoscopic donor nephrectomy. *Urology*. 2007;**69**(5):828-831. PMID: 17482915. DOI: 10.1016/j.urology.2007.01.083
- [58] Wang J, Ma H, et al. Comparison of postoperative morphine requirements in renal donors and patients with renal carcinoma undergoing laparoscopic nephrectomy. *Transplantation Proceedings*. 2016;**48**(1):31-34
- [59] Rege A, Leraas H, et al. Could the use of an enhanced recovery protocol in laparoscopic donor nephrectomy be an incentive for live kidney donation? *Cureus*. 2016;**8**(11). DOI: 10.7759/cureus.889
- [60] Chin EH, Hazzan D, Herron DM, et al. Laparoscopic donor nephrectomy: Intraoperative safety, immediate morbidity, and delayed complications with 500 cases. *Surgical Endoscopy*. 2007;**21**:521-526
- [61] Harper JD, Breda A, Leppert JT, Veale JL, Gritsch HA, Schulam PG. Experience with 750 consecutive laparoscopic donor nephrectomies—Is it time to use a standardized classification of complications? *The Journal of Urology*. 2010;**183**:1941-1946
- [62] Jacobs SC, Cho E, Foster C, Liao P, Bartlett ST. Laparoscopic donor nephrectomy: The University of



Maryland 6-year experience. The Journal of Urology. 2004;**171**:47-51

[63] Mjoen G, Oyen O, Holdaas H, Midtvedt K, Line PD. Morbidity and mortality in 1022 consecutive living donor nephrectomies: Benefits of a living donor registry. Transplantation. 2009;**88**:1273-1279

[64] Boghossian T, Henri M, Dube S, Bendavid Y, Morin M. Laparoscopic nephrectomy donor death due to cerebral gas embolism in a specialized transplant center: Risk zero does not exist. Transplantation. 2005;**79**:258-259

[65] Jalali M, Rahmani S, Joyce AD, Cartledge JJ, Lewis MH, Ahmad N. Laparoscopic donor nephrectomy: An increasingly common cause for testicular pain and swelling. Annals of the Royal College of Surgeons of England. 2012;**94**:407-410. DOI: 10.1308/003588412X13171221592177

[66] Shafizadeh SF, Daily PP, Baliga P, et al. Chylous ascites secondary to laparoscopic donor nephrectomy. Urology. 2002;**60**(2):345

[67] Reese PP, Feldman HI, McBride MA, Anderson K, Asch DA, Bloom RD. Substantial variation in the acceptance of medically complex live kidney donors across US renal transplant centers. American Journal of Transplantation. 2008;**8**:2062-2070. [PMID: 18727695]. DOI: 10.1111/j.1600-6143.2008.02361

[68] Nogueira JM, Weir MR, Jacobs S, Breault D, Klassen D, Evans DA, et al. A study of renal outcomes in obese living kidney donors. Transplantation. 2010;**90**:993-999. [PMID: 20844468]. DOI: 10.1097/TP.0b013e3181f6a058

[69] Lipkin G, Fenton A, Montgomery E, Nightingale P, Peters M, Wroe C. Age and gender-specific normal range for GFR in over 2500 potential UK live kidney donors; implications for

selection and outcomes of live kidney donors. [https://bts.org.uk/wp-content/uploads/2016/09/BTS\\_Abstract\\_pdf\\_2016.pdf](https://bts.org.uk/wp-content/uploads/2016/09/BTS_Abstract_pdf_2016.pdf)

[70] Mjoen G, Hallan S, Hartmann A, et al. Long-term risks for kidney donors. Kidney International. 2014;**86**:162-167

[71] Muzaale AD, Massie AB, Wang MC, et al. Risk of end-stage renal disease following live kidney donation. Journal of the American Medical Association. 2014;**311**:579-586

[72] Ibrahim HN et al. Long-term consequences of kidney donation. The New England Journal of Medicine. 2009;**360**(5):459-469

[73] Boudville N, Prasad GV, Knoll G, Donor Nephrectomy Outcomes Research (DONOR) Network, et al. Meta-analysis: Risk for hypertension in living kidney donors. Annals of Internal Medicine. 2006;**145**:185-196

[74] Garg AX, Prasad GV, Thiessen-Philbrook HR, et al. Cardiovascular disease and hypertension risk in living kidney donors: An analysis of health administrative data in Ontario, Canada. Transplantation. 2008;**86**:399-406

[75] Textor SC, Taler SJ, Driscoll N, et al. Blood pressure and renal function after kidney donation from hypertensive living kidney donors. Transplantation. 2004;**78**:276-282

[76] Sofue T, Unui M, Hara T, et al. Short-term prognosis of living-donor kidney transplantation from hypertensive donors with high-normal albuminuria. Transplantation. 2015;**97**:104-110

[77] Fehrman-Ekholm I, Norden G, Lennerling A, et al. Incidence of end stage renal disease among live kidney donors. Transplantation. 2006;**82**:1646-1648