

# We are IntechOpen, the world's leading publisher of Open Access books Built by scientists, for scientists

6,900

Open access books available

185,000

International authors and editors

200M

Downloads

Our authors are among the

154

Countries delivered to

TOP 1%

most cited scientists

12.2%

Contributors from top 500 universities



WEB OF SCIENCE™

Selection of our books indexed in the Book Citation Index  
in Web of Science™ Core Collection (BKCI)

Interested in publishing with us?  
Contact [book.department@intechopen.com](mailto:book.department@intechopen.com)

Numbers displayed above are based on latest data collected.  
For more information visit [www.intechopen.com](http://www.intechopen.com)



# New Paradigms in Endometriosis Surgery of the Distal Ureter

*José Anacleto Dutra de Resende Júnior,  
Rodrigo Ribeiro Vieirals, Renata Teles Buere  
and Claudio Peixoto Crispi*

## Abstract

It is estimated that 2% of endometriosis cases involve the urinary tract and that the ureter is involved in up to 30% of these cases, or 0.6% of all endometriosis cases. Increasingly, the standardization and systematization of surgical treatment of endometriosis require the surgeon to have knowledge of the surgical spaces and the ureteral and surrounding pelvic anatomy in order to carry out a cytoreductive surgery that is as possible. A thorough workup is essential for the differentiation of intrinsic or extrinsic endometriosis of the ureter. The use of the resonance imaging preoperatively and ureteroscopy intraoperatively is now considered indispensable. The decision and choice of the best technique will be guided by the diagnosis (intrinsic or extrinsic), the location of the lesions, the length of the involved segment (greater or less than 3 cm), vitality of the ureter stumps, and anastomosis without tension. The main alternatives are ureterolysis and dilatation with balloon catheter which is performed for extrinsic endometriosis more than 85% of the time and ureterectomy for intrinsic endometriosis. To perform the reconstruction, the techniques with end-to-end anastomosis with the distal ureter stump or ureterovesical reimplantation are used. Increasingly, with better knowledge of the distal ureter anatomy, easier access through laparoscopy and in contradiction to the current recommendations, we are verifying that the end-to-end anastomosis has become the preferred option *or* procedure of choice for ureteral reconstruction, with ureterovesical reimplantation the second option.

**Keywords:** endometriosis, ureter, laparoscopic surgery, new technique, new surgical approach

## 1. Introduction

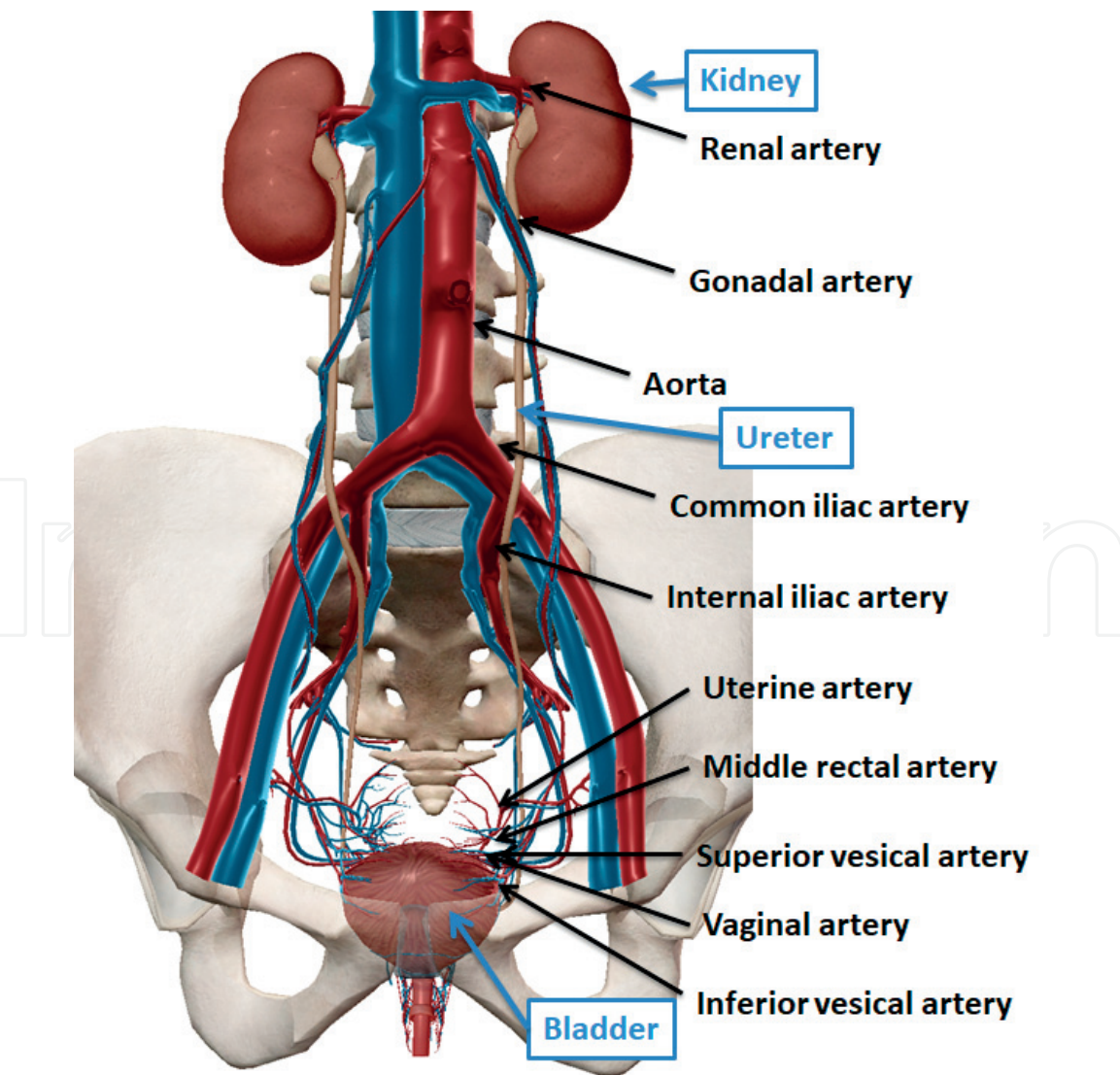
Endometriosis involving the urinary tract is rare, affecting only 1–2% of women with endometriosis. The vast majority of these cases – 80–85% involve the bladder. Ureteral endometriosis occurs in just 15% of cases. Ureteral involvement usually occurs near its insertion in the bladder, just above the ureterovesical junction (UVJ), near where it crosses the uterine artery [1–6]. We believe that this prevalence is underestimated due to the scarce data in the literature and the lack of standardization of the surgical technique around the world in different countries. Based on our practical experience, we believe that extrinsic ureter involvement is

more prevalent than the data in the literature would suggest, and may exceed 30% of all surgeries for multicompartmental deep endometriosis, especially when there is intestinal (rectal/sigmoid) infiltration and/or parametrical infiltration. Thus, knowledge of ureteral endometriosis and its management are of fundamental importance for surgeons who propose to perform comprehensive treatment of the various presentations of endometriosis.

## 2. Ureter anatomy

The ureter connects the renal pelvis to the bladder, typically measuring 20–30 cm in length. It is a tubular conduit with a smooth muscle structure that confers a capacity for peristalsis. The ureter’s course is entirely retroperitoneal; for didactic purposes it is divided into two portions: abdominal and pelvic. The abdominal portion maintains an important relation with the psoas muscle and gonadal vessels, traveling laterally to the latter throughout its abdominal course. Before penetrating the pelvis, uteter passes anteriorly to the iliac vessels, and the pelvic segment initially accompanies the internal iliac artery (**Figure 1**).

In the female, the pelvic segment of the ureter penetrates the parametrium and courses between the uterine artery (above) and vaginal artery (below). At this



**Figure 1.**  
*Vascular supply of the uterers and their relation to the great vessels.*

point, great care must be taken in its identification, as iatrogenic injuries of the ureter may occur during pelvic surgeries.

The ureter is irrigated by multiple arteries along its course, starting with the renal, gonadal, aorta and common iliac arteries. More distally in its pelvic segment the ureter is supplied by the internal iliac, superior vesicle, uterine, medial rectal arteries, vaginal, and inferior vesicle arteries (**Figure 1**). As they approach the ureter, the arterial branches travel along a longitudinal pathway within the adventitia (ureteral sheath), forming anastomotic bundles. In this way the surgical dissection of the ureter should strive to preserve the adventitia in order to avoid ischemia.

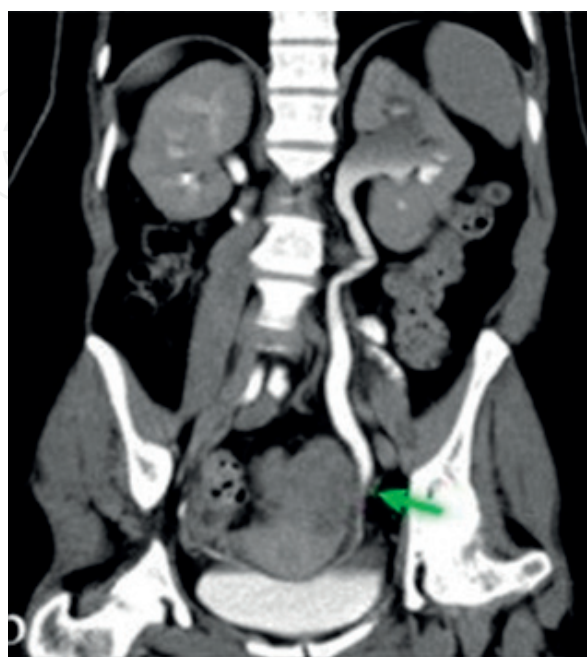### 3. Classification: extrinsic versus intrinsic

Endometriosis can infiltrate the ureter intrinsically or extrinsically. When extrinsic – 80–90% of such cases – the endometriosis infiltrates the adventitia and/or submucosa. When intrinsic (the remainder of cases), the disease infiltrates the mucosa and submucosa and may present as ureteral stenosis [5, 7].

### 4. Clinical and imaging work-up

A thorough history and physical examination are essential in order to recognize or suspect urological impairment secondary to endometriosis. The patient may be asymptomatic or experience cyclical renal colic and hematuria during the menstrual period. In intrinsic cases the endometriosis may progress to obstruct the lumen of the ureter, whereas in extrinsic cases there can be circumferential or annular (extrinsic) compression. Both are capable of insidiously causing partial and even complete loss of renal function in one or both kidneys.

Assessment using imaging studies is indispensable for surgical planning. Not all anatomical sites are accessible to ultrasound. Magnetic resonance imaging can identify and assess hemorrhagic components of endometriomas throughout the pelvis, and thus is the preferred imaging method to assess ureteral involvement (**Figure 2**).



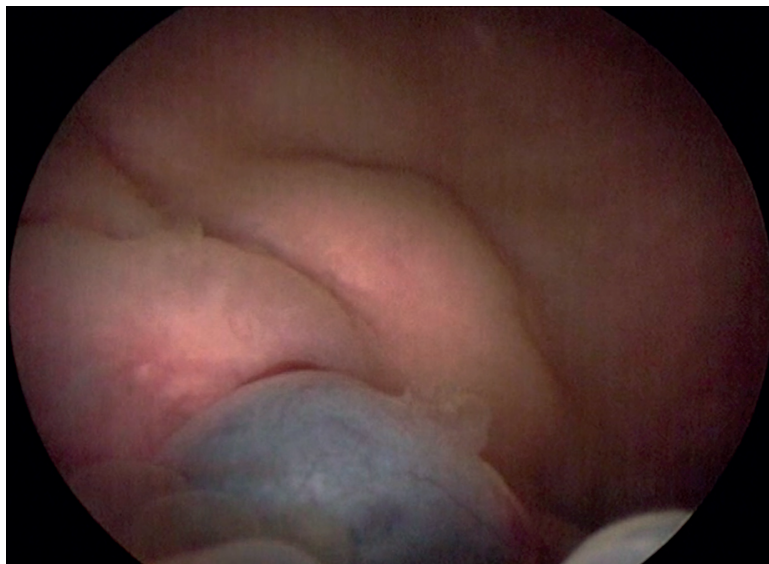
**Figure 2.**  
*Endometriosis infiltrating the left ureter (green arrow) generating ureterohydronephrosis.*



In cases in which impaired renal function is known or suspected, static and dynamic renal scintigraphy should be ordered, and endoscopic investigation (ureteroscopy) contemplated to inform surgical planning.

Preoperative cystoscopy to evaluate bladder endometriosis is necessary especially when a non-invasive imaging method (MRI or ultrasonography) identifies lesions which are suspicious for endometriosis in the compartment anterior to the uterus. In the cases of lesions infiltrating the bladder mucosa, it is important to determine the exact location(s), their size and their distance from the two ureteral ostia, as well as any projection into the ureter intramurally.

Such findings could help determine which surgical approach should be used; options range from simple ureterolysis to ureterectomy with uretero-ureteral anastomosis or a ureterovesical reimplantation. Concomitant cystoscopy with vaginal palpation is important to assess disease or areas of adhesions localized in the vesico-uterine septum that may suggest the need for partial cystectomy or suture-reinforced bladder shaving (**Figure 3**).



**Figure 3.**  
*Endometriosis infiltrating the bladder trigone and right ureteral ostium as visualized during cystoscopy.*

## **5. Preoperative preparation**

It is advisable to perform outpatient urinary sediment (EAS) and urine culture studies preoperatively to ensure sterile urine during the procedure.

Antimicrobial prophylaxis should be administrated during the induction of anesthesia. Thromboembolic prophylaxis of the lower extremities with compressive or pneumatic stockings is also recommended.

## **6. Surgical treatment**

Treatment of endometriosis should be individualized. The laparoscopic approach, robot-assisted or not, has become the option of choice for most surgeons [8, 9]. We observed that through accumulated experience and continuous training, it becomes possible to carry out increasingly complex cases laparoscopically, affording the patient all the advantages and benefits of minimally invasive techniques.

### 6.1 Laparoscopic tools and materials used

The basic laparoscopic surgical tools required include non-traumatic grasping forceps, Maryland forceps, laparoscopic scissors, laparoscopic needle holders and contra-need holders, as well as an articulating Hook with monopolar cautery. No special clamps are required for this procedure. Bipolar or ultrasonic clamps when available will help with the dissection and hemostasis, reducing surgical time.

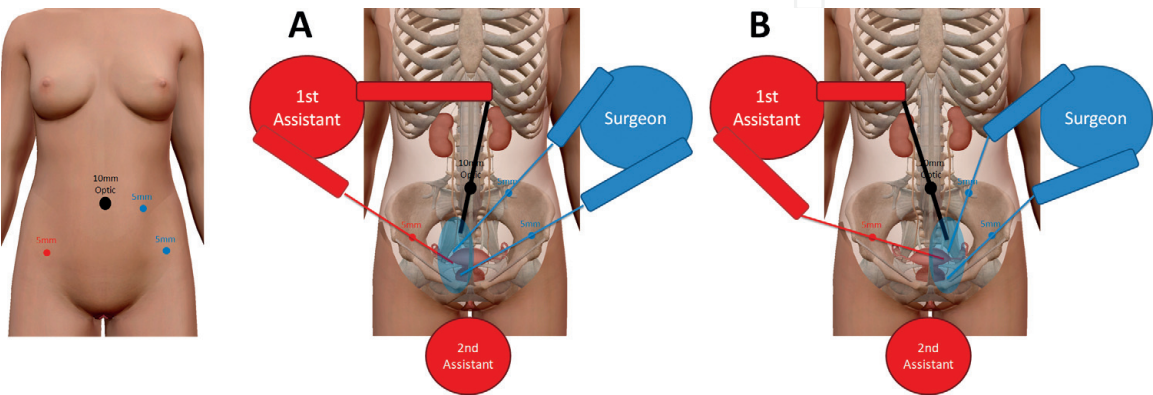
Contemplating the possibility of a joint intervention – laparoscopy and cystoscopy/ureteroscopy – a cystoscope, ureteroscope, hydrophilic guidewire, and ureteral catheter should be available. If there is more intense manipulation or segmental resection of the ureter, double J catheter placement will be necessary, in order to ensure a patent ureter and adequate healing. It is worth mentioning that inoperative dynamic C-arm fluoroscopy should be available to verify proper positioning of the catheters.

### 6.2 Positioning the patient

How the patient is positioned for surgery will depend on the site of ureteral involvement. For the more common case of distal involvement, the patient should be placed in the Lloyd Davies and Trendelenburg position, lying directly on a non-adherent eggcrate foam pad. The legs should be wrapped in pneumatic stockings and secured to boot-like leggings, avoiding continuous compression of the calves.

### 6.3 Surgical approach: Access

The first puncture is performed in the umbilical scar where a 10 mm trocar is placed to introduce the optic (**Figure 4**–black circle) and the patient is kept in dorsal decubitus. After exploration of the cavity, the patient is placed in Trendelenburg (Lloyd Davies) position and the surgeon inserts two 5 mm trocars (**Figure 4**–blue circles) and a fourth trocar for the first assistant. The second assistant stands between the patient’s legs to manipulate the uterus after placement of the uterine manipulator (**Figure 4**–second assistant). With the surgical team members in these positions it is possible to perform ureterolysis, uretero-ureteral anastomosis and ureterovesical reimplantations on the right (**Figure 4-A**) or on the left (**Figure 4-B**).



**Figure 4.**  
*Trocar sites. Position of surgeons for access to the right distal ureter (A) and for access to the left distal ureter (B).*



6.4 Surgical approach–ureterolysis, ureterectomy and end-to-end anastomosis or ureteral replantation

In endometriosis that involves the ureter, we may encounter ureteral involvement due to fibrosis without extrinsic muscle/muscular infiltration or intrinsic endometriosis infiltrating the muscular layer and/or mucosa. It is only after ureterolysis of the entire affected section of the ureter and segments proximal and distal portions to the disease that the surgical approach can be assessed/determined (Figure 5) and (Figures 10–12). It is always important to perform a ureteroscopy (Figures 6 and 13) to evaluate the internal aspect/lumen of this ureter and if necessary to perform a frozen biopsy to confirm or rule out the possibility of intrinsic endometriosis.

With extrinsic disease – the majority of cases – with careful ureterolysis using “cold” scissors all disease can be removed without the need to resect any segment of the ureter (Figures 7 and 8). After a laborious ureterolysis, it is recommended that the narrowed segment be dilated using a ureteral balloon catheter dilator (Figure 9) endoscopically either by cystoscopy or ureteroscopy, with placement of a double J catheter for 30–60 days.

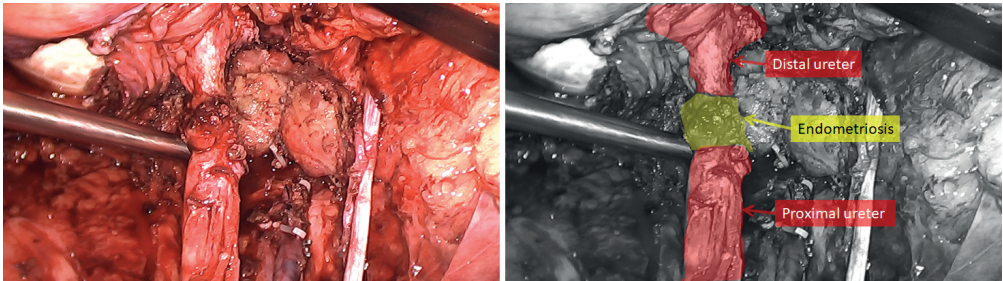


Figure 5.  
*Ureterolysis with identification of segments proximal and distal to the endometriosis.*

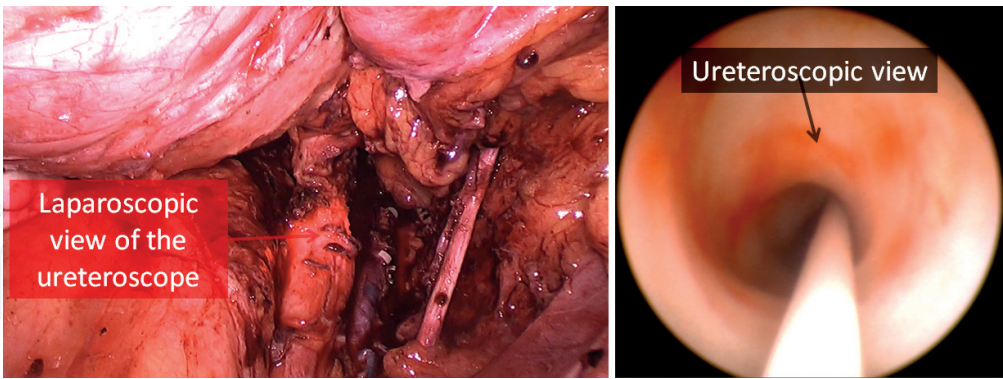


Figure 6.  
*Laparoscopic and ureteroscopic views of the ureteral segment with extrinsic endometriosis.*

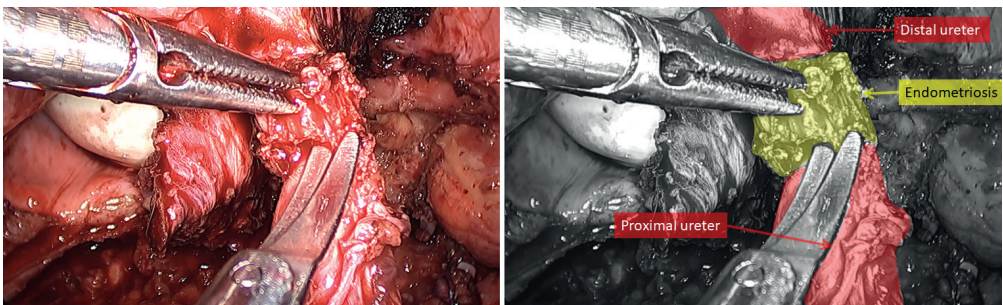
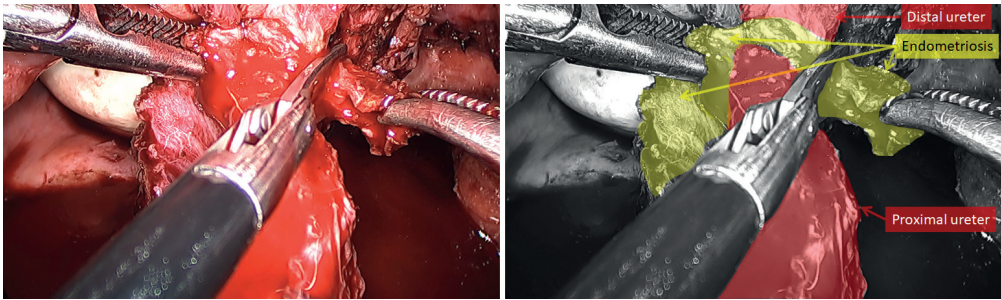
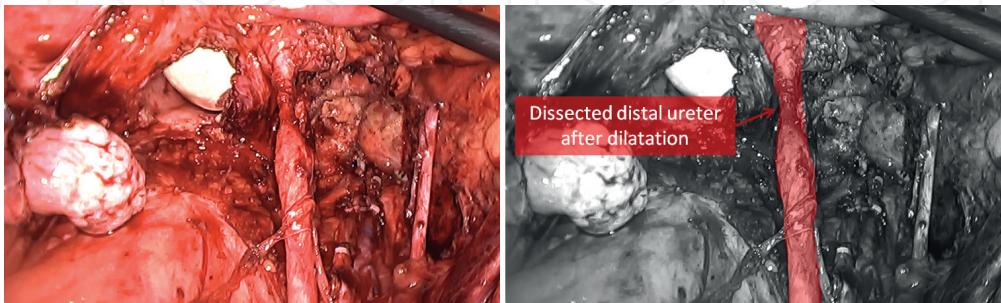


Figure 7.  
*Dissection of the ureter using scissors (without energy) - initiation of the freeing of the extrinsic endometriosis.*

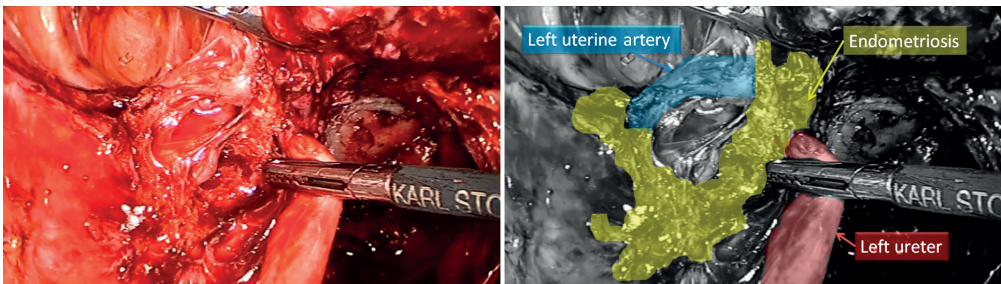



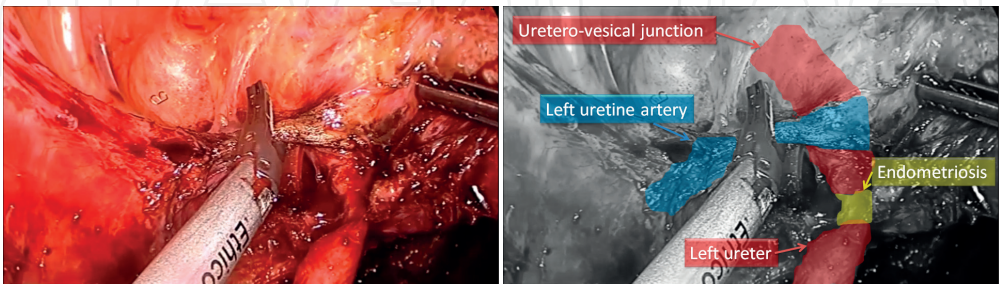
**Figure 8.**  
*Dissection of the ureter with freeing of the extrinsic endometriosis.*



**Figure 9.**  
*Dilatation of the stented segment using a balloon catheter (laparoscopic view) and posterior placement of the double J catheter.*



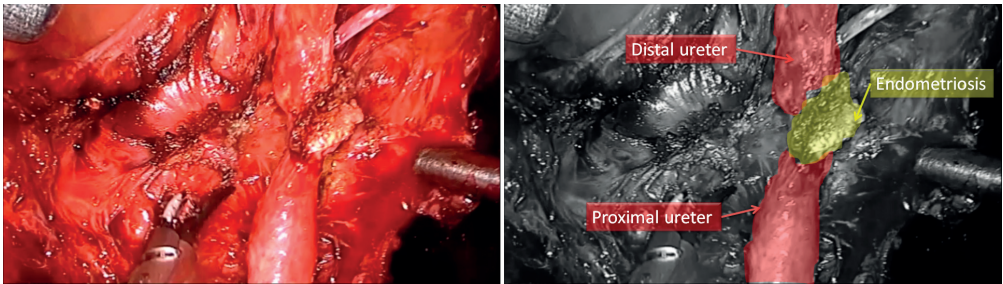
**Figure 10.**  
*Left parametric endometriosis involving the ureter at the intersection of the uterine artery.*



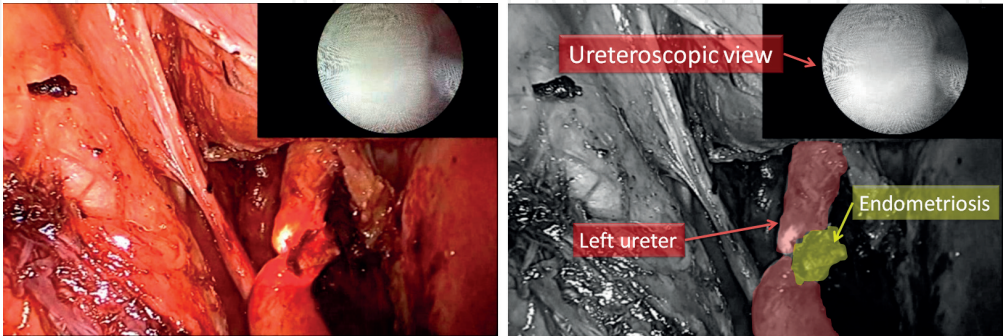
**Figure 11.**  
*Ligature of the uterine artery to access the distal ureter and identification of the uretero-vesical junction (UVJ).*

When ureteroscopy reveals intrinsic endometriosis (**Figure 13**), (typically 3–4 cm from the UVJ) ureterectomy of the involved segment is necessary (**Figures 10–16**) subject to consideration of the best surgical technique [10]. In those cases where the distal ureter stump (close to the UVJ) is greater than 1 cm, one can elect to perform an end-to-end ureteroureterostomy (**Figure 17**), another ureteroscopy after the anastomosis (**Figure 18**), with placement of a double J catheter [11, 12].

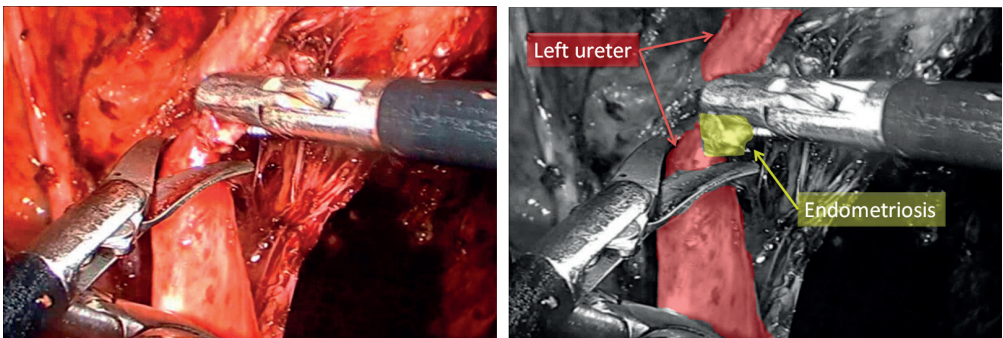




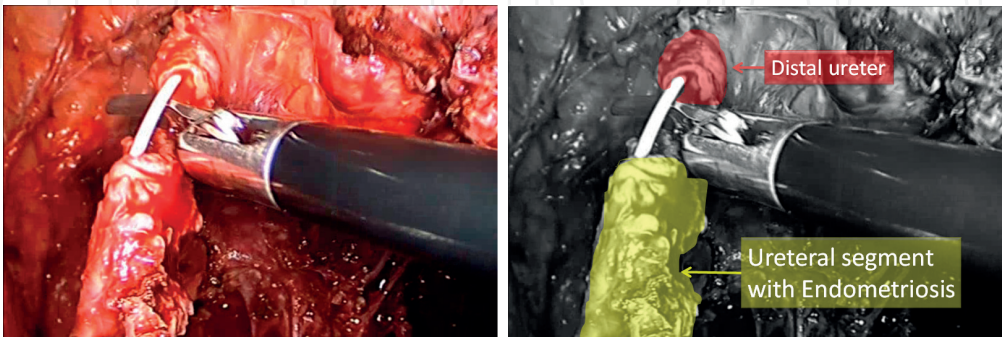
**Figure 12.**  
*Ureterolysis with identification of segments proximal and distal to the endometriosis.*



**Figure 13.**  
*Ureteroscopy with identification of the intrinsic lesion and obstruction to the passage of the ureterscope.*



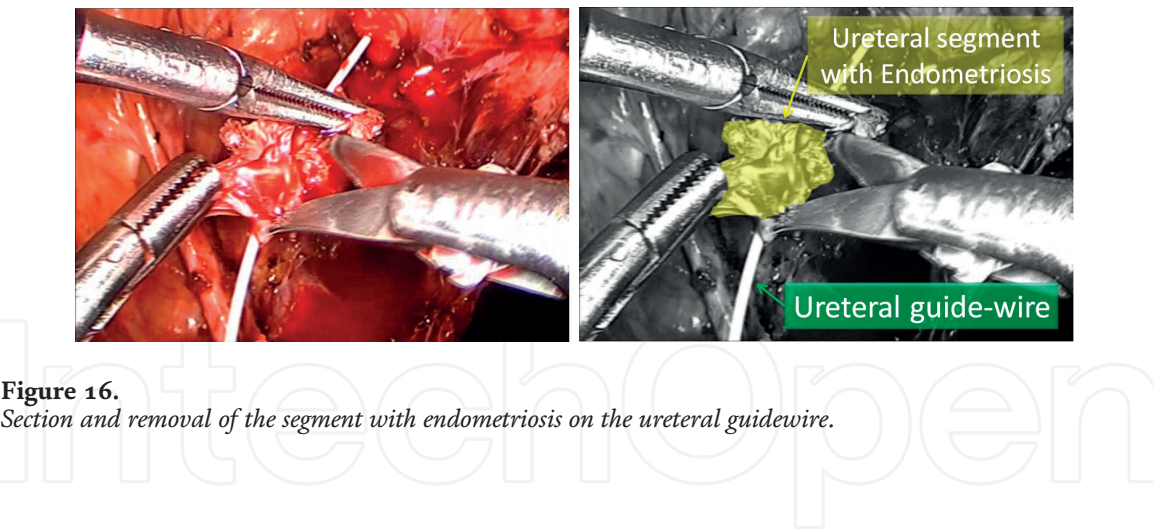
**Figure 14.**  
*Proximal ureterectomy. Section with spatulation of the ureter proximal to the lesion.*



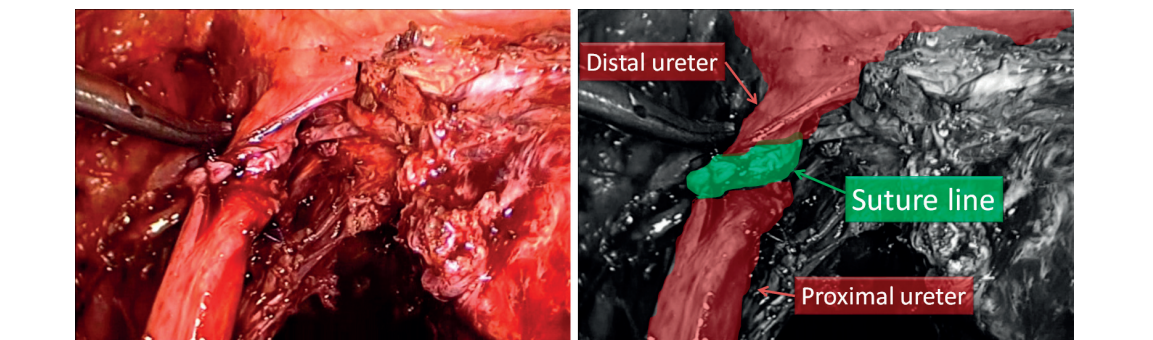
**Figure 15.**  
*Distal ureterectomy. Section with spreading of the ureter distal to the lesion and separation of the segment with endometriosis.*

In cases in which the distal ureteral stump is very small (less than 1 cm) or the endometriotic lesion infiltrates the ureter intramurally and the bladder (via the ureteral ostium), a uretero-vesical reimplantation is required [13, 14] (**Figures 19–26**).

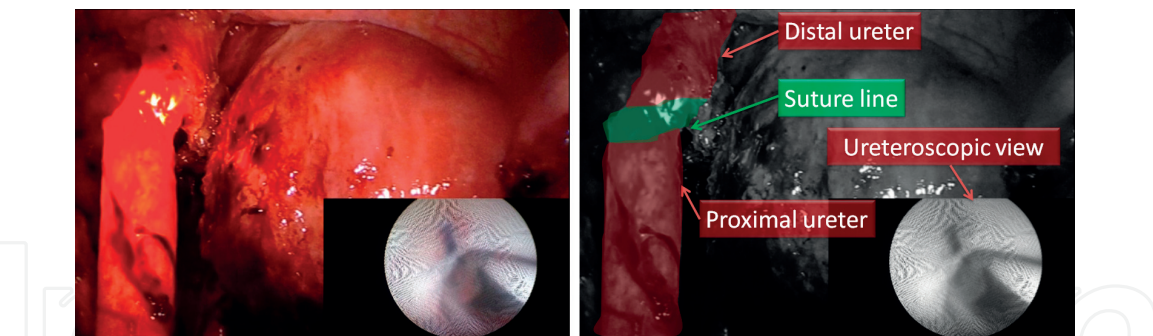




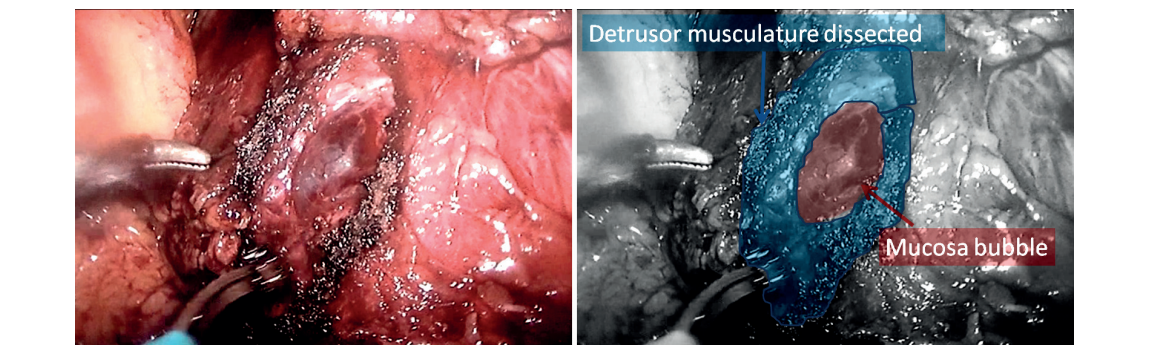
**Figure 16.**  
*Section and removal of the segment with endometriosis on the ureteral guidewire.*



**Figure 17.**  
*Uretero-ureteral anastomosis.*

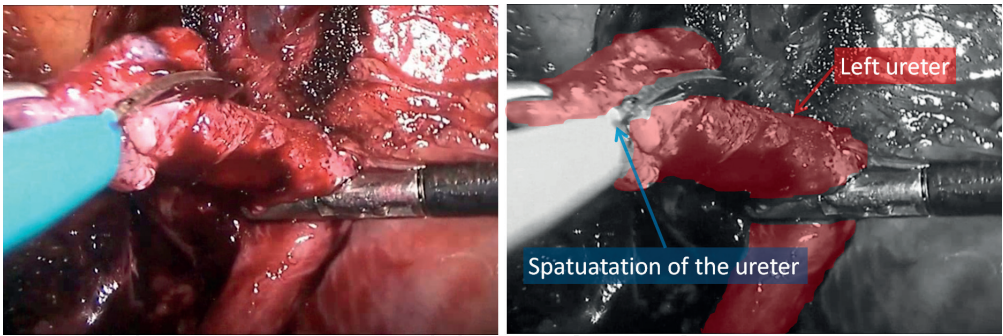


**Figure 18.**  
*Ureteroscopy of the suture line of the uretero-ureteral anastomosis.*

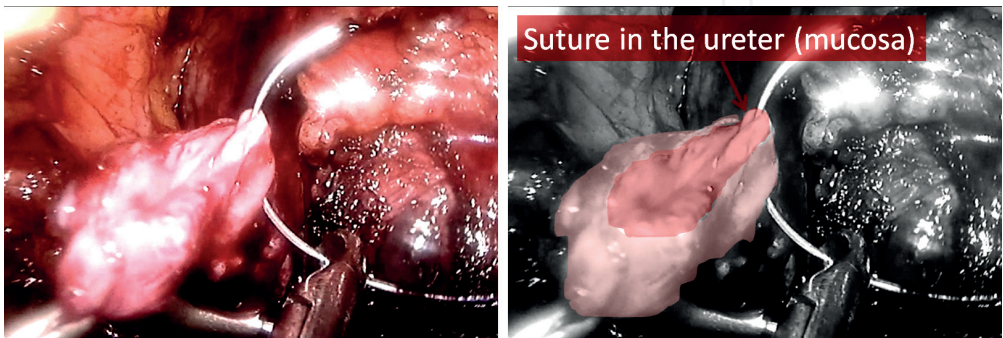


**Figure 19.**  
*Dissection of the detrusor muscles and confection of the mucosal blister.*

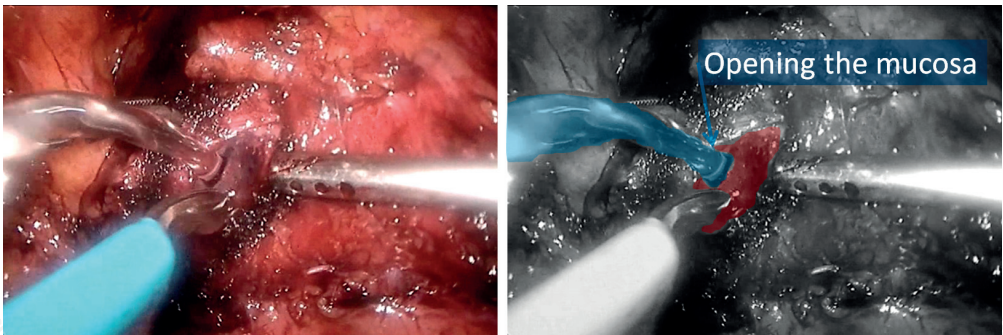




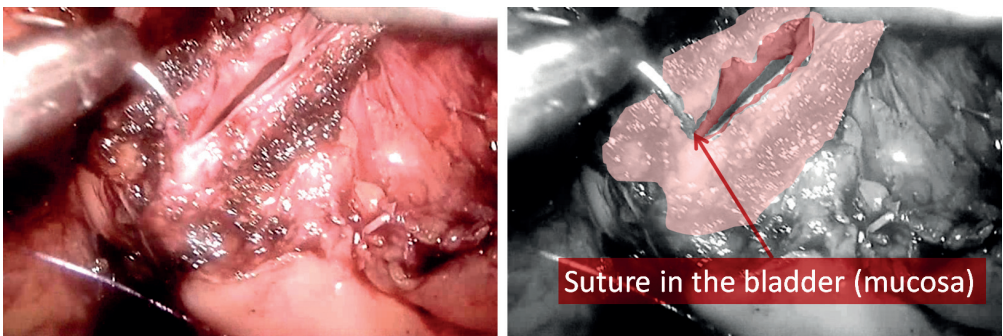
**Figure 20.**  
*Spatulation of the ureter to be implanted.*



**Figure 21.**  
*Starting the anastomosis: Suture in the ureter.*

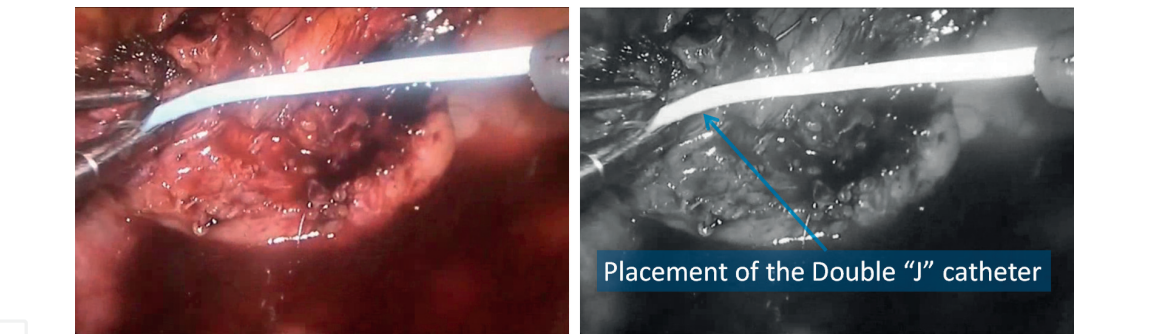


**Figure 22.**  
*Opening the bladder mucosa.*

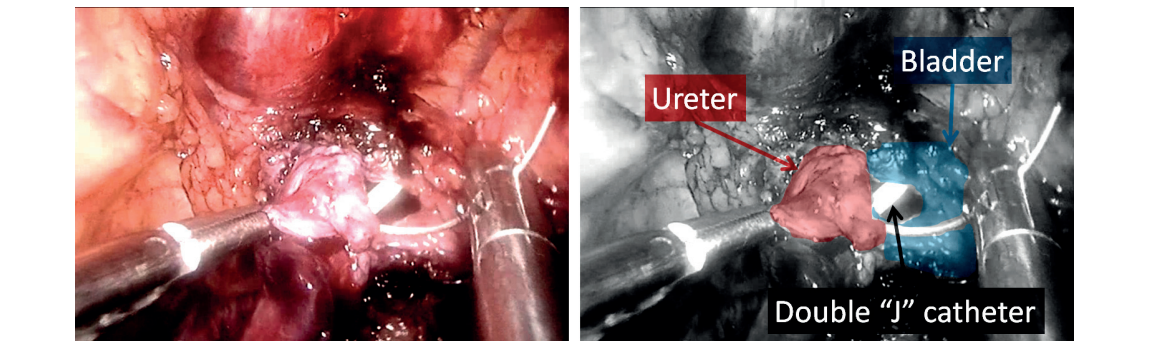


**Figure 23.**  
*First suture of the bladder anastomosis.*

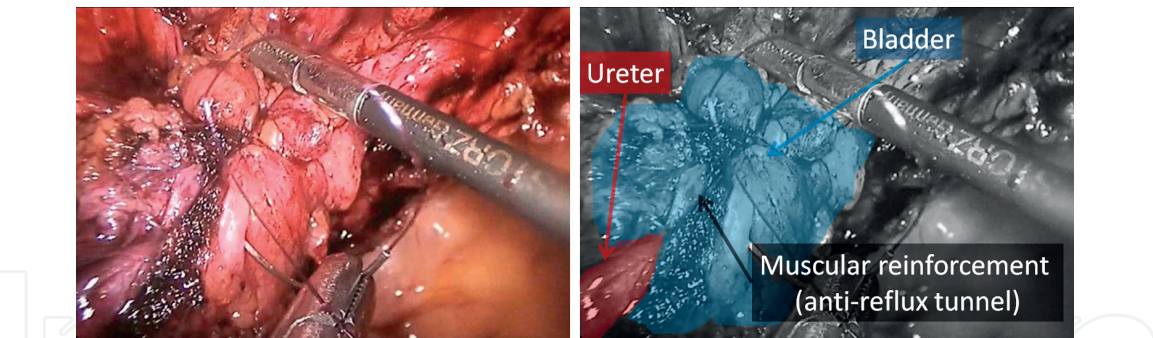




**Figure 24.**  
*Placement of the double “J” catheter.*



**Figure 25.**  
*End of uretero-vesical anastomosis.*



**Figure 26.**  
*Reinforcement suture of the detrusor muscles on the uretero-vesical anastomosis and on the distal ureter (anti-reflux tunnel).*

## 7. Post-operative care

As with all transperitoneal surgery, a period of adynamic ileus should be respected after the procedure. The progression of the diet should be individualized, but typically requires less than 8 hours. Early ambulation is essential in this context, and it also helps to minimize thromboembolic events. Early administration of enoxaparin (starting 12 hours after the end of surgery) is indicated unless there are contraindications. Antibiotic prophylaxis should be restricted to the intraoperative period and certainly should not be initiated more than 24 hours after the procedure [15].



## **8. Complications**

Given an experienced multidisciplinary team, complications should be proportional to the extent of the lesion(s). Specifically regarding ureteral endometriosis, in cases where there is a need for extensive ureterolysis, ureteral ischemia and urinary fistulas with the formation of urinomas can be observed. In cases of ureteral resection and anastomoses (uretero-ureteral anastomosis or ureteral reimplantation) anastomotic dehiscence may occur with formation of urinary fistulas. However, double J catheter placement dramatically reduces such complications. Another common complication is stenosis at the anastomosis site [9, 11, 14].

## **9. Conclusion**

The laparoscopic surgical treatment of ureteral endometriosis is feasible provided the surgeon is trained in laparoscopic surgery and has knowledge of the ureteral anatomy and its anatomical relationships. These conditions being met, laparoscopic surgical treatment of ureteral endometriosis can be considered safe, with low rates of postoperative complications and low morbidity.

## **Acknowledgements**

Our special thanks to Dr. Leigh J. Passman for reviewing the English manuscript.

## **Conflict of interest**

None.

IntechOpen

## Author details

José Anacleto Dutra de Resende Júnior<sup>1,2,3,4\*</sup>, Rodrigo Ribeiro Vieiralves<sup>1,3,4</sup>,  
Renata Teles Buere<sup>2</sup> and Claudio Peixoto Crispi<sup>3,4</sup>

1 Federal Hospital of Lagoa (HFL), Rio de Janeiro, Brazil


2 Rio de Janeiro State University (UERJ), Rio de Janeiro, Brazil

3 Minimally Invasive Surgery Training Complex, Crispi Institute, Rio de Janeiro, Brazil

4 SUPREMA–Faculty of Medical Sciences and Health, Juiz de Fora, MG, Brazil

\*Address all correspondence to: [joseanacletojunior@gmail.com](mailto:joseanacletojunior@gmail.com)

## IntechOpen

© 2018 The Author(s). Licensee IntechOpen. This chapter is distributed under the terms of the Creative Commons Attribution License (<http://creativecommons.org/licenses/by/3.0>), which permits unrestricted use, distribution, and reproduction in any medium, provided the original work is properly cited. 

## References

- [1] Vercellini P, Pisacreta A, Pesole A, Vicentini S, Stellato G, Crosignani PG. Is ureteral endometriosis an asymmetric disease? *BJOG: An International Journal of Obstetrics & Gynaecology*. 2000 Apr; **107**(4):559-561
- [2] Resende Júnior JAD, Buere RT, Guerra CS, Sessa FV, Aragão LC, Raymundo TS, et al. Prevalence of Pre-operative Urodynamic Abnormalities in Women with DEEP Infiltrating Endometriosis: A Descriptive Study. [cited 2015 Dec 10]. Available from: [http://www.ics.org/Abstracts/Publish/218/000602\\_poster.pdf](http://www.ics.org/Abstracts/Publish/218/000602_poster.pdf)
- [3] Resende Júnior JAD, Buere RT, Guerra CGS, Raymundo TS. Urinary Symptoms and Urodynamic Findings in Women with Parametrial Endometriosis: An Exploratory Study. [cited 2017 Jan 4]. Available from: [https://www.ics.org/Abstracts/Publish/218/000608\\_poster.pdf](https://www.ics.org/Abstracts/Publish/218/000608_poster.pdf)
- [4] Resende Júnior JAD, Buere RT, Guerra CS, Sessa FV, Raymundo TS, Oliveira MAP, et al. Dysfunctional Voiding and Urodynamic Changes in Women with Bladder Endometriosis. [cited 2015 Dec 10]. Available from: [http://www.ics.org/Abstracts/Publish/218/000613\\_poster.pdf](http://www.ics.org/Abstracts/Publish/218/000613_poster.pdf)
- [5] Donnez J, Nisolle M, Squifflet J. Ureteral endometriosis: A complication of rectovaginal endometriotic (adenomyotic) nodules. *Fertility and Sterility*. 2002 Jan; **77**(1):32-37
- [6] Seracchioli R, Raimondo D, Di Donato N, Leonardi D, Spagnolo E, Paradisi R, et al. Histological evaluation of ureteral involvement in women with deep infiltrating endometriosis: Analysis of a large series. *Human Reproduction*, Oxford England. 2015 Apr; **30**(4):833-839
- [7] Yohannes P. Ureteral endometriosis. *The Journal of Urology*. 2003 Jul; **170**(1): 20-25
- [8] Hanssens S, Nisolle M, Leguevaque P, Neme RM, Cela V, Barton-Smith P, et al. Robotic-assisted laparoscopy for deep infiltrating endometriosis: The register of the Society of European Robotic Gynaecological Surgery. *Gynécologie, Obstétrique & Fertilité*. 2014 Nov; **42**(11):744-748
- [9] Uccella S, Cromi A, Casarin J, Bogani G, Pinelli C, Serati M, et al. Laparoscopy for ureteral endometriosis: Surgical details, long-term follow-up, and fertility outcomes. *Fertility and Sterility*. 2014 Jul; **102**(1):160-166.e2
- [10] Pérez-Utrilla Pérez M, Aguilera Bazán A, Alonso Dorrego JM, Hernández A, de Francisco MG, Martín Hernández M, et al. Urinary tract endometriosis: Clinical, diagnostic, and therapeutic aspects. *Urology*. 2009 Jan; **73**(1):47-51
- [11] Lee Z, Llukani E, Reilly CE, Mydlo JH, Lee DI, Eun DD. Single surgeon experience with robot-assisted ureteroureterostomy for pathologies at the proximal, middle, and distal ureter in adults. *Journal of Endourology*. 2013 Aug; **27**(8):994-999
- [12] Musch M, Hohenhorst L, Pailliat A, Loewen H, Davoudi Y, Kroepfl D. Robot-assisted reconstructive surgery of the distal ureter: Single institution experience in 16 patients. *BJU International*. 2013 May; **111**(5):773-783
- [13] Lusuardi L, Hager M, Sieberer M, Schätz T, Kloss B, Hruby S, et al. Laparoscopic treatment of intrinsic endometriosis of the urinary tract and proposal of a treatment scheme for ureteral endometriosis. *Urology*. 2012 Nov; **80**(5):1033-1038
- [14] Schonman R, Dotan Z, Weintraub AY, Goldenberg M, Seidman DS, Schiff E, et al. Long-term follow-up after ureteral reimplantation in patients with

severe deep infiltrating endometriosis.  
European Journal of Obstetrics,  
Gynecology, and Reproductive Biology.  
2013 Nov;**171**(1):146-149

[15] Melnyk M, Casey RG, Black P,  
Koupparis AJ. Enhanced recovery after  
surgery (ERAS) protocols: Time to  
change practice? Canadian Urological  
Association Journal. 2011 Oct;**5**(5):  
342-348