

# We are IntechOpen, the world's leading publisher of Open Access books Built by scientists, for scientists

6,900

Open access books available

186,000

International authors and editors

200M

Downloads

Our authors are among the

154

Countries delivered to

TOP 1%

most cited scientists

12.2%

Contributors from top 500 universities



WEB OF SCIENCE™

Selection of our books indexed in the Book Citation Index  
in Web of Science™ Core Collection (BKCI)

Interested in publishing with us?  
Contact [book.department@intechopen.com](mailto:book.department@intechopen.com)

Numbers displayed above are based on latest data collected.  
For more information visit [www.intechopen.com](http://www.intechopen.com)



---

# Micro-Osteoperforations

---

Esra Bolat

Additional information is available at the end of the chapter

<http://dx.doi.org/10.5772/intechopen.81419>

---

## Abstract

The researchers have tended to study on methods which will shorten orthodontic treatment periods due to the fact that orthodontic treatments are long-term treatments with increased side-effect potentials depending on the use of orthodontic force. There is a need for shortening orthodontic treatment time besides minimizing the side effects and achieving permanent results. Therefore, local or systemic application of various chemical agents, some physical-mechanic stimulus, and surgery-assisted methods are used. Surgically assisted methods have a longer clinical history with more predictable and consistent results among the acceleration methods of tooth movement. On the other hand, they include some complication risks due to the interventions as they are invasive methods, which is accepted as the disadvantage of these methods. Outstanding with its ease of implementation and repeatability, “micro-osteoperforation,” which is less invasive than other surgical methods, is an up-to-date technique. Animal studies show that micro-osteoperforations increase orthodontic tooth movement rate by enhancing the cellular response. These findings are also supported by a limited number of clinical studies. Although micro-osteoperforations were reported to be included in tooth acceleration techniques as a trustable and applicable method in clinical routine, issues such as application techniques, possible side effects, and combining with different mechanics should be evaluated with further clinical studies.

**Keywords:** micro-osteoperforations, accelerated orthodontics, tooth movement, bone remodeling

---

## 1. Introduction

Many orthodontic patients complain about the physical and social discomfort which is associated with prolonged use of fixed appliances [1]. There are also numerous studies which report that dental and periodontal complications such as apical root resorption, subsequent

gingivitis, periodontitis, enamel demineralization, increased levels of dental caries, and open gingival embrasure spaces may occur during orthodontic treatment [2].

However, a major challenge in orthodontics is to shorten treatment time by avoiding undesirable side effects without compromising treatment outcome. The rate of orthodontic tooth movement is primarily determined by the remodeling of tissues surrounding the roots; this in return is under the control of molecular mechanisms regulating cellular behaviors in the alveolar bone and periodontal ligament [3]. Assuming that the clinician optimized mechanics and cooperation for any patient, the main factor controlling the treatment time and rate will be the patient's biological response to the orthodontic forces [4, 5]. Therefore, identifying and controlling the cellular regulators are essential to shorten orthodontic treatment time safely.

The concept of accelerating tooth movement has received increased attention recently [6] with the introduction of various clinical techniques; including local injection of cellular mediators [7], physical or mechanical stimuli [8] and surgically assisted orthodontics [9, 10]. Local or systemic pharmaceutical administration and physical or mechanical stimulation methods might not be applicable to daily clinical practice because of their possible side effects and their outcomes that await validation [11]. Over the past decade, the regional acceleratory phenomenon induced by surgical trauma has received emphasis for accelerating orthodontic tooth movement and reducing the treatment time [11]. However, many techniques which are surgically assisted involve considerably high surgical trauma limiting application of the technique currently.

A new method which uses micro-osteoperforations (MOPs) to stimulate alveolar bone remodeling without the disadvantages of surgery such as the requirement of corticotomies, cuts in cortical bone, raising split-thickness flap, and decorticating the bone has recently been identified [5, 12]. Animal studies revealed that micro-osteoperforations significantly stimulate expression of inflammatory markers and increase the number of osteoclasts and bone resorption. The increase in bone remodeling contributes to the rise in both rate and magnitude of tooth movement [4]. In addition to the requirement of additional studies, similar results are reported in clinical trials [4, 5].

In this chapter, we focused on the biologic basis of orthodontic tooth movement, accelerated tooth movement techniques and application methods, advantages, disadvantages, effects, and possible side effects of micro-osteoperforations as a new, reliable, repeatable and minimally invasive method for accelerating orthodontic tooth movement.

## **2. Biologic basis of orthodontic tooth movement**

Application of mechanical forces to teeth causes orthodontic tooth movement as a result of the biological responses of the periodontal tissues. Alveolar bone remodeling includes selective resorption in some areas and apposition in others. The biologic response to orthodontic therapy includes not only the response of the periodontal ligament and alveolar bone but also the response of growing areas which are distant from the dentition. However, it can be stated that tooth movement is primarily a periodontal ligament phenomenon because the alveolar bone response is also mediated by the periodontal ligament [13].

The first step of the biological response to orthodontic force is “tension and compression in the periodontal ligament” which constricts and deforms blood vessels damaging cells in the periodontal tissues. The initial aseptic acute inflammatory response is realized by releasing chemokines and cytokines from localized cells such as osteoblast, fibroblast, and endothelial cells. Most of these cytokines are pro-inflammatory providing the continuity of the inflammatory response by activating osteoclast precursors of periodontal ligament in extravascular range and inflammatory cells. Infiltration of inflammatory cells causes the increase of chemokine and cytokine levels. This enables differentiation of osteoclast precursors to multinucleated giant cells which will realize alveolar bone resorption that is required for tooth movement. The continuity of the existence of anti-inflammatory chemokines and cytokines is essential in order to suppress destructive pro-inflammatory and osteolytic processes [4]. Therefore; the pro- and anti-inflammatory responses of alveolar bone, periodontal ligament, and inflammatory cells to orthodontic force are required to be known in order to develop safe methods to shorten orthodontic treatment period.

### **3. Accelerated tooth movement**

The methods which accelerate tooth movement can be classified in three groups:

1. Chemical applications (local or systemic applications)
2. Mechanical-physical stimulations
3. Surgical-assisted techniques [14]

#### **3.1. Chemical applications**

In this method, substances such as prostaglandins, corticosteroids, vitamin D, cytokines, neuropeptides, leukotrienes, nitric oxide, diazepam, and vasoactive medications, which are considered as physiological agents that transform mechanical forces into cellular response, are used to decrease the resistance to the strength applied during tooth movement that occurs within the cells and to change the environmental factors [15, 16].

Taking systemic effect rather than being limited to the applied area and affecting other target cells in the body are reported as a common side effect of using these hormones and medications [17]. Therefore, there is no medication treatment which safely accelerates tooth movement [18].

#### **3.2. Mechanical-physical stimulations**

It was reported that stimulating periodontal ligament mechanically or physically can increase alveolar bone remodeling and tooth movement accordingly. Physical methods frequently include equipment-assisted treatment methods [6] such as low-dose laser applications, electromagnetic field, direct electrical current, and vibrational applications. These methods take effect by inducing signal molecules such as receptor activator of nuclear factor-kappa

B (RANK), receptor activator of nuclear factor-kappa B ligand (RANKL) pathway, mitogen-activated protein kinase (MAPK), c-fos, and nitric oxide [6, 19].

Low-dosage laser applications are reported to increase osteoblastic and osteoclastic activity by stimulating cellular proliferation and differentiation and accelerate orthodontic tooth movement without creating side effects on periodontal ligament [6, 20].

It is also reported that electromagnetic field applications increased levels of a group of enzyme which is responsible from regulating intracellular metabolism and cellular proliferation accordingly by influencing sodium-calcium change speed in cell membrane [21]. Increase in osteoblastic and osteoclastic activity causes an acceleration in the tooth movement. Darendeliler et al. [22] reported that static magnetic field accelerated tooth movement by shortening unproductive period when no tooth movement is observed but the side effect can be a decrease in serum calcium and slight changes in the chemistry of blood.

Applying direct electric current is also among tooth acceleration techniques, but its clinical use is asserted as not appropriate due to some complications such as application difficulty, ionic reactions that cause damages in tissues, and replacing of bone tissue with connective tissue [23].

Resonance vibration and ultrasonic vibration are also among the methods which are used to accelerate tooth movement. Resonance vibration is reported to increase release of peptide which is called RANKL within periodontal ligament and increase tooth movement rate by providing formation, function, and continuity of osteoclasts. Tooth movement can also be accelerated via ultrasonic vibration with the same mechanism but there is a risk that the heat can cause damage in the dental pulp [19].

### 3.3. Surgical-assisted techniques

The most clinically used and predictable option with stable results among the techniques which accelerate tooth movement is the surgical-assisted technique; it is evaluated as a costly invasive method [6]. It is based on the idea that rapid tooth movement can be achieved by increasing the biological response which is formed in periodontal ligament and alveolar bone. Creating an injury in the bone is a potential physical mechanism which provides rapid tissue recovery. Higher regional tissue response during this tissue remodeling/regeneration period is called as regional acceleratory phenomenon (RAP) [24]. Regional acceleratory phenomenon is a complex physiological case in which initially osteoclastic activity and secondly bone density is decreased followed by a rapid osteoblastic activity and a remodeling process. Orthodontic tooth movement acceleration is provided via the increase in cytokine activity around the teeth and decrease in cortical bone resistance and formation of hyalinization tissue by activation of this recovery mechanisms [25]. The advantages of the dentoalveolar surgical intervention in orthodontic treatment of adult patients are reported as: (a) less treatment time, (b) avoidance of potential periodontal complications, (c) favorable direction of growth, and (d) extensive envelope of the tooth movement [26].

#### 3.3.1. Corticotomy and osteotomy combinations

They were first used by Heinrich Köle who stated that the basic resistance toward tooth movement was in cortical layer so by applying corticotomies and osteotomies might accelerate

tooth movement by breaking the resistance [27]. Köle et al. applied vertical corticotomies between the roots of two adjacent teeth buccally and lingually and horizontal osteotomies subapically as to combine corticotomies buccal-lingually. They theorized that the segments which became “blocks of bone” move as a whole to achieve rapid tooth movement without devitalization in long-term monitoring. Düker et al. also reported that pulpal and periodontal tissues of the teeth which were applied orthodontic force similarly were not damaged in their study on dogs with reference to Köle’s corticotomies [28].

Although Köle and Düker proposed the opposite, periodontal and pulpal damages can be formed following invasive horizontal subapical osteotomies [29]. Additionally, osteotomy surgery is an invasive intervention with possible complications such as vascular and nerve damages so it is not a widely accepted method [30]. Nonetheless, Köle’s studies pioneered surgery-assisted methods which accelerate tooth movement to be involved in the literature of modern orthodontics.

### *3.3.2. Corticotomy-assisted treatments*

Köle’s horizontal subapical osteotomies were changed with horizontal subapical corticotomies by Gantes et al. [31] and Suya [32] and it was stated that treatment of the cases was completed in almost 50% less period when compared to conventional methods. Gantes et al. [31] reported that overall vitality of the tooth was preserved and none of the patients had a periodontal damage that can be clinically recognized despite minimal root resorptions and gingival recession. Suya [32] asserted that corticotomy-assisted orthodontics had less root resorption and relapse risk and pain when compared to traditional treatments. In a recent study, Uzuner et al. [33] reported that corticotomy-assisted orthodontics increased the rate of tooth movement during canine retraction in 20% ratio and also relative bodily movement was achieved with the corticotomy-combined treatment.

### *3.3.3. Periodontal ligament distraction*

The method was introduced to orthodontic literature by Liou and Huang [34]. Initially, a distractor device which consists of canine and molar bands was applied to the patients by the researchers and following extraction of upper first premolar teeth, surgical preparation phase which consists of two vertical channels formed buccally and lingually toward canine teeth through the extraction socket and a horizontal incision on the base of the extraction socket that connects the channels was completed at the same session. Interseptal bone was not cut mesiodistally during the surgical intervention. Activation was carried out without a need for latent period different from traditional distraction method and distalization of canine teeth was completed in a short period of 3 weeks with minimal anchorage loss. None of the patients suffered from pain and minimal resorption was observed in the roots of canine teeth in the radiographies at the end of procedure. Suggesting to be used especially in orthodontic treatments with primary premolar extraction which has anterior crowded teeth, Liou and Huang [34] associate the periodontal ligament distraction with this method to the distraction which is formed in midpalatal suture during rapid maxillary expansion.

### *3.3.4. Dentoalveolar distraction*

The method was introduced by Kişnişci et al. [35] in 2002. The researchers applied a distraction device before teeth extraction as in periodontal ligament distraction method but a more



rigid device was used. Initially, the osteotomy curved apically at a distance of 3–5 mm from the apex of the canine at the same session with the primary premolar tooth extraction as a surgical preparation. Cortical bone which remained in the buccal of the socket after the extraction was carefully removed. Direct distraction was applied by skipping latent period similar to periodontal ligament distraction method. Canine distraction was reported to be completed within 8–12 days without anchorage loss. Root resorption or vitality loss was not observed in the posttreatment evaluations.

Although a faster canine distalization is achieved with less teeth tilting in dentoalveolar distraction method when compared to periodontal ligament distraction method, it is clear to be a more invasive method [36].

### 3.3.5. Periodontally accelerated osteogenic orthodontics

The method which is known as “Wilckodontics” or “periodontally accelerated osteogenic orthodontics” was introduced by Wilcko and Wilcko [9, 37–40]. According to the researchers, achieving optimal tooth movement is possible by forming a bone layer of 1.5 mm or less on the root surface in the direction of movement in corticotomy-assisted orthodontic treatment. When the force is applied, soft tissue matrix and osteoid islets remaining from the demineralized layer move with the root and remineralized when the orthodontic movement is completed. Wilcko brothers explained the acceleration of tooth movement following corticotomy with demineralization-remineralization period that is generated from rapid osteoclastic activity in alveolar bone in the beginning of “regional acceleratory phenomenon” which was introduced by Frost [24]. According to this mechanism, less resorption and rapid orthodontic tooth movement is achieved as a result of the decrease in alveolar bone density and increased metabolic activity in bone tissue. Thus, the term “movement of bone blocks” which was defined by Köle [27] was replaced with the term “bone matrix transplantation.”

Wilcko and Wilcko discussed the need for applying a bone graft in order to prevent dehiscences, fenestrations, and relapses which can occur in posttreatment period due to the decrease in alveolar bone density within the cases with buccal move of the roots or thin buccal bones following corticotomy. They proposed to use resorbable bone graft by saturating clindamycin phosphate or platelet-rich plasma and creating circular perforations on the surface of the bone in order to increase bleeding of graft material if the cortical bone thickness is sufficient [37]. The applied surgery apart from this procedure is almost the same with Suya procedure [32]. In this technique, bonding and applying forces to teeth is initiated 1 week earlier from the surgical intervention and biweekly orthodontic examinations are recommended.

Treatments are completed in three or four times shorter periods with “periodontally accelerated osteogenic orthodontics” method when compared to traditional orthodontic treatments besides its increased root resorption and relapse risks. Its need for additional surgical intervention with an extra cost, possibility of bone loss in alveolar crest, and gingival recession following the surgery and surgical complications such as pain and edema are among the disadvantages of the procedure.

### 3.3.6. Corticision

The necessity to remove flaps during corticotomy-assisted orthodontic treatment makes the method invasive, decreasing its acceptability by the patients and clinicians. Therefore, corticision was introduced by Park et al. [41] as an alternative approach for corticotomy procedures. The researchers made the patients rinse their mouth with an antiseptic mouthwash and then placed a stabilized scalpel on the attached gingiva interradiarily as to make an angle of 45–60° with the long axis of root of the teeth and applied cortical incisions via a surgical hammer without removing flaps [42]. Incisions were applied as 2/3 of the roots vertically and in 10 mm depth. Corticision area must be cleaned with physiological saline solution until hemorrhage stops. Park reported that fixed orthodontic treatment of a patient without extraction was completed in a short period of 10 months through this method. Although corticision method is minimally invasive with a short surgical intervention, it is not widely accepted as it is not appropriate to grafting and the surgical technique is disturbing for the patient.

### 3.3.7. Piezocision

In 2009, Dibart et al. [43] introduced a minimally invasive technique that can be applied by piezosurgical tools, the piezoincision method, which can be carried out without any flap surgery as in corticision method but it allows hard or soft tissue grafting differently. In this method, small piezoelectric incisions are placed in the area from the targeted corticotomy area to periosteum. Piezoincisions of 3 mm length and depth are applied with the piezosaw without removing mucoperiosteal flap. In this stage, mucoperiosteal flap can be removed as a tunnel and a bone graft in pad form can be replaced if necessary. Sutures are required if grafting is applied, otherwise there is no need for sutures. It was reported that no significant difference was found in terms of tooth movement speed and root resorption in the studies which compare corticotomy-assisted methods with piezoincision method [44].

Piezoincision is a practical, minimally invasive, and effective method. Additionally, ultrasonic vibrations which occur during the procedure in piezoincision method also contribute to accelerate tooth movement [3]. Required precautions must be taken before the procedure with patients in high-risk group due to possibility of temporary bacteremia formation risk following the procedure.

### 3.3.8. Piezopuncture

“Piezopuncture” method, which is applied by using an ultrasonic piezosurgical tool, “piezotome” without gingival incisions in piezoincision method was developed by Kim et al. [45]. In their study on 10 dogs, the researchers created several cortical punctures both buccally and lingually on the mesial and distal sides of the teeth which will be moved and reported that anabolic activity and tooth movement were accelerated at the end of the procedure. Omidkhoda et al. who carried out piezopuncture technique on human reported that tooth movement was accelerated but they observed distal tilt in the canine teeth crowns in their case reports which consist of two cases [46].

“Piezopuncture” method also takes part in literature as a method with promising positive results but it must be evaluated by further clinical studies.



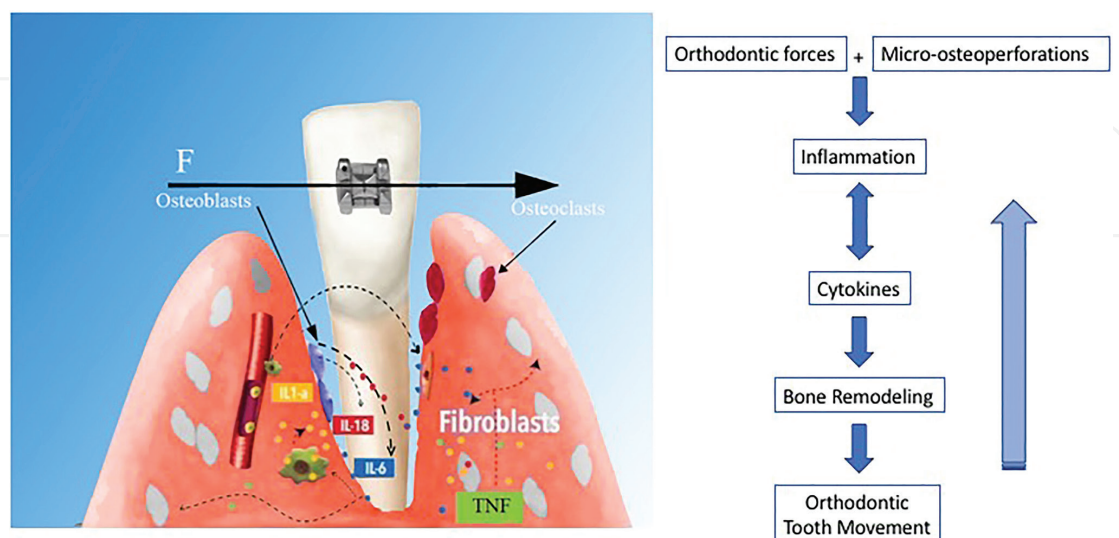
#### 4. Micro-osteoperforations

Orthodontic tooth movement is a biological response which is created by an external force that will prevent the dentofacial complex to be in physiological balance [13]. Orthodontic force creates an aseptic inflammatory response in periodontal tissues. An increase on vascular permeability and cellular infiltration of leucocytes was reported in the early period of orthodontic tooth movement [47]. Along with native cells such as osteoblasts and fibroblasts, migrated immune cells produce inflammatory cytokines that include chemotactic factors, growth factor, monocyte-derived factor, lymphocyte, and colony-stimulating factors [48, 49]. The gingival crevicular fluid of moving teeth includes tumor necrosis factor- $\alpha$  (TNF $\alpha$ ), interleukin-1 (IL-1), IL-2, IL-3, IL-6, IL-8, osteoclast differentiation factor, and interferon- $\gamma$  (IFN $\gamma$ ) [48, 50].

Orthodontic tooth movement rate is basically found associated with the rate of bone resorption which is controlled by osteoclast activity [51]. Therefore, any factors which effect activities of osteoclast precursor cells and their transformations into osteoclasts can be assumed to have significant effects on orthodontic tooth movement. There are a lot of researches that report the increase in the activity of inflammatory markers such as chemokines and cytokines as a response to orthodontic forces [5, 25]. It is reported that several cytokines which play role in osteoclast formation and activity such as TNF $\alpha$ , IL-1, and IL-6 are found in gingival crevicular fluid during orthodontic tooth movement [25]. Although the roles of chemokines and cytokines during orthodontic treatment are not clearly known, they are valued as essential mediators for orthodontic tooth movement in terms of their significant roles on differentiation and activity of osteoclast cells [52–54]. Significant decrease on orthodontic tooth movement rate within the studies in which the effects of these markers are blocked via different techniques such as anti-inflammatory medication or genetic manipulation can be accepted as a proof that these factors are extremely efficient on orthodontic tooth movement rate [55–57]. Previous studies represent that surgical interventions which cause minor bone traumas increase inflammatory cytokines, bone remodeling, and orthodontic tooth movement acceleration together with regional bone density [24, 58]. Surgery-assisted techniques which are applied in order to accelerate orthodontic tooth movement should be studied under subtitles such as corticotomy and osteotomy techniques, dental distraction technique, perisegmental corticotomy, and piezoincision. Corticotomy-assisted orthodontic treatment increases bone remodeling which accelerates recovery and repair mechanisms and tooth movement rate accordingly by creating a mechanical trauma in cortical bone [59]. Although corticotomy-assisted orthodontic treatment was reported to be an efficient method in accelerating tooth movement, the significance of removing flaps is also stated to cause important postoperative complications [60]. Piezoincision technique, which is a minimally invasive technique that includes piezoelectric incisions without removing flaps, was developed in order to overcome these disadvantages [43]. Piezoincision is known to be an effective method for acceleration of tooth movement but it was reported to have high risks of damaging tooth roots [18]. Surgery-assisted techniques are invasive with disadvantages such as bone loss, postoperative pain, edema and infection, avascular necrosis besides low acceptance rates by the patients [37, 40]. Based on this, the hypothesis that small osteoperforations on cortical bone without removing flaps will increase bone remodeling and tooth movement rate accordingly by stimulating

release of inflammatory cytokines minimizing these disadvantages was developed (**Figure 1**). Micro-osteoperforation is an up-to-date procedure which is promoted as an auxiliary dentoalveolar procedure which can accelerate tooth movement via minimum surgical interventions.

In their animal study in 2010, Teixeira et al. [25] classified 48 rats, which were applied experimental orthodontic tooth movement, into four groups as one group with only orthodontic forces, a group via application of soft tissue flaps together with orthodontic force, a group that was applied 3 small perforations on cortical plate with soft tissue flaps together and orthodontic force and a control group. The researchers stated that they formed the microperforations in the cortical bone by using a round bur and handpiece. It was observed that at the end of experimental tooth movement period, release of 37 out of the 92 cytokines increased in all experimental groups and 21 of them were at the maximum level in the group which was applied perforation. In addition to that, light and fluorescent microscopy, microcomputed tomography, and immunohistochemistry examinations, which were carried at the end of the experiment, represented a significant increase in osteoclast number which accompanied by generalized osteoporosis and orthodontic tooth rate besides bone remodeling activity [25]. Similar to previous studies, researchers also demonstrated that the increase in bone remodeling was not limited around the loaded teeth but also involved the periodontal structures of the adjacent teeth. The researchers, who argued that the observed effects of osteoperforations on tooth movement can be related to loss in bone structure rather than release of increased inflammatory cytokine, stated that perforations were applied in the smallest amount and number possible and the remaining cortical bone was healthy in order to minimize this possibility. These findings also represent that the perforations that will be applied in order to accelerate tooth movement rate are not necessarily be adjacent to the moved teeth. Stating that inflammation can cause negative effects on periodontium and tooth structure when it is uncontrolled because it is a double-sided injury, it is also reported that applying micro-osteoperforations instead of some surgical interventions such as corticotomy, which are applied for acceleration of tooth movement, can minimize the side effects.



**Figure 1.** Micro-osteoperforations on cortical bone increase bone remodeling and tooth movement rate by stimulating release of inflammatory cytokines.

Tsai et al. [11] applied both micro-osteoperforations and corticision without removing flaps different from the previous studies and evaluated the differences between the procedures in their animal study which was carried out to evaluate the effects of micro-osteoperforations and corticisions on orthodontic tooth movement rate. It was stated that bone and bone mineral densities were significantly decreased when compared to control group and tooth movement rate was increased in both groups without any significant difference. The rise in tooth movement rate in both groups in this study is smaller than the previous studies. The researchers, who stated that there might be a direct proportion between trauma amount and remodeling rate, reported that the difference was resulted from the smaller amount of the trauma as the flap was not removed.

In 2016, Cheung et al. [12] published a study which evaluated the effectiveness of micro-osteoperforations. Mini-implants were used in order to form micro-osteoperforations different from the previous animal studies and the existence of external apical root resorption was evaluated following the procedure. Similar to previous studies, it was observed that there was a decrease on the density and volume of the bone surrounding moved molar teeth compared with the control side besides the acceleration of orthodontics tooth movement on the side where micro-osteoperforations were applied in the split mouth design study with six rats. Histological examinations also showed that new bone formation increased as well as osteoclast numbers on the side with micro-osteoperforations. This is a proof of the existence of osteoclasts-osteoblast coupling formation with decortication. Despite the fact that resorption and new bone formation were represented together, bone fraction volume and bone mineral density was decreased, which shows that resorption was more than new bone formation during tooth movement period. Contrary to conventional theories which assert osteoclast activity is limited to pressure area, the recent studies show that periodontium was remodeled as a single unit [61]. This study also shows that osteoclast rate in all alveolar bone surrounding the moving teeth is clearly on the pressure areas.

Alikhani et al. [5] designed a clinical trial to evaluate tooth movement with or without micro-osteoperforations in order to investigate whether this phenomenon occurs in human or not. They called the technique of creating micro-osteoperforations in the bone as “alveocentesis.” In their study, 20 adults were divided into 2 groups as control and experimental groups. Micro-osteoperforations were applied in the experimental group on one side of the maxilla using a disposable micro-osteoperforation device designed for this purpose by Propel Orthodontics (Ossining NY) and the control group did not receive any micro-osteoperforations. Following 28 days of canine retraction period, amount of the tooth movement was measured and also the activity of inflammatory mediators was determined in gingival crevicular fluid with an antibody-based protein assay. Additionally, the presence of pain or discomfort was evaluated with a numeric rating scale. Results of this first clinical trial about micro-osteoperforations in the literature reported significant increase in the levels of inflammatory markers and also 2.3-times rise in the rate of tooth movement with micro-osteoperforations. However, significant pain or discomfort during or after the procedure was not reported by the patients; also, any other complications were not observed.

It was stated that orthognathic surgery, corticotomies (applying several incisions and perforations with removing flaps), piezoincision (creating injury on the bone with small incisions

without removing flaps via a piezoelectric device), and even tooth extractions will increase the release of inflammatory markers and bone remodeling by creating injuries similar to micro-osteoperforations on alveolar bone effecting the rate of tooth movement accordingly [5]. Unfortunately, increase of inflammatory marker release cannot continue for a long period of time and a decrease in cytokine activity is observed regardless of the severity of the trauma after 2–3 months [4] which reveals the necessity for repeating the procedure during orthodontic treatment. Therefore, the extraction is suggested to be applied at the same time with major tooth movement for the patients whose tooth is planned to be extracted. There will not be a need for micro-osteoperforation requirement to accelerate tooth movement process as remodeling will speed up. In other words, it would be appropriate to prefer micro-osteoperforations in the treatments without tooth extraction or when extraction is carried out long after the orthodontic treatment because its effects are similar to tooth extraction. It is considered that as the level of trauma increases, inflammatory response will also rise. The rise on tooth movement rate when micro-osteoperforation number is increased can be shown as a proof. It was stated that regional acceleratory phenomenon (RAP) took effect in 1 or 2 days following the surgical intervention and reached its maximum level in 1 or 2 months [9]. Aboul-Ela et al. [59], Al-Naoum et al. [62], and Leethanakul et al. [63] reported that tooth movement speed was high during 2 months following the creation of traumas in cortical layers but it gradually decreased in this period. Alikhani et al. also stated that cytokine activity decreased after 2 months following micro-osteoperforation so they proposed that the procedure shall be repeated after a month break [4]. Micro-osteoperforations are repeatable which can be considered as an advantage because application time can affect the results in all surgically assisted procedures. On the other hand, there is not a clear information on how frequently micro-osteoperforations can be applied in order to achieve an optimum acceleration in tooth movement rate.

In a recent thesis study in Akdeniz University, Faculty of Dentistry, Department of Orthodontics (Antalya, Turkey), efficiency of micro-osteoperforations on molar distalization rate with cervical headgear was evaluated on 3D digital models [64]. About 17 patients whose molar relations were bilateral class II (minimum teeth to teeth) with class I skeletal anomalies or normal or low vertical growth pattern were included in the study which is regarded as the first study to evaluate the efficiency of micro-osteoperforations on molar distalization. Propel device (Ossining, NY) was used to form three micro-osteoperforations—one mesially and two distally—of 1.5 diameter and 5 mm depth on a random molar teeth, in the session where distalization was initiated with cervical headgears in the split-mouth designed study. Micro-osteoperforations were renewed at least twice during the distalization period every 8 weeks in each sample. The procedure continued until class I relationship was achieved on the side where tooth movement was considered to be slower. Studies were carried out on 3D digital models which were taken just before and after molar distalization in order to compare molar distalization rate and tilt and rotation rate in molar teeth. While no significant difference was observed between tilting and rotation rates, it was concluded that on the micro-osteoperforation side, more tooth movement was seen.

Lee et al. [65], who stated that in the studies which evaluated the efficiency of micro-osteoperforations on orthodontic tooth movement, micro-osteoperforations were generally applied on healthy alveolar bone, planned a study considering that the effects of



bone remodeling process that was activated by applying orthodontic tooth movement and micro-osteoperforations on the atrophic ridge could be different. The researchers, who created atrophic alveolar ridge model on eight beagle dogs, evaluated tooth movement rates and atrophic alveolar ridge area on the sides with and without osteoperforations in their study which they planned via split mouth design. Micro-CT based histomorphometry analysis similar to the previous studies suggested that osteoperforations accelerated tooth movement with a decrease in bone density without any differences in atrophic ridge volume. This up-to-date finding can be evaluated as an indicator that the efficiency of micro-osteoperforations on bone remodeling is more related to resorption mechanism and osteoclast activation.

In the literature, there is a limited number of studies which evaluate the effects of micro-osteoperforations on tooth movement in human. Current studies indicate that micro-osteoperforation is a safe method that can accelerate tooth movement but it must be taken into consideration that several factors such as occlusal relations, movement type, applied mechanics, age and gender of the patient, oral hygiene, periodontal illnesses, alveolar bone loss, systemic diseases, and medication use effect tooth movement rate in human. Therefore, the efficiency of micro-osteoperforations must be evaluated with long-term studies in which study groups are standardized as much as possible considering these variable where different tooth movement types (distalization, intrusion, eruption of impacted tooth, etc.) and mechanics are applied containing more sample numbers.

#### **4.1. Micro-osteoperforation application techniques**

Micro-osteoperforation is an up-to-date method among the surgery-assisted techniques of accelerating tooth movement. Therefore, in the literature, there are studies in which different methods are used in order to create MOPs on alveolar bones.

We observe that low-speed handpiece and round bur combinations [11, 25] and mini-implants [12] are used within the animal studies which evaluate effects of MOPs on tooth movement and both methods are accepted as effective. Even if in a limited number of clinical trial; micro-osteoperforations are typically applied with a handheld disposable appliance designed by Propel Orthodontics (Ossining, NY). Propel is an appliance which is designed to apply alveo-centesis procedure. The foremost part of the device which is like an orthodontic stainless steel screw is patented, allowing perforation of alveolar bone traumatically over keratinized gingiva and moving mucosa. Contrary to other rotatory devices, Propel was reported to have a slight effect on soft issue. It is a device which enables tissue remodeling and micro-osteoperforations between tooth roots over both stable and moving tissue of 1.5 mm diameter and 3, 5, and 7 mm depth without flap surgery in order to accelerate tooth movement. The appliance has an adjustable length and a light signal that turns on when the clinician achieved desired depth [5, 64]. Micro-osteoperforations, which are applied on the defined depth, reach to medullar bone from cortical bone increasing inflammatory mediators. The device was also reported not to cause soft tissue damage while enabling remodeling process [5].

While it is not always possible to create homogenous perforations of same size using micro-osteoperforation methods such as round burs, Propel device which is designed in order to



form MOPs has not included in routine clinical use yet. Thus, mini-implants are considered more advantageous than other methods as they are included in clinical routine and frequently used by orthodontists for different purposes and easily tolerated by the patients. On the other hand, in the literature, there are limited studies in which mini-implant-facilitated micro-osteoperforations are carried out with human. Aksakalli et al. [66] applied three micro-osteoperforations distal to the canine teeth with miniscrews just before canine distalization period. In their case report, they reported that MOP method with miniscrews accelerated canine distalization in their 14-year-old male patient with class II malocclusion by almost 1.5-fold and also without harmful effects on root and periodontal structures. On the contrary, Alkebsi et al. [67] could not find any differences of anchorage loss, canine rotation, and tipping between the MOP and control sides in their randomized controlled clinical trial where they investigated the effectiveness of miniscrew-facilitated MOPs on the rate of canine distalization.

All of the methods are applied without a need for additional periodontal surgeries which is considered as a significant advantage but additional clinical studies are required in order to evaluate the efficiency of each technique and their advantages and disadvantages over each other in detail.

#### **4.2. Advantages of micro-osteoperforation over other surgical techniques**

When micro-osteoperforations are compared with several surgical techniques, which are proved to accelerate tooth movement, they are considered as more advantageous because they are less invasive with no need for removing flaps eliminating possible side effects of the surgery [4, 5]. Additionally, all techniques which make use of micro-osteoperforation do not include an invasive surgical procedure represent that they are easily applicable in the clinics by the orthodontists and can be added to clinical routine. Patients did not report any pain or discomfort in the clinical studies with micro-osteoperforations which shows that it is easily accepted and tolerated by the patients who are under orthodontic treatment [5, 64]. These advantages also enable the micro-osteoperforations to be periodically repeated until the desired results are achieved [4, 64].

#### **4.3. The relation of micro-osteoperforations with pain and root resorption**

There is a limited number of studies that evaluate patients' pain and discomfort levels among the clinical studies in which micro-osteoperforations are applied. Alikhani et al. [5] asked their patients to scale their pain and discomfort levels via a numeric rating scale on the day they replaced the device, the day they began canine distalization, 24 h, 7th and 28th days after canine distalization in their study in which they evaluated the effect of micro-osteoperforations on canine distalization. In this scale, which is reported as having high credibility, "0" presents no pain, while "10" stands for the existence of the worst pain. Data analyses showed that the patients had the most pain in 24 h following canine distalization but no significant difference was observed between experimental and control groups. The patients defined a slight and resistible pain on the micro-osteoperforation side which does not require taking painkillers but no statically significant difference was found. The similar feedbacks were taken in Boz's thesis study in 2018 concluding that micro-osteoperforations did not cause a

significant pain or discomfort [64]. In line with these findings, it is possible to state that micro-osteoperforations are easily tolerated by the patients and can be applied to routine clinical use.

Orthodontically induced inflammatory root resorption (OIIRR) is included in negative side effects of orthodontic tooth movement as a frequent research subject. Although its etiology and predictors are not fully understood, it is considered to be resulted from complex interaction of individual sensitivity [68], applied mechanics [69, 70], and specific dental predisposition [71]. Orthodontically induced inflammatory root resorption was stated to be related with periodontal ligament remodeling which is a result of the pressure applied to tooth root during tooth movement and removal of hyalinized necrotic tissues after trauma. Excessive pressure that causes ischemic necrosis [72] of periodontal ligament and root resorption related to orthodontic tooth movement is reported to be frequently observed in the areas in which excessive pressure is applied to periodontal ligament [73]. The underlying biological process of both orthodontic tooth movement and root resorption covers local inflammatory response. Animal studies show that many pro-inflammatory cytokines are common in both pathways. Cytokines such as IL-1, TNF $\alpha$ , and chemokines as IL-8 and MCP-1 are known to have significant roles to initiate and ease root resorption process [74]. These inflammatory mediators have significant roles on activation of tooth movement and osteoclast activity [75]. Inhibition of cytokine activity decreases osteoclast and odontoclast rate as well as tooth movement and root resorption [76]. It is known that accelerated tooth movement techniques increase inflammatory cytokine activation.

In the literature, there are several studies that evaluate the effects of accelerated tooth movement and decortication on root resorption [5]. The cytokines which promote inflammation are also reported to activate cementoclasts which cause root resorption increasing root resorption risk accordingly [77]. On the contrary, there are findings in the literature which state that decortication and demineralization of alveolar bone decrease the pressure toward tooth movement enabling an ease for the movement and decreasing root resorption risk accordingly [12]. It was found out that the effects of tooth movement accelerated via corticotomy on orthodontically induced inflammatory root resorption were similar to conventional orthodontic treatment but it was also reported that periapical radiographies may not be reliable for assessing root resorption in two studies which was carried out by evaluation of periapical radiographies [78, 79]. In an animal study which evaluates the effects of corticotomies on tooth movement, it was found out that there were not any differences between control and experimental groups in terms of root resorption [80].

In the literature, there is a limited number of studies which evaluates the effects of micro-osteoperforations on root resorption. Tsai et al. reported in their study in which they compared the efficiency of micro-osteoperforations and corticisions that root resorption creation risk of minor surgical interventions is lower when compared with conventional orthodontic treatments. The hematoxylin and eosin analysis of the researchers showed that micro-osteoperforation-assisted accelerated tooth movement was resulted in decreased root resorption [11]. Similarly, in the study in which Cheung et al. evaluated effects of micro-osteoperforations on experimental tooth movement in rats, root resorption was observed on the MOP application side on the samples which were colored with hematoxylin eosin reporting that 3D volumetric analysis did not show any volumetric difference in the root

of upper molar teeth which was moved [12]. Although all findings support the idea that micro-osteoperforations do not increase root resorption risk showing that mini-implants can be safely used for MOP procedures in terms of root resorption, it is clear that there is a need for further supportive studies with increased sample number.

Cheung et al. [12] included 20 patients whose upper primary premolars are planned to be extracted for orthodontic purposes in their study which is known as the initial clinical study to evaluate the effects of MOPs on OIRR. About 150 g buccal tipping force was applied to premolar tooth which was planned to be extracted and micro-osteoperforations of 5 mm depth were applied to mesial and distal parts of the premolar teeth on the experimental side via Propel device (Propel Orthodontics, San Jose, Calif) evaluating the patient's opposite side as the control group. Following 28 days of tooth movement period, premolar tooth on both sides was extracted and examined by microcomputed tomography, volumes of root resorption craters were calculated and compared. Volumetric root loss average of the premolar tooth on the side which micro-osteoperforations are applied was found to be 42% more than the premolars on the control side. The researchers represented that the side to be applied micro-osteoperforations was not randomly selected (decision was taken in accordance with the availability of the distance between the roots) and evaluation was carried out following a short-term tooth movement as the limitations of the study and suggested further studies with treatments of longer terms and larger sample numbers. Nonetheless, when the findings of the study are considered, it can be stated that special attention shall be paid on planning micro-osteoperforations with patients who are individually prone to root resorption.

As a result, there are studies which report that micro-osteoperforations can cause positive and negative effects on root resorption. Their relations were not clearly explained so there is a need for further studies.

## 5. Conclusions

- Among several techniques which are defined to accelerate orthodontic tooth movement and treatment periods accordingly, due to numerous studies, surgical techniques that have the most predictable results have been an essential part of modern orthodontics.
- Micro-osteoperforations are outstanding as a minimal invasive, easy-to-use, repeatable, and efficient new method that can eliminate some disadvantages of surgery among the defined invasive techniques.
- Experimental studies have proved that micro-osteoperforations accelerated bone remodeling process and orthodontic tooth movement accordingly together with an increase in osteoclast number and new bone formation and a decrease on bone volume and density. A limited number of clinical studies also support the findings.
- Different techniques are defined to apply micro-osteoperforation in the literature but there is a need for studies that evaluate differences between techniques in order to determine the ideal method.

- Further studies are required for the ideal timing and frequency of the application in order to achieve optimum tooth movement acceleration.
- Although it is reported that side effects such as pain or root resorption are not observed due to micro-osteoperforations, long-term studies with more samples are required.

## Conflict of interest

I declare that I have no conflict of interest regarding the publication of this chapter.

## Author details

Esra Bolat

Address all correspondence to: dtesrabolat@gmail.com

Department of Orthodontics, Faculty of Dentistry, Akdeniz University, Antalya, Turkey

## References

- [1] Ngan P, Kess B, Wilson S. Perception of discomfort by patients undergoing orthodontic treatment. *American Journal of Orthodontics and Dentofacial Orthopedics*. 1989;**96**: 47-53. DOI: 10.1016/0889-5406(89)90228-X
- [2] Zahrowski J, Jeske A. Apical root resorption is associated with comprehensive orthodontic treatment but not clearly dependent on prior tooth characteristics or orthodontic techniques. *Journal of the American Dental Association*. 2011;**142**:66-68. DOI: 10.14219/jada.archive.2011.0030
- [3] Huang H, Williams RC, Kyrkanides S. Accelerated orthodontic tooth movement: Molecular mechanisms. *American Journal of Orthodontics and Dentofacial Orthopedics*. 2014;**146**:620-632. DOI: 10.1016/j.ajodo.2014.07.007
- [4] Alikhani M, Alansari S, Sansuwon C, Alikhani M, Chou MY, Alyami B, et al. Micro-osteoperforations: Minimally invasive accelerated tooth movement. *Seminars in Orthodontics*. 2015;**21**:162-169. DOI: 10.1053/j.sodo.2015.06.002
- [5] Alikhani M, Raptis M, Zoldan B, Sangsuwon C, Lee YB, Alyami B, et al. Effect of micro-osteoperforations on the rate of tooth movement. *American Journal of Orthodontics and Dentofacial Orthopedics*. 2013;**144**(5):639-648. DOI: 10.1016/j.ajodo.2013.06.017
- [6] Nimeri G, Kau CH, Abou-Kheir NS, Corona R. Acceleration of tooth movement during orthodontic treatment—A frontier in orthodontics. *Progress in Orthodontics*. 2013;**14**: 1-8. DOI: 10.1186/2196-1042-14-42

- [7] Yamasaki K, Shibata Y, Imai S, Tani Y, Shibasaki Y, Fukuhara T. Clinical application of prostaglandin E1 (PGE1) upon orthodontic tooth movement. *American Journal of Orthodontics*. 1984;**85**(6):508-518. DOI: 10.1016/0002-9416(84)90091-5
- [8] Fujita S, Yamaguchi M, Utsunomiya T, Yamamoto H, Kasai K. Low-energy laser stimulates tooth movement velocity via expression of RANK and RANKL. *Orthodontics & Craniofacial Research*. 2008;**11**(3):143-155. DOI: 10.1111/j.1601-6343.2008.00423.x
- [9] Wilcko MT, Wilcko WM, Bissada NF. An evidence-based analysis of periodontally accelerated orthodontic and osteogenic techniques: A synthesis of scientific perspectives. *Seminars in Orthodontics*. 2008;**14**:305-316. DOI: 10.1053/j.sodo.2008.07.007
- [10] Aksakalli S, Calik B, Kara B, Ezirganli S. Accelerated tooth movement with piezocision and its periodontal-transversal effects in patients with Class II malocclusion. *The Angle Orthodontist*. 2016;**86**(1):59-65. DOI: 10.2319/012215-49.1
- [11] Tsai CY, Yang TK, Hsieh HY, Yang LY. Comparison of the effects of micro-osteoperforation and corticision on the rate of orthodontic tooth movement in rats. *The Angle Orthodontist*. 2016;**86**(4):558-564. DOI: 10.2319/052015-343.1
- [12] Cheung T, Park J, Lee D, Kim C, Olson J, Javadi S, et al. Ability of mini-implant-facilitated micro-osteoperforations to accelerate tooth movement in rats. *American Journal of Orthodontics and Dentofacial Orthopedics*. 2016;**150**(6):958-967. DOI: 10.1016/j.ajodo.2016.04.030
- [13] Proffit WR, Fields HW, Sarver DM. *Contemporary Orthodontics*. 5th ed. St. Louis: Elsevier Health Sciences; 2014. 278 p
- [14] Ren A, Lv T, Kang N, Zhao B, Chen Y, Bai D. Rapid orthodontic tooth movement aided by alveolar surgery in beagles. *American Journal of Orthodontics and Dentofacial Orthopedics*. 2007;**131**(2):160.e1-160.10. DOI: 10.1016/j.ajodo.2006.05.029
- [15] Bartzela T, Türp JC, Motschall E, Maltha JC. Medication effects on the rate of orthodontic tooth movement: A systematic literature review. *American Journal of Orthodontics and Dentofacial Orthopedics*. 2009;**135**(1):16-26. DOI: 10.1016/j.ajodo.2008.08.016
- [16] Sekhavat AR, Mousavizadeh K, Pakshir HR, Aslani FS. Effect of misoprostol, a prostaglandin E1 analog, on orthodontic tooth movement in rats. *American Journal of Orthodontics and Dentofacial Orthopedics*. 2002;**122**(5):542-547. DOI: 10.1067/mod.2002.126153
- [17] Tunçer Nİ, Yılmaz A. Tooth movement acceleration techniques. *Türk Ortodonti Dergisi*. 2012;**25**:76-91
- [18] Shenava S, Nayak K, Bhaskar V, Nayak A. Accelerated orthodontics—A review. *International Journal of Scientific Study*. 2014;**1**(5):35-39
- [19] Nishimura M, Chiba M, Ohashi T, Sato M, Shimizu Y, Igarashi K, et al. Periodontal tissue activation by vibration: Intermittent stimulation by resonance vibration accelerates experimental tooth movement in rats. *American Journal of Orthodontics and Dentofacial Orthopedics*. 2008;**133**(4):572-583. DOI: 10.1016/j.ajodo.2006.01.046



- [20] Ozawa Y, Shimizu N, Kariya G, Abiko Y. Low-energy laser irradiation stimulates bone nodule formation at early stages of cell culture in rat calvarial cells. *Bone*. 1998;**22**(4): 347-354. DOI: 10.1016/S8756-3282(97)00294-9
- [21] Stark TM, Sinclair PM. Effect of pulsed electromagnetic fields on orthodontic tooth movement. *American Journal of Orthodontics and Dentofacial Orthopedics*. 1987;**91**(2):91-104. DOI: 10.1016/0889-5406(87)90465-3
- [22] Darendeliler MA, Sinclair PM, Kusy RP. The effects of samarium-cobalt magnets and pulsed electromagnetic fields on tooth movement. *American Journal of Orthodontics and Dentofacial Orthopedics*. 1995;**107**(6):578-588. DOI: 10.1001/jama.1982.03320300027017
- [23] Basset CA, Mitchell SN, Gaston SR. Pulsing electromagnetic field treatment in ununited fractures and failed arthrodeses. *Journal of the American Medical Association*. 1982; **247**(5):623-628. DOI: 10.1001/jama.1982.03320300027017
- [24] Frost HM. The regional acceleratory phenomenon: A review. *Henry Ford Hospital Medical Journal*. 1983;**31**(1):3-9
- [25] Teixeira CC, Khoo E, Tran J, Chartres I, Liu Y, Thant LM, et al. Cytokine expression and accelerated tooth movement. *Journal of Dental Research*. 2010;**89**(10):1135-1141. DOI: 10.1177/0022034510373764
- [26] Uzuner FD, Darendeliler N. Dentoalveolar surgery techniques combined with orthodontic treatment: A literature review. *European Journal of Dentistry*. 2013;**7**:257-265. DOI: 10.4103/1305-7456.110201
- [27] Köle H. Surgical operations on the alveolar ridge to correct occlusal abnormalities. *Oral Surgery, Oral Medicine, and Oral Pathology*. 1959;**12**(5):515-529. DOI: 10.1016/0030-4220(59)90153-7
- [28] Düker J. Experimental animal research into segmental alveolar movement after corticotomy. *Journal of Maxillofacial Surgery*. 1975;**3**(2):81-84. DOI: 10.1016/S0301-0503(75)80022-1
- [29] Bell WH, Levy BM. Revascularization and bone healing after maxillary corticotomies. *Journal of Oral Surgery*. 1972;**30**(9):640-648
- [30] Hoogeveen EJ, Jansma J, Ren Y. Surgically facilitated orthodontic treatment: A systematic review. *American Journal of Orthodontics and Dentofacial Orthopedics*. 2014;**145**(4): 51-64. DOI: 10.1016/j.ajodo.2013.11.019
- [31] Gantes B, Rathbun E, Anholm M. Effects on the periodontium following corticotomy-facilitated orthodontics. Case reports. *Journal of Periodontology*. 1990;**61**(4):234-238. DOI: 10.1902/jop.1990.61.4.234
- [32] Suya H. Corticotomy in orthodontics. In: Hosl E, Baldauf A, editors. *Mechanical and Biological Basis in Orthodontic Therapy*. Heidelberg, Germany: Huthig Buch Verlag; 1991. pp. 207-226

- [33] Uzuner FD, Yücel E, Göfteci B, Gülşen A. The effect of corticotomy on tooth movements during canine retraction. *Journal of Orthodontic Research*. 2015;**3**:181-187. DOI: 10.4103/2321-3825.159548
- [34] Liou EJ, Huang CS. Rapid canine retraction through distraction of the periodontal ligament. *American Journal of Orthodontics and Dentofacial Orthopedics*. 1998;**114**(4): 372-382. DOI: 10.1016/S0889-5406(98)70181-7
- [35] Kişnişci RS, Işeri H, Tüz HH, Altug AT. Dentoalveolar distraction osteogenesis for rapid orthodontic canine retraction. *Journal of Oral and Maxillofacial Surgery*. 2002;**60**(4): 389-394. DOI: 10.1053/joms.2002.31226
- [36] Kharkar VR, Kotrashetti SM, Kulkarni P. Comparative evaluation of dento-alveolar distraction and periodontal distraction assisted rapid retraction of the maxillary canine: A pilot study. *International Journal of Oral and Maxillofacial Surgery*. 2010;**39**(11): 1074-1109. DOI: 10.1016/j.ijom.2010.06.012
- [37] Wilcko WM, Wilcko T, Bouquot JE, Ferguson DJ. Rapid orthodontics with alveolar reshaping: Two case reports of decrowding. *The International Journal of Periodontics & Restorative Dentistry*. 2001;**21**(1):9-19
- [38] Wilcko MW, Ferguson DJ, Bouquot JE, Wilcko MT. Rapid orthodontic decrowding with alveolar augmentation: Case report. *World Journal of Orthodontics*. 2003;**4**:197-205
- [39] Wilcko MT, Wilcko WM, Pulver JJ, Bissada NF, Bouquot JE. Accelerated osteogenic orthodontics technique: A 1-stage surgically facilitated rapid orthodontic technique with alveolar augmentation. *Journal of Oral and Maxillofacial Surgery*. 2009;**67**(10):2149-2159. DOI: 10.1016/j.joms.2009.04.095
- [40] Murphy KG, Wilcko MT, Wilcko WM, Ferguson DJ. Periodontal accelerated osteogenic orthodontics: A description of the surgical technique. *Journal of Oral and Maxillofacial Surgery*. 2009;**67**(10):2160-2166. DOI: 10.1016/j.joms.2009.04.124
- [41] Park YG, Kang SG, Kim SJ. Accelerated tooth movement by corticision as an osseous orthodontic paradigm. *Kinki Tokai Kyosei Shika Gakkai Gakuiyutsu Taikai Sokai*. 2006;**48**(6):6-15
- [42] Park YG. Corticision: A flapless procedure to accelerate tooth movement. *Frontiers of Oral Biology*. 2016;**18**:109-117. DOI: 10.1159/000351904
- [43] Dibart S, Sebaoun JD, Surmenian J. Piezocision: A minimally invasive, periodontally accelerated orthodontic tooth movement procedure. *The Compendium of Continuing Education in Dentistry*. 2009;**30**(6):342-344
- [44] Abbas NH, Sabet NE, Hassan IT. Evaluation of corticotomy-facilitated orthodontics and piezocision in rapid canine retraction. *American Journal of Orthodontics and Dentofacial Orthopedics*. 2016;**149**(4):473-480. DOI: 10.1016/j.ajodo.2015.09.029
- [45] Kim YS, Kim SJ, Yoon HJ, Lee PJ, Moon W, Park YG. Effect of piezopuncture on tooth movement and bone remodeling in dogs. *American Journal of Orthodontics and Dentofacial Orthopedics*. 2013;**144**(1):23-31. DOI: 10.1016/j.ajodo.2013.01.022

- [46] Omidkhoda M, Radvar M, Azizi M, Hasanazadeh N. Piezopuncture-assisted canine distalization in orthodontic patients: Two case reports. *Journal of Dentistry (Shiraz)*. 2018;**19**(1):74-82
- [47] Krishnan V, Davidovitch Z. Cellular, molecular, and tissue-level reactions to orthodontic force. *American Journal of Orthodontics and Dentofacial Orthopedics*. 2006;**129**(4):469.e1-469.32. DOI: 10.1016/j.ajodo.2005.10.007
- [48] Ren Y, Vissink A. Cytokines in crevicular fluid and orthodontic tooth movement. *European Journal of Oral Sciences*. 2008;**116**(2):89-97. DOI: 10.1111/j.1600-0722.2007.00511.x
- [49] Krishnan V, Davidovitch Z. On a path to unfolding the biological mechanisms of orthodontic tooth movement. *Journal of Dental Research*. 2009;**88**(7):597-608. DOI: 10.1177/0022034509338914
- [50] Alhashimi N, Frithiof L, Brudvik P, Bakht M. Orthodontic movement induces high numbers of cells expressing IFN-gamma at mRNA and protein levels. *Journal of Interferon & Cytokine Research*. 2000;**20**(1):7-12. DOI: 10.1089/107999000312685
- [51] Henneman S, Von den Hoff JW, Maltha JC. Mechanobiology of tooth movement. *European Journal of Orthodontics*. 2008;**30**(3):299-306. DOI: 10.1093/ejo/cjn020
- [52] Fuller K, Kirstein B, Chambers TJ. Murine osteoclast formation and function: Differential regulation by humoral agents. *Endocrinology*. 2006;**147**(4):1979-1985. DOI: 10.1210/en.2005-1340
- [53] O'Brien CA, Gubrij I, Lin SC, Saylor RL, Manolagas SC. STAT3 activation in stromal/osteoblastic cells is required for induction of the receptor activator of NF-kappaB ligand and stimulation of osteoclastogenesis by gp130-utilizing cytokines or interleukin-1 but not 1,25-dihydroxyvitamin D3 or parathyroid hormone. *The Journal of Biological Chemistry*. 1999;**274**(27):19301-19308. DOI: 10.1074/jbc.274.27.19301
- [54] Jimi E, Ikebe T, Takahashi N, Hirata M, Suda T, Koga T. Interleukin-1 alpha activates an NF-kappaB-like factor in osteoclast-like cells. *The Journal of Biological Chemistry*. 1996;**271**(9):4605-4608. DOI: 10.1074/jbc.271.9.4605
- [55] Taddei SR, Andrade I Jr, Queiroz-Junior CM, Garlet TP, Garlet GP, Cunha Fde Q, et al. Role of CCR2 in orthodontic tooth movement. *American Journal of Orthodontics and Dentofacial Orthopedics*. 2012;**141**(2):153-160. DOI: 10.1016/j.ajodo.2011.07.019
- [56] Iwasaki LR, Haack JE, Nickel JC, Reinhardt RA, Petro TM. Human interleukin-1 beta and interleukin-1 receptor antagonist secretion and velocity of tooth movement. *Archives of Oral Biology*. 2001;**46**(2):185-189. DOI: 10.1016/S0003-9969(00)00088-1
- [57] Knop LA, Shintcovsk RL, Retamoso LB, Ribeiro JS, Tanaka OM. Non-steroidal and steroid anti-inflammatory use in the context of orthodontic movement. *European Journal of Orthodontics*. 2012;**34**(5):531-535. DOI: 10.1093/ejo/cjq173
- [58] Yaffe A, Fine N, Binderman I. Regional accelerated phenomenon in the mandible following mucoperiosteal flap surgery. *Journal of Periodontology*. 1994;**65**(1):79-83. DOI: 10.1902/jop.1994.65.1.79

- [59] Aboul-Ela SM, El-Beialy AR, El-Sayed KM, Selim EM, El-Mangoury NH, Mostafa YA. Miniscrew implant-supported maxillary canine retraction with and without corticotomy-facilitated orthodontics. *American Journal of Orthodontics and Dentofacial Orthopedics*. 2011;**139**(2):252-259. DOI: 10.1016/j.ajodo.2009.04.028
- [60] Sebaoun JD, Surmenian J, Dibart S. Accelerated orthodontic treatment with piezocision: A mini-invasive alternative to conventional corticotomies. *L'Orthodontie Française*. 2011;**82**(4):311-319. DOI: 10.1051/orthodfr/2011142
- [61] Iglesias-Linares A, Yañez-Vico RM, Moreno-Fernandez AM, Mendoza-Mendoza A, Solano-Reina E. Corticotomy-assisted orthodontic enhancement by bone morphogenetic protein-2 administration. *Journal of Oral and Maxillofacial Surgery*. 2012;**70**(2):124-132. DOI: 10.1016/j.joms.2011.10.020
- [62] Al-Naoum F, Hajeer MY, Al-Jundi A. Does alveolar corticotomy accelerate orthodontic tooth movement when retracting upper canines? A split-mouth design randomized controlled trial. *Journal of Oral and Maxillofacial Surgery*. 2014;**72**(10):1880-1889. DOI: 10.1016/j.joms.2014.05.003
- [63] Leethanakul C, Kanokkulchai S, Pongpanich S, Leepong N, Charoemratrote C. Interseptal bone reduction on the rate of maxillary canine retraction. *The Angle Orthodontist*. 2014;**84**(5):839-845. DOI: 10.2319/100613-737.1
- [64] Boz T. Evaluation the effect of periodontal-accelerated treatment protocols on the rate of tooth movement [thesis]. Antalya: Turkey Akdeniz University; 2018
- [65] Lee JW, Cha JY, Park KH, Kang YG, Kim SJ. Effect of flapless osteoperforation-assisted tooth movement on atrophic alveolar ridge: Histomorphometric and gene-enrichment analysis. *The Angle Orthodontist*. 2018;**88**(1):82-90. DOI: 10.2319/061217-388.1
- [66] Aksakalli S, Balaban A, Nazaroglu K, Saglam E. Accelerated tooth movement with orthodontic mini-screws. *Case Reports in Dentistry*. 2017;**2017**:2327591. DOI: 10.1155/2017/2327591
- [67] Alkebsi A, Al-Maaitah E, Al-Shorman H, Abu Alhaija E. Three-dimensional assessment of the effect of micro-osteoperforations on the rate of tooth movement during canine retraction in adults with Class II malocclusion: A randomized controlled clinical trial. *American Journal of Orthodontics and Dentofacial Orthopedics*. 2018;**153**(6):771-785. DOI: 10.1016/j.ajodo.2017.11.026
- [68] Harris EF, Kineret SE, Tolley EA. A heritable component for external apical root resorption in patients treated orthodontically. *American Journal of Orthodontics and Dentofacial Orthopedics*. 1997;**111**(3):301-309. DOI: 10.1016/S0889-5406(97)70189-6
- [69] Roscoe MG, Meira JB, Cattaneo PM. Association of orthodontic force system and root resorption: A systematic review. *American Journal of Orthodontics and Dentofacial Orthopedics*. 2015;**147**(5):610-626. DOI: 10.1016/j.ajodo.2014.12.026
- [70] Weltman B, Vig KW, Fields HW, Shanker S, Kaizar EE. Root resorption associated with orthodontic tooth movement: A systematic review. *American Journal of Orthodontics*

- and Dentofacial Orthopedics. 2010;**137**(4):462-476. Discussion 12A. DOI: 10.1016/j.ajodo.2009.06.021
- [71] Sameshima GT, Asgarifar KO. Assessment of root resorption and root shape: Periapical vs panoramic films. *The Angle Orthodontist*. 2001;**71**(3):185-189
- [72] Brezniak N, Wasserstein A. Orthodontically induced inflammatory root resorption. Part I: The basic science aspects. *The Angle Orthodontist*. 2002;**72**(2):175-179. DOI: 10.1043/0003-3219(2002)072<0175:OIIRRP>2.0.CO;2
- [73] Brudvik P, Rygh P. Root resorption after local injection of prostaglandin E2 during experimental tooth movement. *European Journal of Orthodontics*. 1991;**13**(4):255-263
- [74] Asano M, Yamaguchi M, Nakajima R, Fujita S, Utsunomiya T, Yamamoto H, et al. IL-8 and MCP-1 induced by excessive orthodontic force mediates odontoclastogenesis in periodontal tissues. *Oral Diseases*. 2011;**17**(5):489-498. DOI: 10.1111/j.1601-0825.2010.01780.x
- [75] Garlet TP, Coelho U, Repeke CE, Silva JS, Cunha Fde Q, Garlet GP. Differential expression of osteoblast and osteoclast chemmoatractants in compression and tension sides during orthodontic movement. *Cytokine*. 2008;**42**(3):330-335. DOI: 10.1016/j.cyto.2008.03.003
- [76] Jäger A, Zhang D, Kavarizadeh A, Tolba R, Braumann B, Lossdörfer S, et al. Soluble cytokine receptor treatment in experimental orthodontic tooth movement in the rat. *European Journal of Orthodontics*. 2005;**27**(1):1-11. DOI: 10.1093/ejo/cjh089
- [77] Bartok RI, Văideanu T, Dimitriu B, Vârlan CM, Suciu I, Podoleanu D. External radicular resorption: Selected cases and review of the literature. *Journal of Medicine and Life*. 2012;**5**(2):145-148
- [78] Shoreibah EA, Ibrahim SA, Attia MS, Diab MM. Clinical and radiographic evaluation of bone grafting in corticotomy-facilitated orthodontics in adults. *Journal of the International Academy of Periodontology*. 2012;**14**(4):105-113
- [79] Shoreibah EA, Salama AE, Attia MS, Abu-Seida SM. Corticotomy-facilitated orthodontics in adults using a further modified technique. *Journal of the International Academy of Periodontology*. 2012;**14**(4):97-104
- [80] Lee W, Karapetyan G, Moats R, Yamashita DD, Moon HB, Ferguson DJ, et al. Corticotomy-/osteotomy-assisted tooth movement microCTs differ. *Journal of Dental Research*. 2008;**87**(9):861-867. DOI: 10.1177/154405910808700904