

We are IntechOpen, the world's leading publisher of Open Access books Built by scientists, for scientists

6,900

Open access books available

186,000

International authors and editors

200M

Downloads

Our authors are among the

154

Countries delivered to

TOP 1%

most cited scientists

12.2%

Contributors from top 500 universities



WEB OF SCIENCE™

Selection of our books indexed in the Book Citation Index
in Web of Science™ Core Collection (BKCI)

Interested in publishing with us?
Contact book.department@intechopen.com

Numbers displayed above are based on latest data collected.
For more information visit www.intechopen.com



Anatomy, Histology, and Physiology of the Canine Prostate Gland

Antonio Fernando Leis-Filho and Carlos E. Fonseca-Alves

Abstract

The prostate gland is the only male accessory gland in dogs and is responsible for secreting the prostatic fluid. Morphologically, the canine prostate gland lacks differentiation into zones, presenting a uniform parenchyma along the longitudinal axis. The luminal epithelial cells secrete a liquid rich in calcium, citric acid, simple sugars, and different enzymes as a component of the seminal plasma. Since the prostatic diseases are very common in small animal practice, there are many information regarding mechanisms of the different prostatic conditions and lack of information regarding the anatomy, histology, and physiology of the canine prostate gland. Thus, this chapter aims to meticulously describe the anatomy, histology, and physiology of the canine prostate gland.

Keywords: dog, prostatic fluid, prostatic tissue, secretory cells, urogenital system

1. Introduction

The prostate gland is the only male accessory gland in dogs, having an important role in the secretion of seminal plasma components. It is a bilobed, oval gland located in the pelvic cavity of adult dogs through which passes the urethra and the vas deferens, where the sperm are carried to the urethra. The prostate communicates with the urethra through several openings along the entire prostatic urethra through which the seminal plasma is secreted. Prostate diseases are extremely common in dogs, so their study is of great importance to better understand these conditions [1, 2]. The castration status is very important for the development of different prostatic disorders [3]. Usually, in developed countries, such as Canada, the United States, and Australia, the castration is very common. Due to castration and low levels of androgen hormones, the prostatic epithelium can be atrophic [1, 2]. On the other hand, the South America countries do not castrate dogs. Then, prostatic disorders such as benign prostatic hyperplasia (BPH) and prostatitis have high incidence [4]. Thus, the knowledge of the anatomy, histology, physiology, and pathology of the canine prostate gland is essential for the better approach of the canine patients.

2. Prostate gland anatomy

The prostate is a semioval bilobular exocrine gland that makes dorsal contact with the rectum, ventral with the pubic symphysis, lateral with the abdominal

wall, and cranial with the bladder; its position may present slight variations depending on the age of the dog. Up to 2 months of age, the prostate is located in the caudal portion of the abdominal cavity; from this age until the animal reaches sexual maturity, the prostate is located in the pelvic cavity. After sexual maturity is reached, it increases in size cranially extending into the abdominal cavity [1, 2].

The sulcus dividing the right and left prostate lobes can be palpated dorsally by rectal palpation. Each lobe is subdivided into lobules by trabeculae; these are being formed by composed tubuloalveolar glands, and the ducts of these glands flow into the urethra throughout all its circumference. The prostatic urethra (part of the pelvic urethra that passes through the prostate) crosses the prostatic parenchyma slightly dorsally to its center. In addition, the prostate is covered by a fibromuscular tissue capsule, the prostate capsule [1, 2]. The vas deferens enters the prostate through the cranio-dorsal surface, and each one in a lobe traverses its parenchyma making a caudoventral path ending up in the urethra by the *colliculus seminalis* [1, 2].

The vascularization of the prostate is mainly due to the prostatic artery that originates from the internal pudendal artery. The prostatic artery gives rise to the middle rectal artery that branches and penetrates the prostatic capsule through the dorsolateral surface, becoming subcapsular vessels, until later they enter the prostate to provide the necessary blood supply to the glandular tissue. Anastomoses occur between the prostatic vessels and the urethral, cranial rectal, and caudal arteries, complicating prostatectomy [1, 2].

A venous blood is drained from the prostate by the prostatic and urethral veins to the internal iliac vein. The prostatic lymph vessels drain into the iliac lymph nodes. Prostatic innervation occurs through the hypogastric nerve (sympathetic system), which presents a path similar to the prostatic artery and the pelvic nerve (parasympathetic system). Glandular secretion is increased by parasympathetic stimuli [1, 2].

3. Prostate gland histology

The canine prostate is a morphologically homogeneous organ that does not differentiate into areas such as the human prostate and is mostly composed of secretory glandular tissue (**Figure 1**). The prostatic stroma that surrounds the prostatic urethra extends dorsally and ventrally to almost the limit of the prostate, whereas the lateral projections of the stroma are thinner. These stromal projections subdivide the prostate into several lobules of glandular epithelium. This epithelium is mostly columnar that modifies to cuboid within the ductal structures of

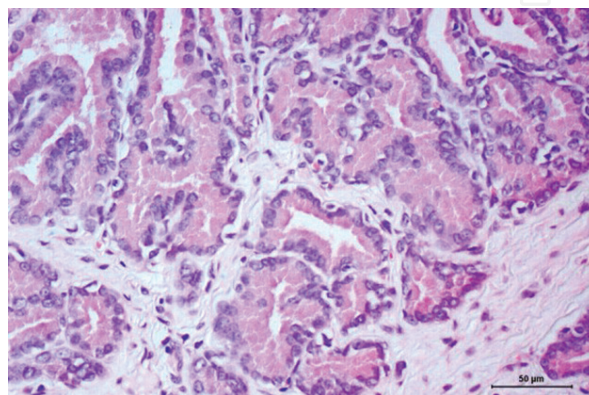


Figure 1. Canine normal prostate gland. Histological evaluation revealing a columnar epithelium distributed in one layer. The tissue stroma is composed by collagen fibers and fibroblasts. Hematoxylin and eosin (H&E) staining, 10×.

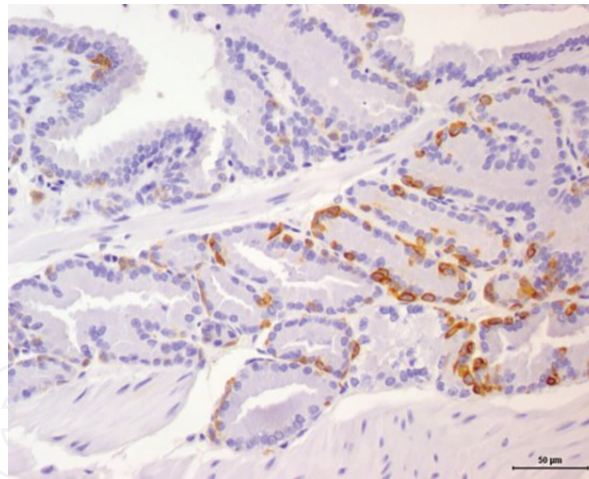


Figure 2.

Immunohistochemical evaluation of high molecular weight cytokeratin (HMWC) in a canine normal prostate gland. It is possible to identify positive membranous staining (brown color) in the basal cells, forming a discontinuous basal cell layer. The luminal cells are negative for the HMWC (blue staining). Harris hematoxylin counterstaining, 3,3'-diaminobenzidine tetrahydrochloride (DAB), 10 \times .

the prostate; meanwhile the epithelium of the prostatic urethra may be cuboid or columnar, simple, or stratified [5].

The prostatic urethra passes through the prostate gland, showing an urothelial (transitional) epithelium, and the prostatic ducts have connection with the prostatic urethra. Then, inflammatory cells infiltrating the prostatic stroma are common due to the constant antigenic stimulus related with ascended bacteria contamination of the urinary system. Thus, the prostatic stroma is composed by collagen fibers, fibroblast, smooth muscle (for prostatic contraction), and few mononuclear inflammatory cells. In dogs, the smooth muscle cells and the nerves are located in the peripheral region of this gland.

The basal or reserve cells are located in the basal cell layer in a discontinuous distribution (**Figure 2**). Usually, the luminal epithelial cells are positive for cytokeratin 8/18, pan-cytokeratin, NKX3.1, PTEN, and AR [3]. On the other hand, basal cells are positive for cytokeratin 5, p63, and high molecular weight cytokeratins (HMWC) [3].

4. Prostate gland physiology

The prostate is responsible for the production of most of the seminal plasma, which contains large amounts of proteins. One of the most studied proteins in humans, produced by both human and canine prostatic epithelia, is prostate-specific antigen (PSA) [6]. The kallikrein-3 (KLK 3) gene encodes the PSA protein in humans, and dog genome lacks KLK 3 gene. In dogs, kallikrein-2 (canine prostate-specific arginine esterase, (CPSE) is a PSA homolog enzyme belonging to the serine-protease class [6]. This protein is normally secreted into the lumen of the prostate ducts and does not come into contact with the bloodstream in a prostate under physiological conditions. However, when there is a lesion that disrupts the prostate architecture, this protein can be found in the blood and may be an indicator of a prostatic disease [7, 8].

Comparably to PSA, the canine prostate-specific arginine esterase (CPSE) is the most produced protein in the canine prostate and seems to be an alternative for the diagnosis of some prostatic conditions in dogs. Although the use of plasmatic markers as a diagnostic method for prostatic pathologies in human medicine is a commonplace in veterinary medicine, it is not a reality [7, 8].

The prostate depends on the testosterone that is produced in the testicles and converted into dihydrotestosterone (DHT) by the enzyme 5α -reductase. It is known that without this hormonal stimulus, the prostate will decrease its secretory function and volume. Castrated dogs lack testosterone, and consequently DHT will lead the prostate to a state of atrophy [7]. Thus, the endocrine control of the prostate gland, mainly by testis, is well characterized. In male dogs, the testosterone is the most important circulating androgen, and CYP19 (aromatase) can be metabolized into an estradiol- 17β . The estrogen can affect the prostate gland growth and differentiation. The role of androgen in prostatic development and pathological process is an understudied area.

5. Prostate gland disorders

5.1 Benign prostatic hyperplasia

Benign prostatic hyperplasia (BPH) is the most common prostatic pathology in dogs. There is a discordance among pathologists regarding the term “BPH.” Since hyperplasia is a term applied for a benign growth, using “benign” prostatic “hyperplasia” seems redundant. However, the term BPH is widely accepted in the international literature. Prostatic hyperplasia (PH) or BPH begins as a process of glandular hyperplasia that can occur around the age of 2–3 years. In intact dogs over 9 years, it affects more than 95% of the population [10]. This condition is part of the normal aging process and may include both hyperplastic and hypertrophic processes [1]. Histologically, the PH can be divided into two entities: glandular and complex hyperplasia.

PH is closely related to hormone stimulation in the prostate, indirectly by estrogen and directly by DHT, the former of which causes an increase in the receptors for DHT, and DHT is directly responsible for prostatic growth when binding to epithelial cell receptors of the prostatic cells. In addition, older dogs can present high levels of testosterone production by the testicle that will be converted into DHT in the prostate [1, 9].

Many dogs affected by PH do not show clinical signs until the prostate is large enough to disrupt fecal flow through rectum compression. The most common clinical signs for PH are hematuria, constipation, blood-stained urethral discharge, and hemospermia [10]. The presumptive diagnosis of PH is usually performed by associating the patient's clinical signs with the ultrasonography findings; however, for a definitive diagnosis, the histopathological examination of a prostatic sample is required [1]. The use of ultrasonography is indicated to aid in the evaluation of the extent of the lesion in which the prostate may present as a honeycomb due to the appearance of multiple cysts or as a symmetrical hyperplasia of the gland, which may or may not contain cysts [1, 10].

Neutering is still the most effective and recommended method of treatment of PH in most dogs with a 50–70% decrease in prostate volume at 3 weeks after the surgical procedure; however, the complete decrease of the prostate can take a month [10]. Surgery is contraindicated in cases where the risk of the procedure is too high or if the animal is used for reproduction. In these cases the drug treatment is indicated.

The most commonly used drug for the treatment of PH is finasteride, an inhibitor of 5α -reductase, the enzyme responsible for the conversion of testosterone to DHT. This drug has been widely used in humans for more than 10 years. The use of finasteride decreases prostate volume by 43% after 16 weeks. Although the volume of the ejaculate decreases, the use of finasteride does not alter the seminal quality of the dogs or the libido and may be an option for breeding animals [11].

There are other drugs that may be used as other options for the treatment of PH, such as progestogens, estrogens, analogues, and antagonists of GnRH, but they all have disadvantages when compared to finasteride, either concerning safety of the continuous use of the drug or cost of the drug [1].

5.2 Prostatic cysts

The appearance of prostatic cysts most often is related to PH. Cysts can be classified as intraprostatic or paraprostatic. Intraprostatic or retention cysts arise due to the clogging of the prostatic gland ducts, causing the prostatic fluid to accumulate [9]. At the beginning of this condition, the cysts are very small and not detectable by ultrasonography or rectal palpation, but with the evolution of the condition, many small cysts begin to communicate forming a large cavity that can be detected macroscopically [10, 12].

Paraprostatic cysts are closely associated with remnants of the uterus masculinus, tend to be larger than intraprostatic ones, and can be palpated rectally or even transabdominally [1]. The clinical signs caused by prostatic cysts are very similar to the signs of conditions that cause an increase in prostatic volume, that is, they are reflex of the prostate pressing other structures that are located in the pelvis [12].

The diagnosis of prostatic cysts is performed by ultrasonography, but in cases where the cysts are very small, they may not be detected. The traditional treatment for prostatic cysts is surgical, by any of these techniques: surgical debridement, omentalization, marsupialization, placement of surgical drains, or partial prostatectomy [10, 13, 14].

However, due to the risks of a surgical intervention, new techniques of ultrasound guided drainage are presented as viable options for the treatment of this affection [14].

5.3 Squamous metaplasia

Continuous stimulation of prostatic epithelial cells by estrogen may lead to squamous metaplasia. This estrogenic stimulus may be exogenous or endogenous [15]. The source of endogenous estrogen in animals with squamous metaplasia is the Sertoli cell neoplasia. As in PH, there is a trend toward the formation of prostatic cysts [10].

Squamous metaplasia (**Figure 3**) does not directly cause any clinical signs. This prostatic alteration is reversible if the endogenous or exogenous estrogen source is withdrawn [10].

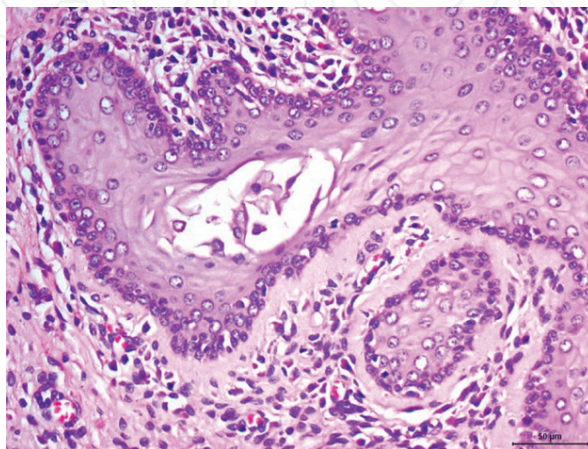


Figure 3. Canine squamous metaplasia of the prostate gland. It is possible to observe a squamous differentiation of the prostatic epithelium, forming filaments of keratins in the lumen. An inflammatory infiltrate, composed by mononuclear cells, is also observed. Hematoxylin and eosin (H&E) staining, 20 \times .

5.4 Prostatitis

Prostatitis is a prostate infection that affects mainly older dogs. The origin of the infection can be both ascending by the urinary tract and by hematogenous spread, the second case being rare. Other prostatic conditions such as PH or cysts may compromise the natural defense mechanisms of the prostate and may lead to the development of prostatitis [1, 10].

The most relevant microorganisms linked to prostatitis are *Escherichia coli*, *Staphylococcus*, *Streptococcus* spp., *Mycoplasma* spp., *Proteus*, *Klebsiella* spp., *Pseudomonas aeruginosa*, *Enterobacter*, *Pasteurella* spp., and *Brucella canis*. In rare cases, prostatitis can be caused by fungi [10, 12].

Prostatitis can be divided into two types: acute, in which the infection is more recent and the inflammatory process is more exacerbated and chronic, in which the clinical signs are milder.

The treatment of prostatitis should take into account some key factors for it to be successful. It is of extreme importance for the choice of the drug to evaluate the result of the culture of the prostatic fluid or semen; in addition, one should take into account the pharmacodynamics of the chosen active principle, since the prostate is a tissue of difficult penetration of the antibiotics due to the difference in pH between the prostate fluid and blood [1, 9].

Antibiotic treatment in the case of bacterial prostatitis should last for at least 4 weeks, and a new culture of prostatic fluid and urine should be performed before the end of treatment so that it can be decided between completion and continuation. A new culture test is also recommended 30 days after the end of treatment so that its success is confirmed [1].

Trimethoprim sulfa, chloramphenicol, and enrofloxacin are antibiotics that have good penetration into the prostatic tissue and are therefore good candidates for the treatment of bacterial prostatitis [16].

Castration is indicated as adjuvant therapy to reduce prostate volume and prevent relapse; however, castration should not be performed during acute infection to avoid complications [16].

5.4.1 Acute prostatitis

In acute prostatitis, the infection is more recent, the inflammation is more intense, and the clinical signs presented are anorexia, fever, apathy, vomit, hypogastric region pain, and preputial discharge. In addition, the complete blood count is a characteristic of an acute infectious process, with neutrophilia and left-sided deviation [1].

Diagnosis should be made based on the animal's history and physical examination associated with exams such as transrectal prostate palpation, ultrasonography, complete blood count, urinalysis, and culture of prostate fluid or semen in cases where collection is possible [1].

In prostate palpation, it is common for the animal to present painful sensitivity due to the inflammatory process present there. In ultrasonography, the prostate will most often be enlarged, with its echogenicity increased, and may or may not have associated cysts or abscesses. Urine and semen will most often have neutrophils and bacteria present [1].

5.4.2 Chronic prostatitis

Unlike acute prostatitis, few chronic or no clinical signs are exhibited by the animal. The most common are recurrent urinary tract infections and bloody

urethral discharge. In addition, in rectal palpation, the prostate often has a normal volume, and the animal has no painful sensitivity. Because of this, the diagnosis in this case is more difficult and should be based on the clinical findings associated with ultrasonography and culture of the prostatic fluid or semen [1, 9].

The difference of “acute” and “chronic” is usually a clinical classification, since both entities present a very divergent clinical signs, prognosis, and treatment. In a pathological “view,” inflammation is usually classified into focal or multifocal and according to the inflammatory infiltrate (cell type involved) and the presence or absence of intraluminal infiltration.

In humans, the chronic inflammatory infiltrate associated with the epithelial atrophy is described as a proliferative inflammatory atrophy (PIA) and is considered as a preneoplastic lesion [17]. In dogs, PIA is also found (**Figure 4**).

5.5 Prostatic abscesses

Prostatic abscesses can be consequences of prostatic cysts that become contaminated or of prostatitis. In the case of prostatitis, tissue inflammation can induce obstruction of the prostatic ducts, causing contaminated contents to accumulate resulting in an abscess [18].

The diagnosis is achieved through the association of history, clinical signs, and complementary tests. The signs of prostatic abscesses are related to the increased prostatic volume, the most common being tenesmus and dysuria. In addition, the animal may or may not feel pain during rectal palpation of the prostate. Ultrasonography and culture of the prostatic fluid are important tests for the diagnosis of prostatic abscesses [1, 14].

The treatment is based on draining the contents of the abscess. The most traditional ones are surgical intervention such as debridement and omentalization, marsupialization, subtotal prostatectomy, or placement of multiple penrose drains. However, due to the risks associated with these procedures, new approaches are emerging [14].

An alternative to the traditional surgical approach is the percutaneous drainage of the abscesses guided by ultrasonography, which in addition to being a cheaper technique than traditional surgery proved to be safe and effective. In addition, antibiotic therapy based on the result of prostatic fluid culture should be instituted in association with the technique chosen for drainage of the abscess [14].

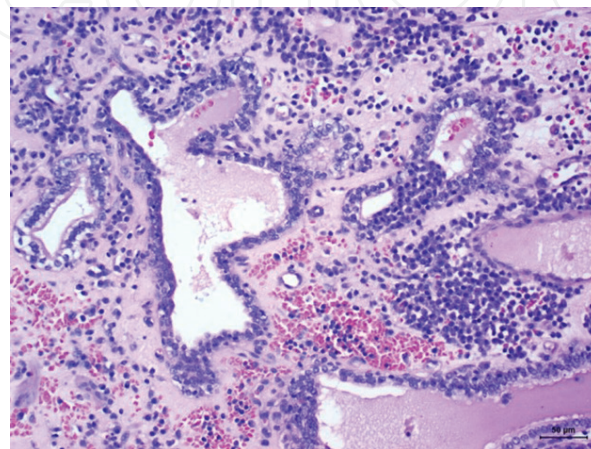


Figure 4.
Canine prostatic atrophic epithelium. There is atrophy of the glandular epithelium, disposed in two or more layers. There is an intense inflammatory mononuclear infiltrate and hemorrhage. Hematoxylin and eosin (H&E) staining, 10 \times .

5.6 Prostatic neoplasia

Prostatic adenocarcinomas are a rare condition, affecting both castrated and non-castrated animals. They present a prevalence of 0.2–0.6% and have a predilection for animals with more advanced age, and the average age of an animal diagnosed with prostatic neoplasia is around 10 years [19]. Castrated dogs may present a greater chance of developing prostatic adenocarcinoma, being up to 2.38 times greater than non-castrated dogs [19]. In addition, prostatic carcinoma in dogs is androgen independent so castration is not a therapeutic possibility, except in cases associated with PH [16].

In the author's experience, intact dogs present a higher prevalence of prostate cancer (PC), and this can be related to our dog population. Usually, castration is not performed in male dogs. Thus, we have a majority population of intact dogs. In a previous study of our research group [20], we have described a tumor phenotype in 90 canines with PC, and all dogs (90/90) were intact. We did not find any PC in a castrated dog, probably because in our dog population, castration is not routinely performed.

The clinical signs associated with prostatic carcinoma are dysuria, tenesmus, hematuria, anorexia, and weight loss. In addition, through transrectal palpation, the prostate is most often enlarged and asymmetric, and the animal may or may not present pain [16]. Complementary tests such as ultrasound and X-ray should always be required to assess the extent of the neoplasm in both the prostate and possible metastasis. Common radiographic findings are prostatic enlargement, prostatic mineralization, sublumbar lymphadenopathy, axial skeletal metastasis, pulmonary metastasis, and appendicular skeletal metastasis [19].

In ultrasonography, the most common findings are prostatic enlargement, prostatic tissue mineralization, diffuse areas presenting hyperechogenicity, and irregular prostatic contour [19]. Areas of metastasis of prostatic carcinoma in descending order of incidence include the lungs, regional lymph nodes, liver, urethra, spleen, colon, rectum, urinary bladder, bones, heart, liver, and distal and adrenal lymph nodes [16].

The definitive diagnosis of prostatic carcinoma is made by means of cytology or prostate biopsy. Both techniques can be performed transabdominally with the aid of ultrasonography. There are different histological subtypes of prostatic adenocarcinoma, and the major challenge is the differentiation between urothelial and luminal origins of the undifferentiated subtypes. The castrated dogs are more prone to develop the most undifferentiated kinds of neoplasms and seem difficult

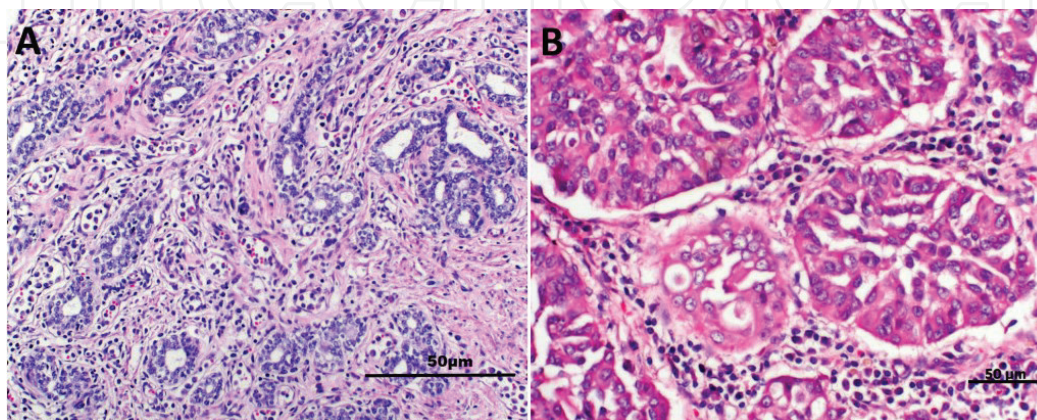


Figure 5. Canine prostate cancer. (A) Low-grade canine prostate cancer (Gleason score 6) composed by small glandular proliferation with tubules showing more than two layers with evident nucleoli. Hematoxylin and eosin (H&E) staining, 10×. (B) High-grade prostate cancer (Gleason score 8), showing moderate anisokaryosis, evident nucleoli, and mitosis. Hematoxylin and eosin (H&E) staining, 40×.

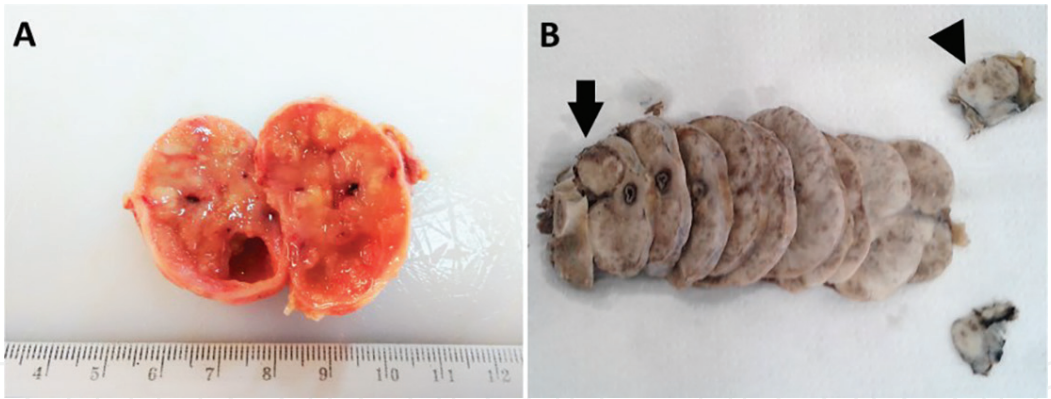


Figure 6.
Gross morphology of two canine prostate cancers. (A) Infiltrative prostate cancer, with the prostate gland showing a heterogeneous parenchyma, cystic areas, and necrosis. (B) A serial section of a prostate gland with a canine prostate cancer showing a well-delimited mass (arrows).

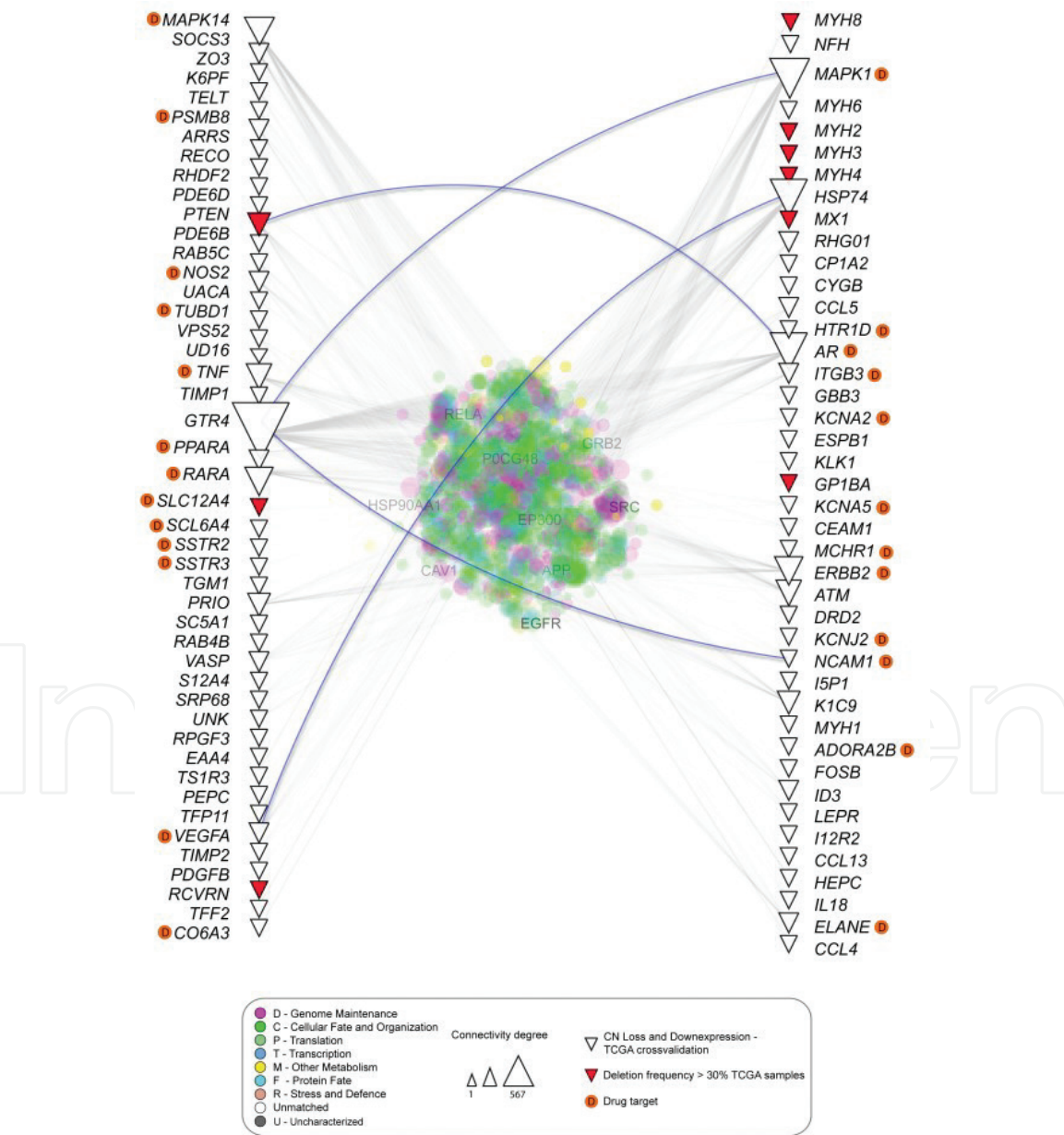


Figure 7.
Protein-protein interaction (PPI) analysis using the canine data (copy number alteration provided by Amorim et al. [27]) and the human prostate cancer data from The Cancer Genome Atlas (TCGA). It is possible to evaluate the connectivity degree between gene alterations in human and dogs (triangles). Genes with deletion frequency higher than 30% (red triangles) and genes with developed drug targets are also observed.

to differentiate an undifferentiated prostatic adenocarcinoma from an undifferentiated prostatic urothelial carcinoma [21]. Recently, the Gleason score was also proposed in canine prostatic pathology (**Figure 5**) [22].

Morphologically, canine PC can present an infiltrative growth pattern or form a prostatic mass (**Figure 6**). The infiltrative pattern can be difficult to differentiate from other prostatic diseases such as prostatitis and PH. Thus, in these cases, ultrasound examination can be challenging.

The treatment of prostatic adenocarcinoma is most often ineffective, making it palliative rather than curative. In addition, in most cases the diagnosis is made only at an advanced stage of the disease, making the prognosis even more reserved [1]. The results of chemotherapy and surgical protocols in cases of prostatic adenocarcinoma are unsatisfactory, not prolonging the life expectancy of the patient. Radiotherapy may be an option in cases where increased prostatic volume due to the tumoral mass is a problem for the animal, since this therapeutic option can cause reduction of the prostate volume but without increase in life expectancy [8].

Another important point to consider is if the animal is neutered or not. Castration or the use of finasteride may help in reducing the prostatic volume but

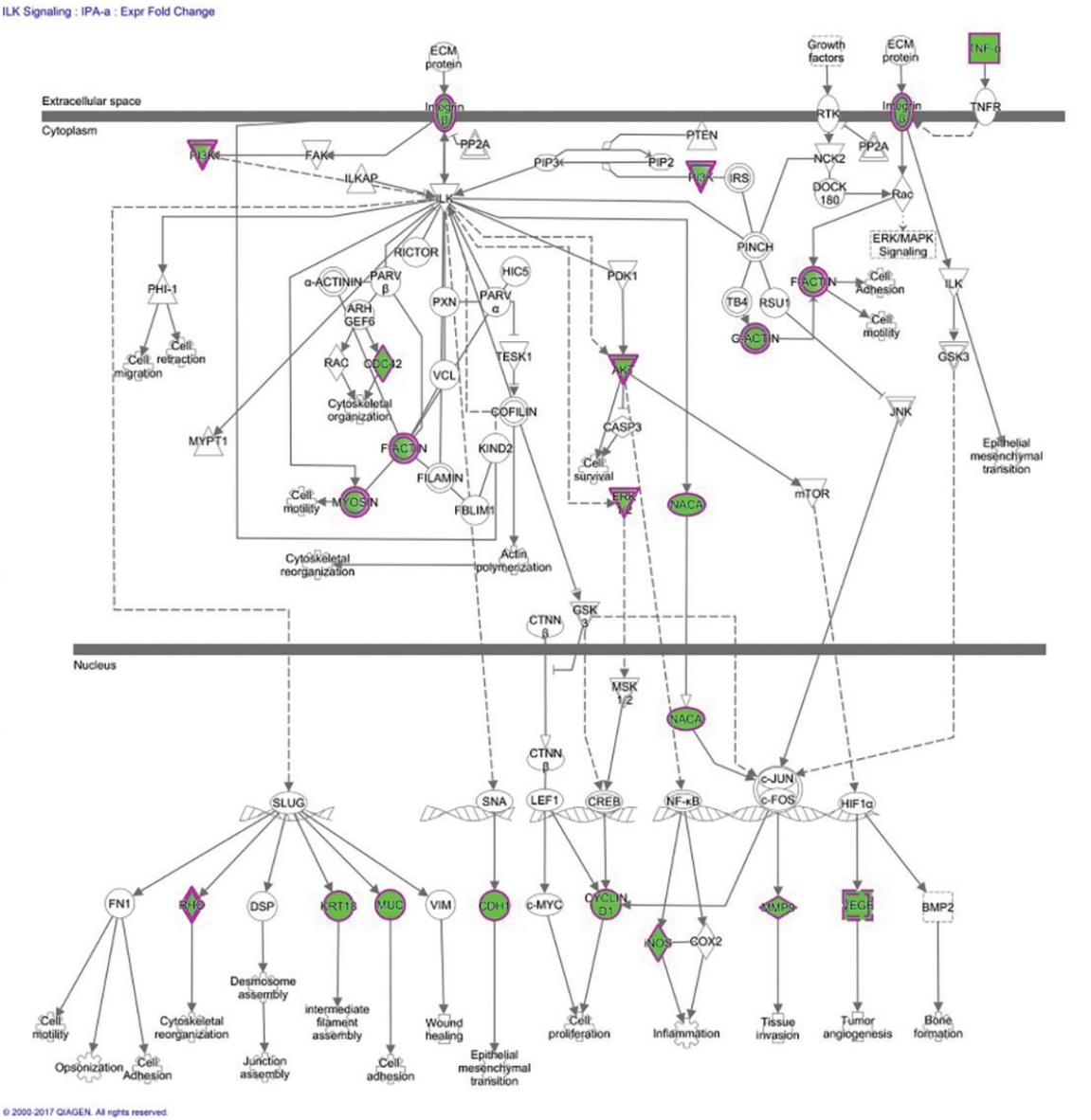


Figure 8. Ingenuity pathway analysis (IPA) of the canine copy number alteration data published by Amorim et al. [27]. Disruption of the ILK signaling pathway. Genes in green present a significant copy number loss compared to normal tissue.

without influence on the tumor mass. Due to the poor prognosis of this condition, usually euthanasia must be taken into consideration [1].

The genomic profiling of canine PC is poorly explored. Few previous studies have evaluated the genomic of transcriptomic alterations in canine PC. In human, the molecular subtype of the PC is very important for the patient prognosis. The recurrent *SPOP*, *FOXA1*, and *IDH1* mutations, genic fusions (*ERG*, *ETV1/4*, and *FLI1*), activated *PI3K/AKT/mTOR* and *MAPK* pathway mutations, and germ line or somatic DNA-repair gene mutations (including *BRCA1/2*, *CDK12*, *ATM*, *FANCD2*, and *RAD51C*) (~20% of primary PC) represent different subtypes of human PC [23].

Canine molecular alteration in E-cadherin, Caveolin-1, APC and β -catenin [24], NKX3.1 and c-Myc [3], c-KIT [25] and PTEN, TP53, MDM2, and AR expression [26] was previously described in literature. However, these studies have evaluated only gene expression. A recent study from our research group investigated the copy number alterations in canine PC [27]. We identified copy number loss in TP53 and PTEN and gain of MDM2, indicating the role of the TP53 pathway in the development of canine PC. Moreover, we identified many drug targets in canine PC, including VEGF and HER-2 (**Figure 7**) and imbalances in ILK signaling pathway (**Figure 8**).

Acknowledgements

The authors would like to thank Fundação de Amparo à Pesquisa do Estado de São Paulo (FAPESP) for its financial support (#2015/25400-7).

Conflict of interest

The authors have no conflict of interests.

Author details

Antonio Fernando Leis-Filho and Carlos E. Fonseca-Alves*
School of Veterinary Medicine and Animal Science, Sao Paulo State
University—UNESP, Botucatu, Brazil

*Address all correspondence to: carloseduardofa@hotmail.com

IntechOpen

© 2018 The Author(s). Licensee IntechOpen. This chapter is distributed under the terms of the Creative Commons Attribution License (<http://creativecommons.org/licenses/by/3.0>), which permits unrestricted use, distribution, and reproduction in any medium, provided the original work is properly cited. 

References

- [1] Smith J. Canine prostatic disease: A review of anatomy, pathology, diagnosis, and treatment. *Theriogenology*. 2008;**70**:375-383. DOI: 10.1016/j.theriogenology.2008.04.039
- [2] Evans HE, Christensen GC. The urogenital system. In: *Miller's Anatomy of the Dog*. 4th ed. Philadelphia, USA: WB Saunders; 1993. pp. 514-516
- [3] Fonseca-Alves CE, Kobayashi PE, Laufer-Amorim R. Evaluation of NKX3.1 and C-MYC expression in canine prostatic cancer. *Research in Veterinary Science*. 2018;**118**:365-370. DOI: 10.1016/j.rvsc.2018.04.001
- [4] Fonseca-Alves CE, Gonçalves Corrêa A, Leal Santos-Junior H, Elias F, dos Santos Costa S, Dignani de Moura VMB. Abscesso prostático em cães: relato de 15 casos. *Semina: Ciências Agrárias*. 2012;**33**:1157-1164. DOI: 10.5433/1679-0359.2012v33n3p1157
- [5] Lai CL, van den Ham R, van Leenders G, van der Lugt J, Teske E. Comparative characterization of the canine normal prostate in intact and castrated animals. *The Prostate*. 2008;**68**:498-507. DOI: 10.1002/pros.20721
- [6] Dubé JY, Lazure C, Tremblay RR. Dog prostate arginine esterase is related to human prostate specific antigen. *Clinical and Investigative Medicine*. 1986;**9**:51-54
- [7] Hayward SW, Cunha GR. The prostate: Development and physiology. *Radiologic Clinics of North America*. 2000;**38**:1-14. DOI: 10.1016/S0033-8389(05)70146-9
- [8] Gobello C, Castex G, Corrada Y. Serum and seminal markers in the diagnosis of disorders of the genital tract of the dog: A mini-review. *Theriogenology*. 2002;**5**:1285-1291. DOI: 10.1016/S0093-691X(02)00628-3
- [9] Barsanti JA, Finco DR. Canine prostatic diseases. *Veterinary Clinics of North America: Small Animal Practice*. 1986;**16**:587-599. DOI: 10.1016/S0195-5616(86)50063-2
- [10] Korodi G, Igna V, Cernescu H, Mircu C, Frunză I, Knop R. Canine prostate pathology. *Lucrari Stiintifice-Universitatea de Stiinte Agricole a Banatului Timisoara, Medicina Veterinara*. 2008;**41**:187-194
- [11] Sirinarumitr K, Johnston SD, Kustritz MVR, Johnston GR, Sarkar DK, Memon MA. Effects of finasteride on size of the prostate gland and semen quality in dogs with benign prostatic hypertrophy. *Journal of the American Veterinary Medical Association*. 2001;**218**:1275-1280. DOI: 10.2460/javma.2001.218.1275
- [12] Paclikova K, Kohout P, Vlasin M. Diagnostic possibilities in the management of canine prostatic disorders. *Veterinarni Medicina (Praha)*. 2006;**51**:1. DOI: 10.17221/5511-vetmed
- [13] White RA. Prostatic surgery in the dog. *Clinical Techniques in Small Animal Practice*. 2000;**15**:46-51. DOI: 10.1053/svms.2000.7304
- [14] Boland LE, Hardie RJ, Gregory SP, Lamb CR. Ultrasound-guided percutaneous drainage as the primary treatment for prostatic abscesses and cysts in dogs. *Journal of the American Animal Hospital Association*. 2003;**39**:151-159. DOI: 10.5326/0390151
- [15] Lindberg R, Jonsson OJ, Kasström H. Sertoli cell tumours associated with feminization, prostatitis and squamous metaplasia of the renal tubular epithelium in a dog. *Journal of Small Animal Practice*. 1976;**17**:451-458. DOI: 10.1111/j.1748-5827.1976.tb06985.x
- [16] Johnston SD, Kamolpatana K, Root-Kustritz MV, Johnston GR. Prostatic disorders in the dog.

Animal Reproduction Science.
 2000;**60**:405-415. DOI: 10.1016/
 S0378-4320(00)00101-9

[17] De Marzo AM, Marchi VL, Epstein JI, Nelson WG. Proliferative inflammatory atrophy of the prostate: Implications for prostatic carcinogenesis. *The American Journal of Pathology*. 1999;**155**:1985-1992. DOI: 10.1016/S0002-9440(10)65517-4

[18] White RA, Williams JM. Intracapsular prostatic omentalization: A new technique for management of prostatic abscesses in dogs. *Veterinary Surgery*. 1995;**24**:390-395. DOI: 10.1111/j.1532-950X.1995.tb01349.x

[19] Bell FW, Klausner JS, Hayden DW, Feeney DA, Johnston SD. Clinical and pathologic features of prostatic adenocarcinoma in sexually intact and castrated dogs: 31 cases (1970-1987). *Journal of the American Veterinary Medical Association*. 1991;**199**:1623-1630

[20] Fonseca-Alves CE, Kobayashi PE, Rivera Calderón LG, Felisbino SL, Rinaldi JC, Drigo SA, et al. Immunohistochemical panel to characterize canine prostate carcinomas according to aberrant p63 expression. *PLoS One*. 2018;**12**:e0199173. DOI: 10.1371/journal.pone.0199173

[21] Gobello C, Corrada Y. Noninfectious prostatic diseases in dogs. *Compendium on Continuing Education for the Practising Veterinarian-North American Edition*. 2002;**24**:99-109

[22] Palmieri C, Grieco V. Proposal of Gleason-like grading system of canine prostate carcinoma in veterinary pathology practice. *Research in Veterinary Science*. 2015;**103**:11-15. DOI: 10.1016/j.rvsc.2015.09.004

[23] Cancer Genome Atlas Research Network. The molecular taxonomy of primary prostate cancer. *Cell*.

2015;**163**:1011-1025. DOI: 10.1016/j.cell.2015.10.025

[24] Kobayashi PE, Fonseca-Alves CE, Rivera-Calderón LG, Carvalho M, Kuasne H, Rogatto SR, et al. Deregulation of E-cadherin, β -catenin, APC and Caveolin-1 expression occurs in canine prostate cancer and metastatic processes. *Research in Veterinary Science*. 2018;**118**:254-261. DOI: 10.1016/j.rvsc.2018.03.004

[25] Fonseca-Alves CE, Kobayashi PE, Palmieri C, Laufer-Amorim R. Investigation of c-KIT and Ki67 expression in normal, preneoplastic and neoplastic canine prostate. *BMC Veterinary Research*. 2017;**13**:380. DOI: 10.1186/s12917-017-1304-0

[26] Rivera-Calderón LG, Fonseca-Alves CE, Kobayashi PE, Carvalho M, Drigo SA, de Oliveira Vasconcelos R, et al. Alterations in PTEN, MDM2, TP53 and AR protein and gene expression are associated with canine prostate carcinogenesis. *Research in Veterinary Science*. 2016;**106**:56-61. DOI: 10.1016/j.rvsc.2016.03.008

[27] Fonseca-Alves CE, Busso AF, Silveira SM, Rogatto SR, Amorim RL. Genomic gains in prostatic carcinoma and proliferative inflammatory atrophy in dogs. *Cancer Research*. 2014;**72**: 5260. DOI: 10.1158/1538-7445.AM2012-5260