

# We are IntechOpen, the world's leading publisher of Open Access books Built by scientists, for scientists

6,900

Open access books available

186,000

International authors and editors

200M

Downloads

Our authors are among the

154

Countries delivered to

TOP 1%

most cited scientists

12.2%

Contributors from top 500 universities



WEB OF SCIENCE™

Selection of our books indexed in the Book Citation Index  
in Web of Science™ Core Collection (BKCI)

Interested in publishing with us?  
Contact [book.department@intechopen.com](mailto:book.department@intechopen.com)

Numbers displayed above are based on latest data collected.  
For more information visit [www.intechopen.com](http://www.intechopen.com)



---

# Arthroplasty for Proximal Femur Fracture

---

Mark Curtin, Eoghan Pomeroy and James Broderick

Additional information is available at the end of the chapter

<http://dx.doi.org/10.5772/intechopen.77053>

---

## Abstract

With an increasing global incidence of hip fractures, designing appropriate treatment strategies for hip fractures is fundamentally important to healthcare professionals, policymakers, and payers of healthcare services. We will evaluate the role of total hip replacement (THR) in the setting of trauma for the acute treatment of hip fractures. In this chapter, we will compare hemiarthroplasty and total hip replacement in the acute setting while also examining the role of arthroplasty in the setting of failed internal fixation, as well as in pathologic fractures. We will describe the pearls and pitfalls of surgical technique in these scenarios, highlighted with case examples.

**Keywords:** arthroplasty, trauma, hemiarthroplasty, THR, salvage

---

## 1. Introduction

The incidence of the neck of femur fracture is increasing alongside the increasing proportion of elderly patients with multiple comorbidities in our population statistics [1]. It is currently estimated that more than 80,000 hip fractures are treated each year in the United Kingdom—the great majority of these fractures require some form of surgical treatment, as nonoperative management is associated with high morbidity and complication rates [2–5]. Deciding on the most appropriate intervention is often challenging; factors such as fracture location and configuration, bone stock, physiological age, mobility, comorbidity, and implant selection are only some of the considerations in such cases. Optimal care for these patients requires multidisciplinary intervention across a broad range of services including surgery, anaesthesia, physiotherapy, geriatrics, and rehabilitative medicine.

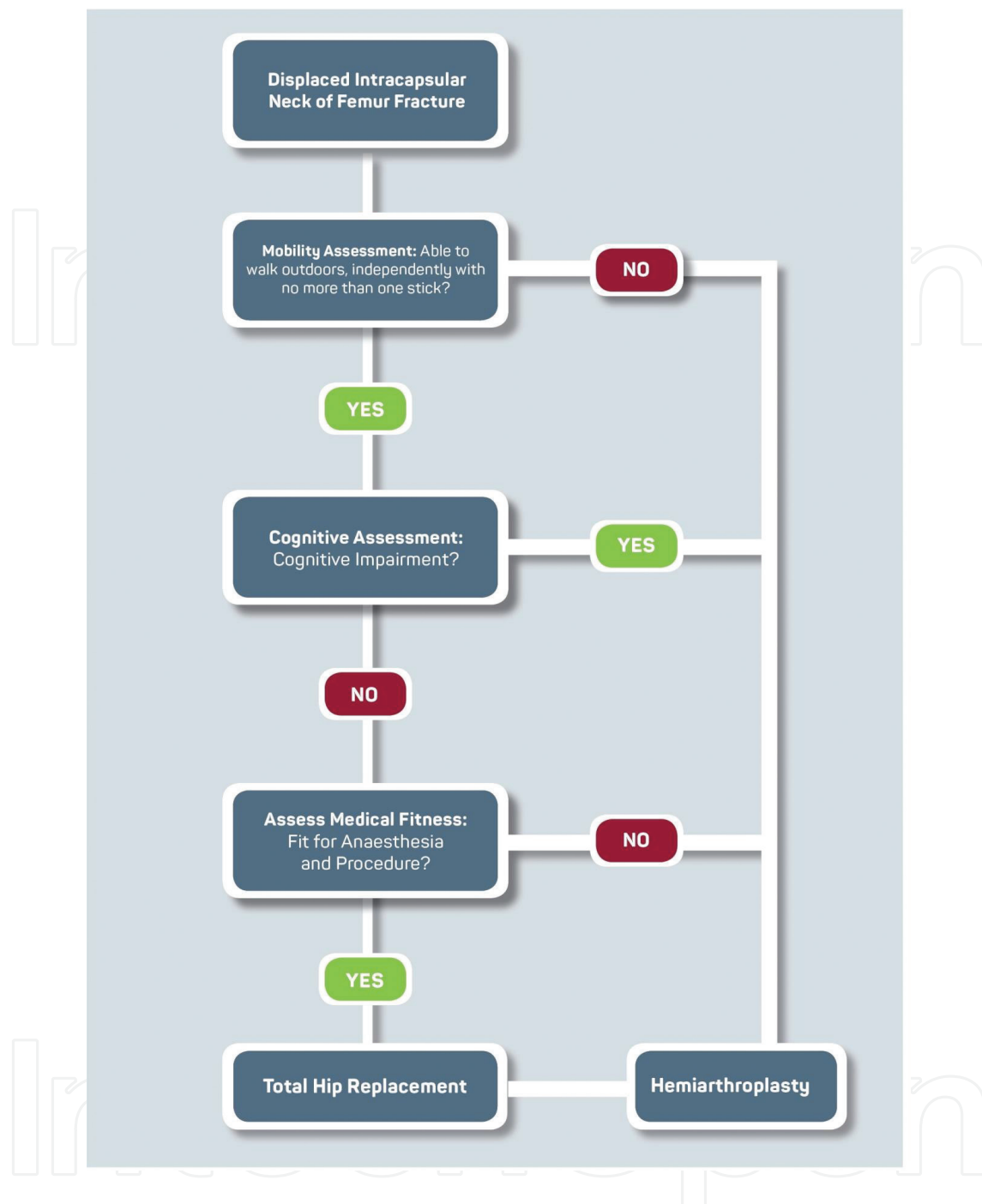
Fractures are broadly categorised as intracapsular or extracapsular and can be classified as stable or unstable. In general, extracapsular fractures are treated by reduction and

osteosynthesis, as are selected intracapsular fractures. Displaced intracapsular fractures are conventionally treated by hemiarthroplasty, but total hip replacement [THR] has a role either as a primary intervention in the younger more active patient or as a salvage procedure for failed osteosynthesis or hemiarthroplasty. Well-recognised goals of operative treatment include immediate pain relief, a rapid return to ambulation, an accelerated period of rehabilitation, and maintenance of independent living. Arthroplasty is generally considered to be a highly effective treatment for many painful hip conditions. By definition total hip replacement requires prosthetic replacement of the femoral and acetabular joint surfaces. All implants require an interface for skeletal fixation which can be achieved using bone cement or by biological fixation. In addition the implant must be able to accommodate an articular surface to provide a low-friction, physiological range of motion. Identifying the most appropriate treatment strategy for hip fractures avoids secondary hospital admissions, costly and often complicated reoperations, loss of independence, and physical disability. Designing optimal treatment strategies for hip fractures is fundamentally important to healthcare professionals, policymakers, and payers of healthcare services.

Stable fractures can be treated by osteosynthesis with predictable and favourable results [6, 7]. Conversely, surgical fixation of unstable fracture patterns remains challenging due to deficient bone stock and osteoporosis [8, 9]. In the past, fixed nail-plate devices used for the fixation of these fractures had high rates of cut-out and fracture displacement. Sliding hip screws have become the predominant method of fixation of these fractures with reduced rates of cut-out and fracture displacement compared with fixed nail-plate devices [10–14]. Cephalomedullary fixation has also demonstrated reduced cut-out rates in osteoporotic bone and is the preferred method of fixation for unstable intertrochanteric fractures [15, 16].

Complications of internal fixation are well documented including perforation of the femoral head, excessive sliding with secondary shortening, plate pull-out, and plate breakage [17, 18]. In cases where fixation is tenuous, a period of restricted mobilisation is suggested [19] during which morbidities such as pressure sores, respiratory tract infections, atelectasis, and deep vein thrombosis may develop. Despite considerable advances in internal fixation methods, the failure rate of the sliding hip screw is 6.8–9.8%, while the failure rate of cephalomedullary nails ranges from 7.1 to 12.5% in unstable fractures [20–22].

While internal fixation is widely viewed as the preferred treatment for young patients and elderly patients with stable fractures, there is still no standard treatment for active patients above 70 years of age [23, 24]. A suggested treatment algorithm can be seen in **Chart 1**. While hemiarthroplasty is expeditious and permits early mobilisation, in certain cases revision to a THR is required due to painful acetabular erosion or protrusion [25]. Radiographic studies have demonstrated that most of the motion in hemiarthroplasties occurs at the interface of the bipolar component and the acetabulum, not between the femoral head and the bipolar component. The significance of acetabular erosion and groin pain after a hemiarthroplasty is a topic of debate among the orthopaedic community. Many studies contributing to the pool of knowledge on the topic use outdated implants. Added to this is the fact that the cognition and activity levels of patients receiving hemiarthroplasty vary widely and may affect the reporting of pain.



**Chart 1.** Proposed algorithm in addressing femoral neck fractures in the trauma setting.

The recently published HEALTH trial protocol [26] outlines a prospective randomised control trial to evaluate the outcomes of THR versus hemiarthroplasty in the treatment of femoral neck fractures. This study aims to assess the outcomes of both treatment modalities up to 2 years postoperatively. A recent publication in the *Journal of Arthroplasty* by Grosso et al. demonstrated a low conversion rate of hemiarthroplasty to THR when a hemiarthroplasty was performed for a displaced neck of femur fracture in patients over 75 years. In this study, a 2.5% conversion rate at an average of 1.9 years post-index procedure was recorded, with

acetabular wear, which is the leading cause [27]. Uncertainty remains as to which type of prosthesis is most appropriate for the treatment of fractures in these elderly patients. This leads to significant regional variations in treatment: THR is up to three times more likely to be performed in the treatment of hip fractures in Sweden than in England and twice as likely as in Canada [28].

## 2. Preoperative evaluation

A detailed history and clinical examination is necessary in all cases of hip fractures. Particular care must be made to identify pre-existing medical comorbidities and regular anticoagulants being taken by the patient. A comprehensive discussion should take place with the patient and their relatives in relation to any proposed management strategy. Morbidity and mortality associated with femoral neck fracture care should be discussed. Mortality is 10% within the first 30 days reflecting the compromised status of many of these patients. Mortality rates rise to approximately 40% at 12 months.

Examination may reveal a shortened, externally rotated lower extremity. The neurovascular status of the lower limb should be evaluated and documented, and a secondary survey should be completed to rule out associated injuries.

Appropriate imaging should take the form of plain film radiographs of the pelvis and femur in anterior-posterior and lateral planes. The pelvis should be held in neutral with both femurs clearly visible and the feet held in internal rotation. Preoperative estimates of magnification on X-rays are frequently incorrect and can lead to mismatching of implant sizes, limb length discrepancies, and disturbance of the biomechanical parameters of the hip joint. The magnification factor for pelvic imaging normally ranges from 109 to 128%. Radioopaque calibration spheres can be sited midline to femurs and proximally towards the pubic symphysis to aid in digital templating of the preoperative X-rays. The contralateral hip should be used as a surrogate for templating in the trauma setting. Digital templating is essential to determine the location of the neck cut, size of the prosthesis, appropriate offset, and depth of insertion. If there is a concern for pathological fracture, appropriate imaging of the whole femur should be obtained in the first instance, and intraoperative histological samples should be sent for analysis.

All patients with a hip fracture should have a preoperative electrocardiogram, and in those over the age of 65, a chest X-ray should also be performed. It has been determined by the Association of Anaesthetists of Great Britain and Ireland (AAGBI) that a preoperative echocardiogram should not delay the passage of a patient with a hip fracture to theatre and should rather be performed, if necessary, during the postoperative period. Routine preoperative blood tests may reveal preoperative anaemia which occurs in 30–40% of patients and may be attributable to the fracture itself, haemodilution or a pre-existing condition. The acute response to trauma may lead to neutrophilia or leucocytosis. It is noteworthy that electrolyte imbalances are not uncommon in this cohort of patients, especially hyponatremia and hypokalemia. Hyperkalemia may also be an indicator of rhabdomyolysis occurring secondary to a prolonged period of immobilisation following the initial traumatic event.

Neuraxial anaesthesia is often the preferred form of anaesthesia for treatment of femoral fractures. The suspicion of aortic stenosis on clinical examination often precludes neuraxial anaesthesia. Despite this, general anaesthesia is also a safe option, and the Sprint Audit has shown no significant difference in mortality between these modes of anaesthesia [29]. Combined neuraxial anaesthesia and general anaesthesia has shown a trend towards increased mortality. This is most likely related to the 'double hit' hypotensive effects of both modalities of anaesthesia.

### 3. Hemiarthroplasty versus total hip replacement

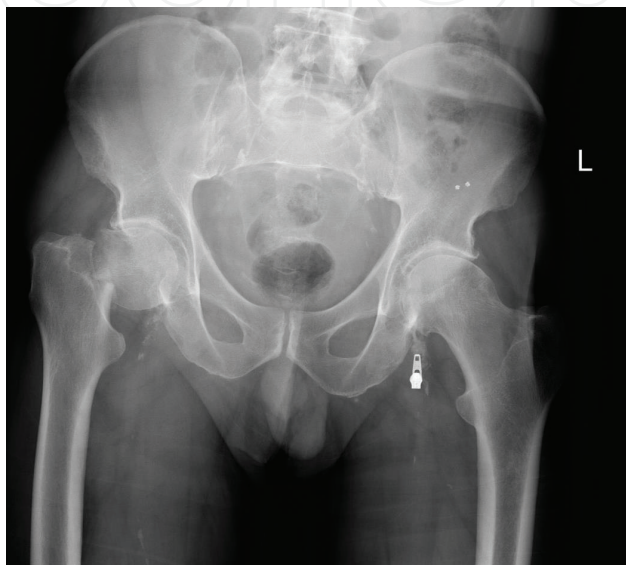
In the vast majority of cases, the accepted treatment for displaced neck of femur fractures in the elderly is a unipolar or bipolar hemiarthroplasty, especially in elderly patients with low functional demands. Compared with THR, hemiarthroplasty has the advantage of being a simpler, standardised procedure with shorter operating times, and less blood loss. In the acute trauma setting, many orthopaedic surgeons are more comfortable performing hemiarthroplasty rather than THR. Therefore, THR may not be readily available to the trauma patient, and surgical delay is likely to increase morbidity and mortality. Recent studies conclude that THR in the trauma setting is associated with improved functional outcomes and lower reoperation rates when compared with hemiarthroplasty, albeit with a higher dislocation rate [30–32]. Instability post THR is multifactorial, and contributory factors include surgical approach, bearing diameter, restoration of hip biomechanics, cognitive dysfunction, and presence of neuromuscular disease. Where the posterior approach has been utilised, meticulous capsular repair is essential to minimise instability. Some authors advocate the anterolateral approach when treating a femoral neck fracture with THR. This reduces the dislocation rate at the expense of potential abductor dysfunction and a postoperative Trendelenburg gait. The use of large head sizes has also reduced dislocation rates, with the literature suggesting that the benefit is greatest when utilising the posterior approach.

It is essential to adhere to strict selection criteria when determining suitability of patients with hip fractures for THR in order to minimise complication rates. In 2011 the National Institute for Health and Care Excellence (NICE) published their guidelines and recommended THR for patients with adequate cognitive and physical function who are fit to undergo anaesthesia and major surgery. Perry et al. evaluated UK Hip Fracture Database information to ascertain compliance with NICE guidelines for THR [33]. Their study evaluated patients over the age of 60 presenting acutely with displaced intracapsular femoral neck fractures. They determined that only 32% of ostensibly eligible patients underwent THR, and, of those who had surgery, 42% did not qualify under the NICE eligibility criteria. Inclusion and exclusion criteria for THR in trauma need to be defined more accurately based on specific rather than arbitrary parameters.

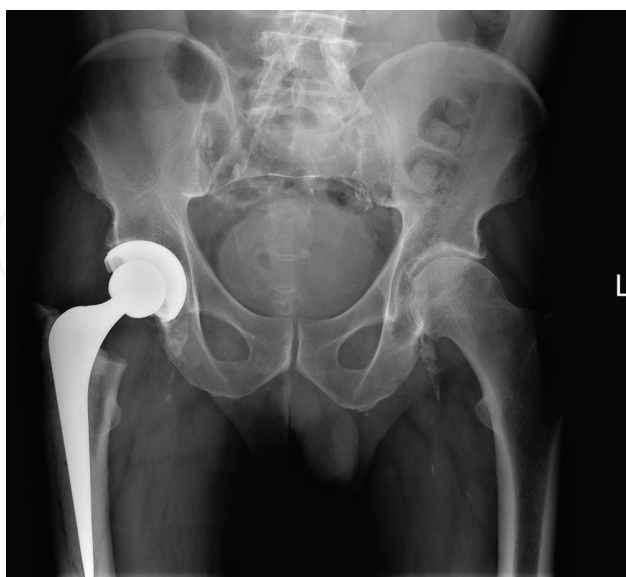
THR performed for trauma has equivalent results to those performed electively. Anakwe et al. matched 100 trauma patients with an elective cohort and demonstrated equivalent functional outcomes [34]. THR may appear as a more expensive treatment for trauma in terms of implant cost, but the overall costs associated with unipolar and bipolar hemiarthroplasties (including



revision surgeries) are higher in the long term [35]. Maceroli et al. demonstrated lower mortality rates in patients undergoing THR for femoral neck fractures in centres that performed large numbers of such procedures [36]. Uhler et al. demonstrated that a patient will gain more cumulative utility over the course of 2 years by waiting 48 hours for a THR, despite an increase in short-term morbidity associated with delayed surgery [37]. It seems reasonable therefore to advocate THR for suitable patients where dedicated arthroplasty services are available. **Figure 1** demonstrates a left basicervical neck of femur fracture, with subsequent treatment with a hybrid THR shown in **Figure 2**.



**Figure 1.** AP radiograph of pelvis showing left basicervical neck of femur fracture.



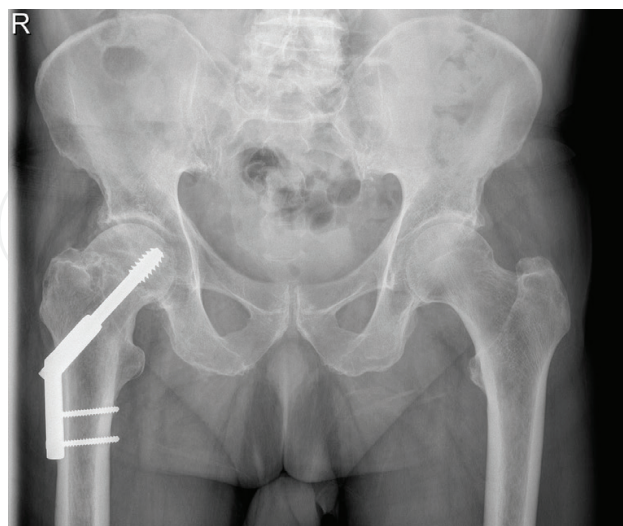
**Figure 2.** AP pelvis demonstrating subsequent treatment with a hybrid THR in the acute setting.

#### 4. THR for failed neck of femur internal fixation

Following initial treatment with internal fixation, the neck of femur fractures may develop nonunion and osteonecrosis, with reoperation rates of up to 40% reported in the literature. Nikolopoulos et al. demonstrated in a prospective study that patients with displaced neck of femur fractures who underwent internal fixation had a higher rate of avascular necrosis than those that were undisplaced [38]. This group of patients may develop disabling secondary degenerative symptoms necessitating arthroplasty. We highlight this with examples of clinical cases. **Figure 3** shows the collapse of the femoral head following initial sliding screw fixation of a basicervical neck of femur fracture. This was subsequently revised to a hybrid THR as demonstrated in **Figure 4**. **Figure 5** describes the case of screw cut-out post ORIF of the neck of femur fracture, which was subsequently revised to a modular prosthesis as seen in **Figure 6**.

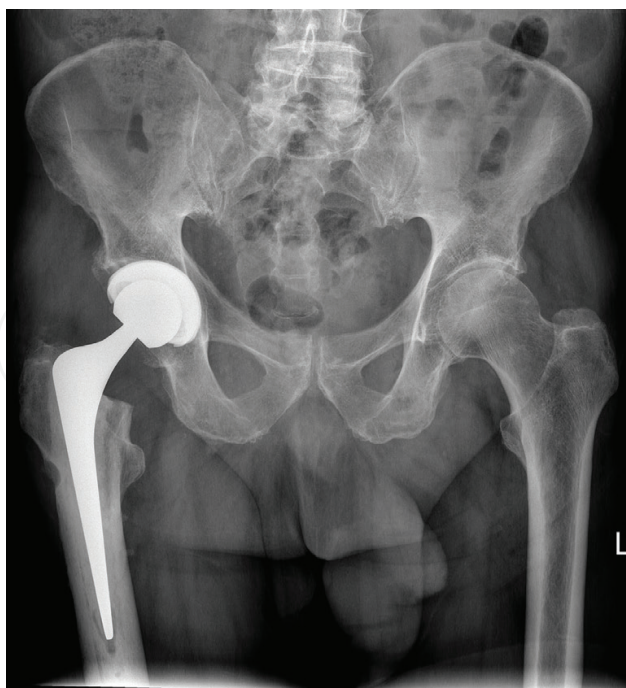
Tidermark et al. demonstrated suboptimal outcomes in patients with displaced neck of femur fractures treated with internal fixation, showing impaired functional outcomes when compared with a cohort of undisplaced fractures despite radiographic and clinical evidence of union [39].

In treating nonunion the surgical team must consider the presence of infection. Clinical evaluation and serial erythrocyte sedimentation rate (ESR) and C-reactive protein (CRP) levels are useful diagnostic tools and if abnormal might prompt joint aspiration or bone biopsy and culture. If preoperative or intraoperative findings suggest infection, a two-stage revision with removal of metalwork and excision of the femoral head is usually performed. An antibiotic-impregnated spacer is implanted in the first instance, and subsequent arthroplasty is performed at an appropriate later date.

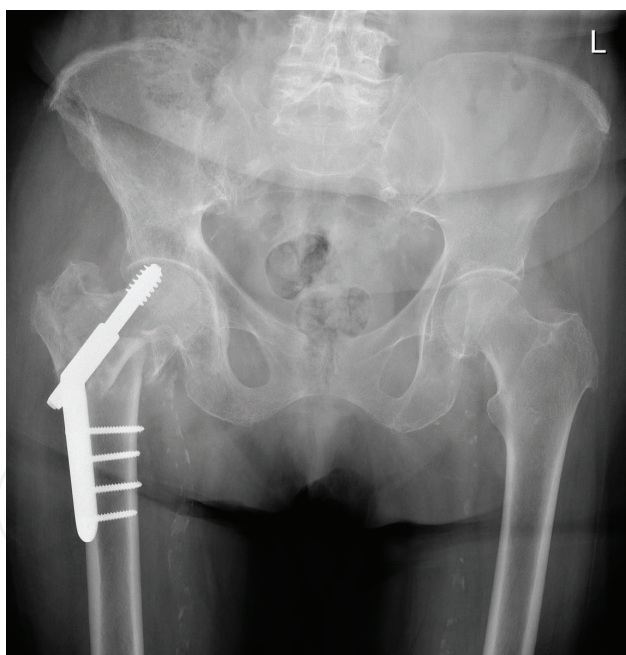


**Figure 3.** AP radiograph of pelvis demonstrating collapse of femoral head post dynamic hip screw fixation of basicervical neck of femur fracture.



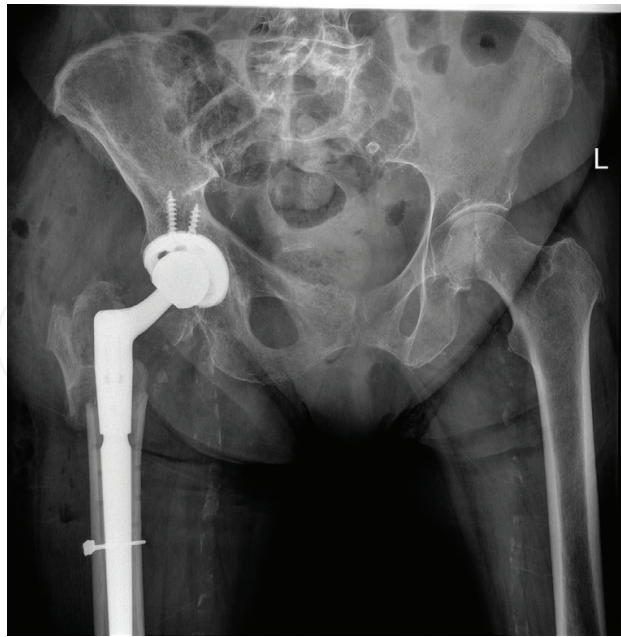


**Figure 4.** Demonstrating subsequent revision to hybrid THR following failed internal fixation.



**Figure 5.** AP radiograph demonstrating screw cut out of post ORIF of neck of femur fracture.

Preoperative templating, paying particular attention to the length of the proposed femoral component is essential to bypass bone defects or screw tracks. An attempt should be made to recreate the patients' normal anatomy; it is essential to restore offset, length, and centre of rotation. If acetabular bone loss is noted as autogenous bone graft, allograft or a fixation device may be necessary to reconstruct or span a marginal, cavitary, or combined defect.



**Figure 6.** Demonstrating subsequent revision to a modular prosthesis.

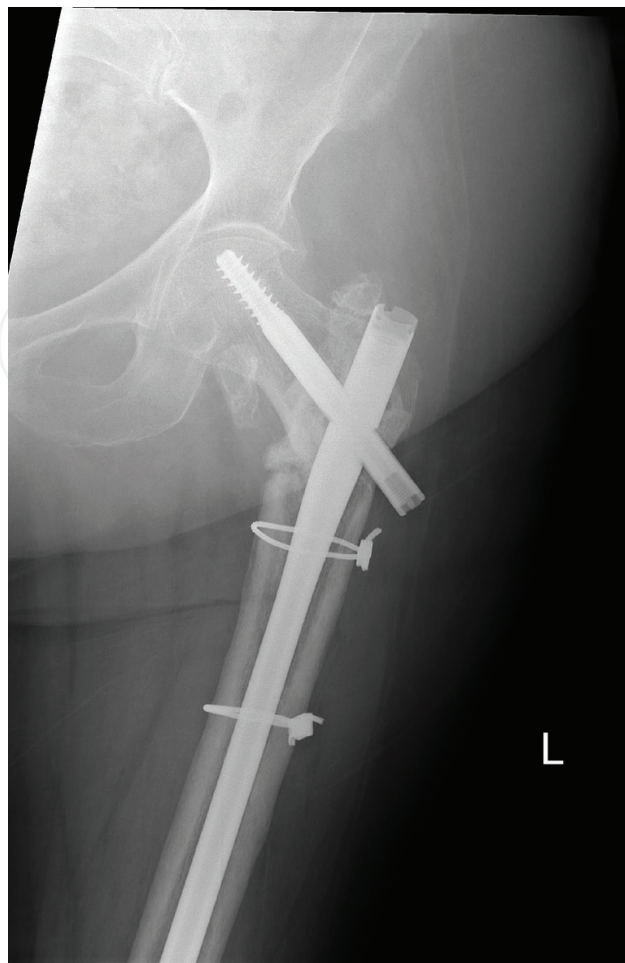
During the preparation of the femur, it is recommended to leave the internal fixation device in situ and to avoid excessive traction and leg rotation until dislocation to minimise the risk of intraoperative fracture. Cemented or uncemented components can be used depending on user preference and in conjunction with intraoperative evaluation of acetabular and femoral bone quality.

In such cases the acetabulum may not be degenerative and thus less sclerotic than usually encountered in elective arthroplasty. Reaming therefore should be performed with caution, being mindful of the risk of medial wall penetration. In performing a THR in a cognitively impaired patient, an extended stability or constrained liner and a larger diameter bearing should be considered.

## 5. THR for failed intertrochanteric fracture fixation

Patients with failed internal fixation of intertrochanteric fractures present with significant functional disability and pain. In these patients revision of the fixation device will often be considered as a first option, but these surgeries are often complicated by bone loss and the presence of avascular bone at the nonunion site. Hip arthroplasty offers a good salvage option for selected patients as it obviates the need for fracture healing and establishes immediate skeletal continuity allowing early, progressive weight bearing. **Figure 7** shows a nonunion of a subtrochanteric femur fracture following cephalomedullary fixation which was successfully revised to a modular THR as seen in **Figure 8**.

Technical issues such as difficulty of implant removal, bone loss, trochanteric nonunion, anticipated haemorrhage and suboptimal bone quality must be considered. A common mode of

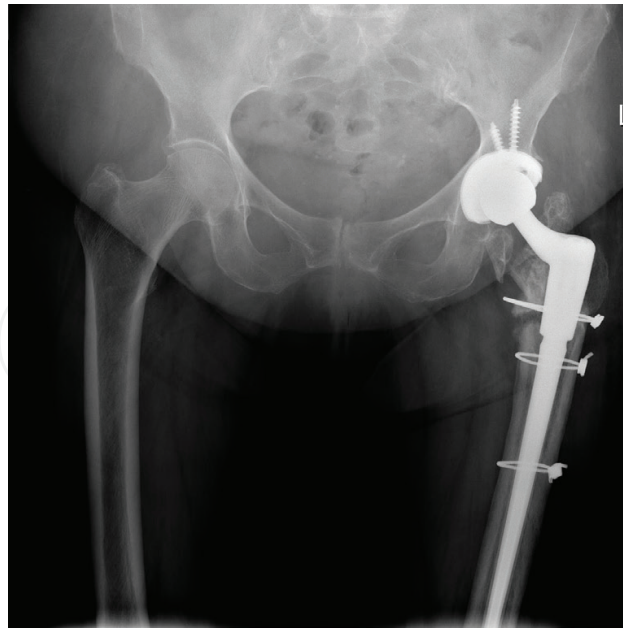


**Figure 7.** AP radiograph demonstrating non union of a subtrochanteric femur fracture following cephalomedullary fixation.

failure in intertrochanteric fractures is cut-out of the lag screw which consequently damages the acetabular cartilage and often necessitates acetabular replacement during the conversion arthroplasty.

It is imperative that the surgeon eliminates infection as a cause of failure and preoperative evaluation should include measurements of CRP and ESR levels and aspiration or biopsy if inflammatory marker levels are concerning. If infection is demonstrated, a two-stage procedure should be performed with the removal of components and the femoral head during the first stage, with the use of an antibiotic-impregnated cement prosthesis.

During revision of a failed intertrochanteric fracture, it is again advisable to leave the fixation in place until surgical dislocation of the hip is performed. Access is often determined by trochanteric anatomy: gained either between ununited fragments or with mobilisation of mal-united fragments. If some continuity is maintained with the fibres of vastus lateralis, the exposure resembles a trochanteric slide. In these cases, the risk of mechanical complications such as fractures and cortical perforations is increased due to reduced bone quality, loss of bone stock, presence of screw holes from previous fixation devices, and distorted bony landmarks. If trochanteric nonunion is encountered, fibrous tissue is debrided from the cancellous surface



**Figure 8.** Demonstrating subsequent revision to a modular prosthesis.

of the fragments, and a high-speed burr can be used to expose bleeding cancellous bone. The excised femoral head is often a useful source of autograft, and applying an acetabular reamer to the femoral head will rapidly morselise the fragment. Patients with cephalomedullary nails in situ may exhibit neocortex formation and sclerosis around the nail, and broaching the canal in these cases can be facilitated by using a high-speed burr. Calcar replacing and fully coated stems may be considered in those with loss of proximal bone. Modular implants may also play a role in the setting of severe proximal bone loss. Reattachment of the trochanter in cases of nonunion is a crucial step towards regaining stability, and trochanteric cable plates are particularly useful in many of these cases.

Lee et al. recommended the use of total hip arthroplasty for failed internal fixation of intertrochanteric fractures. They report a 3% 1 year mortality rate in the conversion group. At 3 years of follow-up, there was no significant difference in clinical scores or component loosening when compared to a matched cohort who received hemiarthroplasties [40].

## **6. THR for pathological or impending fracture**

Of patients with advanced cancer, 50% develop bony metastases, and 30% of metastatic deposits occur within the proximal femur. Due to the high mechanical forces directed through the hip, surgery is often required for pain palliation, to restore function and to allow immediate unrestricted weight bearing. Current treatment options include intramedullary nailing, osteosynthesis with a plate-screw construct and endoprosthetic replacements—taking the form of hemiarthroplasties, total hip arthroplasties, and proximal femoral replacements.

For patients expected to live greater than 6 months, the literature supports curettage of the lesion with cemented hemiarthroplasty [41–43]. Those patients demonstrating a



radioresistant tumour may necessitate en bloc excision and proximal femoral replacement [44]. Intramedullary fixation should be utilised in those with a life expectancy less than 6 months as it has been demonstrated to provide reliable fracture fixation up to 12 months post-procedure [45, 46]. The use of a hemiarthroplasty to treat pathologic or impending pathologic fractures of the proximal femur has an acceptable rate of complications, reoperations, and functional outcomes as demonstrated by Houdek et al., who studied 199 patients treated with a hemiarthroplasty for metastatic femoral neck disease. They demonstrated a 1% conversion rate to THR due to degenerative changes and groin pain. [47].

With advances in medical management of metastatic disease and concomitant increase in patient's life expectancy, the durability of these implants has become increasingly important. Due to the poor survival rates in this cohort of patients, it has been difficult to compare implant survival rates for patients with metastatic disease with those utilised in primary joint replacement. However, in series comparing THR with osteosynthesis in the setting of pathologic fracture, THR has demonstrated a lower rate of mechanical failure as well as a higher rate of implant survival [48].

## 7. Conclusion

In conclusion, in the setting of the neck of femur fracture, a cemented hemiarthroplasty is an appropriate treatment for elderly patients. However, studies have suggested that patients treated with THR experience improved functional outcomes but at the expense of a greater dislocation rate. The selective use of THR in cognitively intact, active patients is well supported. In the setting of failed internal fixation, an arthroplasty, while technically demanding, represents an acceptable salvage procedure for the neck of femur and intertrochanteric fractures. However, in both scenarios it is essential that infection is excluded as a precipitant of fixation failure prior to arthroplasty. In cases of pathologic fracture, arthroplasty can represent an appropriate treatment option following careful evaluation of the patient's life expectancy.

## Conflict of interest

The authors declare no conflict of interest in the preparation of this chapter. No funding was received by the authors.

## Author details

Mark Curtin<sup>1\*</sup>, Eoghan Pomeroy<sup>1</sup> and James Broderick<sup>2</sup>

\*Address all correspondence to: markcurtin10@gmail.com

1 Department of Trauma and Orthopaedics, Beaumont Hospital, Dublin, Ireland

2 Department of Trauma and Orthopaedics, Galway University Hospital, Galway, Ireland



## References

- [1] Cornwall R, Gilbert MS, Koval KJ, Strauss E, Siu AL. Functional outcomes and mortality vary among different types of hip fractures: A function of patient characteristics. *Clinical Orthopaedics and Related Research*. Aug 2004;**425**:64
- [2] Lewinnek GE, Kelsey J, WHITE III AA, Kreiger NJ. The significance and a comparative analysis of the epidemiology of hip fractures. *Clinical Orthopaedics and Related Research*. 1980;**152**:35-43
- [3] Hung WW, Egol KA, Zuckerman JD, Siu AL. Hip fracture management: Tailoring care for the older patient. *JAMA*. 2012;**307**(20):2185-2194
- [4] Haidukewych GJ, Berry DJ. Hip arthroplasty for salvage of failed treatment of intertrochanteric hip fractures. *JBJS*. 2003;**85**(5):899-904
- [5] Haidukewych GJ, Berry DJ. Salvage of failed internal fixation of intertrochanteric hip fractures. *Clinical Orthopaedics and Related Research*. 2003;**412**:184-188
- [6] Sancheti KH, Sancheti PK, Shyam AK, Patil S, Dhariwal Q, Joshi R. Primary hemiarthroplasty for unstable osteoporotic intertrochanteric fractures in the elderly: A retrospective case series. *Indian Journal of Orthopaedics*. 2010;**44**(4):428
- [7] Lindskog DM, Baumgaertner MR. Unstable intertrochanteric hip fractures in the elderly. *Journal of the American Academy of Orthopaedic Surgeons*. 2004;**12**(3):179-190
- [8] Marsh JL, Slongo TF, Agel J, Broderick JS, Creevey W, DeCoster TA, et al. Fracture and dislocation classification compendium-2007: Orthopaedic Trauma Association classification, database and outcomes committee. *Journal of Orthopaedic Trauma*. 2007;**21** (10 Suppl):S1-S133
- [9] Larsson S. Treatment of osteoporotic fractures. *Scandinavian Journal of Surgery*. 2002;**91**:140-146
- [10] Bannister GC, Gibson AGF, Ackroyd CE, Newman JH. The fixation and prognosis of trochanteric fractures: A randomised prospective controlled trial. *Clinical Orthopaedics and Related Research*. 1990;**254**:242-246
- [11] Chinoy MA, Parker MJ. Fixed nail plates versus sliding hip systems for the treatment of trochanteric femoral fractures: A meta analysis of 14 studies. *Injury*. 1999;**30**(3):157-163
- [12] Flores LA, Harrington IJ, Heller M. The stability of intertrochanteric fractures treated with a sliding screw-plate. *Bone & Joint Journal*. 1990;**72**(1):37-40
- [13] Sernbo I, Fredin H. Changing methods of hip fracture osteosynthesis in Sweden: An epidemiological enquiry covering 46,900 cases. *Acta Orthopaedica Scandinavica*. 1993;**64**(2):173-174
- [14] Larsson S, Friberg S, Hansson LI. Trochanteric fractures mobility, complications, and mortality in 607 cases treated with the sliding-screw technique. *Clinical Orthopaedics and Related Research*. 1990;**260**:232-241

- [15] Bess RJ, Jolly SA. Comparison of compression hip screw and gamma nail for treatment of peritrochanteric fractures. *Journal of the Southern Orthopaedic Association*. 1997;**6**(3):173-179
- [16] Halder SC. The gamma nail for peritrochanteric fractures. *Bone & Joint Journal*. 1992;**74**(3):340-344
- [17] Davis TR, Sher JL, Horsman A, Simpson M, Porter BB, Checketts RG. Intertrochanteric femoral fractures. Mechanical failure after internal fixation. *Bone & Joint Journal*. 1990;**72**(1):26-31
- [18] Thomas AP. Dynamic hip screws that fail. *Injury*. 1991;**22**(1):45-46
- [19] Kyle RF, Gustilo RB, Premer RF. Analysis of six hundred and twenty-two intertrochanteric hip fractures. *Orthopaedic Trauma Directions*. 2010;**8**(06):25-29
- [20] Watson JT, Moed BR, Cramer KE, Karges DE. Comparison of the compression hip screw with the Medoff sliding plate for intertrochanteric fractures. *Clinical Orthopaedics and Related Research*. 1998;**348**:79-86
- [21] Michael RC. Prospective randomised controlled trial of an intramedullary nail versus dynamic screw and plate for intertrochanteric fractures of the femur. *Journal of Orthopaedic Trauma*. 2001;**15**(6):394-400
- [22] Simmermacher RKJ, Bosch AM, Van der Werken CHR. The AO/ASIF-proximal femoral nail (PFN): A new device for the treatment of unstable proximal femoral fractures. *Injury*. 1999;**30**(5):327-332
- [23] Bhandari M, Devereaux PJ, Swiontkowski MF, Tornetta P III, Obrebsky W, Koval KJ, et al. Internal fixation compared with arthroplasty for displaced fractures of the femoral neck: A meta-analysis. *JBJS*. 2003;**85**(9):1673-1681
- [24] Parker MJ, Khan RJK, Crawford J, Pryor GA. Hemiarthroplasty versus internal fixation for displaced intracapsular hip fractures in the elderly. *Bone & Joint Journal*. 2002;**84**(8):1150-1155
- [25] Poolman RW, Struijs PA, Krips R, Sierevelt IN, Lutz KH, Bhandari M. Does a "Level I Evidence" rating imply high quality of reporting in orthopaedic randomised controlled trials? *BMC Medical Research Methodology*. 2006;**6**(1):44
- [26] Bhandari M, Devereaux PJ, Einhorn TA, Thabane L, Schemitsch EH, Koval KJ, et al. Hip fracture evaluation with alternatives of total hip arthroplasty versus hemiarthroplasty (HEALTH): Protocol for a multicentre randomised trial. *BMJ Open*. 2015;**5**(2):e006263
- [27] Grosso MJ, Danoff JR, Murtaugh TS, Trofa DP, Sawires AN, Macaulay WB. Hemiarthroplasty for displaced femoral neck fractures in the elderly has a low conversion rate. *The Journal of Arthroplasty*. 2017;**32**(1):150-154
- [28] Hopley C, Stengel D, Ekkernkamp A, Wich M. Primary total hip arthroplasty versus hemiarthroplasty for displaced intracapsular hip fractures in older patients: Systematic review. *BMJ*. 2010;**340**:c2332

- [29] White SM, Moppett IK, Griffiths R, Johansen A, Wakeman R, Boulton C, et al. Secondary analysis of outcomes after 11,085 hip fracture operations from the prospective UK Anaesthesia Sprint Audit of Practice (ASAP-2). *Anaesthesia*. 2016;**71**(5):506-514
- [30] Su EP, Su SL. Femoral neck fractures. *The Bone & Joint Journal*. 2014;**96**(11 Supple A): 43-47
- [31] Zi-Sheng A, You-Shui G, Zhi-Zhen J, Ting Y, Chang-Qing Z. Hemiarthroplasty vs. primary total hip arthroplasty for displaced fractures of the femoral neck in the elderly: A meta-analysis. *The Journal of Arthroplasty*. 2012;**27**(4):583-590
- [32] Gao H, Liu Z, Xing D, Gong M. Which is the best alternative for displaced femoral neck fractures in the elderly?: A meta-analysis. *Clinical Orthopaedics and Related Research*. 2012;**470**(6):1782-1791
- [33] Perry DC, Metcalfe D, Griffin XL, Costa ML Inequalities in use of total hip arthroplasty for hip fracture: Population based study. *Bmj*. 2016;**353**:i2021
- [34] Anakwe RE, Middleton SD, Jenkins PJ, Butler AP, Aitken SA, Keating JF, et al. Total hip replacement in patients with hip fracture: A matched cohort study. *Journal of Trauma and Acute Care Surgery*. 2012;**73**(3):738-742
- [35] Ossendorf C, Scheyerer MJ, Wanner GA, Simmen HP, Werner CM. Treatment of femoral neck fractures in elderly patients over 60 years of age-which is the ideal modality of primary joint replacement? *Patient Safety in Surgery*. 2010;**4**(1):16
- [36] Maceroli MA, Nikkel LE, Mahmood B, Elfar JC. Operative mortality after arthroplasty for femoral neck fracture and hospital volume. *Geriatric Orthopaedic Surgery & Rehabilitation*. 2015;**6**(4):239-245
- [37] Uhler LM, Schultz WR, Hill AD, Koenig KM. Health utility of early hemiarthroplasty vs. delayed total hip arthroplasty for displaced femoral neck fracture in elderly patients: A Markov model. *The Journal of Arthroplasty*. 2017;**32**(5):1434-1438
- [38] Nikolopoulos KE, Papadakis SA, Kateros KT, Themistocleous GS, Vlamis JA, Papagelopoulos PJ, et al. Long-term outcome of patients with avascular necrosis, after internal fixation of femoral neck fractures. *Injury*. 2003;**34**(7):525-528
- [39] Tidermark J, Zethraeus N, Svensson O, Törnkvist H, Ponzer S. Quality of life related to fracture displacement among elderly patients with femoral neck fractures treated with internal fixation. *Journal of Orthopaedic Trauma*. 2002;**16**(1):34-38
- [40] Lee YK, Kim JT, Alkitaini AA, Kim KC, Ha YC, Koo KH. Conversion hip arthroplasty in failed fixation of intertrochanteric fracture: A propensity score matching study. *The Journal of Arthroplasty*. 2017;**32**(5):1593-1598
- [41] Wedin R, Bauer HC. Surgical treatment of skeletal metastatic lesions of the proximal femur. *Bone & Joint Journal*. 2005;**87**(12):1653-1657
- [42] Harvey N, Ahlmann ER, Allison DC, Wang L, Menendez LR. Endoprostheses last longer than intramedullary devices in proximal femur metastases. *Clinical Orthopaedics and Related Research*. 2012;**470**(3):684-691

- [43] Park DH, Jaiswal PK, Al-Hakim W, Aston WJS, Pollock RC, Skinner JA, et al. The use of massive endoprostheses for the treatment of bone metastases. *Sarcoma*. 2007;**2007**:62151
- [44] Hwang N, Nandra R, Grimer RJ, Carter SR, Tillman RM, Abudu A, et al. Massive endoprosthetic replacement for bone metastases resulting from renal cell carcinoma: Factors influencing patient survival. *European Journal of Surgical Oncology (EJSO)*. 2014;**40**(4):429-434
- [45] Moholkar K, Mohan R, Grigoris P. The Long Gamma Nail for stabilisation of existing and impending pathological fractures of the femur. An analysis of 48 cases. *Acta Orthopaedica Belgica*. 2004;**70**(5):429-434
- [46] Piccioli A, Rossi B, Scaramuzzo L, Spinelli MS, Yang Z, Maccauro G. Intramedullary nailing for treatment of pathologic femoral fractures due to metastases. *Injury*. 2014;**45**(2):412-417
- [47] Houdek MT, Wyles CC, Labott JR, Rose PS, Taunton MJ, Sim FH. Durability of Hemiarthroplasty for Pathologic Proximal Femur Fractures. *The Journal of Arthroplasty*. 2017;**32**(12):3607-3610
- [48] Harvey N, Ahlmann ER, Allison DC, Wang L, Menendez LR. Endoprostheses last longer than intramedullary devices in proximal femur metastases. *Clinical Orthopaedics and Related Research*. 2012;**470**(3):684-691