

We are IntechOpen, the world's leading publisher of Open Access books Built by scientists, for scientists

6,900

Open access books available

186,000

International authors and editors

200M

Downloads

Our authors are among the

154

Countries delivered to

TOP 1%

most cited scientists

12.2%

Contributors from top 500 universities



WEB OF SCIENCE™

Selection of our books indexed in the Book Citation Index
in Web of Science™ Core Collection (BKCI)

Interested in publishing with us?
Contact book.department@intechopen.com

Numbers displayed above are based on latest data collected.
For more information visit www.intechopen.com



Plasmapheresis in Treatment of Myasthenia Gravis

Valerii Voinov

Abstract

Treatment of myasthenia gravis is still a rather difficult task, since there is no single tactic to use different drugs (corticosteroids, rituximab, immunoglobulins), especially since it is associated with a number of side effects. They are not able to remove the accumulating autoantibodies and immune complexes, the large size of which does not allow them to be excreted by the kidneys as well. Special problems of treatment arise when myasthenic crises develop associated with respiratory failure requiring artificial lungs ventilation. Plasmapheresis can help to solve this for it is possible to remove antibodies and other pathological metabolites. In addition, regular plasmapheresis is able not only to prevent exacerbations but also to reduce doses of the maintenance therapy with less risk of their side effects, which is confirmed by our own experience.

Keywords: myasthenia gravis, autoimmunity, autoantibodies, drug therapy, plasmapheresis

1. Introduction

Myasthenia gravis (MG) is a relatively rare disease, affecting about 140 people per million [1, 2]; however, its frequency has been increasing in the recent years, especially in the elderly population with mortality rate of 0.27/100,000 people, and in intensive care units, mortality of such patients reaches 5.3% [3, 4]. However, MG also affects children, manifesting in three forms: transient neonatal myasthenia, congenital myasthenic syndrome, and juvenile MG [5]. In the latter case, the disease onset can be from 11 months to 17 years [6]. Although the disease has been known for decades, a single tactic of its treatment has not yet been developed. In many respects, it depends on the variety of forms and their etiopathogenetic features. In particular, the main focus is on the use of drug therapy, and too little attention is paid to plasmapheresis. Therefore, the main objective of this study is to justify the need for plasmapheresis in the treatment of MG.

2. Etiology and pathogenesis

MG is a long-term neuromuscular disease that leads to various degrees of the skeletal muscles weakness. The most commonly affected muscles are those of the eyes, face, and swallowing [7]. In this case, IgG antibodies appear to nicotine

acetylcholine (ACh) receptors of the postsynaptic membrane, which leads to the muscle weakness increase [8]. In some cases, antibodies can also emerge to the muscle-specific kinase (MuSK) [9]. In this case, antibodies against MuSK can produce plasmoblasts, and in such cases, removal of B-lymphocytes does not exclude recurrence of MG [10]. It also does not exclude autoantibodies presence to other postsynaptic proteins (anti-titin, anti-integrin antibodies) in small amounts [11–13].

3. Drug therapy

3.1 Cholinesterase inhibitors

Cholinesterase inhibitors (pyridostigmine bromide) delay the disease progression and increase the availability of ACh on the motor end membranes and lead to their strength increase [14]. Cholinergic side effects, including hyperactivation of the smooth muscles of the urinary bladder and intestines causing diarrhea, abdominal cramps, increased salivation, sweating, and bradycardia, are dose limiting and lead to noncompliance to the treatment plan [15].

3.2 Corticosteroids

The most common tactic for MG treatment is based on corticosteroids therapy [16]. However, such therapy is not deprived of a large number of adverse reactions. They lead to *Cushingoid syndrome*. Glucocorticoids, in particular, are *diabetogenic* hormones for they suppress glucose consumption by the tissues, and its production by the liver becomes increased. Besides, they can also directly suppress the release of insulin, thus showing that β -cells of pancreatic islets are one of their targets. Other complication of long glucocorticoid therapy is *osteoporosis*. It is considered that these hormones inhibit proliferation and differentiation of osteoblasts and stimulate their apoptosis. There is also an indirect mechanism of bones resorption caused by secondary hyperparathyreosis due to intestinal calcium adsorption decrease. Glucocorticoids effect on hypothalamus and gonads causes *hypogonadism* [17]. Development of chronic inflammatory polyneuropathy is also described [18]. There are evidences about correlation between such intensive and prolonged immunosuppressive therapy and the onset of tumors [19, 20].

3.3 Immunoglobulins

Administration of large doses of immunoglobulins does lead to such serious complications as aseptic meningitis, hemolytic anemia, cardiac rhythm disorders, and neurologic frustration in children with thrombotic thrombocytopenic purpura. Arthritis, thromboembolic complications, vasculitis, and a systemic lupus erythematosus are the side effects of autoantibodies and circulating immune complexes. Besides, there are other complications such as lethal hypersensitive (allergic) myocarditis and refractory heart failure, rash and skin itch, a leucopenia, a neutropenia, fever, etc. [21–24]. Presence of immune complexes may be the cause of it [25]; however, the main cause that must be recognized is the technology of immunoglobulins preparation from thousands (!) of donors having different blood types with full set of anti-A and anti-B isohemagglutinins (α and β), which lead to destruction of the corresponding erythrocytes [26]. At the same time, plasma exchange was necessary to relieve such hemolytic complication [27].

3.4 Rituximab

In the recent years, treatment of autoimmune diseases with rituximab—chimeric monoclonal antibody to CD20 antigen of B-lymphocytes—has become rather widespread, which should reduce the production of autoantibodies [28]. Rituximab is believed to be the first choice therapy [7]. Nevertheless, there are also complications of such treatment described leading even to *fulminant hepatitis* and *multiple organ failure* development [28–30]. Rituximab, cetuximab, and panitumumab have direct nephrotoxic effect [31]. *Rituximab* and *alemtuzumab* are reported to cause interstitial pneumonia development [32]. Prospectively, after rituximab treatment, neutropenia with pneumonia and other infectious complications may develop in up to 17% [33, 34]. There are reports about development of male infertility due to either gonadal dysfunction or antisperm autoantibodies production [35]. In addition, as noted above, removal of B-cells is not always accompanied by decrease in the autoantibodies reproduction [10].

4. Plasmapheresis

Considering the disease autoimmune nature, direct removal of antibodies by plasmapheresis is more effective [9, 36–38]. It causes normalization of immunoglobulin levels and reduction of the circulating immune complexes (CICs) in 1.7–2 times. The overall subjective improvement is observed in 94% of patients after a primary set of five plasma exchange procedures with their addition if necessary [39]. In severe cases, patients can be quickly disconnected from the artificial lung ventilation, but it is a relatively short-term effect and requires repeated sets of procedures [40].

Nevertheless, along with plasmapheresis, the same results are obtained by intensive intravenous immunoglobulin administration at a dose of 0.4 g/kg daily for 3 or 5 days [41, 42]. Though, using intensive plasmapheresis, we can achieve better results in the treatment of myasthenic crises, rather than by intravenous administration of immunoglobulins, the course of which costs \$78.814 [43–47]. Immunoabsorption methods are also used; however, the best results are achieved in combination with plasma exchange [16].

It is advisable to carry out three to five procedures of plasmapheresis with removal of plasma up to 2.0–2.5 ml/kg of the body weight [48]. It is also possible to carry out daily procedures of plasma exchange removing smaller amounts of plasma, instead of the abovementioned plasma exchange, being carried out every other day [49]. Similarly, plasma exchange provides faster positive effect (already after the first procedure) in patients resistant to rituximab [50]. Nevertheless, carrying out plasma exchange along with rituximab treatment appeared more effective [51].

Plasmapheresis before thymectomy greatly facilitates the postoperative period [52–55]. Moreover, in cases when thymoma recurs postoperatively after a course of a plasma exchange, its involution is observed [56].

In juvenile forms of MG, plasmapheresis with immunoglobulins appears successful [57, 58], and it was noted that *plasma exchange yields more stable results* than IVIG therapy [44].

It should be noted that in the earliest symptoms of MG such as weakness of the cervical paraspinal muscles (*dropped head syndrome*), plasma exchange and immunoabsorption are justified [59].

The use of specific IgG-immunoabsorption to remove antibodies to ACh receptors [60] seems prospective as well as new systems for cascade plasmapheresis [53, 61].

At a cascade plasma exchange, the level of soluble molecules of intercellular adhesion decreases more effectively and the quantity of the T-regulating cells increases [62]. After a cascade plasma exchange, they observe increase in the SatO₂ levels associated with decrease in pCO₂ [63].

Nevertheless, in the comparable groups of patients with MG, there were no significant differences noted in the effectiveness of immunoadsorption or cascade plasmapheresis [64, 65]. On the other hand, there were no benefits found of immunoglobulin transfusions before cascade plasmapheresis or immunoadsorption [66]. After a cascade plasma exchange, they also noted a decrease in cytotoxic activity of the natural killer cells that even more improves the effectiveness of such treatment [67].

MG development is also possible in infants due to “graft-versus-host” disease (GVHD) following bone marrow transplantation. The course of plasmapheresis with subsequent administration of immunoglobulins was quite effective [68].

Our own experience shows that there are two possible applications of plasmapheresis. In myasthenic crises accompanied by swallowing and breathing disorders when patients need artificial lung ventilation, it is really necessary to urgently conduct a massive plasma exchange, removing 1–1.5 of the total plasma volume (TPV) with compensation with albumin and fresh frozen donor plasma for four to five procedures every day or every other day [69, 70]. The same tactic is described in the American Society for Apheresis Guidelines on the Use of Therapeutic Apheresis in Clinical Practice [71].

Then, to achieve a more stable remission, it is necessary to repeat procedures of less massive plasmapheresis at intervals of 2–4 weeks, removing only 0.3–0.5 TPV. The same tactic is used in less severe degrees of the disease, when the removed plasma volume can be compensated only by crystalloid solutions. In this case, the primary course also consists of four such plasmapheresis procedures, followed by one procedure every 1–2 months. Given the fact that MG can be observed in young children up to the development of myasthenic crises, it is desirable to use equipment with a small volume of filling. In our practice, we use a device for membrane plasmapheresis called “Hemophenix” (“Trackpore Technology,” Russia) with an internal filling volume up to 70 ml, which can be used even in unstable hemodynamics, including in children. The advantage is a single-needle access using any peripheral vein.

Our practice includes 15 patients with MG. Two of them were in acute stage of the myasthenic crisis with respiratory failure, requiring connection to artificial lungs ventilation. One of them was a girl of 8 years old, who had complication of GVHD on the background of lymphocytic leukemia. She had already been on artificial lung ventilation for 10 days without visible effect (**Figure 1**). After two procedures of plasma exchange in a volume of 1.2 TPV, she was already able to breathe herself. In total, five such procedures were performed with a good effect of restoring the motor activity except for some left eyelid ptosis, which persisted after a month (**Figure 2**). The second patient had been on the artificial lung ventilation for 2 weeks in one of the clinics in Sofia, Bulgaria (**Figure 3**). Also, after two plasma exchange procedures, it was possible to switch him off the artificial lung ventilation (**Figure 4**), and after the last fourth procedure, he was already able to move without assistance and was discharged from the clinic.

The other patients were in different degrees of MG severity, and they performed a conventional plasmapheresis in the volume of 0.3–0.5 TPV with replacement of the removed plasma with an isotonic solution of sodium chloride. The course of treatment consisted of four such procedures, conducted every other day. Most of the procedures were performed in outpatient settings. The main task was to stabilize the condition and prevent the disease recurrence. One of them was in

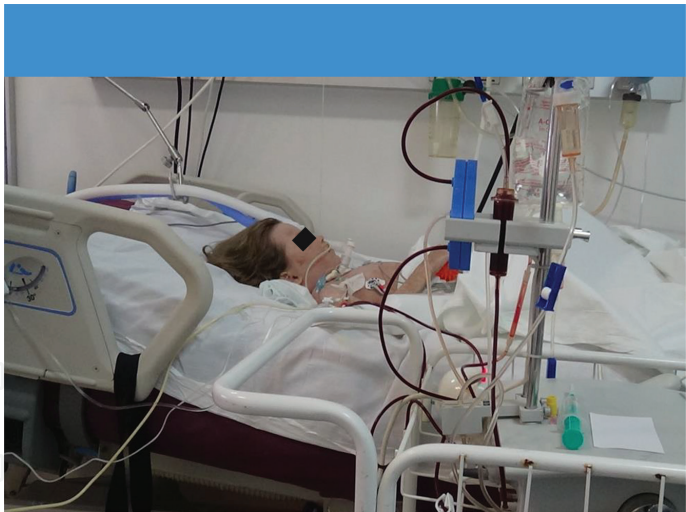


Figure 1.
Girl M of 8 years old and 18 kg body weight. Myasthenic crisis with artificial ventilation for 10 days. Plasma exchange using the “Hemophenix” device.

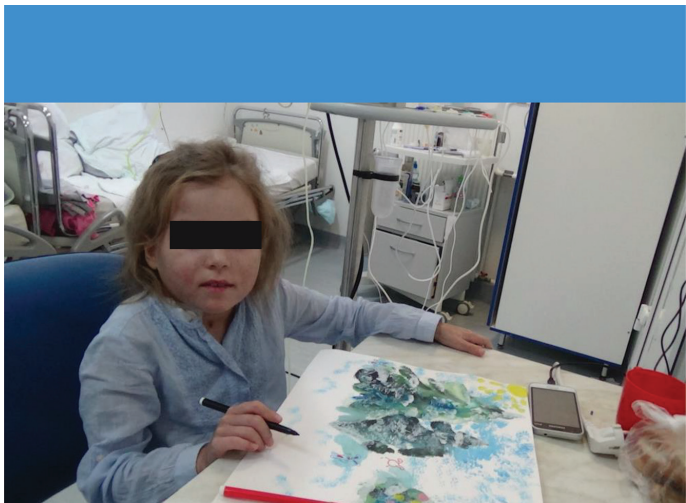

Figure 2.
The same girl a month after the course of plasma exchange.

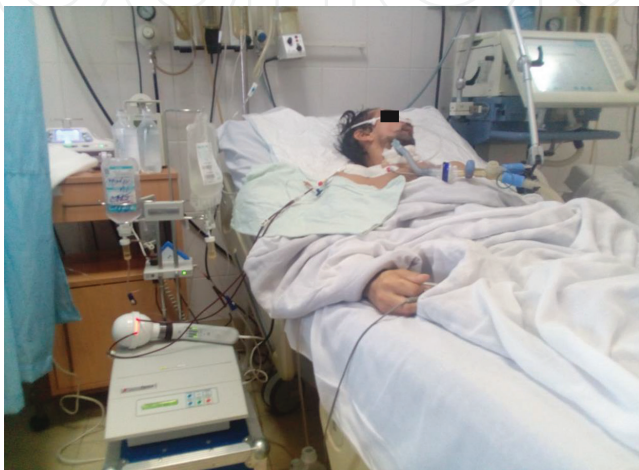

Figure 3.
Patient T of 28 years old. The first session of plasma exchange on the device “Hemophenix” on the background of artificial lung ventilation, carried out for 2 weeks.

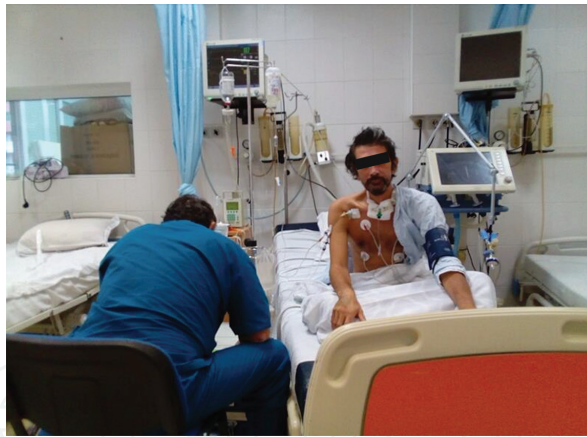

Figure 4.
The same patient after two sessions of plasma exchange. Disconnected from the ventilator.

quite serious condition and was able to move only with someone's assistance. After the primary course of plasmapheresis, we followed the tactics of a “programmed” plasmapheresis once per month, which enabled him to return to his physical work of an auto mechanic. The follow-up period is 6 years.

5. Conclusion

The autoimmune nature of the disease undoubtedly is an indication for plasmapheresis since it is the only way to remove large-molecule pathological products (autoantibodies, immune complexes) that cannot be excreted by the kidneys. Our experience shows that after such courses of plasmapheresis, conducted twice a year, it is possible to practically reduce the doses of corticosteroids and other medicines by half and, thereby, avoid the toxic consequences of their use.

Author details

Valerii Voinov

First I.P. Pavlov State Medical University of Saint Petersburg, Russia

*Address all correspondence to: voinof@mail.ru

IntechOpen

© 2018 The Author(s). Licensee IntechOpen. This chapter is distributed under the terms of the Creative Commons Attribution License (<http://creativecommons.org/licenses/by/3.0>), which permits unrestricted use, distribution, and reproduction in any medium, provided the original work is properly cited. 

References

- [1] Silvestri NJ, Wolfe GI. Myasthenia gravis. *Seminars in Neurology*. 2012;**32**(3):215-226
- [2] Lin CW, Chen TC, Jou JR, Woung LC. Update on ocular myasthenia gravis in Taiwan. *Taiwan Journal of Ophthalmology*. 2018;**8**(2):67-73
- [3] Al-Bassam W, Kubicki M, Bailey M, et al. Characteristics, incidence, and outcome of patients admitted to the intensive care unit with myasthenia gravis. *Journal of Critical Care*. 2018;**45**:90-94
- [4] Martinka I, Fulova M, Spalekova M, Spalek P. Epidemiology of myasthenia gravis in Slovakia in the years 1977-2015. *Neuroepidemiology*. 2018;**50**(3-4):153-159
- [5] Peragallo JH. Pediatric myasthenia gravis. *Seminars in Pediatric Neurology*. 2017;**24**(2):116-121
- [6] Castro D, Derisavifard S, Anderson M, et al. Juvenile myasthenia gravis: A twenty-year experience. *Journal of Clinical Neuromuscular Disease*. 2013;**14**(3):95-102
- [7] Stetefeld HR, Schroeter M. Myasthenic crisis. *Fortschritte der Neurologie-Psychiatrie*. 2018;**86**(5):301-307(article in German)
- [8] Nakamura R, Makino T, Hanada T, et al. Heterogeneity of auto-antibodies against nAChR in myasthenic serum and their pathogenic roles in experimental autoimmune myasthenia gravis. *Journal of Neuroimmunology*. 2018;**320**:64-75
- [9] Yamada C, Teener JW, Robertson D, et al. Maintenance plasmapheresis treatment for muscle specific kinase antibody positive myasthenia gravis patients. *Journal of Clinical Apheresis*. 2014;**29**(1):37-38
- [10] Stathopoulos P, Kumar A, Heiden JAV, et al. Mechanisms underlying B cell immune dysregulation and autoantibody production in MuSK myasthenia gravis. *Annals of the New York Academy of Sciences*. 2018;**1412**(1):154-165
- [11] Misra MK, Damotte V, Hollenbach JA. The immunogenetics of neurological disease. *Immunology*. 2018;**153**(4):399-414
- [12] Ruff RL, Lisak RP. Nature and action of antibodies in myasthenia gravis. *Neurologic Clinics*. 2018;**36**(2):275-291
- [13] Yi JS, Guptil JT, Stathopoulos P, et al. B cells in the pathophysiology of myasthenia gravis. *Muscle & Nerve*. 2018;**57**(2):172-184
- [14] Farrugia ME, Ckeary M, Carmichael C. A retrospective study of acetylcholine receptor antibody positive ocular myasthenia in the west of Scotland. *Journal of the Neurological Sciences*. 2017;**382**:84-86
- [15] Petrov KA, Kharlamova AD, Lenina OA, et al. Specific inhibition of acetylcholinesterase as an approach to decrease muscarinic side effects during myasthenia gravis treatment. *Scientific Reports*. 2018;**8**(1):304
- [16] Schneider-Gold C, Krenzer M, Klinker E, et al. Immunoabsorption versus plasma exchange versus combination for treatment of myasthenic deterioration. *Therapeutic Advances in Neurological Disorders*. 2016;**9**(4):297-303
- [17] Compston JE. Management of bone disease in patients on long term glucocorticoid therapy. *Gut*. 1999;**44**(6):770-772
- [18] Chroni E, Veltsista D, Gavanozi E, et al. Pure sensory chronic

inflammatory polyneuropathy: Rapid deterioration after steroid treatment. *BMC Neurology*. 2015;**15**:27

[19] Pasquet F, Pavic M, Ninet J, Hot A. Autoimmune diseases and cancers. Part I: Cancers complicating autoimmune diseases and their treatment. *Rev Med Interne (French)*. 2014;**35**(5):310-316

[20] Giat E, Ehrenfeld M, Shoenfeld Y. Cancer and autoimmune diseases. *Autoimmunity Reviews*. 2017;**16**(10):1049-1057

[21] Lorenzana A, Armin S, Sharma A, et al. Cerebral infarctions after intravenous immunoglobulin therapy for ITR in child. *Pediatric Neurology*. 2014;**50**(2):188-191

[22] Bharath V, Eckert K, Kang M, et al. Incidence and natural history of intravenous immunoglobulin-induced aseptic meningitis: A retrospective review at a single tertiary care center. *Transfusion*. 2015;**55**(11):2597-2605

[23] Charhon N, Bonnet A, Schmitt Z, Charpiat B. A case of circulatory collapse during intravenous immunoglobulin therapy: A manageable adverse effect! *Anaesthesia Critical Care & Pain Medicine*. 2015;**34**(2):113-114

[24] Thornby KA, Henneman A, Brown DA. Evidence-based strategies to reduce intravenous immunoglobulin-induced headaches. *The Annals of Pharmacotherapy*. 2015;**49**(6):715-726

[25] Zimring JC. Do immune complexes play a role in hemolytic sequelae of intravenous immune globulin? *Transfusion*. 2015;**55**(Suppl. 2):S86-S89

[26] Branch DR. Anti-A and anti-B: What are they and where do they come from? *Transfusion*. 2015;**55**(Suppl. 2):S74-S79

[27] Welsh KJ, Bai Y. Therapeutic plasma exchange as a therapeutic modality for

the treatment of IVIG complications. *Journal of Clinical Apheresis*. 2015;**30**(6):371-374

[28] Ruch J, McMahon B, Ramsey G, Kwaan HC. Catastrophic multiple organ ischemia due to an anti-Pr cold agglutinin developing in a patient with mixed cryoglobulinemia after treatment with rituximab. *American Journal of Hematology*. 2009;**84**(2):120-122

[29] Sagnelli E, Pisaturo M, Sagnelli C, Coppola N. Rituximab-based treatment, HCV replication, and hepatic flares. *Clinical & Developmental Immunology*. 2012;**2012**:945950

[30] Yazici O, Sendur MA, Aksoy S. Hepatitis C virus reactivation in cancer patients in the era of targeted therapies. *World Journal of Gastroenterology*. 2014;**20**(22):6716-6724

[31] Abbas A, Mitza MM, Ganti AK, Tendulkar K. Renal toxicities of targeted therapies. *Targeted Oncology*. 2015;**10**(4):487-499

[32] Barber NA, Ganti AK. Pulmonary toxicities from targeted therapies: A review. *Targeted Oncology*. 2011;**6**(4):235-243

[33] Deborska-Materkowska D, Kozińska-Przybyl O, Mikaszewska-Sokolewicz M, Durlík M. Fatal late-onset pneumocystis pneumonia after rituximab: Administration for posttransplantation recurrence of focal segmental glomerulosclerosis-case report. *Transplantation Proceedings*. 2014;**46**(8):2908-2911

[34] Lentine KL, Axelrod D, Klein C, et al. Early clinical complications after ABO-incompatible live-donor kidney transplantation: A national study of Medicare-insured recipients. *Transplantation*. 2014;**98**(1):54-65

- [35] Tiseo BC, Cocuzza M, Bonfa F, et al. Male fertility potential alteration in rheumatic diseases: A systematic review. *International Braz J Urol*. 2016;**42**(1):11-21
- [36] Dasararaju R, Man S, Marques M, Williams L. Seasonal variations in myasthenia gravis patients requiring therapeutic plasma exchange. *Journal of Clinical Apheresis*. 2014;**29**(1):36
- [37] Lánéz-Andrés JM, Gascón-Giménez F, Coret-Ferrer F, et al. Therapeutic plasma exchange: Applications in neurology. *Revista de Neurologia*. 2015;**60**(3):120-131
- [38] Gotterer L, Li Y. Maintenance immunosuppression in myasthenia gravis. *Journal of the Neurological Sciences*. 2016;**369**:294-302
- [39] Yamada C, Pham HP, Wu Y, et al. Report of the ASFA apheresis registry on muscle specific kinase antibody positive myasthenia gravis. *Journal of Clinical Apheresis*. 2016;**32**(1):5-11
- [40] Kosachev VD, Yulev NM, Bechik SL. Plasma exchange for complex treating of myasthenia. *Efferent Therapy*. 2006;**12**(2):28-31 (Rus)
- [41] Barth D, Nabavi N, Ng E, et al. Comparison of IVIg and PLEX in patients with myasthenia gravis. *Neurology*. 2011;**76**:2017-2023
- [42] Ortiz-Salas P, Velez-Van-Meerbeke A, Galvis-Gomez CA, Rodriguez QJH. Human immunoglobulin versus plasmapheresis in Guillain-Barré syndrome and myasthenia gravis: A meta-analysis. *Journal of Clinical Neuromuscular Disease*. 2016;**18**(1):1-11
- [43] Hellmann MA, Mosberg-Galili R, Lotan I, Steiner I. Maintenance IVIg therapy in myasthenia gravis does not affect disease activity. *Journal of the Neurological Sciences*. 2014;**338**:39-42
- [44] Liew WK, Powell CA, Sloan SR, et al. Comparison of plasmapheresis and intravenous immunoglobulin as maintenance therapy for juvenile myasthenia gravis. *JAMA Neurology*. 2014;**71**(5):575-580
- [45] Morgan SM, Shaz BH, Pavenski K, et al. The top clinical trial opportunities in therapeutic apheresis and neurology. *Journal of Clinical Apheresis*. 2014;**29**(6):331-335
- [46] Dhawan PS, Goodman BP, Harper CM, et al. IVIG versus PLEX in the treatment of worsening myasthenia gravis: What is the evidence?: A critically appraised topic. *The Neurologist*. 2015;**19**(5):145-148
- [47] Furlan JC, Barth D, Barnett C, Bril V. Cost-minimization analysis comparing intravenous immunoglobulin with plasma exchange in the management of patients with myasthenia gravis. *Muscle & Nerve*. 2015;**53**(6):872-876
- [48] Köhler W, Bucka C, Klingel R. A randomized and controlled study comparing immunoadsorption and plasma exchange in myasthenic crisis. *Journal of Clinical Apheresis*. 2011;**26**(6):347-355
- [49] Trikha I, Singh S, Goyal V, et al. Comparative efficacy of low dose, daily versus alternative day plasma exchange in severe myasthenia gravis: A randomized trial. *Journal of Neurology*. 2007;**254**:989-995
- [50] Nowak RJ. Response of patients with refractory myasthenia gravis to rituximab: A retrospective study. *Therapeutic Advances in Neurological Disorders*. 2011;**4**(5):259-266
- [51] Hayashi R, Tahara M, Oeda T, et al. A case of refractory generalized myasthenia gravis with anti-acetylcholine receptor antibodies

treated with rituximab. *Rinshō Shinkeigaku*. 2015;55(4):227-232 (Japan)

[52] Gold R, Schneider-Gold C. Current and future standard in treatment of myasthenia gravis. *Neurotherapeutics*. 2008;5(4):535-541

[53] Konishi T. Plasmapheresis in patients with myasthenia gravis. *Nippon Rinsho*. 2008;66(6):1165-1171 (Japan)

[54] El-Bawab H, Hajjar W, Rafay M, et al. Plasmapheresis before thymectomy in myasthenia gravis: Routine versus selective protocols. *European Journal of Cardiovascular Surgery*. 2009;35(3):392-397

[55] Yeh JH, Chen WH, Huang KM, Chiu HC. Prethymectomy plasmapheresis in myasthenia gravis. *Journal of Clinical Apheresis*. 2005;20(4):217-221

[56] Jiang W, Yu Q. Case report of thymoma tumor reduction following plasmapheresis. *Medicine (Baltimore)*. 2015;94(47):e2173

[57] Rybojad B, Lesiuk W, Fialkowska A, et al. Management of myasthenic crisis in a child. *Anaesthesiology Intensive Therapy*. 2013;45(2):82-84

[58] Krocicka S, Stasiak K, Kaciński M. Neurophysiological parameters in myasthenia gravis in children in diagnostic and therapeutic view. *Przegląd Lekarski*. 2016;73(3):119-123

[59] Tamai M, Hashimoto T, Isobe T, et al. Treatment of myasthenia gravis with dropped head: A report of 2 cases and review of the literature. *Neuromuscular Disorders*. 2015;25(5):429-431

[60] Zisimopoulou P, Lagoumintzis G, Kostelidou K, et al. Towards antigen-specific apheresis of pathogenic autoantibodies as a further step in the treatment of myasthenia

gravis by plasmapheresis. *Journal of Neuroimmunology*. 2008;15:95-103

[61] Batocchi AP, Evoli A, Di Schino C, Tonali P. Therapeutic apheresis in myasthenia gravis. *Therapeutic Apheresis*. 2000;4(4):275-279

[62] Zhang L, Liu J, Wang H, et al. Double filtration plasmapheresis benefits myasthenia gravis patients through an immunomodulatory action. *Journal of Clinical Neuroscience*. 2014;21(9):1570-1574

[63] Yeh JH, Lin CM, Cheh WH, Chiu HC. Effects of double filtration plasmapheresis on nocturnal respiratory function in myasthenic patients. *Artificial Organs*. 2013;37(12):1076-1079

[64] Yeh JH, Chiu HC. Comparison between double-filtration plasmapheresis and immunoadsorption plasmapheresis in the treatment of patients with myasthenia gravis. *Journal of Neurology*. 2000;247(7):510-513

[65] Pittayanon R, Treepraertsuk S, Phanthumchinda K. Plasmapheresis or intravenous immunoglobulin for myasthenia gravis crisis in King Chulalongkorn Memorial Hospital. *Journal of the Medical Association of Thailand*. 2009;92(4):478-482

[66] Liu JF, Wang WX, Xue J, et al. Comparing the autoantibody levels and clinical efficacy of double plasmapheresis, immunoadsorption, and intravenous immunoglobulin for the treatment of late-onset myasthenia gravis. *Therapeutic Apheresis and Dialysis*. 2010;14(2):153-160

[67] Chien PJ, Yeh JH, Chiu HC, et al. Inhibition of peripheral blood natural killer cell cytotoxicity in patients with myasthenia gravis treated with plasmapheresis. *European Journal of Neurology*. 2011;18(11):1350-1357

[68] Nakashima J, Itonaga H, Fujioka M, et al. Durable remission attained with plasmapheresis and intravenous immunoglobulin therapy in a patient with acute exacerbation of GVHD-related myasthenia gravis. *Rinshō Ketsueki*. 2018;**59**(5):480-484

[69] Voinov VA. Therapeutic Apheresis. Constanța: Celebris; 2016. 403 p (Romania)

[70] Voinov VA, Kenarov PD. The Plasmapheresis as Intensive Treatment of Neurologic Diseases. St Petersburg: RITC FSPbGMU; 2018. p. 49

[71] Schwartz J, Padmanabhan A, Aqui N, et al. Guidelines on the use of therapeutic apheresis in clinical practice—Evidence-based approach from the writing committee of the American Society for Apheresis: The sixth special issue. *Journal of Clinical Apheresis*. 2016;**28**:149-338