

We are IntechOpen, the world's leading publisher of Open Access books Built by scientists, for scientists

6,900

Open access books available

185,000

International authors and editors

200M

Downloads

Our authors are among the

154

Countries delivered to

TOP 1%

most cited scientists

12.2%

Contributors from top 500 universities



WEB OF SCIENCE™

Selection of our books indexed in the Book Citation Index
in Web of Science™ Core Collection (BKCI)

Interested in publishing with us?
Contact book.department@intechopen.com

Numbers displayed above are based on latest data collected.
For more information visit www.intechopen.com



Radio Frequency in the Treatment of Lumbar Facet Joint Arthropathy: Indications and Technical Notes

Antonios El Helou, Charbel Fawaz, Robert Adams and Dhany Charest

Abstract

Low back pain is one of the most reported symptoms in adult life. Different etiologies have been evoked. Degenerative disease of the spine is the most common cause. Facet joint arthropathy is the second leading cause of low back pain in degenerative disease. Failure of medical treatment will lead to more invasive therapeutic option. Radio frequency is a well-known therapeutic option for refractory low back pain related to facet arthropathy. We present our results analyzed retrospectively between January 2015 and March 2018. In addition, we describe our workflow, our procedure technique, and our results. According to our findings, 73% improved their VAS pain score by at least 50% over 3 months. Twenty-seven percent failed to improve with this procedure. There was a 20-point improvement on the SF-36 QOL; the overall satisfaction was high. When patients are selected carefully, radio-frequency ablation technique is a safe and efficient procedure. Its complication rate and cost are low. We recommend it as one of the therapeutic tools in the management of low back pain related to facet joint disease.

Keywords: low back pain, facet joint arthropathy, neurolysis, radio-frequency ablation, denervation

1. Introduction

Low back pain is one of the most reported symptoms in adult life [1]. Eighty percent of the population has experienced at least one episode in their life. It results in major disability for patients when it becomes chronic [2].

Different etiologies were described, but in more than 75% of cases, a nonspecific cause is evoked. Several factors were implicated: age, work, smoking, obesity, and psychological.

Pure low back pain is generally related to degenerative changes in one or more structures of the spine. The most common cause is discogenic followed by facet joint arthropathy [1, 3].

Facet joint disease is a multifactorial problem implicating mechanical and inflammatory damages, and the most common underlying etiology is arthritis [2–4].

Radio frequency is a well-known therapeutic option for refractory low back pain related to facet arthropathy [3]. It is still a very controversial procedure in terms of efficiency. Some studies showed its superiority to placebo or conservative treatment where others were not conclusive [4–6]. We consider it as a safe, minimally invasive, inexpensive procedure. It is successful in well-selected patients.

2. Anatomy of the facet joint

The spine is a complex structure in which its integrity depends on multiple anatomical elements that are functionally and structurally related to each other. The spine is a multi-articular system. Its function is to maintain axial stability. Spinal stability is based on three connected systems: the columns, the muscles, and the spinal cord with its nerve roots [7].

The columns contain mechanical receptors that send proprioceptive information on the load, motion, and postures through the spinal nerves to the central nervous system.

Facet or zygoapophysial joints are part of the columns. They are bilateral on each level and contain synovial fluid lined with hyaline cartilage. Their role is to control the direction and the amplitude of the movements in addition to share the loads. In the physiological condition, a balanced action exists between the three columns. The posterior facets support up to the third of the load depending on the posture [3, 7].

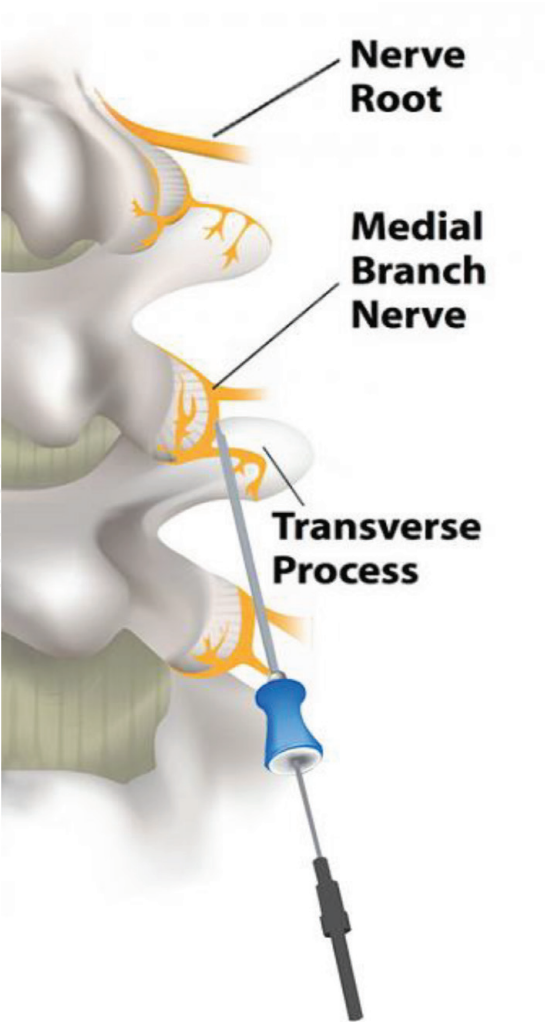


Figure 1.
Anatomy of the medial branch at the level of the facet joint with schematic representation of the needle in addition to the radio-frequency probe.

Facet joints are symmetrical which maintain the correct function in mobility. Any changes in the symmetry predispose to instability and lead to degeneration of the joint. Degenerative disease of the facet joints is accompanied by an inflammatory reaction leading to nervous irritation and low back pain.

There are two types of innervation in the lumbar spine, the somatic and the sympathetic.

The L1–L4 dorsal rami are different from the L5. They are shorter and go backward into intertransverse spaces, whereas the L5 goes over the top of all of the sacrum. L1–L4 are divided into three branches; L5 has two branches: the medial and the intermediate [8]. The medial branch at all levels is responsible for the innervation of the facet joint. It runs on the top of the transverse process toward the articular process (**Figure 1**). Each medial branch covers two levels though each articular facet joint gets its innervation from the level itself and the level above [7, 8].

3. Clinical and para-clinical evaluation

Patients suffering from low back pain are initially assessed by their family physician. The majority are referred to low back pain clinic developed in our hospital. If there is a failure of conservative medical treatment for 12 weeks in the absence of red flags, patients are referred to neurosurgical evaluation. MRI or CT scan of the lumbosacral spine is always done before their first visit, in addition to the dynamic lumbosacral spine X-rays and laboratory workup. Initial findings on MRI or CT scan of the lumbosacral spine are related to facet joint arthropathy. There is a joint space narrowing with intra-articular fluid leading to T2 hypersignal on MRI [3, 9]. Osteophyte formation at the level of the superior articular facet of the lower vertebra, ligamentum flavum with recess stenosis is frequently observed. They are evaluated clinically by a multidisciplinary team (neurosurgeon, anesthesiologist pain specialist, neuropsychologist, physiotherapist, occupational therapist) after being referred from their primary care physician.

The initial evaluation is done by a neurosurgeon. Patients answer three questionnaires before their initial consultation: the visual analog scale, the McGill pain questionnaire, and the Sf-36 quality-of-life questionnaire. Those questionnaires are evaluated before the patient is seen at the office. In the absence of red flags, we developed a workflow for the management of chronic low back pain (**Figure 2**).

Patient undergoes a complete neurological examination. Facet joint inflammation is suspected when there is an increase in pain on palpation of the joint or in hyperextension position and lateral torsion of the low back. Pain is induced by position changes from supine to sitting and from sitting to standing. In some patients, we may observe some radiating pain mainly to the hip and thigh. Without discogenic disease, straight leg rising is non-painful usually. Motor and sensory examination of the lower limbs is normal.

In the absence of any surgical condition but evident facet hypertrophy of the MRI or the CT, patients are referred for SPECT CT scan (single photon emission computed tomography) [9] and neuropsychological evaluation. SPECT CT scan usually shows an increase uptake at the level of facet joint and eliminates other inflammatory process mainly at the disc level. The mean waiting time between the initial evaluation and the follow-up is 6–8 weeks.

If the SPECT CT scan is normal or if there is a severe psychological problem, conservative treatment is considered. Otherwise, in case where the SPECT CT confirms the presence of facet arthropathy (**Figure 3**), patients are referred for facet

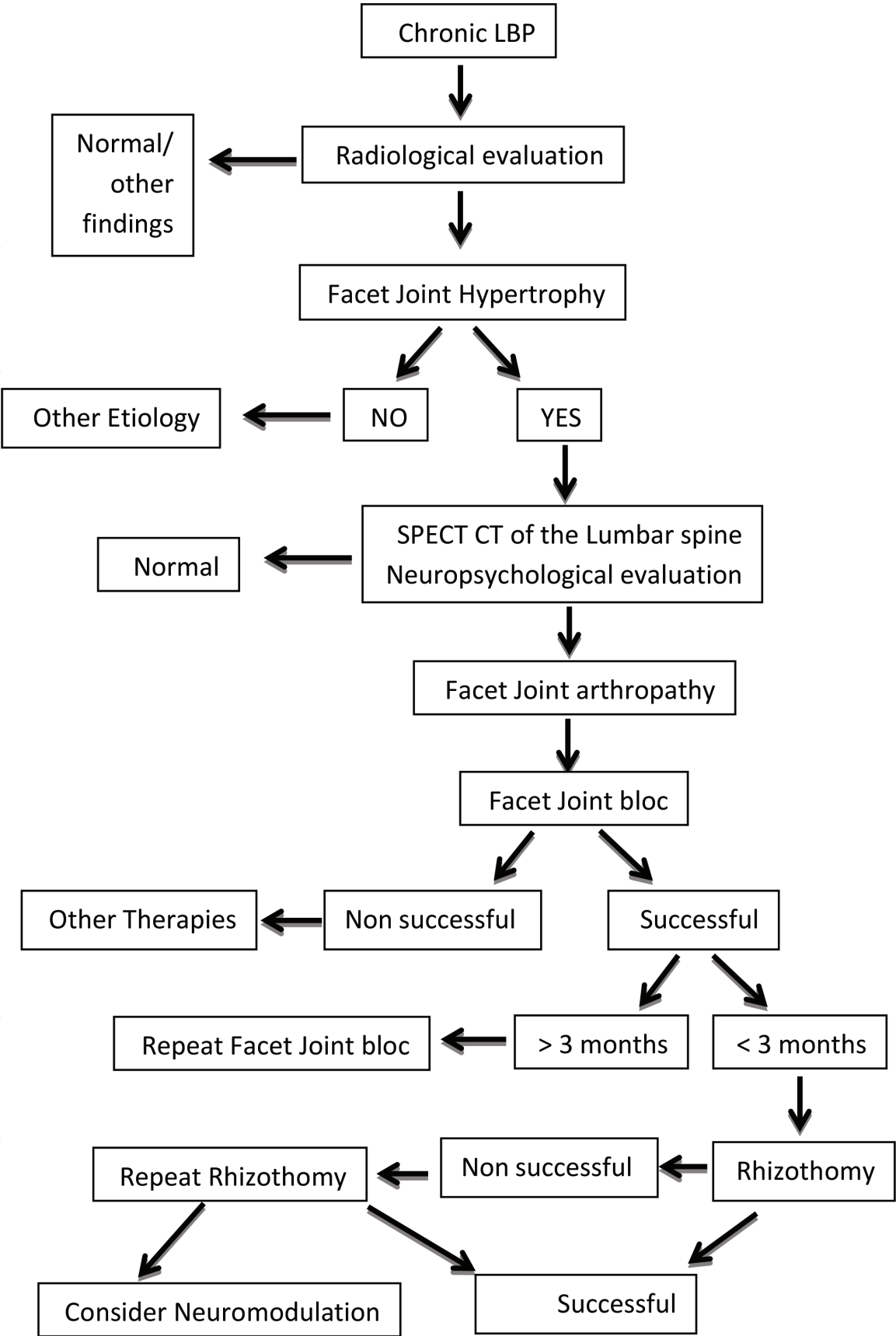


Figure 2.
The Moncton workflow for facet radio-frequency ablation treatment.

block under fluoroscopy at the pain clinic. In case of improvement that lasts more than 3 months, reevaluation and second facet block are offered to the patient.

In case of improvement for more than 48 h but less than 3 months, patients are considered candidates for radio-frequency ablation.

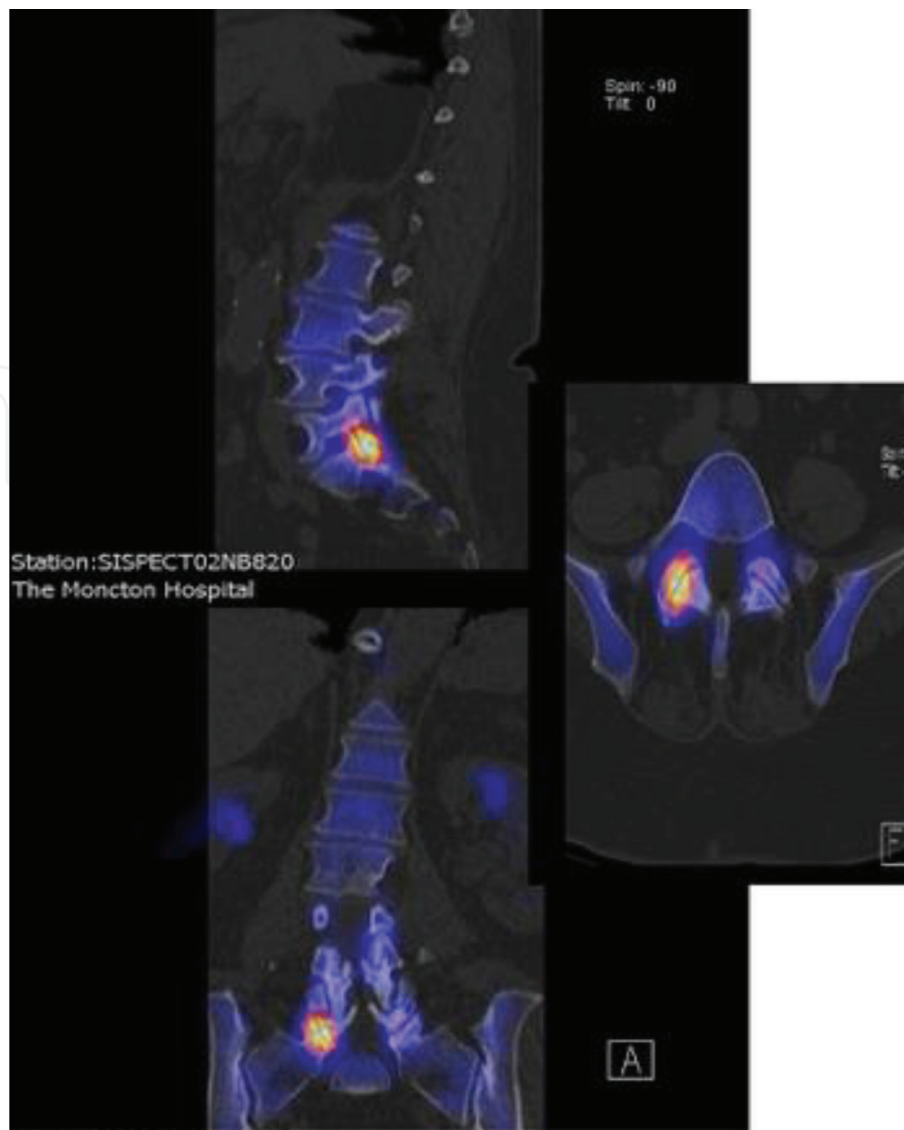


Figure 3.
 SPECT CT of the lumbosacral spine showing increase uptake of the right L5–S1 facet joint in favor of facet arthropathy.

4. Surgical technique

Rhizotomy is an outpatient procedure performed under local-assisted anesthesia [10]. Patients are evaluated at the office few weeks prior to the procedure; surgical consent and laboratory workup with a complete blood count in addition to PT are signed; PTT tests are done.

Patients are asked to fast 6 h prior to the procedure. All anticoagulant and anti-aggregant are stopped according to guidelines.

The procedure is done in the operating room. The anesthesiologist proceeds by inserting an intravenous access on the arrival of the patient to the OR. The patient is positioned prone on a radiolucent table with pillow under the head; the arms are above the head in a comfortable position.

Fluoroscopy is used for anteroposterior and lateral views (**Figure 4**). Aseptic technique is used. Once level is verified, local anesthesia using xylocaine 2% is infiltrated from the skin to the muscle aponeurosis. Under fluoroscopy, we insert a 20 gauge needle percutaneously targeting the junction of the transverse process and superior articulating facet, where the medial branch of the Luschka nerve runs innervating the facet joint. The needle is advanced until bone contact is made. Once position is verified, the patient is assessed for motor and sensory manifestations in the lower limb.

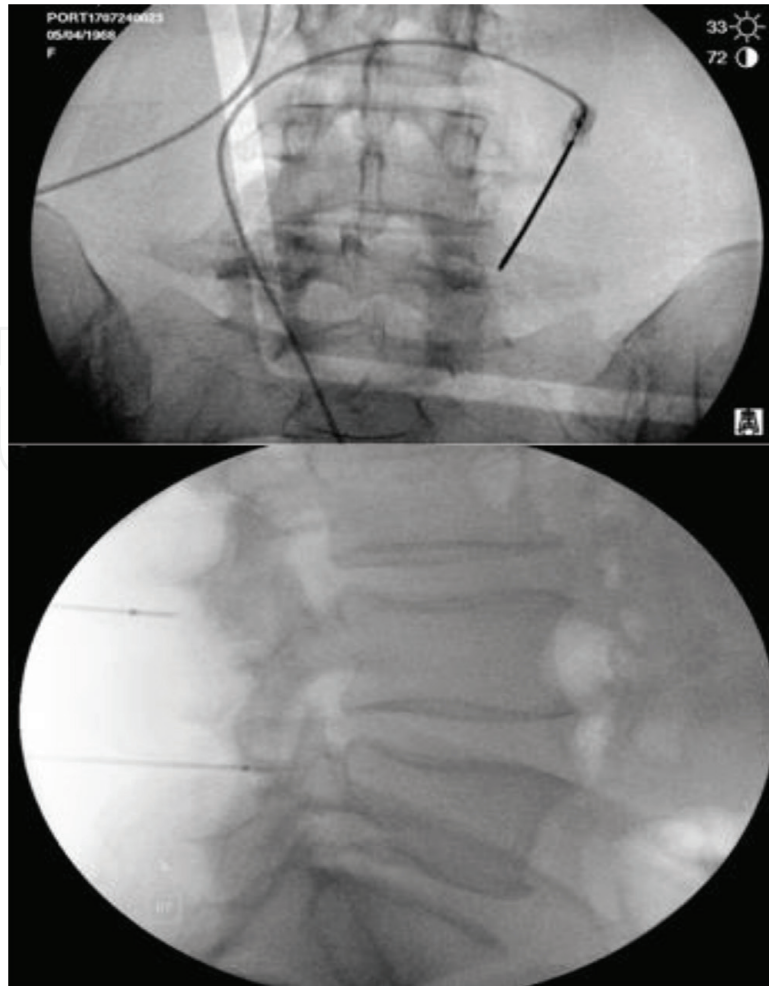


Figure 4.
Anteroposterior and lateral per operative views for L4–L5 rhizotomy.

Using Baylis radio-frequency machine (Baylis medical), we start by a stimulation until reproducing patients pain and paraspinal lumbar muscle contraction. Radio frequency is started at 80°C for 90 s. Once 80° is reached (10–15 s), the needle is rotated progressively every 15 s to reach 360° coverage. The patient is then reassessed for motor or sensory manifestations in the lower limb.

A new stimulation trial is performed. In case there is a need to increase the stimulation two times compared to prior or there is no pain reported by the patient, the procedure is considered successful, and the needle is removed. The entry point is covered by a small dressing. If the patient still feels the pain or the pain was reproduced with the same stimulation level, the procedure is repeated for 60 s at 80°. After the second trial, when needed, the needle is removed and a dressing is applied. Patients are turned to their back and transferred to the same day care facility.

5. Postoperative care

Patients are discharged the same day, 30–60 min after the procedure. They are followed at 2 and 4 weeks post procedure. Pain is reevaluated by visual analog scale and quality-of-life scale at the office (questionnaire is administered to the patient before their appointment).

In case of recurrence of pain after 2 weeks of relief, patients are rescheduled for a second radio-frequency treatment. During the second procedure, we target the same level as the first in addition to the superior level trying to cover the largest area

and ablating the two medial branches innervating that facet. In case of failure at 1 month, we offer other neuromodulation procedures for the patient.

6. Complications

The overall complication rate is very low in radio-frequency procedure in the treatment of facet joint arthropathy [3, 10]. The main complication is injury to the nerve root at its exit if the needle is advanced beyond the bony anatomical landmark inferior to the transverse process.

Infectious rate is very low in purely aseptic technique done in the neurosurgical operating room. Dural puncture may occur if the needle is advanced medially or if the technique is not done under fluoroscopy.

7. Methods

The radio-frequency treatment is a minimally invasive cost-effective procedure. Although it is still very controversial, we found it as a safe and efficacious procedure to be offered for chronic low back pain patients refractory to conservative treatment. Selection criteria for the patients are very important to benefit from the procedure.

7.1 Selection criteria

Patient's age is 18 years and older.

Refractory low back pain to at least 3 months of conservative treatment.

Positive SPECT CT for facet joint arthropathy. Absent MRI/CT scan finding for other spinal disease.

Improvement for at least 48 h after facet joint block and absent neurocognitive diseases.

7.2 Study design

All charts of patients that benefited from the procedure were analyzed retrospectively. The procedure was done by the same neurosurgeon, but the clinical evaluation and the indication were decided at the practice of all the neurosurgical team included in this study.

7.3 Outcomes

The primary outcome was the pain intensity evaluated by the visual analog scale (VAS), 11 points of evaluation of the pain where 0 indicates the absence of pain and 10 is the worst pain ever.

The McGill pain questionnaire score between 20 and 30 points indicates the presence of chronic low back pain.

The SF-36 QOL questionnaire, with a score of 0, indicates severe or absent activities and worse QOL, whereas a score of 100 shows an excellent QOL.

Patients' response to the procedure was considered by an improvement of 50% or more on the VAS and a change of 20 or more points on the SF-36 QOL score. An improvement of 25–50% on the VAS leads us to suggest a second rhizotomy procedure to increase the area of coverage and try to have a better outcome.

8. Results

In total, 63 patients were treated by radio-frequency ablation of the medial branch of the facet joint in the lumbar spine between 2015 and March 2018.

All included patients had long history of low back pain refractory to medical treatment with short-term response to facet joint steroid injection block. Patients didn't have any major psychological disease.

All included patients were adults. The mean age was 57 years (21–84 years). Forty-one patients were male, and 22 patients were females.

The mean pretreatment VAS was 8.4, the McGill pain score was between 20 and 30, and the SF-36 score was 58.6.

The post-procedure mean VAS was 3.8. Forty-four patients had an improvement of more than 50% of their pain; eight patient had an improvement of 25% of their pain, and 11 patients did not notice any changes at 2 weeks.

All the eight patients that reported 25% of improvement were scheduled for a second procedure. Six of eight reported an improvement of more than 50%, one did not notice any difference, and one returned to his previous VAS.

At 3 months, 40 patients were maintaining a VAS score of 50% or more than their initial pain score. Five patients had their pain score between 25 and 50%. And, seven patients returned to their baseline score. From all seven, four had already two radio-frequency treatments and were redirected to a neuromodulation procedure, and three had a second rhizotomy. One improved and was considered successful.

The overall patients that improved were 73%. Sixty-five percent had a major improvement, 8% moderate improvement, and 27% failed to improve after one or two trials.

In the 65% of patients, the overall SF-36 score improvement was to a mean of 77.9.

Three patients reported lower limb paresthesia post-procedure. Two of them had a complete remission of their symptoms at 2 weeks of follow-up, and the third improved after 6 weeks. No infection, no CSF leak, and no injury to the motor nerve root were observed.

9. Discussion

Our result on low back improvement is similar to different studies at 2 and 4 weeks of the procedure [2, 11, 13].

At 3 months, we had a better outcome compared to other studies [11, 12]. All studies used the VAS for pain evaluation.

We consider the selection criteria specifically the positive SPECT CT findings in addition to the response to facet block as a major contributor in the prediction of the success of the procedure. No previous study used both criteria in conjunction. Van Wijk et al. showed the importance of the diagnostic test block, although their result was the same compared to sham at 3 months [12].

We followed the patients for 3 months, which is an intermediate time follow up as in other studies that showed the same results [11–14]. We found that improving pain score and QOL for 3 months was a sufficient time to consider the procedure as efficient. The subjective satisfaction rate and the reported improvement on VAS and SF-36 score, respectively, were good indicators to maintain the procedure as one of the armamentarium in the treatment of chronic low back pain related to facet joint arthropathy; this finding is against Juch et al. findings that have a statistically positive finding without any clinical improvement [4]. Although, in their study published in JAMA, they suggested to improve the selection criteria to improve the outcome related to that procedure, our workflow chart improved the results dramatically.

10. Conclusion

Radio-frequency ablation technique is a safe and efficient procedure. Its complication rate and cost are low. It is a reproducible procedure. Careful patient selection increases its success rate.

The use of this technique for the treatment of other etiologies has been described. Its use in the management of metastatic vertebral bone disease is promising and becoming a very useful tool as a pain management procedure.

Acknowledgements

We extend our thanks to Dr. Jennifer Hakim who participated in the editing of this chapter.

Conflict of interest

All four authors have no conflict of interest.

Author details

Antonios El Helou*, Charbel Fawaz, Robert Adams and Dhany Charest
Department of Neurosurgery, The Moncton Hospital, Horizon Health Network,
Moncton, New Brunswick, Canada

*Address all correspondence to: dr.antonios.elhelou@horizonnb.ca

IntechOpen

© 2018 The Author(s). Licensee IntechOpen. This chapter is distributed under the terms of the Creative Commons Attribution License (<http://creativecommons.org/licenses/by/3.0>), which permits unrestricted use, distribution, and reproduction in any medium, provided the original work is properly cited. 

References

- [1] Leggett LE, Soril LJ, Lorenzetti DL, Noseworthy T, Steadman R, Tiwana S, et al. Radiofrequency ablation for chronic low back pain: A systematic review of randomized controlled trials. *Pain Research & Management*. 2014;**19**(5):e146-e153
- [2] Al-Najjim M, Shah R, Rahuma M, Gabbar OA. Lumbar facet joint injection in treating low back pain: Radiofrequency denervation versus SHAM procedure. Systematic review. *Journal of Orthopaedics*. 2017;**15**(1):1-8. DOI: 10.1016/j.jor.2017.10.001
- [3] Kelekis A, Filippiadis DK. RFN on Lumbar facet joint. In: Marcia S, Saba L, editors. *Radiofrequency Treatment of the Spine*. Springer International Publishing Switzerland; 2017. pp. 57-62. DOI: 10.1007/978-3-319-41462-1_7.ch7
- [4] Juch JNS, Maas ET, Ostelo RWJG, George Groeneweg J, Kallewaard J-W, Koes BW, et al. Effect of radiofrequency denervation on pain intensity among patients with chronic low Back pain. The mint randomized clinical trials. *Journal of the American Medical Association*. 2017;**318**(1):68-81. DOI: 10.1001/jama.2017.7918
- [5] Lee CH, Chung CK, Kim CH. The efficacy of conventional radiofrequency denervation in patients with chronic low back pain originating from the facet joints: A meta-analysis of randomized controlled trials. *The Spine Journal*. 2017;**17**(11):1770-1780. DOI: 10.1016/j.spinee.2017.05.006
- [6] Cohen SP, Doshi TL, Constantinescu OC, Zhao Z, Kurihara C, Larkin TM, et al. Effectiveness of lumbar facet joint blocks and predictive value before radiofrequency denervation: The facet treatment study (FACTS), a randomized, controlled clinical trial. *Anesthesiology*. Sep 2018;**129**(3):517-535. DOI: 10.1097/ALN.0000000000002274
- [7] Bogduk N, Dreyfuss J. A narrative review of lumbar medial branch neurotomy for the treatment of back pain. *Pain Medicine*. 2009;**10**(6):1035-1045. DOI: 10.1111/j.1526-4637.2009.00692.x
- [8] Masini M, Paiva WS, Araújo AS Jr. Anatomical description of the facet joint innervation and its implication in the treatment of recurrent back pain. *Journal of Neurosurgical Sciences*. 2005;**49**(4):143-146
- [9] Russo VM, Dhawan RT, Baudracco I, Dharmarajah N, Lazzarino AI, Casey AT. Hybrid bone SPECT/CT imaging in evaluation of chronic low Back pain: Correlation with facet joint arthropathy. *World Neurosurgery*. 2017;**107**:732-738. DOI: 10.1016/j.wneu.2017.08.092
- [10] Pacetti M, Fiaschi P, Gennaro S. Percutaneous radiofrequency thermocoagulation of dorsal ramus branches as a treatment of "lumbar facet syndrome" how I do it. *Acta Neurochirurgica*. 2016;**158**:995-998. DOI: 10.1007/s00701-016-2759-7
- [11] Leclaire R, Fortin L, Lambert R, et al. Radiofrequency facet joint denervation in the treatment of low back pain: A placebo controlled clinical trial to assess efficacy. *Spine*. 2001;**26**:1411-1416
- [12] Van Wijk R, Geurts JWM, Wynne HJ, et al. Radiofrequency denervation of lumbar facet joints in the treatment of chronic low back pain: A randomized, double-blind, sham lesion-controlled trial. *The Clinical Journal of Pain*. 2005;**21**:335-344
- [13] Van Kleef M, Barendse GA, Kessels A, et al. Randomized trial of radiofrequency lumbar facet denervation for chronic low back pain. *Spine*. 1999;**24**:1937-1942

[14] Nath S, Nath CA, Pettersson K.
Percutaneous lumbar zygapophysial
(facet) joint neurotomy using
radiofrequency current, in the
management of chronic low back pain:
A randomized double-blind trial. *Spine*.
2008;**33**:1291-1297

IntechOpen

IntechOpen