

We are IntechOpen, the world's leading publisher of Open Access books Built by scientists, for scientists

6,900

Open access books available

186,000

International authors and editors

200M

Downloads

Our authors are among the

154

Countries delivered to

TOP 1%

most cited scientists

12.2%

Contributors from top 500 universities



WEB OF SCIENCE™

Selection of our books indexed in the Book Citation Index
in Web of Science™ Core Collection (BKCI)

Interested in publishing with us?
Contact book.department@intechopen.com

Numbers displayed above are based on latest data collected.
For more information visit www.intechopen.com



Allogenic Decal-Bone Grafts: A Viable Option in Clinical Orthopedics

Surendar Tuli

Additional information is available at the end of the chapter

<http://dx.doi.org/10.5772/intechopen.80877>

Abstract

One has to resort to allogenic source of bone grafts especially in filling up of large or multiple containable cavitory lesions, structural reconstruction of large circumferential osteoperiosteal defects, extensive spinal fusions for gross deformities, or extensive operative reconstruction after total joint replacements. These procedures demand an abundant quantity of bone material in which a patient's (recipient's) body cannot supply without significant morbidity and risks. At present most of the allogenic bone banks use deep-freezing or freeze-drying or radiation for long-term preservation. The techniques maintain sterility, reduce immunogenicity, and provide adequate structural integrity; however, such procedures reduce the bone-forming biological activity and are expensive. We have worked for clinical translation of the basic research performed by Marshal Urist (1965–1994). After extensive experimental observations, we have been using partially decalcified allogenic bone as grafts in clinical cases since 1978. Favorable outcome has been observed in benign cystic lesions, wide-gap grafting, and spinal fusions. Minimum follow-up for declaring "success" or "failure" of the procedure was 2 years after implantation.

Keywords: bone grafts, allogenic bone grafts, allogenic decal-bone grafts

1. Introduction

Bone grafting is a standard orthopedic procedure performed in clinical practice. Autogenous graft is the gold standard and the preferred graft used. However, allograft bone continues to play an important role in many orthopedic reconstructive procedures. One has to resort to the allogenic sources especially in filling up of large or multiple containable cavitory lesions, structural intercalary reconstruction of large circumferential osteoperiosteal defects, extensive

spinal fusion for gross deformities or severe instabilities especially in children, and repeat surgeries after total joint replacements. These procedures demand an abundant quantity of bone which the recipient’s body cannot supply without significant morbidity and risks. At present popularly allogenic bone is preserved by deep-freezing or freeze-drying or by radiation for long-term preservation. These techniques have been shown to maintain sterility, reduce immunogenicity, and provide adequate structural integrity; however, such procedures also reduce the bone-forming biological activity and are expensive (**Table 1**). Autoclaving and radiation completely destroy bone inductive principles.

One of the most exciting works during the latter half of the twentieth century (1965–1994) has been the clinical translation of the basic research performed by marshal Urist [1, 2].

After extensive experimental work [3, 4], we have been using partially demineralized allogenic bone (decal-bone) as grafts in clinical cases. For preparation and preservation of allogenic bone graft, we used the techniques described by Urist (1965–1987). We aimed at removal of approximately 50% of mineral from the graft, thus retaining adequate structural integrity (**Table 2**). We used this material since 1978, and we closely observed the clinical results on long-term bases in 67 benign cystic lesions, 32 wide-gap graftings, and 11 posterior

	Fresh autogenous	Fresh/unprocessed allogenic	Frozen freeze-dried allogenic	Partially decalcified	Deproteinized allogenic
Osteoinduction	++++	+++	+++	++++	0
Osteoconduction	+++	++	++	+++	++
Osteogenic	++	0	0	0	0
Immunogenicity	0	+++	++	?+	0
Mechanical strength	+++	+++	++	++	++
Cost	?+	+	+++	+	+++

Frozen grafts require thawing, freeze-dried grafts require hydration before implantation, and the unused graft cannot be re-preserved.

Table 1. Commonly used bone grafts in clinical orthopedics.

A. Treatment with 0.6 MHcl:
<ul style="list-style-type: none">• Removes mineral and exposes BMP and other growth factors on matrix• Opens and cleanses vascular, Haversian, Volkmann channels, and lacunar spaces of cells and debris• Reduces antigenicity, chemosterilizes, and is virucidal
B. Treatment with ethanol:
<ul style="list-style-type: none">• Preserves without denaturing the bone morphogenetic protein (BMP) and other osteoinductive principles (OIP), chemosterilizes, and is virucidal• Leaches out fat ex vivo• These processes as a rule are done by the host scavenger cells in vivo in un-demineralized bone grafts

Table 2. Processing of allogenic decal-bone.

or posterolateral spinal fusion. Minimum follow-up for declaring “success” or “failure” of the grafting procedures was 2 years after implantation. We prefer to use the expression of “decal-bone” because the whole process of decalcification is performed in vitro.

2. Preparation of allogenic “decal-bone” graft

Human bones were obtained from freshly (posttraumatic) amputated extremities, under strict aseptic operation theater conditions. Soft tissues and periosteum were removed from the bones using sharp instruments. After a minimum of three washings with normal saline, the bones were placed and immersed in 0.6 M HCl solution for 3–5 days in a domestic refrigerator. The solution was changed every 24 hours. The partially decalcified bone was washed with normal saline to remove any traces of acid, sealed in 80–90% ethanol, and kept in a domestic refrigerator at about 4–6°C (**Figures 1 and 2**). The stored bone was used between 1 and 12 months of preservation. Osteoporotic bone from old persons would be ready by the third day; however, fully mineralized bone from athletic or healthy persons may take 5 days for achieving 50–40% decalcification. Bone obtained from total knee replacements in the operating rooms was another material processed for use as decal-bone.

When required for implantation, the preserved bone was washed thoroughly with normal saline. The superficial surface of graft was pared using a sharp scalpel, and it was cut to the required size to give a snug fit in the host bed for structural grafting, generally fixing to the host bone using an intramedullary nail. For filling large cystic cavities of bone, the decal-bone was cut like matchstick silvers with thickness and width of 4–6 mm and washed with normal saline. The cavities after thorough curettage were compactly packed with the matchstick graft.

For spinal fusions the recipient bed was decorticated, and abundant graft was placed oriented along the long axis of the spine. In cases with gross mechanical instability, a suitable implant with multi-segmental fixation was employed as an adjunct. Standard operative principles for such extensive procedures were followed with modifications to suit individual requirements.

For giant cell tumors of bone (GCT) prior to 1986, en bloc resection and structural reconstruction was performed as a standard procedure. We had an opportunity to observe the behavior of large allogenic segmental graft used for such patients. Global observation however advised less aggressive joint-sparing intralesional procedures since approximately 1987.

Currently for all containable cystic lesions including GTC, we use and recommend the following steps for grafting:

- I. Perform thorough intralesional curettage through an adequate window.
- II. Aspirate the debris completely.
- III. Fill up the cavity with hydrogen peroxide for 3 minutes, and clean the cavity with normal saline.
- IV. Fill the cavity with absolute ethanol (80–90%) for 3 minutes.
- V. Remove ethanol and wash with normal saline.

VI. Do compact filling of the cavity with decal-bone grafts.

VII. After wound closure protect the limb with suitable cast, and follow the standard post-operative care.

This routine has appreciably reduced the incidence of infection and recurrence, and the success rate has markedly improved.

2.1. Cytological and histological observations

In addition to clinical and radiological assessment, postimplantation observations were made by (i) periodic fine-needle aspiration cytology (FNAC) from the graft and perigraft area,

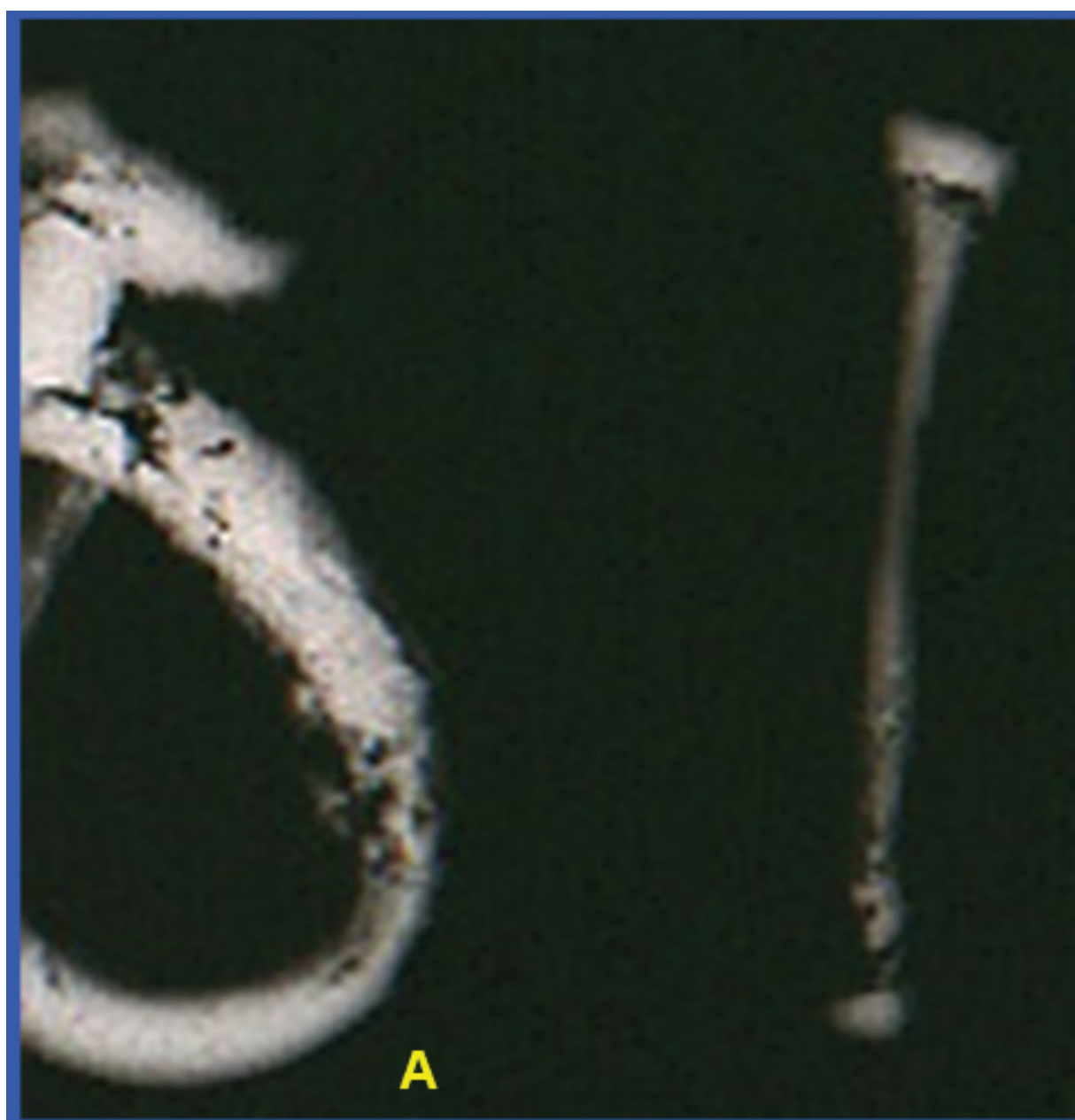


Figure 1. After complete decalcification, the bone (radius in picture) becomes soft like leather.

(ii) by periodic core biopsy of the graft after tetracycline administration, and (iii) by histological studies of the retrieved graft in cases of reoperation.

2.1.1. Observations

Cavitory cystic lesions: the observations regarding cystic lesions are listed in **Table 3**. The success after curettage and bone grafting was uneventful in 60% of cases of giant cell tumor (GCT), in 75% of cases of aneurysmal bone cyst (ABC), and in 85% of cases of unicameral bone cyst (UBC) **Figure 3**. Further success by supplementary curettage and bone grafting was obtained in 10% of cases of GCT, 25% of ABC, and 15% of UBC. Supplementary bone grafting was required because of unexplained resorption of the graft or low-grade infection leading to sequestration and resorption of the graft. Six cases of GCT failed because of uncontrolled

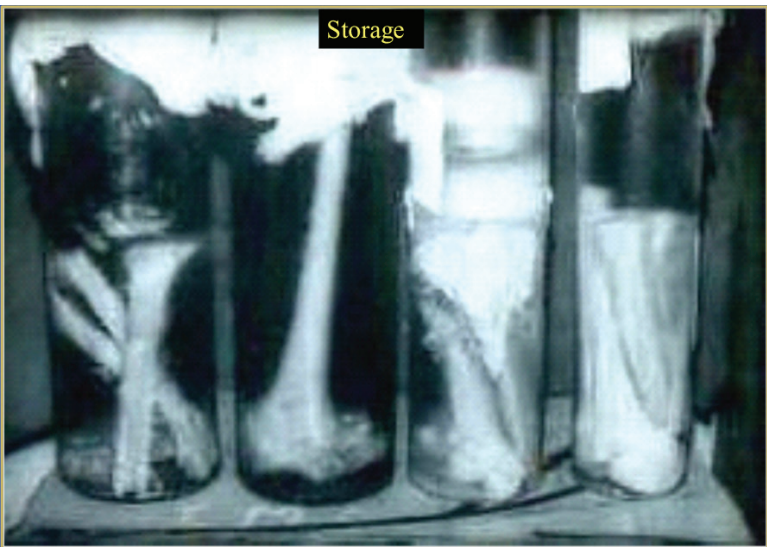


Figure 2. Partially decalcified bone stored in ethanol.

Pathology	Success		Sup. success	Failure
Typ. giant cell tumor	18	60%	10%	30%
Aneurysmal bone cyst	21	75%	25%	
Unicameral bone cyst	11	85%	15%	
• Fibrous defect	6	6		
• Solitary chondroma	3	3		
• Chod. myxoid fibroma	2	2		
• Poly-OFD	4	3	1	
• Multiple enchondromas	2	1	1	

• Number is too small to express as valid percentage.
Poly-OFD = polyostotic fibrous dysplasia.

Table 3. “Cystic lesions” of bone (67) treated by curettage and allogenic decal-bone grafting.

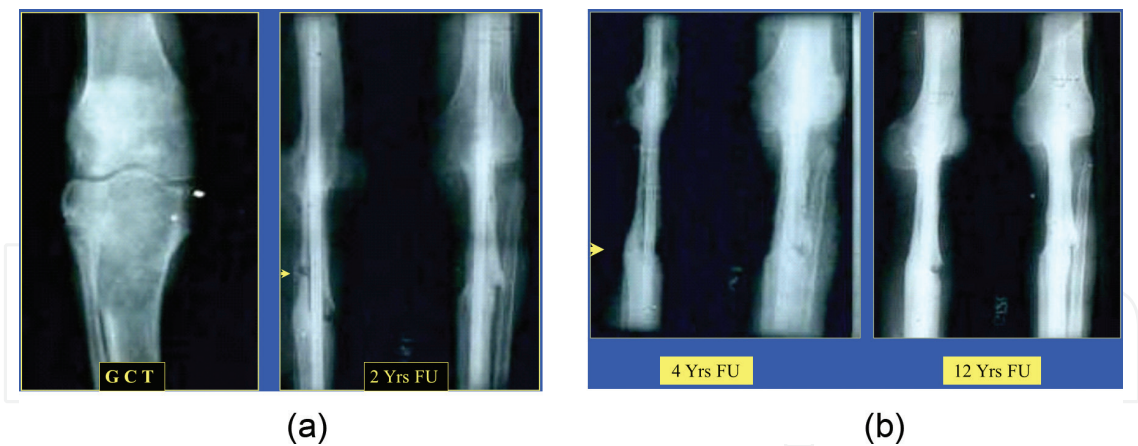


Figure 3. A recurrent giant cell tumor of distal femur with pathological fracture. The healed status achieved by intralesional curettage and decal-bone grafting following 12 years.

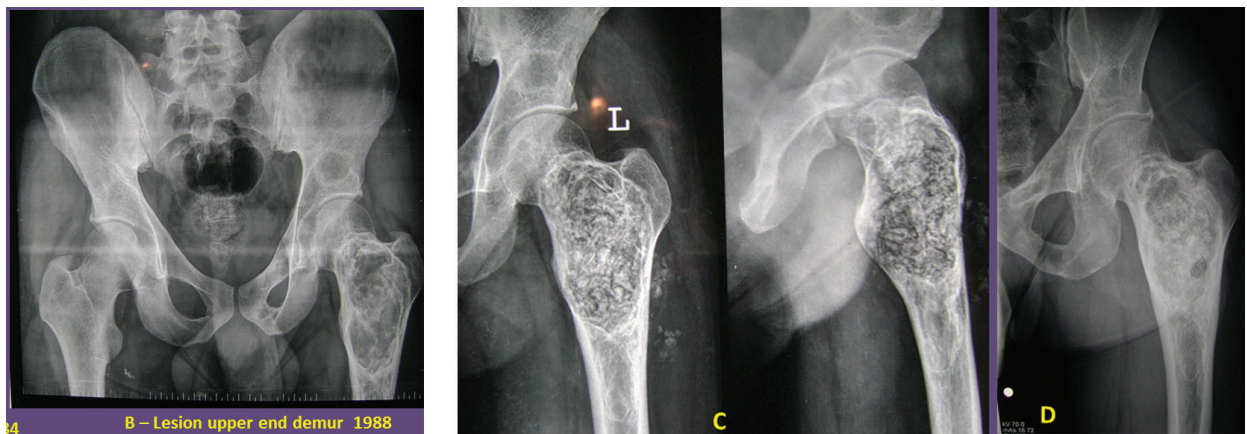


Figure 4. A case of polyostotic fibrous dysplasia. The cyst in the trochanteric area remained healed after curettage and decal-bone grafting. After about 14 years of gap, another cyst in the supra-acetabular region needed treatment.

infection (three cases) and massive recurrence of tumor (three cases). All patients of solitary osseous lesions healed successfully. Polyostotic fibrous dysplasia (4), multiple fibrous defects (6), enchondromas (3), chondromyxoid fibroma (2), and enchondromatosis (2) by their biological nature may need reoperation for an increase in the size of the lesions which were insignificant at the time of the first surgery. One patient of fibrous dysplasia had to undergo a second operation for a new lesion, and one patient of enchondromatosis is awaiting surgery for the additional area (**Figure 4**).

3. Intercalary structural bone grafts

Observations regarding 32 cases of structural bone grafts used for large osteoperiosteal gaps are summarized in **Table 4**. The largest group was 28 cases of giant cell tumors, 40% of these obtained uneventful success (**Figure 5**), 38% needed supplementary operation in the form of

Pathology		Success	Supp. success	Failure
Giant cell tumor	28	40%	38%	28%
• Aneurysmal bone graft	1	1	–	–
• Unicameral bone graft	1	1	–	–
• Central fibrosarcoma	1		–	1
• Traumatic extrusion	1	1	–	–
• Number is too small to express valid percentage.				

Table 4. Large osteoperiosteal gaps (32) and structural grafts (1979–1999).

further autologous bone grafts for areas of non-union at host graft junctions or for pseudarthrosis in the intermediate part of the graft 20%, for control of infection, or for a combination of these factors (18%).

Six patients were considered a failure because the reconstruction failed. Two had recurrence of tumor, one had uncontrolled infection, and these ended up in amputations. In three patients despite two attempts at supplementary grafting, the areas of pseudarthrosis did not heal; these patients accepted an orthosis till further decision. One case of malignant fibrous histiocytoma failed because of recurrence of tumor within 4 months of limb salvage attempt.

Of the 11 patients of posterior or posterolateral spinal fusion, 10 were considered to have obtained satisfactory osseous fusion based upon clinical assessment and stress X-rays done 12–24 months after the operation (**Figure 6**). One young nurse who had posterior fusion along with Steffi’s fixation at L3–L4 for spondylolisthesis was considered a failure because of the implant breakage observed 2 years after operations.

3.1. Cytological and histological observation

Fine-needle aspiration cytology (FNAC) was done from the perigraft region (in 20 patients) between the 10th and 40th day after grafting. The FNAC showed high cellularity composed of

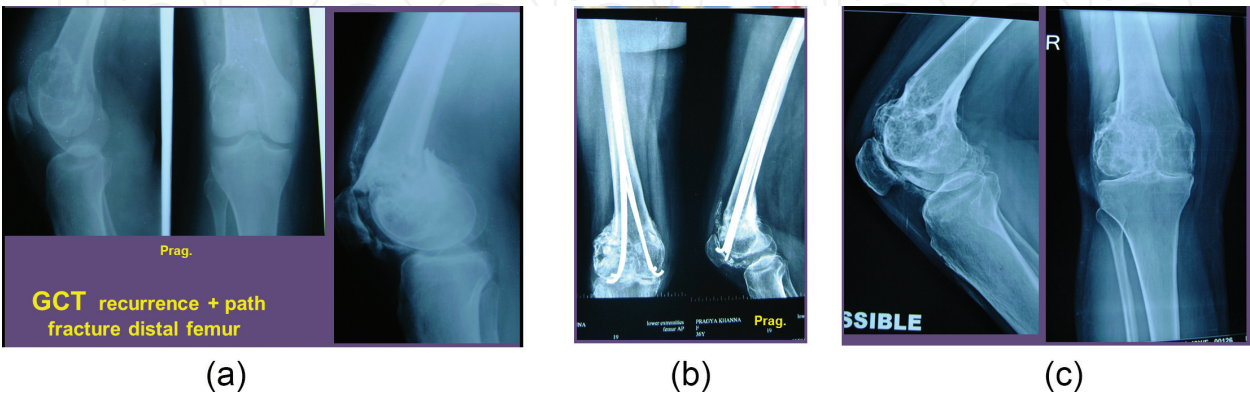


Figure 5. Intercalary reconstruction after en bloc resection of giant cell tumor of distal femur. Note gradual incorporation and remodeling as observed in the 12-year follow-up.

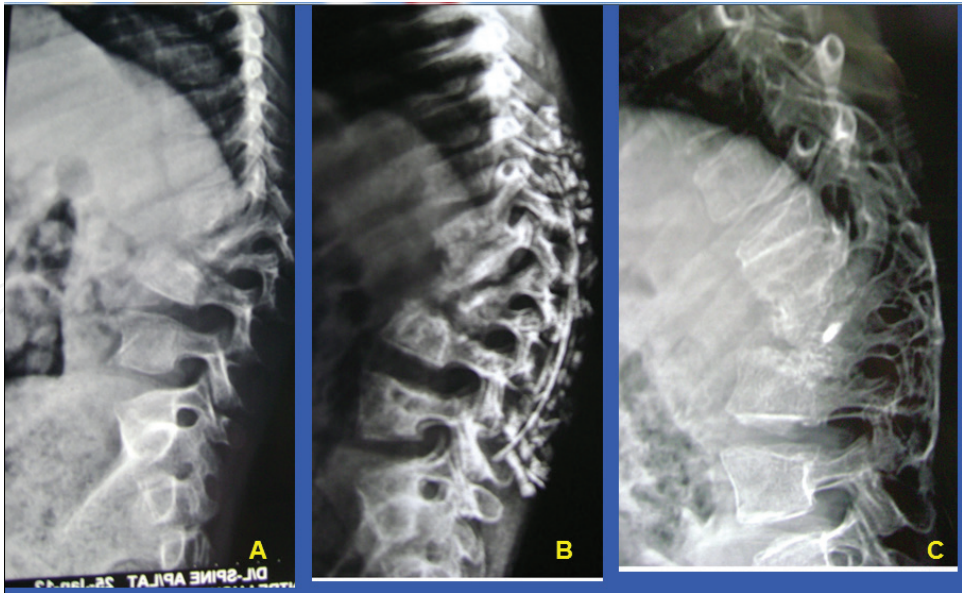


Figure 6. A child having tuberculosis of the spine involving multiple vertebrae: posterior spinal fusion was performed using allogenic decal-bone. Note the incorporation of the graft with remodeling during a 3-year follow-up.

polymorphs, lymphocytes, and macrophages between 10 and 20 days. The cellularity gradually reduced with relative increase in the number of lymphocytes. By the 40th postimplantation day, the macrophages were practically absent, and one could see appreciable osteogenic activity by the presence of osteoblasts and osteoclasts. No cellular immune reaction was discernable.

Periodic core biopsy in early stages and biopsy of the graft in patients who required a second operation showed histological and tetracycline fluorescence evidence of neo-osteogenesis between 6 and 12 weeks. The fluorescence in the implanted allogenic bone was quantitatively the same as the bone of a patient’s iliac crest in specimens available 12 months after the grafting.

3.2. Discussion

Contents of bone grafts and their roles: In general calcium hydroxyapatite, the predominant mineral in bones provides an inert framework providing mechanical stability and offering a lattice work for penetration of neocapillaries, reparative tissues, and osteoconduction (Table 5). Only the most superficial bone-forming cells in fresh autografts which survive getting nutrition by tissue perfusion provide direct osteogenic activity. In allografts no viable cells are expected; however, the debris of dead cells act as the most potent immunogenic agent. Organic matrix provides the most potent bone morphogenetic (bone induction principles)

Ca hydroxyapatite	Mechanical stability
Autogenous surviving cells	Osteogenesis
Allogenic non-surviving cells	Immunogenesis
Matrix	Bone morphogenetic agents(weak mechanical strength)

Table 5. Contents of bone graft and their role.

agent. Its viability however depends upon the influence of processes of allograft preparation and preservation [5–10].

Bone graft incorporation: The biological process of incorporation of bone grafts is practically similar to that of a fracture healing. Under favorable environment, the following major steps occur in a cascaded fashion from the time of placement of the bone graft in the recipient bed to its incorporation and remodeling according to Wolff's law: (i) hematoma formation and its organization by invasion of neocapillaries surrounded by perivascular pluripotent mesenchymal cells; (ii) osteoclastic and phagocytic resorption of nonviable mineral (calcium hydroxyapatite), cellular debris and marrow fat, and tunneling of the graft-making channels for ingrowth and propagation of neocapillaries and osteoprogenitor cells; (iii) conversion (tissue engineering) of osteoprogenitor cells to osteoblastic cells under the influence of local osteoinductive agents (bone morphogenetic protein, other inductive agents, and growth factors present in the organic matrix of the bone graft) and the platelets. Laying down of the new bone (neo-osteogenesis) on the surface of matrix framework and along the vascular spaces/channels; and (iv) remodeling of the newly formed bone to conform to the trabecular pattern along the lines of functional loading and stress (according to Wolff's law). These events are a slow process; the grafted area needs protection with repetitive physiological axial or functional loading. The most challenging clinical condition of structural (intercalary) bone grafting for large osteoperiosteal gaps in the lower limb may take 2–4 years for adequate incorporation permitting unprotected loading [11, 12]. The mechanical strength of the reconstruct is weak for 1 and 1/2 to 2 years, after which the strength increases by more neo-osteogenesis. The least time is taken in a cavitary pathology which offers a very large osteogenic bed and copious surface for intimate contact with the graft [13–15]. As incorporation takes place from periphery to the center, the time taken for large cavities and large grafts is correspondingly higher. In un-demineralized cortical (e.g., fibula) graft, 20–30% (deepest sector) of the grafted bone may never get incorporated; it may stay incarcerated surrounded by newly formed bone.

By HCL decalcification we aimed at the removal of nearly 50% of mineral, thus providing adequate structural integrity. The said treatment removed all cell debris and fat providing opened-up channels for ready penetration of neocapillaries and perivascular mesenchymal cells. Acid demineralization also removed the mineral from the surface of the bone, along the vascular channels, and on the lacunar spaces, thus exposing the matrix for intimate contact with the invading perivascular tissues, and facilitated the interaction between the graft matrix (most active osteoinductive principle) and the pluripotent mesenchymal cells from the host. The technique used by us does not destroy the biological osteoinductive property of the bone matrix.

Immunogenicity of allogenic bone is now better understood. Fresh unmatched and untreated allogenic bone inevitably evokes an immune response in the host. The immune response in general is delayed and mild and develops slowly; however, it results in "unexplained" graft resorption and delay or failure in its incorporation. In clinical practice deep-freezing, freeze-drying, freeze-drying, and irradiation are currently employed to reduce immunogenicity. Pure BMP from an allogenic source or even a xenogenic source is considered to have negligible immunogenicity. We feel that a simple treatment of allogenic bone by HCL decalcification and ethanol preservation practically eliminates the antigenic material (cells and debris) to permit unhindered incorporation in clinical practice as observed in our cases. Overall analysis

in our clinical material has been approximately 80–90% successful for benign cavitory lesions; for impaction grafts in revision joint surgeries, 50–70% success for structural reconstruction in circumferential osteoperiosteal gaps; and 70–90% clinical success in extensive spinal fusion. Supplementary procedures for obtaining success in difficult cases, especially for osteoperiosteal gaps, are an accepted norm in 20–30% of cases. The success rate in our clinical cases is compatible with the observations of the outcome where allogenic bone was used from more sophisticated bone banks. Allogenic bone graft is a rational option when the recipient's patient owns bones that are inherently defective (e.g., fibrous dysplasia, enchondromatosis).

Acknowledgements

The author is grateful to Mr. Kundan Thakur for his preparation of the typed scripts and to Mr. Amit Kumar for his preparation of figures.

Conflict of interest

There are no conflicts of interest.

Financial support

None.

Author details

Surendar Tuli

Address all correspondence to: smohantuli@yahoo.co.in

Spinal Disorder and Orthopaedics, Vimhans-Primamed Hospital, New Delhi, India

References

- [1] Urist MR. Surface-decalcified allogenic bone (SDAB) implants. A preliminary report of 10 cases and comparable operations with undecalcified lyophilized bone implants. *Clinical Orthopaedics and Related Research*. 1968;**56**:37-50
- [2] Urist MO'Connor B, Burwell RG, editors. *Bone Grafts, Derivatives and Substitutes*. Oxford: Butterworth Heinemann; 1994

- [3] Tuli SM, Singh AD. The osteoinductive property of decalcified bone matrix: An experimental study. *Journal of Bone and Joint Surgery*. 1978;**60-B**:116-123
- [4] Gupta D, Tuli SM. Osteoinductive of partially decalcified alloimplants in healing of large osteoperiosteal defects. *Acta Orthopaedica Scandinavica*. 1982;**53**:857-865
- [5] Delloye C, Hebrant A, Munting E, Piret L, Coutelier L. The osteoinductive capacity of differently HCI-decalcified bone alloimplants. *Acta Orthopaedica Scandinavica*. 1985; **56**:318-322
- [6] Inclan A. The use of preserved bone graft in orthopaedic surgery. *Journal of Bone and Joint Surgery*. 1992;**24**:81-82
- [7] Boden SD, Stevenson S, editors. Bone grafting and bone graft substitutes. *Orthopedic Clinics of North America*. 1999;**30**:1999
- [8] Strong DM, Fridlaender GE, Tomford WW, et al. Immunological responses in human recipients of osseous and osteochondral allografts. *Clinical Orthopaedics*. 1996;**326**: 107-114
- [9] Keating JF, McQueen MM. Substitutes for autologous bone graft in orthopaedic trauma. *Journal of Bone and Joint Surgery*. British Volume (London). 2001;**83**:3-8
- [10] De Long, JR WG, Einhorn TA. Koval Ketel bone grafts and bone grafts substitutes in orthopaedic trauma surgery. A critical analysis. *Journal of Bone and Joint Surgery*. 2007; **89A**:649-658
- [11] Einhorn TA, Lane JM, Burstein AH, et al. The healing of segmental bone defect induced by 11 demineralized bone matrix: A radiographic and biomechanical study. *Journal of Bone and Joint Surgery*. 1984;**66**:274-279
- [12] Tuli SM, Srivastava TP, Sharma SV, Goel SS, Gupta D, Khanna S. The bridging of large osteoperiosteal gaps using Decalbhone. *International Orthopaedics*. 1988;**12**:119-124
- [13] Goel SC, Tuli SM, Singh HP, Sharma SV, Saraf SK, Srivastava TP. Allogenic decalbhone in the repair of benign cystic lesion of bone. *International Orthopaedics*. 1992;**16**:176-179
- [14] Sethi A, Agarwal K, SEthi S, Kumar S, Marya SK, Tuli SM. Allograft in the treatment of benign cystic lesions of bone. *Archives of Orthopaedic and Trauma Surgery*. 1993; **112**:167-170
- [15] Gupta AK, Kumar K, Kumar P. Decalcified allograft in repair of lytic lesions of bone: A basis of bone bank in developing countries. *Indian Journal of Orthopaedics*. 2016; **50**:427-433

