

We are IntechOpen, the world's leading publisher of Open Access books Built by scientists, for scientists

6,900

Open access books available

186,000

International authors and editors

200M

Downloads

Our authors are among the

154

Countries delivered to

TOP 1%

most cited scientists

12.2%

Contributors from top 500 universities



WEB OF SCIENCE™

Selection of our books indexed in the Book Citation Index
in Web of Science™ Core Collection (BKCI)

Interested in publishing with us?
Contact book.department@intechopen.com

Numbers displayed above are based on latest data collected.
For more information visit www.intechopen.com



Distraction Osteogenesis in Oral and Craniomaxillofacial Reconstructive Surgery

*Firdaus Hariri, Siok Yoong Chin, Jonathan Rengarajoo,
Qi Chao Foo, Siti Nur Nabihah Zainul Abidin
and Ahmad Fadhli Ahmad Badruddin*

Abstract

Distraction osteogenesis (DO) is a tissue engineering method to regenerate new bone. The application of DO in the field of oral and craniomaxillofacial surgery has provided a promising alternative as it can be integrated with conventional surgical technique for bone lengthening or expansion. This technique has the advantages of providing superior amount of bone lengthening thus eliminating the need of autogenous graft and donor site morbidity, can be applied in young patients and allows simultaneous expansion of the surrounding soft tissues. In this chapter, we provide a comprehensive overview of the background history and development of DO which is based on Ilizarov technique, along with its basic principles, indications, classification of DO devices and protocol in craniomaxillofacial bone lengthening or expansion. Its clinical applications which include alveolar DO, mandible DO, maxilla DO, transport DO and craniofacial DO are clarified. This technique however requires proper understanding of clinical and technical components to avoid potential complications which include relapse, infection, adjacent structure injury, device failure and other complications. The emerging results of research and advances in DO are further elaborated at the end of this chapter.

Keywords: distraction osteogenesis, craniomaxillofacial, craniofacial surgery, bone lengthening, osteodistraction

1. Introduction

Distraction osteogenesis (DO) is a tissue engineering method and can be integrated with various craniomaxillofacial surgical techniques to generate new bone via stretching the surgically osteotomized bone with the aid of a mechanical device that is designed to control both the traction rate and the movement vector. This technique utilizes the fundamental healing properties of the human body by inducing regeneration and remodeling of callus between osteotomized site, also known as distraction gap. Callus between the distraction gap will be stretched with the aid of the distraction device to apply a uniform traction force thus allowing formation of new bone. Distraction osteogenesis does not only cause creation of new bone but also stimulates a process called neohistogenesis, where the surrounding soft tissue simultaneously expand and cover the newly formed callus.

The evolution of DO technique in clinical application which was first introduced in orthopedics field has now been widely applied as treatment alternative in cranio-maxillofacial region particularly for the management of congenital and acquired complex craniofacial structural defects. These complex structural defects involve conditions such as severely atrophic alveolar ridge, micrognathia (small mandible) or maxillary hypoplasia leading to respiratory issue as well as complex craniofacial deformities causing restriction of intracranial space and potential eye problems. The application of DO allows superior structural expansion and bone lengthening to restore the important functional discrepancies associated with these deformities.

2. History

Most novel approach in medical field evolved from the requirement of its clinical demand. Based on ancient records, Hippocrates was the first to come up with ideas of bone fracture reduction and stabilization. **Table 1** below summarizes the evolving history of DO.

In craniomaxillofacial region, the first clinical application of DO was reported by McCarthy in 1992 for mandibular lengthening. The success of mandibular lengthening has paved ways for many other craniomaxillofacial DO indications involving other regions such as the alveolar ridge, maxilla, and midface, as well as in cranial vault expansion.

3. Principles of distraction osteogenesis

3.1 Basic principles

In a normal fracture healing, soft callus formation (callotasis) allows the fracture site to heal. With this principle, DO involves the manipulation of this callus in the distraction chamber for structural lengthening before calcification occurs.

Corticotomy is a process where an osteotomy to the cortical layer of the bone is performed in order separate the segments while at the same time preserving the blood supply to the bone from the medulla and periosteum. Distraction rate in DO

Year	Surgeon	Advancement
1860	Dr. Angell [2]	Threaded jackscrew attached to both premolar transpalatally to obtain expansion over the maxillary suture
1905	Codivilla	Femoral bone extension using axial forces – serial application of casts that we pulled with the aid of the bed frame traction.
1927	Abbot	Replaced the multiple cast with pins inserted on the femur and used springs to aid in distraction
1948	Allan	Screw device was incorporated to control the rate of distraction (technique was abandoned due to multiple complications)
1950	Ilizarov [3, 4]	Corticotomy with minimal insult to the surrounding blood supply and using tension ring fixators to control distraction
1973	Snyder et al.	Mandibular lengthening in a canine animal model
1992	McCarthy et al.	First series of successful distraction in human mandible – the start of distraction osteogenesis technique for craniofacial deformities

Table 1.
The history and evolution of distraction osteogenesis [1].

describes the distance in millimeter (mm) in which the bone is moved per day and distraction rhythm describes the frequency of device activation per day.

Distraction osteogenesis comprises of three sequential phases; latency, distraction and consolidation phase which is distinct in every aspect. These phases are simplified in the illustration below (**Figure 1**).

- a. Latency phase: A time period which is required for the formation of callus. Ilizarov suggested 5–7 days, but this depends on the microvasculature and physiological state of bone formation over the distraction site. At cellular level, there is hypoxia occurring over the osteotomized structure inducing angiogenic respond and migration of mesenchymal cells to help produce collagen synthesis. Latency period should be short enough to prevent calcification and long enough for adequate callus formation.
- b. Distraction phase: To achieve target bone growth, the rigid distraction device needs to be activated as per suggested protocol. The device is activated via turning axial screw with a movement of 0.25–0.5 mm (depends on the system used) per turn. The success of the distraction depends on the rate and frequency of the distraction. If the distraction is carried out fast by increasing the rate and frequency it may lead to ischemia at the cellular level causing malunion over the distraction site. In contrary, reduced rate and frequency may lead to early ossification, thus indirectly causing complication to the distraction. Clinicians worldwide tend to keep the frequency to 2–4 times of activation daily with the target of 1.0–1.5 mm distraction rate per day. Histologically, 10–14 days post distraction, osteoid synthesis starts at the margin of the osteotomized bone adjacent to the blood vessels [5]. At around 3 weeks post distraction, progressive calcification starts to form bone spicules.

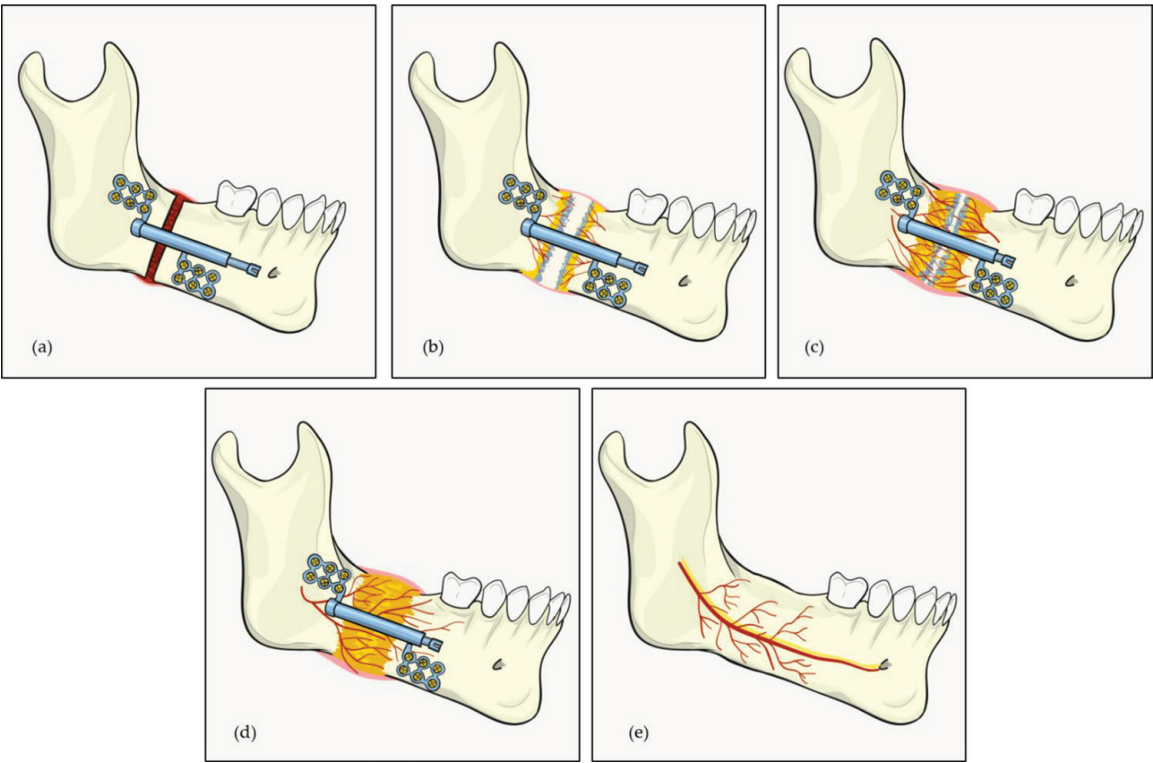


Figure 1.
The phases of distraction osteogenesis. (a) Latency period in which hematoma formation occurs following osteotomy which is later replaced by granulation tissue. (b) During distraction period, bone gap is progressively increased with osteogenesis at the margin of distraction gap. (c) Osteogenesis extend to the Centre of the gap during consolidation phase. (d) Maturation of the ossification in the distraction chamber in late consolidation period. (e) Bone remodeling and continuity of alveolar canal after completion of distraction osteogenesis.

c. Consolidation phase: This phase entails a long period of immobilization where the stretched callus is allowed to mature with the support of the device, keeping the callus in a stretched and stable position as well as preventing cartilaginous intermediate. Remodeling starts by allowing the formation of lamella bone with bone marrow elements over a period of time. The duration of the consolidation phase is around 4–12 weeks with 8 weeks being the average. Clinically, it is suggested that the consolidation phase is kept at twice as long as the activation phase and the timing of the consolidation period depends on the location of the distraction site and rate of bone metabolism [6].

Even though there is a variation of value for latency phase, rate and rhythms of distraction as well as duration of consolidation phase, most protocols are based on Ilizarov principle and in addition, tailored specifically according to the site of distraction, type of device used, surrounding soft tissue resistance and rate of bone metabolism. Meticulous planning using 3-dimensional surgical model (**Figure 2**) with a simulated activation will help gauge the required length of distraction as well as anticipating potential complications that may arise throughout the treatment.

3.2 Classification of distractor devices

Distractor devices are generally classified as external or internal. External device is bone-borne, consisting of fixation clamps and distraction rods which are attached to the bone by percutaneous pins. Internal device can be placed subcutaneously or intraorally, and subdivided into bone-borne, tooth-borne or hybrid (a combination of bone-borne and tooth-borne).

The devices are available in different vectors of distraction. Most commonly used is unidirectional or single vector distractor. There are also bidirectional, multidirectional

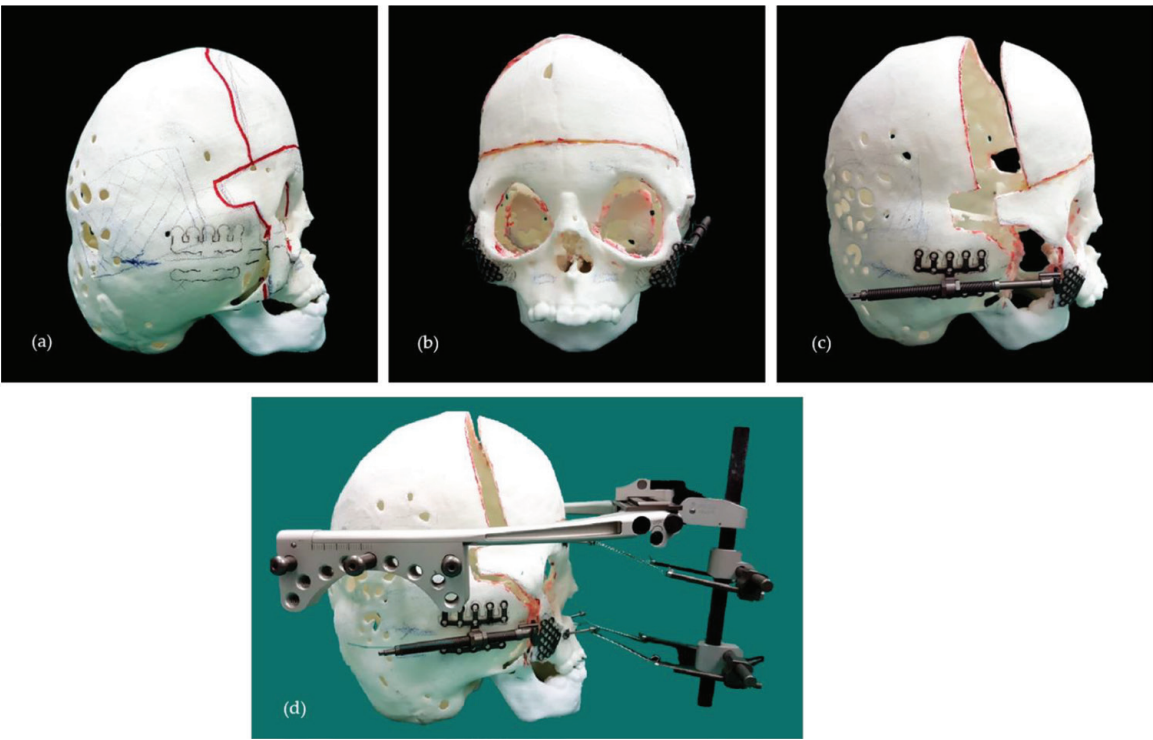


Figure 2. Surgical simulation for DO procedure using stereolithography (STL) model for craniofacial distraction in AP direction. (a) Red line markings indicate the planned osteotomy line. (b) Placement of internal devices at zygoma area bilaterally, parallel in the horizontal plane. (c) Distraction simulation on STL model to confirm correct direction and final position of distracted midfacial bone. (d) Placement of external device to distribute the distraction forces equally to supraorbital and maxillary region, therefore increasing the distraction stability.

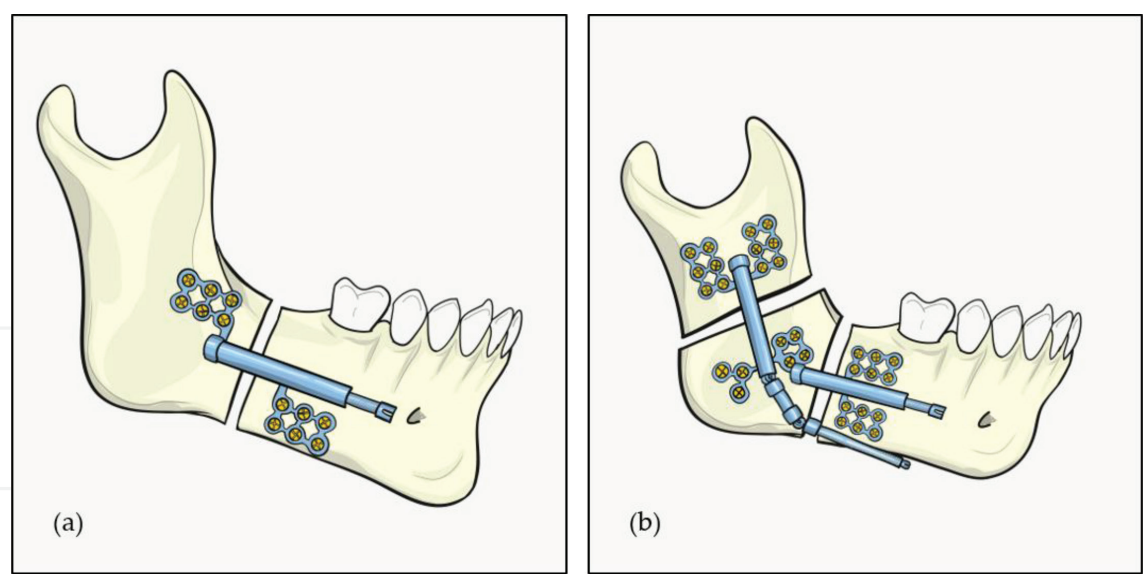


Figure 3.
Different designs for distractor devices according to its vector. (a) Unidirectional distractor (b) Bidirectional distractor.

and curvilinear distractors (**Figure 3**). External device allows better vector control in multidirectional lengthening with adjustment possible during the distraction period [7]. Internal devices carry less morbidity but both types of distractor device are associated with their own complications as described later in this chapter.

The choice of distractor depends on the site of device application, vector of distraction path, magnitude of movement, patient’s factors such as age, medical comorbidities, financial as well as surgeon’s preference. The advantages and disadvantages of external and internal distractor devices [8, 9] are described in **Table 2** below.

3.3 Indications

Generally, DO in craniomaxillofacial region is indicated for superior bone lengthening, expansion or augmentation in which, conventional methods may have limitations. The direction of augmentation or expansion may vary from vertical, anterior–posterior (AP), transverse or multi-directional.

In pediatric population, DO is used in syndromic craniosynostosis cases where there is a functional need to increase the size of intracranial volume and orbital cavities to relieve increased intracranial pressure (ICP) and severe exorbitism,

	Advantages	Disadvantages
External device	Multidirectional lengthening with angular adjustment possible during distraction	Patient apprehension to wear bulky external devices
	Relatively simple to apply intraoperatively	Potential permanent facial scarring
	Easy for patient to activate	
	Can be removed without the need for second operative procedure	
Internal device	Absence of facial scars	Design limitations due to limited size of device and restricted access to oral cavity
	Inconspicuous nature of device	
	Better stability of device to bone	

Table 2.
Advantages and disadvantages between external and internal distractor.

respectively. Obstructive sleep apnea (OSA) resulting from midfacial retrusion or hypoplastic mandible is another indication for DO in children.

In adult patients with severe mandibular or maxillary deficiency in which correction cannot be achieved via conventional orthognathic surgery, DO is recommended. It is also used for correction of hemifacial microsomia and in bone transport technique, for example to reconstruct a hypoplastic or resected mandibular condyle.

Distraction of atrophic alveolar ridges can be performed to increase the width or height of alveolar bone, hence creating adequate bone for dental implant insertion without the need for autogenous bone graft. These indications are summarized in **Table 3**.

3.4 Protocol

There is a wide variation in the protocol of craniomaxillofacial distraction. Following osteotomy, latency period ranges from 3 to 7 days [10]. Standard activation rate is 1 mm per day. Faster rate may cause incomplete osteogenesis or fibrous union while slower rate may result in premature ossification [11].

However, successful distraction in pediatric population has been reported with latency period as little as 24 hours [12, 13], owing to significant vascularity and healing potential in young bone. In addition, distraction of 2 mm per day is proven safe and provide similar success rate as 1 mm per day in children younger than 12 months [14].

Rhythm of activation can be adjusted based on manufacturer’s design of activation rod. One full turn may represent 0.35, 0.5 or 1.0 mm. Therefore, amount of desired daily bone lengthening can be divided throughout the day instead of single activation to produce higher bone quality in terms of volume and architecture. Amid this, an experimental study by Djasim et al. [15] concluded that an increase in rhythm from one to three activations daily does not create significantly more bone. With the advent of automated device for continuous distraction, it allows bone fill at faster distraction rate compared to discontinuous distraction [16].

Site of DO	Direction of DO	Conditions
Mandible	Vertical (Ridge)	Severely atrophic ridge
	Width (Ridge)	Knife edge ridge
	Lengthening (Body)	Micrognathia
	Vertical (Ramus)	Hemifacial microsomia
	Transverse (Symphysis)	Micrognathia in transverse
Maxilla	Vertical (Ridge)	Severely atrophic ridge
	Advancement	Maxillary hypoplasia in AP (craniofacial syndrome, cleft maxilla)
	Transverse	Maxillary hypoplasia in transverse
Craniofacial	Posterior expansion	Syndromic craniosynostosis (increased in ICP)
	Fronto-orbital	Syndromic craniosynostosis (increased in ICP, severe exorbitism)
	Monobloc	Syndromic craniosynostosis (increased in ICP, severe exorbitism, OSA)
Other: Transport Reconstructed jaw	Vertical	Facial cleft
	Anterior–posterior	Zygoma
	(AP)	Severe alveolar ridge defect (trauma, post-ablative)
	Vertical	Vascularized or non-vascularized reconstructed jaw (e.g. fibula, iliac, etc.)

Table 3.
Summary of indications for DO.

Period of consolidation is based upon the length of bony distraction. An experimental study on dog mandible by Smith et al. [17] demonstrated that minimum time for bone regenerate to mineralize is 6–8 weeks, however they suggested that this period should be extended up to 10 or 12 weeks in human population. The authors also discussed that the Ilizarov protocol which was based on long bone lengthening of allowing 2 days of consolidation for each millimeter of distraction does not apply in craniomaxillofacial bone. As craniomaxillofacial bone distraction is shorter in length as compared to lower limb distraction, it is less mineralized at the beginning of consolidation period therefore needing a longer consolidation period. Whereas in long bones, due to more length of distraction, mineralization of regenerate would have started during distraction period itself resulting in less regenerate needed to be mineralized during consolidation period itself.

Most commonly practiced consolidation period for craniomaxillofacial region is 12 weeks [18, 19]. This duration may be lengthened based on surgeon's clinical judgment such as in syndromic craniosynostosis cases. However, to accommodate patient's and parents' schedule, distraction devices are often removed well past the determined consolidation period.

4. Clinical application

4.1 Alveolar DO

In deficient alveolar bone height for implant placement, DO could increase bone level up to 16 mm at the rate of 1 mm per day (**Figure 4**). However, comprehensive assessment is required in a severely resorbed ridge as minimal thickness for both basal and transport segment are necessary for the fixation of the distractor plates. It is also very important to ensure the lingual or palatal mucosa remains intact to the transport segment for vascularization.

4.2 Mandibular DO

In micrognathia or mandibular hypoplasia in anterior–posterior (AP) direction, DO can be considered when superior mandibular body lengthening is needed

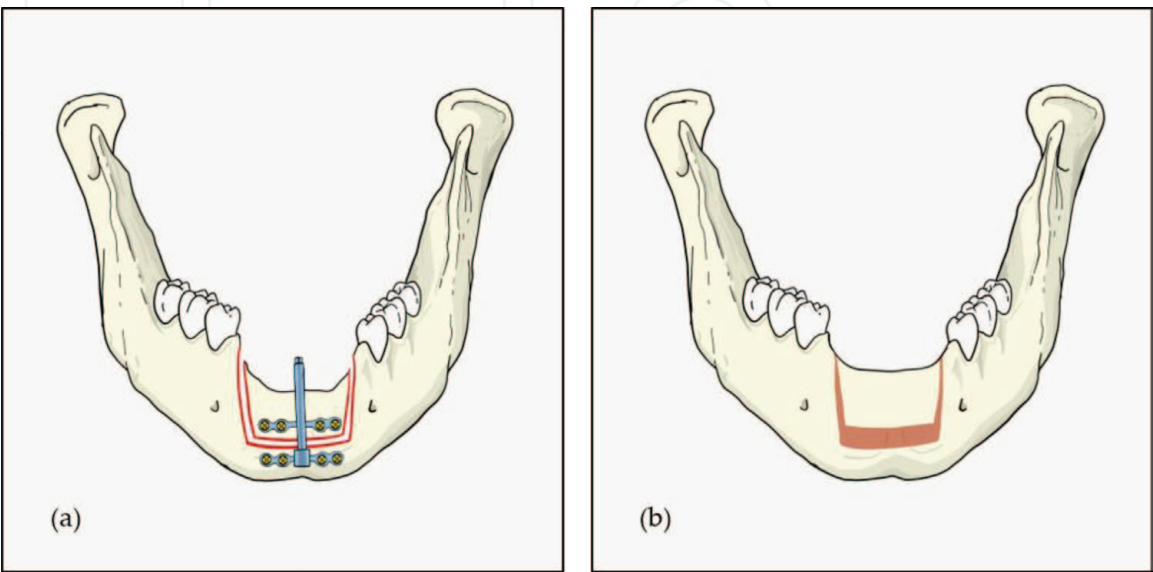


Figure 4. Alveolar DO for atrophic mandibular anterior ridge. (a) Application of internal device for vertical distraction. (b) New height of distracted alveolar ridge.

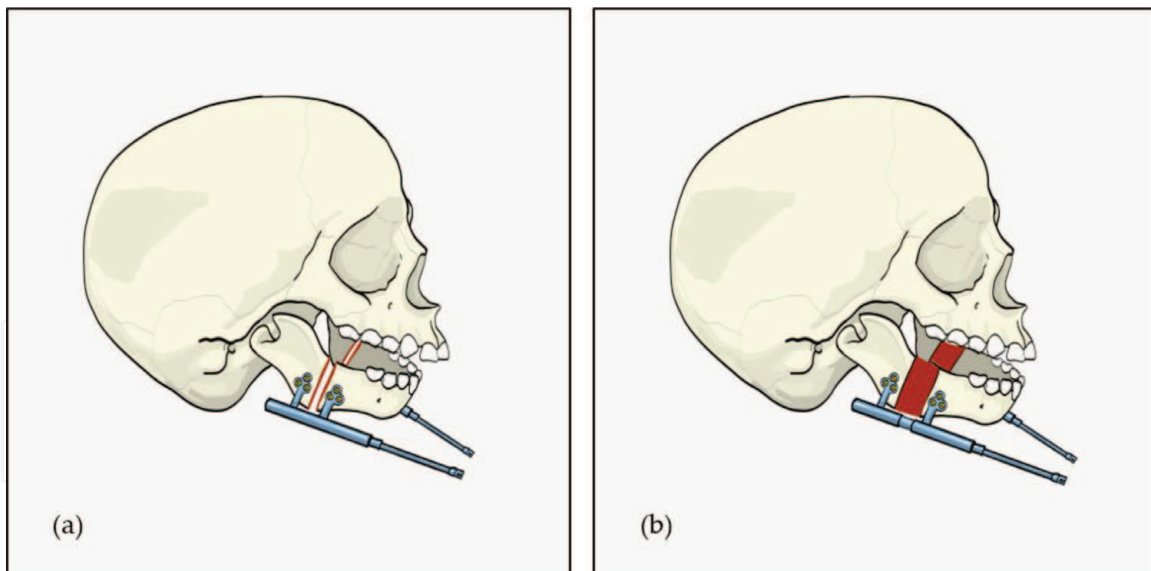


Figure 5.

Example of mandibular DO for hypoplastic mandible. (a) Application of internal distractor device in parallelism for bilateral mandibular lengthening. (b) Distracted mandible in AP direction.

(**Figure 5**). In comparison, a conventional bilateral sagittal split osteotomy may allow up to 10 mm of jaw lengthening while up to 30 mm advancement could be achieved with DO subjected to the size of device [20].

Mandibular DO is often indicated in cases of OSA secondary to conditions such as Treacher Collins syndrome and non-syndromic micrognathia. Improvement in apnea hypopnea index (AHI) score could be seen after 15 mm of DO and the distraction could continue up to 25 mm until an acceptable AHI of less than 5 is achieved [20]. However, the determination of distraction vector is paramount as deviated mandibular arch position at the end of distraction procedure may lead to severe malocclusion. Precaution is also needed intra-operatively as the osteotomy carries the risk of inferior dental nerve injury.

4.3 Maxillary DO

This technique can be applied for maxillary advancement in patients with OSA secondary to severe maxillary or midface hypoplasia (**Figure 6**). Other condition such as cleft maxillary hypoplasia may also need superior segmental advancement to correct the class III jaw discrepancy. Traditional Le Fort I osteotomy with superior advancement may carry the risk of significant relapse due to scar formation and soft tissue memory [21]. DO allows controlled soft tissue expansion and consolidation period thus reducing this problem.

4.4 Transport DO

Transport DO can be indicated in a condition where significant defect is presence (**Figure 7**). Defect can be secondary to post-ablative procedure such as in maxillectomy, huge cyst enucleation or congenital condition such as in facial cleft. Comprehensive planning is important as the pre-determination of osteotomy design and vector is paramount in ensuring the right position for the transported segment is achieved at the targeted opposing bony region. The challenging aspect of transport DO is to ensure the vascularity and maintaining an intact distraction chamber as failure to do so may lead to transport segment resorption resulting to a more severe defect.

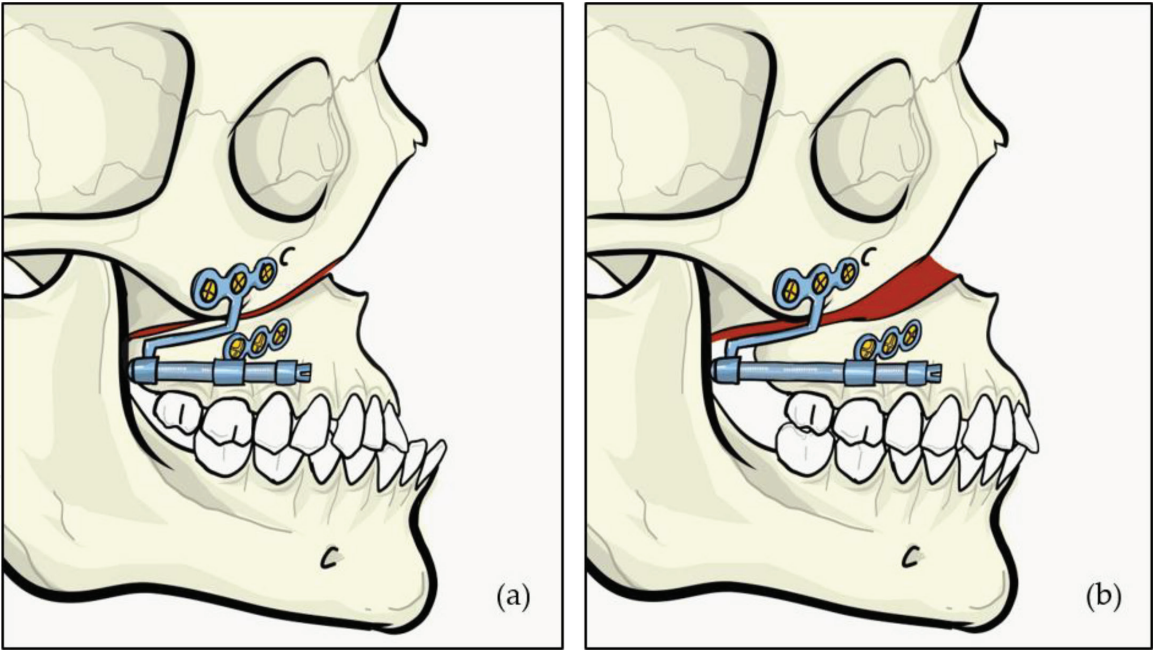


Figure 6.
Example of maxillary DO hypoplastic maxilla. (a) Application of internal distractor device following osteotomy. (b) Distracted maxilla in AP direction.

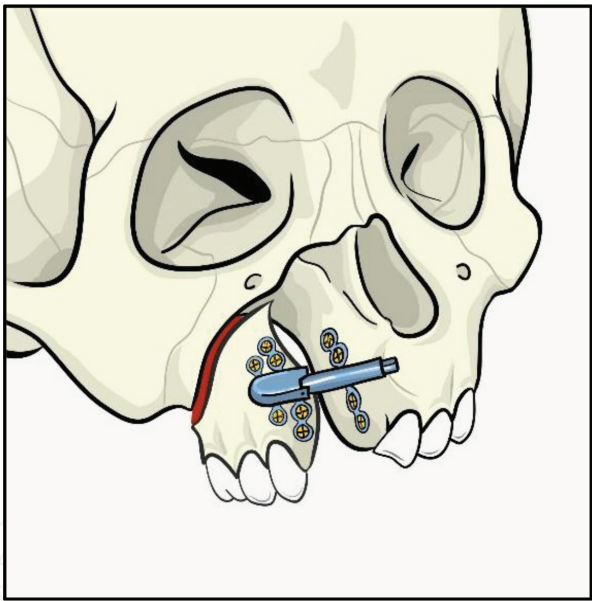


Figure 7.
Application of transport DO to reconstruct a defect in the right maxillary bone.

4.5 Craniofacial DO

Complex congenital craniofacial cases such as syndromic craniosynostosis may cause serious functional impairment (**Figure 8**). These conditions include Crouzon, Apert and Pfeiffer syndrome in which patients may suffer serious functional problems associated to increased ICP, severe exorbitism and OSA secondary to structural growth abnormality related to the early fusion of cranial sutures.

Patients with these problems often require massive segmental expansion of the skull and midface region to decompress the restricted intracranial space, achieving orbital protection and eyelid closure as well as opening up the nasopharyngeal space to treat the respective functional issues. Devices used for these cases may either be an external distractor device or internal devices or a combination of both [22].

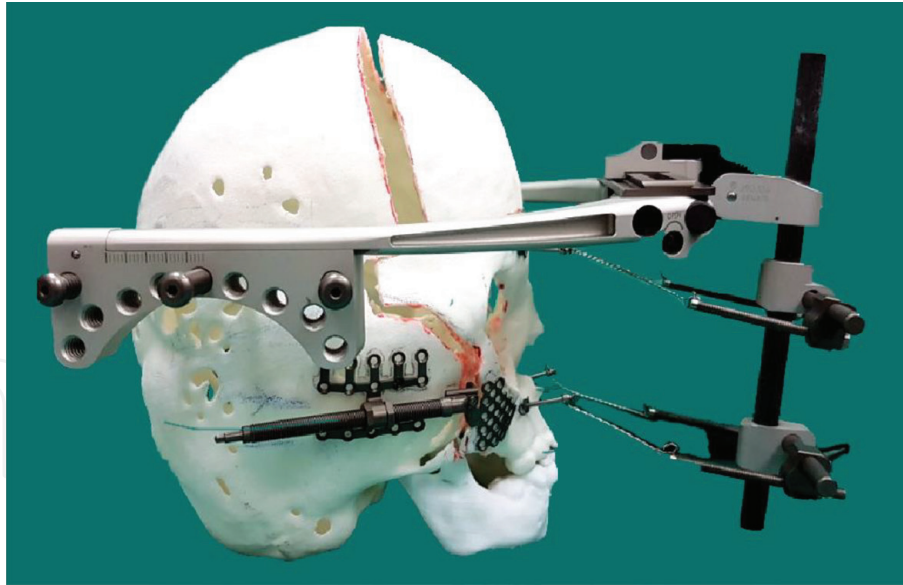


Figure 8.

Craniofacial DO in a Pfeiffer syndrome patient incorporating external and internal devices. External device in which the head frame is fixed at parietal region using percutaneous cranial pins uses pulling mechanism by wires at supraorbital and maxillary regions to advance the bone. Internal device at zygoma area uses pushing mechanism to push the bone forward. Combination of these two mechanisms provide a stable distraction of the midfacial bone with equal distribution of forces. Despite its huge size, this external device is made of lightweight aluminum, titanium and carbon fiber components for patient comfort.

5. Complications

Ever since the clinical application of DO in craniofacial region by McCarthy in 1992, this technique has been widely used to improve the morphology of the facial skeleton in patients with congenital or acquired deformities. The gradual bone distraction that leads to the regeneration of bone and simultaneous neohistogenesis eliminates the need for bone grafting procedures, thus minimizing the morbidities in the treatment of craniofacial deformities [23]. Literature cites that the complication in relation to DO is much similar to that of the other standard treatment procedures, which is up to 40% [24].

From the literature, there are numerous methods in describing complication of DO. In 1990, Paley has described problems, obstacles and complications in limb lengthening by Ilizarov technique. In 2002, Neyt et al. has adopted Paley's classification for transpalatal DO cases [25]. As for craniofacial region, Mofid et al. [26] reviewed 3278 cases and classified complications into five major categories: (1) technical failure of the distraction process, (2) injury to a vital structure, (3) failure to guide the distraction process along the appropriate vector, (4) infection and (5) 'other'.

In 2002, after reviewing 70 cases of bilateral mandibular distraction osteogenesis, van Strijen et al. [27] has divided complications into three groups: (1) intra-operative, (2) intradistraction and (3) post distraction. In 2014, Mahdah et al. [28] has adopted this classification and then further divided it into device-related and non-device related. Cheung et al. [29] has described almost similar classification in which they divided the complications into stages namely: intraoperative, latency period, active distraction and consolidation. Shetye et al. [30] reported a stratification system for mandibular osteogenesis in which incidents related to hardware or hard and soft tissue were subdivided into minor, moderate, and major.

Agarwal [31] used the same method as written by Cherkashin and Samchukov by separating the unfavorable result into error and complications. An error is an inattentive action that results in a deviation of the course of treatment thereby

leading to the development of a complication whereas a complication is an unexpected deviation from the treatment plan that without appropriate correction will lead to worsening of the existing, development of a new or recurrence of the initial pathologic process. Complications of distraction can be further categorized into two categories, technical complications and specific complications.

In a systemic review paper on complications of mandibular DO, an index was developed to standardized classification that is more detailed with regards to the relevant clinical situation and possible further treatment and is more widely applicable for use by clinicians [25].

The severity and frequency of complications that may occur is correlated with the extent of the surgery. Overall, DO at craniomaxillofacial region is relatively safe. The rate of published complications in DO can vary from 27.7–40% [29]. From literature review, average percentage of complications for alveolar DO was 36.3% [32], mandibular DO ranges from 20.5% to 35.6% [33] and cumulative percentage at craniofacial region was found to be 35.6 percent [26]. Percentage of the above-mentioned complications are listed in **Table 4**.

There are few rare complications reported related to this field. Hariri et al. [23] has reported a case of eye exodeviation with limited abduction during monobloc Le Fort III DO. With regards to mandibular DO, a case of severe temporal bone resorption after mandibular DO [38] was reported and in 2017, two cases of temporomandibular joint ankylosis after early mandibular DO [39] were noted. Many of these complications can be avoided with meticulous technique and planning, but early recognition will optimize the outcomes for both patients and their family [40].

Authors (years)	Types of complications	Incidence (%)
Master et al. [33]	Mandibular DO	
	Relapse	64.8
	Tooth injury	22.5
	Hypertrophic scarring	15.6
	Nerve injury	11.4
	Infection	9.5
	Inappropriate distraction vector	8.8
	Device failure	7.9
	Fusion error (Premature consolidation & fibrous union)	2.4
	Temporomandibular joint injury	0.7
Mazzonetto et al. [32]	Alveolar DO	
	Infection	14.5
	Paresthesia	10.9
	Tipping of transport disk	5.5
	Hyperplasia	5.5
	Dehiscence	5.5
	Fracture of screw	1.8
	Fracture of device	1.8
	Osteotomy revision	1.8
	Inadequate length	1.8

Authors (years)	Types of complications	Incidence (%)
Mofid et al. [26]	Craniofacial DO	
	(a) <i>Technical failure of the distraction process</i>	
	Compliance	4.7
	Hardware failure	4.5
	Device dislodgement	3.0
	Premature consolidation	1.9
	Pain preventing distraction	1.0
	Fibrous union	0.5
	(b) <i>Damage to vital structure</i>	
	Inferior alveolar nerve injury	3.6
	Tooth bud injury	1.9
	Facial nerve injury	0.4
	Spinal cord injury (quadripareisis)	<0.1
	Maxillary sinus perforation	<0.1
	Parotid injury(fistula)	<0.1
	(c) <i>Failure to guide distraction along appropriate vector</i>	
	Inappropriate vector of distraction associated with single-vector distractor	8.8
	Inappropriate vector of distraction associated with single-vector distractor	7.2
	(d) <i>Infection</i>	
	Pin-tract infection or loosening	5.2
	Infection not requiring removal	2.9
	Infection requiring removal	0.9
	Osteomyelitis	0.5
	(e) <i>Others</i>	
	Chronic pain after distraction	<0.1
	Midface seroma	<0.1
Nout et al. [34]	Rigid external distraction	
	Frame migration (1/4 cases was traumatic migration)	28.6
	Pain at pin site	7.1
	Pin loosening	42.9
	Skin infection	7.1
	Scarring	4.8
	Decubitus of forehead	4.7
	Severe motivation problem	4.7
	Pin migration complicated with local skull fracture	4.7

Authors (years)	Types of complications	Incidence (%)
McMillan et al. [35]	Posterior calvarial distraction	
	CSF leaks	14
	Bleeding	2
	Incomplete osteotomies and gull winging	6
	Infection	18
	Minor wound breakdown	4
	Mechanical problem	12
	Serious complications	
	Torcula hemorrhage	2
	Cerebritis	2
	Dural tear	2
Dunaway et al. [36]	Frontofacial distraction	
	Mortality	<1
	Significant blood loss (greater than 1 blood volume)	5.3–9.1
	CSF leak	2–20
	Frontal bone necrosis	3–20
	CSF fistula	6.2
	Seizure	6.2
	Major blood loss	6.2
	Zygomatic fracture	6.2
von Bremen et al. [37]	Mandibular midline distraction	
	Instable screw	4
	Re-osteotomy	3
	Scar stricture	2
	Tooth fracture	2
	Mandibular swelling	1
	Abscess	1
	Recession	1

Table 4.
Percentage of complications in craniomaxillofacial DO.

6. Research and advances

Distraction osteogenesis offers many advantages in craniofacial surgical practice, such as the ability of correction of the deformity without the need for a bone graft [26]. Because of the advances in surgical technique and technical equipment, the indications of the DO have significantly widened [41].

There has been an explosion of distractor designs available on the market in the last 20 years. Further development is limited by the intermittent mode of distraction activation and the mechanical age may soon be replaced by biological modulation of distraction for compromised tissues and hosts. Emerging results of distraction from some new research directions are further elaborated below [29].

6.1 Automated continuous DO

Currently available distraction devices are patient and surgeon dependent. The patient must adjust the manual control two or more times daily, often over long periods. Because non-compliance and device failure are the leading causes of treatment failure, the patient requires numerous clinical visits to ensure proper distractor activation [42]. Considering these drawbacks, many research groups are working to design novel distraction devices that expand automatically and continuously. An automated mechanism would eliminate the need for patient compliance and decrease the frequency of post-operative visits for patient supervision. At the moment, the types of these devices are classified into three categories based on the method of power: hydraulic, motor-driven and spring-mediated [43–47]. It has also been reported that continuous distraction may be carried out at rates up to 2 mm per day with formation of bone in the gap. This would allow greater distraction distances in a shorter period, without sacrificing bone quality [43].

6.2 Administration of growth factors to enhance bone healing

The major disadvantage of DO is the long distraction and consolidation period, which contributes to the risk of complications such as local infection (**Figure 9**) which may jeopardize the effectiveness of DO application clinically. The major objectives in current DO research focus on the acceleration of new bone formation and shortening the treatment period. Great efforts have been made by researchers and clinicians to promote bone formation via local and systematic administration of angiogenic and osteogenic growth factors or cytokines, including bone morphogenic protein (BMP), transforming growth factor beta (TGF- β), platelet-derived growth factor (PDGF), vascular endothelial growth factor (VEGF), and fibroblast growth factor (FGF). Among all these growth factors and cytokines, BMPs play the most important role in bone healing and regeneration by inducing the osteogenic differentiation of mesenchymal stem cells and have a synergistic effect with the angiogenic growth factor, VEGF [29]. On a rabbit model of mandibular lengthening, recombinant human (rh) BMP-2 has been demonstrated to enhance bone ossification at both routine and

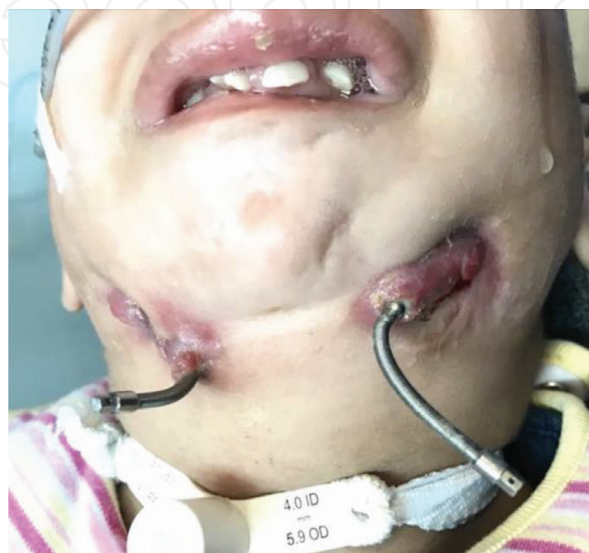

Figure 9.
Common complication of a localized infection at the exit wound of mandibular distractor's activation rods.

rapid distraction rates. The addition of rhBMP-2 was able to compensate for the rapid distraction rate in DO [46]. Nevertheless, the effectiveness of delivery method, cost and biological safety still require further investigation [29].

6.3 Development in distraction devices

In a case of complex mandibular deformities, a complex multivector extraoral device with multiple joints is used in order to achieve movements in all desired plane. This device may be difficult for the patient and surgeon to manage and errors often occur during active distraction. The use of a semi-buried curvilinear distraction device (Synthes CMF, West Chester, PA), with 3-dimensional treatment planning, is a potentially powerful tool to correct complex mandibular deformities [48].


In conclusion, DO is a reliable technique to regenerate new bone and can be considered as an effective alternative in oral and craniomaxillofacial reconstructive surgery. The technique application requires comprehensive understanding of its principles, appropriate pre-surgical planning, expert technical handling, reasonably good surgical skills, and a holistic post-surgical care in preventing potential complications.

Author details

Firdaus Hariri*, Siok Yoong Chin, Jonathan Rengarajoo, Qi Chao Foo,
Siti Nur Nabihah Zainul Abidin and Ahmad Fadhli Ahmad Badruddin
Department of Oral and Maxillofacial Clinical Sciences, Faculty of Dentistry,
University of Malaya, Kuala Lumpur, Malaysia

*Address all correspondence to: firdaushariri@um.edu.my

IntechOpen

© 2018 The Author(s). Licensee IntechOpen. This chapter is distributed under the terms of the Creative Commons Attribution License (<http://creativecommons.org/licenses/by/3.0>), which permits unrestricted use, distribution, and reproduction in any medium, provided the original work is properly cited. 

References

- [1] Hegab AF, Shuman MA. Distraction Osteogenesis of the Maxillofacial Skeleton: Biomechanics and Clinical Implications. Vol. 1. 2012. p. 509
- [2] Angell E. Treatment of irregularity of the permanent or adult teeth. *Dental Cosmos*. 1860;1:540-544, 99-600
- [3] Ilizarov GA. The tension-stress effect on the genesis and growth of tissues. Part I. The influence of stability of fixation and soft-tissue preservation. *Clinical Orthopaedics and Related Research*. 1989;238:249-281
- [4] Ilizarov GA. The tension-stress effect on the genesis and growth of tissues: Part II. The influence of the rate and frequency of distraction. *Clinical Orthopaedics and Related Research*. 1989;239:263-285
- [5] McCarthy JG, Stelnicki EJ, Mehrara BJ, Longaker MT. Distraction osteogenesis of the craniofacial skeleton. *Plastic and Reconstructive Surgery*. 2001;107:1812-1827
- [6] Swennen G, Schliephake H, Dempf R, Schierle H, Malevez C. Craniofacial distraction osteogenesis: A review of the literature. Part 1: Clinical studies. *Journal of Oral and Maxillofacial Surgery*. 2001;30:89-103
- [7] Carls FR, Sailer HF. Seven years clinical experience with mandibular distraction in children. *Journal of Cranio-Maxillofacial Surgery*. 1998;26:197-208
- [8] Andrade N, Gandhewar T, Kalra R. Development and evolution of distraction devices: Use of indigenous appliances for distraction osteogenesis-an overview. *Annals of Maxillofacial Surgery*. 2011;1:58-65
- [9] Chin M, Toth BA. Distraction osteogenesis in maxillofacial surgery using internal devices: Review of five cases. *Journal of Oral and Maxillofacial Surgery*. 1996;54:45-53
- [10] Nada RM, Sugar AW, Wijdeveld MG, Borstlap WA, Clauser L, Hoffmeister B, et al. Current practice of distraction osteogenesis for craniofacial anomalies in Europe: A web based survey. *Journal of Cranio-Maxillofacial Surgery*. 2010;38:83-89
- [11] Al Ruhaimi KA. Comparison of different distraction rates in the mandible: An experimental investigation. *International Journal of Oral and Maxillofacial Surgery*. 2001;30:220-227
- [12] Lin SJ, Roy S, Patel PK. Distraction osteogenesis in the pediatric population. *Otolaryngology-Head and Neck Surgery*. 2007;137:233-238
- [13] Higuera S, Cole P, Stephenson JB, Hollier L. Distraction rate and latency: Factors in the outcome of paediatric maxillary distraction. *Journal of Plastic, Reconstructive & Aesthetic Surgery*. 2009;62:1564-1567
- [14] Breik O, Tivey D, Umapathysivam K, Anderson P. Does the rate of distraction or type of distractor affect the outcome of mandibular distraction in children with micrognathia? *Journal of Oral and Maxillofacial Surgery*. 2016;74:1441-1453
- [15] Djasim UM, Wolvius EB, Van Neck JW, Van Wamel A, Weinans H, Van Der Wal KGH. Single versus triple daily activation of the distractor: No significant effects of frequency of distraction on bone regenerate quantity and architecture. *Journal of Cranio-Maxillofacial Surgery*. 2008;36:143-151
- [16] Peacock ZS, Tricomi BJ, Murphy BA, Magill JC, Kaban LB, Troulis MJ. Automated continuous distraction

osteogenesis may allow faster distraction rates: A preliminary study. *Journal of Oral and Maxillofacial Surgery*. 2013;**71**:1073-1084

[17] Smith SW, Sachdeva RCL, Cope JB. Evaluation of the consolidation period during osteodistraction using computed tomography. *American Journal of Orthodontics and Dentofacial Orthopedics*. 1999;**116**:254-263

[18] Yamaguchi K, Imai K, Fujimoto T, Takahashi M, Maruyama Y, Sakamoto H, et al. Cranial distraction osteogenesis for syndromic craniosynostosis: Long-term follow-up and effect on postoperative cranial growth. *Journal of Plastic, Reconstructive & Aesthetic Surgery*. 2014;**67**:e35-e41

[19] Alkan A, Ozer M, Bas B, Bayram M, Celebi N, Inal S, et al. Mandibular symphyseal distraction osteogenesis: Review of three techniques. *International Journal of Oral and Maxillofacial Surgery*. 2007;**36**:111-117

[20] Baur DA, Meyers AD. Distraction osteogenesis of the mandible. Available from: <https://emedicine.medscape.com/article/844837-overview>

[21] Shah AR, Meyers AD. Distraction osteogenesis of the maxilla. Available from: <https://emedicine.medscape.com/article/844742-overview>

[22] Hariri F, Azmi MN, Bahuri NF, Abdullah NA, Rahman ZA, Ganesan D. Crouzon syndrome: A case series of craniomaxillofacial distraction osteogenesis for functional rehabilitation. *Journal of Oral and Maxillofacial Surgery*. 2017;**76**:646.e1-646e12

[23] Hariri F, Cheung LK, Rahman ZA, Ramasamy SN, Ganesan D. A rare orbital complication of eye exodeviation with limited abduction during monobloc Le Fort III distraction osteogenesis. *The*

Cleft Palate-Craniofacial Journal. 2015;**52**:489-493

[24] Balaji SM. Identifying complications in distraction osteogenesis. *Annals of Maxillofacial Surgery*. 2017;**7**:3-4

[25] Verlinden CR, van de Vijfeijken SE, Jansma EP, Becking AG, Swennen GR. Complications of mandibular distraction osteogenesis for congenital deformities: A systematic review of the literature and proposal of a new classification for complications. *International Journal of Oral and Maxillofacial Surgery*. 2015;**44**:37-43

[26] Mofid MM, Manson PN, Robertson BC, Tufaro AP, Elias JJ, Vander Kolk CA. Craniofacial distraction osteogenesis: A review of 3278 cases. *Plastic and Reconstructive Surgery*. 2001;**108**:1003-1114. discussion 115-107

[27] van Strijen PJ, Breuning KH, Becking AG, Perdijk FB, Tuinzing DB. Complications in bilateral mandibular distraction osteogenesis using internal devices. *Oral Surgery, Oral Medicine, Oral Pathology, Oral Radiology, and Endodontics*. 2003;**96**:392-397

[28] Mahdah S, Bariah K, Azmi MN, Saleh I, Nabil S, Hariri F. Distraction osteogenesis in the craniomaxillofacial region. Part II: Peri-operative issues, surgical procedure, complications and reliability. *Malaysian Journal of Oral Maxillofacial Surgery*. 2015;**13**:1-10

[29] Cheung LK, Chua HDP, Hariri F, Lo J, Ow A, Zheng LW. Chapter 48: Distraction osteogenesis. In: Andersson L, Kahnberg K-E, Pogrel MA, editors. *Oral and Maxillofacial Surgery*. 1st ed. West Sussex, United Kingdom: Wiley-Blackwell; 2010. pp. 1027-1059

[30] Shetye PR, Warren SM, Brown D, Garfinkle JS, Grayson BH, McCarthy JG. Documentation of the incidents associated with mandibular distraction:

Introduction of a new stratification system. *Plastic and Reconstructive Surgery*. 2009;**123**:627-634

[31] Agarwal R. Unfavourable results with distraction in craniofacial skeleton. *Indian Journal of Plastic Surgery*. 2013;**46**:194-203

[32] Mazzonetto R, Allais M, Maurette PE, Moreira RW. A retrospective study of the potential complications during alveolar distraction osteogenesis in 55 patients. *International Journal of Oral and Maxillofacial Surgery*. 2007;**36**:6-10

[33] Master DL, Hanson PR, Gosain AK. Complications of mandibular distraction osteogenesis. *The Journal of Craniofacial Surgery*. 2010;**21**:1565-1570

[34] Nout E, Wolvius EB, van Adrichem LN, Ongkosuwito EM, van der Wal KG. Complications in maxillary distraction using the RED II device: A retrospective analysis of 21 patients. *International Journal of Oral and Maxillofacial Surgery*. 2006;**35**:897-902

[35] McMillan K, Lloyd M, Evans M, White N, Nishikawa H, Rodrigues D, et al. Experiences in performing posterior calvarial distraction. *The Journal of Craniofacial Surgery*. 2017;**28**:664-669

[36] Dunaway DJ, Britto JA, Abela C, Evans RD, Jeelani NU. Complications of frontofacial advancement. *Child's Nervous System*. 2012;**28**:1571-1576

[37] von Bremen J, Schäfer D, Kater W, Ruf S. Complications during mandibular midline distraction. *The Angle Orthodontist*. 2008;**78**:20-24

[38] Feng S, Zhang Z, Shi L, Tang X, Liu W, Yin L, et al. Temporal bone resorption: An uncommon complication after mandibular distraction. *The*

Journal of Craniofacial Surgery. 2015;**26**:e185-e187

[39] Galie M, Candotto V, Elia G, Clauser LC. Temporomandibular joint ankylosis after early mandibular distraction osteogenesis: A new syndrome? *The Journal of Craniofacial Surgery*. 2017;**28**:1185-1190

[40] Winters R, Tatum SA. Craniofacial distraction osteogenesis. *Facial Plastic Surgery Clinics of North America*. 2014;**22**:653-664

[41] Norholt SE, Jensen J, Schou S, Pedersen TK. Complications after mandibular distraction osteogenesis: A retrospective study of 131 patients. *Oral Surgery, Oral Medicine, Oral Pathology, Oral Radiology, and Endodontics*. 2011;**111**:420-427

[42] Goldwasser BR, Papadaki ME, Kaban LB, Troulis MJ. Automated continuous mandibular distraction osteogenesis: Review of the literature. *Journal of Oral and Maxillofacial Surgery*. 2012;**70**:407-416

[43] Kessler P, Neukam FW, Wiltfang J. Effects of distraction forces and frequency of distraction on bony regeneration. *The British Journal of Oral & Maxillofacial Surgery*. 2005;**43**:392-398

[44] Schmelzeisen R, Neumann G, von der Fecht R. Distraction osteogenesis in the mandible with a motor-driven plate: A preliminary animal study. *The British Journal of Oral & Maxillofacial Surgery*. 1996;**34**:375-378

[45] Mofid MM, Inoue N, Tufaro AP, Vander Kolk CA, Manson PN. Spring-mediated mandibular distraction osteogenesis. *The Journal of Craniofacial Surgery*. 2003;**14**:756-762

[46] Zheng LW, Cheung LK, Ma L, Wong MC. High-rhythm automatic driver for bone traction: An experimental

study in rabbits. *International Journal of Oral and Maxillofacial Surgery*. 2008;**37**:736-740

[47] Ayoub AF, Richardson W, Barbenel JC. Mandibular elongation by automatic distraction osteogenesis: The first application in humans. *The British Journal of Oral & Maxillofacial Surgery*. 2005;**43**:324-328

[48] Kaban LB, Seldin EB, Kikinis R, Yeshwant K, Padwa BL, Troulis MJ. Clinical application of curvilinear distraction osteogenesis for correction of mandibular deformities. *Journal of Oral and Maxillofacial Surgery*. 2009;**67**:996-1008