

We are IntechOpen, the world's leading publisher of Open Access books Built by scientists, for scientists

6,900

Open access books available

186,000

International authors and editors

200M

Downloads

Our authors are among the

154

Countries delivered to

TOP 1%

most cited scientists

12.2%

Contributors from top 500 universities



WEB OF SCIENCE™

Selection of our books indexed in the Book Citation Index
in Web of Science™ Core Collection (BKCI)

Interested in publishing with us?
Contact book.department@intechopen.com

Numbers displayed above are based on latest data collected.
For more information visit www.intechopen.com



Clinical Assessment of Lesions Compressing the Visual Pathway

Lawan Abdu

Additional information is available at the end of the chapter

<http://dx.doi.org/10.5772/intechopen.80277>

Abstract

There is a close relationship between the visual pathway and other neuro endocrine structures. Tumours and other compressive lesions could often present with visual impairment and/or finite visual field changes. Careful clinical assessment could aid in accurate diagnosis and treatment. Pituitary gland lies in the fossa located in the sphenoid bone. Growth hormone, adreno cortico tropic hormone, and prolactin secreting adenomas could present with respective endocrine features. Optic chiasmal compression by pituitary adenoma is an indicator of suprasellar extension. Meningioma and vestigial remnant craniopharyngioma arise in the parasellar region and can compress on different parts of the optic chiasma often giving rise to classical radiological appearances and visual field changes. This includes atheroma and aneurysm of the internal carotid artery impinging on the temporal chiasma exerting direct pressure and counterpressure on the contralateral side. Others are aneurysms of the precommunicating section of the anterior cerebral artery and those of the posterior communicating artery. Compressive lesions of the visual pathway require a multi-disciplinary approach involving neurosurgeon, endocrinologist as well as the ophthalmologist.

Keywords: pituitary, adenoma, parasellar, tumours, visual, pathway

1. Introduction

The visual pathway is the anatomic channel of communication from the retinal photoreceptors where vision signals commence to their termination at the visual cortex. The photoreceptors synapse with bipolar cells (which constitute the outer nuclear layer) at the outer plexiform layer. The bipolar cells synapse with the ganglion cells at the inner plexiform layer. The ganglion cells constitute the retinal nerve fibre layer (RNFL) that enters the optic disc and collectively with

the addition of apparent pupillary fibres forms the optic nerve. The ganglion nerve fibres pass through and constitute the optic nerve that has about 2.4 million afferent axons [1]. The optic nerve has an intra-ocular, intra-orbital, intra-canalicular and intra-cranial components measuring 1, 25–30, 6 and 10 mm, respectively. The optic canal entrance is about 5.5–6.5 mm and a difference of >1 mm between the two sides is unusual. The optic chiasma is about 6 mm wide and 12 mm long, it is tilted about 45° with the anterior portion being lower than posterior. In most instances (80%), the chiasma lies directly over the sella turcica. The sella is a bony cavity that houses the pituitary gland. The anterior and posterior clinoid processes bound the entrance and a piece of dura matter called the diaphragm sellae covers it. Posteriorly, the chiasma is related to the anterior part of the third ventricle (optic recess). On either side lies the extra cavernous part of the internal carotid artery. Chiasma is related above to the anterior perforating substance. Retinal nerves on reaching the optic chiasma are arranged such that fibres from the temporal half of the retina continue and join the optic tract on the same side without crossing. Inferior nasal fibres that serve superior temporal visual field cross in the anterior part of the chiasma. Such crossing fibres loop into the proximal part of the contralateral optic nerve (forming a Wilbrand's knee) before ascending the optic tract. The superior nasal fibres (that sub-serve the inferior nasal field of vision) cross the chiasma posteriorly before ascending the contralateral optic tract. Macular fibres cross throughout the chiasma. Crossed nerve fibres terminate at layers 1, 4, 6 of the lateral geniculate body while uncross fibres terminate at layers 2, 3, 5. From the lateral geniculate body arise the geniculocalcarine nerve fibres that form the optic radiations that terminate in the visual cortex. As the fibres proceed more posteriorly, those from corresponding retinal points are brought close together thus ensuring binocular single vision and stereopsis.

2. Intra-orbital and intra-canalicular optic nerve compression

The optic nerve can be compressed in the intra-orbital portion by inflammatory conditions of the orbit such as idiopathic inflammatory pseudo-tumour and thyroid-related orbitopathy (TRO). TRO is associated with increased orbital volume from extra-ocular muscle enlargement particularly the medial rectus and such occurrence is predictive of compressive dysthyroid optic neuropathy (DON) [2]. DON could precede, occur simultaneously or even after control of symptoms of hyperthyroidism. In the presence of toxic hyperthyroidism, the ocular signs such as lid lag/retraction, proptosis and the typical open staring facies are present in addition to the systemic features. Increased orbital volume leads to restrictive myopathy and pupillary dilation unresponsive to light stimulation is a pointer to optic nerve damage with eventual optic atrophy. This can present with marked reduction in vision even in the absence of exposure keratopathy. After clinical and hormonal evaluation, treatment involves graded and tapered doses of steroids and orbital decompression. Rapamycin, a fibroblast and T cell inhibitor, has been shown to be effective in improving visual acuity, colour plate test and visual fields when dysthyroid orbital inflammation is refractory to steroid and orbital decompression [3].

Intra-canalicular optic nerve may be compressed by optic nerve glioma, meningioma or schwannoma. Although quite rare, isolated optic nerve glioma poses a special challenge in ensuring vision preservation at the same time achieving tumour control [4]. The tumour could present in child or adulthood with progressive painless vision loss and axial proptosis.

There could be a demonstrable apparent pupillary defect and a scotoma on the affected side. The contralateral eye may be normal. Children with sporadic optic pathway glioma have a poorer visual prognosis than those with neurofibromatosis (NF-1) [5]. Diagnosis is based on clinical neuroradiological assessment. Serial scanning is required to detect changes in size and or extent. Chemotherapy is an option to be considered. Pattern visual evoked potential (VEP) and pattern electroretinograms (ERGs) provide early objective indication of optic nerve dysfunction even in the presence of unchanged neuroradiological features [6]. **Figure 1** is a CT scan coronal section of right optic nerve glioma.

2.1. Compression of the optic chiasma by pituitary tumours

The pituitary gland lies in the pituitary fossa, a bony cavity in the sphenoid bone. In most instances, the optic chiasma is positioned directly above the sella turcica. The pituitary gland has an anterior and a posterior portion. The anterior portion has a variety of cells that secrete different hormones. The acidophil cells produce growth hormone (GH), basophil cells produce adrenocorticotrophic hormone (ACTH), while the chromophobe "C"-cells produce prolactin. Tumours secreting luteinizing hormone (LH) and thyroid stimulating hormones (TSH) are extremely rare to deserve a mention. Pituitary tumours have both endocrine and ophthalmological manifestations. Pituitary adenomas represent 15% of primary brain tumours and visual disturbances arising from local mass effect on the visual system are common clinical manifestation [7]. In some instances, more so with younger patients, vision lost is more frequent (39%) followed by endocrine abnormality (21%), and headache (15%). Bitemporal visual field defects were the most prevalent (41%) [8]. Common neuro-ophthalmic manifestations include blurred vision, impairment in colour vision, relative afferent pupillary defect, optic atrophy headache and bitemporal field defect [9]. A study showed that the size of the pituitary adenoma has bearing on its effect as those larger than 2 cm cause defects in vision while those 2 cm or smaller do not cause significant visual impairment [10].

A growth hormone secreting adenoma manifesting before closure of the epiphyseal plate is characterised by gigantism and after puberty it causes acromegaly. Such patients often notice

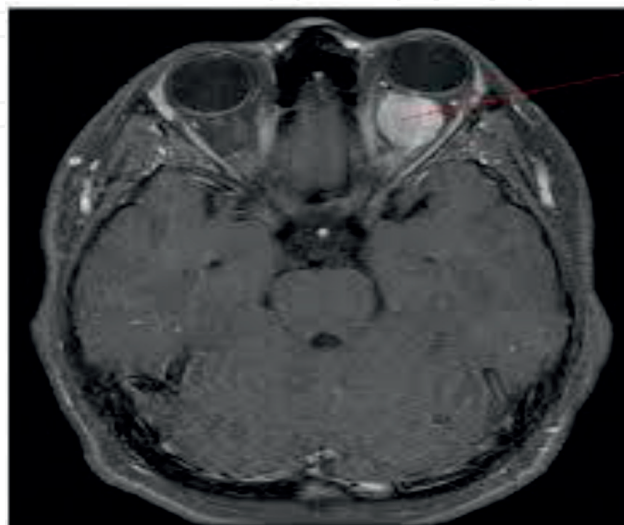


Figure 1. Coronal CT scan showing optic nerve glioma.

their shoe, hat, clothes and ring do not fit. Other features include skin (hyperhidrosis and hirsutism in females), hoarseness of the voice and malocclusion due to jaw enlargement. The clinical features are quite obvious in most instances.

ACTH secreting basophil adenoma is characterised by fat mal-distribution giving rise to hump back and swollen “moon-shaped” face. Other features include skin striations and sign of fluid retention, easy bruising and slow wound healing. In the presence of elevated serum cortisol, the entity is described as Cushing’s syndrome. Such patients are prone to developing diabetes mellitus, hypertension and osteoporosis. A paradoxical rise in GH level is observed in response to oral glucose tolerance test in contrast to normal individuals in whom there is suppression of the hormone to below 2 mU/L.

Chromophobe adenomas are the most common primary intra-cranial tumours and when prolactin secreting is named prolactinoma, the tumour present in early adulthood or middle age. The tumour causes infertility, amenorrhea and galactorrhea in females. Males could present with loss of libido, impotence, infertility and breast signs similar to females.

2.2. Craniopharyngioma

Craniopharyngioma arises from the vestigial remnants of Rathke’s pouch along the path of the pituitary stalk. The tumour present in children with delayed sexual development and dwarfism, and in adults, visual impairment and field defects are common. Craniopharyngioma often causes visual loss due to the tumour’s close relation to the anterior visual pathways [11]. The tumour compresses the chiasma from above and behind affecting the superior nasal fibres and giving rise to bitemporal hemianopia dense inferiorly and progresses clockwise in the left eye and anticlockwise in the right eye. The tumour gives rise to supra sella calcification and may have cystic areas.

In general, some hormone-secreting pituitary tumours may present with endocrine features in the early stages before headache and signs of chiasmal compression manifest. Patient may present with visual impairment which could be progressive in nature. As the tumour expands, it reaches the diaphragma sellae. The dura structure has pain sensing fibres and stretching results in non-specific headache. With further growth, the tumour breaks through the diaphragma and the headache stops. Presence of headache indicates supra sella extension of pituitary tumour. Pituitary tumours compress the chiasma at its anterior portion. Therefore, the inferior nasal fibres are affected first and subsequently the superior nasal fibres. Visual field assessment would reveal a bitemporal hemianopia dense superiorly and progressing anticlockwise in the left eye and clockwise in the right eye as shown in **Figure 2**. Diagnosis is aided by clinical evaluation, perimetry, hormonal assay and radiological investigations.

MRI is the radiological investigation of choice although in resource-scarce sub-Saharan Africa, it is not accessible to most clinicians. Therefore, digital X-ray and CT scan are more readily available and affordable. MRI demonstrates presence of a mass lesion and its relation to the optic chiasma. Coronal section demonstrates contents of the sella turcica, while sagittal sections can be obtained through the chiasma and optic nerve (before and after gadolinium injection which is known to enhance pituitary adenomas), and axial scans. Radiological features with the presence of identifiable and quantifiable space occupying mass which may erode the sellae floor or clinoid




Figure 2. Bitemporal hemianopia dense superiorly.

processes cause widening of the inter clinoid space and may cause supra sellae calcification. Calcification in pituitary adenoma is rare (a report indicates occurrence in 5.6%); therefore, pre-operative radiological calcification should not be a decider regarding surgical intervention [11].

On MRI, craniopharyngioma shows an isodense lesion on T1 images, while cystic components appear hyperintense. It also causes oedema that spread along the optic tracts [12]. For most of the tumours irrespective of the imaging technique use to evaluate the patient, there is a direct link between visual defect and chiasmal compression [13].

2.3. Meningioma

Meningioma that accounts for one-third of primary intracranial tumours [14] typically affects middle-aged women and could arise at the tuberculum, the sphenoid ridge or olfactory groove. Sphenoidal ridge meningioma compresses the optic nerve early if positioned medially. When present in the sphenoid bone and mid-cranial fossa, the vision is affected later and patient may have temporal fullness as a result of reactive hyperostosis.

Tuberculum meningioma (**Figure 3**) compresses proximal part of the ipsilateral optic nerve giving rise to ipsilateral scotoma and a crescent-shaped junctional scotoma in the contra lateral eye due to its effect on the looped crossed inferior nasal fibres (Wilbrand's knee) as illustrated in **Figure 4**. Olfactory groove meningioma affects both vision and sense of smell. CT scan may show new bone formation due to reactive hyperostosis.

2.4. Treatment of pituitary and other parasellar tumours

The type, size, site, nature, presentation and associated clinical complexity of the tumour determine the best modality of treatment. Treatment of growth hormone secreting adenoma is necessary due to associated mortality from metabolic [15], circulatory impairments and cancer [16] apart from visual pathway compression. IGF-1 lowering medications can be used although surgical options like trans-sphenoidal trans-cranial surgery have been in practice. Stereotactic radio surgery (SRS) has been found to be a definitive treatment option for patients with persistent or recurrent acromegaly after surgical resection [17].

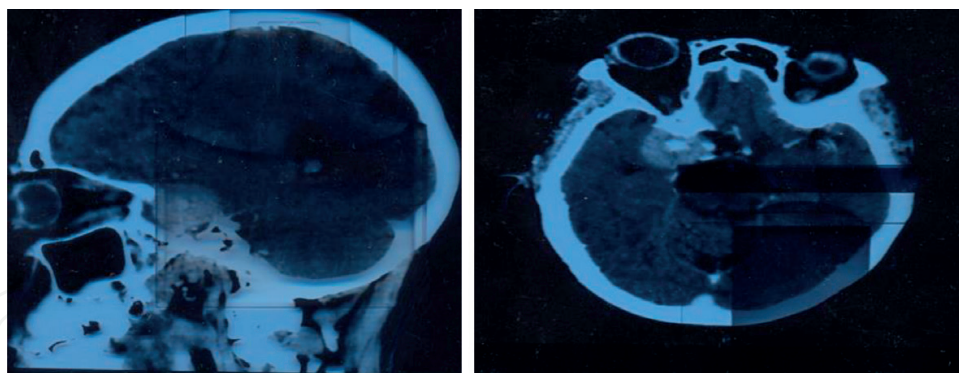


Figure 3. CT scan showing tuberculum sellae meningioma with areas of hyperostosis.

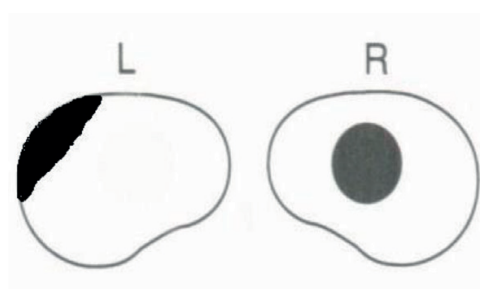


Figure 4. Ipsilateral scotoma with contralateral junctional scotoma.

ACTH secreting pituitary adenoma is amenable to trans-sphenoidal surgery as the first line of treatment. Some patients may not achieve cure, while others have recurrence warranting use of medication such as the recently approved pasireotide, a somatostatin receptor ligand [18].

Traditionally, prolactin-secreting pituitary adenoma is treated with bromocriptine, a dopamine agonist, though the drug has been implicated in predisposing the patient to pituitary apoplexy. This complication is less with cabergoline therapy. Trans-sphenoidal surgery can be performed to relieve visual impairment [19].

Gross total resection of craniopharyngioma is the aim of treatment [20]; failure of which requires adjunct radiotherapy. Intra-cavity radiotherapy using phosphorus-32 (^{32}P) colloid has been tried in cystic craniopharyngioma [21]. There is a reported case of vision recovery after endoscopic transplanum transtuberculum resection of a craniopharyngioma [22].

Meningioma can be an asymptomatic benign disease. Tumour growth is experienced in two-thirds of patients and a third may eventually require neurosurgical interventions. Gamma knife surgery (GKS) can control the tumour clinically and radiologically [23]. Radiotherapy remains one of the most relevant therapeutic options for the treatment patients with meningioma [14].

2.5. Vascular chiasmal compression

The internal carotid artery (ICA) on emerging from the cavernous sinus ascends upwards in close relation to the underneath of the proximal part of the optic nerve. ICA curves posteriorly and upwards on the lateral edge of the optic chiasma. The pre-communicating branch of the

anterior cerebral artery crosses the chiasma close to its junction with the optic nerve. The posterior communicating artery passes backwards under the optic tract to join the posterior cerebral artery. An atheroma of the internal carotid artery can compress the chiasma laterally and also impinge it on the contralateral giving rise to binasal hemianopia and the defect is not often symmetrical as illustrated in **Figure 5**. Aneurysm of the ICA, pre-communicating segment of the anterior cerebral and posterior cerebral arteries, could give rise to binasal hemianopia [24].

2.6. Visual field defects in retrochiasmal pathway lesions

2.6.1. Optic tract

Brain tumours and aneurysm can affect the retrochiasmal visual pathway giving rise to varied visual field defects [25, 26]. The optic tract arises from the posterior aspect of the chiasma and extends posteriorly around the cerebral peduncle to reach the lateral geniculate body (LGB). It consists of crossed nasal fibres and ipsilateral temporal fibres. Compression results in bilateral hemifield loss opposite to the side of the lesion. The homonymous hemianopia may be complete or incomplete but incongruous as nerve fibres from corresponding retinal points are not closely related. Compression of the LGB similarly results in asymmetrical hemianopic visual field defect. The optic tract contains both visual and pupillomotor fibres. The visual fibres terminate at the LGB, while pupillary fibres leave the tract anterior to the LGB pass through the brachium to reach the pretectal nucleus at the level of the superior colliculus. Tract lesion can give rise to afferent pupillary defect, thus the pupil contracts when the unaffected side of the retina is stimulated with light, but not so when the affected hemiretina is stimulated (Wernicke's hemianopic pupil). In clinical practice, this is difficult to demonstrate due to scattering of light shone on the retina unless a pinpoint source of light is used. The ganglion cells from the retina terminate at the LGB; therefore, tract lesion can result in optic atrophy. In this instance, the ipsilateral disc manifests atrophy of the superior and inferior aspects (due to effect on temporal fibres), while the contralateral disc shows atrophy of the nasal and temporal neuroretinal rim "bow tie atrophy" due to effect on the nasal retinal fibres. Typical homonymous hemianopic field loss is shown in **Figure 6**.

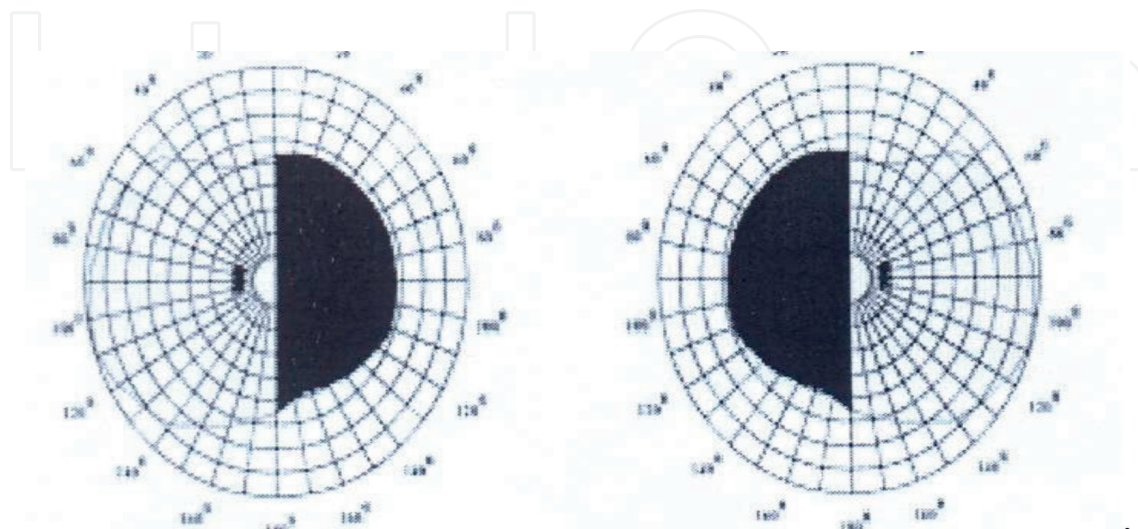


Figure 5. Binasal hemianopia in vascular chiasmal compression.

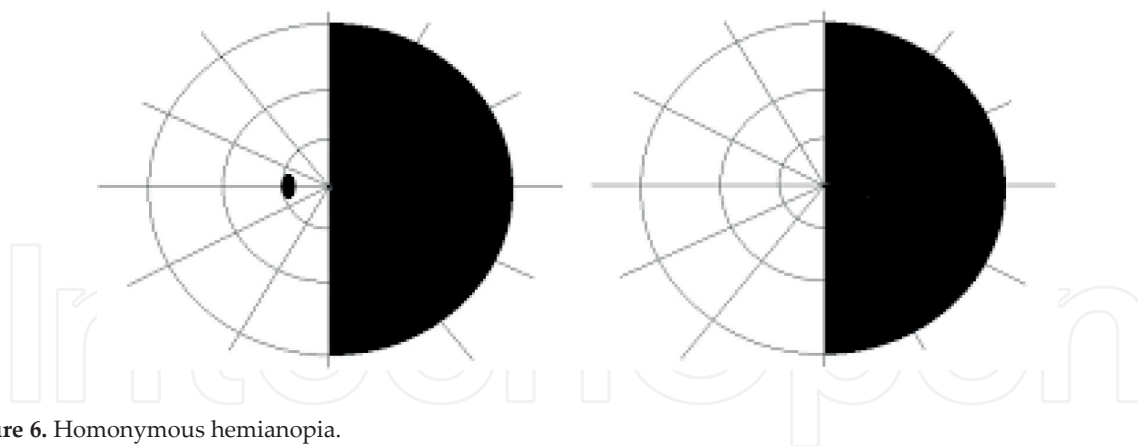


Figure 6. Homonymous hemianopia.

2.6.2. Optic radiations

The geniculocalcarine fibres arise from the LGB to the striate cortex located on the medial aspect of the occipital cortex above and below the calcarine fissure. As the fibres spread posteriorly, nerves from corresponding retinal points are brought close together so that incomplete hemianopia caused by lesions in the posterior radiations is more congruous than those located anteriorly. The middle and posterior cerebral arteries provide dual blood supply to the optic radiations and visual cortex.

2.6.3. Main radiations

The main radiations are related to the occipital horn of the lateral ventricle and the trigone. Compression at this location results in complete homonymous hemianopia. Optokinetic nystagmus (OKN) involves smooth pursuit movement followed by a saccade in the opposite direction of the initial movement as the eye fixate on the next target. In homonymous hemianopia, due to parietal lobe lesions, the smooth pursuit movement towards side of the lesion is defective.

2.6.4. Temporal radiations

The visual defects observed in lesion of the temporal radiations are homonymous superior quadrantanopia (described as “pie in the sky”) illustrated in **Figure 7**. There may be associated




Figure 7. Superior quadrantanopia—“pie in the sky”.

hemiparesis and sensory loss on the affected side due to close relation of the radiations with sensory-motor fibres of the internal capsule.

2.6.5. Anterior parietal radiations

The superior nasal fibres that sub-serve the inferior temporal visual fields pass through the parietal lobe; therefore, lesions of the anterior parietal radiations result in contralateral congruous homonymous inferior quadrantanopia (described as “pie on the floor”) as shown in **Figure 8**.

2.6.6. Striate cortex

Peripheral visual fields are represented anteriorly (supplied by posterior cerebral artery), while central macula vision is posteriorly located lateral to the tip of the calcarine cortex and supplied by a branch of the middle cerebral artery. Anteriorly located lesions of the striate cortex will result in congruous homonymous hemianopia. If the cause has a vascular component, the macular vision is spared as shown in **Figure 9**.

Figure 10 shows congruous macular homonymous hemianopia typical of lesions of the tip of the occipital cortex.

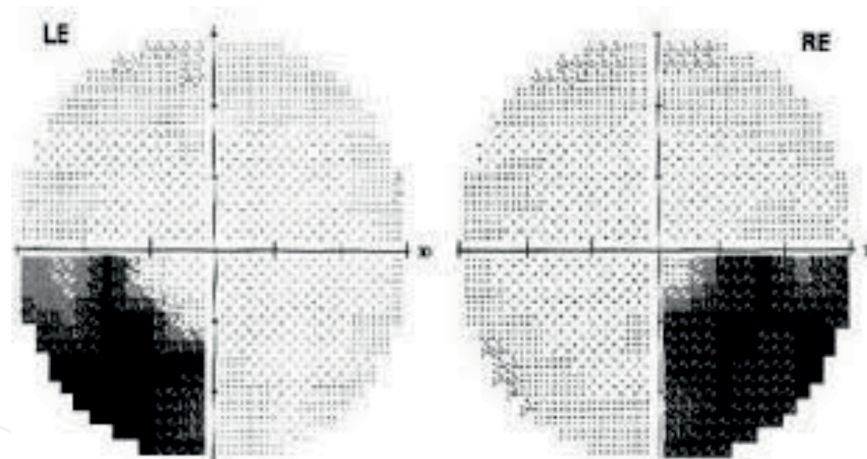


Figure 8. Inferior quadrantanopia—“pie on the floor”.




Figure 9. Congruous homonymous hemianopia with macular sparing.

2.6.7. Conclusion

Compressive lesions affecting the visual pathway could present with variety of visual impairments. Hormone-secreting adenoma can present with endocrine features in addition to visual field changes. **Figure 11** is an illustration of some of different causes and the associated visual fields.

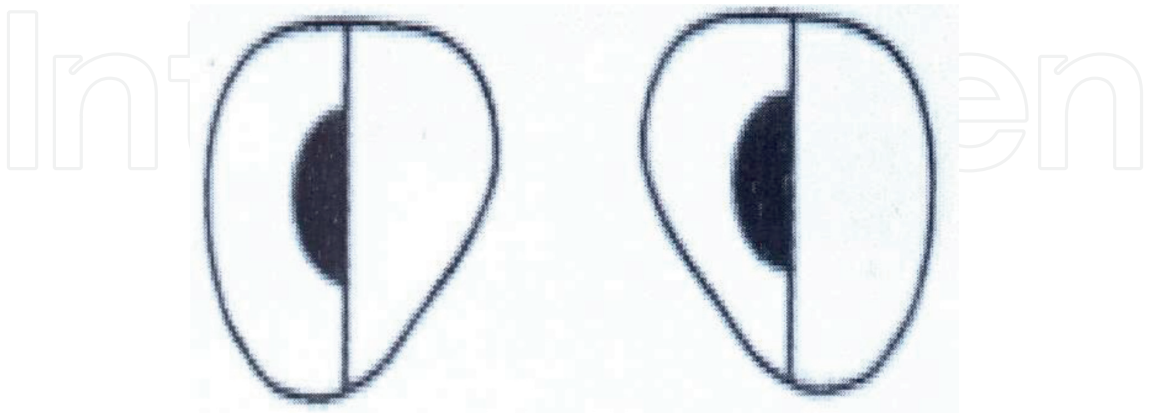


Figure 10. Congruous macular homonymous hemianopia.

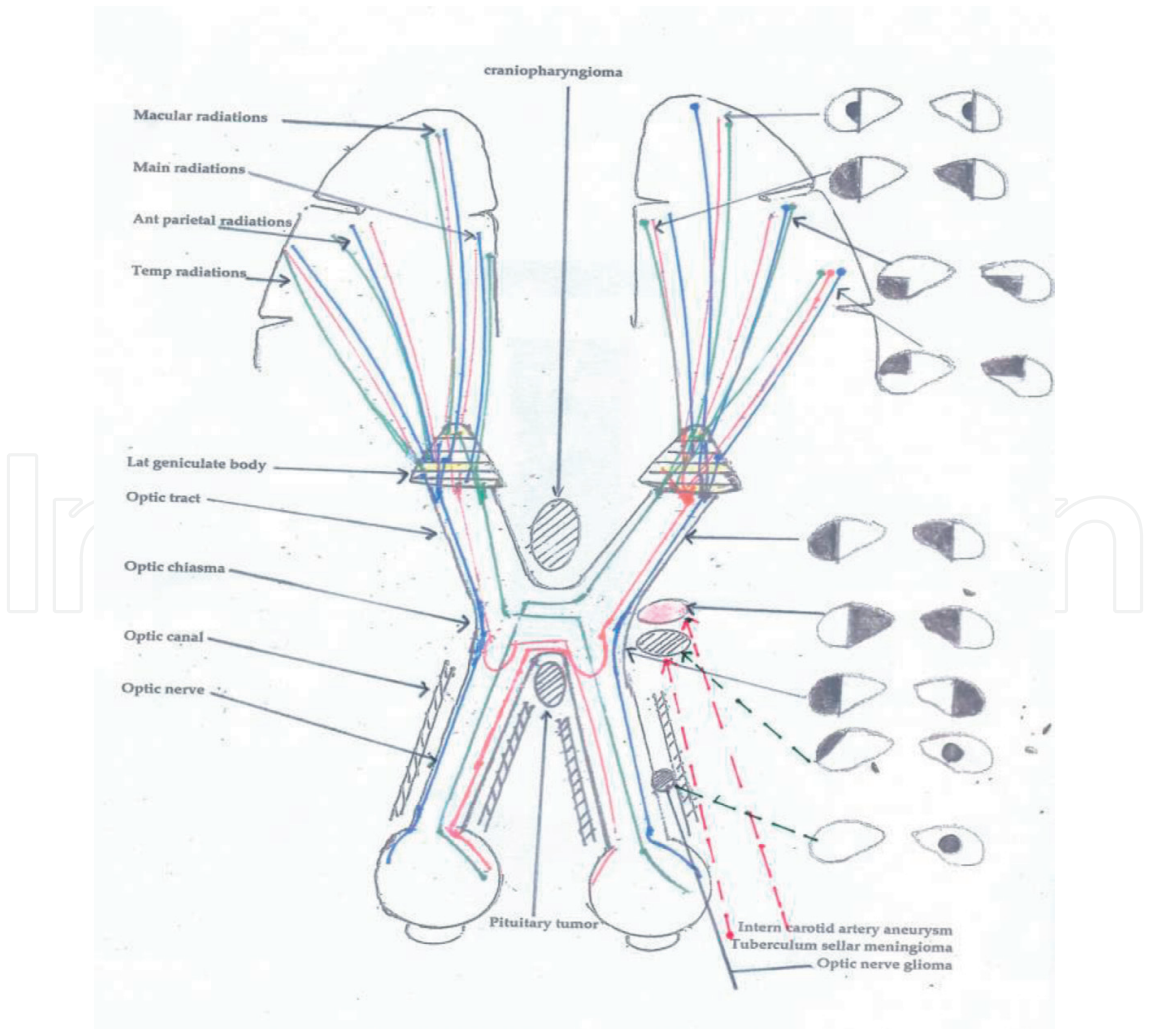


Figure 11. A diagram of the visual pathway showing location of some of the lesions and the associated field changes.

Acknowledgements

Appreciation to my employer Bayero University Kano—Nigeria for creating an enabling academic environment.

Conflict of interest

None.

Author details

Lawan Abdu

Address all correspondence to: lawal1966@yahoo.com

Department of Ophthalmology, Faculty of Clinical Sciences, College of Health Sciences, Bayero University Kano, Nigeria

References

- [1] Jost BJ, Andreas MS, Jens AM, et al. Human optic nerve fiber count and optic disc size. *Investigative Ophthalmology & Visual Science*. 1992;**32**(6):2012-2018
- [2] Weis E, Heran MK, Jhamb A, et al. Quantitative computed tomographic predictors of compressive optic neuropathy in patients with thyroid orbitopathy: A volumetric analysis. *Ophthalmology*. 2012;**119**(10):2174-2178
- [3] Chang S, Perry JD, Kosmorsky GS, et al. Rapamycin for treatment of refractory dys-thyroid compressive optic neuropathy. *Ophthalmic Plastic & Reconstructive Surgery*. 2007;**23**(3):225-226
- [4] Hamideh D, Hoehn ME, Harreld JH, et al. Isolated optic nerve glioma in children with and without neurofibromatosis: Retrospective characterization and analysis of outcomes. *Journal of Child Neurology*. 2018;**33**(6):375-382
- [5] Glaser JS. Topical diagnosis: The optic chiasma. In: Glaser JS, editor. *Neuro-Ophthalmology*. Philadelphia: Lippincott Williams & Wilkins; 1999. p. 99
- [6] Moradi P, Robson AG, Rose GE, et al. Electrophysiological monitoring in a patient with an optic nerve glioma. *Documenta Ophthalmologica*. 2008;**117**(2):171-174
- [7] Fredes F, Undurraga G, Rojas P, et al. Visual outcomes after endoscopic pituitary surgery in patients presenting with preoperative visual deficits. *Journal of Neurological Surgery. Part B, Skull Base*. 2017;**78**(6):461-465
- [8] Ogra S, Nichols AD, Stylli S, et al. Visual acuity and pattern of visual field loss at presentation in pituitary adenoma. *Journal of Clinical Neuroscience*. 2014;**21**(5):735-740

- [9] Tagoe NN, Essuman VA, Fordjuor G, et al. Neuro-ophthalmic and clinical characteristics of brain tumours in a tertiary Hospital in Ghana. *Ghana Medical Journal*. 2015;**49**(3): 181-186
- [10] Ho RW, Huang HM, Ho JT. The influence of pituitary adenoma size on vision and visual outcomes after trans-sphenoidal adenectomy: A report of 78 cases. *Journal of Korean Neurosurgical Association*. 2015;**57**(1):23-31
- [11] Ogiwara T, Nagm A, Yamamoto Y, et al. Clinical characteristics of pituitary adenomas with radiological calcification. *Acta Neurochirurgica*. 2017;**159**(11):2187-2192
- [12] Nagahata M, Hosoya T, Kayama T, et al. Edema along the optic tract: A useful MR finding for the diagnosis of craniopharyngiomas. *AJNR. American Journal of Neuroradiology*. 1998;**19**(9):1753-1757
- [13] Huang WC, Lee LS. Visual field defects in patients with pituitary adenomas. *Zhonghua Yi Xue Za Zhi (Taipei)*. 1997;**60**(5):245-251
- [14] Pinzi V, Bisogno I, Prada F, et al. Radiotherapy of meningioma: A treatment in need of radiobiological research. *International Journal of Radiation Biology*. 2018;**18**:1-23
- [15] Ku CR, Choe EY, Hong JW, et al. No differences in metabolic outcomes between nadir GH 0.4 and 1.0 ng/mL during OGTT in surgically cured acromegalic patients (Observational study). *Medicine (Baltimore)*. 2016;**95**(24):e3808
- [16] Esposito D, Ragnarsson O, Granfeldt D, et al. Decreasing mortality and changes in treatment patterns in patients with acromegaly from a nationwide study. *European Journal of Endocrinology*. 2018;**178**(5):459-469
- [17] Ding D, Mehta GU, Patibandla MR, et al. Stereotactic radiosurgery for acromegaly: An international multicenter retrospective cohort study. *Neurosurgery* 2018 May 10. DOI: 10.1093/neuros/nyy178. [Epub ahead of print]
- [18] Langlois F, Chu J, Fleseriu M. Pituitary-directed therapies for Cushing's disease. *Frontiers in Endocrinology (Lausanne)*. 2018;**1**(9):164. DOI: 10.3389/fendo.2018.00164. eCollection 2018
- [19] Ghadirian H, Shirani M, Ghazi-Mirsaeed S, et al. Pituitary apoplexy during treatment of prolactinoma with cabergoline. *Asian Journal of Neurosurgery*. 2018;**13**(1):93-95
- [20] Guo F, Wang G, Suresh V, et al. Clinical study on microsurgical treatment for cranio-pharyngioma in a single institutional series of 335 patients. *Clinical Neurology and Neurosurgery*. 2018;**167**:162-172
- [21] Chang H, Zhang J, Cao W, et al. Drug distribution and clinical safety in treating cystic craniopharyngiomas using intracavitary radiotherapy with phosphorus-32 colloid. *Oncology Letters*. 2018;**15**(4):4997-5003
- [22] Todeschini AB, Montaser AS, Shahein M, et al. Endoscopic endonasal approach to a suprasellar craniopharyngioma. *Journal of Neurological Surgery. Part B, Skull Base*. 2018;**79**(Suppl 3):S237-S238

- [23] Kim KH, Kang SJ, Choi JW, et al. Clinical and radiological outcomes of proactive gamma knife surgery for asymptomatic meningiomas compared with the natural course without intervention. *Journal of Neurosurgery*. 2018;**18**:1-10
- [24] O'Connell JEA, Du Boulay EDGH. Binasal hemianopia. *Journal of Neurology, Neurosurgery, and Psychiatry*. 1973;**36**(5):697-709
- [25] Rico G, Smith SV, Siddiqui Y, Whyte A, et al. Neuro-ophthalmologic manifestations of cholangiocarcinoma: A case series. *Eye (London, England)*. 2017;**31**(8):1245-1248
- [26] Zorić Geber M, Krolo I, Zrinscak O, et al. Unruptured giant intracranial aneurysm of the internal carotid artery: Late ocular symptoms. *Seminars in Ophthalmology*. 2016; **31**(3):291-294

